UC SOUTHERN REGIONAL LIBRARY FACILITY
G 000 005 923 8



THE

AMERICAN

SYSTEM OF DENTISTRY.

IN TREATISES BY VARIOUS AUTHORS.

EDITED BY

WILBUR F. LITCH, M.D., D.D.S.,

PROFESSOR OF PROSTHETIC DENTISTRY, THERAPEUTICS, AND MATERIA MEDICA IN THE PENNSYLVANIA COLLEGE OF DENTAL SURGERY, PHILADELPHIA.

VOLUME I.

REGIONAL AND COMPARATIVE DENTAL ANATOMY, DENTAL HISTOLOGY, AND DENTAL PATHOLOGY.

WITH FIVE HUNDRED AND THIRTY-SEVEN ILLUSTRATIONS AND SIX PLATES.

N. Y. COLLEGE

PHILADELPHIA:

LEA BROTHERS & CO.

1886.

N. Y. UNIVERSITY
209 E. 23rd ST.
N. Y. CITY

Entered according to Act of Congress, in the year 1886, by
LEA BROTHERS & CO.,
in the Office of the Librarian of Congress at Washington. All rights reserved.

WESTCOTT & THOMSON,
Stereotypers and Electrotypers, Philada.

WILLIAM J. DORNAN,
Printer, Philada.

PREFACE.

No fact is now more fully recognized than that a clear, intelligent, and comprehensive knowledge of any subject can best be communicated by one who has a working acquaintance with it or has made it an object of special research. To secure for the several departments of this work writers thus informed, and willing to take from needed rest and give to toil the time necessary for the systematic presentation of their specialized knowledge, was not the least of the difficulties which attended the inception of this undertaking. How well those who assumed this labor have accomplished their several tasks these pages must testify.

In judging of their work, the fact must be borne in mind that those textual abridgments which are essential in a compend or manual would fall far short of the obvious requirements of a systematic treatise. Throughout the preparation of these volumes this distinction has been recognized, and, while prolixity and useless verbiage have been avoided, space has been given for the fullest possible exposition of the subjects taught. Above all, it has been desired that each contribution should be a teaching paper; hence no detail necessary to make clear the meaning of the writer has been spared.

This particularity of method has been specially emphasized in the sections devoted to technical processes and manipulative procedures; and as a full comprehension of their intricate details can rarely be attained through so imperfect an agency as a merely verbal description the text has been lavishly furnished with illustrations largely made from original drawings and models prepared by the various contributors.

Upon certain points in histology, pathology, and therapeutics some divergence of views will be noted. The Editor has not sought to enforce absolute harmony of doctrine, or assumed to commit this work to a partisan advocacy of either side of questions which are still *sub judice*. Recognizing the fact that the profession at large still differ upon many questions of great although not vital importance, and that

in practice the same end may often be attained by widely different means, he has deemed it the wiser course to allow freedom of statement to all, sure that at last the truer knowledge will prevail.

It has been found impossible in a work of this character to define the limitations of each paper so sharply and rigidly as to avoid all duplication of matter. It will, however, be found that if writers traverse for short distances the same field, they do it from different directions and survey it from varying standpoints, often to the reader's profit; so that within reasonable limits this defect in the method of literary collaboration is not an unmixed evil. It has, however, been restricted to the narrowest possible bounds.

The Editor cannot close this preface without extending to the contributors his heartfelt thanks for their generous co-operation. He trusts and believes that they will find abundant reward for their unselfish labors in that satisfaction which ever comes from a good work well wrought, and in the approval of their professional brethren everywhere.

His special thanks are due to Dr. JAMES W. WHITE, Editor of the *Dental Cosmos*, and also to Professors C. N. PEIRCE, T. C. STELLWAGEN, HENRY LEFFMANN, and ALBERT P. BRUBAKER, for counsel and help which have been of the highest value in the editorial supervision of this work.

THE EDITOR.

June, 1886.

CONTRIBUTORS TO VOLUME I.

BLACK, G. V., M. D., D. D. S.,

Professor of Pathology in the Chicago College of Dental Surgery, Chicago.

BRUBAKER, ALBERT P., A. M., M. D., D. D. S.,

Professor of Physiology and Pathology in the Pennsylvania College of Dental Surgery; Demonstrator of Physiology in the Jefferson Medical College, Philadelphia.

CRYER, M. H., M. D., D. D. S.,

Chief of Clinic of Oral Surgery, Medico-Chirurgical College of Philadelphia.

DALL, W. H.,

Curator of the Department of Mollusks, National Museum, Washington, D. C.

SUDDUTH, W. XAVIER, M. D., D. D. S., F. R. M. S.,

Demonstrator of Dental Histology in the Philadelphia Dental College, Philadelphia.

TRUMAN, JAMES, D. D. S.,

Professor of Dental Pathology, Therapeutics, and Materia Medica in the Dental Department of the University of Pennsylvania.

WORTMAN, JACOB L., M. D.,

Anatomist to the U. S. Army Medical Museum, Washington, D. C.

CONTENTS OF VOLUME I.

PAGE

PREFACE 3

PART I.

REGIONAL ANATOMY.

REGIONAL ANATOMY, Etc. By M. H. Cryer, M.D., D.D.S. 35

LYMPHATIC VESSELS OF THE HEAD AND NECK. By Albert P. Brubaker, A.M., M.D., D.D.S. 325

PART II.

DENTAL ANATOMY.

THE TEETH OF THE INVERTEBRATES. By W. H. Dall 337

THE TEETH OF THE VERTEBRATES. By Jacob L. Wortman, M.D. . 351

PART III.

EMBRYOLOGY AND DENTAL HISTOLOGY.

EMBRYOLOGY AND DENTAL HISTOLOGY. By W. Xavier Sudduth, M.D., D.D.S. 519

PART IV.

GENERAL AND DENTAL PATHOLOGY.

GENERAL PATHOLOGY. By G. V. Black, M.D., D.D.S. 661

DENTAL CARIES. By G. V. Black, M.D., D.D.S. 729

PATHOLOGY OF THE DENTAL PULP. By G. V. Black, M.D., D.D.S. 829

DISEASES OF THE DENTAL PULP, AND THEIR TREATMENT. By James Truman, D.D.S. 888

DISEASES OF THE PERIDENTAL MEMBRANE. By G. V. Black, M.D., D.D.S. 918

ABRASION AND EROSION OF THE TEETH. By G. V. Black, M.D., D.D.S. 993

INDEX 1011

ILLUSTRATIONS.

FIGURE		PAGE
1.	Section of a Sound Adult Femur	36
2.	Structure of the Neck of the Femur	36
3.	Fibula tied in a Knot after Maceration in a Dilute Acid	38
4.	Transverse Section of Compact Tissue of Humerus	38
5.	Section Parallel to the Surface from the Shaft of the Femur	39
6.	Lamellæ torn off from a Decalcified Human Parietal Bone	40
7.	Transverse Section of Decalcified Human Tibia	41
8.	Lacunæ of Osseous Substance	41
9.	The External Periosteum	42
10.	Cells from the Marrow of Bone during their Period of Development	44
11.	Three Multinuclear Giant-cells (Osteoclasts)	44
12.	Section of Part of One of the Limb-bones of a Fœtal Cat	46
13.	Imperfectly and Ill-developed Upper Jaw	49
14.	Occipital Bone, outer surface	50
15.	Occipital Bone, inner surface	52
16.	Development of Occipital Bone	54
17.	Left Temporal Bone, outer surface	55
18.	Left Temporal Bone, inner surface	57
19.	Petrous Portion of Temporal Bone, inferior surface	58
20.	Development of the Temporal Bone by Four Centres	61
21.	Sphenoid Bone, superior surface	63
22.	Sphenoid Bone, anterior surface	64
23.	Sphenoid Bone, posterior surface	66
24.	Fœtal Sphenoid Bones	68
25.	Left Parietal Bone, external surface	69
26.	Left Parietal Bone, internal surface	70
27.	Frontal Bone, outer surface	72
28.	Frontal Bone, inner surface	74
29.	Frontal Bone at Birth, developed by two lateral halves	76
30.	Ethmoid Bone, outer surface of right lateral mass	76
31.	Perpendicular Plate of Ethmoid Bone	77
32.	Ethmoid Bone, inner surface of right lateral mass	78
33.	The Vomer Bone	80
34.	Left Superior Maxillary Bone, outer surface	82
35.	Left Superior Maxillary Bone, inner surface	83
36.	The Anterior Palatine Fossa	86
37.	Alveoli of Permanent Teeth	87
38.	Development of the Superior Maxillary Bone	89
39.	Left Palate Bone, internal view	91
40.	Left Palate Bone, posterior view	92
41.	Right Inferior Turbinated Bone, internal surface	94
42.	Right Inferior Turbinated Bone, outer surface	94
43.	Left Lachrymal Bone, external surface	95
44.	Right Nasal Bone	96
45.	Left Nasal Bone	96
46.	Left Malar Bone, outer surface	98
47.	Left Malar Bone, inner surface	98
48.	Inferior Maxillary Bone, outer surface	100
49.	Inferior Maxillary Bone, inner surface	102
50.	Internal Face of the Right Maxilla of Human Embryo of Three Months	105
51.	The Inferior Maxilla of a Fœtus of Nine Months	105
52.	Appearance of Lower Jaw with Deciduous Teeth	106
53.	Lower Jaw with Permanent Teeth in position	106
54.	Partial Absorption of Alveolar Process	106
55.	Complete Absorption of Process	106
56.	Absorption of Alveolar Process in Old Age	107
57.	Hyoid Bone, anterior surface (enlarged)	108
58.	Temporo-maxillary Articulation, internal view	113
59.	Vertical Section of Temporo-maxillary Articulation	114
60.	Side View of Skull	116
61.	Anterior and Posterior Fontanelles at Birth	119
62.	The Lateral Fontanelles at Birth	119
63.	Base of the Skull, inner or cerebral surface	121
64.	Base of the Skull, external surface	125
65.	Anterior Region of Skull	131

FIGURE PAGE

66. Roof of the Mouth 137
67. Vertical Section of Articular Cartilage 139
68. White Fibro-cartilage from an Intervertebral Disc 139
69. Fibro-cartilage of an Intervertebral Ligament 140
70. Multiplication of Cartilage-cells 141
71. Vertical Section of the Skin of the Thumb 143
72. Section of Skin 146
73. Tactile Corpuscle 146
74. Section of Hair-follicle 147
75. Lower portion of Hair-pouch, from the lip of a kitten . . . 148
76. Duct of the Sweat-gland 151
77. Section of Coil of a Sweat-gland 152
78. Sebaceous Gland from the Alæ Nasi 153
79. Tendon of Mouse's Tail 159
80. Transverse Section from the Sterno-mastoid 161
81. Muscular Fibre 161
82. Muscular Fibres (highly magnified) 161
83. A Branched Muscular Fibre of Frog's Tongue 162
84. Fragments of an Elementary Fibre of the Skate 162
85. Magnified Human Muscular Fibre 163
86. Nuclei of Muscular Fibre . . . 164
87. Involuntary Muscular Fibre-cells from Human Arteries 164
88. The Muscles of Expression . . 167
89. Muscles of the Head, Face, and Neck 170
90. Muscles of the Right Orbit . . . 175
91. Position and Attachment of the Muscles of the Left Eyeball . 176
92. The Temporal Muscle 180
93. The Pterygoid Muscle 181
94. Muscles of the Neck, anterior view 184
95. Muscles of the Tongue, left side 187
96. Muscles of the Pharynx, external view 192
97. Muscles of the Soft Palate . . . 195
98. Vertical Section through the Mucous Membrane of the Large Intestines of a Dog 202
99. Submaxillary Gland of the Dog . 204
100. Section of Human Submaxillary Gland 205
101. Alveoli of a Serous Gland . . . 206
102. The Salivary Glands 207
103. View of the Right Submaxillary and Sublingual Glands, from the inside 210
104. The Meibomian Glands, etc. from the inner surface of the eyelids 211
105. The Lachrymal Apparatus, right side 212
106. The Arch of the Aorta and its Branches 215

FIGURE PAGE

107. Anatomy of the Arteries of the Neck, right side 217
108. The Arteries of the Face and Scalp 223
109. The Internal Maxillary Artery and its Branches 231
110. The Internal Carotid and Vertebral Arteries, right side . . . 236
111. Arteries of the Orbit, from the outer side 238
112. Veins of the Head and Neck . . 250
113. Vertical Section of the Skull, showing the sinuses of the dura mater 257
114. The Sinuses of the Dura Mater, seen in horizontal section of the skull 260
115. Veins of the Diploë, as displayed by the removal of the outer table of the skull 262
116. Ganglion-cell of a Frog 264
117. A Ganglion-cell within its Sheath from the Human Sympathetic 264
118. Nerve-cell from Spinal Cord of Ox 265
119. Section of the Saphenous Nerve 265
120. Diagram of Structure of Nerve-fibre 266
121. Nerve-substance from the Eel, magnified 266
122. Tubular Nerve-fibres 267
123. Nerve-fibres 267
124. Portions of Two Nerve-fibres from a Young Rabbit 268
125. Nerve-fibre from the Sciatic Nerve of the Rabbit 268
126. Portion of the Network of Fibres of Remak 269
127. Division of a Nerve-fibre, from pulmonary membrane of frog . 269
128. Division of a Nervous Branch into its Ultimate Fibres 269
129. Plexus of Fine Non-medullated Nerve-fibres of the Cornea . . 270
130. Intra-epithelial Nerve-termination in Cornea 270
131. End-bulb from the Human Conjunctiva 271
132. Termination of the Nerves in the Salivary Glands 272
133. Termination of Nerves in Non-striped Muscular Tissue . . . 272
134. Muscular Fibres of Lacerta viridis, with the terminations of nerves 273
135. Dissection of the Sinuses of the Skull and Cranial Nerves . . 274
136. Base of the Brain 275
137. Semi-diagrammatic View of a Deep Dissection of the Cranial Nerves on left side of head . . 276
138. The Nervous Distribution of the Head 278
139. Nerves of the Septum of the Nose 277

FIGURE PAGE

140. Diagram of the Optic Nerves and Tracts in Man 279
141. Nerves of the Orbit, seen from above 280
142. Nerves of the Orbit and Ophthalmic Ganglion 282
143. Distribution of the Second and Third Divisions of the Fifth Nerve and Submaxillary Ganglion 283
144. A Diagram of the Distribution of the Fifth Nerve 285
145. Pterygo-maxillary Region and Fifth Nerve 296
146. The Spheno-palatine Ganglion and its Branches 300
147. The Otic Ganglion and its Branches 303
148. Diagram of the Facial Nerve and its Distribution 304
149. Middle Fossa of the Base of the Skull 306
150. Ganglia and Communications of the Divisions of the Ninth, Tenth, and Eleventh Pairs . . 311
151. Tympanic Nerve 312
152. Distribution of the Ninth, Tenth, and Eleventh Pairs of Nerves on the left side 314
153. Origin and Connections of the Glosso-pharyngeal, Pneumogastric, and Spinal Accessory Nerves 317
154. Dissection of the Side of the Neck 321
155. Section of Small Lymphatic Gland 328
156. Portion of the Medullary Substance of the Mesenteric Gland of an Ox 329
157. Superficial Lymphatics and Glands of the Head, Face, and Neck 331
158. The Deep Lymphatics and Glands of the Neck and Thorax 332
159. Head of Nereis margaritacea . . 338
160. Cephalic Region of the Leech . . 338
161. Oral Apparatus of Echinus . . 339
162. Dental System of Echinus . . . 340
163. Sectional Diagram of Molluscan Radular Apparatus 342
164. Jaw of Tritonium 343
165. Teeth of Bela 346
166. Teeth of Conus 346
167. 168. 169. Rhachiglossate Teeth 346
170. 171. Tænioglossate Teeth 347
172. Ptenoglossate Teeth 347
173. 174. Rhiphidoglossate Teeth . . 347, 348
175. 176. 177. Docoglossate Teeth 348

FIGURE PAGE

178. 179. 180. 181. 182. Jaws of Pulmonates 349
183. 184. 185. 186. Teeth of Pulmonates 349
187. Section through the Skin of an Embryonic Shark 353
188. Third Lower Premolar of a Dog 355
189. Three Stages in the Development of a Mammalian Tooth-germ 362
190. Skull of the Codfish 367
191. Teeth of Notidanus 372
192. Lower Jaw of Port Jackson Shark 373
193. Teeth of Rays 374
194. Ceratodus, and Teeth of Same . 376
195. Vertical View of the Upper Jaw of a Dog 397
196. Vertical View of the Lower Jaw of a Dog 398
197. Side View of the Skull of a Dog 402
198. Side View of the Skull of an Armadillo 409
199. Side View of the Skull of Zeuglodon cetoides 415
200. Mandible of Mesonyx ossifragus 418
201. Skull of Mesonyx ossifragus, anterior to post-glenoid process . 419
202. Right Mandibular Ramus of Dissacus navajovius 420
203. Skull of Hyænodon horridus . . 421
204. Skull and Part of the Posterior Foot of two individuals of Stypolophus whitiæ 422
205. Left Mandibular Ramus of Triisodon quivirensis 423
206. Skull of Lepticitis haydeni . . . 424
207. Parts of Upper and Lower Jaws of Esthonyx burmeisteri . . . 425
208. Side View of a Portion of a Skull of Blarina talpoides . . 426
209. Vertical View of Grinding Surface of Same 426
210. View of the Grinding Surface of an Unworn Molar Tooth of Dasyurus 428
211. Two Incisors of the Lower Jaw of Galeopithecus, external view 429
212. Vertical View of Upper and Lower Jaws of European Hedgehog 429
213. Fragment of the Lower Jaw of a species of Miacis 430
214. Upper and Lower Jaw of two species of Didymictis 430
215. Superior Maxillary Bone of Man 438
216. Inferior Maxillary 439
217. A Left Upper Central Incisor . 440
218. A Lower Incisor 440

FIGURE PAGE

219. Left Superior Human Canine . 441
220. First Upper Bicuspid or Premolar 442
221. Second Lower Human Bicuspid 443
222. First Lower Human Molar . . 443
223. First Superior Human Molar . 445
224. Occlusion of the Teeth 446
225. Deciduous Teeth 446
226. Dentition in Childhood 447
227. Vertical View of the Upper Jaw of a Seal (Phoca vitulina) . . 449
228. Vertical View of the Lower Jaw of a Seal 450
229. Skull of Amphicyon cuspigerus 452
230. Portions of Skull of Oligobunus crassivultus 453
231. Part of Right Mandibular Ramus of Temnocyon altigenis . 453
232. Skull of Ailurodon sævus . . . 454
233. Superior Dental Series of Ictitherium robustum 455
234. Skull of Hyæna 455
235. Superior Sectorial and First Molar of Hyænictis græca 456
236. Fragment of Lower Jaw of Hyænictis græca 456
237. Skull of Proælurus julieni . . . 458
238. Portions of Jaw of Proælurus julieni 459
239. Skull of Archælurus debilis . . 459
240. Skull of Nimravus gomphodus . 459
241. Skull of Dinictis cyclops . . . 460
242. Skull of Pogonodon platycopis 461
243. Cranium of Smilodon necator . 462
244. Upper and Lower Jaw of American Pine Marten 465
245. Cranium of Common Rat . . . 466
246. Grinding Surface of the First Lower Molar of a Muskrat . 467
247. Teeth of Fox Squirrel 467
248. First Lower Premolar of Porcupine 468
249. Last Molar of Capybara 469
250. Dentition of Periptychus rhabdodon 470
251. Dentition of Ectoconus ditrigonus 471
252. Skull of Phenacodus primævus . 473
253. Parts of Cranium of Meniscotherium terræ rubræ 474
254. Lower Jaw of Meniscotherium terræ rubræ 474
255. Molar Teeth of Dendrohyrax arboreus 475
256. Skull of Hyracotherium angustidens 477
257. Skull of Aphelops megalodus . 479
258. Superior Molar Dentition of Rhinoceros 480
259. Upper and Lower Molar Teeth of Lambdotherium 481
260. Upper and Lower Molars of Right Side of a species of Anchitherium 481
261. A Superior Molar Tooth of species of Hippotherium 482

FIGURE PAGE

262. Lower Molar of Same 482
263. Skull of Hippotherium seversum 483
264. Molar Tooth of a species of Horse 483
265. Upper and Lower Jaw of Virginia Deer 487
266. Molar Teeth of Indian Elephant 490
267. Skull of Loxolophodon cornutus 492
268. Dentition of Virginia Opossum . 495
269. Dental Series of Kangaroo . . . 497
270. Human Blood-corpuscles . . . 532
271. Fibrin-filaments and Blood-tablets 533
272. Epithelial Cells in the Oral Cavity of Man 535
273. Columnar Ciliated Epithelium Cells 536
274. Epithelium-cells of Salamander Larva in Different Phases of Division 536
275. Connective-tissue Corpuscles . . 537
276. Preparation of the Omentum of Guinea-pig 537
277. Bundles of the White Fibres of Areolar Tissue 537
278. Elastic Fibres of Areolar Tissue 537
279. Articular Cartilage from Head of Metatarsal Bone 538
280. Frog's Egg, Early Stage of Development 544
281. Egg of Frog in Process of Development 544
282. Egg of Frog, farther advanced . 544
283. Tadpole, fully developed . . . 544
284. } Cross-section of Frog's Egg . . 544
285. }
286. } Cross-section of Tadpole . . . 544
287. }
288. Three Stages in the Segmentation of the Rabbit's Ovum . . 545
289. Optical Section of Rabbit's Ovum at the Close of Segmentation . 545
290. Rabbit's Ovum between Seventy and Ninety Hours after Impregnation 546
291. Diagrammatic Views of the Blastodermic Vesicle of a Rabbit on the Seventh Day 547
292. Embryonic Area of a Rabbit's Ovum on the Seventh Day . 547
293. Rabbit Embryos of about the Ninth Day, seen from the dorsal side 548
294. Rabbit Embryo of about the Twelfth Day 549
295. Figures illustrating the Formation of a Face in the Human Embryo 550
296. Face of an Embryo of Twenty-five to Twenty-eight Days . . 551
297. Embryo removed from the Ovum 551
298. Meckel's Cartilage from Human Embryo of Forty to Forty-two Days 552

FIGURE PAGE

299. Embryo Pig an inch and a third long; side view of Mandibular and Hyoid Arches 552
300. Meckel's Cartilage, from jaw of two-and-a-half months' human fœtus undergoing ossification . 553
301. Transverse Section through a Blastoderm of Chick, about the eighth hour after incubation . 554
302. Porcine Embryo 555
303. Growth of Jaw from the Blastoderm 556
304. Embryotic Hairs and Hair-follicle 558
305. Longitudinal Section of Hair-follicle 559
306. Commencing Replacement of Old by New Hair 559
307. Sebaceous Gland and Hair . . . 561
308. Vertical Section of the Skin of the Thumb 562
309. Three Stages in Developing Enamel-organ 563
310. Porcine Embryo 564
311. Deposition of Fat in Connective-tissue Cells 565
312. Jelly of Wharton 566
313. Porcine Embryo 567
314. Surface View, from below, of a small portion of the posterior end of the pellucid area of a thirty-six hours' chick 568
315. Osseous Lamellæ 572
316. Transverse Section of Compact Tissue (of Humerus) 576
317. Section of a Haversian Canal . 577
318. A Small Mass of Bone-substance in the Periosteum of Lower Jaw of a Human Fœtus . . . 578
319. Osteoblasts from the Parietal Bone of a Human Embryo thirteen weeks old 579
320. Inferior Maxilla of Porcine Embryo 580
321. Developing Lamella of Bone, Porcine Embryo 581
322. Forming Bone in Human Fœtus, two months 582
323. Developing Parietal Bone of a Fœtal Cat 583
324. Transverse Section of a Bone . . 584
325. Section of Phalangeal Bone of Human Fœtus, five months . 585
326. Longitudinal Section through the Upper Half of the Decalcified Humerus of a Fœtal Sheep 586
327. Section of Part of One of the Limb-bones of a Fœtal Cat . 588
328. Section of Femur of Human Fœtus of five months 589
329. Section of Fang parallel to the Dentinal Tubules 591
330. Section of Developing Tooth of Young Rat 592

FIGURE PAGE

331. Interglobular Spaces 595
332. Transverse Section of Shell of Pinna 596
333. Membranous Basis of Shell of Pinna 596
334. Longitudinal Section of Shell of Pinna 598
335. Oblique Section of Prismatic Shell-substance 598
336. Enamel-prisms 601
337. Section of Hinge-tooth of Myo-arenaria 603
338. Longitudinal Vertical Section of the Upper Small Incisor of a Rabbit 607
339. Diagrammatic Section of Enamel and Dentine 608
340. Connective Tissue of Mesoblast; Epiblast, formed of one layer of cells 612
341. Infant Layer of Epithelium and Embryonal Connective Tissue . 613
342. Epithelium, infant layer; Embryonal Connective Tissue . . 614
343. Mucous Membrane of Mouth . . 615
344. Inferior Maxilla, first stage in the formation of band 617
345. Vertical Section of Band of Porcine Embryo 618
346. Epithelium with Infant Layer, Connective Tissue, Band, and Lamina 619
347. Longitudinal Transverse Section of Inferior Maxilla 620
348. Longitudinal Transverse Section of both sides of the Inferior Maxilla 621
349. Vertical Section through Band from Jaw of Porcine Embryo . 621
350. Same as 349, only more highly magnified 622
351. Vertical Section through Band and Cord of 3½ cm. Porcine Embryo 623
352. Vertical Transverse Section through Jaw of Porcine Embryo 623
353. Illustration of Invagination . . 624
354. Inner Tunic Enamel-organ of Porcine Embryo 626
355. Vertical Transverse Section of Jaw of Porcine Embryo . . . 629
356. Vertical Transverse Section of Jaw of Porcine Embryo, showing differentiation of periosteum 630
357. Vertical Transverse Section of Jaw of Porcine Embryo . . . 632
358. Vertical Transverse Section of Jaw of Porcine Embryo, injected 633
359. Vertical Transverse Section of 9 cm. Bovine Embryo 635
360. Section of Jaw of Eight Months' Human Fœtus, showing ver-

FIGURE PAGE

tical transverse section of central insisor 636
361. Temporary Molar (Rabbit), with permanent molar developing underneath 637
362. Vertical Section of Jaw of Porcine Embryo 638
363. Vertical Transverse Section Central Incisor of Porcine Embryo 639
364. Stellate Reticulum, Inner Tunic, and Odontoblastic Layer . . . 640
365. Circle showing Dental Papilla, Odontoblasts, Dentine, Ameloblasts, and Stellate Reticulum . 641
366. Vertical Section through Apex of Central Incisor of 10 cm. Porcine Embryo 642
367. Calcification and Decalcification of the Teeth 647
368. Comparative Stages of Calcification of the Temporary and Permanent Teeth 651
369. Vertical Section of a Tooth *in situ* 657
370. Sphygmographic Tracings illustrating Different Characters of the Pulse 668
371. Normal Capillary 679
372. Capillaries after Passive Hyperæmia 679
373. Natural Hæmostasis 681
374. Ligatured End of the Crural Artery of a Dog 682
375. Section of a Thrombus, after modified ligation 682
376. Diagram of the Conditions following Embolism of an End-artery 684
377. Diagram of a Hemorrhagic Infaret 685
378. Cells containing Blood-corpuscles from the neighborhood of a hemorrhage 686
379. Crystals of Hæmatoidin 686
380. Crystals of Hæmin 687
381. Crystals of Hæmatoidin from a Uterine Blood-clot 687
382. Blood in Pernicious Anæmia . . 688
383. From Red Medulla of Bone in Pernicious Anæmia 689
384. Inflamed Capillary of the Mesentery of a Frog 691
385. Amœboid Movement of White Blood-corpuscles 691
386. Inflamed Human Omentum . . 692
387. Inflamed Iris 695
388. Cornea of the Frog, excised three hours after irritation . . . 697
389. Corpuscles of the Cornea, eight hours after irritation 698
390. Cornea, sixteen hours after irritation 698
391. Cornea, about twenty-four hours after the insertion of a fine ligature 698
392. Pus-cells 701

FIGURE PAGE

393. Pus-corpuscles 701
394. Granulation-cells 704
395. Section through the Border of a Healing Surface of Granulations 705
396. New Formation of Blood-vessels in a Granulating Wound . . . 706
397. Formation of the Ducts in the Sprouting of a Grain of Corn . 707
398. Regeneration of Epithelium in Cornea of a Rabbit 708
399, 400. Sections showing Absorption of Blood-clot 709
401. Cross-section of Arterial Thrombus of Three Months 710
402. Carious Dentine 766
403–406. Represent the number of carious cavities observed in one hundred persons, and the position of these cavities on the individual surfaces of the teeth 782–785
407. Damp Chamber 792
408. Forms of Fungus from the Saliva 795
409, 410. Lactate-of-Zinc Crystals . . 798, 800
411. Cocci and Diplococci 802
412. Fungus of Caries 802
413. Tubules of Dentine united . . . 803
414. Tubules from Natural Caries . . 804
415. Outline of Epithelial Scale from Human Mouth 804
416. Fungus Growth in Starch . . . 804
417. Fungus from Carious Dentine . 804
418. Apparatus for Experiment with Tobacco 809
419–421. Fungus Growths 814
422–424. Growths in Gelatin-tubes . . 814, 814, 814
425–439. Fungus Growths 815, 817, 823, 824, 824, 825, 825, 825, 826, 826, 826, 827, 827, 827
440. Tissue of Dental Pulp 829
441. Odontoblasts clinging to Imperfectly-developed Dentine . . . 830
442. Point of the Pulp of an Incisor injected with Beale's Blue . . 831
443. Hyperæmia of the Dental Pulp 843
444. Dilated Blood-vessels from the Dental Pulp in Hyperæmia . 845

FIGURE PAGE

445. A Small Vein from a Hyperæmic Pulp 846
446. Dilated Vessels from the Dental Pulp 846
447. Section of Hyperæmic Pulp . . 847
448. Inflammation of Dental Pulp . 850
449. Section of Dental Pulp, showing the invasion of the inflammatory process 850
450. Minute Inflammatory Foci within the Tissues of the Pulp 851
451. Lower Molar with Caries, and microscopical section of the same 854
452. Progressive Suppuration of the Pulp of an Incisor 855
453. Abscess within the Tissues of the Pulp 856
454. Carious Tooth and Microscopical Section 858
455. Chronic Inflammation of the Pulp 860
456. Deposit of Calcoglobulin within the Tissues of an Inflamed Pulp 861
457. A Small Pulp-nodule 863
458. Section of a Pulp-nodule . . . 863
459. Pulp-nodules in the Canal Portion of the Pulp 864
460. } Abrasion of a Cuspid Tooth and
461. } Microscopical Section . . . 866
462. Narrowing of the Pulp-chamber in a Molar 867
463. Deposit of Secondary Dentine excited by Abrasion 868
464. Deposit of Secondary Dentine, resulting from caries of an incisor 869
465. Secondary Dentine, resulting from irritation of the dentinal fibrils by caries 870
466. Secondary Dentine in Pulp-chamber 871
467. }
468. } Carious Cavity in Molar Tooth,
469. } and microscopical appearances 872
470. Dentinal Tumor within the Pulp-chamber 873
471. Proximal Decay in Incisor, and microscopical appearances . . 875
472. Calcification of the Dental Pulp 876
473. Calcific Deposit in Incisor . . . 877
474. Lower Molar, with a large carious cavity, with cylindrical calcifications 878
475. Cylindrical Calcification of the Pulp 879
476. Cylindrical Calcification, more advanced stage 879
477. } Representations of Osteo-den-
478. } tine 881
479. }
480. } Atrophy of the Odontoblasts . 884

FIGURE PAGE

481. }
482. } Effect of Caries in Producing
483. } Secondary Dentine 914
484. Root and Membrane of Tooth . 919
485. Acute Alveolar Abscess of Superior Incisor pointing on the Gum 930
486. Acute Alveolar Abscess of the Lower Incisor pointing on the Gum 931
487. Acute Alveolar Abscess, with Pocket of Pus between the Periosteum and the Bone . . 932
488. Necrosis of the Buccal Plate . . 932
489. Acute Alveolar Abscess of a Lower Incisor 932
490. Upper Molar with Acute Abscess at the Buccal Roots and Chronic Abscess at the Palatine Root . 933
491. Upper Incisor with Acute Alveolar Abscess the Pus from which has raised the Periosteum from the Hard Palate 933
492. Blind Abscess at the Root of an Upper Incisor 936
493. Chronic Alveolar Abscess at the Root of a Lower Incisor . . . 938
494. Chronic Alveolar Abscess at the Root of an Upper Incisor, with Fistula discharging on the Gum 938
495. Alveolar Abscess at the Buccal Roots of an Upper Molar discharging on the Face 939
496. Scar caused by Alveolar Abscess discharging on the Face . . . 939
497. Alveolar Abscess at the Root of a Superior Incisor discharging into the Nose 940
498. Relations of the Roots of the Teeth to the Antrum 941
499. Alveolar Abscess at the Root of an Upper Molar discharging into the Antrum of Highmore. 941
500. Abscess of Lower Incisor with Fistula discharging under the Chin 942
501. Abscess of Lower Incisor with Cavity passing through the Body of the Bone and discharging beneath the Chin . 942
502. Fistula through the Lower Maxilla 942
503. Loss of Bone and Teeth from Subperiosteal Inflammation . 944
504. Operation for the Remedy of Scar caused by Alveolar Abscess 952
505. The Gingival Border 955
506. Deposit of Serumal Calculus under the Gingival Borders . . 958
507. Deposit of Serumal Calculus within the Free Margin of the Gum 958

FIGURE PAGE

508. Calculus and Destruction of the Lower Border of the Alveolar Wall and Peridental Membrane 959
509. Absorption of the Septum of Bone and Recession of Gum 959
510. Inflammation of the Gum from Deposit of Salivary Calculus . 960
511. Inflammation and Absorption of the Gum and Lower Border of the Peridental Membrane and Alveolar Wall from Calculus . 960
512. } 513. } 514. } Destruction of Tissues from Salivary Calculus 961
515. Dr. George H. Cushing's Scalers 964
516. Farrar's Syringe 967
517. Alveoli irreparably Destroyed by Calcic Inflammation 968
518. } 519. } 520. } 521. } 522. } 523. } 524. } Destruction of Membrane and Alveolus from Phagedenic Pericementitis 970 970 970 971 971 971 972

FIGURE PAGE

525. Acute Pericementitis with Eversion of the Alveolar Wall . . 973
526. Phagedenic Pericementitis complicated with Serumal Calculus 975
527. } 528. } Incisions for Exposing the Roots of the Teeth 981 981
529. Chronic Case of Phagedenic Pericementitis 990
530. Amputation of the Affected Root and Filling of the Pulp-cavity. 991
531. Amputation of the Posterior Root of the First Lower Molar . . 991
532. Erosion of the Lower Anterior Teeth 999
533. Erosion of both Upper and Lower Dentures 1000
534. Peculiar Case of Erosion of the Superior Anterior Teeth . . . 1001
535. Artificial Erosion 1004
536. Section of the Crown of an Incisor, showing effects of erosion 1007
537. Group of Odontoblasts with their Processes 1009

LIST OF PLATES.

PLATE I 505
PLATE II 507
PLATE III 509
PLATE IV 511
PLATE V 513
PLATE VI 515

PART I.

REGIONAL ANATOMY.

LIBRARY
209 E. 23rd ST.
N. Y. CITY
DENTISTRY

REGIONAL ANATOMY.

By M. H. CRYER, M. D., D. D. S.

BONES.

Bones belong to one of the three groups of connective tissue, fibro-connective, cartilage, and bone connective tissue. Each of these divisions may be again subdivided into several minor divisions; but under all circumstances the ground substance, or matrix, or intercellular substance of each is distinguished by the cells peculiar to it. The matrix of fibro-connective tissue yields gluten or gelatin, that of cartilage connective tissue yields chondrin, and that of bone connective tissue yields the salts of calcium. With the single exception of the teeth, bone is the hardest, heaviest, and most solid structure of the body: it forms the framework of the body, keeps the parts in position, and acts as lever and fulcrum; its grooves act as pulleys through which glide the tendons of certain muscles; it protects vital parts, such as the brain and spinal cord, from injury; it also, in great measure, gives character and individuality of expression to the head and body generally.

Bones are derived from the two great kingdoms of nature—the organic and inorganic.

The principal portions of the several bones, such as the shafts of long bones, are called the diaphyses; and the smaller parts, such as the ends of long bones, their epiphyses, the term apophyses being applied to those nodules on bones which are not formed from separate points of ossification.

If a long bone be cut longitudinally (Fig. 1), it is seen to be made up of an outer and an inner layer; the outer being called the compact, the inner the spongy or cancellated, portion.

Note.—The writer claims no originality for the purely descriptive matter herein contained. In its preparation notes of the lectures of Professors Allen, Garretson, Stellwagen, and Leidy have been of great value, and the following works have been consulted and freely drawn from: Gray's, Allen's, Quain's, and Leidy's works on *Human Anatomy;* Treves's *Applied Anatomy;* Bell's *Anatomy of Expression;* Allen's *Facial Region;* Tomes's *Dental Anatomy;* Garretson's *System of Oral Surgery;* Parker and Bessang's *Morphology of the Skull;* Klein's *Elements of Histology;* Flint's *Physiology and Diseases of the Nervous System;* Cole's *Studies in Microscopical Science;* Prudden's *Practical Histology;* and Duhring on *Diseases of the Skin.*

The outer or compact portion is hard and ivory-like in texture, giving rigidity and firmness to the shaft. In long bones the compact substance is thickest in the centre of the diaphysis, gradually growing thinner toward the ends, the fibres running longitudinally.

The inner, spongy, or cancellated portion is softer than the outer covering, and is made up of slender bars and thin lamellæ, which cross each other in various directions (see *a a*, *b b*, *c c*, Fig. 2), and produce

FIG. 1.

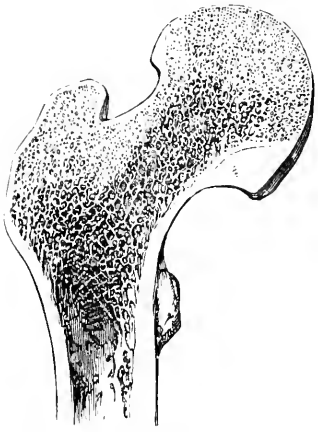

Section of a Sound Adult Femur.

FIG. 2.

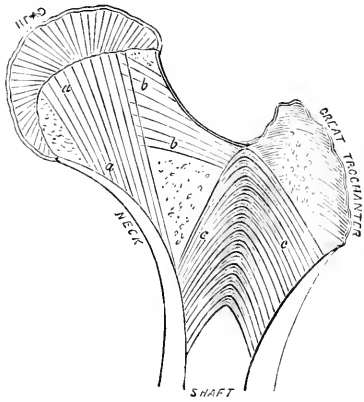

Diagram showing the Structure of the Neck of the Femur.

an open structure having a reticular appearance, so arranged as to form an internal support to the outer portion of the bone. This formation is specially marked in the upper end of the femur.

The cancellated portion is found in greatest quantity at the ends of long bones, at which position the surfaces are enlarged for purposes of articulation. It is the more vascular portion of bone; adds bulk without greatly increasing weight; acts as a cushion to articulating surfaces; and by its elastic properties modifies the force of concussion.

The flat bones, such as those found in the skull, furnish surfaces for the more convenient attachment of ligaments, muscles, and tendons. They are composed of two tables, an outer and an inner, with the cancellated portion (diploë) between.

The cancellar substance of bones generally, but especially in those of the cranium, is pervaded by irregular canals for the accommodation of blood-vessels. The two plates or tables of flat bones are bound together by the cancellated tissue, which not only helps to resist fracture, but acts as a cushion, deadening the force of shock by distributing it over larger surfaces, thus in great measure preventing injury to the brain: it also combines great strength with lightness of weight.

If a close examination is made of a specimen, as shown in Fig. 1, by the aid of a magnifying-glass, it will be found that the compact tissue is porous in a greater or less degree, its density depending upon the

amount of solid matter deposited in it. In other words, where the spaces are small and contracted the solid matter is abundant; in the spongy portions, the spaces being large, the solid matter is proportionately less. It will also be observed that there is no line of demarcation between the outer and inner structure, the compact gradually expanding into the cancellated portion.

The color of bone depends upon the condition in which it is when examined; if fresh, it will be of a yellowish hue, due to the contained lymph and the fatty medulla. The blue shade so frequently seen is due in a great measure to the mode of death. If the subject from which the bone is taken died from drowning, suffocation, or any kindred cause, a bluish tinge would be imparted to the bone. The redness of fresh bone is dependent upon its vascularity; therefore some bones will be redder than others, and the bones of young healthy persons more so than those of the aged, whose osseous tissues contain a relatively greater amount of inorganic matter.

Bones which have been cleaned, first by maceration in water, then in ether, become white, the cartilaginous material, the blood, fat, and membranes having been removed. By this process bones become extremely porous by reason of the removal of the contents of the innumerable small openings for blood-vessels which are found scattered over their surface.

After exposure for a long time to the atmosphere, bones undergo exfoliation and split into laminæ, thus demonstrating that osseous tissue is heterogeneous and not homogeneous in its formation.

The weight of bones varies in direct proportion to their compactness of structure. Their chemical analysis yields, on an average—

Calcium carbonate	7.05
Magnesium phosphate	2.08
Calcium phosphate	58.39
Calcium fluoride	2.25
Organic matter	30.23
	100.00

It is seldom that the analytical chemists will produce exactly the same results in their respective analyses of different bones, as it would be difficult to find two bones identical in structure and composition. There are many reasons for this, among which age may be mentioned as a prominent factor. During youth bone is principally made up of organic matter, but as life advances there is assimilated continually more inorganic material, part of the organic matter being lost. Disease may also influence the proportional quantity of the inorganic constituents, and, as might be expected, bones taken from different parts of the body will be dissimilar in composition, as they are designed for different functions.

If bone be placed in a solution consisting of one part of hydrochloric acid to sixteen parts of water, the fluid being changed each day, the inorganic matter will be dissolved out, leaving the organic material, which is held together by its connective tissue, in its original shape, these remaining parts being quite soft and flexible. Thus treated, a

Fig. 3.

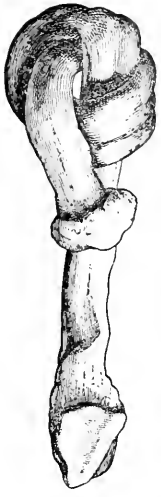

Fibula tied in a Knot after Maceration in a Dilute Acid (from a specimen preserved in spirit).

vertebra will become like a sponge, and the long bones may be tied into knots (see Fig. 3). In this way the internal parts of bone may be prepared for study by cutting away portions with a sharp knife or pair of scissors.

A preferable manner of preparing bone for microscopical examination is to take a small piece, about half a cubic inch in size, of the compact portion of a long bone, either of man, dog, cat, or rabbit, and immerse it in an aqueous solution of chromic or picric acid, either of which hardens the organic tissue as well as dissolves the inorganic matter, and renders the tissue capable of being cut into thin sections, which are to be stained or not according to methods in vogue by practical histologists. Hard sections can also be made by sawing a small piece from a long bone and grinding it upon a whetstone or plate of glass with emery-powder until sufficiently thin.

When a bone is placed in a slow fire or a sufficiently heated furnace, the organic material will be consumed, leaving only inorganic substance and the ash from the organic matter. The shape is still preserved, but the specimen is very brittle and will crumble almost at the touch.

Minute Structure of Bone.

A transverse and longitudinal section of the compact structure of

Fig. 4.

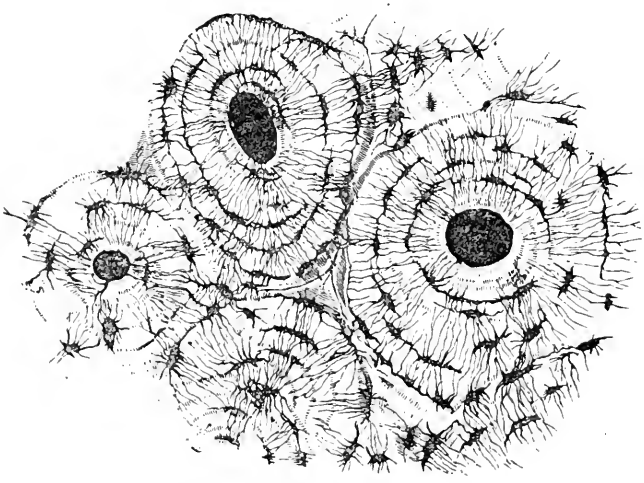

Transverse Section of Compact Tissue of Humerus (magnified about 150 diameters). Three of the Haversian canals are seen, with their concentric rings; also the lacunæ, with the canaliculi extending from them across the direction of the lamellæ. The Haversian apertures had become filled with air and débris in grinding down the section, and therefore appear black in the figure, which represents the object as viewed with transmitted light.

bone examined under a microscope will demonstrate the appearance, as shown in Figs. 4 and 5.

The minute structure of bone is examined in five divisions—viz. (*a*) the Haversian canals; (*b*) the bony lamellæ; (*c*) the Sharpey or perforating fibres; (*d*) bone lacunæ; (*e*) canaliculi; and (*f*) bone-cells.

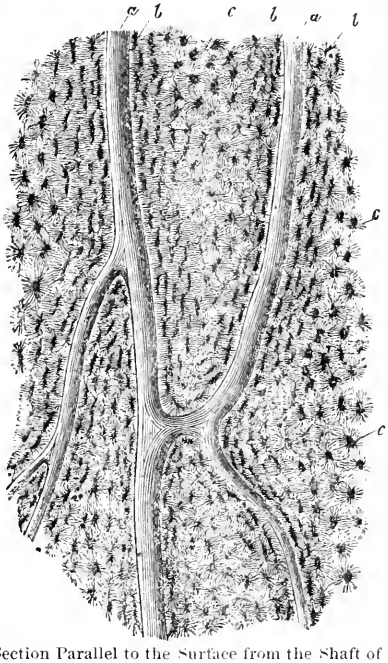

FIG. 5.

Section Parallel to the Surface from the Shaft of the Femur (magnified 100 times): *a*, Haversian canals; *b*, lacunæ from the side; *c*, others seen from the surface in lamellæ which are cut horizontally.

(*a*) THE HAVERSIAN CANALS (Figs. 4 and 5) are named after their discoverer, Clopton Havers. They are from $\frac{1}{1000}$th to $\frac{1}{200}$th of an inch in diameter, occasionally being found as small as $\frac{1}{2000}$th of an inch. The smallest canals are found near the surface or outside of the bone, the larger ones near the medullary canal. Their general direction is longitudinal with the axis of a long bone, although they anastomose with each other by short or oblique branches at varying angles, while others pass into the periosteum and the medullary cavity, thus forming a reticulated intercommunication by which capillary blood- and lymph-vessels pass, not only longitudinally, but from the outer to the inner portion of the bone. When the canals are not filled by the above vessels the remaining space is occupied by delicate loose connective tissue enclosing cellular elements identical with the bone marrow, hereafter to be described.

(*b*) THE BONY LAMELLA is divided into three systems—viz. (1) the Haversian, (2) interstitial, and general or (3) circumferential systems.

(1) *The Haversian or Concentric System* is a series of concentric rings immediately surrounding each Haversian canal, varying in number from four to twenty according to the age of the formation. All the laminæ do not form complete circles, some terminating between two others. Frequently the rings are oval in shape, this form depending to some extent on the cutting of the section. If cut obliquely to the canal, both the rings and canal have an oval appearance, though the canal is not always in the centre of its system.

(2) *The Interstitial System*:—The lamellæ of this system are composed of bands of osseous tissue of varying thickness, running in different directions between the Haversian and the circumferential systems.

(3) *The Circumferential or Parietal System*.—The lamellæ here are principally found upon the surface of bone, although they are also seen passing through the interstitial system, and even next to the medullary cavity. They have a general direction parallel to the surface of the bone.

(*c*) SHARPEY'S OR PERFORATING FIBRES.—Besides the three systems of lamellæ which form for the most part all the intercellular substance of bone, there is found in many instances a well-defined system of fibres known as Sharpey's fibres (see Fig. 6). These pass through or penetrate the lamellæ in a perpendicular or oblique direction, appearing to dowel or bind the parts together. Many pass from the periosteum—especially is this marked in the external table of the cranial bones—while others seem to have their origin from some of the intermediate

FIG. 6.

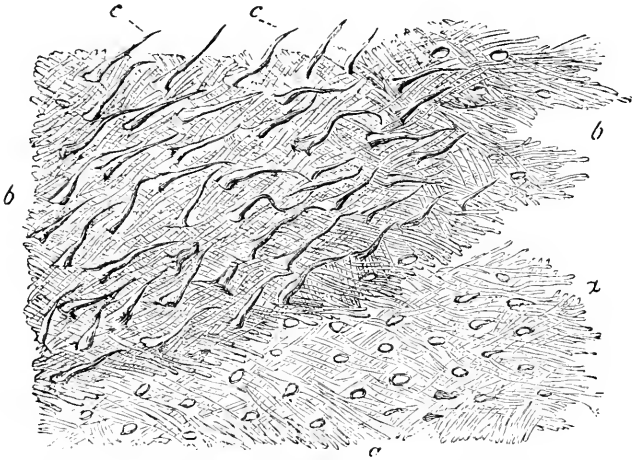

Lamellæ torn off from a Decalcified Human Parietal Bone at some depth from the surface: *a*, long lamellæ; *b*, *b*, thicker part, where several lamellæ are superposed; *c*, *c*, perforating fibres: the fibrils which compose them are not shown in the figure. Apertures through which perforating fibres had passed are seen, especially in the lower part, *a*, *a*, of the figure (magnitude as seen under a power of 200, but not drawn to a scale).

lamellæ of the interstitial or circumferential systems, though it is more probable they had their origin from the periosteum when that membrane was in close contact with the lamella from which their fibres start. These fibres are not found in the Haversian lamellæ. If a lamella is torn away from a decalcified bone, these fibres can be seen attached to the under surface of the removed portion, the apertures being visible in the remaining bone from which the fibres have been drawn. They are supposed to be ossified bundles of white fibrous tissue originally belonging to the inner layer of the periosteum.[1]

Occasionally these fibres do not ossify, and as they shrink or are drawn out in removing the periosteum, perforations will be found leading into the bone. It is by means of these perforating fibres that tendons and ligaments obtain such firm hold upon bones, their number being increased at the points of such attachments.[2]

[1] Perforating fibres (*c*, *c*, Fig. 6) exist abundantly in the crusta petrosa or cementum of the teeth (Sharpey). H. Müller has shown that some are of the nature of elastic tissue (Quain's *Anatomy*).

[2] The fibre-bundles of the tendon are continued into the bone as perforating fibres. Some of the bundles of white fibres of the periosteum may also pass into the bone as perforating fibres, and the same is the case with elastic fibres (Quain's *Anatomy*).

Fig. 7.

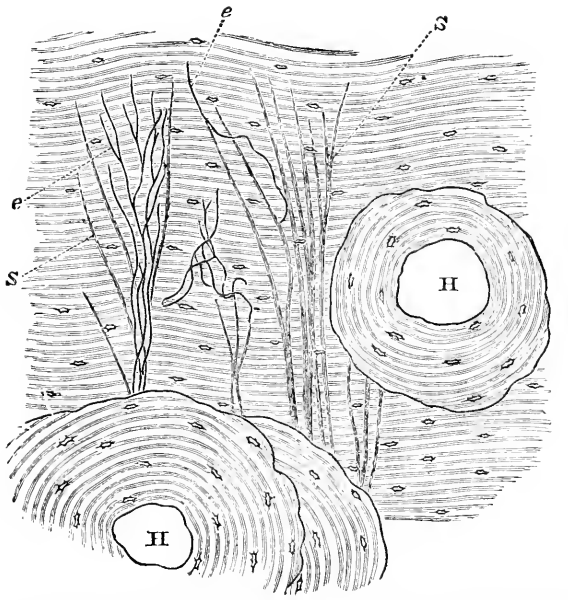

Transverse Section of Decalcified Human Tibia, from near the surface of the shaft: H, H, Haversian canals, with their systems of concentric lamellæ; in all the rest of the figure the lamellæ are circumferential; S, ordinary perforating fibres of Sharpey; *e*, *e*, elastic perforating fibres (drawn under a power of about 150 diameters).

(*d*) The Lacunæ or Lymph-spaces (osseous corpuscles) are best demonstrated in thin sections, prepared by grinding instead of softening by acids and cutting with a knife or microtome. When examined by transmitted light the lacunæ have a dark appearance, but when seen with a dark background, the light being thrown upon them, they will appear quite white. They are very small cavities situated between the lamellæ of the bone, flattened ellipsoidal in shape, and with many radiating elongations.

Fig. 8.

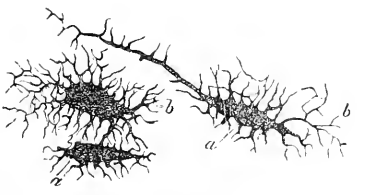

Lacunæ of Osseous Substance (magnified 500 diameters): *a*, lacuna; *b*, canaliculi.

(*e*) The Canaliculi are very fine canals opening into the radiating elongations of the lacunæ. They extend between and through the different lamellæ, giving free communication to the lacunæ situated between the various lamellæ; they also pass from the lacunæ to the Haversian canals, the surface of the bone, and the medullary canals, and are intimately connected with the lymphatic vessels situated in and around the bones, showing that the lacunæ and canaliculi form the lymphatic system of the osseous structure.

(*f*) The Bone-cells are flattened and nucleated, and are situated within each lacuna, with prolongations extending into the canaliculi. In structure they are analogous to the connective-tissue corpuscle. "Rouget and Neumann have been able to detach the proper wall of the

lacuna and its appertaining canaliculi after decalcification, and to obtain it separate with its included corpuscle." "It can scarcely be doubted that the protoplasm of the nucleated corpuscle takes an important share in the nutritive process in bone, and very probably serves both to modify the nutritive fluid supplied from the blood and to further its distribution through the lacunar and canalicular system of the bony tissue."[1]

In flat, thin, or irregular-shaped bones the Haversian canals, the lamellæ, etc. are similar to those in the diaphyses of long bones, just described, though the Haversian system is not so regular in formation.

The Periosteum.

The periosteum is that membrane which covers the greater portion of all surfaces of bone, and is composed in a great measure of fibrillated connective tissue. Between the interlacing of the fibrous bundles lymph-spaces are formed which contain elementary cellular matter. Although it is made up of several closely-attached lamellæ, for convenience of description this structure is divided into two principal layers, an outer and an inner.

Fig. 9.

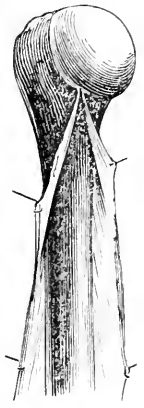

The External Periosteum laid open and turned off from a Young Humerus.

The outer layer is the firmer of the two, being composed mainly of one or more strata of dense white connective tissue, with a few fine yellow elastic fibres interspersed with several fat-cells. Blood- and lymph-channels are found in abundance; the latter anastomose quite freely with those of the inner layer.

The inner or osteogenic layer has its fibrous bundles more loosely arranged than the outer, and is composed chiefly of elastic fibres of connective tissue, generally arranged in several distinct strata. It is much more vascular than the outer layer, the blood-vessels forming a network of capillaries which anastomose with those of the outer layer and send numerous offshoots into the substance of the bone. In the lower strata of this layer, or that one next to the bone, especially during the period of formation, there is a large number of spheroidal or oblong granular cells or corpuscles, with oval nuclei, which are usually situated on the side of the cell. These cells were named *osteoblasts* by Gegenbauer. The bone-producing property of the inner layer of the periosteum is especially well marked in the fully-developed inferior maxilla, clavicle, and bones of the arm and forearm. If the surgeon when operating is careful to first strip this membrane aside, he can excise or resect a large portion of bone, the lost tissue being subsequently renewed to a great extent through the agency of the osteoblasts.

If by disease or otherwise the periosteum be removed from any living bone, the portion thus denuded generally suffers atrophy, and finally necrosis. This is not usually the case, however, with the bones of the cranial vault, as will be hereafter explained.

The periosteum serves as a support to the vessels which supply the

[1] Quain's *Anatomy*.

bones with blood, these capillaries being assisted by the medullary (nutritive) arteries, which pass directly into the bone and are distributed throughout its system of Haversian canals, until they anastomose with the branches coming from the periosteum. Thus the bones are permeated by the blood and absorbent vessels, a few nerves also entering their structure. In the bones containing marrow there is an endosteum, composed of a fine layer of areolar tissue, which lines the medullary canals and other spaces. This lining membrane is very vascular, and contains myeloplaxes or osteoclasts. Osteoclasts are also found at the roots of deciduous teeth when their roots are being absorbed, and in the lining membranes of bony sinuses. When the periosteum is stripped from living bone, numerous bleeding spots appear, which indicate the points where the vessels pass from the membrane into the bone. The muscles, aponeuroses, tendons, and ligaments are attached to the bone through the intervention of the periosteum, which is attached to the bone by its perforating fibres. Tendons and ligaments obtain firm adherence to bones by sending prolongations of their fibre-bundles through the periosteum.

In inflammation of the bone the periosteum often becomes thickened, and may be easily removed. At the point of attachment of a muscle to a bone there is seen a roughening, a depression, or a protuberance corresponding in size to the strength of the attached muscle.

The Marrow of Bone.

The marrow is a highly vascular, soft tissue situated within all bones. It fills the medullary canals of long bones, the spaces within spongy bones, and to a greater or lesser extent the Haversian canals of compact bone tissue. As a matrix it has a small amount of fine delicate connective tissue woven or interlacing in such a way as to form very thin septa between the vesicles. Its color and composition vary according to age and the position it occupies within the bone; and this difference has led to its generally being divided into two kinds—*yellow* and *red*. The yellow receives its color from the large number of fat-vesicles it contains, and is principally found in the medullary canals of long bones and in small quantity in some of the cavities of spongy bone. Yellow marrow is not found in young bones.

The red marrow is dependent for its color on its greater vascularity and upon its containing red cell-elements independent of the blood; it lacks adipose tissue in its substance, and is more fluid than the yellow. Red marrow is situated in the spaces of spongy bones, especially the bodies of the vertebræ, sternum, the ribs, and diploë of the cranial bones. The vessels of the marrow, which are numerous, are imbedded within its substance. Their walls are very thin, and they supply in part the adjacent bone as well as the surrounding marrow. They anastomose through the bone with those of the periosteum. Within the marrow are found a variety of cell-elements (Fig. 10) which vary according to position and age, and are described as—the medullary or true marrow-cells; fat-vesicles or adipose-tissue cells; multinuclear giant-cells;

nucleated red blood-cells; osteoblasts; colored cells similar to the red blood-corpuscles.

The Medullary or True Marrow-cells are round and nucleated. They have amœboid movements, and in general appearance may be compared to lymph-cells or the white corpuscles of the blood, though somewhat larger and possessing a clearer protoplasm. This class is more abundant in red than yellow marrow.

FIG. 10.

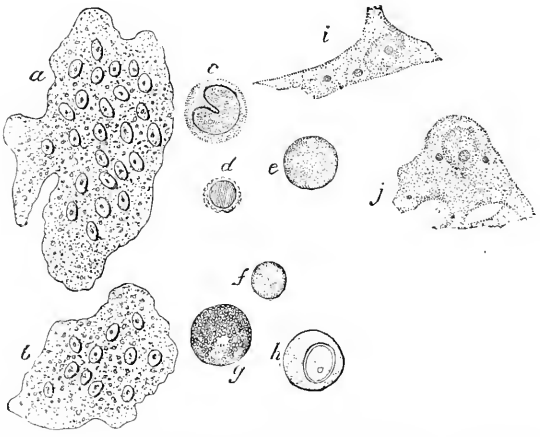

Cells from the Marrow of Bone during their Period of Development: *a*, *b*, multinuclear "giant-cells;" *c*, *f*, *g*, lymph-cells from the marrow of the tibia of the guinea-pig, examined in the serum of the blood; *c*, *d*, *h*, after the action of alcohol and water 33 per cent.; *i*, *j*, so called osteoblasts from the femur of a new-born dog, after the action of alcohol 33 per cent. (high power).

The Fat-vesicles are similar to those found in adipose tissue. As previously stated, the color of yellow marrow is due to these vesicles, of which it is in greater part made up. Fat-vesicles are found in very small numbers in the red marrow.

The Multinuclear Giant-cells are large, soft, protoplasmic masses, granular in appearance. They generally contain a large number of nuclei; these are sometimes grouped on one side, and have a fine fibrillated network running through them. Sometimes they contain only one nucleus, which is large and shows indications of segmentation. These cells have been called by Robin myeloplaxes, and by Kölliker osteoclasts. The latter authority considers them necessary to bone-absorption.

FIG. 11.

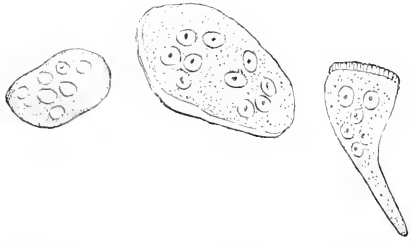

Three Multinuclear Giant-cells (Osteoclasts), from absorption-surfaces of growing bone (400 diameters—Kölliker).

The Nucleated Red Blood-cells resemble the red corpuscles of the blood, but are somewhat larger; they have a smooth, homogeneous cell-body with a distinct nucleus. These cells are supposed by some to lose their nuclei, become biconcave, and assume the character of the

ordinary red blood-corpuscles. Those holding this view claim that the marrow of the bones is one of the blood-producing tissues of the body.

Osteoblasts (described p. 42) are found principally and in large numbers in red marrow along the osseous trabeculi, especially during the development of bone.

Red cells, having every appearance of red blood-corpuscles, are numerous. Their presence has been explained by the fact that the walls of the capillary blood-vessels are very thin and delicate, permitting the escape of the corpuscles into the surrounding tissue.

Development of Bone.

The central column of the body, consisting of the vertebræ and the base of the skull, is seen in rudimentary outline at a very early period of embryonal life. This outline, formed from the mesoblastic layer of the blastoderm, and composed of tissue not unlike the primordial structure by which it is surrounded, soon becomes cartilage; and in man, about the fortieth day of embryonal life, bone-development commences in the clavicle and inferior maxilla. This early ossification of the lower jaw, before the upper, may be explained as due to the same law of development that brings about the eruption of the inferior teeth before the superior. Some of the lower animals, however, have more teeth in the lower than the upper maxilla, the former being more important, as in mastication it has active movement, while the upper jaw is passive. Nearly all the bones of the body have their commencement in hyaline cartilage. Those of the face, with the two exceptions of a portion of the inferior maxilla and the inferior turbinated, and those covering the brain, excepting a part of the occipital, are developed within membranes. In addition to these two modes of formation, the cartilaginous and membranous, bone seems to be principally developed from the osteogenetic layer of the periosteum. From this it will be seen that it is best to consider the development in three divisions—viz.: I. Intracartilaginous; II. Subperiosteal; III. Intramembranous.

I. The Intracartilaginous (endochondral) Bones are those having their origin or first formation in hyaline cartilage, which usually presents, in minature, a general outline of the future bone. The transformation from cartilage to bone is gradual, and commences at one or more points, called centres of ossification. In the bones of the higher animals, including man, the number of ossific centres varies, being dependent on the degree of complexity in the formation of the bones and the number of vessels and nerves which pass through them. If there is but one point, it is usually situated near the middle and upon the surface, else next to the perichondrium or future periosteum. For convenience of description and facility of study the development of endochondral bone may be divided into four stages:

1st. The first observable change is at one or more of the ossific points, at which the cartilage-cells (for description see p. 138) immediately under the perichondrium enlarge and multiply within their capsules, the matrix-substance becoming partly absorbed.

2d. Into this area blood-vessels enter from the under layer of the perichondrium (chondrogenetic layer), accompanied by osteoblasts (bone-germs) and marrow-tissue. As the vessels and osteoblasts advance into the partly-absorbed cartilage, the change of the cartilage is carried on in front of them; thus the cartilage becomes channelled, forming cavities irregular in shape named medullary spaces. These are lined by osteoblasts and invaded or permeated by blood-vessels and marrow-tissue.

FIG. 12.

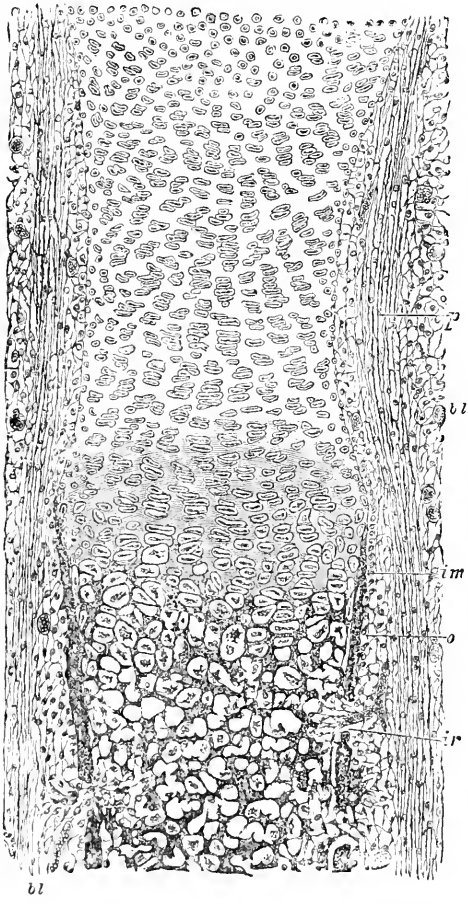

Section of Part of one of the Limb Bones of a Fœtal Cat. The calcification of the cartilage-matrix has advanced from the centre, and is extending between the groups of cartilage-cells, which are arranged in characteristic rows. The subperiosteal bony deposit (*im*) has extended *peri passum* with the calcification of the cartilage-matrix. The cartilage-cells in the primary areolæ are mostly shrunken and stellate; in some cases they have dropped out of the space. At *cr* and in two other places an irruption of the subperiosteal tissue, composed of ramified cells with osteoblasts and growing blood-vessels, has penetrated the subperiosteal bony crust, and has begun to excavate the secondary areolæ or medullary spaces; *p*, fibrous layer of the periosteum; *o*, layer of osteoblasts: some of them are imbedded in the osseous layer as bone-corpuscles in lacunæ; *bl*, blood-vessels occupied by blood-corpuscles.

3d. That portion of the cartilage basement-substance which is not absorbed forms irregular septa or trabeculæ, and is infiltrated with fine particles of calcic salts, causing opacity and a granular appearance, which, when cut, has a gritty feel: this process is called calcification, and is an intermediate stage between the absorption of the cartilage-matrix into medullary spaces, and the ossification of the bone by the influence of the osteoblasts.

4th. The last stage, following closely that of calcification, is called ossification through the influence of the osteoblasts. Portions of the walls of the medullary spaces become absorbed, causing two or more of the primary medullary spaces to become united and form secondary spaces. In this way a great part of the primary bone (or calcified cartilage-matrix) is at once removed.

"Turning our attention to the exact way in which bone is formed under the influence of the osteoblasts, we find that just beneath these cells, lying along the walls of the new-formed medullary spaces, the basement-substance of true bone begins to be deposited, at first in the form of a narrow shell beneath each osteo-

blast. These deposits, which on cross-section have a ereseentic shape, become thicker and thicker, rising up around the cell, which they finally enclose—the enclosed osteoblast becoming, as it would seem, a bone-cell. This process occurring around each osteoblast, the walls of the medullary cavities soon become covered with a layer of bone containing bone-cells. New osteoblasts appear on the walls, and in turn become enclosed in a layer of bone, and thus the lamellar arrangement of bone-tissue is produced. The remains of cartilage basement-substance between the medullary space thus covered by bone finally disappear in a manner unknown to us."[1]

II. The Subperiosteal Bone is the portion formed on the outer surface of that which is developed within the cartilage, and by the formation of which bones increase in thickness. It is deposited in a manner similar to endochondral bone, through the influence of osteoblasts found on the inner portion of the osteogenetic layer of the perichondrium, which has now become periosteum. The osteoblasts are arranged along the line of blood-vessels and connective-tissue bundles of the osteogenetic layer of the periosteum, and as these structures are not parallel to each other or to the surface of the bone, but cross at various angles, forming an uneven network, they cause newly-formed bone to have an uneven surface, with branching grooves and canals passing in different directions. Upon the walls or sides of these grooves and canals the osteoblasts, by means of which bone-tissue is deposited, are distributed, spaces being left for blood-vessels and marrow-tissue: these spaces subsequently become the Haversian canals. During the time these canals and spaces are being encroached upon by ossific deposit newer layers are commenced on the outer surface of the bone, the fully-formed or ossified layer being continually overlaid by fresh coatings in a manner similar to the lamellæ of the Haversian system: by this process the bone grows in thickness. These lamellæ are held or bound together by perforating fibres (Sharpey's fibres), which pass through several layers at nearly right angles with the surface. These fibres originate from the bundles of connective tissue of the subperiosteal membrane, but do not all have connection with the periosteum itself, though doubtless they had their origin from that membrane, the same as the bone in which they are found. Perforating fibres are usually ossified, but in some instances they are not, and in the drying of the bone they become shrunken, leaving perforations.

In the long bones the cartilage grows and extends toward the epiphyses, where, by gradually increasing in diameter, it causes the cancellated portion of the bone to present a somewhat similar shape to that of an elongated hour-glass. Where deposition of bone first commenced the cancellated part is the narrowest, and the cortical portion, which grows from the periosteum, is the thickest. Toward the ends of the bones the cortical substance gradually diminishes to a thin layer, thus maintaining a nearly equal diameter for the bone from end to end. A little before or about the time of the development of the periosteal bone the central portion of the embryonal spongy or endochondral bone undergoes a process of softening or absorption (osteoporosis, Schwalbe). In

[1] Pruden's *Practical Histology*, 2d ed., p. 73.

this way the central or marrow cavity is formed, and the partitions or septa of the medullary spaces become absorbed, especially around the medullary canal, thereby enlarging it. This absorption may be carried on until the entire embryonal spongy bone is removed.

III. The Intramembranous Ossification takes place within membranes of fibrillar connective tissue, independent of any cartilaginous formation. It is found within the roof of the brain-case, as in the parietal and frontal bones and portions of the occipital and temporal, and within all the facial bones, except the inferior turbinated and part of the inferior maxilla. (The base of the skull, the two inferior turbinated, and part of the inferior maxillary bones are developed within cartilage.) This development of bone is analogous to that of periosteal formation, which takes place on or around endochondral bones.

The parietal bone presents a good example of this development. At first it is composed of a single fibrous membrane; next it divides near its centre into two layers, these eventually becoming the external and internal periosteums. Between these two layers are numerous interlacing bundles of connective-tissue fibres, making an intervening network between the two membranes and forming irregular medullary spaces similar to the partially-absorbed cartilage in endochondral bone-formation. The bundles of connective-tissue fibres forming the walls of the medullary spaces become infiltrated with calcic salts; the spaces themselves are occupied by blood-vessels and marrow-tissue, and their walls lined by osteoblasts, which develop bone, as described p. 42.

As the centre thickens the cleavage of the membrane extends toward the circumference, and bony spicula grow outward in radiating lines until they meet neighboring bones, with which they unite by sutures.

While this process is going on, the two osteogenetic membranes deposit successive layers of bone, causing an increase in thickness, each layer becoming more dense, thus forming what are known as the external and internal plates. Between the two tables of a fully-formed bone is the cancellated structure or diploë. These irregularly-formed spaces are made through absorption of portions of the bony tissue by osteoporosis. The diploë is a highly vascular tissue, in which the arteries of the external and internal periosteum anastomose.

Bones are divided into four classes—viz. *long* bones, such as those of the arm and leg; *tabular* or *flat* bones, as those forming the vault of the cranium; *irregular* bones, such as the vertebræ; and *short* bones, as those of the carpus and tarsus.

Many of the bones are arranged in symmetrical pairs, one on each side, as illustrated in the ribs, arms, legs, parietal and temporal bones; while the vertebræ, commencing with the coccyx, and continuing upward through the skull with the occipital, sphenoid, ethmoid, frontal, and vomer, are single bones, developed from two symmetrical halves. The inferior maxilla is usually described as a single bone, but in embryonal life and in some of the lower animals there are two. In man the bones on either side of the body are seldom of equal size, those of the right side usually being slightly larger; their markings, such as processes and foramina, are also dissimilar in size and shape.

Disease of the soft parts often changes the shape of bones, particularly in the young. Aggravated tonsillitis in childhood will, if chronic and accompanied by hypertrophy, cause the roof of the mouth to take an inverted V-form (Fig. 13). If the patient has suffered from the disease on one side only, that side will be pulled down. This is due to the extra tension of the palato-glossus and palato-pharyngeus muscles. Thus the palatal processes of the superior maxillæ and palate bones are prevented from forming the normal dome-shape roof of the mouth, and the vomer is directed or pushed from its proper position; becoming crooked or lacking space to occupy its normal position, it is deflected or pushed forward, thus forming an unduly large nose. By proper treatment at an early period, many such deformities can be avoided. Tumors of the maxillary sinus may change the shape of one or more of the surfaces of the superior maxilla, and an aneurism or other soft tumor constantly pressing against a bone will cause its absorption.

FIG. 13.

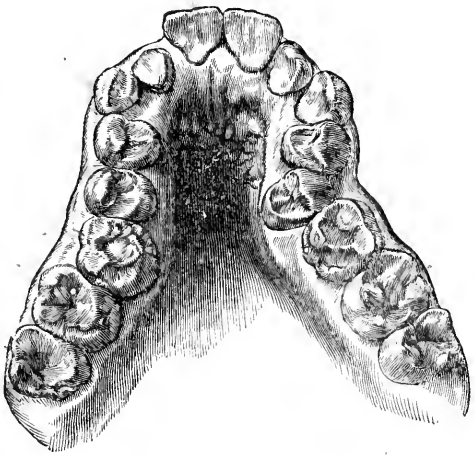

Imperfectly and Ill-developed Upper Jaw.

In describing bones, the following terms will be used:

Proximal, the end or surface of a bone next to the centre of the body.

Distal, the end or surface that is farthest away from the centre.

Head. If the extremity forms a single rounded prominence, it is called the head.

Condyles. If there are a pair of prominences, they are called condyles, though this name is applied to the single articular eminence of the occipital bone and of the lower jaw.

Neck is that portion which is constricted just below a head, condyle, or other articular eminence.

Process is an elevation, projection, or prominence on a bone.

Spinous Process, a narrow and tapering prominence or elevation on a bone.

Tubercle or a *Tuberosity*, an obtuse prominence.

Line, *Ridge*, or *Crest*, an elevation extending some distance along the surface of a bone, a prominent border.

Foramen (plural *Foramina*), an aperture in a bone or between several bones.

Canal or *Meatus*, a prolongation of a foramen for some distance in the bone.

Fossa (plural *Fossæ*), a broad, shallow depression.

Sinus, a cavity with a small external communication.

A line in measurement is one-twelfth part of an inch. In describing the development of bones, weeks and months refer to embryonic and fœtal life.

An articulating surface is that portion of a bone where it joins another.

A facet is a portion of an articular surface which is distinguished from adjacent portions of the same surface by difference of its curvature.

The Skull.

The skull is composed of twenty-two bones, exclusive of the six otic (ear bones), the Wormian bones, and the teeth. These are united by sutures and synchondroidal articulations, with the exception of the

Fig 14.

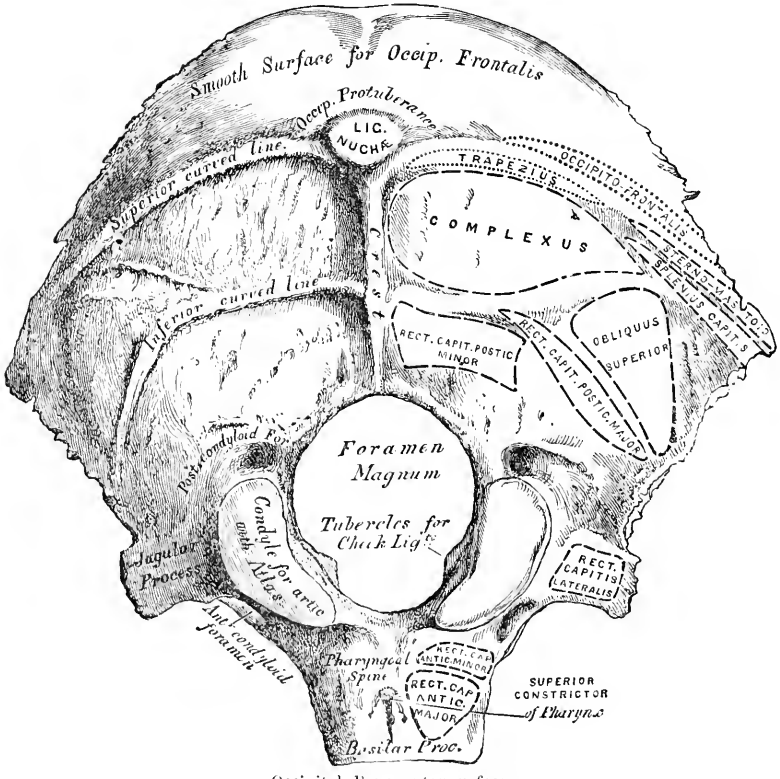

Occipital Bone, outer surface.

inferior maxilla, which is a diarthroidal joint. The skull approaches the spheroidal shape, flattened at the sides, broader posteriorly than anteriorly, and is supported upon the atlas, the first bone of the vertebral column. Anatomists divide the bones of the skull into two groups—the cranial and the facial. The cranial bones, which encase

the brain, are eight in number—one occipital, two temporal, one sphenoid, two parietal, one frontal, and one ethmoid. The remaining fourteen bones form the oral cavity, nasal chamber, and portions of the orbits. They are called the facial bones, and consist of the two superior maxillary, two palatal, one vomer, two inferior turbinated, two lachrymal, two nasal, two malar, and the inferior maxilla, six being in pairs, and two being single bones. The hyoid bone, though generally classed as a bone of the neck, will be described with the bones of the head.

Occipital Bone.—The occipital bone (Fig. 14) is situated at the base of the cranium, at the top of the spinal column, and articulates with the atlas. It is oval in form, resembling somewhat a saucer, and presents for examination four angles, four borders, two condyles, two surfaces—one concave or inner toward the brain, the other or outer convex. It is also perforated on its under surface by a large oval foramen.

The Basilar Process forms the anterior (inferior) angle of the bone. If a section of this process were made through the mesial line, the surface would assume the appearance of a wedge about an inch in length, widening from the anterior border of the foramen magnum, the base of the wedge, about half an inch in thickness, being that portion of the process which articulates with the sphenoid bone. In early life a layer of cartilage intervenes between the basilar process of the occipital and the sphenoid bones. This cartilage becomes ossified at the age of puberty. The upper surface of the basilar process is grooved for the accommodation of the medulla oblongata and basilar artery; the under surface (laterally) is convex and forms the roof of the pharynx. Near its centre is a rounded prominence called the pharyngeal spine, for the attachment of the raphé and the superior constrictor of the pharynx. On each side of this prominence is a rough depression for the attachment of the rectus capitis anticus major and minor muscles. Laterally, the superior border of this process is roughened for articulation with the petrous portion of the temporal bone, forming the petro-basilar suture. During life, the under portion of this process is filled with a mass of fibrous tissue.

The Superior Angle of the occipital bone articulates with the posterior superior angles of the parietal bones at the position occupied in fœtal life by the posterior fontanelle. The lateral angles articulate at the posterior juncture of the parietals with the mastoid portions of the temporal bones. The superior borders extend from the superior to the lateral angles of the bone; they are deeply serrated for articulation with the posterior borders of the parietal bones, and form the occipito-parietal (lambdoid) suture. In this suture Wormian bones of different sizes are most frequently met, the denticulations being distinctly marked. The inferior borders extend from the lateral angles to the sphenoid bone. Each border is divided into two portions by the jugular process. The upper part is serrated for articulation with the mastoid portion of the temporal bone, forming the occipito-mastoid suture; the lower portion is simply roughened.

The Jugular Processes, two in number, are sharp points of bone extending laterally, and are analogous to the transverse processes of a vertebra; they form the posterior boundary of the jugular notch.

The Jugular Notch is a smooth semicircular concavity, extending half an inch outwardly and three-fourths of an inch anteriorly, forming by its articulation with the temporal bone the jugular or posterior lacerated foramen. This foramen is frequently divided by one or more septa, and through it the ninth, tenth, and eleventh pairs of nerves pass out of the brain-case. It is at this point also that the lateral sinuses terminate and the internal jugular vein commences.

FIG. 15.

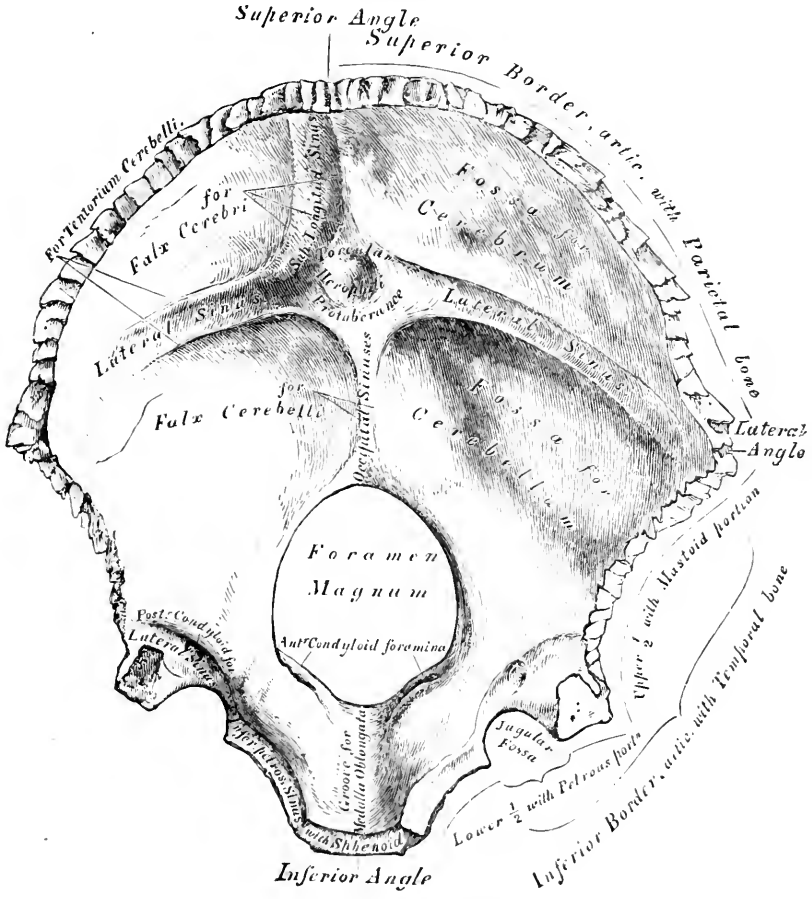

Occipital Bone, inner surface.

The External Surface.—On each side of the lateral borders of the foramen magnum are the two condyloid processes (exoccipitales) which articulate with the atlas (the first cervical vertebra).

The Condyles are elliptical in form and converge somewhat in front. Their surfaces are convex, both transversely and longitudinally, being divided into two articulating facets, which are occasionally separated by a transverse groove. The inner side of each condyle is roughened for

the attachment of the odontoid ligament of the axis (the second cervical vertebra). Immediately above the anterior facet on either side are the anterior condyloid foramina, situated at the side and above the foramen magnum; they transmit the hypoglossal nerves. Occasionally these foramina are found doubled, which allows the superior and inferior bundles of the hypoglossal nerve to pass through separate foramina in their exit. Behind the posterior facet is the condyloid fossa, which usually contains the posterior condyloid foramen, for the transmission of the occipital emissary vein to the lateral sinus. Two foramina are also occasionally found in this situation. The outer surface of the tabular portion of the occipital bone (supraoccipital) is divided transversely into three sections by the superior and inferior curved lines. The superior curved line runs inwardly from the lateral angles of the bone, at the temporo-parietal suture, to the external occipital protuberance; it forms the major portion of that line, which extends in the articulated skull from the apex of the mastoid portion of the temporal bone on the one side of the cranium to the same point on the opposite side. The inferior curved line runs almost parallel with the superior. Its extremities are situated at each jugular process, from which point it ascends to the occipital crest. The lower two-thirds of the external surface is divided longitudinally by the occipital crest. This crest is a slight ridge running from the external occipital protuberance to the foramen magnum. The upper third, or that portion above the superior curved lines, is comparatively smooth. The external occipital protuberance, which gives attachment to the ligamentum nuchæ, is situated in the centre of the superior curved line, and is analogous to the spinous process of a vertebra. Its size varies in different individuals, being much larger in some persons than in others. The upper margin of the superior curved line gives attachment to the occipito-frontalis muscle, its inner extremity to the trapezius, and just beneath the outer extremity are the points of attachment of the splenius capitis muscle. On either side of the crest, between the curved lines, are marked depressions for the attachment of the complexus muscles, and just below and to the outer side of these is a smooth surface for the insertion of the superior oblique muscles. The space below the inferior curved line gives attachment to the rectus capitis posticus major and minor muscles.

The Internal Surface of the bone is divided into four fossæ by two distinct ridges, transverse and longitudinal: the former runs from the lateral angles to the internal occipital protuberance, the longitudinal ridge extending from the superior angle of the bone to the foramen magnum. The point where these ridges intersect is called the internal occipital protuberance. The superior fossæ afford lodgment to the lobes of the cerebrum, while the inferior accommodate those of the cerebellum. The superior part of the longitudinal and the transverse ridges are generally grooved, to accommodate the longitudinal and the lateral venous sinuses. Frequently the longitudinal sinus is found to the right side of the superior longitudinal ridge, particularly where it approaches the intersection of the ridges.

The inferior portion of the longitudinal ridge is rounded, and is generally called the internal occipital crest.

The Foramen Magnum is the largest foramen of the brain-case. It is situated on the inferior surface, between the jugular and basilar processes and the tabular portion of the bone. It is oval in shape, its long diameter being antero-posterior. It transmits the spinal cord and its membranes, the spinal accessory nerves, and the vertebral arteries.

Structure.—About one-third of the basilar process, commencing at the foramen magnum, is made up of two plates of compact tissue. These plates then divide and enclose between them cancellated tissue. The jugular processes are principally made up of spongy substance, the fossæ being composed of compact tissue. The fossæ for the lodgment of the two lobes of the cerebellum are formed of compact bone, the remainder of the tabular portion of the bone being made up in a great part of two plates, with abundant diploë between them. Especially is this the case near the occipital protuberance.

Development.—The occipital bone is developed from osseous cartilage and osseous membrane. The condyloid (ex-occipital) and the basilar (basi-occipital) portions commence to ossify in cartilage about the seventh or eighth week of embryonic life, each having a separate nucleus

Fig. 16.

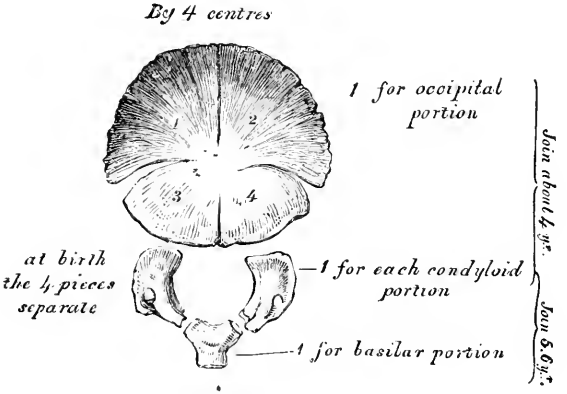

Development of Occipital Bone.

or centre. The osseous union of the basilar and condyloid portions begins at the third or fourth year, and is completed by the end of the fifth or sixth year. The basi-occipital and the basi-sphenoidal portions of the respective bones are united by intervening cartilage until about the fifteenth year, at which time ossification commences, and it is generally completed by the twentieth year.

The tabulated portion (supraoccipital) commences its process of ossification in membranous tissue a short time before the remainder of the bone, from four centres, which at birth have been united and form one bone. At this time three deep fissures are noticeable at the superior and lateral angles. Occasionally the lateral fissures run into each other, and the upper portion forms the interparietal bone of many animals.

The osseous union of the supra and the condyloid portions begins during the second or third year, and is completed by the third or fourth year.

Remarks.—The basilar and condyloid portions of this bone, being so nearly connected with the mouth and associate parts, claim special attention.

The basilar process forms the roof of the pharynx, and is situated on a level with the posterior nares, and in surgical operations may be reached through the nose or through the oral cavity.

Hydatid or exostosed cysts and other enlargements within the anterior condyloid foramen, producing pressure upon the hypoglossal nerve, would cause paralysis, atrophy, or deflection of the tongue.

The Temporal Bone (Fig. 17) is situated at the side and base of the brain-case. It articulates in front with the great wing of the sphenoid bone, above with the parietal bone, behind with the lateral portion of the occipital bone, and at the base of its petrous portion is wedged

Fig. 17.

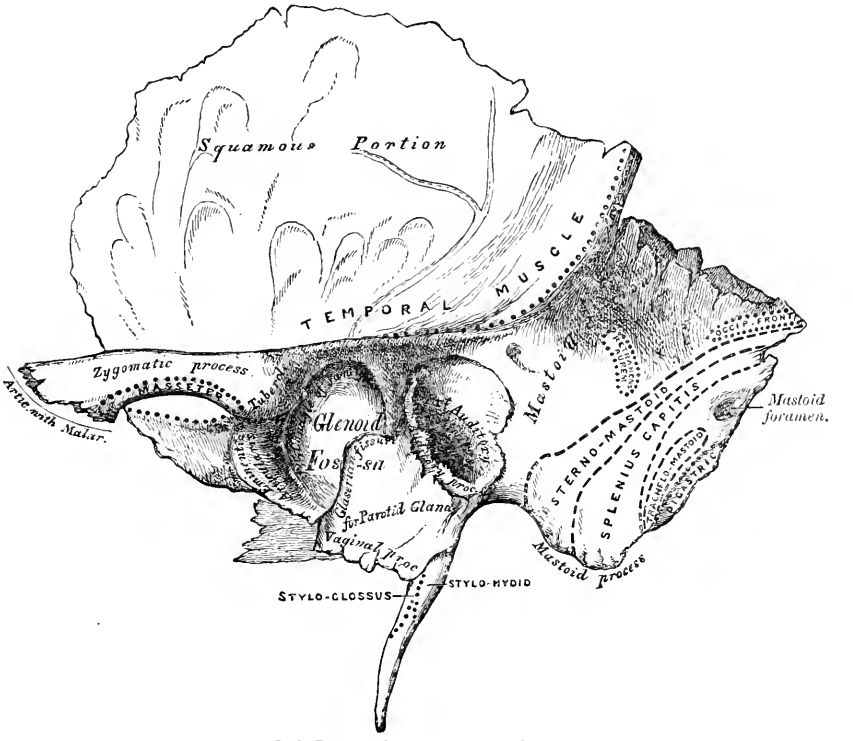

Left Temporal Bone, outer surface.

in between the basilar process of the occipital and the great wing of the sphenoid bone. By its outer surface it assists in the formation of the temporal and the zygomatic fossæ and the zygomatic arch; by its under surface it forms part of the roof of the parotid region; and by its inner surface it forms part of the middle fossæ of the brain-case. For convenience of description this bone is generally divided into three portions —viz. the squamous (scale), the mastoid (nipple), and the petrous (rock).

The styloid process may also be added to this division, and studied separately, as it has its own centre of ossification.

The Squamous Portion is divided into three parts—the ascending, the horizontal, and the part forming the wall of the glenoid cavity. The ascending portion is concavo-convex, the convexity, which is almost perpendicular, being smooth and giving origin to the temporal muscle. It is marked by two grooves running upward, one near its anterior border, the other at the posterior termination of the zygomatic arch. They indicate the position of the deep temporal arteries at the upper border of the squamous portion, where it articulates with the parietal bone, forming the temporo-parietal suture (squamous); the outer table is extended considerably beyond the inner, thus forming a scale or bevel at the expense of the inner border. This scale overlaps the corresponding surface of the parietal bone. That portion which forms the suture is bevelled inwardly, the middle portion is serrated, and the lower portion anteriorly is bevelled outwardly.

The zygomatic process (horizontal portion) has a triangular origin from the squamous portion of the bone, where it bends abruptly inward toward the base of the skull, and has three roots. Its large posterior root passes backward, above the external auditory meatus, behind which it forms the boundary between the squamous and the mastoid portions of the bone, and is called the supramastoid ridge; this then curves upward, and, uniting with the temporal ridge of the parietal bone, forms the posterior boundary of the temporal fossa. The middle root forms the outer boundary of the glenoid fossa; then bends inwardly and terminates in the posterior glenoid process at the outer extremity of the glenoid fissure. The anterior root runs directly inward in front of the glenoid fossa, forming its anterior border, which is also known as the eminentia articularis. At the juncture of this root with the zygomatic process is a rounded eminence, called the tubercle, for the attachment of the external lateral ligament of the inferior maxilla. The zygomatic process projects outwardly from the skull about one-fourth of an inch, and has an upper and a lower surface; it then turns upon itself, and its posterior edge, which is thin, forms the superior border. The inferior border is about half an inch in length, its extremity being serrated and bevelled at the expense of the inferior border, where it articulates with the zygomatic process of the malar bone. The masseter muscle arises in part from the lower border of this process, and each side of the upper border gives attachment to the two layers of the temporal fascia.

The Glenoid Fossa is situated at the base of the squamous portion of the bone. It is bounded in front by the anterior root of the zygoma, behind by the tympanic plate of the petrous portion, externally by the auditory process and middle root of the zygoma. It is divided into an anterior and posterior portion by the glenoid fissure (fissure Glaserius, the squamoso-tympanic suture). The anterior half is the articulating portion of the fossa, and is occupied by the condyle of the inferior maxilla. In man this is a complicated articulation, which will be described subsequently. The posterior half accommodates the upper portion of the parotid gland.

The glenoid fissure communicates with the tympanum (middle ear), and lodges the processus gracilis of the malleus. It is at this point that Meckel's cartilage is united to the bones of the ear in the early stage of development. It also transmits the levator tympani muscles and the tympanic branch of the internal maxillary artery. The chorda tympani nerve passes through a separate canal parallel to the glenoid fissure (canal of Hugier) on the outer side of the Eustachian tube and between it and the carotid canal.

The Internal Surface of the temporal bone (Fig. 18) is concave and marked by depressions for the middle lobe of the cerebrum. It is

FIG. 18.

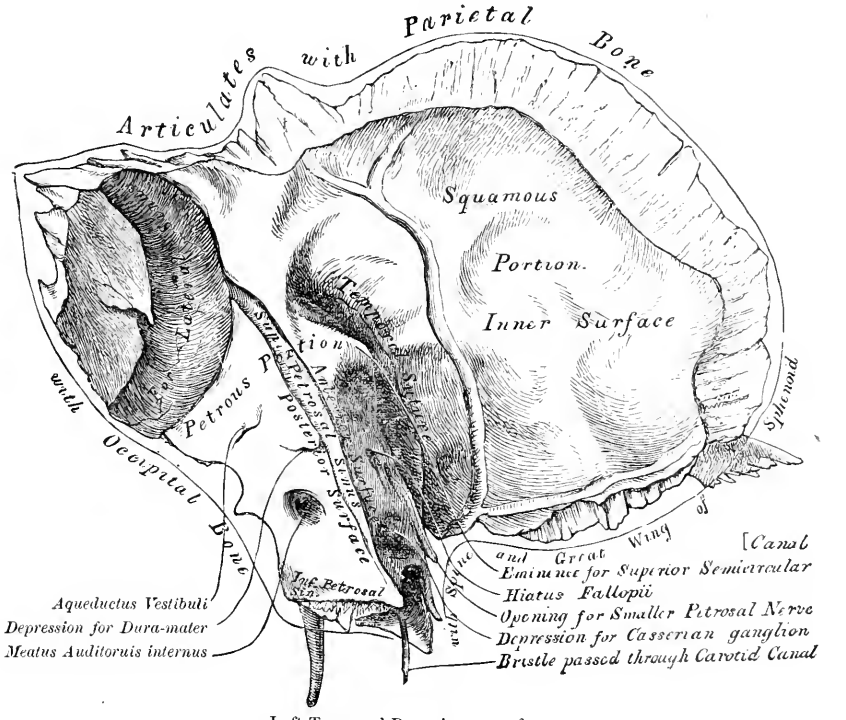

Left Temporal Bone, inner surface.

grooved for the meningeal arteries, which run almost parallel with the deep temporal arteries on its outer surface. At the lower portion there is an eminence corresponding partially to the glenoid fossa on the outer surface. At this point the bone is so thin as to be almost transparent.

The Petrous Portion (Fig. 19), so named from its hardness, contains the internal and middle ear. The facial nerve passes outward through this part of the bone, and the internal cartoid artery inward; it supports, in part, the cartilaginous portion of the Eustachian tube. It forms a three-sided pyramid, with its base directed outward, its apex forward, inward, and slightly downward, where it is wedged between the basilar process of the occipital bone and the great wing of the

sphenoid, leaving a portion unoccupied by bone. This unoccupied portion is called the middle lacerated foramen, and is filled up with cartilage in the recent state. It has three surfaces: two (the anterior and posterior) are situated within the brain-case; the other, the inferior, on the outside.

The Anterior Surface looks forward and upward, marking in the base

FIG. 19.

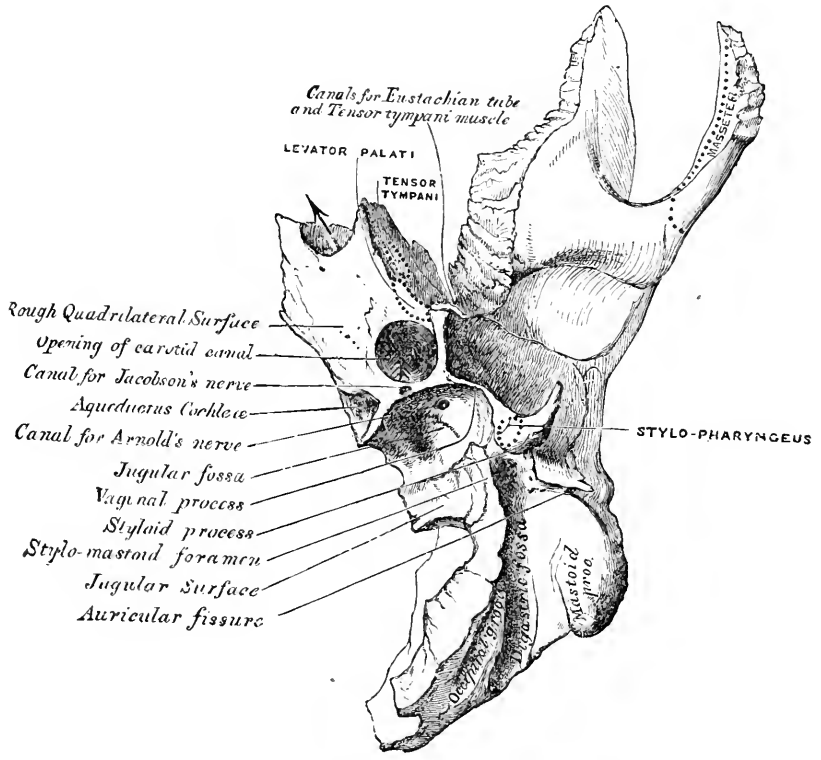

Petrous Portion of Temporal Bone, inferior surface.

of the brain-case the posterior border of its middle fossa, being divided into a superior and an inferior portion.

The Superior Portion of the petrous portion of the temporal bone is of hard consistency; near the centre is a rounded eminence marking the situation of the superior semicircular canal. A depression near the apex defines the position of the Gasserian ganglion (semilunar ganglion of the fifth pair of nerves; see p. 284). Below this depression is the termination of the internal carotid canal. A narrow groove, sometimes double, divides the superior from the inferior portions of the surface. Along this groove are one or more minute openings, the principal one being the hiatus Fallopii, for the transmission of the greater superficial petrosal nerve; a smaller opening below is occupied by the lesser petrosal nerve. The inferior portion, known as the tegmen

tympani, is a thin layer of bone which forms the roof of the tympanum and the bony portion of the Eustachian tube. It is bounded anteriorly by the petro-squamous fissure, which commences internally at the angle between the squamous and petrous portions of the bone, and extends outwardly to the masto-parietal suture: internally it extends downward and backward, forming the glenoid fissure (fissure of Glasserius).

The Posterior Surface looks backward and inward; it is less oblique than the anterior, and forms, in great part, the anterior border of the posterior fossa of the brain-case. Near its centre is a large orifice leading into a short canal. The canal is directed outward, and is called the internal auditory meatus. It transmits the seventh (facial) and eighth (auditory) nerves and the auditory artery.

The meatus is about four lines in depth, and terminates in a thin plate of bone, the lamina cribrosa, in the lower portion of which are several small openings for the transmission of the divisions of the auditory nerve; in the upper portion is the aqueduct of Fallopius, for the passage of the facial nerve. This canal has a tortuous course through the petrous portion of the temporal bone, passing at first outward for a short distance between the cochlea and vestibule to the inner wall of the tympanum; then backward over the fenestra ovalis, the ear, and then downward, terminating at the stylo-mastoid foramen. External to the internal auditory meatus, and between it and the posterior fossa, is a slit-like opening, quite indistinct in some cases, which leads to a canal, the aqueductus vestibuli. This canal transmits venous blood from the internal ear. The superior border, which divides the anterior from the posterior surface, is grooved for the superior petrosal sinus, but it never extends to the apex of the bone. That portion of the border internal to the meatus is depressed for the reception of a thick fold of dura mater, under which the third, fourth, fifth, and sixth nerves pass.

The Inferior Surface of the petrous portion is rough and uneven. From within outwardly, or from the apex to a large foramen situated about midway of this surface, is a rough triangular space which gives attachment to the levator palati and tensor tympani muscles. The large round foramen is the external opening to the canal for the internal carotid artery. It first passes upward, then horizontally forward and inward to the apex of the bone, from which point the vessel enters the brain-case.

A plexus of the sympathetic nerve accompanies the artery in its course through the canal. External to and a little above this foramen is a smooth, deep depression, the jugular fossa, which varies in size in different skulls, and when articulated with the jugular notch in the occipital bone the two form the jugular foramen. Just back of the jugular fossa, at the commencement of the border of the mastoid portion of the bone, is an irregular, rough surface, the jugular facet, which articulates by synchondrosis with the transverse process of the occipital bone.

Several small foramina are situated in this portion of the bone. In the ascending portion of the carotid canal is a small foramen for the tympanic branch of the internal carotid artery, and between the jugular fossa and the opening for the carotid canal will be found a foramen for

the tympanic branch of the glosso-pharyngeal (Jacobson's) nerve. On the border between the posterior and the inferior surfaces, internal to the jugular fossa, is the aqueductus cochlea, which transmits a vein from the cochlea to join the internal jugular vein. In the internal portion of the jugular fossa is a foramen for the auricular branch of the pneumogastric nerve (Arnold's nerve).

The Tympanic Portion forms part of the roof of the external auditory meatus, and is that part of the glenoid fossa which lies below and posterior to the glenoid fissure. It is irregular in outline, and is wholly made up of compact tissue. When examined externally, it presents a U-shaped portion which bounds three-fourths of the external auditory meatus; which opening leads direct to the tympanic membrane. The remaining or upper boundary of the meatus is formed by the squamous portion of the bone. The curve of the U is roughened for the attachment of the cartilage of the ear. The tympanic division extends inward and downward, encasing the base of the styloid process. This division terminates anteriorly in the vaginal process and posteriorly in the glenoid fossa. It is concave in form, and receives the upper portion of the parotid gland. It terminates in the point opposite the spinous process of the sphenoid bone, at the commencement of the opening for the cartilaginous portion of the Eustachian tube.

The Styloid Portion is of hard consistency, long and tapering, pointing downward, inward, and forward in the direction of the great cornu of the hyoid bone; its average length is about one inch, though sometimes it is greater, complicating surgical operations in the region through which it passes. It is situated directly in front of the digastric fossa and behind the vaginal process, which in great part surrounds it. It gives origin to the stylo-pharyngeus, the stylo-glossus, and the stylo-hyoideus muscles; also to it the stylo-hyoid and the stylo-maxillary ligaments are attached. The mastoid portion is the enlarged roughened portion situated at the posterior inferior extremity of the bone. It assists in forming the masto-occipital and the masto-parietal sutures, the mastoid ridge separating it from the squamous portion of the bone. It is divided into two portions, the mastoid and the posterior mastoid, by the extension over it of the superior semicircular line from the occipital bone, which line continues its curve, terminating at the extremity of the mastoid process. The last is large, extending downward and forward behind the external auditory meatus and the tympanic portion of the glenoid fossa. It is small during infancy, but increases and becomes of large size in the adult, especially in individuals with large and powerful muscles. It serves for the attachment of the sterno-cleido-mastoideus, the splenius capitis, and the trachelo-mastoid muscles, the two former extending their attachment along the superior semicircular line of the occipital bone. The internal portion of the mastoid process is full of cells, which communicate with the middle ear. On the inner portion and at the base of the process is a deep groove, the digastric fossa, for the attachment of the digastric muscle; and on the inner side of the groove and parallel with it is the occipital groove for the occipital artery.

Between the mastoid and the styloid processes, and immediately in

front of the digastric fossa, is the stylo-mastoid foramen, which is the termination of the aqueductus Fallopii, and transmits the facial nerve and the stylo-mastoid artery. Beneath the semicircular curved line are one or more foramina of variable size which admit veins to the lateral sinus. When these foramina are large, wounds in this region are dangerous, as the blood would flow freely from the sinus. Sometimes these veins enter the sinus through the suture.

The internal surface is marked by a deep groove, the sigmoid groove, for the accommodation of the lateral sinus. Frequently these sinuses vary greatly in depth in the same skull.

DEVELOPMENT.—The temporal bone is developed from four centres of ossification. The squamous, the zygomatic, and the tympanic portions are developed from membrane, the petrous portion and the styloid process from cartilage. The squamo-zygomatic portion commences to ossify in the lower part of the squamous portion at the latter part of the second or the beginning of the third month of embryonic life. Ossification extends upward into the squamous and outward into the zygomatic portions. Shortly afterward an ossific centre appears in the lower part of the membranous tympanum, ossification spreading upward and inward until it joins the petro-mastoid portion behind and the squamo-zygomatic in front, forming the incomplete tympanic ring. Ossification of the petro-mastoid portion commences much later, usually about the end of the fifth or the beginning of the sixth month of fœtal life. The osseous deposits are made at many points in the cartilage, being all united, however, at birth. The styloid portion is the last to ossify, remaining cartilaginous until after birth.

FIG. 20.

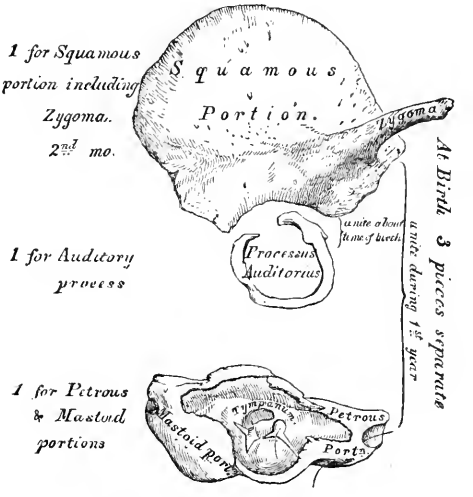

Development of the Temporal Bone by Four Centres.

The temporal bone is composed of four separate pieces at birth. The mastoid process has not appeared, and does not commence to develop until the second year; from this period it increases in size until adult life, the air-cells appearing about the age of puberty. The external auditory meatus at first is shallow, but increases in depth by the outgrowth of the united squamous and petro-mastoid portions above and behind, and the tympanic portion in front and below.

The glenoid fossa is superficial, the articulating eminence being slight. By the growth of the tympanic portion downward the depth of the fossa is increased.

The Sphenoid Bone.

The sphenoid bone is situated across the base of the skull, extending upward and anteriorly until it joins the frontal and parietal bones. It is placed mostly in front of, but partially internal to, the temporal bones. The posterior face of the body of the sphenoid bone articulates with the basilar process of the occipital bone; anteriorly the articulation is with the malar and palate bones, the ethmoid, and the vomer, and occasionally, through the inferior angle of its anterior border, with the superior maxilla. Acting as a key or wedge, the central location of this bone causes it to enter into the formation of the anterior and middle fossa of the brain-case by the inner, and of the temporal, zygomatic, and sphenomaxillary fossa by the external, surface; also the orbital and nasal cavities internally. It forms part of the roof of the pharynx, and the hamular process of its internal pterygoid plate can be reached through the mouth just posterior to the tuberosity of the superior maxillary bone. It gives support to the superior dental arch and origin to three of the four muscles of mastication. The great sensory nerve of the teeth and face and the branch of this nerve governing the muscles of mastication pass from the brain-case through three of the foramina of this bone. It also gives passage to the optic, motor oculi, pathetic, and abducens nerves, the ophthalmic artery and veins, and to two of the meningeal arteries.

For convenience of study the sphenoid bone is divided into a body and six processes, three on each side, a greater and lesser wing, and a pterygoid process composed of two plates. The body of the bone is cuboidal in shape, having six surfaces—a superior, inferior, anterior, posterior, and two lateral.

The Superior Surface (Fig. 21), the most irregular of the six, is situated within the brain-case. Its anterior border, known as the ethmoidal spine, is thin, projects forward and slightly upward, and by its centre articulates with the crista galli of the ethmoid bone. Just posterior to this spine is a smooth, slightly concave surface extending backward to the optic groove and laterally into the lesser wings. This surface forms part of the floor of the anterior fossa of the brain-case. The optic groove, slightly curved, passes nearly transversely across the body of the bone, and terminates on either side in the optic foramina. These foramina transmit the optic nerves and the ophthalmic arteries, while the groove lodges the optic commissure. Just behind the optic groove, and between it and the pituitary fossa (sella turcica), is a small surface of bone, the olivary process, which assists in supporting the optic commissure. Posterior to this process is a deep concavity, the pituitary fossa (sella turcica) for the reception of the pituitary body. All that portion of the bone situated behind this fossa, and between it and the spheno-occipital articulation, is termed the dorsum sellæ. At the superior lateral angles of this portion of the bone are the posterior clinoid processes. The posterior border of the lesser wings terminates in rounded points, the anterior clinoid processes. At the superior lateral angle of the anterior border of the pituitary fossa, on the posterior margin of the olivary process, is sometimes seen a small tubercle

of bone, the middle clinoid process. Occasionally this process is connected by a spiculum of bone with the anterior clinoid process, forming a foramen; more rarely to both the anterior and posterior processes, forming two foramina and a continuous and uninterrupted border from the superior anterior angle of the lesser wing to the superior angle of the dorsum sellæ.

The lateral surfaces of the body of the sphenoid bone are almost entirely within the brain-case. A small portion, however, of this surface runs forward and forms the proximal border of the foramen rotundum, the base and proximal boundary of the sphenoidal fissure, and continues forward until it meets the sphenoidal turbinated bones.

FIG. 21.

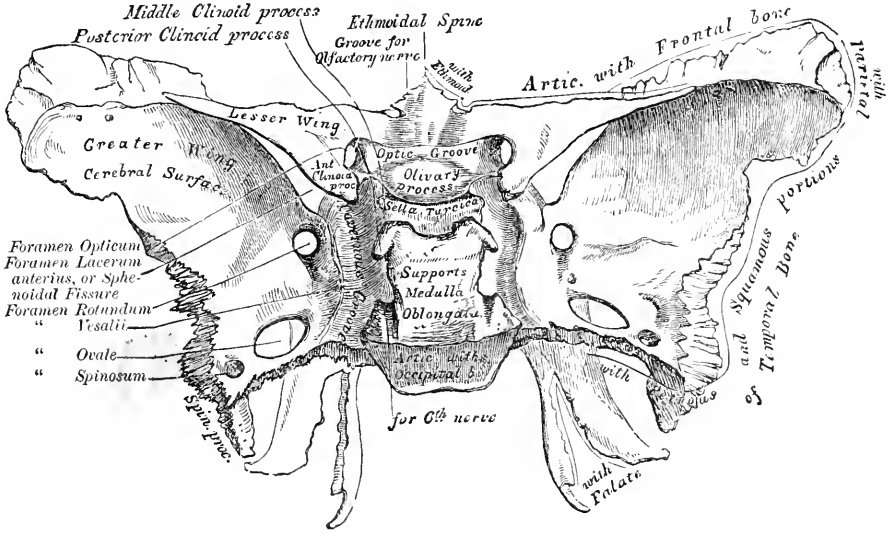

Sphenoid Bone, superior surface.

On that portion of the lateral surface within the brain-case is a marked depression, the sigmoid groove, for the accommodation of the internal carotid artery and the cavernous sinus.

The posterior surface is quadrilateral in shape. Until about the fifteenth year this surface is separated from the occipital bone, with which it articulates, by a layer of cartilage. At this time ossification commences between the two bones, and is completed about the twentieth year.

In the middle of the anterior (nasal) surface is a thin vertical lamina of bone which forms part of the septum of the nose and articulates with the perpendicular plate of the ethmoid bone. On each side of this lamina are irregular openings, varying in size in different bones, and often in the same bone; they lead into the sphenoidal sinuses situated in the body of the bone. The body of the bone is completely hollowed by these sinuses, which accounts for the complete thinness of its walls. The septum of bone between these cavities is generally deflected to

the one side or the other, making the sinuses of unequal size. Other incomplete septa may be seen at the posterior portion of these cavities, which divide them into several compartments. Sometimes they extend back and penetrate the basilar process of the occipital bone. They are lined by mucous membrane, which is continuous with that of the nasal cavity. The larger part of the anterior surface of the body is formed by the sphenoidal turbinated or spongy bones; they are triangular in shape, their apices pointing downward and backward, their upper margins being somewhat deflected, which opens a passage or communication between the sinuses and the nose. They are formed from separate points of ossification, but soon unite with the sphenoid behind and the ethmoid in front.

The Inferior Surface (Fig. 22) is apparently a continuation of the anterior. It presents in the middle line a triangular spine, the ros-

FIG. 22.

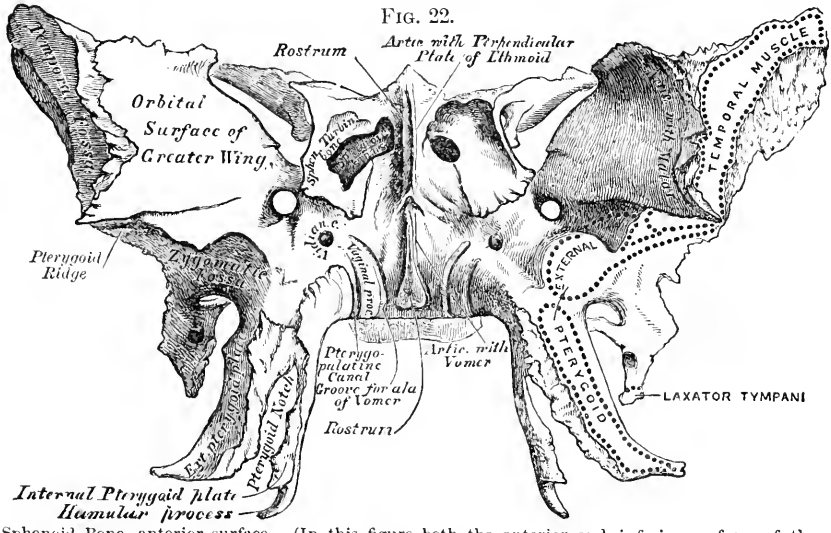

Sphenoid Bone, anterior surface. (In this figure both the anterior and inferior surfaces of the body of the sphenoid bone are shown, the bone being held with the pterygoid processes almost horizontal.)

trum, which is a continuation of the vertical lamina of the bone of the anterior surface, and articulates with the fissure formed by the alæ of the vomer. These alæ, together with the vaginal process of the sphenoid, which are prolongations of the internal pterygoid plates, cover the greater part of the inferior surface of the body of the bone, and lock the parts together.

The Greater Wings are two irregular strong processes of bone arising from the lateral surfaces of the body. They extend outward, forward, upward, and backward, and present for examination three surfaces, the internal, external, and orbital; and five borders, the superior, inferior, anterior, lateral, and posterior.

The Internal or Cerebral Surface is situated entirely within the brain-case, and forms part of the middle fossa of the cranium. This surface is deeply concave, and marked by eminences and depressions

for the convolutions of the brain. At the point where the wing joins the body of the bone anteriorly is a round opening, the foramen rotundum, which transmits the second division of the fifth nerve. About half an inch posterior to this may be seen an oval aperture larger than the preceding. This is called the foramen ovale, and transmits the third division of the fifth and the small petrosal nerves from within outwardly, and the lesser meningeal artery from without inwardly. Behind and a little external to the former, in the spinous process of the bone, is a small aperture, the foramen spinosum, for the transmission of the middle meningeal artery.

The External (*Temporo-zygomatic*) *Surface* is convex from above downward, and is divided into two portions, a superior and an inferior, by a ridge of bone, the infratemporal crest. The superior portion is the larger of the two, averaging about half an inch in width and an inch and a half in height. This is concave, forms part of the temporal fossa, and gives attachment to part of the temporal muscle. The inferior portion is also concave, enters into the formation of the zygomatic fossa, and gives attachment to the outer part of the external pterygoid muscle. The posterior border of this portion of the bone extends downward and outward, and terminates externally in a point of bone called the spinous process, which gives attachment to the internal lateral ligament of the lower jaw and the laxator tympani muscle.

The Orbital Surface, or that portion of the greater wing which assists in forming the outer wall of the orbit, is smooth, and may be divided for purposes of description into two portions, an outer and an inner, by an imaginary line drawn from the notch found in its superior border, for the accommodation of a branch of the lachrymal artery to a point just external to the foramen rotundum. The outer portion is quadrilateral in form, while the inner, or that immediately above the pterygoid process, is triangular.

The Quadrilateral or Outer Portion is composed principally of spongy tissue, though that which joins the malar bone is compact and helps to form the orbito-temporal partition. This surface articulates above with the frontal bone, externally with the malar bone, and inferiorly it forms the posterior boundary of the spheno-maxillary fissure. The inner portion is thin, being made up of compact tissue. The superior border forms the posterior boundary of the sphenoidal fissure. Just below this border, on the inner surface, near the imaginary line dividing the orbital surface, there is generally found a small spine of bone, for the origin of part of the lower head of the external rectus muscle.

Borders.—*The Superior Border* is divided into two portions, an outer and an inner; the outer is broad, triangular, and roughened, the greater part being for articulation with the frontal, the remainder with the parietal bone. The inner portion is thin, and forms the outer boundary and anterior superior angle of the sphenoidal fissure or anterior lacerated foramen.

The Inferior Border is smooth, rounded, and forms the posterior boundary of the spheno-maxillary fissure.

The Anterior or Malar Border is serrated for articulation with the malar bone.

The Lateral Border is serrated, and bevelled above and below by the projections of the outer plate and by the extension of the inner plate. This border articulates with the squamous portion of the temporal bone.

The Posterior Border (Fig. 23), somewhat concave in form, commences at the body of the bone and terminates in the spinous process, the outer

FIG. 23.

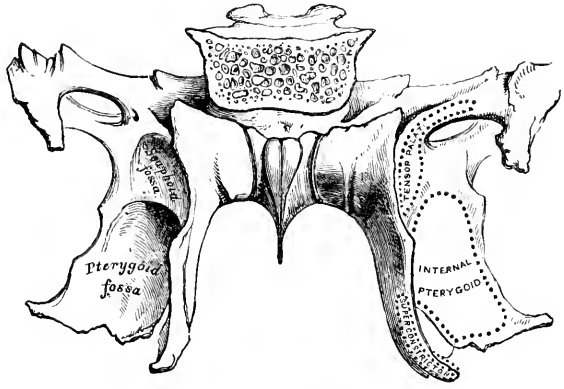

Sphenoid Bone, posterior surface.

portion being rough for articulation with the apex of the petrous portion of the temporal bone. The internal portion of this border is smooth, and forms the anterior boundary of the middle lacerated foramen, and is perforated by the posterior opening of the Vidian canal.

The Lesser Wings are two thin triangular plates of compact bone rising by two pedicles from the anterior superior portion of the body. They extend outwardly in the direction of the superior border of the greater wings, and terminate in short points. The superior surface of the lesser wing is smooth, being a continuation of the body of the bone, and helps to form the base of the anterior fossa of the brain-case. The inferior surface is part of the roof of the orbit, and forms the superior and part of the internal boundary of the sphenoidal fissure (lacerated foramen).

The Sphenoidal Fissure is an opening approaching an isosceles triangle in shape, the base of the triangle being the body of the bone, the apex extending outward to the notch in the superior border of the greater wing. When the sphenoid bone is articulated with the frontal, this fissure becomes the anterior lacerated foramen, which transmits from within outwardly the third, fourth, ophthalmic division of the fifth, which breaks into three branches in this foramen, and the sixth nerve, and from without inwardly the ophthalmic vein and a branch of the lachrymal artery. The anterior border of the lesser wing is serrated for articulation with the orbital plate of the frontal bone.

The Posterior Border of the lesser wing is short, and by its junction

with the lateral border forms the anterior clinoid process. The internal aspect of this border at the point where it joins the body of the bone is pierced by the optic foramen, which follows the line of junction of the lesser wing with the body.

The Lateral Border is free, smooth, and rounded, and is received into the fissure of Sylvius of the brain.

The Superior Pedicle is broad, thin, and forms the roof of the optic foramen.

The Inferior Pedicle forms the base and external boundary of the optic foramen. It is in shape a three-sided prism.

The Optic Foramen transmits the optic nerve and the ophthalmic artery.

The Pterygoid Processes project downward from the junction of the great wings with the body of the bone. Each process is composed of two plates, which separate at their lower third, forming a triangular notch for the reception of the pyramidal process of the palate bone, with which it articulates by a serrated surface. Above the pterygoid notch, anteriorly, is a smooth, triangular surface of bone which forms the posterior wall of the spheno-maxillary fossa. At the upper border of this triangular surface is seen the foramen rotundum, while at its superior inner angle, or apex, will be found the anterior opening of the Vidian canal. It is just at this point that the spheno-palatine or Meckel's ganglion is situated.

The external plate is broader than the internal. It is a continuation of the great wing, passing downward and outward, forming a concavity externally. Its anterior border articulates with the palate bone near to the tuberosity of the superior maxilla. Its external surface gives origin to the lower head of the external pterygoid muscle. The upper two-thirds of these two plates of bone are joined anteriorly. Posteriorly they diverge, forming the pterygoid fossa.

The Pterygoid Fossa.—The internal pterygoid muscle in this fossa arises from the outer plate only.

The inner plate is vertical, longer, and thinner than the outer plate. Its anterior border articulates with the palate bone. The posterior border is free, and forms the distal and lateral boundary of the posterior naris.

The Scaphoid Fossa.—Above the pterygoid fossa, and between it and the posterior opening of the Vidian canal, is situated the scaphoid fossa. It gives origin to the tensor palati muscle, the tendon of which descends the outer surface of the internal pterygoid plate to its inferior extremity, winds around the hook-like projection, the hamular process, and is inserted into the soft palate.

The hamular process can be felt at the posterior lateral portion of the mouth, behind the tuberosity of the superior maxilla.

Vaginal Process.—The internal pterygoid plate at its upper internal surface curves inwardly until it meets and partially leaves the body of the bone. The extremity of this curve is called the vaginal process. The internal surface of the external pterygoid plate forms part of the external wall of the nasal chamber.

DEVELOPMENT.—The sphenoid bone is developed from fourteen cen-

tres of ossification. There is a natural division of these ossific points into a posterior (postsphenoid) and an anterior (presphenoid) portion.

The Sella Turcica and the great wings belong to the former of these divisions, while that portion of the body in front of the olivary process and the lesser wings belong to the latter. This division is found complete and persistent throughout life in many of the lower animals. At about the eighth week of embryonal life ossification commences in the postsphenoid division. There is one nucleus for each great wing (alisphenoid), including the external pterygoid plates. About the same time two nuclei appear for the posterior part of the body of the bone (basisphenoid). These unite about the fourth month. After this union

FIG. 24.

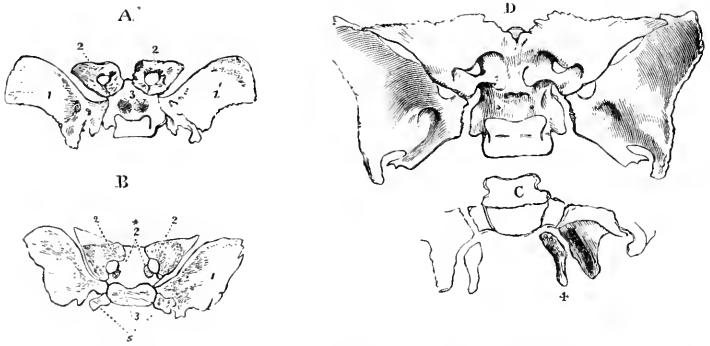

A, the sphenoid bone of a fœtus, aged about three months, is seen from above. The great wings are ossified; the body has two round granules of bone beneath the sella turcica, and the rest of it is cartilaginous. In the small wings, which are formed from a single centre, the ossification has encircled the optic foramen, and a small suture is distinguishable at its posterior and inner side. The internal pterygoid processes are still separate (4) in the preparation from which the drawing was made.—B. This figure is copied from Meckel (*Archiv*, Ed. i. Taf. vi. F. 23). It is stated to be from a fœtus at the middle of the sixth month. The two granules for the body are united, and a trace of their union is observable in the notch in front. The lateral projections of the body (5) are separate pieces.—C is a sketch of the back part of the preparation shown in A. The internal pterygoid process, which was united only by cartilage to the rest of the bone, has been drawn aside.—D. This figure represents the sphenoid at the usual period of birth. The great wings are separate. The anterior sphenoid is joined to the body.

1. The great wings; 2. The small wings; 2*. Additional nuclei for the small wing; 3. The body: 4. The internal pterygoid process; 5. The lateral processes of the body.

two other centres appear, from which are formed the tongue of the bone (basitemporal).

The Internal Pterygoid Plate arises from two separate points of ossification, which appear about the fourth month. The internal plates unite with the external pterygoid plates about the fifth or sixth month, and are analogous to the pterygoid bones of some animals, in which they remain separate throughout life. In the anterior (presphenoid) division ossification commences about the eighth or ninth week by two nuclei, which are deposited just outside the optic foramina. These form the lesser wings (orbito-sphenoid). Two more centres appear on the inside of the optic foramina, and form the presphenoidal portion of the body of the bone. Some authors describe this portion of the bone as developed from one centre of ossification, while others say that it is formed from the same centres of deposit which build the lesser wings. The sphenoidal turbinated bones arise from two centres of ossification, generally after birth.

At birth the sphenoid bone is in three separate parts, excluding the sphenoidal turbinated bones. The great wings and external pterygoid plates have joined the internal pterygoid plates on either side, and the posterior portion of the body has joined the anterior portion, including the lesser wings. The great wings join the body about the end of the first year. The spheno-turbinated bones unite with the body, and the posterior surface of the body with the basilar process of the occipital bone about the age of puberty.

The Parietal Bone.

The parietal bones form a large portion of the walls and the greater part of the roof of the brain-case. They are two in number, quadrilateral in shape, and have two surfaces, an external and an internal; four borders anterior, posterior, superior, and inferior; and four angles, anterior superior, posterior superior, anterior inferior, and posterior inferior.

The External Surface (Fig. 25) is convex in form, the greatest con-

Fig. 25.

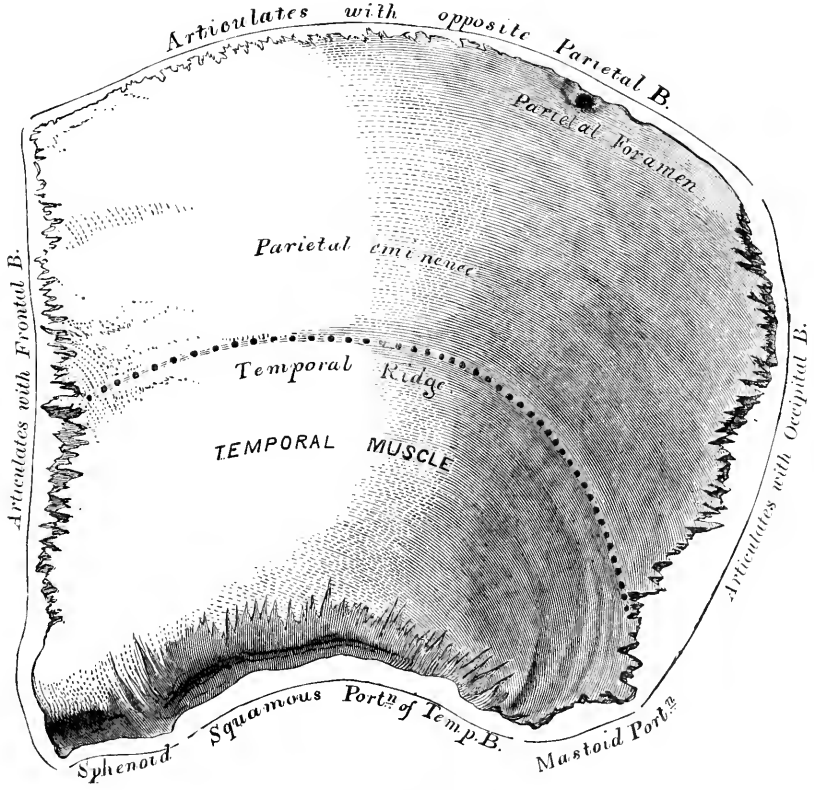

Left Parietal Bone, external surface.

vexity being in the centre of the bone, forming the parietal eminence and indicating the point where ossification commences. Below this

eminence is always one, and generally two, curved lines: the lower one marks the superior boundary of the temporal fossa, and divides the bone into two portions; the upper one limits the attachment of the temporal aponeurosis. The superior portion of the external surface is rough, porous, and covered by the aponeurosis of the occipito-frontalis muscle. Close to the upper border, near the posterior superior angle, in one bone or the other, is a small foramen, the parietal foramen, which transmits a vein to the superior longitudinal sinus. This foramen is not constant; it varies in size in different bones: sometimes it is situated between the two bones. The inferior portion is flatter and smoother than the superior, and forms part of the temporal fossa.

The Internal Surface (Fig. 26) is deeply concave, and forms the parietal fossa. It presents eminences and depressions corresponding to the

FIG. 26.

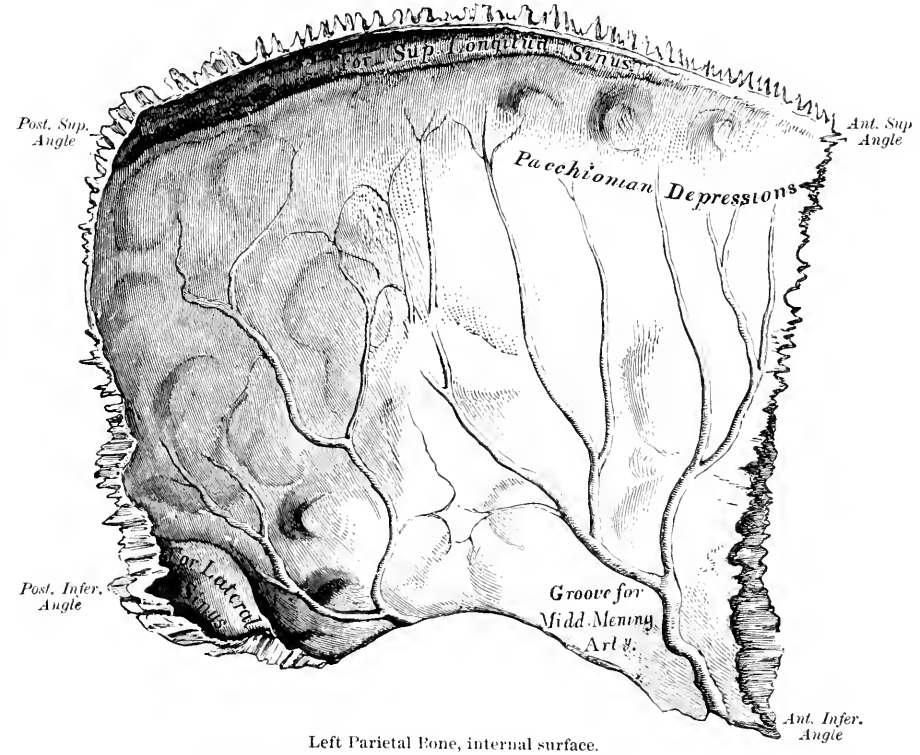

Left Parietal Bone, internal surface.

convolutions of the cerebrum. Near the anterior inferior angle, at a point posterior to the middle of the inferior border, will be seen the commencement of grooves which extend upwardly and divide into numerous branches. These grooves are for the accommodation of the anterior and posterior branches of the middle meningeal arteries. Sometimes the groove commencing at the anterior inferior angle has its origin in a long canal. Along the inner aspect of the superior border of this bone is a slight depression, which, together with its fellow on

the opposite side, forms the groove for the longitudinal sinus. The elevated edges of this groove give attachment to the falx cerebri. Below this groove, especially in bones of old subjects, are seen several depressions, which lodge the Pacchionian bodies. Extending across the posterior inferior angle of the bone is a depression which forms part of the groove for the lateral sinus.

Borders.—*The Anterior Border* is deeply serrated, and above is slightly bevelled by the prolongation of the inner table, but toward the lower angle it is bevelled by the extensions of the external table. This anterior border articulates with the frontal bone, forming the parieto-frontal part of the coronal suture.

The Posterior Border is irregular in outline, deeply serrated, and articulates with the occipital bone, forming the parieto-occipital part of the lambdoid suture. Numbers of what are known as Wormian bones are often found attached to this border.

The Superior Border is the longest and thickest of the four. It is deeply serrated, and articulates with its fellow on the opposite side, forming the interparietal or posterior portion of the sagittal suture, being all that remains after the ossific union of the two halves of the frontal bone. Wormian bones are less frequently found in this border.

The Inferior Border is divided into three portions. The anterior portion, about half an inch in extent, is thin and fluted, bevelled on its outer surface for articulation with the great wing of the sphenoid bone, which overlaps it and forms the spheno-parietal suture. The posterior portion is thick, serrated, and articulates with the mastoid portion of the temporal bone, forming the masto-parietal suture.

Angles.—The anterior superior angle is nearly a right angle. It is completely ossified in adult life, but in infancy it is membranous, and in conjunction with the membranous portions of the bone of the opposite side and the adjoining portion of the frontal bone forms the anterior or great fontanelle.

The posterior superior angle is an obtuse angle. In the articulated skull it is situated at the junction of the interparietal (sagittal) and parieto-occipital (lambdoid) sutures. In infancy this space is occupied by the posterior superior fontanelle.

The Anterior Inferior Angle is the most prominent of the four. It is thin and elongated, filling up the space between the frontal bone and the squamous portion of the temporal bone. It articulates with the great wing of the sphenoid bone. In infancy this space is occupied by the anterior inferior fontanelle.

The Posterior Inferior Angle is thick, broader, and more rounded than the others, and articulates with the mastoid portion of the temporal and the lateral angle of the occipital bone; this is the location of the posterior inferior fontanelle in infancy.

Structure.—The parietal bone is made up of an outer plate of compact tissue and an inner vitreous table, enclosing between them a mass of cancellated fibrous bone.

Development.—The parietal bone is developed within a membranous matrix from one point of ossification, which appears about the sixth week of embryonal life.

Frontal Bone.

The Frontal Bone (Fig. 27) is symmetrical in form—*i. e.* equal on both sides of the median line of the head. It is situated in front of the two parietal and a portion of the sphenoid bones, and above the malar, lachrymal, nasal, part of the sphenoid, and ethmoid bones. Though it is a true cranial bone, it forms that portion of the face called the forehead, and is included in the "facial region." Its ascending portion forms the anterior boundary and part of the roof of the brain-

Fig. 27.

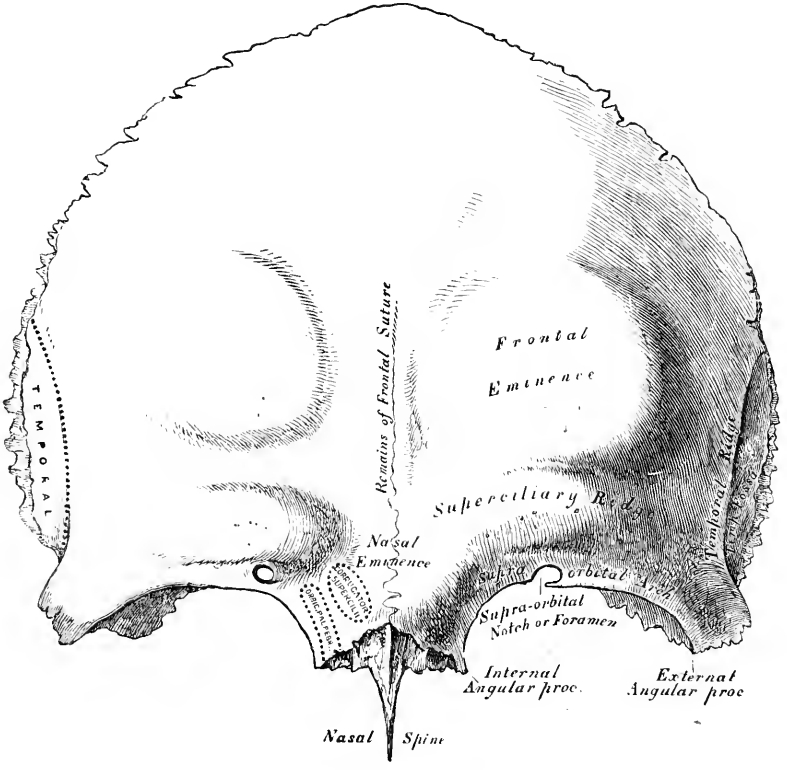

Frontal Bone, outer surface.

case. Its horizontal portion forms nearly the entire floor of the anterior fossa of the skull and the roofs of the orbits. Laterally, the bone also enters into the formation of the temporal fossa. It is composed principally of compact tissue, and is divided into an ascending and a horizontal portion.

The ascending portion commences at the supraorbital arch, and extends upward and backward until it articulates with the parietal bones. It has two surfaces, an external and an internal, and is divided in the median line by a slight ridge. In young subjects before this ridge is developed a suture occupies this line.

The Supraorbital Arches are prominent curved borders of bone, forming the superior boundaries of the orbits. They are most prominent toward their outer extremities, and form the dividing-line between the horizontal and ascending portions of the bone.

The Supraorbital Notch or Foramen.—At the inner third of the supraorbital arch is a well-defined notch, the supraorbital notch; sometimes this is converted into a foramen by a spiculum of bone thrown out from its lower margin. When this spiculum is not present the foramen is formed by fibrous tissue. It transmits the frontal branches of the ophthalmic nerve, artery, and vein. There is generally a small opening in the base of the notch for the passage of an emissary vein from the diploë to join the ophthalmic vein.

The Frontal Notch is not constant: when it is, it is situated to the median side of the supraorbital notch.

The External Angular Process.—The outer extremity of the supraorbital arch terminates in the external angular process. This is strong, and projects to articulate with the frontal process of the malar bone; the outer margin forms a sharp curved crest, which is the commencement of the temporal ridge and affords attachment to the temporal fascia. Just posterior to this crest is a slight concavity which forms the anterior boundary of the temporal fossa.

The Internal Angular Process.—The inner extremity of the supraorbital arch terminates in the internal angular process, which is less marked than the external, and articulates with the lachrymal bone. It also gives origin to part of the orbicularis palpebrarum muscle.

The Nasal Eminence is between and slightly above the two internal angular processes; it is a rounded elevation which forms a portion of the anterior wall of the frontal sinuses.

The Frontal Sinuses are two irregular chambers situated above and between the orbital plates, and separated by a thin lamina of bone. They appear about the second year, and are formed by the dissolution of tissue through the agency of osteoclasts. They continue to increase in size until advanced age, at which time they often extend over the orbits and occupy a larger or smaller portion of the bone above the superciliary ridge: in the hollow-horned animals these cavities extend into the bony base or cores of the horns. They are lined by mucous membrane, and communicate with the nasal chambers through the infundibulum of the ethmoid bone.

The Nasal Notch is situated below the nasal eminence: it is a semilunar serrated border of bone for articulation with the ascending process of the superior maxillæ, the vertical plate of the ethmoid, and the nasal bones.

The Nasal Spine is a prominent process of bone in the centre of the nasal notch: it is firmly wedged between the nasal bones when they are in position.

The Superciliary Ridges are above the supraorbital arches: they are broad externally, where they are continuous with the nasal eminence. They curve outwardly, becoming less prominent as they approach the lateral surface of the bone. The internal portions of these ridges give origin to the corrugator supercilii muscles.

The Frontal Eminences are about an inch above the superciliary ridges, near the centre of each lateral half of the bone: they are two rounded prominences, varying in size in different individuals, and are seldom of equal size in the same bone.

The External or Upper Surface is smooth and rounded, and passing over it is the aponeurosis of the occipito-frontalis muscles.

The Inner or Encranial Surface (Fig. 28) is marked by depressions for the convolutions of the brain; by grooves running inwardly from

FIG. 28.

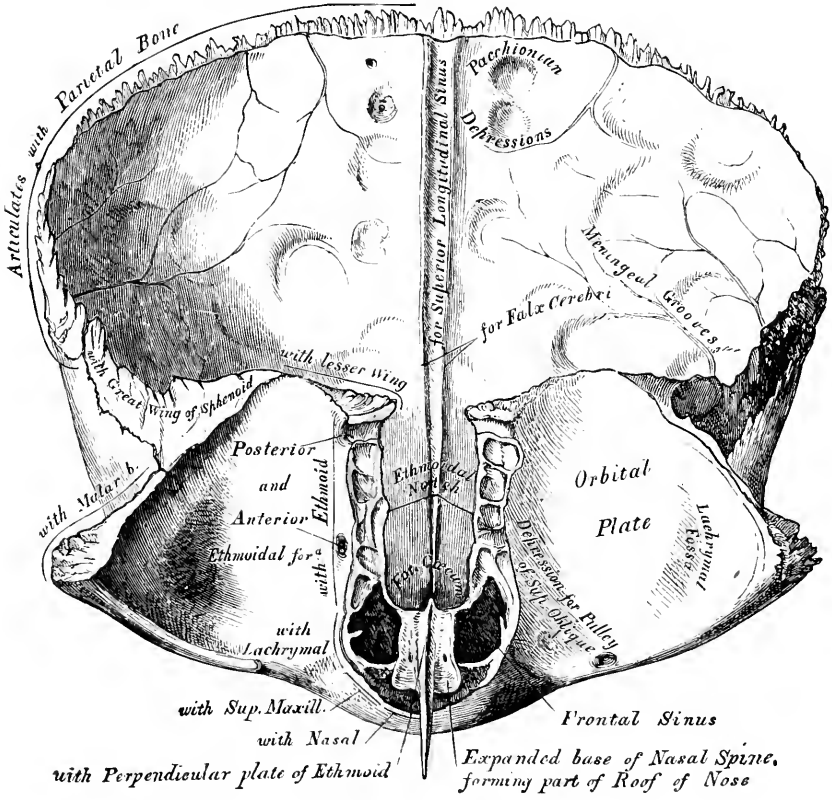

Frontal Bone, inner surface.

the lateral border for the accommodation of the anterior meningeal arteries and their branches; and by several irregular hollows on either side of the median line for the lodgment of the Pacchionian bodies.

The Internal Frontal Crest is the anterior termination of a groove which occupies the median line of the internal surface of the bone.

The Foramen Cæcum, anterior to the frontal crest, is a groove which, when the frontal bone is articulated with the ethmoid, forms a blind foramen. This foramen is continuous in childhood with the nasal chambers, and transmits a small vein to the longitudinal sinus. In adult life this so-called foramen is closed at its base.

The Longitudinal Sinus commences at the foramen cæcum, passes upward along the frontal crest to the groove, and thence backward over the internal surface of the dome of the brain-case to the internal occipital protuberance.

The Horizontal Surface is divided by the ethmoidal notch into two portions, the orbital plates. The orbital plates are two concavo-convex, triangular surfaces of bone separated by the ethmoidal notch. They are each composed of two thin plates of compact tissue, the space between them being largely occupied by the frontal sinuses.

The Inferior Surfaces of the orbital plates are concave and form the roofs of the orbits.

The Lachrymal Fossæ are slight depressions just internal to the external angular process within the orbits; they lodge the lachrymal glands.

The Trochlear Fossæ are small concavities, sometimes tubercles, situated immediately behind the internal angular processes, within the orbits; they afford attachments to the pulleys of the superior oblique muscles.

The Superior or Encranial Surfaces of the orbital plates are convex in form, deeply marked by eminences and depressions for the convolutions of the brain: they form the greater portion of the floors of the anterior fossæ of the brain-case. The "digital depressions" are so called because of a fancied resemblance to markings made by pressing the ends of the fingers upon some soft substance.

The Ethmoidal Notch, between the two orbital plates, is a quadrilateral opening. In the articulated skull this notch is filled by the cribriform plate of the ethmoid bone. On each side of the nasal spine, running its entire length, is a grooved surface which enters into the formation of the roofs of the nasal chambers.

The Fronto-ethmoidal Cells.—The borders of the ethmoidal notch are marked by numerous depressions, which form half cells of irregular shape. The ethmoid bone contains depressions of similar form in the superior surface of its lateral masses, and when articulated with the frontal bone forms the fronto-ethmoidal cells.

The Anterior and the Posterior Ethmoidal Foramina.—The borders of the ethmoidal notch are each traversed at various angles by two grooves. In the articulated skull these grooves, in connection with similar ones in the ethmoid bone, form the anterior and posterior ethmoidal foramina. The anterior foramina transmit the nasal nerves and the anterior ethmoidal blood-vessels, while the posterior foramina transmit the posterior ethmoidal blood-vessels.

The Borders of the Frontal Bone.—The upper half of the ascending border is thick, serrated, and slightly bevelled by the prolongation of the upper table. The lower half of this border is thinner than the upper; it is serrated and bevelled by extension of the inner plate. The upper seven-eighths of the border of the bone on either side articulate with the parietal bones, forming the fronto-parietal (coronal) suture. The lower eighth is rough and triangular, and articulates with the great wing of the sphenoid bone, forming the spheno-frontal suture.

The inner border of the horizontal portion of the bone, just external

to the posterior margin of the ethmoidal notch, is thin and serrated, and articulates with the lesser wing of the sphenoid bone.

Fig. 29.

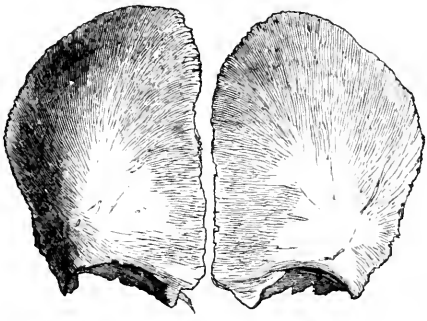

Frontal Bone at Birth, developed by two lateral halves.

Development.—The frontal bone is an intra-membranous bone, developing from two centres of ossification, which are deposited, one on each side above the orbital arches, about the seventh week of embryonal life. At birth the bone is in two portions, which about the first year unite by a vertical suture (saggital) in the median line. The union commences from below and extends upward; it is generally completed about the third year, though occasionally the two halves remain separate much later in life.

Ethmoid Bone.

The ethmoid bone (Fig. 30), like the occipital, sphenoid, frontal, vomer, inferior maxillary, and all bones in the median line of the skeleton, is symmetrical. It is cuboid in form, and though a true

Fig. 30.

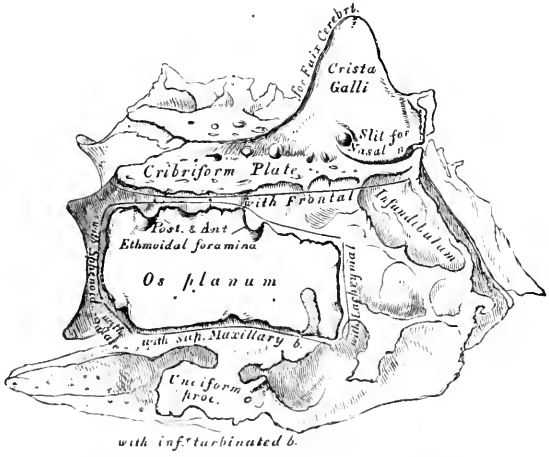

Ethmoid Bone, outer surface of right lateral mass (enlarged).

cranial bone it extends largely into the region of the face. It is situated at the anterior part of the brain-case, between the orbits, and forms part of the floor of the anterior cerebral fossa. When articulated it closes the ethmoidal notch in the frontal bone and forms the greater part of the internal walls of the orbital cavities. It also forms the roof and part of the septum and external walls of the nasal chambers. It is divided into a vertical plate and lateral masses, with a horizontal

(cribriform) plate uniting the masses. The vertical plate (meso-ethmoid) is again divided into the perpendicular plate and the crista galli.

The Perpendicular Plate (Fig. 31) is a thin lamina of compact bone situated in the median line between the two lateral masses. It extends

FIG. 31.

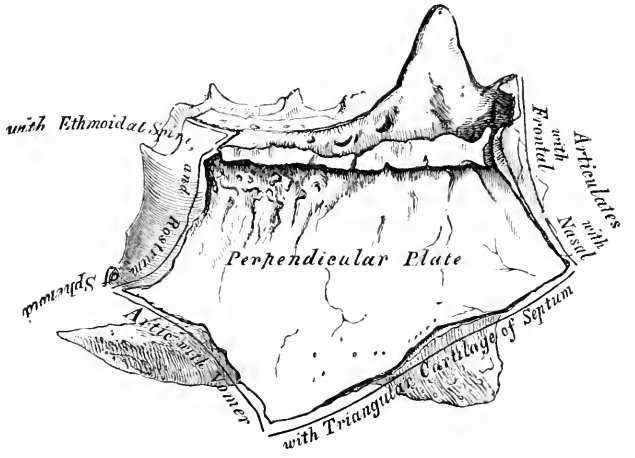

Perpendicular Plate of Ethmoid (enlarged), shown by removing the right lateral mass.

downward and forward in the direction of the intermaxillary suture, though it is frequently deflected to the one side or the other. It forms the upper third of the septum of the nose, and articulates posteriorly with the crest of the sphenoid bone.

BORDERS.—The superior border of the perpendicular plate conjoins the cribriform plate.

The Inferior Border is divided nearly in the centre into two portions. The posterior inferior portion articulates with the vomer, while the anterior inferior is roughened for the attachment of the nasal cartilage. This cartilage is triangular in shape, and in the recent state forms part of the septum of the nose.

The Anterior Border articulates with the under surface of the nasal bones and also with the nasal spine of the frontal bone.

Grooves for Olfactory Nerves.—Immediately below the cribriform plate, on the sides of the perpendicular plate, are fine grooves, running downward, forward, and backward, in which are lodged the olfactory nerves.

The Crista Galli (named from its resemblance to a cock's comb in shape) is an extension of the perpendicular plate above the horizontal portion of the bone between the anterior fossæ of the brain-case. It is ivory-like in appearance.

The anterior border of the crista galli is vertical in direction and grooved at its base. In the articulated skull this groove, joining a similar one in the frontal bone just anterior to the internal frontal crest, forms the so-called foramen cæcum.

The Ethmoidal Wings.—Extending outwardly from the base of the

crista galli are two wing-like processes of bone, the ethmoidal wings or alæ.

The posterior border of the crista galli is long, thin, and slightly curved.

The longitudinal fold of the dura mater and the commencement of the falx cerebri are both attached to the crista galli.

Lateral Masses (Fig. 32).—The lateral masses (ethmo-turbinated) are cuboidal in form and present six surfaces—the superior and inferior, external and internal, anterior and posterior.

FIG. 32.

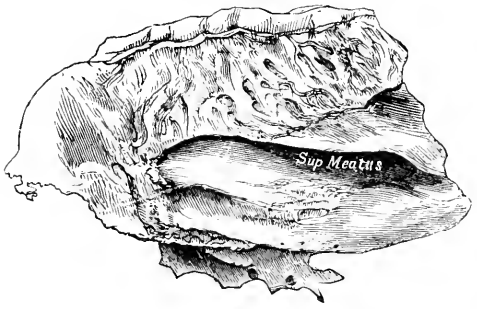

Ethmoid Bone, inner surface of right lateral mass (enlarged).

The Superior Surface.—The anterior portion is composed of irregular cell-like openings, which are covered in and completed by articulation with the frontal bone.

The Ethmoidal Foramina (*Internal Orbital Canals*).—Crossing this border, about half an inch apart, are two slight grooves, which, when conjoined to similar grooves on the external border of the ethmoidal notch of the frontal bone, form the anterior and posterior ethmoidal foramina: the first transmits the internal nasal nerve, a branch of the ophthalmic and anterior ethmoidal vessels, the posterior transmitting the posterior ethmoidal vessels and spheno-ethmoidal nerve, a branch of the nasal.

The Inferior Surface extends from the inferior external border of the lateral mass to the free margin of the middle turbinated bone in the articulated skull, and from the anterior to the posterior surface of the lateral mass. It is divided into three portions:

(*a*) The external portion lies between the inferior external border of the lateral mass and the uncinate process anteriorly, the middle and posterior line being formed by a curved plate of bone in the median line of the inferior surface of the external mass. This portion articulates with the superior border of the nasal surface of the superior maxilla, closing in the cell-like cavities found on that border.

(*b*) Anteriorly, the middle portion is formed by the uncinate process and posteriorly by the curved plate of bone forming the internal wall of the anterior ethmoidal cells. The uncinate process arises from the middle of the anterior surface of the ethmoid bone, and extends downward, outward, and backward, being somewhat hook-shaped in outline. It articulates with the inner surface of the nasal process of the superior maxilla, the ethmoidal process of the inner surface of the lachrymal bone, and the inferior turbinated bone; it also assists in closing the orifice leading to the maxillary sinus.

(*c*) The internal portion is free, and is formed by the curved border of the middle turbinated bone in the articulated skull.

The Internal or Nasal Surface is the most complex portion of the bone. It forms part of the external wall of the nasal chamber, or all

that portion of the wall which is devoted to olfaction. It commences at the cribriform plate and descends downward and slightly forward. Its posterior two-thirds is divided by a sulcus, which is directed backward and inward. This groove forms the superior meatus of the nose. It extends backward to the posterior margin of the bone and terminates in a deep notch. The anterior third of the internal surface is uninterrupted from the cribriform plate to its lower border.

The Superior Meatus divides the internal surface of the lateral mass into two portions—the superior and middle turbinated bones; it extends antero-posteriorly upward, outward, and forward from the median line, and communicates with the ethmoidal cells.

The Superior Turbinated Bone is all that portion between the sulcus and the cribriform plate.

The Middle Turbinated Bone is that portion of the internal surface lying below the sulcus and between it and the lower free border. The middle turbinated bone is free, and extends downward into the nasal chamber. Its lower border curves outward and upward toward the superior maxilla, the outer surface of the curve appearing like a scroll. This bone overhangs the middle meatus of the nose.

The Infundibulum.—At the anterior portion of the middle meatus may be seen a passage known as the infundibulum, leading up through the anterior ethmoidal cells into the frontal sinus.

The External or Orbital Surface of each lateral mass is a thin, smooth lamina of bone, quadrilateral in form. Its length from the front to the back is about double its width. This surface has also received the name "os planum," on account of its smoothness; it forms part of the inner wall of the orbit. The two grooves which in the articulated bone assist in forming the anterior and posterior ethmoidal foramina indent the superior edge of this surface, which articulates with the frontal bone. The inferior edge articulates with the superior maxilla.

The Anterior Surface extends inwardly from the os planum until it reaches the nasal surface of the bone. It presents numerous cell-like depressions. The inner portion of the anterior surface articulates with the nasal process of the superior maxilla, the internal portion being covered by the lachrymal bone; this, with the aid of the frontal bone, already referred to, completes the anterior ethmoidal cells.

The Posterior Surface of the lateral masses is thin and penetrated by numerous openings. It is divided into two portions, a superior and an inferior. The superior portion articulates with the turbinated plates of the sphenoid bone, and the inferior portion with the orbital process of the palate bone. These bones conjointly complete the posterior ethmoid cells.

The Cribriform Plate is symmetrical in outline, being divided into two lateral halves by the crista galli. It forms part of the base of the anterior fossa of the brain-case, and fits the ethmoidal notch of the frontal bone. It unites the two lateral masses and vertical plate of the bone. The olfactory sulcus, for the lodgment of the olfactory bulbs of the brain, are depressions of the cribriform plate situated on each side of the crista galli. This plate is pierced by numerous foramina for the transmission of the filaments of the olfactory nerves: those next the crista galli pass

into the delicate perpendicular grooves and canals of the perpendicular plate of the bone; next and external are those for the filaments distributed to the roof of the nasal chambers; and the outer ones pass into fine canals which subdivide as they penetrate the lateral masses of the bone. Some anatomists speak of these holes as forming three rows or lines, but the irregular arrangement of them makes it an ideal rather than a definite or distinct description.

The Cerebro-nasal Slit is immediately posterior to the ethmoidal wings at the base of the crista galli. It is a narrow or strait opening uniting the cranial cavity with the nasal chamber. External to this above may be seen a groove extending posteriorly to the anterior ethmoidal foramen. The passage, groove, and foramen are for the accommodation of the nasal nerve, a branch of the ophthalmic, and also a branch of the ophthalmic artery.

DEVELOPMENT.—The ethmoid bone arises from three points of ossification—one for each lateral mass, the other for the perpendicular and cribriform plates. They are deposited in the orbital plates of the lateral masses about the fourth or fifth month, and gradually extend into the turbinated bones. During the first year it commences to ossify in the perpendicular and cribriform lamellæ, the three parts uniting early in the second year, ossification being completed during the fourth or fifth year, at which time the ethmoidal cells commence formation.

VOMER.

The Vomer (Fig. 33) is a single bone, situated in the median line of the nasal chamber, forming the principal portion of the bony sep-

FIG. 33.

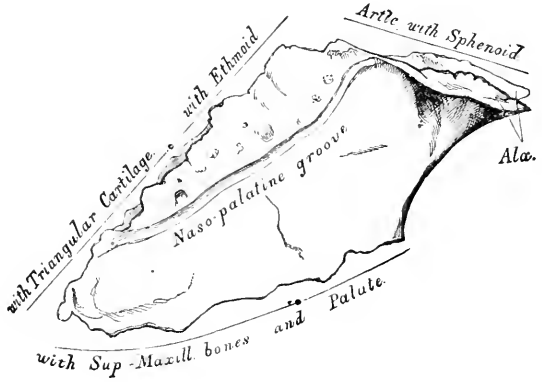

Vomer.

tum. It usually is more or less deflected to one or the other side, and is placed in front of and below the sphenoid bone, with the rostrum of which it articulates, and below the ethmoid bone, articulating with the perpendicular plate of the latter. It is a thin plate of bone, rhomboidal in form, having four borders, superior, inferior, anterior, and posterior; and two surfaces, a right and a left.

The Superior Border is the thickest of the four, and is shaped like the letter V. The upper portion of this V is described as two alæ or wings, which extend on both sides of the rostrum of the sphenoid bone. The lateral edge of each wing articulates with the superior margin of the internal plate of the pterygoid process (vaginal process) of the sphenoid bone and the sphenoidal process of the palate bone.

The Inferior Border is long, thick, and uneven, for articulation with the nasal crest of the superior maxillary and palate bones. It is thinner posteriorly where it articulates with the latter bones.

The Anterior Border slopes downward and forward at an angle of about forty-five degrees. The upper half of this border generally consists of two thin laminæ of bone, between which articulates the perpendicular plate of the ethmoid. The inferior half is rough and uneven, to give attachment in the recent state to the nasal cartilage.

The Posterior Border is free, and forms the septum of the posterior nares. It is the shortest of the four borders—thin, smooth, and slightly concave.

The Surfaces.—The right and left surfaces are smooth, but marked by narrow grooves for the accommodation of blood-vessels. A larger groove, sometimes formed into a canal (naso-palatine), traverses each surface of this bone, running downward and forward, terminating in the anterior palatine canal in the intermaxillary suture. These grooves transmit the naso-palatine vessels and nerves.

DEVELOPMENT.—The vomer is an intracartilaginous bone formed from one centre of ossification, which makes its appearance in the posterior part of the bone at about the eighth week of embryonic life. From this centre two laminæ arise, and pass upward and forward on each side of the median line until they meet the nasal cartilage. These two plates of bone gradually unite from behind forward until about the age of puberty, at which period they form a single plate of bone, marked on its anterior and superior borders by a slight groove, indicating the position where the two parts unite.

SUPERIOR MAXILLARY BONES.

The superior maxillary bones are of the utmost importance to the dentist and to the surgeon. They give support to the upper teeth and are subject to defects of development and to various pathological changes. Chief among these may be mentioned cleft palate, congenital or acquired, necrosis, caries, and odontocele. Either of these bones may be affected by alveolar abscess, diseases of the antrum, which may give rise to such symptoms as impaired respiration and discharge of offensive matter through the nasal chamber. Tumors or abscesses of the antrum often grow to such a size as to elevate the floor of the orbit, depress the roof of the mouth, and bulge out the wall of the cavity, distorting the face in the region of the canine fossa. Neuralgic trouble in the teeth may be only symptomatic of disease of this bone, as neuralgia in the head often may be traceable to the teeth. It is therefore highly necessary that the bone should be carefully studied.

Together, the superior maxillæ are, of the bones of the face, second in

importance and size only to the lower maxilla. When articulated they form the bony base of the entire central portion of the face. Each one assists in forming three cavities—first, part of the floor and the infra and internal borders of the orbit; second, part of the sides and floor of the nasal chamber; third, it contributes largely to form the roof or hard palate of the mouth. It also assists in the formation of the zygomatic and spheno-maxillary fossæ and the spheno-maxillary and pterygo-maxillary fissures.

Its body forms the walls of the maxillary sinus (antrum Highmorianum). It presents for examination a body, four surfaces, the orbital, the proximal or nasal, the lateral or facial, and posterior or zygomatic; and four processes, the nasal, the malar, the palatal, and the alveolar.

The Body (Fig. 34) may be compared to a very irregular triangular

FIG. 34.

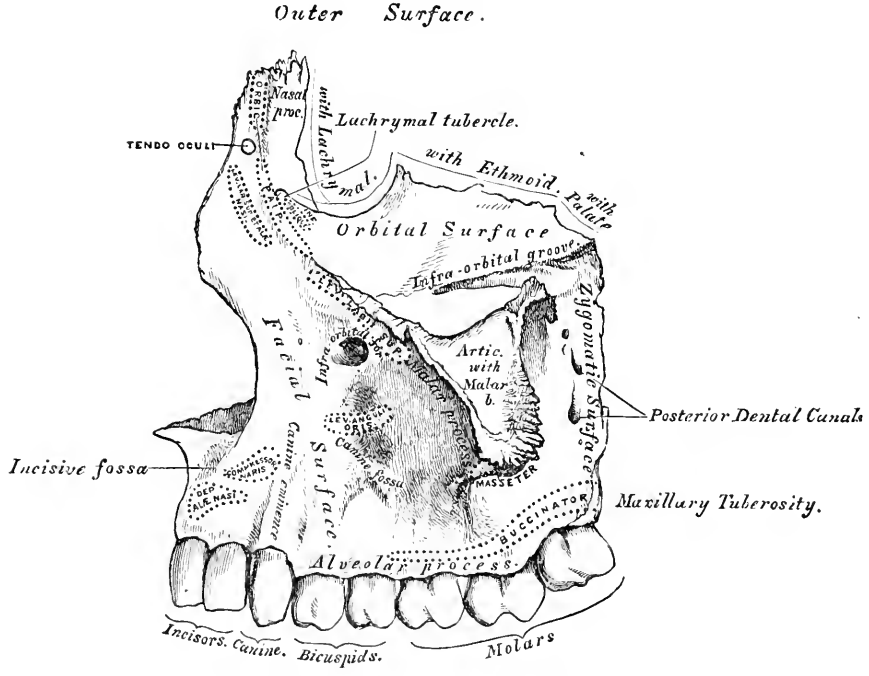

Left Superior Maxillary Bone, outer surface.

pyramid, the base being the proximal surface and the apex under the malar process.

The Orbital Surface is a triangular plate, smooth and slightly concave, constituting the greater part of the floor of the orbit.

The Infraorbital Canal runs forward from the posterior border as a groove, which at the centre dips or is covered by the orbital floor, and makes its exit just above the centre of the facial surface, at the infra-orbital foramen. It transmits the infraorbital vessels and nerve. A branch of the infraorbital canal passes down the anterior wall of the maxillary sinus and transmits the anterior dental nerve and vessels.

Just external to the junction of this plate with the nasal process is a small depression which gives origin to the inferior oblique muscle of the eye.

The Mesial Border of the orbital surface at its anterior portion is smooth, and in it is the commencement of the lachrymal groove, which in the articulated skull becomes a canal and runs downward and slightly backward to communicate with the inferior meatus of the nose. The remainder of this border is roughened for articulation with the lachrymal bone anteriorly and the os planum of the ethmoid bone posteriorly.

The Anterior Border of the orbital plate and the orbital process of the malar bone from the infraorbital ridge is sharp at its inner third, but the remainder is rounded.

The Posterior Border of the above plate is frequently referred to as the outer border: it extends from the centre of the malar process backward and inward to the orbital process of the palate bone. The inarticulated portion of this border, together with part of the orbital process of the palate bone, forms the anterior boundary of the spheno-maxillary fissure.

The Proximal or Nasal Surface (Fig. 35) presents a large irregular opening into the maxillary sinus. This orifice is partially closed by

FIG. 35.

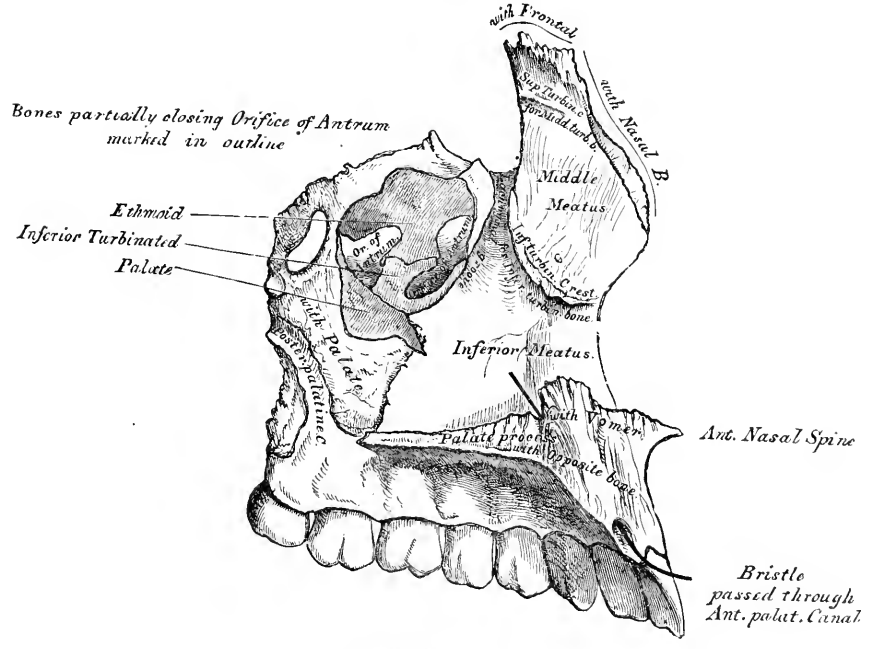

Left Superior Maxillary Bone, inner surface.

articulation with the lachrymal, the uncinate process of the ethmoid, the vertical plate of the palate, and the ethmoidal process of the inferior turbinated bones of the same side. In the articulated skull one or two small openings communicate from the antrum with the middle meatus

of the nose. Usually there is left but one small opening. Along the superior border of this surface are a number of cellular openings, which are closed in by articulation with the lachrymal and ethmoid bones. The anterior two-thirds of the thin plate of bone below the aperture is smooth and concave, forming most of the external wall of the inferior meatus of the nose. The posterior third is slightly roughened for articulation with the vertical plate of the palate bone.

The Lachrymal Groove is at the anterior superior angle of the nasal surface, behind the nasal process: it is converted into a canal by articulation with the lachrymal bone, the uncinate process of the ethmoid, and the lachrymal process of the inferior turbinated bone. The canal extends downward and backward, terminating in the inferior meatus of the nose. In the recent state it is lined by a mucous membrane, the lachrymal duct.

The Lachrymal Tubercle is a small prominence of bone at the junction of the infraorbital ridge with the external border of the nasal process. This tubercle serves as a guide to the lachrymal sac, which is the expanded portion of the lachrymal duct, situated posterior to the tubercle.

The Posterior Palatine (*Palato-maxillary*) *Canal*, for the passage of the posterior palatine vessels and anterior palatine nerves, commences about the middle of the posterior border of the bone and runs downward and forward as a groove, which in the articulated bone is closed by the vertical plate of the palate bone to form a canal.

The Anterior Border of the nasal surface is thin and deeply indented in its central portion, forming the lateral boundary of the anterior naris. The portion of this border above the indentation is roughened and articulates with the nasal bone; that below articulates with its fellow of the opposite side, and forms half of the nasal spine.

The Lateral or Facial Surface is concave, and extends from the anterior border to the root of the malar process. The outer portion of its superior border is roughened for articulation with the lower border of the orbital process of the malar bone. Internally, this border is smooth, and curves upward from the inner portion of the infraorbital ridge.

The Infraorbital Foramen.—Just below this ridge, about midway of the border, is an oval aperture for the passage of the infraorbital nerve and vessels. Between this foramen and the infraorbital ridge arises the proper elevator muscle of the upper lip (levator labii superioris proprius).

The Canine Eminence is a vertical ridge that divides the lower portion of this surface, and corresponds in position to the root of the canine tooth. It gives origin to the depressor muscle of the wing of the nose and also to the depressor of the upper lip. *The Incisive or Myrtiform Fossa* is a slight depression between the canine eminence and the median border of the bone. It gives origin to the depressor muscle of the wing of the nose and to the depressor of the upper lip. Above, and a little external to the incisive fossa, arises the compressor of the nose (compressor nasi).

The Canine Fossa is a larger depression on the outer side of the canine eminence. The floor is very thin, and an opening into the antrum may be readily made through it. This fossa gives origin to the elevator muscle of the angle of the mouth (levator anguli oris).

The Posterior or Zygomatic Surface is convex, and extends from the root of the malar process inward and backward to its articulation with the vertical plate of the palate bone.

The Superior Border is well defined, and is the dividing-line between this and the orbital surfaces. The central portion of the border is marked by the infraorbital groove.

The Posterior Superior Angle is bevelled for articulation with the orbital process of the palate bone.

The Tuberosity is a rounded eminence of bone just behind the posterior inferior angle, back and above the wisdom tooth; it is often so fragile as to be broken away in extracting this tooth, the roots of which curve upward, outward, and backward in it. The inner surface of the tuberosity is frequently roughened for articulation with the pyramidal process of the palate bone. The tuberosity in the living bone is penetrated by numbers of nutrient vessels. Midway between it and the zygomatic surface are several larger apertures which lead into canals in the substance of the bone; they are the posterior dental canals. One of them passes into the substance of the bone, traverses the outer wall of the maxillary sinus, and joins the anterior dental canal, which branches from the infraorbital posterior to the infraorbital foramen. These canals transmit the posterior dental vessels and nerves.

The Nasal Process is a thick irregular process of bone. Commencing at the anterior superior angle of the facial surface of the bone, it extends upward, inward, and backward, and forms part of the inner boundary of the orbit and external surface of the nasal chambers. Its upper extremity is serrated for articulation with the frontal bone in front and the ethmoid bone behind, thus completing the anterior ethmoidal cells. The anterior border is serrated for articulation with the nasal bones.

The External Surface or Anterior Surface is marked by shallow grooves, which are traces of the development and growth of the bone downward. It is perforated by several foramina for the passage of nutrient vessels to the substance of the bone. This surface gives origin to the elevator muscle of the upper lip and of the wing of the nose (levator labii superioris alæque nasi), the sphincter muscle of the orbit (orbicularis palpebrarum), and the tendon of the eye (tendo oculi).

The Internal Surface of the Nasal Process is, for convenience of description, all that portion of bone included between the superior border and the floor of the anterior nares. This surface is marked by two slightly concave portions of bone and two ridges. The lower ridge articulates with the inferior turbinated bone, while the upper one articulates with the middle turbinated bone.

The Inferior Meatus of the nose is bounded on the outside anteriorly by the concave portion of bone below the inferior ridge. *The Middle Meatus* is partly bounded externally by that concave portion between these ridges. *The Superior Meatus* at its commencement is similarly bounded by that portion of this surface above the superior ridge.

The Malar Process is rough and triangular, and projects outward and upward from the external surface of the body of the bone. It forms a strong abutment immediately above the first molar tooth, and articulates

with the malar bone. It gives origin to a portion of the masseter muscle.

The Palate Process, with its fellow of the opposite side, forms about three-fourths of the hard palate, the same process of the palate bones making up the remaining fourth. This process has two surfaces. The nasal or superior surface is smooth and concave from side to side; the oral or inferior surface is vaulted and roughened to give attachment to the muco-periosteum.[1] It is also marked by numerous small depressions for the lodgment of the mucous glands. Its anterior half is pierced by minute foramina for the passage of nutrient vessels, and the antero-posterior grooves on the posterior half are for the accommodation of the posterior palatine nerves and vessels.

The Anterior Border of this process, where it fuses with the premaxilla (see paragraph on development of superior maxilla, p. 88), is thick and roughened, while its posterior border is thin, serrated, and articulates with the palate bone.

The Mesial Border of this process and that of the premaxilla are thicker before than behind, and is serrated for articulation with its fellow of the opposite side.

The Nasal Spine.—The anterior border of the palate process is smooth and concave; it terminates superiorly in a well-defined spine, which gives attachment to the cartilage which forms the anterior portion of the septum of the nose.

The Incisor Crest is a sharp projection just posterior and continuous with the nasal spine, and between it and the incisor foramen.

The Nasal Crest is an elevation of the median border of this bone, including the same border of the palate bone. These when joined form the nasal crest for articulation with the vomer.

The Incisor Foramen (or foramen of Stenson) is situated immediately behind the incisor crest, and leads downward and forward from the nasal chamber toward the oral cavity, terminating just back of the incisor teeth. As this foramen extends downward, it is soon converted into a groove by the deficiency of its inner wall. In the articulated bones this groove forms the anterior palatine meatus or canal, and opens on the nasal surface of the palatal process through four foramina—the incisive foramina just described, and the foramina of Scarpa or the naso-palatine foramina. The meatus is seen as a single orifice back of the incisor teeth at the point of union of the premaxillary bones with the palatal processes.

Fig. 36.

The Anterior Palatine Fossa. It will be found to contain four openings—two placed laterally, 1, 2, and two in the middle, one (4) before the other (3).

The Foramina of Scarpa, or Naso-palatine Foramina, are situated in the plates of bone that separate the upper part of the incisor foramina, and are anterior and posterior or directly in the mesial line, the posterior opening transmitting the right and the anterior the left naso-palatine nerves.

The Alveolar Process extends forward from the tuberosity, along the inferior margins of the zygomatic and facial surfaces, to the median line

[1] Harrison Allen, *Human Anatomy*.

of the bone, where it articulates with its fellow of the opposite side. It is broader behind than in front, and composed principally of cancellous or spongy tissue. It is curved in outline, corresponding to some extent to the body of the bone above. This curve varies in different bones, the extent of variation depending in great measure on the race and temperament of the individual from which the bone is taken. With its fellow in well-formed mouths its axis is parabolic. It is composed of two plates of bone—an inner and an outer—with numerous septa of cancellous tissue uniting them and forming the alveoli for the accommodation or reception of the roots of the teeth.

The Outer Plate of the alveolar process is continuous with the facial and zygomatic surfaces of the bone. It is the thinner and weaker of the two, which accounts for the fact that a healthy tooth is more easily pressed outward than inward. After a tooth has been extracted the outer plate absorbs much more quickly and to a greater extent than the inner.

The Inner Plate is well defined superiorly, where it forms an angle with the palate process. It is thicker and stronger than the outer plate.

The Outer Surface is marked by eminences corresponding to the roots of the teeth, and depressions marking the position of the interspaces. The eminence over the canine tooth is more prominent than the others. This surface at or near its superior margin, over the second bicuspid and three molar teeth, gives origin to the buccinator muscle.

FIG. 37.

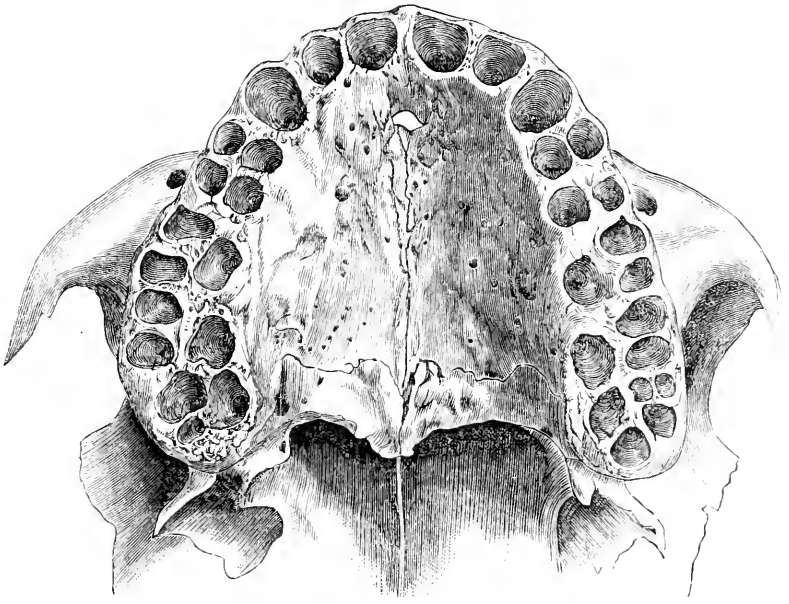

Alveoli of Permanent Teeth.

The Alveoli (Fig. 37) in the normal adult bone are eight in number, and correspond in shape and size with the roots of the teeth which they

accommodate. The socket for the central incisor tooth is nearly conical in shape. That for the lateral incisor is conical, but smaller and more compressed meso-distally than the central socket, and often presents a slight distal curve at its upper extremity. The socket for the cuspid (canine) tooth is conical in form, deeper and larger than those for the incisors, and somewhat compressed, especially at its inner aspect, forming an oval in transverse section. The sockets for the bicuspidati resemble flattened cones, that for the first bicuspid generally bifurcating at the upper portion, as this tooth frequently has two roots. The same reason occasionally causes a bifurcation of the socket for the second bicuspid. The sockets for the molar teeth are broad, and divided at their upper three-fourths into three compartments. The socket for the wisdom tooth is an exception to this formation, frequently not dividing at all, and sometimes having more than three compartments.

The septa between the alveoli extend downward to a lower level than the plates composing the alveolar processes, so that their free margins are convex—a point to be remembered in practical dentistry in fitting permanent bands and metal crowns on roots that are embraced in the alveolar walls.

Each alveolar wall consists of a shell of thin, compact bony structure surrounded by spongy tissue. This shell comes into contact with the dense cortical plates composing the surfaces of the bone, mainly at the margin near the neck of the tooth. At the apical portion of the sockets are small openings for the entrance of vessels and nerves supplying the teeth.

The teeth are held in their sockets by alveolo-dental connective tissue. It is elastic, and allows a considerable motion of the teeth. In the dried bone the loss of this tissue loosens the teeth and permits their detachment from the sockets.

Development.—The development of the superior maxillary bone (Fig. 38) commences so early and increases with such rapidity that it is difficult to mark out its line of growth. It arises in membrane from many points of ossification, at least one each for the orbital plate, the nasal process, and the alveolar border. These appear about the sixth or seventh week of embryonal life, and soon coalesce. Hence these parts are claimed by some to arise from one centre. They form the lateral portion of the bone, which contains all the teeth except the two incisors, and is called by comparative anatomists the true maxilla. That portion of the bone which contains the central and lateral incisor teeth arises from a separate point of ossification, and is known as the premaxilla. In many of the lower animals it remains distinct from the true maxilla throughout life.

When there is union between the two premaxillary bones in the median line, but no lateral union between them and the true maxillæ, they form the intermaxillary bone of the lower animals. In man the premaxilla soon unites with the maxilla proper by a suture, which on the facial surface may be seen until the sixth year, and on the hard palate it generally remains until adult life. The suture on the hard palate extends as far back as the posterior portion of the anterior palatal canal. In single or unilateral complete cleft palate—*i. e.* the cleft extending

from the facial surface to the posterior portion of the palate process—the premaxilla does not unite with the parts containing the other teeth, neither do the true maxillæ and palatal processes of the palate bones unite. In double cleft palate the incisorial divisions may have united in the median line (forming an intermaxillary bone), but not laterally

Fig. 38.

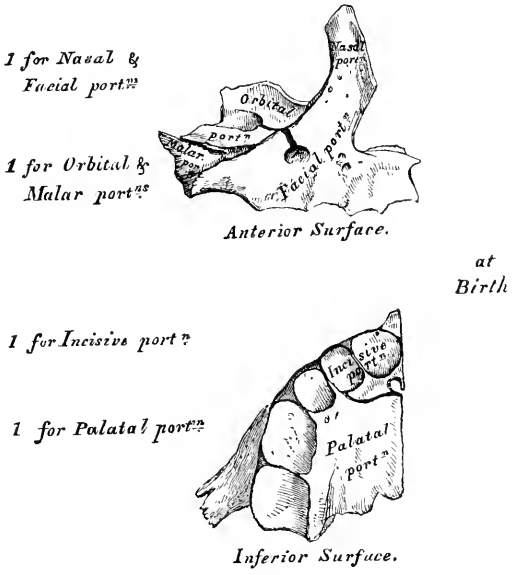

Development of the Superior Maxillary Bone, by four centres.

with the true maxillæ. In some of these cases the vomer can be seen protruding in the median line between the two halves of the hard palate.

The alveolar process is developed as a special support for the teeth. At birth it is represented by the walls of a deep groove, in which the deciduous and the germs of the permanent teeth are situated. As the teeth grow the alveolar process advances, until it encases them. Just prior to the shedding of the deciduous teeth their roots and their bony processes are absorbed, and the latter are re-formed on the appearance of the permanent teeth. This process again commences to disappear on the loss of the second set of teeth, and in time may be wholly removed. In certain diseased conditions of the bones this process disappears to some extent before the permanent teeth are lost; and this bone-absorption may go on until teeth otherwise healthy become loose and drop out.

The Maxillary Sinus (antrum of Highmore) is the large air-cavity situated in the body of the bone. It is irregularly pyramidal in shape, the apex bearing toward the malar bone, into which it may extend, and its base toward the nasal cavity. Its development is similar to the sinuses in the frontal bone, and like them is not completed until after the age of puberty, although it makes its appearance as early as the fifth or sixth month of fœtal life. Hence in early life the surrounding

walls are much thicker than in the adult. Its capacity varies in different subjects and in the opposite bones of the same subject, ranging from one drachm to one ounce fluid measure, the average being about three drachms. It is somewhat larger in the male than in the female.

The floor of the sinus is marked by irregular eminences corresponding to the roots of the molar teeth. Sometimes it is punctured by the roots of these teeth, which may extend into the sinus. The walls of the sinus often support thin plates of bone which subdivide it into small compartments. A knowledge of this fact is of importance in operating on tumors and abscesses in this location, as the drill may simply penetrate one of these distinct compartments, misleading the operator as to the extent of the sinus or of the disease.

The sinus opens into the middle meatus of the nose by an orifice of variable size situated at the base of the pyramid. This orifice is partly closed by the uncinate process of the ethmoid, the vertical plate of the palate, the inferior turbinated, and the lachrymal bones, also by soft tissue, so that in the recent state it is about the size of an ordinary lead-pencil. This small opening is situated near the upper part of the sinus, and does not, when the head is perpendicular, afford a ready outlet to fluids collected within the chamber.

The mucous membrane lining the sinus is ciliated, and is continuous through this quill-like opening with the membrane lining the nasal cavity. It is, however, less vascular than the nasal mucous membrane.

The sinus may be encroached upon by any of the teeth situated in the superior maxilla, but those that most frequently protrude into it are the roots of the first and second molars.

With the exception of the alveolar border the walls of the sinus are quite thin. These walls are four in number—one extending toward the orbit; another toward the nose and roof of the mouth, including a portion of the palatal process; a third toward the facial and zygomatic surfaces of the bone; and a fourth is formed by the alveolar border. Morbid growths within the sinus will more readily cause either of the first three walls to project or bulge than the alveolar process.

The posterior wall, or that toward the zygomatic surface of the bone, is marked by the posterior dental canals, through which the posterior dental vessels and nerves are conducted to the teeth. The anterior wall is in like manner grooved by the anterior dental or incisor vessels and nerves.

Palate Bone.

The palate bones, two in number, are wedged between the superior maxillary bones and the pterygoid plates of the sphenoid bone at the back part of the nasal chambers. They assist in forming the boundaries of the orbital, nasal, and oral cavities, the spheno-maxillary, the spheno-palatine, and the pterygoid fossa, the spheno-maxillary fissure, the posterior ethmoidal cells, and the maxillary sinus.

The palate bone is composed of thin, delicate, and compact tissue. Its general form is that of the letter L. It is composed of two plates, a horizontal and vertical; and three processes, a pyramidal, orbital, and sphenoid.

The Horizontal or Palate Process.—This corresponds to the palate process of the superior maxilla. It is thin, quadrilateral in form, and presents for examination two surfaces and four borders.

The Superior Surface is smooth, concave from side to side, and forms the posterior portion of the floor of the nasal chamber.

The Inferior Surface is smooth, excepting at its posterior portion, where it is marked by a transverse ridge for the attachment of the tensor palati muscle. This surface forms the posterior portion of the hard palate.

The Posterior Palatine (*or Palato-maxillary*) *Canal* is a groove, sometimes a canal, situated at the outer portion of the ridge, for the attachment of the tensor palati muscle. It is converted into a canal by articulation with the superior maxilla. It transmits the posterior palatine vessel and anterior palatine nerves.

The Accessory Posterior Palatine Canal, or Canals, are between this ridge and the pyramidal process.

The Anterior Border is serrated for articulation with the palatal process of the superior maxilla.

The Posterior Border is free, smooth and concave, forming the posterior boundary of the hard palate and floor of the nasal chamber.

FIG. 39.

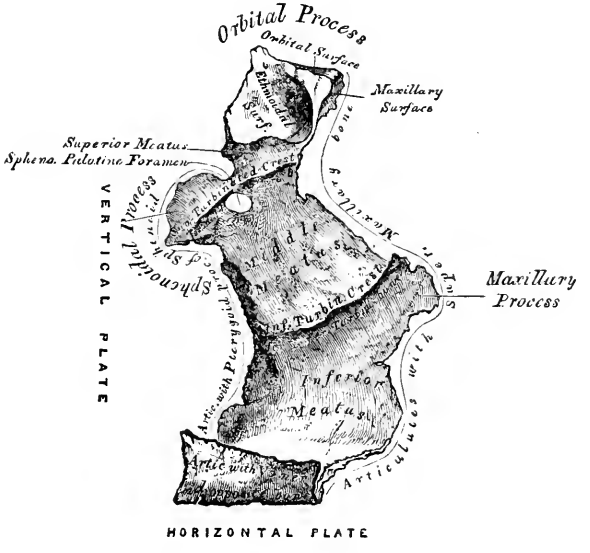

Left Palate Bone, internal view (enlarged).

This border gives origin to the soft palate, and terminates in the median line in a sharp point. This point, when articulated with its fellow of the opposite side, forms the posterior nasal or palatine spine and gives origin to the azygos uvula muscle.

The External Border is situated just below the junction of the horizontal and vertical plates. In it is the groove which assists in forming a portion of the posterior palatine canal.

The Internal Border is much thicker than any of the others. It is serrated and elevated into a ridge, which, when articulated with the corresponding one of the opposite bone, forms a continuation of the nasal crest of the superior maxilla, with which the vomer articulates.

The Vertical Plate is thin, and extends from the floor of the nasal chamber to the upper extremity of the spheno-palatine notch. It has two surfaces, an external and an internal; and four borders, an anterior, posterior, superior, and inferior.

The Internal Surface is similar in structure to the same surface of the superior maxilla. It is divided into three portions by two antero-posterior ridges, the superior and inferior turbinated crests. The inferior crest articulates with the inferior turbinated bone, and thus forms the division between the inferior and middle meati of the nose. The superior crest articulates with the middle turbinated bone (part of the ethmoid), and forms the division between the middle and superior meati of the nose. Between the superior turbinated crest and the superior border of the bone is a groove which forms part of the superior meatus.

The External Surface is generally rough and uneven. Its posterior boundary is marked by a groove (occasionally a canal) which, in the articulated skull, forms the posterior palatine canal, already described.

The Anterior Border is thin, its inferior turbinated crest projecting anteriorly to form the maxillary process. This process assists in closing the maxillary sinus.

The Posterior Border (Fig. 40) is irregular and serrated. Its lower third is marked internally by a deep groove, the edges of which articulate with the internal plate of the pterygoid process of the sphenoid bone, a portion of which fits into the groove. Above the groove this border articulates with the outer edge of the internal pterygoid plate, the thin projecting border overlapping its internal surface.

FIG. 40.

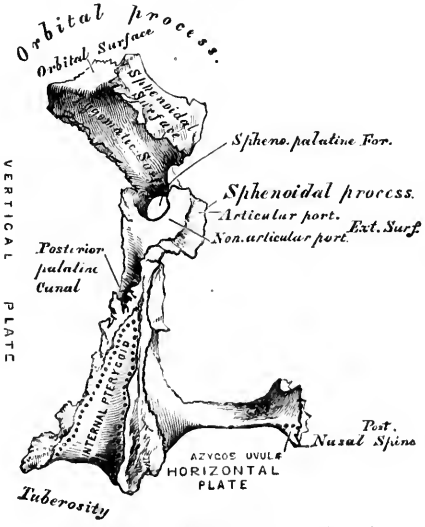

Left Palate Bone, posterior view (enlarged).

The Superior Border is divided by a deep notch, sometimes a foramen, the spheno-palatine notch or foramen, which divides the orbital from the sphenoidal process.

The Spheno-palatine Notch or Foramen is converted into a foramen by articulation with the sphenoid bone. It transmits the spheno-palatine vessels and nerves from the spheno-palatine fossa into the nasal chambers.

The Inferior Border joins the external border of the horizontal plate.

The Pyramidal Process extends downward and backward from the

inferior and posterior borders, and fits into the pterygoid notch between the two pterygoid plates of the sphenoid. Posteriorly, this process has a triangular surface which rounds out the lower portion of the pterygoid fossa. The borders of this process are serrated for articulation with both pterygoid plates of the sphenoid bone.

The Orbital Process extends outwardly from the superior border of the vertical plate, overhanging its outer surface. This process has five surfaces, enclosing a cellular cavity, generally opening through its internal or ethmoidal surface. When it so opens it communicates with the posterior ethmoidal cells. Sometimes, however, this cell-like cavity opens through the posterior or sphenoidal surface and communicates with the sphenoidal sinus, or it may open both ways. Three of these surfaces—the anterior or maxillary, the posterior or sphenoidal, and the internal or ethmoidal—are articulating surfaces, while the remaining two, the superior or orbital and the external or zygomatic, are free.

The Anterior or Maxillary Surface is directed forward, outward, and downward. It is oblong in form and articulates with the posterior superior angle of the inner surface of the superior maxilla.

The Posterior or Sphenoidal Surface is directed backward, upward, and inward, and articulates with the vertical portion of the sphenoidal turbinated bone.

The Internal or Ethmoidal Surface is directed inward, upward, and forward, and articulates with the vertical plate of the ethmoid bone.

The Superior or Orbital Surface is triangular in form, extends upward and outward, and forms the posterior angle of the floor of the orbit.

The External or Zygomatic Surface is smooth and oblong in form, is directed outward, backward, and downward, and forms a portion of the spheno-maxillary fossa.

The Sphenoidal Process curves upward, backward, and inward from the posterior third of the superior border, and presents three surfaces, the superior, external, and internal; and two borders, the anterior and posterior.

The Superior Surface is the smallest of the three, and articulates with the horizontal portion of the sphenoidal turbinated bone. It is marked by a groove which assists in forming the pterygo-palatine canal.

The External Surface is divided into two portions, anterior and posterior. The anterior portion is smooth, and helps to form the spheno-maxillary fossa, while the posterior portion is rough, for articulation with the inner surface of the pterygoid plate of the sphenoid bone.

The Internal Surface is smooth and concave, and forms part of the outer wall of the posterior nares.

The Anterior Border forms the posterior margin of the spheno-palatine notch.

The Posterior Border is serrated, and articulates with the inner surface of the pterygoid process.

DEVELOPMENT.—The palate bone is developed from a single centre of ossification, which is deposited in membrane, and appears at the junction of the vertical with the horizontal plate about the seventh or

eighth week of embryonal life. Before birth the horizontal is longer than the vertical plate.

The Inferior Turbinated Bone.

The inferior turbinated bones (maxillo-turbinal), two in number, are situated at the lower third of each lateral wall of the nasal chamber. Each bone forms the upper boundary of the inferior meatus of the nose and the lower boundary of the middle meatus. It is thin and frail, full of small foramina and minute canals. It is scroll-like in form, curving outward and downward. It presents a body with two surfaces, an internal and an external; two borders, superior and inferior; and two extremities, anterior and posterior.

Fig. 41.

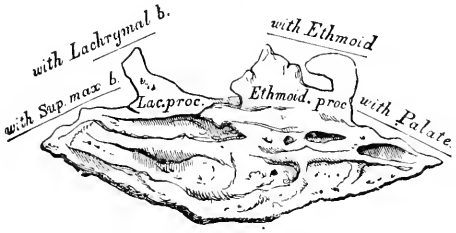

Right Inferior Turbinated Bone, internal surface.

The Internal Surface (Fig. 41) is convex from above downward, and is marked by numerous foramina and longitudinal canals for the passage of blood-vessels and nerves.

The External Surface (Fig. 42) is concave, smoother than the internal, excepting at its lower margin, where it is somewhat cellular in structure and marked by numerous foramina. It forms the roof of the middle meatus of the nose.

Fig. 42.

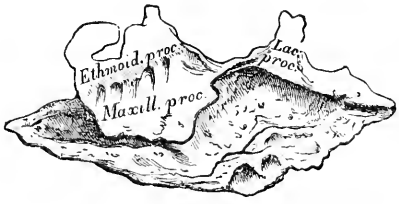

Right Inferior Turbinated Bone, outer surface.

The Superior Border is thin and irregular, and is divided into three portions, anterior, middle, and posterior.

The Anterior Portion articulates with the inferior turbinated crest on the internal surface of the nasal process of the superior maxilla.

The Middle Portion has arising from it three processes—the lachrymal, the ethmoidal, and the maxillary.

The Lachrymal Process runs upward and forward, and articulates with the anterior inferior angle of the lachrymal bone. The outer portion of this process is grooved and assists in forming the lachrymal canal.

The Ethmoidal Process arises just anterior to the posterior third of the superior border. It is broad, and extends upward to articulate with the uncinate process of the ethmoid bone.

The Maxillary Process arises from the base of the ethmoidal process externally, and curves outward and downward, forming a hook-like projection semicircular in shape. This process articulates with the inferior border of the opening to the maxillary sinus.

The Posterior Portion of the superior border articulates with the inferior turbinated crest of the palate bone.

The Inferior Border is thickened, and marked by several indentations of a cell-like character.

The Extremities are narrowed and somewhat pointed, especially the posterior.

Development.—The inferior turbinated bone is developed from cartilage from one point of ossification, which appears about the fifth month of fœtal life.

The Lachrymal Bones.

The lachrymal bones, or os unguis, two in number, are situated at the inner and anterior portion of the orbit, just posterior to the nasal process of the superior maxilla. They pass downward into the nasal chamber.

The lachrymal bone (Fig. 43) is the smallest and most delicate bone of the face. It is quadrilateral in shape, and presents two surfaces, the external or orbital and the internal or nasal; and four borders, anterior, posterior, superior, and inferior.

Fig. 43.

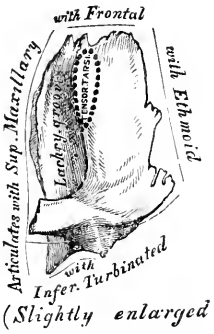

Left Lachrymal Bone, external surface.

The Orbital or External Surface is divided into two portions, an anterior and posterior, by a vertical ridge of bone, the lachrymal crest.

The Anterior Portion of the orbital surface presents a smooth perpendicular groove, the lachrymal groove, the upper part of which lodges the lachrymal sac. In the articulated skull this groove assists in forming the lachrymal canal.

The Posterior Portion of the orbital surface is smooth and concave, and forms part of the inner wall of the orbit. The tensor tarsus muscle arises from the lachrymal crest and part of the orbital surface just posterior to the crest. The hook-like process seen at the lower portion of the lachrymal crest articulates with the lachrymal tubercle of the superior maxilla, and completes the orbital orifice of the lachrymal canal. Occasionally this hook-like process exists as a separate bone known as the lesser lachrymal bone.

The Internal Surface forms part of the outer wall of the nasal chamber. It is marked opposite the lachrymal crest on the external surface by a longitudinal depression. That portion of the bone in front of this depression enters into the formation of the outer surface of the middle meatus of the nose; that behind it articulates with the ethmoid bone, and in conjunction with the superior maxilla closes the anterior ethmoidal cells.

The Anterior Border is the longest of the four, and articulates at the inner margin of the lachrymal groove with the nasal process of the superior maxilla.

The Posterior Border is thin and uneven; it articulates with the anterior border of the os planum of the ethmoid bone.

The Superior Border is the thickest and shortest of the four. It articulates with the internal angular process of the frontal bone.

The Inferior Border is more complicated than any of the others. It is thicker at the termination of the lachrymal crest than elsewhere, which gives strength to the posterior wall of the lachrymal canal. It is divided by the lower extremity of the lachrymal crest into two portions, an anterior and a posterior.

The Anterior Portion, or that portion in front of the extremity of the crest, extends downward, backward, and inward, and terminates in a pointed process which articulates with the lachrymal process of the ethmoid bone. As it extends downward it passes on the outer side of the uncinate process of the ethmoid bone, and to the inner side of the orifice to the maxillary sinus, and thus assists in closing the anterior portion of the opening leading to the sinus. This portion also partly bounds the lachrymal canal, and is supported by the uncinate process of the ethmoid.

The Posterior Portion, or that situated behind the extremity of the crest and below the orbital surface, articulates with the orbital plate of the superior maxilla.

Development.—The lachrymal bone arises from one point of ossification, which is deposited about the eighth week of fœtal life.

The Nasal Bones.

The nasal bones, two in number, are situated at the upper portion of the external nose, and form what is often termed the "bridge" of the nose; also the anterior boundary of the nasal chambers.

The nasal bone is oblong in shape, has the lower extremity wider than the upper, and presents two surfaces, anterior and posterior; with four borders, superior, inferior, lateral, and median.

The Anterior or Outer Surface (Fig. 44) varies in shape, but may be said to be generally convex from side to side and concave from above

Fig. 44.

Right Nasal Bone.

Fig. 45.

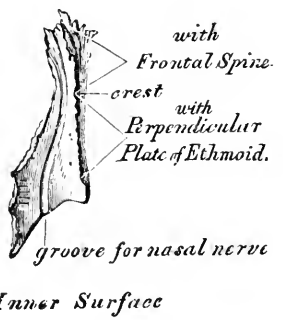

Left Nasal Bone.

downward. The upper portion is punctured by numerous nutrient foramina; the lower portion is smooth and rounded. Near the centre of this surface will be seen a foramen which passes through to the internal aspect of the bone, and transmits a small vein. This foramen

is not constant, and sometimes two foramina are found in this location. Occasionally the foramen cæcum, the commencement of the longitudinal sinus of the brain, opens on this surface.

The Posterior or Internal Surface (Fig. 45) is concave from side to side and convex from above downward. Upon this surface is a longitudinal groove (sometimes a canal) for the transmission of the internal branch of the nasal nerve, which passes out between the bone and the lateral cartilage of the nose.

The Superior Border is triangular in form, and serrated for articulation in the nasal notch of the frontal bone.

The Inferior Border is the broadest part of the bone. It is thin and notched in the centre for the transmission of the anterior branch of the nasal nerve; this border extends downward, outward, and backward, terminating in a sharp point; it gives support to the lateral cartilage of the nose. In the articulated skull the inferior borders of the two nasal bones form a triangular notch called the nasal angle, serving for partial attachment of the lateral nasal cartilage.

The Lateral or External Border is the longest of the four; it is serrated and bevelled at the expense of the anterior surface, and articulates with the nasal process of the superior maxilla.

The Median or Internal Border at its upper portion is thick, gradually becoming thinner and tapering as it descends. When the bone is articulated with its fellow of the opposite side the border produces internally a vertical crest which forms part of the septum of the nose, and articulates with the nasal spine of the frontal, the perpendicular plate of the ethmoid bone, and affords attachment to the nasal cartilaginous septum.

Development.—The nasal bone is developed in membrane from one point of ossification, which appears about the eighth week of embryonal life.

The Malar Bones.

The malar (or cheek) bones are two in number, situated at the lateral angles of the face, and support the most prominent portion of the cheeks; they assist in forming the outer wall, lower border, and floor of the orbit, the anterior portions of the temporal and zygomatic fossæ, and the zygomatic arch. The bone is quadrangular in shape, and presents for examination a body with two surfaces, external and internal; four processes, frontal, orbital, maxillary, and zygomatic; and five borders, superior, inferior, anterior, posterior, and sphenoidal.

The External or Facial Surface (Fig. 46) is convex in form; the upper portion is smooth, and supports the sphincter muscle of the eye, the orbicularis palpebrarum; the lower portion is roughened, and gives origin to the major and minor zygomatic muscles. The upper portion of this surface is pierced by one or two foramina, which pass into the orbit and transmit the terminal ends of the lachrymal blood-vessels and nerves. The foramina or canals in the malar bone vary with different subjects: sometimes they are double, and occasionally they are wanting.

The Internal or Zygomatic Surface (Fig. 47) is directed backward and outward toward the temporal fossa above and the zygomatic fossa below; it is concave in form, and near the outer portion it is punctured by one or two small foramina for the passage of blood-vessels and

Fig. 46.

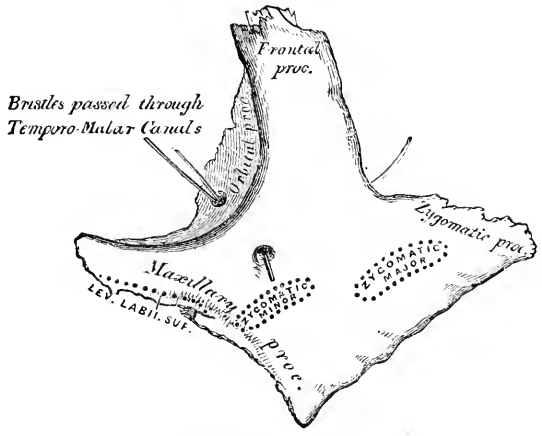

Left Malar Bone, outer surface.

nerves. At the anterior inferior angle of this surface is a rough triangular plate of bone for articulation with the malar process of the superior maxilla. The remainder of the internal surface is smooth, and enters into the formation of the temporal and zygomatic fossæ; the

Fig. 47.

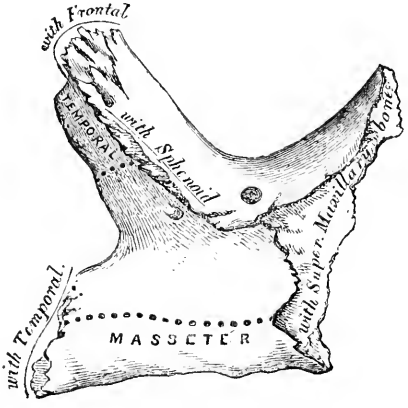

Left Malar Bone, inner surface.

lower third of this surface, extending as far as the lower border of the bone, gives origin to the greater part of the masseter muscle.

The Frontal Process is the most prominent of the four: its upper portion is thick and serrated, and articulates with the external angular process of the frontal bone.

The Orbital Process is situated at the outer wall and floor of the orbit: it is divided into two surfaces, the orbital and the temporal; and two borders, the external and the internal.

The Orbital or Anterior Surface is smooth and concave, generally presenting two grooves, which extend to near its anterior border, and terminate in two foramina or canals for the passage of vessels and nerves—one to the facial surface of the bone, and the other into the temporal fossa. This surface, together with the great wing of the sphenoid bone, forms the external wall and part of the floor of the orbit.

The Temporal or Posterior Surface, in connection with the external angular process of the frontal bone, forms the anterior boundary of the temporal fossa. This surface is smooth and convex: it is pierced by a foramen leading to the orbit.

The Maxillary Process is the strongest and thickest of the four: it extends along the entire anterior border of the bone, forming the articulating portion of the zygomatic surface, and joining the malar process of the superior maxilla.

The Zygomatic Process is situated at the posterior inferior portion of the bone. It is broad and extends backward, its extremity being bevelled at the extension of its lower part. It is rough and serrated, and articulates with the zygomatic process of the temporal bone, completing the zygomatic arch.

The Superior or Orbital Border is smooth and rounded, and presents in outline an inverted arch. It forms a large portion of the outer boundary of the orbit.

The Inferior or Zygomatic Border extends horizontally backward to the zygomatic process, which, together with the lower border of the zygomatic process of the temporal bone, forms the inferior border of the zygomatic arch. This border is roughened for the origin of the masseter muscle.

The Anterior Border is continuous with the articulating surface of the maxillary process. The elevator muscle of the upper lip (levator labii superioris proprius) arises just above the suture marking this articulation, its point of origin extending slightly on to the external surface of the bone.

The Posterior or Temporal Border is thin and curved somewhat like an italic *f*. It faces backward, and is continuous above with the temporal ridge, and below with the superior border of the zygomatic arch. This border completes the circle enclosing the temporal region which gives attachment to the temporal muscle.

The Sphenoidal Border extends downward and inward from the frontal process to the non-articulating notch, when it exists, at the base of the great wing of the sphenoid bone. This notch forms the anterior boundary of the spheno-maxillary fissure. Occasionally the malar bone does not enter into the formation of this fissure. When this happens it is prevented from so doing by the articulation of the great wing of the sphenoid with the superior maxilla, or by a small Wormian bone. This border is serrated, and articulates with the great wing of the sphenoid.

Development.—The malar bone is developed in membrane from two points of ossification, which appear about the eighth week of embryonal life, uniting about the fourth month. Occasionally the two portions of the bone remain separate throughout life. When this is the case the bone is divided into an upper and a lower portion by a horizontal interspace, the upper portion being the larger.

The Inferior Maxillary Bone.

The importance of the inferior maxillary bone, mandible, or lower jaw to the dentist and the surgeon cannot be over-estimated. Its position, composition, and development, its nerve- and blood-supply, combine to render it liable to various and grave diseases. In order that these shall be thoroughly understood and properly treated, a detailed knowledge of its anatomy is absolutely necessary.

The inferior maxilla is symmetrical in form, and is situated below the alveolar border of the superior maxilla, beneath the zygomatic and glenoid fossæ, articulating in the latter cavity. The lower border, extending from side to side, forms the anterior inferior boundary of the face. It assists in forming the lateral portions of the outer boundaries of the zygomatic fossæ. It also forms the greater portion of the superior boundary of the surgical squares of the neck and the digastric triangles.

The inferior maxilla is the largest, heaviest, and strongest bone of the head, and contains one-half the teeth. It presents for examination a

Fig. 48.

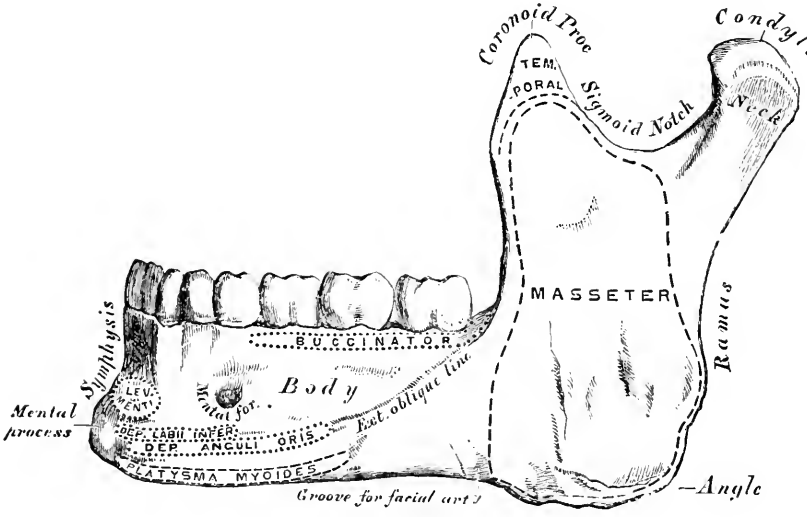

Inferior Maxillary Bone, outer surface, side view.

body, which is horizontal in direction, and two rami, which extend almost perpendicularly upward to the articulation with the temporal bones.

The Body or Horizontal Portion of the bone is parabolic in form, the anterior portion presenting a slight vertical ridge, the symphysis. This symphysis indicates the point of union between the primitive halves of the bone, which unite shortly after birth. The body is divided into two surfaces, external and internal; and two borders, superior and inferior.

The External or Facial Surface (Fig. 48). The vertical ridge in the median line of the external surface extends outward and forward about halfway between the upper and lower borders of the bone. It divides to the right and left and forms a triangular process, the mental process or chin, a feature exclusively human.

The Incisor Fossa.—Above the mental process and below the incisor teeth is a shallow depression, the incisor fossa. This fossa gives origin to the elevator muscle of the lower lip (levator labii inferioris). At the side, a little below the incisor fossa, beneath the cuspid (canine) tooth, is a depression for the origin of the depressor muscle of the lower lip (depressor labii inferioris).

The Mental or Anterior Dental Foramen is not constant in its position. When the teeth are imbedded in the bone it is generally placed midway between the superior and lower borders of the bone, below the root of the second bicuspid tooth, though it may appear as far back as the first molar or as far forward as the first bicuspid. This foramen transmits the mental branches of the inferior dental nerve and vessels.

The External Oblique Line commences at the lateral portion of the mental process, passes backward beneath the mental foramen, and extends slightly upward and backward to the anterior margin of the ramus of the jaw. That portion of this line below the mental foramen gives origin to the depressor muscle of the angle of the mouth (depressor anguli oris). Between the line of origin of this muscle and the inferior border of the bone is a roughened surface for the attachment of the platysma myoides muscle. This roughened surface divides the body of the bone into two portions, a superior alveolar or mucous portion, and an inferior basilar or non-mucous portion.

The Superior Alveolar or Mucous Portion is situated within the vestibule of the mouth, and is covered by mucous membrane and mucoperiosteum. It gives origin to the buccinator muscle just below the three molar teeth.

The Inferior Basilar or Non-Mucous Portion is outside and below the vestibule of the mouth, and is covered with periosteum similar to other bones.

The Internal Surface (Fig. 49) in the median line is marked by a slight vertical depression corresponding to the symphysis externally.

The Mylo-hyoid or Internal Oblique Ridge commences at the base of the coronoid process and extends downward and forward to a point just below the genial tubercles, where it joins the ridge of the opposite side. This ridge is but faintly marked as it reaches the median line of the bone; it divides the internal surface into two portions, a superior and inferior, and gives origin throughout its whole extent to the mylo-hyoideus muscle. This muscle forms the floor of the mouth. Between the posterior portion of this ridge and the wisdom tooth the

buccinator muscle of the cheek and the superior constrictor muscle of the pharynx have slight attachments.

The Superior Portion is situated within the mouth, and is covered by mucous membrane and muco-periosteum.

The Inferior Portion is all that surface of bone below the mylo-hyoid ridge. It is situated below the floor of the mouth, and is covered by periosteum.

The Genial Tubercles are situated at the lower portion of the median line of the bone. They are four in number, two on each side. Occasionally, these tubercles are indistinct, and sometimes they unite and form one tubercle. The superior pair afford origin to the genio-hyo-glossi muscles, the lower pair to the genio-hyoidei muscles.

The Sublingual Fossa is an oval depression, posterior to the genial tubercle, below the cuspid teeth and above the mylo-hyoid ridge. This

FIG. 49.

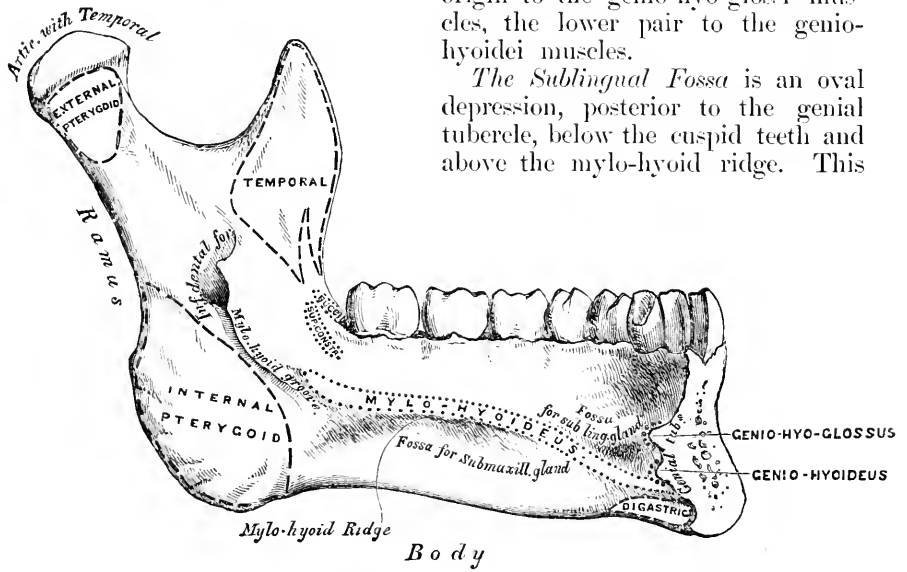

Inferior Maxillary Bone, inner surface, side view.

fossa supports the anterior border of the sublingual gland. It is wider behind than in front.

The Digastric Fossa is a depression for the insertion of the digastric muscle. It is situated at the anterior portion of the internal surface of the bone, near the symphysis and the lower border of the inferior maxilla.

The Submaxillary Fossa is an oblong depression, wider behind than in front, situated near the centre of the internal surface and between the mylo-hyoid ridge and the lower border of the bone. In it rests the external surface of the submaxillary muco-salivary gland.

The Mylo-hyoid Groove is situated beneath the mylo-hyoid ridge, commencing at the posterior (inferior) dental canal. This groove accommodates the mylo-hyoid nerve, artery, and vein as they pass to the floor of the mouth.

The Superior Border of the bone extends from the ramus of one side to the same point on the other. It is situated on that portion of the bone analogous to the alveolar process of the superior maxilla.

It is broader behind than in front, and is marked by sixteen pits of various shapes for the accommodation of the teeth. The pits for the central incisors are the smallest, conical in shape, and compressed laterally. Those for the lateral incisors are somewhat larger and not quite so compressed. The cavities for the cuspids (canine or stomach) teeth are situated at the angles of this border, are larger and deeper than those for the incisors, but less compressed in proportion to their size. The six anterior sockets just described are arranged in the form of an arc, while those for the remainder of the teeth extend in almost a straight line posteriorly, the straightness of the line varying with the temperament of the individual. The sockets for the bicuspid teeth are variably compressed and occasionally bifurcated, though it is exceptional to find a double-rooted inferior bicuspid. The sockets for the molar teeth are round superiorly, but as they descend soon bifurcate into two flattened cone-shaped depressions. Those for the third molar or wisdom tooth, however, vary from this rule just as their roots vary.

The Alveolar Process is very similar to that of the superior maxilla before described, the principal point of difference being in the external plate. The external plate of the superior maxilla is thin throughout the entire surface—so much so that the roots of the teeth are often bared in macerating the bone. In the inferior maxilla the external plate is thick and compact, thus rendering the lower teeth more difficult of extraction than those in the upper jaw. After extraction the external plate of the superior maxilla is absorbed much more rapidly and to a greater extent than the internal plate, while with the external and internal plates of the inferior maxilla the rate of absorption is more uniform.

The Inferior Border of the bone extends from a depression at the union of the ramus with the body of the bone to the same point upon the opposite side. It is thick, strong, rounding, and composed of compact tissue. The depression or groove at the union of the ramus at the base of the bone is sometimes called "the facial notch." It is at this point that the facial artery passes from the neck to the face—an important fact to remember when the parts are wounded or in surgical operations on the face, for hemorrhage can generally be controlled by pressure at this point.

The Rami or Ascending Portions of the inferior maxilla are quadrilateral in shape and divided into two surfaces, external and internal; four borders, superior, inferior, anterior, and posterior; and two processes, the condyloid and coronoid.

The External Surface is nearly flat. It is slightly roughened near its posterior inferior angle for the insertion of the masseter muscle.

The Internal Surface.—The central portion is marked by an oblique opening, the posterior or inferior dental foramen. Running downward and forward from the lower border of this foramen is a groove, the mylo-hyoid, already described. Posterior to this groove, extending to the angle of the bone, is a roughened surface for the insertion of the internal pterygoid muscle.

The Posterior or Inferior Dental Foramen is oval in shape; a sharp border of bone extends along its anterior margin, and terminates above in a spine for the insertion of the internal lateral ligament of the lower jaw.

The Dental Canal extends through the body of the bone from the posterior (inferior) dental foramen to the anterior (mental) foramen. Its course is at first downward and forward, until it reaches the body of the bone, through which it runs in a horizontal direction, finally passing forward and opening through the mental foramen on the outer surface of the bone. It lies beneath the alveolar process, and communicates with the teeth and bony tissue through small canals. Opposite the mental foramen in the substance of the bone there are small canals passing forward to the cuspid and incisor teeth and the symphysis of the chin. The posterior (inferior) dental canal and its branches transmit the inferior dental nerve, artery, and vein.

The Superior Border of the Ramus.—Arising from this anteriorly is an elevated process of bone, the coronoid process. From its posterior portion there arises a rounded eminence of bone, the condyloid process, which is continuous with the posterior border of the ramus.

The Coronoid Process is flat and pointed, being thinner at the apex than at the base. The anterior border is a continuation of the external oblique line. This border bends slightly outward as it ascends, and terminates in the apex of the process. Extending downward and forward from the apex of this process on its internal surface is a curved ridge of bone which joins the internal oblique line just posterior to the wisdom tooth. Between the anterior border and this rounded ridge of bone, posterior to the third molar tooth, is a wide groove for the insertion of a part of the temporal muscle above and the buccinator muscle below. The posterior border of this process is thin, and forms the anterior margin of the sigmoid notch. The outer surface of this process is smooth, and affords attachment to a portion of the temporal and masseter muscles. The inner surface is rough, and gives attachment to the temporal muscle superiorly.

The Condyloid Process is shorter, thicker, and more massive than the coronoid. It is continuous with the posterior or free border of the ramus. As this border extends upward it widens, until it forms an articulating surface convex in outline. The superior surface of the condyloid process articulates with the anterior portion of the glenoid fossa of the temporal bone. This surface is separated from the glenoid fossa by interarticular fibro-cartilage.

The Neck is that constricted portion of bone immediately below the articulating surface. Just internal to the posterior portion of the superior border of the ramus it presents a depression, the pterygoid fossa, for the insertion of the greater part of the external pterygoid muscle. At the junction of the neck with the articulating surface of the bone externally is a tubercle for the insertion of the external lateral ligament. Between the coronoid and condyloid processes is situated the sigmoid notch. The border of this notch is thin and crossed by the masseteric artery and nerve on their way to the masseter muscle.

The Inferior Border of the ramus is continuous with that of the body of the bone. The point of junction between the inferior and posterior borders is the angle. This angle extends outwardly, and is grooved and roughened for the insertion of part of the superficial portion of the masseter muscle.

The Anterior Border.—(For description see Coronoid Process.)

The Posterior Border at its upper portion is smooth and rounding. As it approaches the angle of the bone it is roughened for the insertion of the stylo-maxillary ligament.

DEVELOPMENT.—The inferior maxilla is the second bone developed, the clavicle being the first; it is developed from the first pair of what are known as the visceral or branchial folds or arches of the embryo, called the mandibular plates. These plates from the twenty-fifth to the twenty-eighth day of embryonal life advance from the sides of the base of the cranium and meet in the median line. Soon after this union the cartilage of Meckel appears in the deeper portion of the mandibular plate. In mammals the proximal end of this cartilage forms the malleus (one of the small bones of the middle ear), and its distal portion advances along the mandibular plate until it meets its fellow of the opposite side at the symphysis menti.

Meckel's cartilage (Fig. 50) forms in great measure what may be termed a temporary framework for the support of the lower jaw. It disappears at the latter part of the fifth or beginning of the sixth month of fœtal life, and ossification proceeds.

FIG. 50.

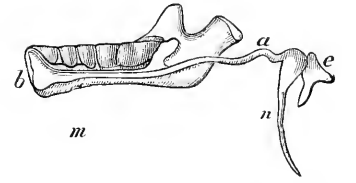

Internal Face of the Right Maxilla of a Human Embryo of about Three Months, showing the natural size and the relative position of Meckel's cartilage.

About the fortieth day of embryonic life ossification commences from several centres deposited on the outside, about midway between the proximal and the distal extremities, in the membrane which partially surrounds the cartilage of Meckel. These centres speedily unite. Ossification then proceeds in both directions along the outer, under, and inner surface of the cartilage, but does not unite with it. About the sixtieth day a miniature jaw is formed, a small portion of the body at the symphysis resulting from direct ossification of Meckel's cartilage. The condyles and a portion of the rami are also ossified from other cartilage. From the centre of the rami internally Meckel's cartilage is prolonged backward to the glenoid fissure, and thence to the middle ear. That portion which passes between the temporal bone and the inferior maxilla becomes surrounded by fibrous tissue and forms the internal lateral ligament of the jaw.

FIG. 51.

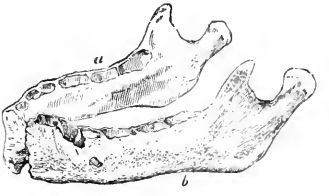

The Inferior Maxilla of a Fœtus at about the Full Period of Intra-uterine Life. The two sides (*a*, *b*) are separate.

At birth osseous union between the lateral halves of the bone has not taken place, they being connected by fibro-cartilaginous tissue. They unite, however, during the first year, ossification commencing below and extending upward, a trace only remaining at the upper portion at the beginning of the second year. The body of the bone is shell-like, open at the top, and contains the germs of the teeth. The coronoid processes are large proportionately to the remainder of the

Fig. 52.

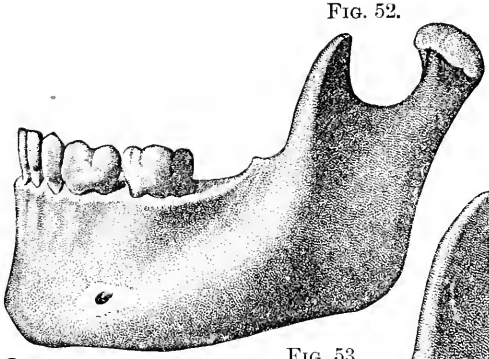

Fig. 53.

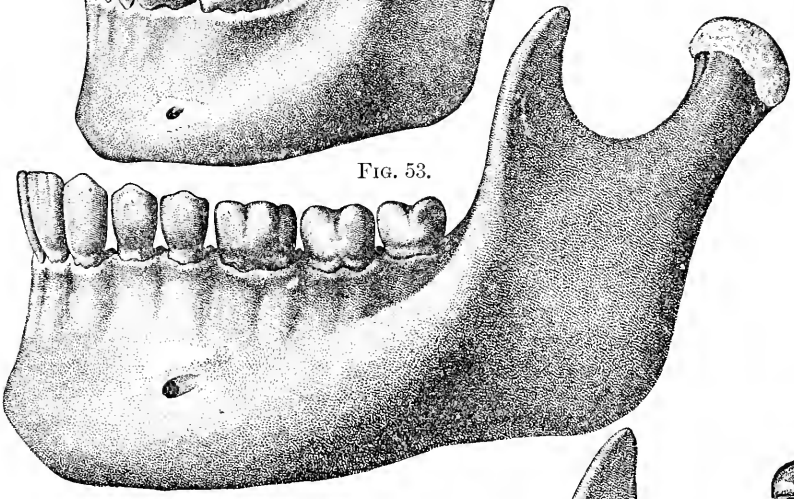

Fig. 54.

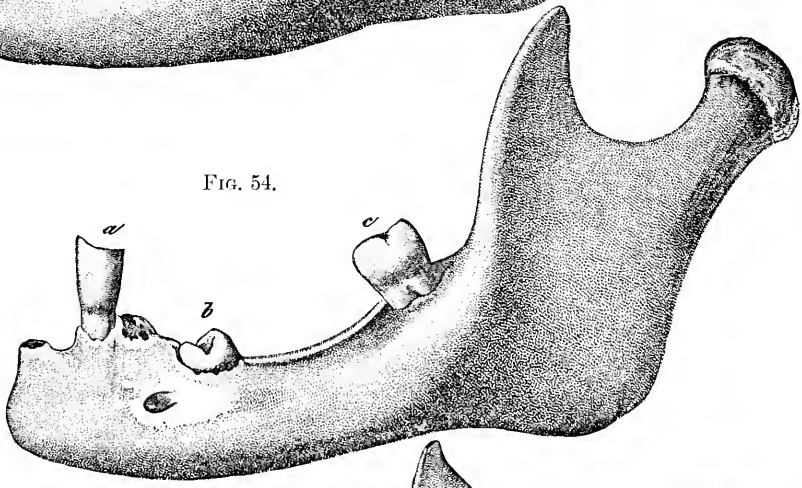

Fig. 55.

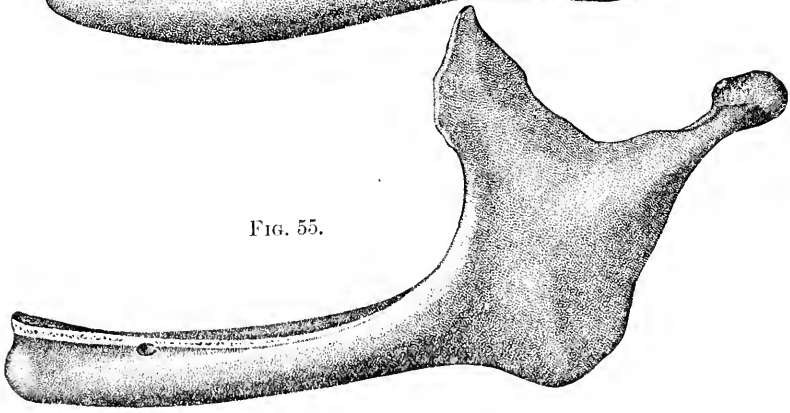

Fig. 52. Appearance of Lower Jaw with Deciduous Teeth.
" 53. Lower Jaw with Permanent Teeth in position.
" 54. Partial Absorption of Alveolar Process.
" 55. Complete Absorption of Process.

bone, the condyloid processes being short and inclined slightly backward. The rami are short, and but slightly deflected upward from the axis of the body of the bone.

After birth the body of the bone becomes elongated (Fig. 52), increasing backward behind the anterior (mental) foramen to a greater extent than it does in front of it. This difference is to give greater space for the accommodation of the permanent molar teeth.

The growth of the body of the bone above the oblique line is made up principally of its alveolar process, which sustains the teeth. The growth below the oblique line, both in extent and thickness, gives strength to the bone and space for the attachment of muscles, lodgment of glands, etc. The rami and condyles of the bone increase in length, and the angles between the rami and the body of the bone become less obtuse; finally, they are almost at right angles with the body (Fig. 53), the difference in direction being due to the gradual separation of the jaws by the growth of the teeth. As the teeth wear away, the jaws approach each other more closely again, and the angles between the rami and the body of the bone begin to reassume their

FIG. 56.

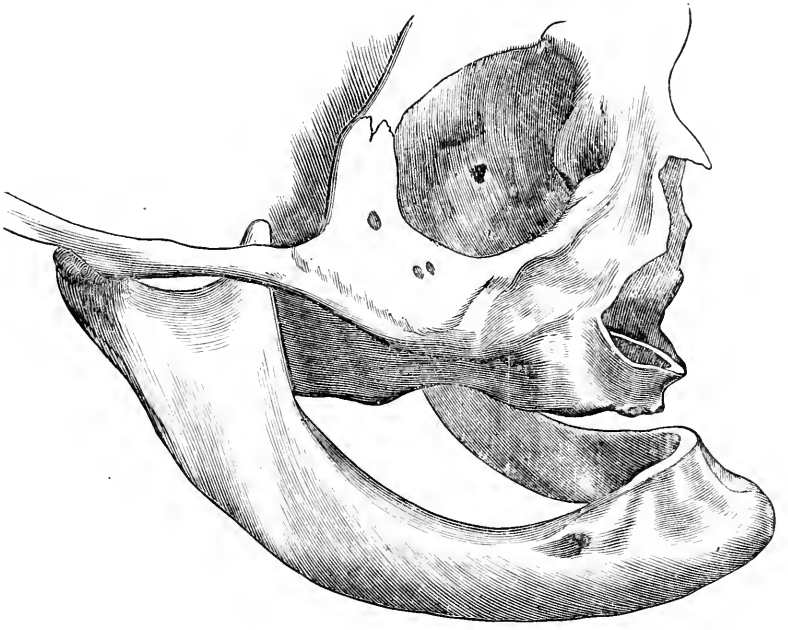

Engraving showing Absorption of Alveolar Process in upper and lower jaw after loss of all the teeth.

former shape (Fig. 54). When the teeth are lost by decay or otherwise, the alveolar process is absorbed (Fig. 55), the depth of the bone thereby diminishes, the mental foramen being nearly on a level with the superior border of the bone, the dental canal becoming superficial. The buccinator, levator labii inferioris, and the genio-glossus muscles are

attached just below the superior border of the bone, sometimes extending well up on this border—a fact which, in such jaws, interferes in a measure with the wearing of artificial teeth. The endeavor to bring the jaws together after the teeth and alveolar process are lost causes the angle between the ramus and body of the bone to assume almost the same obtuse form as at birth (Fig. 56). The employment of artificial teeth immediately after the loss of the natural ones delays to a certain extent this change of form.

The Hyoid Bone.

The hyoid bone (Fig. 57), or os linguæ, is symmetrical in outline. It

Fig. 57.

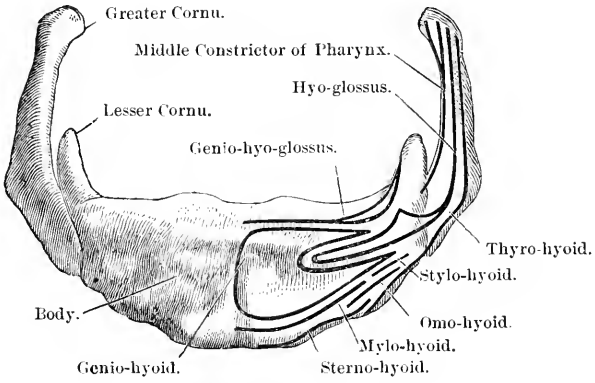

Hyoid Bone, anterior surface (enlarged).

is situated in the median line of the upper part of the neck, at the base of the tongue, and above the larynx. It is so superficially placed that ordinarily the outlines of the bone can be traced beneath the skin below the chin. It is a floating bone, having no osseous articulation. In form it is U-shaped, the convexity of the U being directed forward and its concavity backward. It is divided into a body and four processes called horns or cornua, two on each side.

The Body or Central Portion (basihyal) of the bone is quadrilateral in form. It is compressed from before backward, the anterior surface being convex and marked in the median line by a vertical ridge. On each side of this ridge are eminences and depressions for the attachment of the genio-hyoid muscles. Below these the two mylo-hyoid, the two stylo-hyoid, and the aponeuroses of the digastric muscles are inserted. Between the surfaces for the attachment of these muscles are inserted portions of the two hyo-glossus muscles.

The Posterior Surface is smooth and deeply concave. It is directed backward and downward toward the epiglottis. The space between this surface and the epiglottis is filled by loose areolar tissue.

The Superior Border is thin, rounding, and continuous with the inner margin of the great cornua. It gives attachment to the thyro-hyoid membrane.

The Inferior Border is thicker than the superior, and gives attachment to the sterno-hyoid muscles anteriorly and the thyro-hyoid muscles posteriorly. The omo-hyoid muscles are attached at the junction of the body with the great cornua.

The Great Cornua (thyrohyals) project backward from the body of the bone on each side. They are compressed from above downward, the ends being rounded for the attachment of the thyro-hyoid ligaments. Their outer surfaces give attachment to the hyo-glossus muscles. The superior borders of these horns give attachment to the superior constrictor of the pharynx, while on their inferior borders are inserted the thyro-hyoid muscles.

The Lesser Cornua (ceratohyals) are short and conical; they accompany the great cornua, and project upward and backward from the body of the bone. Their extremities give attachment to the stylo-hyoid ligaments.

Development.—The hyoid bone is developed from the second pair of visceral arches, and ossified from five centres of deposit—one for the body and one for each of the cornua. The first centres for the body and the great cornua are deposited during the last period of fœtal life, those for the lesser cornua not appearing until the first year. Ossific unions between the greater cornua and the body of the bone take place during middle life, while unions between the lesser cornua and the body do not take place until advanced age. Occasionally the stylo-hyoid ligaments are partially ossified.

The Skull as a Whole.

The study of the skull as a whole includes a consideration of all the bones of the head and face articulated, described under three heads:

I. General Development; II. Articulation; III. Regional Anatomy.

GENERAL DEVELOPMENT.

The entire bony structure of the head is developed from the mesoblastic layer of the embryo. The axis around which the first parts of the fœtus are formed is called the notochord or chorda dorsalis. The anterior or superior portion of this chord extends forward into the mass of tissue which forms the principal matrix of the future bony walls of the base of the brain-case, and terminates at the posterior border of the pituitary fossa, its extreme anterior portion forming the dorsum sellæ of the sphenoid bone.

From the anterior portion of the dorsum sellæ, in close proximity to the posterior clinoid processes, two cartilaginous rudiments (known as the trabeculæ cranii of Rŏthke) are thrown out and pass forward, uniting in front of the olfactory depressions. As these rudiments pass forward they unite and separate from each other at intervals, enclosing small interspaces between them. The nasal cartilage is developed directly from these trabeculæ at or near their union in front of the olfactory fossæ.

This axis, or line of origin, at the base of the brain-case is divided into two portions, anterior and posterior.

The Anterior Portion, or spheno-ethmoid portion, forms in front of the notochord, along the trabeculæ cranii, and includes the matrix of the presphenoid and the septal-ethmoid cartilage. It extends forward to the anterior portion of the nasal cartilage and the aperture for the external nose.

Behind the nasal cartilage the trabeculæ cranii unite to form the ethmo-vomerine cartilage, which forms part of the nasal septum. Laterally, the presphenoid cartilage, the matrix of the orbito-sphenoid, the lesser wings of the sphenoid bone, and the optic foramen are developed.

The Posterior Portion, or occipito-sphenoid portion, is formed from that part of the notochord situated behind the pituitary fossa, and, in conjunction with the surrounding tissue, contains the matrix of the basi-sphenoidal cartilages. This portion also extends laterally, and forms the matrix of the exoccipital and periotic mass of cartilage which surrounds the primary auditory vesicles.

The greater part of the occipito-sphenoid portion prolongs forward, and extends below the posterior and middle primary encephalic vesicles, and the matrix for the great wing of the sphenoid process derived from the basi-sphenoid.

It will thus be seen that the base of the brain-case, extending to the most anterior portion of the cartilage of the nose, is a foundation of cartilaginous tissue, and all the bones—speaking of them as they are divided by the comparative anatomist—arising immediately from this foundation to form the base of the brain-case are cartilaginous bones. The remainder of the bones of the brain-case, or those formed on each side of the chorda dorsalis and trabeculæ cranii, such as the interparietals and squamo-zygomatics, are developed in membrane. These membranous bones are claimed by Kölliker to be of dermal origin and to belong to the group of investing bones.

The facial bones, except the inferior turbinated, are developed in membrane, similarly to the tabular bones of the head; and as the membranous bones of the cranial vault articulate with the cartilaginous bones which form the base of the brain-case, so all the membranous bones of the face articulate from below with this same cartilaginous foundation. The inferior maxilla would seem to be an exception to this membro-cartilaginous articulation; but in the early stages of its development it is connected, through the cartilage of Meckel, with the periotic bones.

The Face.—The bones of the brain-case, formed from the notochord and trabeculæ, are in an advanced state of development before the facial bones commence to be built. To such an extent is this the fact that the dermoid structure (the skin) lies almost in contact with all that portion of the head below and anterior to the notochord, and there is at this time no opening to the upper portion of the alimentary canal.

The facial bones arise from the under surface of the base of the brain-case from certain processes, and push outward and downward, leaving a layer of dermoid tissue on their inner as well as their outer surfaces. This dermoid tissue becomes the mucous or epidermoid (epiblastic) lining of the mouth, nasal cavities, and all the internal sur-

faces of the face, excepting the tympanum and Eustachian tubes. These tubes are lined with hypoblastic tissue similar to that which lines the alimentary canal.[1]

The processes in front which push downward and forward are called the fronto-nasal; those on the side, the maxillary and mandibular. Those which are situated deeply within the face are known as the spheno-ethmo prolongations of the trabeculæ cranii.

The changes that occur during the formative process are complex: they produce the external nose, the lips, and the cheeks; the mouth, including the upper and lower jaws, the hard and soft palate; the nasal chambers; the orbits; the labyrinths; the external auditory meatus and tympano-Eustachian tubes; the different air-sinuses, such as the ethmoidal, spheno-maxillary, and frontal cells. This explains how it is that all the facial bones proper, excepting the malar, are lined by mucous membrane. (The special development of each bone is described under the head General Anatomy.)

ARTICULATIONS.

When two or more bones are united together, this union is called a joint or articulation. There are three varieties of articulation in the head—viz. sutura, synchondroses, and diarthroses.

THE SUTURA are those articulations which exist between the intermembranous bones and also between the intermembranous and intercartilaginous bones of the head. This articulation permits of but slight or no appreciable movement. The bones forming this variety of articulation are separated from each other by a thin layer of membrane, that on the outer surface of the joint being derived from the pericranium, and that on the inside from the dura mater.

There are four kinds of sutures—viz. harmonic, squamosa, dentata, and serrata.

The Harmonic sutures are those that have comparatively smooth articulating surfaces or borders. Examples, the articulation between the palate process of the superior maxilla and the palate bones, also the internal surfaces of the articulations of the cranial vault.

The Squamosa (*squama*, a scale) are those in which the opposing surfaces of bone are bevelled, overlapping each other like the scales of a fish. Examples, the temporo-parietal and the temporo-sphenoidal articulations.

The Dentata (*dens*, a tooth) are those in which the articulating borders of the bones are severally armed with numerous tooth-like projections fitting into corresponding indentations. Example, the suture between the two parietal bones.

The Serrata (*serra*, a saw) are those in which the articulating borders of the bones are marked like the teeth of a saw. Example, the suture between the two halves of the frontal bone.

The dentation and serration of the borders of the bones of the brain-case are not marked internally, the under surface of the dome of the skull being smooth. On the internal surface, therefore, these sutures

[1] Quain's *Anatomy*.

would be called harmonic, no matter under what head they might be classed externally.

The Synchondroses are almost immovable articulations. A thin layer of cartilage intervenes between the intercartilaginous bones which go to form this articulation, uniting them together. It is found between the epiphyses and shafts of long bones. Examples, the occipito-sphenoidal articulation and the articulations of the hyoid bone at the cornua.

The Diarthroses.—The greater number of the joints of the body are of this variety. These articulations have extensive movement, such as is seen in the elbow, knee, shoulder, hip, and temporo-maxillary joints. The articulating surfaces of these bones are either convex or concave, and covered by a thin layer of cartilage, forming a smooth articulating extremity. Synovial cavities also exist between the extremities of the bones forming these joints, which are further lubricated by a synovial fluid secreted by a delicate membrane lining all the internal portions of the joints excepting the cartilaginous, though it invests the borders of the cartilages interposed between the joints and assists in holding the bones in apposition. In some joints interarticular discs of fibro-cartilage are placed between the articulating surfaces of bones composing them, these discs dividing the space into two compartments of dissimilar size. An example of this is seen in the temporo-maxillary articulation.

Articulating surfaces are also often marked by irregular facets, so that when the bones are at different degrees of flexion and extension in the joint-cavity there is a special articulating point for that particular position. The opposing surfaces of bones forming these joints are held in apposition by fibrous tissue of various shapes as well as by synovial membrane. This fibrous tissue receives its name according to its relation with the joint. For example, the crucial ligaments of the knee receive their name because they cross each other (obliquely), while the capsular ligaments of joints are so named because they surround the joints.

The diarthrodial articulation is variously subdivided. Gray speaks of four divisions—viz. Arthrodia, Enarthrodia, Ginglymus, and Diarthrodia Rotatoria; while Allen recognizes five divisions—the Arthrodial, Spherical, Cylindrical, Conical, and Composite. Here it will be necessary only to describe the combination of these subdivisions which covers the movements of the temporo-maxillary joint.

The Temporo-maxillary Articulations are formed by the union of the condyloid processes of the inferior maxilla with the anterior portions of the glenoid fossæ of the temporal bones, the glenoid fissures being immediately behind the condyles, while the eminentiæ articulariæ are in front.

Gray describes the arthrodial as "that form of joint which admits of a gliding movement, ... the amount of motion between them being limited by the ligaments or osseous processes surrounding the articulation, as in the articular processes of the vertebræ, the temporo-maxillary, sterno-clavicular, and acromio-clavicular," etc. etc.

Allen describes the ginglymus or hinge-joint, which is a subdivision of the cylindrical division of diarthrotic joints, as the "best expression

of a cylindroid joint. The axis of rotation is perpendicular to the axis of the moving bone, or, as in the case of the elbow, the axis of two bones, the radius and ulna, since both of these describe curvations around the axis of rotation. The paths of movement of the hinge-joint are free within certain limits. These degrees of freedom are of necessity fixed by the direction of the greatest convexity. The co-operation of the surfaces is exact."

In man the temporo-maxillary articulation presents a combination of these movements. In the Carnivora, however, this joint has no gliding movement, as the condyle is a half cylinder working in a deep glenoid fossa of corresponding form, which only allows an up-and-down or hinge movement. In ruminants the condyles of the inferior maxillæ are only slightly convex, and the glenoid fossæ of the temporal bones but slightly concave. This arrangement allows great latitude of motion, and the joint is a combination of the arthrodial and of the hinge, as it likewise is in man.

The gliding movement of this joint in man, characteristic of the arthrodial articulation, has an important bearing in the adjustment of artificial teeth. If the condyles of the inferior maxilla are carried well up into the glenoid fossæ when the mouth is closed, the jaws or their teeth will be in proper apposition to each other.

The structures connected with the temporo-maxillary articulation are generally described as five ligaments and two synovial sacs. The liga-

Fig. 58.

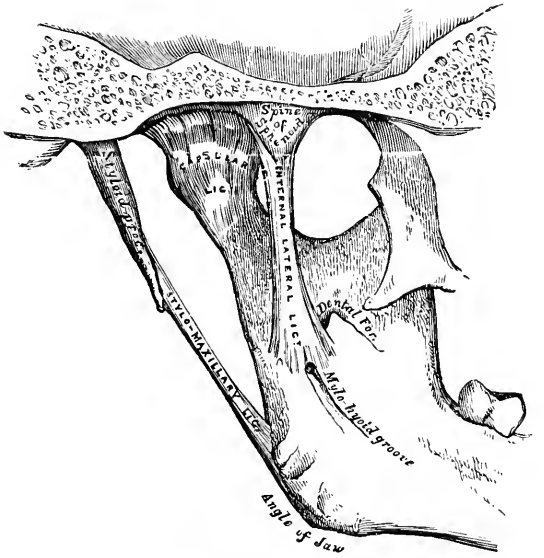

Temporo-maxillary Articulation, internal view.

ments are the capsular, external and internal lateral, stylo-maxillary, and an interarticular fibro-cartilage. The capsular and external lateral will be described as one ligament, while the internal lateral and stylo-

maxillary, not being in direct connection with the joint, will be described as accessory ligaments to the articulation (Fig. 58).

The Capsular Ligaments of the temporo-maxillary articulation is an exceedingly loose fibrous bag. It is thin in front and on the inner side, being thick and strong behind and on the outer side. It is attached above to the articulating circumference of the glenoid fossa, and below it encircles the neck of the condyle of the inferior maxilla. The most superficial fibres of this ligament extend downward and backward from the outer surface and tubercle at the anterior root of the zygoma to the outer surface and posterior border of the neck of the inferior maxilla. This portion is generally spoken of as the external lateral ligament of the articulation.

The structures found within this joint (Fig. 59) are the interarticular disc of cartilage and the synovial sacs.

Fig. 59.

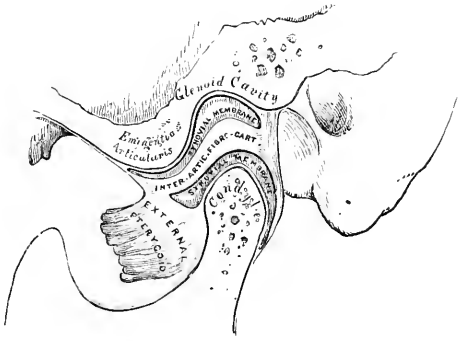

Vertical Section of Temporo-maxillary Articulation.

The Interarticular Disc of Fibro-cartilage is a thin plate of cartilaginous tissue situated between the articulating bones. It is elliptical in form, its broadest diameter being transverse. Its lower surface is concave for the accommodation of the condyle of the jaw, its upper surface being concave in front, where it passes under the articular eminence, and thick and convex behind, where it adapts itself to the deeper portion of the glenoid fossa. Its circumference affords attachment to the common capsular ligament, while its anterior portion gives insertion to part of the tendon of the external pterygoid muscle. Its surfaces are smooth and divide the articulating cavity into two unequal pockets. Sometimes an opening will be found in the centre of this cartilage which allows communication between the chambers. When this is the case the synovial sacs are continuous with each other.

The Synovial Sacs are two pouches which secrete the fluid for lubricating the joint. They are situated one above the other below the interarticular disc of cartilage.

The Superior Synovial Sac is the larger and freer of the two. It begins at the margin of the disc, and passes over the eminentia articularis, the roof of the glenoid fossa, and the upper surface of the cartilage.

The Inferior Synovial Sac is situated between the cartilage and the condyle. It extends on the condyle posteriorly to a greater extent than it does anteriorly.

The Internal Lateral Ligament is not directly connected with the temporo-maxillary articulation, but acts as an accessory ligament to the joint. It is a fascia-like band extending from the spinous process of the sphenoid bone; becoming broader as it descends, it is inserted into a triangular process of bone on the anterior border of the posterior dental foramen. The external pterygoid muscle crosses the superior portion of this ligament externally, the internal maxillary artery and the inferior dental vessels and nerve passing lower down between the ligament and the bone.

The Stylo-maxillary Ligament is the other accessory ligament of the temporo-maxillary articulation. It is a strong fibrous band connected with the deep cervical fascia, extending from a point in close proximity to the apex of the styloid process of the temporal bone to the inferior portion of the posterior border of the ramus of the jaw, where it is inserted between the masseter muscle externally and the internal pterygoid muscle internally. The stylo-maxillary ligament divides the parotid from the submaxillary region, and is connected by fasciculi with the stylo-glossus muscle.

The movements permitted by the temporo-maxillary articulation are more varied and of greater number than those of any joint in the body. The jaw has the power of extension and retraction; it can be depressed and elevated, moved from side to side, and combines all the movements intermediate between these, thus allowing the gliding motion necessary to mastication. The interarticular fibro-cartilage assists in these varied movements and acts as a multiplier of them. The superior surface of this cartilage glides forward on to the articular eminence of the anterior root of the zygoma, while the condyle of the inferior maxilla rotates on a transverse axis in the concavity of the inferior surface of this cartilage. When the mouth is widely opened the cartilages of each articulation move forward on to the articular eminence, the condyles being carried upward on the lower surfaces of these cartilages. If the inferior maxilla is drawn forward, so that the lower incisor teeth are in advance of the upper ones, the action of this articulation is restricted to a gliding of the superior surface of the interarticular cartilage over the anterior root of the zygoma.

If the lower jaw is too much depressed, as is sometimes the case in yawning, vomiting, the extraction of the teeth, or as the result of blows, dislocation will follow. This luxation is caused by the interarticular cartilage being carried forward to the eminence on one or both sides, or by one of the condyles of the inferior maxilla breaking through the anterior portions of the capsular ligament, its weakest point, and lodging in the zygomatic fossa.

Sutures.

The bones of the skull, with the exception of the inferior maxilla and temporal bones and the cartilaginous bones at the base of the skull, are

closely united through borders more or less uneven. This variety of union is called a suture, and those occurring in the head may be separated into four divisions—viz. those of the cranial vault, those of the

FIG. 60.

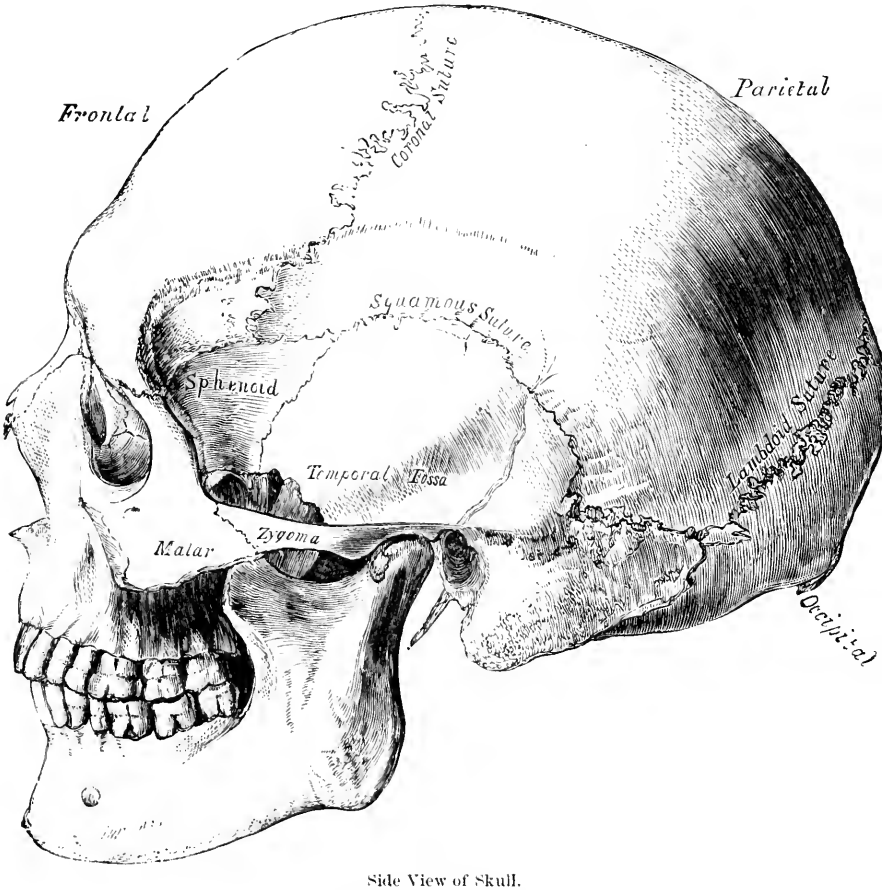

Side View of Skull.

lateral portions of the cranium, those of the face, and those of the occiput (Fig. 60).

In describing sutures the names of the bones forming them should always be used.

SUTURES OF THE CRANIAL VAULT.—Those between the bones forming the cranial vault are three in number.

I. *The Interparietal or Sagittal Suture* is between the two parietal bones, extending from the frontal bone to the superior angle of the occipital bone. In childhood, and occasionally in adult life, ossification between the two halves of the frontal bone is not completed in the median line. This causes the formation of a frontal suture, and a continuation of the sagittal suture from the superior angle of the occipital bone posteriorly to the nasal bones anteriorly. On either side of the suture posteriorly

the parietal foramen or foramina are located, and Wormian bones of large size are often found within the suture.

II. *The Fronto-parietal or Coronal Suture* is between the frontal and parietal bones, extending across the anterior portion of the cranial vault from the superior extremity of the great wing of the sphenoid bone on one side to the same point on the other.

III. *The Occipito-parietal or Lambdoid Suture* is between the occipital and parietal bones, extending from the mastoid portion of the temporal bone on one side upward to the interparietal suture, and thence downward to the mastoid portion of the temporal bone of the other. Wormian bones are more numerous within this than the other sutures.

The Sutures of the Lateral Portions of the Cranial Vault are six in number, without referring to the parieto-frontal and the parieto-occipital articulation where they come within these regions.

The Fronto-malar Suture, describing this region from its anterior to its posterior boundary, is between the external angular process of the frontal bone and the frontal process of the malar bone.

The Fronto-sphenoidal Suture is within the temporal fossa, where the frontal bone articulates with the great wing of the sphenoid bone. This articulation forms the second suture.

The Spheno-malar Suture is the third; it also is within the temporal fossa, and is formed by articulation of the malar bone with the anterior border of the great wing of the sphenoid bone.

The Parieto-sphenoid is the fourth, and is found between the parietal bone and the tip of the great wing of the sphenoid bone. In some rare cases the parietal bone does not articulate with the sphenoid at this point; the frontal bone then articulates directly with the squamous portion of the temporal bone.

The Parieto-squamous Suture, the fifth, is formed by the articulation of the parietal bone with the squamous portion of the temporal bone.

The Parieto-mastoid Suture is the sixth, and is formed by the articulation of the parietal bone with the mastoid portion of the temporal bone.

The Sutures of the Face.—In the face the frontal bone assists in forming several sutures. These likewise receive their names from the bones that form them, as the fronto-sphenoid, fronto-ethmoid, fronto-lachrymal, fronto-maxillary, and fronto-nasal. This rule for naming sutures is carried out in describing the articulations between the other bones of the face.

The Articulations of the Occiput are those between the occipital bone and the posterior inferior angle of the parietal bone, and of the occipital bone and mastoid portion of the temporal bone.

The articulations between the bones at the base of the brain-case are the occipito-sphenoid, occipito-temporal, and the temporo-sphenoid. In early life a thin layer of cartilage is interposed between these bones, which at adult age becomes ossified. These articulations, therefore, are of the synchondroidal variety.

The Skull and its Articulations at Different Periods of Life.

About the second month of embryonal life the brain-case is divided into two almost equal compartments by the tentorium cerebelli, which at this period extends almost perpendicularly from its anterior attachment within the skull. This division shows the posterior or cerebellar portion of the encephalon at this period to be larger in proportion to the anterior or cerebral than in the adult. Shortly after the second month the rapid growth of the parietal bones causes the occipital portion of the cranium to be pushed backward. By the final enlargement of the frontal bones the anterior or cerebral fossæ are completed.

At birth the parietal bones are large in proportion to the other bones of the head, and their centres of ossification are extremely prominent. The frontal eminences and the occipital protuberance are also noticeably convex.

During the first year, to accommodate the enlarging brain, the dome of the case grows with greater rapidity than the base, the upper portion of the frontal bone developing to a greater extent than the orbital portion, which causes the prominence of the forehead peculiar to children at this age. At this period the facial bones occupy but about one-eighth of the entire skull, while at adult life they form almost one-half. The external auditory meatus and the alveolar processes are but partially developed, and only the anterior deciduous teeth are erupted. The sutures are more or less open, while the different parts of the bones formed by separate centres of ossification in many instances are not united.

During the first year the sutures of the cranial vault are generally so widely open that the border of one bone can be made to overlap that adjoining without damage to either or to the brain of the child. Such overlapping takes place during the birth of a child, and the head may be subjected to considerable compression of various kinds during early life with comparatively little or no injury.

The sutures according to their location, disappear at different periods; the general ossific development of the individual likewise seems to influence their disappearance. Traces of them can be found in the skull as late as the fiftieth or sixtieth year. When a suture is obliterated by ossification such complete union is called synostosis.

Occasionally some pathological condition will cause a suture to close prematurely. When this occurs the cranium will bulge on the opposite side, in order to accommodate the brain as it develops.

Wormian Bones (ossa triquetra).—Wormian bones of various shapes and sizes are found within the sutures uniting the membranous bones of the cranial vault. They are rarely found in the face. Their form is irregular, and their borders are adapted to the suture within which they are situated. Generally they are small, but occasionally they exceed an inch in diameter. They are most frequently found in the occipito-parietal suture, where they are occasionally met with in considerable numbers. Their function between membranous bones is similar to that of cartilage between cartilaginous bones. They have their own

centres of ossification, and act independently until synostosis takes place.

FONTANELLES.—The fontanelles of the head are six in number—two situated in the median line, anterior and posterior, and four laterally. They are membranous interspaces formed by the incomplete ossification at the four angles of the parietal bones (Figs. 61 and 62).

The Anterior Median Fontanelle is situated at the anterior superior angle of the parietal bones, and is formed by the incomplete ossific con-

FIG. 61.

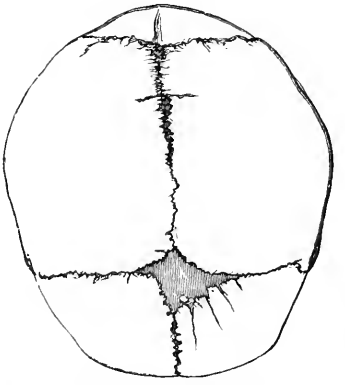

Skull at Birth, showing the Anterior and Posterior Fontanelles.

FIG. 62.

The Lateral Fontanelles.

dition of these angles as well as the superior angles of the two halves of the frontal bone. It is quadrilateral in form, its angles extending into the four sutures belonging to the frontal and parietal bones. It is the largest of the six fontanelles, and usually remains partially open until the tenth or fifteenth month after birth, *holding in this respect a close relation with the rapidity of the development of the entire osseous system. In quickly-closing fontanelles the teeth appear soon and the child walks early.*[1] Sometimes this fontanelle remains open through years of early life, and it has been known to exist in the adult.

The Posterior Median Fontanelle is situated at the posterior superior angles of the parietal bones and the superior angle of the occipital bone. It is triangular in outline, the angles extending into the sutures formed by the parietal and occipital bones. This fontanelle is closed at birth or shortly thereafter, the bones being united by membrane which permits them to move freely upon each other.

The Lateral Fontanelles, four in number, are situated at the inferior angles of the parietal bones and the bones in immediate juxtaposition therewith. They are small in size and irregular in form, those situated posteriorly being the larger. They are closed at birth or soon thereafter.

The fontanelles are gradually closed by the extension of the bones into the membranes which fill the spaces. It is in this way that the angles of the bones are completed and the sutures formed.

The posterior lateral and occasionally the anterior fontanelles are filled

[1] Allen's *Human Anatomy.*

in by Wormian bones; usually all traces of the fontanelles disappear about the fourth year.

The Walls of the Brain-case.[1]

The bones forming the walls of the brain-case are composed of two plates of compact tissue, an outer and an inner, with intervening cancellated tissue, called diploë, between them.

The Outer or Fibrous Plate or Table is thick and tough, and roughened in different places for the origin and insertion of muscles. It is also covered by minute orifices for the attachment of the pericranium (periosteum) and entrance of the nutrient vessels.

The Inner Plate or Vitreous Table is thinner, smoother, closer-grained, and more brittle than the outer, and has a glossy appearance. The minute orifices are not so numerous as they are externally, and they give attachment to the dura mater, which acts as the internal periosteum.

The Diploë (see Fig. 115, veins) is the cancellated tissue situated between the external and the internal plates. It gives the bone lightness, and at the same time acts as a cushion to diffuse, and thus moderate, shocks. It is extremely vascular, and gives passage to numerous blood-vessels, which communicate with both the pericranium and the dura mater in such manner that death of the pericranium is not always followed by death of the bone. It is unevenly distributed throughout the different parts of the skull, being thick in some places, as in the region of the greater portion of the occipital bone and the mastoid portion of the temporal bone, while it is entirely absent in others, as in portions of the orbital plates of the frontal bone and the glenoid fossæ of the temporal bones.

The Internal Surface of the Brain-case is smooth, glossy, and marked by digitate depressions corresponding to the convolutions of the brain. The interior of the skull is separated into two principal divisions—first, the roof or dome; and second, the floor or base.

The Dome or Vertex of the brain-case is oval-shaped and vaulted, generally wider behind than in front, and made up of the frontal, two parietal, and a portion of the occipital bones. The sutures between these internally belong to the variety known as harmonia. It is marked by the superior longitudinal groove, which extends from its anterior to its posterior portion. This groove is deeper in front and behind than in its central portion. The surfaces of the bones are furrowed for the accommodation of the meningeal vessels, and marked by depressions of different depths for the lodgment of the Pacchionian bodies.

The Floor or Base of the internal portion of the brain-case is divided into three pairs of fossæ, the anterior, middle, and posterior (Fig. 63).

The Anterior Fossæ are formed by the cribriform plate of the ethmoid, the orbital plates of the frontal, the lesser wings, and a portion of the

[1] For detailed particulars of the processes, surfaces, and foramina of the bones forming the brain-case see description of individual bones. Foramina formed by the union of two or more bones will be described under this heading.

FIG. 63.

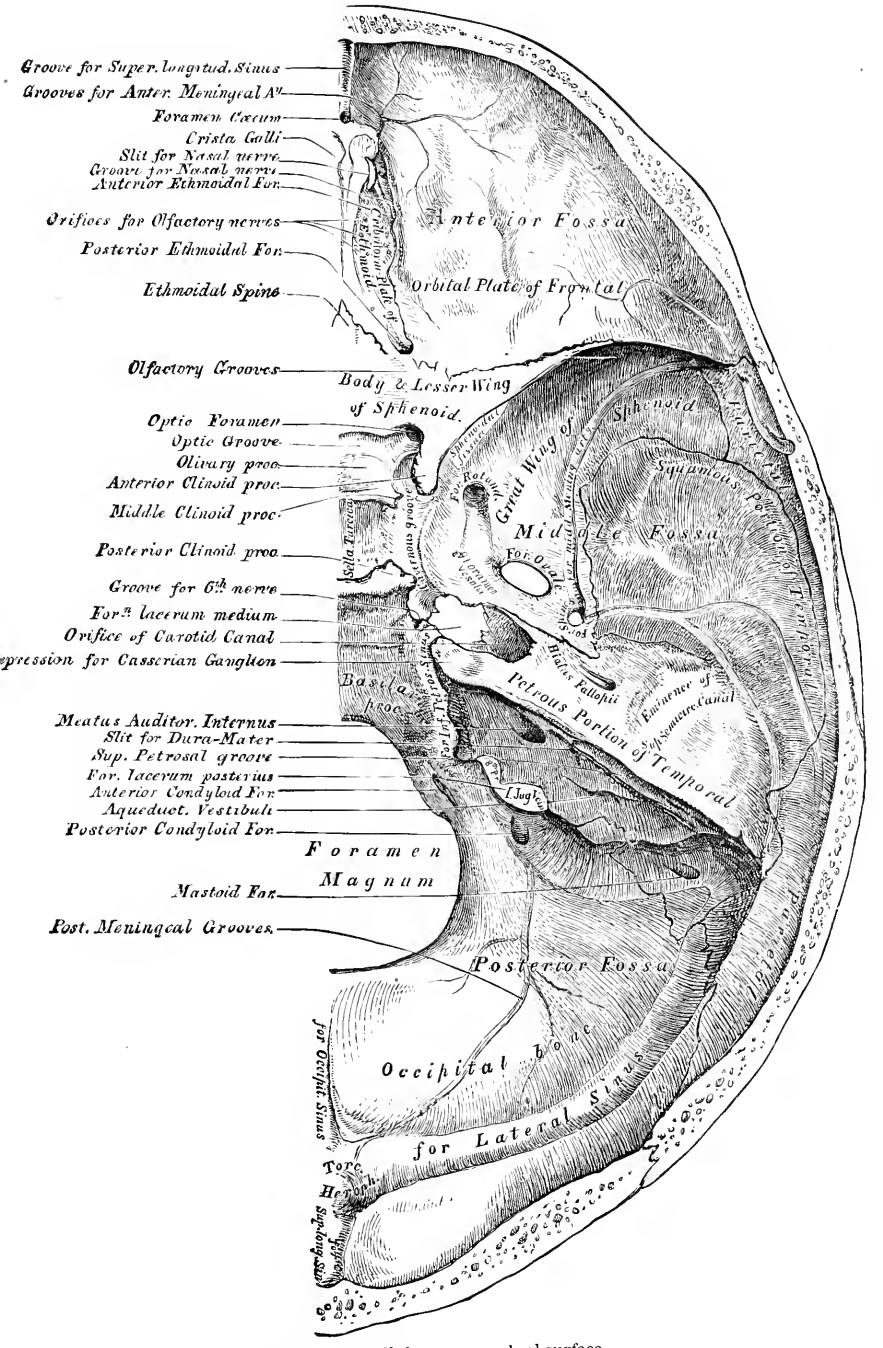

Base of the Skull, inner or cerebral surface.

body of the sphenoid bone. They are convex and digitated over the orbits, concave over the ethmoid bone, the crista galli projecting upward from the centre of its cribriform plate. Just anterior to the crista galli is situated the foramen cæcum, the openings, including the cerebro-nasal slit, for the olfactory and nasal nerves and vessels being found on either side of the projection. At the union of the lesser wings with the body of the sphenoid bone the optic foramina are found. These foramina transmit the optic nerves and ophthalmic arteries. The lesser wings and a portion of the body of the sphenoid bone form the posterior boundary of these fossæ, the wings extending outwardly into the fissure of Sylvius of the brain. The anterior fossæ support the frontal lobes of the brain.

The Middle Fossæ of the brain-case are formed by the great wings and part of the body of the sphenoid bone, the squamous portion of the temporal bone, and the anterior inferior portion of the parietal bones. They are cup-shaped in form, and situated on a lower plane than the anterior fossæ. They are bounded in front by the lesser and a portion of the greater wings of the sphenoid bone, behind by the anterior surface of the petrous portion of the temporal bone, externally by the squamous portion of the temporal bone and the anterior inferior angle of the parietal bones, and internally by the body of the sphenoid bone.

The Pituitary Fossa separates these fossæ in the median line.

The middle fossæ are digitated and their floors are pierced by numerous openings. The anterior lacerated foramina, which are formed by the approximation of the frontal bone and the body and two wings of the sphenoid bone, open into these fossæ anteriorly. Each of these foramina transmits from within outwardly the third, fourth, and sixth, and the ophthalmic division of the fifth cranial nerves. The ophthalmic vein and a branch of the lachrymal artery pass through this foramen from without inwardly. Just posterior to the anterior lacerated foramen, close to the body of the bone, is the foramen rotundum. This transmits the superior maxillary, the second division of the fifth nerve. Behind the foramen rotundum, in the deepest portion of the fossa, is situated a large oval foramen, the foramen ovale. It gives passage from within outwardly to the inferior maxillary or the third division of the fifth cranial nerves, and from without inwardly to the lesser meningeal artery.

External to the foramen ovale, and a little posterior to it, in the spine of the great wing of the sphenoid bone, is situated the foramen spinosum. This foramen gives passage from without inwardly to the middle meningeal artery.

Between the round and the oval foramina is sometimes located a small foramen, the foramen Vesali, for the transmission of a small vein to the cavernous sinus.

Between the apex of the petrous portion of the temporal bone and the body and posterior border of the great wing of the sphenoid bone will be found the middle lacerated foramen (foramen lacerum medius). In the recent state this foramen is filled up from below with fibrous tissue. The carotid canal terminates at the apex of the petrous portion

of the temporal bone at the external boundary of this foramen, while the Vidian canal commences below at its anterior margin.

The hiatus Fallopii is a small canal, the opening of which is situated on the anterior surface of the petrous portion of the temporal bone just external to the termination of the carotid canal. This canal transmits the Vidian nerve, which is a branch of the seventh or facial nerve, and goes to the spheno-palatine ganglion. On the apex of the petrous portion of the temporal bone is an irregular depression for the lodgment of the ganglion of Gasser (semilunar ganglion). This is the large ganglion of the fifth nerve.

Three divisions are thrown off from this ganglion within the middle fossa, and pass outwardly through its walls or floor.

The middle cerebral lobes of the brain rest upon the floor of the middle fossæ of the skull.

The Posterior Fossæ of the brain-case are in great part formed by the occipital bone. This bone, in conjunction with a portion of the body of the sphenoid bone, forms the floors; their anterior boundary is formed by the posterior surface of the petrous portion of the temporal bone, while the mastoid portion of the temporal bone and a small portion of the parietal bones complete the sides.

These fossæ are deeper and larger than the others. Their central portions anteriorly are marked by the posterior clinoid processes.

The elongated concave surface of bone between the posterior clinoid processes and the foramen magnum is composed of the dorsum sellæ of the sphenoid bone anteriorly and the basilar process of the occipital bone posteriorly. This surface lodges the medulla oblongata and the basilar artery.

The posterior surface of the petrous portion of the temporal bone is marked by a large opening, the internal auditory meatus. The seventh and eighth nerves pass into this opening, the seventh going to the face, while the eighth passes to the internal ear.

The posterior lacerated foramen (foramen lacerum posterius) is below the internal auditory meatus, between the petrous portion of the temporal bone and the basilar process of the occipital bone. It is a large, irregular, twisted, wedge- or pear-shaped aperture, the base rounded and directed to the posterior and distal portion of the base of the skull, the axis of its external opening being toward the mastoid process of the temporal bone. This base is rounded, being formed by the jugular fossa of the occipital and temporal bones. It is here, within this foramen, that the internal jugular vein is formed by the termination of the lateral sinuses.[1] The apex of the posterior lacerated foramen is generally separated into two divisions by the intrajugular processes of bone. The posterior division transmits from the brain-case the ninth (glossopharyngeal), the tenth (pneumogastric), and the eleventh (spinal accessory) nerves, while the anterior division gives passage to the inferior petrosal sinus.

The deep groove for the accommodation of the lateral sinus termi-

[1] The sinuses of the brain-case are membranous for the passage of venous blood. They resemble veins, differing from them in that they lack the fibrous and muscular coats of these vessels.

nates at the posterior boundary of this foramen. From this point it extends outwardly over the junction of the petrous with the mastoid portion of the temporal bone, curves backward over the posterior inferior angle of the parietal bone, and thence inward over the occipital bone to the torcular Herophili, which is situated at the internal occipital protuberance, and formed by the confluence of all the sinuses of the brain excepting those transmitted through the petrosal sinuses. The posterior condyloid and mastoid foramina open into this groove. In the region of these sinuses the bones are generally extremely thick.

The central portion of the floor of the posterior fossæ of the cranium is pierced by the foramen magnum. This foramen transmits the spinal cord and its membranes, the vertebral arteries, and the roots of the spinal accessory nerves. The anterior condyloid foramen opens into the anterior border of the foramen magnum. It transmits the twelfth cranial nerve (hypoglossal).

The Cerebellar Fossæ form that portion of the posterior fossæ situated between the lateral sinuses and the foramen magnum; they lodge the lobes of the cerebellum.

The External Surface of the Brain-case.

The external surface of the brain-case (Fig. 64) is divided into five regions—a superior, inferior, anterior or facial, and two lateral regions.

The Superior Region extends longitudinally from the supraorbital arches anteriorly to the superior curved line on the occipital bone posteriorly, and from the right to the left temporal ridges. It is in shape an elongated dome, its length extending antero-posteriorly. It is flattened in front to form the forehead, and projects behind. It is marked by four eminences, two frontal and two parietal.

The greatest width of the superior region is generally from one parietal eminence to that of another. No muscles arise or are attached in this region, but it is well marked by fine pits for the attachment of the pericranium, over which play the fibres and aponeuroses of the occipito-frontalis muscle.

Base of the Brain-case.—When the facial bones are removed from the anterior portion of the skull, the under surface of the brain-case corresponds in great measure with the floor of its internal surface, like which it is separated into three divisions—anterior or facial, middle or cervical, and posterior or occipital; and these divisions are situated directly under corresponding ones internally. This surface, however, is rougher and the projections of bones are much more prominent than on the internal surface.

The Anterior Portion is bounded anteriorly by the supraorbital arches, with their notches or foramina, and the rough articulating surface for the nasal bones and the nasal processes of the superior maxillary bones; laterally by the external angular processes of the frontal bone and the anterior border of the great wing of the sphenoid; and posteriorly by the inferior border of the great wing of the sphenoid bone, and a line drawn from the base of the anterior surface of the pterygoid process on

FIG. 64.

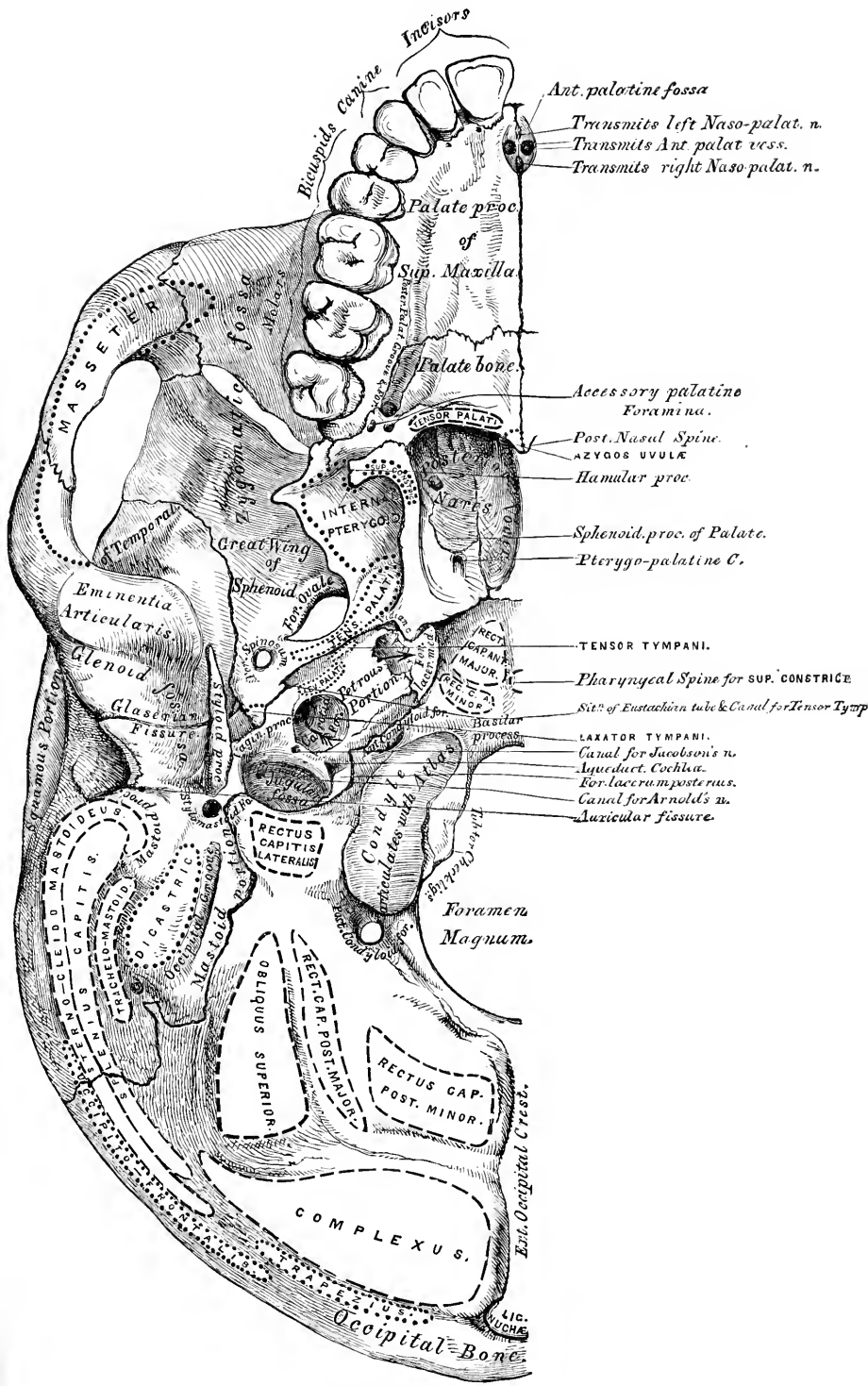
Incisors
Bicuspids
Canine
Ant. palatine fossa
Transmits left Naso-palat. n.
Transmits Ant palat vess.
Transmits right Naso palat. n.
Palate proc. of Sup. Maxilla
Palate bone.
Accessory palatine Foramina.
TENSOR PALATI
Post. Nasal Spine.
AZYGOS UVULÆ
Hamular proc.
Sphenoid. proc. of Palate.
Pterygo-palatine C.
TENSOR TYMPANI.
Pharyngeal Spine for SUP. CONSTRICE
Sites of Eustachian tube & Canal for Tensor Tymp
LAXATOR TYMPANI.
Canal for Jacobson's n.
Aqueduct. Cochlæ.
For. lacerum posterius.
Canal for Arnold's n.
Auricular fissure.
Foramen Magnum.
Ext. Occipital Crest.
Occipital Bone.
Base of the Skull, external surface.

one side, across the body of the sphenoid bone, to the same process on the other side.

This region is symmetrically divided by the descending plate of the ethmoid and the rostrum of the sphenoid bone.

The structures forming the anterior division on each side of this central division, from within outwardly, are, first, the cribriform plate of the ethmoid bone, which forms the roof to the nasal chamber; second, the lateral masses of the ethmoid, which, through its os planum, forms a portion of the inner wall of the orbital cavity; third, the orbital plate of the frontal bone and a portion of the lesser wing of the sphenoid; and fourth, the great wing of the sphenoid, together with the rough articulating surface of the external angular process of the frontal bone.

Immediately in front of the ethmoid bone, and between the internal angular processes of the frontal bone, will be found the articulating surfaces for the lachrymal, maxillary, and nasal bones.

The foramina of this region have already been described. They are as follows: The perforations of the cribriform plate of the ethmoid bone, the anterior and posterior ethmoidal foramina, the supraorbital, anterior lacerated, and optic foramina within the orbital cavity, and the foramen rotundum and Vidian canal.

The Median or Cervical Region is bounded anteriorly by the inferior border of the great wing of the sphenoid bone, and by a line drawn from the base of the anterior surface of the pterygoid process on one side, across the body of the sphenoid bone, to the same point on the other. The lateral boundary is formed by a line drawn along the pterygoid ridge of the sphenoid bone, extending to the extreme outer point of the glenoid fossa, and thence to the apex of the mastoid portion of the temporal bone. The posterior boundary is formed by a line drawn from the apex of the mastoid portion of the temporal bone on one side to the same point on the other, crossing the centre of the condyloid processes of the occipital bone and the foramen magnum.

A line drawn from the anterior portion of the rostrum of the sphenoid bone to the centre of the anterior portion of the foramen magnum will divide the middle region into two symmetrical halves.

The structures forming this division on each side of the central line from its anterior to its posterior portion are as follows:

First: *the Pterygoid Process*, which extends downwardly.

Second: *the Pterygoid Fossa*, which is situated posteriorly between the plates composing the pterygoid process. The outer plate of this process gives origin within the fossa to the internal pterygoid muscle.

Third: *the Scaphoid Fossa*, at the base of the roots of the pterygoid fossa posteriorly. This fossa gives origin to the tensor palati muscle.

Fourth: *the Vaginal Process*, situated at the base of the internal pterygoid plate, at its junction with the body of the bone.

Fifth: *the Inferior Surface of the Great Wing of the Sphenoid Bone.*—This surface is smooth, concave, and quadrilateral; it is situated just external to the pterygoid process. It gives origin to the external head of the external pterygoid muscle.

Sixth: *the Foramen Ovale*, situated in the posterior portion of the

inferior surface of the great wing of the sphenoid, back of, and a little external to, the pterygoid process. This foramen transmits the inferior maxillary nerve and the lesser meningeal artery.

Seventh: *the Foramen Spinosum*, situated behind and externally to the foramen ovale in the inferior surface of the great wing of the sphenoid bone. It transmits the middle meningeal artery.

Eighth: *the Spinous Process of the Sphenoid Bone*, which is the posterior external angle of the inferior surface. This process gives origin to the laxator tympani muscle.

Ninth: *the Glenoid Fossa*, situated external to the spinous process of the sphenoid bone. This fossa is a large oval depression which receives the condyle of the inferior maxillary bone in the articulated skull, and also the superior portion of the parotid gland.

Tenth: *the External Auditory Meatus*, situated behind the posterior external boundary of the glenoid fossa.

Eleventh: *the Glenoid Fissure*, which passes inward and forward through the centre of the glenoid fossa.

Twelfth: *the Eustachian Sulcus*, which is between the inner extremity of the glenoid fissure and the body of the sphenoid bone. The sides of this sulcus are formed by part of the petrous portion of the temporal and the great wing of the sphenoid bone, its internal portion being frequently incomplete.

Thirteenth: *the Middle Lacerated Foramen*, which is situated between the apex of the petrous portion of the temporal and the body of the sphenoid bone. In the recent state it is filled up by fibro-cartilage. Its size varies in different skulls, and occasionally it is found filled with bone.

Fourteenth: *the Petro-basilar Groove*, between the petrous portion of the temporal and the basilar process of the occipital bones. This groove in the recent state is filled with fibrous tissue.

Fifteenth: *the Posterior Lacerated Foramen*, which extends backward and outward from the petro-basilar groove. This foramen is formed by the union of the jugular fossæ of the temporal and occipital bones. It transmits the jugular vein and the ninth, tenth, and eleventh nerves, a septum of bone often separating the vein from the nerves.

Sixteenth: *the Opening for the Carotid Canal* is situated on the under surface of the petrous portion of the temporal bone, just anterior to the posterior lacerated foramen.

Seventeenth: *the Digastric Groove*, situated on the internal surface of the mastoid portion of the temporal bone. It is long, deep, and narrow, for the origin of the digastric muscle.

Eighteenth: *the Stylo-mastoid Foramen*, situated at the anterior extremity of the digastric groove at the base of the styloid process of the temporal bone. This foramen gives exit to the seventh or facial nerve.

Nineteenth: *the Styloid Process of the Temporal Bone* extends downward from a point just anterior to the stylo-mastoid foramen. The base of this process is surrounded by what is termed the vaginal process.

Twentieth: *the Pharyngeal Spine* is a small tubercle situated about

the centre of the basilar process of the occipital bone. This spine gives attachment to what is known as the raphé of the pharynx.

Twenty-first: *the Anterior Condyloid Foramen* is just in front of the condyles of the occipital bone, on the lateral surface of the basilar process. This foramen is the external orifice of the hypoglossal canal.

Twenty-second: *the Condyloid Processes of the Occipital Bone* are situated on each side of the foramen magnum anteriorly. They are double-convex articulating facets, upon which the head rocks within the corresponding concavities of the atlas or first cervical vertebra.

Posterior Region.

The Posterior Division of the base[1] of the brain-case is semicircular in outline. Its anterior boundary extends from the apex of the mastoid portion of the temporal bone on one side, across the articulating condyles of the occipital bone, to the same point on the other side. Its posterior or semicircular boundary extends from the apex of the mastoid portion of the temporal bone on one side, upward and backward, joining the superior curved line of the occipital bone, and passing along this ridge to the occipital protuberance, from which point it runs forward and downward on the ridge of the other side to the apex of the mastoid portion of the temporal bone. The surface of bone included within this semicircular outline, excluding the condyles, the posterior condyloid foramina, and the foramen magnum, affords attachment to muscles.

The line forming the anterior boundary of the posterior region not only separates it from the middle region, but is the axis between the anterior muscles, which act as the motor power in bowing the head, from those which antagonize these and raise and draw the head backward: this, therefore, is the axis upon which the head oscillates; its centre is the point around which the head rotates.

On either side, immediately behind the condyles, are depressions pierced by foramina leading to the lateral sinuses. These are known respectively as the posterior condyloid fossæ and foramina.

Lateral Regions of the Skull.

The points of interest on the lateral region (see Fig. 60) from the posterior to the anterior boundary are the mastoid process, the external auditory meatus, the auditory process, the glenoid fossa, all of which are parts of the temporal bone; the zygomatic arch, formed by union of the zygomatic processes of the temporal and the malar bones; the condyloid and coronoid processes of the inferior maxilla.

Two deep fossæ mark the lateral region of the skull—one above the zygomatic arch, known as the temporal fossa, and the other below the arch, known as the zygomatic fossa.

The Temporal Fossa occupies the greater portion of the lateral region

[1] In comparative anatomy this is the posterior half of the roof of the brain-case in animals, it being above the spinal cord or neural cavity, and the only portion of the roof formed from cartilage.

of the skull. It is made up of parts of five bones—the temporal, the sphenoid, and the malar below, the parietal and the frontal above—and is crossed by seven sutures uniting these bones. It is also traversed by grooves for the accommodation of the deep temporal arteries, and marked by fan-like grooves for the origin of the deep fibres of the temporal muscle.

The temporal fossa is bounded in front by the posterior surface of the frontal process of the malar, the external angular process of the frontal, and part of the great wing of the sphenoid bones. It is bounded above and behind by the supratemporal ridge. This is formed by two slightly-elevated borders that originate near the fronto-malar articulation from a single point, from which it diverges into two nearly semicircular lines that curve upward, backward, and downward across the fronto-parietal suture at a distance of about a half inch or more from each other.

The Inferior Line extends backward and curves downward to join the posterior root of the zygomatic process of the temporal bone. This line is the uppermost limit of the deep attachment of the temporal muscle.

The Superior Line, which is separated from the inferior, gradually increasing the distance as it proceeds backward and downward, terminates near the parieto-occipito-mastoid articulation. This upper line and space between it and the lower afford attachment to the temporal fascia. The inferior boundary of the temporal fossa internally is formed by the infratemporal ridge. This ridge extends from the parieto-occipito-mastoid articulation forward along the posterior root of the zygomatic process of the temporal bone, across the pterygoid ridge, which separates the lateral from the inferior surface of the great wing of the sphenoid bone, to the roughened prominence on the posterior border of the malar bone. The external boundary of the temporal fossa is formed by the zygomatic arch, and in the recent state by the temporal fascia. This fossa accommodates the tendon and muscular fibres of the temporal muscle.

The Zygomatic Fossa is below the zygomatic arch. It is an irregularly-shaped cavity, bounded anteriorly by the posterior or zygomatic surface of the superior maxilla; internally, by the external pterygoid plate; superiorly, by the inferior surface of the great wing of the sphenoid bone and a part of the squamous portion of the temporal bone, the infratemporal ridge dividing the zygomatic from the temporal fossa in this region; and laterally by the ramus of the inferior maxilla.

The following openings will be found within the fossa: The orifices of the *Posterior Dental Canals*, situated in the superior maxillary bone for the transmission of the posterior dental vessels and nerves; the *Spheno-maxillary Fissure*, between the sphenoid and the superior maxillary bones, leading into the orbit; the *Pterygo-maxillary Fissure*, between the pterygoid process of the sphenoid bone and the superior maxilla, leading into the spheno-maxillary space or fossa; *the Foramen Ovale* and *Foramen Spinosum*, situated in the great wing of the sphenoid bone in close proximity to each other. The foramen ovale transmits the third division of the fifth nerve and a small meningeal artery,

while the spinous foramen transmits the middle meningeal artery. *The Inferior Dental Foramen* is situated in the inferior maxillary bone, and transmits the inferior dental vessels and nerve, while between the zygomatic arch and the infratemporal ridge is the temporo-zygomatic strait, joining it with the temporal fossa.

The zygomatic fossa accommodates the tendon and lower portion of the temporal muscle, the external and internal pterygoid muscles, the inferior maxillary nerve and its branches, and, finally, the internal maxillary artery, passing through and giving off branches as it extends inward and forward into the pterygo-maxillary fissure.

The Spheno-maxillary Fossa is a triangular space bounded behind by the upper portion of the anterior surface of the pterygoid process; in front by the internal portion of the zygomatic surface of the superior maxilla and a portion of the palate bone; above by the under surface of the body of the sphenoid bone and the orbital process of the palate bone; and internally by the perpendicular plate of the palate bone, which separates this fossa from the nasal chambers.

This fossa lodges the spheno-palatine (Meckel's) ganglion and the terminal end of the inferior maxillary artery. Opening into it are the pterygo-maxillary and spheno-maxillary fissures and five foramina—the anterior lacerated, the rotund, the Vidian, the pterygo-palatine, and the spheno-palatine.

The Pterygo-maxillary Fissure extends vertically between the superior maxilla and the pterygoid process of the sphenoid bone. It is wider above than below, and communicates with the zygomatic fossa, transmitting the internal maxillary artery and vein.

The Spheno-maxillary Fissure extends nearly horizontally outward and forward from the body of the sphenoid bone at an angle of about forty-five degrees. Its posterior boundary is formed by the inferior border of the orbital surface of the great wing of the sphenoid bone; its anterior boundary is formed by the angle between the orbital and zygomatic surfaces of the superior maxilla and a portion of the orbital process of the palate bone. Externally it is bounded by a smooth notch in the orbital process of the malar bone, and internally by the body of the sphenoid bone.

This fissure extends between the orbit and the spheno-maxillary and pterygo-maxillary fossa, and transmits the superior maxillary division of the fifth nerve, the infraorbital artery and vein, and the ascending branches of the spheno-palatine (Meckel's) ganglion.

The Pterygo-palatine Foramen is situated between the pterygoid process of the sphenoid bone and the posterior border of the horizontal plate of the palate bone. This foramen opens into a canal, the posterior palatine, which passes directly downward, opening into the roof of the mouth at the posterior lateral angle of the hard palate.

Occasionally there will be found in this locality two or more accessory palatine canals, which give passage to branches of nerves from the spheno-palatine ganglion to the hard and soft palate. These canals also transmit vessels to the roof of the mouth.

The Spheno-palatine Foramen is situated between the superior border of the perpendicular plate of the palate bone and the under surface

of the body of the sphenoid bone. This foramen opens into the posterior portion of the superior meatus of the nose, and transmits the naso-palatine nerve and vessels.

Facial or Anterior Region of the Skull.

The facial region of the brain-case is bounded above by a curved line extending from the extremity of the angular process of the frontal bone on one side, upward across the frontal eminences, to the

Fig. 65.

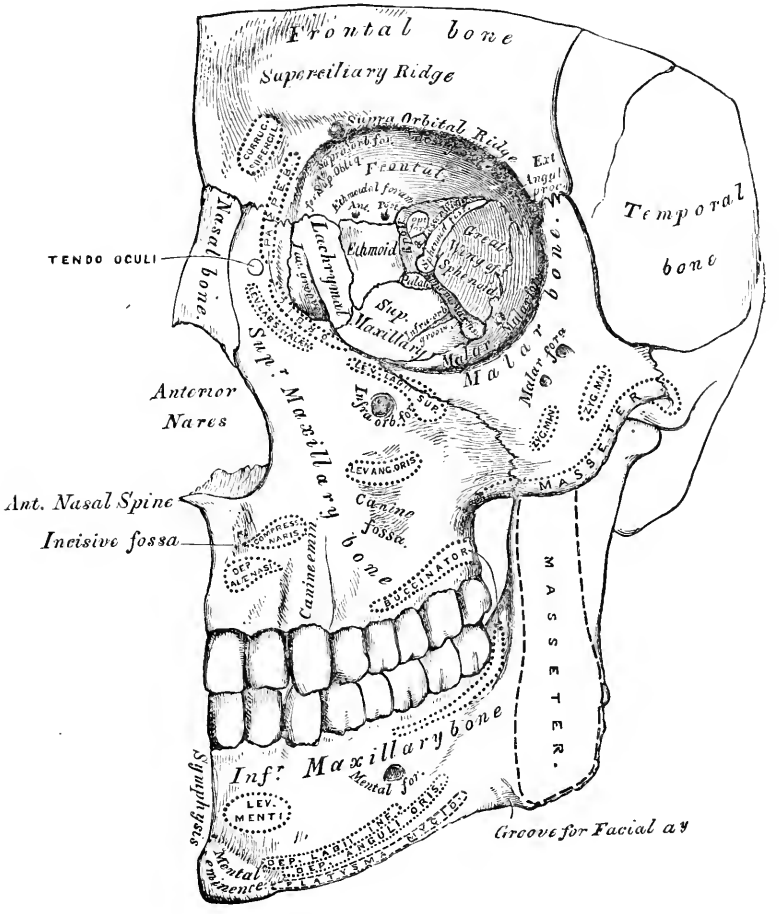

Anterior Region of Skull.

angular process of the frontal bone on the other side; laterally by a line drawn from the commencement of the superior boundary, downward and slightly backward, across the malar bone to the angle of the lower jaw, and below by the lower border of the inferior maxilla. It

is nearly oval in shape, being slightly broader above than below (see Fig. 65).

The surface of the facial region is extremely irregular, presenting as it does the orifices to several large cavities which protect three of the organs of special sense—viz. that of sight, of smell, and of taste. This region is divided into three portions—one central and two lateral.

The Central Portion commences a little above the nasal eminence, situated between the internal angular processes of the frontal bone. This eminence marks the position of the frontal sinuses.

Below the nasal eminence is a semicircular suture uniting the superior maxilla and nasal bones with the frontal bone.

Directly under this suture is the bridge-roof or arch of the nose. It is formed by the nasal bones and the nasal processes of the superior maxillæ. It is convex from side to side, and concave from above downward. The median line of this arch presents the internasal suture, while its lateral surfaces are marked by the naso-maxillary sutures.

The nasal arch is generally pierced by a foramen on either side for the passage of a vein.

Below the arch of the nose are situated the anterior openings to the nasal chambers. Conjointly, they are pyriform in shape, bounded above by the inferior border of the nasal bones, the lateral and inferior boundaries being formed by the superior maxillæ. The borders of this opening are sharp and give attachment to the lateral cartilage of the nose.

Beneath the anterior opening to the nasal chambers are situated the two incisive fossæ, between which will be found the intermaxillary suture.

Continuing downward, are next found the four incisor teeth, situated in the alveolar border of the intermaxillary bone.

Below this, in the median line of the inferior maxilla, will be found the four inferior incisor teeth and the symphysis menti, a slight vertical ridge at its commencement, but as it passes outward and downward diverging to form the mental process or chin, a feature characteristic of man alone. On each side of the upper portion of the ridge are the inferior incisive fossæ.

The Lateral Portions of the face commence above in the frontal eminences. These eminences are rarely of the same size on both sides of the forehead. Below the frontal eminence is a depression situated just above the superciliary ridge. Beneath this depression is the large circular opening to the orbital cavity. This cavity is bounded above by the *Supraorbital Arch*, which extends superiorly from the internal to the external angular processes of the frontal bone.

The inner third of this boundary is marked by a notch or foramen, the *Supraorbital Notch or Foramen*, for the passage of the frontal nerve and vessels. The inferior boundary of the orbital cavity is formed externally by the malar bone, below by the superior maxilla, and internally by the nasal process of the superior maxilla and the lachrymal bone.

The Infraorbital Foramen is below the infraorbital border, and affords exit to the nerve and artery of the same name. It is internal to the

maxillo-malar articulation, and below the foramen is situated the canine fossa.

The Canine Fossa is above the alveolar process of the superior maxilla, which supports the teeth.

Anterior Dental or Mental Foramen is usually situated below a line between the bicuspid teeth and above the external oblique line of the inferior maxilla. This foramen transmits the mental nerve and vessels.

The Supraorbital Notch or Foramen, the Infraorbital Foramen, and the *Anterior Dental Foramen* are situated in a vertical line, one beneath the other. They give exit to the terminal branches forming the three divisions of the fifth or trifacial nerve, which transmits sensation from the face.

THE ORBITAL CAVITIES are two in number. They are situated between the anterior portion of the brain-case and the superior portion of the facial bones. They are irregular quadrilateral pyramids in shape, their bases being directed forward and a little outward, and their apices backward and a little inward. Their outer walls diverge from the median line of the face at about an angle of forty-five degrees, while their inner walls are nearly parallel with each other.

The roof of the orbit is concave, and formed by the horizontal or orbital plate of the frontal bone and a portion of the lesser wing of the sphenoid bone. The outer portion of the roof anteriorly is marked by the lachrymal fossa for the lodgment of the lachrymal gland. There is also a depression at the inner portion of the roof anteriorly for the attachment of the pulley of the superior oblique muscle.

The floor of the orbit is formed by the orbital surface of the superior maxilla and the orbital processes of the malar and palate bones, the latter being situated at the posterior median angle.

At the inner third of this surface anteriorly will be found the opening to *the Lachrymal Canal*. The depression just external to the lachrymal canal is for the origin of the inferior oblique muscle of the eye.

The outer wall of the orbit is formed by the anterior or orbital surface of the great wing of the sphenoid and part of the malar bone, its internal wall being formed by the nasal process of the superior maxilla, the os planum or orbital plate of the ethmoid bone, and the lachrymal bone, making, in all, seven bones involved in the formation of the orbital cavity. Three of these bones, however, the frontal, ethmoid, and sphenoid, enter into the formation of each orbit, so that it takes but eleven bones to form the two cavities.

The circumference of the orbit was described with the structures of the face.

The apex of the orbit corresponds to the optic foramen.

There are ten openings into the orbit—viz. the optic, anterior lacerated, supraorbital, malar, and the anterior and posterior ethmoidal foramina, the lachrymal and infraorbital canals, the spheno-maxillary fissure, and the facial opening.

The Optic Foramen opens into the apex of the orbital cavity, between the body and lesser wing of the sphenoid bone. It transmits the optic nerve and the ophthalmic artery from the brain into the orbit.

The Anterior Lacerated Foramen is situated near the apex of the orbital cavity, just external to the optic foramen, and extends upward and outward between the greater and lesser wings of the sphenoid bone. It transmits from the brain into the orbit the third, fourth, first division (ophthalmic) of the fifth and sixth nerves, and through the orbit into the brain the ophthalmic vein and a small artery, a branch of the lachrymal.

The Anterior and Posterior Ethmoidal Foramina are situated on the inner wall of the orbital cavity in the ethmo-frontal suture, between the ethmoid and frontal bones. The anterior foramen transmits from the orbit into the brain-case the nasal branch of the ophthalmic nerve and an artery and vein, branches of the ophthalmic, which accompany this nerve.

The Posterior Foramen transmits from the orbit the posterior ethmoidal artery and vein.

The Lachrymal Canal is situated at the anterior inferior angle of the orbital cavity. Its superior orifice is between the nasal process of the frontal bone and the lachrymal bone. From this point the canal extends downward, inward, and backward, terminating in the inferior meatus of the nose. It accommodates the lachrymal duct.

The Infraorbital Canal commences by a groove situated about the centre of the posterior border of the floor of the orbital cavity. This groove passes forward and downward into the body of the superior maxilla, and makes its exit on the face in the infraorbital foramen below the middle of the infraorbital ridge. It transmits the infraorbital nerve, which is a continuation of the second division of the fifth or superior maxillary nerve, and infraorbital vessels.

The Spheno-maxillary Fissure is situated in the posterior portion of the orbital cavity, extending from the body of the sphenoid bone forward and outward to the sphenoidal border of the malar bone. It is bounded in front by the posterior superior border of the superior maxilla and orbital process of the palate bone, and behind by the inferior border of the great wing of the sphenoid bone. It transmits from the brain to the orbit the infraorbital nerve and vessels and branches of nerves from the spheno-maxillary ganglion.

The Malar Foramina are situated within the orbital cavity on the orbital surface of the malar bone. They transmit from the orbital cavity to the cheek and temporal fossa terminal branches of nerves and vessels. The facial opening is that opening formed by the anterior borders of the orbit.

The Nasal Fossæ.

The Nasal Fossæ, two in number, forming the internal nose, are situated on either side of the median line of the face, and extend from the under surface of the anterior portion of the brain-case superiorly to the upper surface of the bones forming the hard palate inferiorly, and from the facial border of the external aperture of the nose anteriorly to the free border of the internal pterygoid plate posteriorly. They are separated by a thin partition of bone, the nasal septum, open on the face by

the anterior apertures, and posteriorly into the pharyngeal space by the posterior nares. There are also several smaller openings leading from the nasal fossæ in other directions.

For convenience of description the nasal fossæ are divided into a roof, a floor, outer walls, and inner walls formed by the septum.

The Inner Walls or Nasal Septum.—These are composed of six bony structures, named in the order of their importance viz.—the perpendicular plate of the ethmoid, the vomer, the crest of the superior maxillary and palate bones, the rostrum of the sphenoid bone, and the nasal spine of the frontal bone. These bones do not complete the septum, but have a triangular notch in the anterior portion. In the recent state this is filled by the nasal cartilage.

The nasal septum is rarely perpendicular, but is deflected either to the one side or the other. In skulls with the flat or normal palate the nasal septum is most apt to be perpendicular, but in those having the inverted V-shaped (Λ) palate either the septum must be greatly deflected, or pressure upward upon the vomer will push the perpendicular plate of the ethmoid bone forward, thus causing that external protrusion characteristic of the Roman nose.

The cause of this abnormal formation of one of these structures *pari passu* with that of the other has been ascribed by Prof. Harrison Allen to an inflammatory condition of the walls of the oro-naso-pharyngeal space, frequent in some children, this producing tension of the muscles, thus pressing the lateral portions inward, contracting this space, thereby deforming the roof of the mouth,[1] and changing the natural dome shape to the gable or Λ shape.

The septum of the nose is also occasionally incomplete, and this imperfection is generally situated at the junction of the perpendicular plate of the ethmoid bone with the vomer. It is also occasionally marked by a groove or canal on each side for the passage of the naso-palatine nerve.

The Roof of the nasal fossa is long, narrow, and irregular in outline. It is divided into three portions—anterior, middle, and posterior.

The Anterior Portion is formed by the under surface of the nasal bones and the nasal spine of the frontal bone. It is concave from side to side, and extends inward and upward at an angle of about forty-five degrees.

The Middle Portion is narrow, nearly horizontal in direction, and is composed of the cribriform plate of the ethmoid bone.

The Posterior Portion is the longest of the three, and extends from the posterior extremity of the cribriform plate, obliquely downward and backward, to the free margin of the internal pterygoid plate. It is composed of the body of the sphenoid bone and the alæ of the vomer.

The Floor of the nasal fossa extends from the face anteriorly to the pharyngeal space posteriorly. It is smooth, inclining slightly downward and backward, being concave from side to side. It is composed

[1] It is of great importance to recognize, and early in life guard against, the evil results of the inflammation of the throat in children of a strumous diathesis, since it is liable to produce deformity of these parts and irregularity of arrangement of the teeth.

of that portion of the bony structure of this region which forms the premaxillæ and the palatal processes of the superior maxillæ and horizontal plates of the palate bones.

The External or Lateral Wall is the most extended, uneven, and complicated portion of the nasal fossa. Seven bones enter into the formation on each side—viz. the nasal, superior maxilla, lachrymal, ethmoid, inferior turbinated, and palate bones, and the pterygoid process of the sphenoid bone. To form the outer walls of both sides twelve bones are required—two of the brain-case, the ethmoid and the sphenoid, and all the bones of the face excepting four, the malar, the vomer, and the inferior maxilla. These walls are divided by the projections of the turbinated processes of the ethmoid bone and the inferior turbinated bone into three horizontal compartments, the superior, middle, and inferior.

The Superior Meatus is the shortest and shallowest of the three. It is situated between the superior and inferior turbinated masses of the ethmoid bone, and in the articulated skull between the superior and inferior turbinated bones.

The Middle Meatus is situated between the middle and inferior turbinated bones, and forms two-thirds of the posterior portion of the outer wall of the nasal fossa.

The Inferior Meatus is situated between the inferior turbinated bone and the floor of the nose. It is the longest of the three meati.

The openings into the nasal fossa are numerous, and may be classified as follows:

The Anterior Aperture is that pyriform opening leading from the face into the fossa, and has been previously described.

The Posterior Aperture opens into the pharyngeal space. It is bounded above by the vaginal process of the sphenoid bone and the alæ of the vomer; below by the palatal process of the palate bone; internally by the vomer; and externally by the free border of the internal plate of the pterygoid process of the sphenoid bone.

The Lachrymal Canal opens into the superior portion of the inferior meatus, behind the nasal process of the superior maxilla and external to the inferior turbinated bone. This canal is occupied by the nasal or lachrymal duct, which conveys the lachrymal fluid from the eye into the nose.

The Spheno-palatine Foramen is situated in a line just back of the superior meatus. It is bounded below by the palate bone, above by the sphenoid bone, and opens into the spheno-palatine space. It transmits into the nasal fossa the naso-palatine nerves and vessels.

The Incisor Foramen, or Foramen of Stenson, is situated in the anterior portion of the nasal fossa, near the septum and back of the premaxilla. It opens into the anterior palatine canal on the oral aspect of the hard palate, and transmits the anterior palatine vessels.

The Foramen of Scarpa is situated within the intermaxillary suture, and opens into the anterior palatine canal on the oral aspect of the hard palate. It transmits the naso-palatine nerve.

The Olfactory Apertures are those numerous small openings found in the cribriform plate of the ethmoid bone. They communicate with the brain-case, and transmit the filaments of the olfactory nerves.

The slit-like openings in the anterior portion of the cribriform plate communicate with the brain-case, and transmit the nasal nerve and the vessels which accompany it.

The Openings into Air-cells.—In the dried skull there are generally two openings into the maxillary sinus, but in the recent state there is not often more than one. It is situated about the centre of the middle meatus, and permits the passage of fluid from the antrum into the nasal chambers.

The Infundibulum extends from the superior portion of the middle meatus anteriorly to the outer side of the middle turbinated bone, uniting this meatus with the frontal sinuses and the anterior ethmoidal cells; it allows the fluid from these openings to descend into the nasal chambers.

The other openings into the remaining air-cells have already been fully described under the headings of the bones.

The Cavity of the Mouth.

The Cavity of the Mouth is situated between the two superior maxillary bones above and the inferior maxillary bone and their attached muscles. When the jaws are closed this cavity is paraboloid in shape, opening behind and below. In the recent state the inferior opening is closed by the tongue and mylo-hyoid muscle.

The Roof of the Mouth (Fig. 66), which is formed by the hard palate, is generally arched in front and flattened behind. It is composed of the palatal processes of the two superior maxillary and palate bones.

Fig. 66.

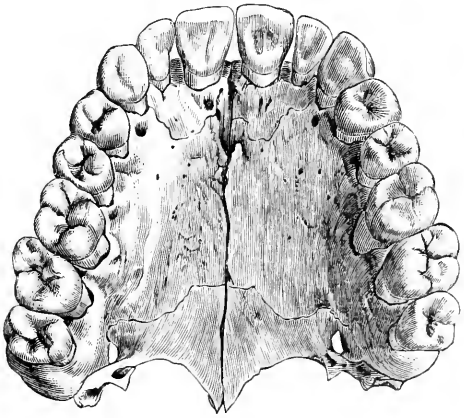

Roof of the Mouth.

The Posterior Border is free, thin, and divided into two portions by the posterior nasal spine. On each side of this spine the border is concave, and terminates laterally in the pyramidal process of the palate bone and the hamular process of the sphenoid bone.

Situated within the palato-maxillary suture, just internal to the tuberosity of the superior maxilla, are the posterior and accessory palatine canals for the transmission of the posterior palatine nerves and vessels.

The surface of the roof of the mouth is perforated by numerous small foramina for the transmission of nutrient vessels to the body of the bone, pitted for the lodgment of the mucous glands, and grooved longitudinally for the accommodation of vessels.

The Floor of the Mouth.—The circumference of the floor of the mouth is formed by the mylo-hyoid ridge. This ridge gives attach-

ment throughout its entire extent to the mylo-hyoid muscle, which, together with the base of the tongue, forms the true floor.

The anterior and two lateral walls of the mouth are formed by the alveolar processes and the teeth of both jaws.

Posteriorly the oral cavity opens into the pharyngeal space.

CARTILAGE.

Cartilage is one of the three groups of connective tissues of the body. It is made up of cells imbedded in a matrix, which yields, on boiling, chondrin, the basement-substance. That this differs from other connective tissue has of late been questioned, and the view that it is a distinct chemical substance now appears to be undergoing a change. By some it is believed to be a mixture of gelatin, mucin, and salts. (See Prudden's *Normal Histology*, p. 53.) Cartilage forms the entire skeleton of many of the cold-blooded (or lower order of) animals, and of others it constitutes a varying proportion. In the highest vertebrates only a small portion of cartilage exists at puberty, though it is found after this period in the covering of the articulating surfaces of bones and connecting the ribs with the sternum; in the rings of the trachea, walls of the bronchi, larynx, and other parts of the air-passages; in the grooves through which muscular tendons glide; and in interarticular discs situated between the articulating surfaces of bones, where a decidedly firm though more yielding structure than bone is required. The early embryonic life of the entire skeleton, with but minor exceptions, is composed of cartilage, in which is gradually deposited calciferous matter; it is then apparently absorbed and replaced by bone-cells or osteoblasts, which first appear at the different points of ossification and develop the entire bony structure. Temporary cartilage is that which gradually develops into bone. Permanent cartilage is that which remains cartilage throughout life, as the interarticular discs that cover the articular extremities of bones, etc.

The principal function of cartilage in the higher vertebrates is its physical property of elasticity. It yields to pressure or to muscular force, but immediately resumes its normal position or shape when such pressure or force is removed.

When placed between articulating extremities, as the proximate surfaces of the vertebræ, the temporo-maxillary articulation, etc. etc., it acts as a cushion, diminishing the force of concussion. In positions where shock would be particularly harmful there is interposed within the joint, in addition to the cartilage covering the articular surfaces of bones, a cartilaginous disc or extra cushion. Were it not for the cartilage placed within the joints situated between the feet and the head, the shock communicated to the brain in the simple act of walking would probably be so great as to absolutely prevent its practice in man.

The cartilages connecting the ribs with the sternum permit the

expansion and contraction of the chest necessary to breathing, and those within the walls of the air-passages prevent closure of the tubes when they are flexed.

Histologists divide cartilage into two parts—the cartilage-cell and the hyaline or intercellular substance or matrix.

Cartilage is also divided into three kinds, according to the character of the matrix—hyaline cartilage, fibro-cartilage, and fibro-elastic cartilage.

Hyaline Cartilage is so named from its resemblance to glass. It is firm, homogeneous, and more or less transparent according to thick-

FIG. 67.

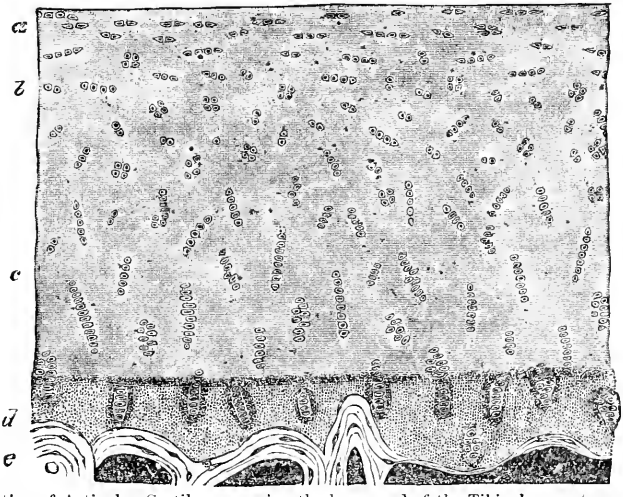

Vertical Section of Articular Cartilage covering the lower end of the Tibia, human (magnified about 30 diameters): *a*, cells and cell-groups flattened conformably with the surface; *b*, cell-groups irregularly arranged; *c*, cell-groups disposed perpendicularly to the surface; *d*, layer of calcified cartilage; *e*, bone.

ness. It is found at the articulating surfaces of all except intermembranous bones (articulating cartilage); at the anterior extremities of the ribs (costo-cartilage); in the wings of the trachea, walls of the

FIG. 68.

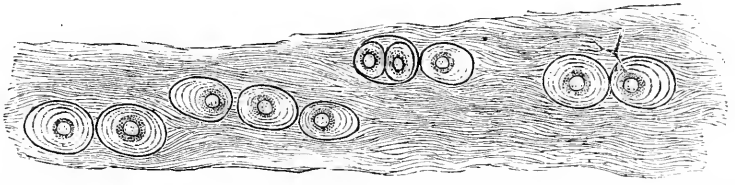

White Fibro-cartilage from an Intervertebral Disc, human (highly magnified). The concentric lines around the cells indicate the limits of deposit of successive capsules. One of the cells has a forked process which extends beyond the hyaline area surrounding the cell, amongst the fibres of the general matrix.

bronchi, and in the septum and lateral cartilages of the nose, etc. etc. The articulating cartilage has cells and cell-groups, which near the surface are flattened (Fig. 67). Late in life the costal cartilages become finely fibrillated and occasionally completely ossified.

Fibro-Cartilage (white) (Fig. 68) receives its name because its matrix is composed of bundles of fibrous connective tissue, the bundles being arranged in layers. Between the lamellæ of these fibrous bundles are rows of flattened, oval, nucleated cells, each cell being surrounded by a delicate capsule. These cells are similar to those found in tendons, though they are not so flat, and are distinguished by their surrounding capsule.

Where fibro-cartilage unites with tendinous tissue, as does the inter-articulating fibro-cartilage of the temporo-maxillary articulation with the tendon of the external pterygoid muscle, the two kinds of cells merge imperceptibly into one another. The sesamoid cartilage, inter-vertebral discs, interarticular cartilage, the interarticular fibro-cartilage of the temporo-maxillary articulation, all are of the fibrous variety.

The Fibro-elastic Cartilage (yellow elastic) is spoken of by some as reticular cartilage, by reason of the arrangement of its fibres. In early life this variety of cartilage is hyaline, but in adult life it becomes permeated with elastic fibres which proceed from the perichondrium inward. It is the most elastic of all cartilage. Its fibres are fine, and so branch and anastomose with each other as to form a dense network, with spherical or oblong spaces or meshes, in which lie nucleated cells of varying sizes surrounded by a zone of hyaline cartilage. This cartilage is found in the epiglottis, in the auditory canals, the cartilage of Wrisberg and Santorini, of the larynx, etc. etc.

FIG. 69.

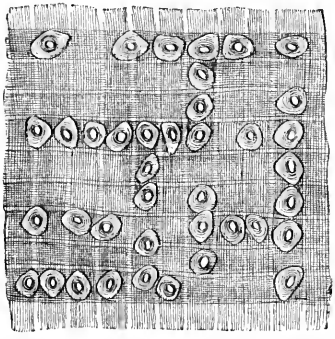

Fibro-cartilage of an Intervertebral Ligament.

Cartilage-cells have one characteristic which distinguishes them from all others—viz. the power of casting around themselves a halo composed of a substance similar to the matrix of hyaline cartilage; this halo or capsule, however, possesses the property of absorbing certain stains which do not affect true hyaline cartilage. It is therefore an independent structure, and forms what is known as the *cartilage lacunæ*, which are in reality lymph-spaces.

These lacunæ are not isolated cavities, but have minute capillary tubes communicating with each other, and finally open into larger tubes which extend to the surface of the cartilage.

Cartilage-cells are spherical or oval-shaped bodies, usually containing one nucleus. Under certain circumstances, however, the shape of the cell may be modified, as will be shown hereafter. They increase by division (Fig. 70). At first the two new cells formed from the original old one are arranged side by side, in close proximity to each other, and are half-moon shape in outline. These cells gradually separate from each other through the increase of the capsular substance between them. Finally, a division takes place in the capsules or lacunæ and the new cells are completed. But one cell usually occupies a lacuna, and during the increase of cells by division each lacuna may contain two, four, six, or eight cells, according to the rapidity of the proliferation.

Cells are often differently arranged in the same kind of cartilage, this depending upon the depth of the cartilage and the connection it has with other tissues. Where cartilage is joined to a synovial membrane and an articulating capsule, the cartilage-cells are more or less branched, and pass insensibly into the branched connective-tissue cells of the membrane. In the hyaline cartilage of the fœtus are many spindle or

FIG. 70.

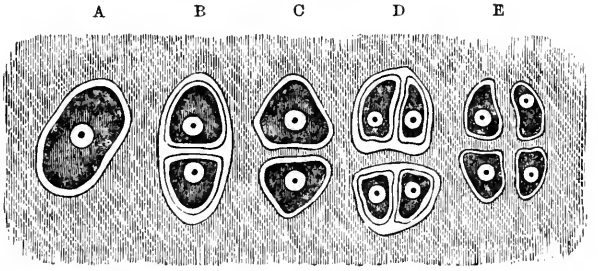

Plan of the Multiplication of Cells of Cartilage: A, cell in its capsule: B, divided into two, each with a capsule; C, primary capsule disappeared, secondary capules coherent with matrix; D, tertiary division; E, secondary capsules disappeared, tertiary coherent with matrix.

branched cells. The cells in the cartilage which separates an apophysis from a diaphysis of long bones are arranged uniformly in vertical rows.

The Perichondrium covers cartilage as periosteum covers bone: it is a vascular, fibro-connective tissue envelope containing a few elastic fibres. It is furnished with blood-vessels, lymphatics, and nerves, and is important, as it furnishes protection to the blood-vessels that supply the cartilage. It covers all cartilage excepting that on the articulating surfaces of bone and in the lines of ossification. Through the blood-vessels of the perichondrium the adjacent cartilage receives nourishment —not by the passage of the blood itself into the cartilage, but from the plasma of the blood in the perichondrium, which permeates the cartilage through numberless minute tubes that open into the lacunæ or capsules of the cartilage by one end, while by the other they open into larger tubes, freely communicating with the perichondrium.

The distance between the substance of the cartilage and its source of pabulum or nourishment accounts for its slow repair after injury. When cartilage has been injured the wound at first fills up with connective tissue. This connective tissue at times remains permanent, but is occasionally transformed into hyaline cartilage. When the lesions are deep the margins of the wound, being situated nearer to the perichondrium, are more likely to heal than the deeper portions.

THE SKIN.

THE skin is the superficial covering of the body, extending over its entire surface and into the openings of its mucous canals to varying depths until it joins their mucous membrane. It is flexible, elastic, and extensible. It is loosely attached to the parts directly beneath,

excepting at such places as the palmar surface of the hand, soles of the feet, face, and the calvarium, where it is attached to the fascia beneath by numerous stout fibrous trabeculæ, the spaces between these bands being filled with cushions of fat.

In the region of the face and neck, as is shown by the action of the muscles of expression, the skin is movable and is under the control of the striated or voluntary muscular structure.

The thickness of the skin varies in different regions of the body. On the back, the palmar and plantar regions it is very thick, while in the inguinal and axillary regions and on the eyelids it is extremely thin. Hairs, either long or short, coarse or fine, are found protruding from the skin throughout almost its entire extent, but they are much more plentiful in some places than in others.

The Tactile Corpuscles are in the papillæ of the skin; they are the principal organs of touch, and are capable of a high degree of cultivation, as is aptly illustrated in the marvellous sensitiveness of many blind persons. By this sense can be detected degrees of heat and cold, hardness and softness, and the direction of the air-current when but gentle. The sensitiveness of the skin varies in different parts of the body, it being most acute at the tips of the fingers and lips.

The skin is also an important excretory organ, and, under certain circumstances, is capable of effecting absorption, its functions in this respect varying in different parts of the body.

In some of the lowest orders of animals there is no integumentary covering, while in others of a somewhat higher scale there is a distinct outer layer of cells performing the functions of the integument. Others are provided with special organs of secretion, as is illustrated in the shell membrane of the mollusca, etc.

In the higher forms of animal life (the vertebrates) the integument can be separated into two great divisions—the epiderm, or cuticle, or scarf skin, and the derm, or corium, or cutis vera—synonymous names for the skin layers that have much complicated its study.

The Blastoderm at a very early stage of its existence divides into two layers, the *epiblastic* and the *hypoblastic;* a third, or *mesoblastic* layer, derived from the contiguous portion of the epiblast and hypoblast, forms, and is situated between them. From the epiblastic or upper layer are formed the epiderm, or cuticle of the skin, and all its appendages, such as the hair, the nails, the enamel of the teeth, the brain, and the nerves. From the mesoblastic or middle layer are formed the true skin, the cartilage, the bones, muscles, the dentine and cementum of the teeth, etc. From the hypoblastic or lower layer are formed the epithelium of the mucous membrane and the various glands of the alimentary canal situated posterior to or below the palato-glossal fold of the mouth, and in front or above the lower third of the rectum.

Fig. 71 is a diagram of the skin divided into different strata or layers. The first natural or embryonic division is formed through its separation into two layers, the upper one, the epiderm, being derived from the epiblastic, and the lower one, the true skin, from the mesoblastic layer, an apparent basement-membrane (hereafter explained) being situated between them.

The Epidermis is that portion of the skin which is separated from the deeper structure in the formation of a blister. It is clearly demonstrated, as it constitutes the thin wall or covering of the blister. It comprises

FIG. 71.

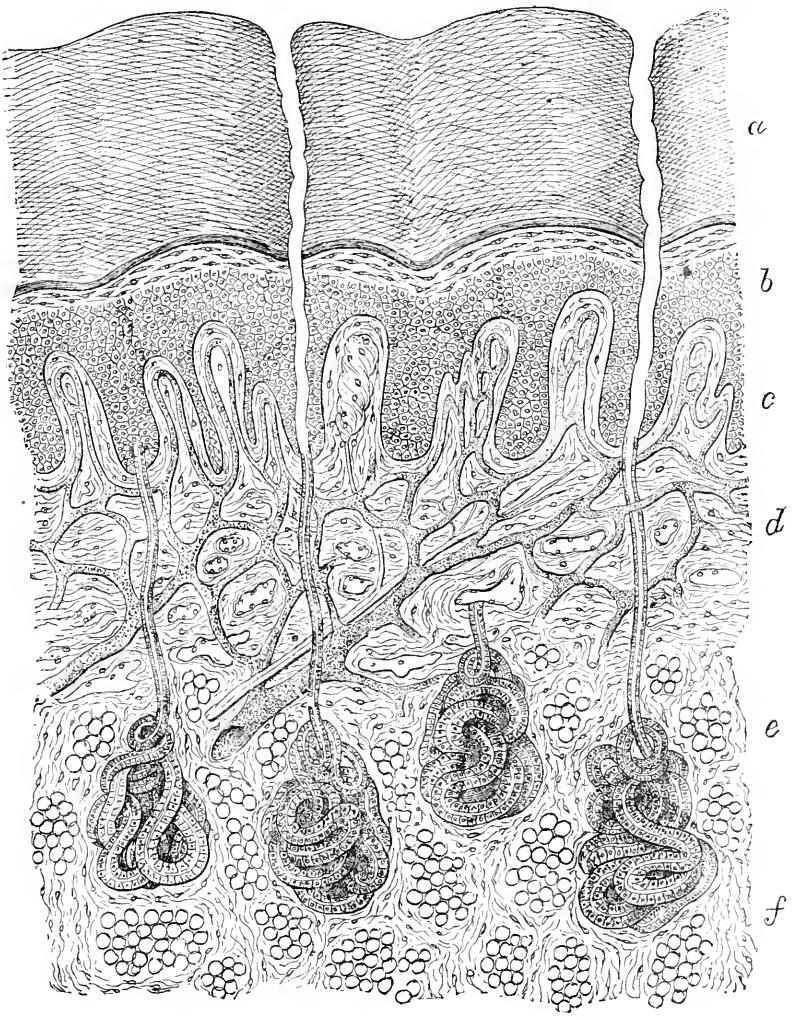

Vertical Section of the Skin of the Thumb, partly diagrammatic: *a*, stratum corneum, or epiblastic portion, traversed by ducts of two glands; *b*, rete mucosum, with prolongations extending between papilla beneath; between *a* and *b* is seen the stratum lucidum, also the basement-membrane; *c*, mesoblastic portion or papillary layer of corium. Near the centre of the figure is seen a nervous papilla; *d*, reticular layer of corium with vascular plexus, nucleated connective tissue, and interspaces; *e*, coils of four sweat-glands; *f*, fat-globules in the meshes of connective tissue. (From Hyde's *Diseases of the Skin.*)

all that portion of the first division above the basement-membrane. Its under surface is uneven, being marked by depressions and elevations corresponding to and fitting over the papillæ of the true derm. Com-

mencing at its foundation or lower portion, it is subdivided as follows: stratum Malpighii or rete mucosum, stratum granulosum, stratum lucidum, and stratum corneum. The continued growth of the epidermis as a whole, with its appendages, the hair, nails, and the enamel of the teeth, depends upon this function of development of the stratum Malpighii.

Stratum Malpighii.—Just above the papillary layer of the corium is a layer of oval cells, each containing nuclei. These cells are constantly undergoing proliferation, and are connected by numerous fine filaments (imbricated cells). As the cells multiply, those which have been previously formed are pushed upward toward the surface, die, and are cast off.

Stratum Granulosum.—Above the stratum Malpighii the cells change their form—become more flattened and possess large and distinct nuclei. The protoplasmic contents of the cells also exhibit numerous granular masses, and from this appearance the layer thus formed receives its name.

Stratum Lucidum.—Above the stratum granulosum the cells flatten out still more, become narrower and homogeneous, and sections of them freely transmit light; hence the name.

Stratum Corneum.—Above the stratum lucidum another change in the cells takes place. At first they appear to swell up, but soon assume a more flattened appearance, the most superficial of them becoming structurally horny scales are constantly undergoing desquamation.

The True Skin, Derm, Corium, or Cutis Vera is a tough, flexible, elastic, highly vascular, and nervous tissue, containing lymphatic vessels. It is developed from the mesoblastic or middle layer of the blastoderm.

Structure.—The true derm is principally composed of a reticulum of white fibrous connective tissue largely interwoven with elastic fibres. There are also found in it many independent lymphoid cells and a complicated network formed by an intimate association of the processes of the connective-tissue corpuscles. Unstriated or involuntary muscular fibres are found in the vicinity of the nipples and their alveoli, etc., and striated or voluntary muscular fibres are to be met with in the region of the face, head, neck, and portions of the hand.

The Papillæ.

The true skin is divided into two portions, upper and lower, known as the papillary and reticular (or vascular) layers. These receive their name from their anatomical formations. The papillæ of these layers are considered to be the organs of touch, as they are found more highly developed at those points where the sense of touch is most delicate. They act by extending the surface for the production of cuticular tissue, and hence are found large and numerous under the nails. The pulps of the teeth and the papillæ of the hairs are developed from them. They are conical or finger-like in shape, and are either simple or compound, sometimes dividing near their apices into two or more projections. They vary both in shape and size in different

parts of the body, being largest on the palmar surfaces of the hands and the soles of the feet. These papillæ of the true derm fit into corresponding depressions of the epiderm. As the superior surface of the papillary layer is approached the fibrous network of the connective and the elastic tissue becomes finer and finer, the fibres approximating more closely until they appear to form a homogeneous layer known as the *basement membrane* of Todd and Bowman.

The fibres toward the inferior surface of the papillary layer are coarser and more loosely interwoven than they are at the superior surface, and finally pass into the subareolar tissue.

The Reticular Layer.—The line of demarcation between the upper and the lower layers of the true skin is not clear and distinct, but one part gradually merges into the other, the principal point of difference being in the arrangement of the fibrous network. Descending from above, the fibres become fewer and are situated farther apart, until a coarse network is formed, which is finally lost in the subcutaneous connective tissue. At this point these bands form a loose reticulum, the meshes of which are generally filled with an abundance of fat.

The quantity of fat within the reticulum varies considerably in different regions of the body, being large about the mammary glands and in the palms of the hands and the soles of the feet, while in the eyelids and about the ears but little if any is found.

The Blood-vessels of the Skin ascend through the subcutaneous connective tissue, and divide as they pass through the true derm toward the surface. They give off branches which pass to the fat-clusters, sweat-glands, hair-follicles, and the corium. As they approach the papillary layer they form a fine capillary network of anastomosing vessels, the papillæ being supplied with capillary vessels which pass through their central portion, furnishing an abundant supply of blood. Veins accompany the arteries in their ramifications, but no blood-vessels pass into the epiderm.

The Lymphatics are distributed throughout the entire surface of the skin, except the epidermal layer, though not equally in all parts, being larger and more abundant around the nipples and on the scrotum. They are arranged in two strata, with anastomosing vessels between them. The superior stratum is situated just below the network of capillary blood-vessels, passing up into some of the papillæ in the palms of the hands and soles of the feet. Valves are found in the larger vessels of the corium, but not in the smaller ones or in those of the superior layer. The hair-follicles and the glands of the skin have special plexuses of lymphatics as well as of blood-vessels.

The lymphatics of the skin orginate in the spaces between the cells, as they do in other kinds of connective tissue, and have a linear arrangement between the bundles of fibres.

The Nerves.—As the skin is the organ of the body possessing the special function of touch-perception, it is but natural to expect many nerves to be distributed over its surface; and as the degree of sensibility varies, it is also to be supposed that the nerves are not equally distributed. The principal branches pass through the subcutaneous connective tissue, divide at the corium, and run in various directions,

forming plexuses of fine nerve-fibres near the surface. From the most superficial of these plexuses, or those situated immediately below the epidermis,[1] fine non-medullated nerve-fibres pass upward between the cylindrical cells of the stratum Malpighii of the cuticle, where they terminate. The nerves are abundantly distributed to parts that are covered with hair, especially where such hair is used as a sentient organ, as is the case with the whiskers of the cat. The termination of many of the nerves will be found in the tactile and Pacinian corpuscles.

The Tactile or Touch Corpuscles (Figs. 72, 73) are usually oval in

FIG. 72.

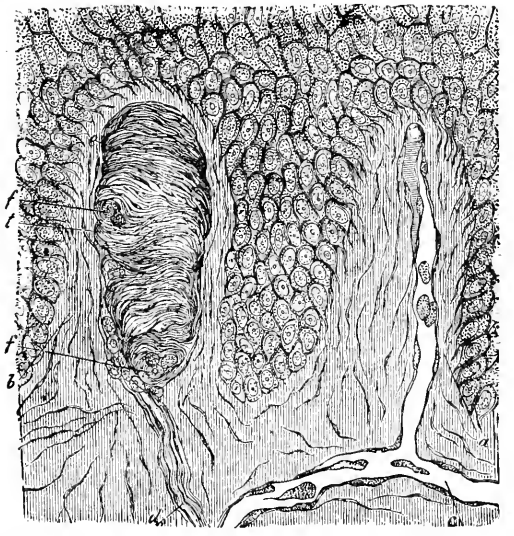

Section of Skin, showing two Papillæ and deeper layers of Epidermis: *a*, vascular papilla with capillary loop passing from subjacent vessel, *c*; *b*, nerve-papilla with tactile corpuscle, *t* (the latter exhibits transverse fibrous markings); *d*, nerve passing up to it; *f*, *f*, sections of spirally winding nerve-fibres.

FIG. 73.

Tactile Corpuscle within a papilla of the skin of the hand, stained with chloride of gold. The convolutions of the nerve-fibres within the corpuscle are seen. *Ep.* epidermis.

shape—they may be straight or slightly folded—and are situated within certain of the papillæ of the corium; they are attached to medullary nerve-fibres. These papillæ contain no blood-vessels, and are called tactile or sensory, in contradistinction to the vascular papillæ which contain the blood-vessels. Their number varies according to location, they being most numerous where the touch is most acute, as on the inner or palmar side of the last phalanges of the fingers.

The Pacinian Corpuscles are oval or olive-shaped bodies, receiving the terminal ends of cutaneous nerves. In the skin they are situated in the subcutaneous connective tissue, and like the touch-corpuscles are most abundant on the palms of the hands, soles of the feet, the fingers and toes, and more especially on their distal phalanges.

Pigment.—The color of the skin depends upon the deposit of pigment-granules. This is generally found in the lowest stratum of the

[1] The lymphatics do not pass into the epiderm, and that is the reason normal skin is not an absorbing organ.

Malpighian layer, and appears to fade away gradually as it approaches the surface. In the normal condition it is never found in the corium. The color of the skin will depend upon the quantity of this pigmentary deposit, varying from white to black according to race, and differing in shade in the same race, as is illustrated in the blonde and brunette.

Appendages of the Skin.

In man these are the hair, teeth, nails, and sebaceous glands. The teeth will be described elsewhere in this work.

The Hair, like the nails and the enamel of the teeth, is a peculiar modification of the epidermis. It is developed from the epiblastic or upper layer of the blastoderm, and consists necessarily of the same structure, and is governed by the same general laws of development, growth, and sustenance, as the epidermis. It is found on nearly every part of the surface of the body, the exceptional parts being the soles of the feet, the palms of the hands, the eyelids, the inner surface of the prepuce, glans penis, and the last phalanges of the fingers and toes.

Its color, length, and thickness vary according to the part of the body on which it is found, and are influenced by race and temperament. The color, like that of the skin, depends upon the quantity of pigment deposited within its structure, absolutely white hair having none. Oftentimes the color varies, not alone in different individuals, but in the same person, as the hair of the face is seldom of the same shade as that on the head.

The length of the hair varies from that which does not extend beyond the opening of the follicle to the longest grown upon the head. Its thickness also varies considerably, that covering the head being finer than that found on the face and on the borders of the eyelids, etc. etc. Straight hair is coarser, and its transverse sections are more circular, than curly hair, which is generally fine and oval in transverse section.

Anatomically, the hair is divided into a root, shaft, and point.

The Follicle is formed by the dipping down of the epiderm into the tissue below (Fig. 72).

The Root of the hair is that portion which is in the hair-follicle of the skin.

The Bulb is the expansion of the extremity of the root.

The Shaft is that portion of the hair above the mouth of the follicle. In straight hair its transverse section is almost cylindrical; in curly hair it is compressed or oval. It is composed of compact tissue, which gradually tapers as it approaches the end.

Histologically, the hair is also divided into three portions—the cuti-

Fig. 74.

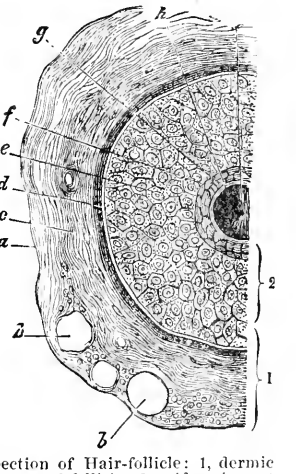

Section of Hair-follicle: 1, dermic coat of follicle; 2, epidermic coat or root-sheath; *a*, outer layer of dermic coat, with blood-vessels, *b*, *b*, cut across; *c*, middle layer; *d*, inner or hyaline layer; *e*, outer root-sheath; *f*, *g*, inner root-sheath; *h*, cuticle of root-sheath; *i*, hair.

cle, fibrous (cortical), and medullary portions, though the latter is not always present.

The Cuticle is the outer or investing membrane of the hair, firmly binding its bundles of fibres together. Under the microscope this membrane is seen to be composed of fine imbricated scales. The upper edges of these project and form fine transverse wave-like lines. They are without nuclei, and are analogous to the upper cells of the corneous layer of the epidermis, and perform a like function for the hair.

The Fibrous or Cortical Portion.—The bulk of the hair is made up of this substance; it is translucent, and is arranged in longitudinal

FIG. 75.

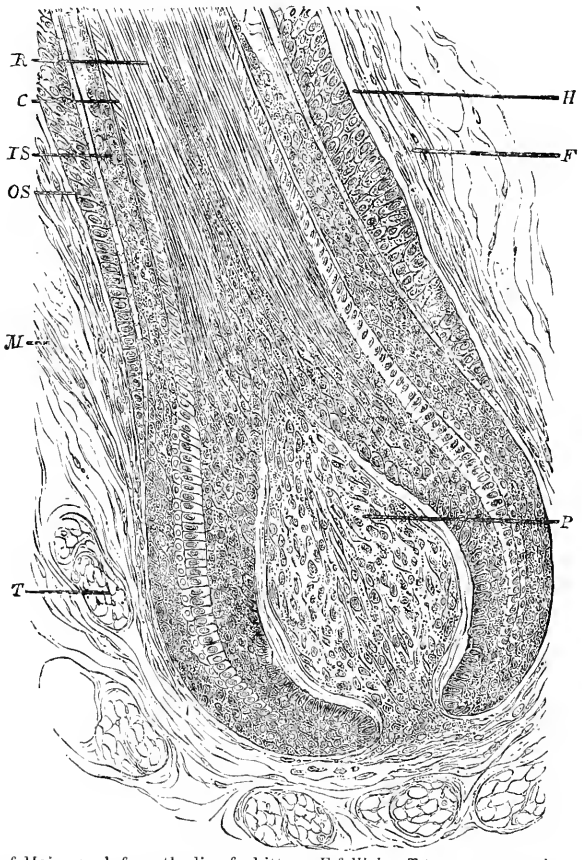

Lower portion of Hair-pouch from the lip of a kitten: *F*, follicle; *T*, transverse sections of connective-tissue bundles of derma; *M*, arrector pili muscle; *IS*, inner root-sheath; *OS*, outer root-sheath; *P*, papilla; *C*, cuticle; *R*, root of hair; *H*, hyaline or so-called structureless membrane (magnified 500 diameters).

bundles containing oblong patches of pigment-granules and other coloring matter of less intensity.

The fibres which make up the bundles composing this portion are subdivided into flattened fusiform cells with slender elongated nuclei, which are distinctly visible when certain reagents are used. There are

also spaces between these cells containing air which are called hair-lacunæ; these are more abundant in white hair than in colored. Examined by transmitted light, these spaces are dark, but with reflected light they are a brilliant white.

The Medulla or Pith is usually absent in the fine hairs covering the surface of the body, and is not commonly met with in those covering the scalp. It is also lacking in the hair of children under five years of age. It is met with, however, in the short thick hairs. When present, it is found in the centre of the shaft and is lost before reaching the point. It is composed of soft cells, oblong or rectangular in shape, containing minute particles, some of which appear like fat-granules. There are also air-spaces between the cells.

Under the microscope, with transmitted light, the medulla appears to be darker than the fibrous substance of the hair. When reflected light is used, however, it appears white. This change in appearance is due to the lacunæ found within its substance.

The Hair-follicles contain the hair, and are generally found in groups of three or four, more rarely two; very rarely are they single. With few excepted places they are found all over the entire integument. This follicle is an elongated pear-shaped sac passing obliquely down through the different strata of the skin into the subcutaneous tissue, in which fat is found. The follicles of small hairs do not pass so deeply as those of larger ones, and those which accommodate woolly hairs are curved at the bottom, the ends often curving so far as to extend upward.

The mouth of the follicle is slightly funnel-shaped, the lower portion being enlarged to accommodate the bulb or root of the hair. The follicle is also invaginated over a pear-shaped papilla. It is formed by the skin dipping down into the tissue below.

The coats of the follicle are separated into two divisions, dermic and epidermic. These are again subdivided, the dermic into three layers—external, middle, and internal; and the epidermic into an outer and an inner root-sheath.

The External Layer is formed in a manner precisely similar to the lower layer of the corium, with which it is continuous above. It, in a measure, determines the form of the follicle, and in composition is highly vascular and supplied with nerve-filaments. No elastic tissue enters into its structure. The bundles composing this layer are laid longitudinally with the axis of the follicle.

The Middle Layer is very similar in its structure and arrangement of blood-vessels to the external layer of the corium. It is thinner, and composed of transverse connective-tissue fibres with elongated nuclei. Nerves have not been found in this layer.

The Internal Layer, or "glass membrane," corresponds in structure to the basement-membrane of Todd and Bowman. It is a transparent, homogeneous stratum, the inner surface of which is raised, the outer surface being smooth.

The Epidermic or Cuticular Coat is that portion of the follicle derived exclusively from the epidermis, and is continuous with it. It adheres closely to the root of the hair, and is generally removed with the root in extracting the hair. For this reason it is called the root-sheath,

and is composed of two layers, called the external and the internal root-sheaths.

The External Root-sheath is that portion of the hair-follicle which is derived from the lowest or Malpighian stratum of the cuticle. It is composed of several layers of polygonal cells with nuclei, as far as the hair-bulb, where it is composed of but one row of cells, which become continuous with the hair-bulb at its lowest portion.

The external root-sheath contains pigment-granules in the dark races, and Langerhaus claims to have found in it nerve-filaments similar to those found in the Malpighian layer of the skin.

The Internal Root-sheath is derived from the corneous layer of the epidermis, but is not connected with it. It commences just below the orifices of the sebaceous glands, passing downward to the bottom of the follicle, where it joins the layer of columnar cells covering the hair-bulb.

This sheath is composed of two layers—an outermost, or layer of Henle, and an innermost, or layer of Huxley. These two layers commence as one just below the orifices of the sebaceous glands. As they pass downward they again unite and form one layer of large polygonal nucleated cells having no spaces between them, and finally become continuous with the hair-bulb.

The Outermost, or Layer of Henle, is composed of elongated, flattened, non-nucleated cells, generally having spaces between them.

The Innermost, or Layer of Huxley, is composed of flattened, nucleated scales two or three deep. The layer thus made forms the internal lining of the follicle below the orifices of the sebaceous glands. The innermost scales are imbricated, lapping over the superimposed layer of cuticular imbricated scales of the hair, and thus serve to hold the hair in position.

The Papilla of the Hair is a conical-shaped eminence in every respect similar to the papilla of the skin—in fact, is a papilla of the skin carried to a lower level than those entering into this structure, and being continuous with the dermic layer of the follicle. It is highly vascular, and is supplied with nerve-filaments. Its blood-vessels supply the nourishment for its development and growth.

The bulbous expansion at the root of the hair is soft, and consists of polyhedral epidermic cells united together by a cement-like substance. These cells are continuous at the circumference of the bulb with the outer root-sheath, from which they were originally derived. The base of the bulb is attached to the bottom of the follicle, where the latter is invaginated over the papilla, there being a depression in the base for this purpose. The circumference of the base is attached to and continuous with the lining membrane of the hair-follicle.

Extending over the surface of the papilla (above the basement-membrane) is a special layer of short oval cells (hair-builders) which are analogous to all similar building cells, such as those of the epidermis, the nails, and the enamel of the teeth. The formation of these structures is governed by one general law: that is, the special layer of cells at the base and on the circumference of the papilla are constantly in an active state of proliferation. New cells are thus formed which push the older

ones upward into the bulb, where a special action takes place, some going to form hair, others nails, etc. etc. They form the hair: the great bulk of the cells become elongated and spindle-shaped, and form what has been described as the fibrous substance of the shaft.

The Sudoriferous or Sweat Glands (Fig. 76) are distributed over nearly the entire surface of the body. They are most numerous in parts not supplied by hair, though they are plentiful in parts where the growth of hair is abundant, their ducts occasionally emptying into the hair-follicle. Krause has estimated the entire number distributed over the body to be 2,381,248, or from 400 to 600 to the square inch on the lower limbs, back of the neck, and trunk, where they are fewest, while in the palms of the hands and on the soles of the feet they are found in their greatest number, and reach 2800 to the square inch.

The length of the sudoriferous gland, together with its tube, has been estimated to be about a quarter of an inch. This gives the human body, containing as it does 2,381,248 such glands, about fifty thousand feet, or over nine miles, of perspiratory tubing.

The size of the sudoriferous glands varies in different parts of the body, those in the axilla being the largest. Here they have been found about a sixth of an inch in diameter, though their average diameter in this region is from one-thirty-sixth to one-twelfth of an inch, the average over the entire body being one-seventieth of an inch.

FIG. 76.

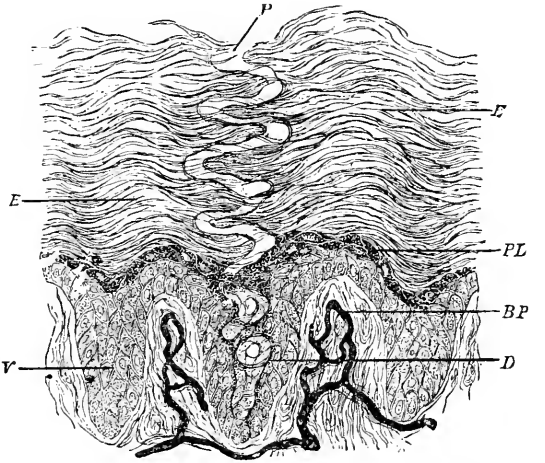

Duct of the Sweat-gland within the epithelial layers of the skin: *BP*, papilla with injected blood-vessels; *V*, valley between two papillæ; *D*, duct in the rete mucosum; *E, E*, epidermal layer; *I L*, coarsely granulated epithelia deeply stained with carmine; *P*, duct with corkscrew windings in the epidermal layer (magnified 200 diameters).

These glands eliminate a large proportion of the aqueous and gaseous matter from the body. Under ordinary temperatures, in the absence of too severe physical exercise, perspiration goes on imperceptibly, but in warmth and the stimulus of vigorous bodily exercise there is a perceptible and more or less profuse flow.

These glands are situated in the lowest stratum of the corium, and

are found at various depths in the subcutaneous connective tissue, surrounded by adipose tissue.

They are tubular, with a coiled, rounded, or flattened extremity, the duct through the epiderm resembling a spiral screw. This duct ascends vertically through the true skin and cuticle, terminating in an enlarged pore or aperture (Fig. 76). Occasionally these glands are formed of two tubes coiled around each other. When so formed the tubes unite at the superior extremity of the gland and form one duct.

Both the duct and the gland proper are invested with connective tissue similar to and continuous with the corium. Situated within this tissue, which forms the outer portion of the tube, is a thin membrane which traverses the gland and the duct as far as the epidermis, and is analogous to, and continuous with, the basement-membrane of the skin. That portion of the tube above this basement-membrane is epidermic in structure, while the coiled portion, or the true secreting gland, is lined by a single layer of cuboidal and polyhedral epithelium (Fig. 77), with nuclei, and often containing pigment-granules. Between these cells of the basement-membrane is a layer of non-striated muscular fibres arranged longitudinally. These fibres are not found in the duct, which coils several times before leaving the gland.

Fig. 77.

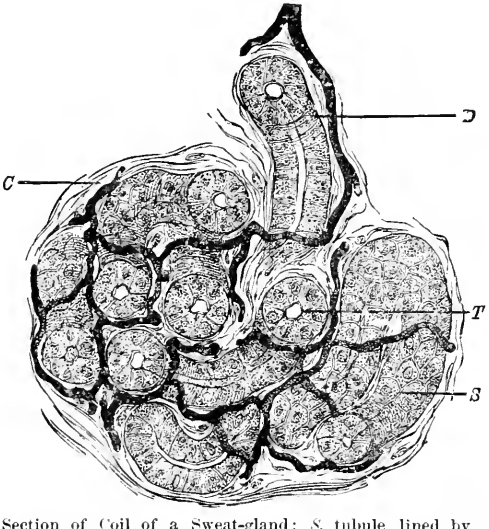

Section of Coil of a Sweat-gland: *S*, tubule lined by cuboidal epithelia; *T*, central calibre of the tubule; *D*, the beginning of the duct; *C*, connective tissue with injected blood-vessels (magnified 500 diameters).

The duct proper is lined by an extremely fine cuticular membrane. Between this lining and the basement-membrane are situated two or three layers of epithelial cells. The epithelium within the tube forming both the gland and the duct is continuous with the epidermis.

The Ceruminous Glands found within the external auditory meatus are so similar to the sudoriferous glands in structure and mode of development that they have been classed as of that variety.

Sweat-glands are surrounded by numerous blood-vessels.

The Sebaceous Glands belong to the racemose variety. They are distributed over almost the entire surface of the body, with the exception of the palms of the hands, soles of the feet, and the backs of the last phalanges of the fingers and toes. They are situated within the corium of the skin, and are usually connected with the hair-follicle by two ducts which empty into it a little below its mouth. These glands do not pass into the subcutaneous tissue.

The number and size of these glands connected with each follicle do not depend upon the calibre of the hair, for some of the finest hairs found upon the surface of the body have as many as six sebaceous glands emptying into their follicles. Occasionally the gland has its outlet upon the surface of the skin.

The largest of this variety of glands are found in connection with the eyelashes, within the eyelid, and have received the name of Meibomian glands. Sebaceous or cystic tumors, which sometimes appear on the external surface of the head and in the eyelids, are caused by the clogging of the orifices of these glands while active secretion goes on within. The secretion of these glands on the face often becomes inspissated, especially in the region of the alæ nasi.

Sebaceous glands differ in shape, though their general outline is pyriform, the duct of the gland corresponding to the stem of the pear.

In structure they are lobular (Fig. 78), each lobule consisting of a

FIG. 78.

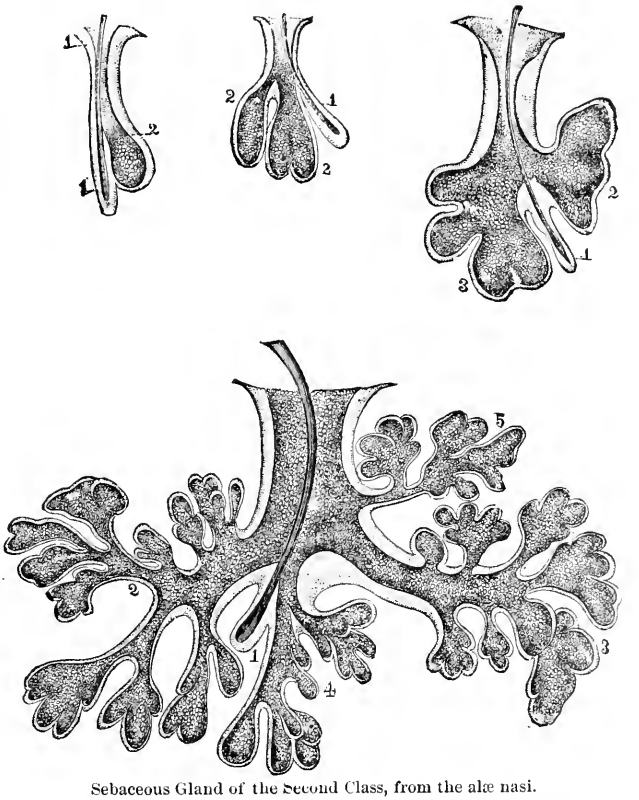

Sebaceous Gland of the Second Class, from the alæ nasi.

cluster of spherical secreting saccules. The secretion of each saccule is collected into the principal duct of the lobule, and passes into the main duct of the gland, which usually has its outlet a little below the mouth of the hair-follicle.

The outer surface of the saccules is formed by a basement-membrane which is continuous with the basement-membrane of the skin. Next to this membrane, within the gland, is situated a layer of polyhedral granular epithelial cells, each containing a spherical or an oval nucleus. Resting upon this layer and filling the saccule is a layer of large polyhedral cells with spherical nuclei. The cells are largest near the centre of the saccule, while toward its outlet they become atrophied.

The duct of the gland is a continuation of the outer root-sheath. The cuboidal cells of the gland undergo active proliferation; as this process continues the older cells are pushed toward the duct until they reach the surface of the skin, where they form sebaceous matter.

AREOLAR TISSUE, TENDONS, AND MUSCLES.

The Areolar Tissue is the third variety of connective tissue, bone and cartilage representing the other two. It is a soft filamentous substance, with considerable tenacity and elasticity. It is found immediately below the skin, extending between and forming the sheaths of the muscles. It comprises the subcutaneous or superficial fascia and the reflections into deeper planes known as deep fascia, and connects mucous and serous membranes with the parts which they line or invest, in which position it is known as *submucous* or *subserous* areolar tissue. It likewise both separates and encloses all muscles, forming envelopes for them. It forms the sheaths around the blood-vessels and deep-seated parts or organs, in which position it is designated *intermediate areolar tissue*, and if it comes in immediate contact with the part it is called *investing areolar tissue*. In a word, it is found throughout the various organs of the body, penetrating between the muscular bundles, the lobes and lobules of the compound glands, following the vessels and nerves to their finest divisions. It is continuous with itself, and can be traced from one part of the body to another without interruption. Hypodermic injections intended to enter the general circulation are thrown within this tissue. It serves as the storehouse of fat. Dropsical fluids, by reason of the sieve-like arrangement of its meshes, may be diffused through it from one part of the body to another. It allows the skin to move freely over adjoining parts, and assists it in reassuming the normal position after having been drawn in any one direction.

Fascia.

Fascia, one of the divisions of areolar tissue, is composed of a multitude of soft, fine, and somewhat elastic fibres, transparent in appearance, but intermixed with numerous delicate colorless membranous laminæ. These fibres and laminæ are interwoven in every imaginable direction, forming net-like meshes of different sizes. These interspaces communicate freely with each other, many of them being filled with fat, which

is enclosed in its own vesicle. In health this tissue is moistened and lubricated by a transparent fluid of the nature of lymph.

Fascia is divided into two varieties, superficial and deep.

Superficial or Subcutaneous Fascia connects the skin with the deeper and firmer parts beneath by numerous delicate bands or trabeculæ; its structure is more open than that of the deep fascia, and its bands run more irregularly. It varies in thickness and density in different parts, and is found distributed throughout nearly the entire surface of the body. Within the meshes of this tissue is found the subcutaneous fat, which forms a blanket of adipose tissue and serves to keep the body warm, fat being a poor conductor of heat. No adipose tissue is found upon the eyelids, the penis, and the scrotum. In animals, such as the cow, the horse, and the dog, the superficial fascia contains within its structure a muscle known as the panniculus carnosus, which extends over almost the entire body. In man a muscle corresponding to this, known as the platysma myoides, is found in the region of the head and neck.

In some portions of the body the superficial fascia is separable into several layers; this is especially true in the region of the groin. In health the superficial fascia often becomes loaded with fat, this tissue in corpulent people being much thicker. The opposite is the case with emaciated people, the superficial fascia becoming extremely thin; its fibrous bands are closely approximated, and the skin appears wrinkled or in folds. Also on the soles of the feet and in the palms of the hands it is very thin and closely attached to the skin. It is generally divided into two or more layers, between which are the glands, and through which pass the superficial blood-vessels, nerves, and lymphatics, these structures having free communication with each other.

The Deep or Aponeurotic Fascia is immediately beneath the superficial fascia. The course of its fibres is not so irregular as that of the superficial fascia, inclining more to an arrangement in layers or bands, with much less adipose tissue confined within its meshes; this formation makes it denser and stronger than the superficial fascia.

Like the superficial, the deep fascia extends over nearly the entire surface of the body, forming an envelope which holds the muscles to their shape and in their proper position. Numerous septa are given off from it which dip down between the muscles, dividing and enclosing their bands, subdividing and enclosing their fibres, and forming a sheath which enwraps the vessels and nerves wherever met. It encloses the tendinous structures in the same manner as the muscular. That portion of the fascia which invests a tendon is called its *theca* or *vagina*.

This fascia also assists in forming intermuscular connections and septa, as those between the two bellies of the digastric and the occipito-frontalis muscle. When the fascia is broad and well defined it is called an aponeurosis. The deep fascia, in different forms, serves to attach muscles and tendons to osseous and other structures, and throws off stout fibrous bands which form various ligaments, such as those surrounding the joints, the annular and the bicipital, the palmar and the plantar fascia, etc.

The deep fascia likewise forms pulley-like apertures through which

pass the tendons of muscles, good illustrations of these being found in the trochlear of the superior oblique muscle of the eye and the pulley for the passage of the intermuscular tendon of the digastric muscle.

A thorough knowledge of this fascia will materially assist in the diagnosis of deep tumors and in prognosticating the direction, course, or route likely to be taken by morbid fluids and growths from one point to another.

Fascia of the Neck, Face, and Head.—The superficial fascia of the face and anterior portion of the neck is so slightly developed, and so intimately blended with the adjoining parts, that it is not recognized as a separate tissue. Its thickness varies inversely to the development of the platysma myoides and facial muscles, the one seeming to take the place of the other. That portion of the fascia of the head situated between the aponeurosis of the occipito-frontalis muscle and the integument is dense and firm, and by its fibres unites the skin, the fascia, and the aponeurosis closely together. This union is so intimate that the structures are difficult to separate in dissection. Between the layers of the fascia as it extends over the temporal aponeurosis are situated the muscles which move the external ear, as well as the superficial temporal vessels and nerves. It is continuous behind with the superficial fascia of the back part of the neck.

The Deep Cervical Fascia anteriorly is a dense structure, having a somewhat complex arrangement, and is of great importance from a surgical point of view: it limits to a certain degree the growth of cervical tumors and abscesses and modifies their direction and their extent. Deep-seated abscesses often follow the course of the fascia, though occasionally these as well as tumors penetrate or stretch this membrane in their growth and adopt a course of their own. The deep cervical fascia is divided into two portions, superficial and deep, the superficial forming a complete covering for the neck, enclosing every structure belonging to it except the skin, the superficial fascia, the platysma myoides muscle, and some superficial veins and nerves. In the anterior portion of the neck it passes forward from the upper surface of the trapezius muscle as it passes under the platysma to the posterior border of the sterno-cleido-mastoid muscle, where it divides into two lamellæ—one, the superficial, passing over, and the other, the deep, passing under, the muscle. At the internal border of the sterno-cleido-mastoideus it again reunites, thus forming a sheath for the entire muscle: from this point it passes forward to the median line and joins its fellow of the opposite side. Its attachment above anteriorly commences at the symphysis of the lower jaw, passing backward along the base of the bone to the parotid region, where it divides into two laminæ, the deep layer passing beneath the parotid gland to be inserted into the base of the skull. The stylo-maxillary ligament is developed from this leaflet of fascia. The upper layer passes over the parotid gland and masseter muscle, forming their upper covering. Laterally, above, the fascia is attached to the zygomatic arch, from which it extends backward along the zygoma to the posterior root, thence to the mastoid process of the temporal bone and the superior curved line of the occipital bone, to which it is also attached. The inferior attachment of this fascia is to the clavicle, near which it is pierced for the passage of the external jugular vein on its

way from the neck to its deeper relations. In the median line in front the fascia is also attached to the hyoid bone.

Below the thyroid body the deep fascia divides into two layers, the upper and thinner going to the outer and upper portion of the sternum, to which and the interclavicular ligament it is attached, while the lower layer is attached to the inner and upper portion of the sternum. Both layers are superficial to the sterno-hyoid muscles. The space between the layers of fascia extends laterally until it encloses the sternal heads of the sterno-cleido-mastoid muscles. The anterior jugular vein passes through this interfascial space, which contains loose connective tissue and fat, also sometimes a small lymphatic gland. Thus the upper portion of the deep fascia of the anterior part of the neck covers in all that portion known as *the surgical square of the neck*, and externally offers a barrier to the extension of abscesses and growths from the deeper parts toward the surface, which causes them to burrow more deeply. Abscesses forming exterior to this fascia rarely if ever burrow.

(*a*) *The Deep Portion of the Cervical Fascia.*—Near the anterior margin of the sterno-cleido-mastoid muscle a process is given off from the superficial layer of the deep fascia which descends behind that muscle and is associated with the depressors of the hyoid muscular system. It invests the thyroid body and the front of the trachea, spreads out in front of the large vessels of the neck, and passes into the thorax as far as the pericardium. It is supposed to assist in suspending the heart.

(*b*) *The Prevertebral Fascia* is a layer of the deep fascia which, being attached to the base of the skull, descends on the prevertebral muscles into the thorax, separating them from the pharynx and œsophagus. Laterally, it becomes continuous with, and forms the back portion of, the carotid sheath, from which it extends outward and downward over the scaleni muscles, the brachial plexus of nerves and subclavian vessels, which it accompanies beneath the clavicle into the axilla, where it forms the axillary sheath, and becomes connected with the under surface of the costo-coracoid membrane.

(*c*) *The Carotid Sheath.*—The upper portion of this sheath is formed from the fascia described as *a*, while the under portion is derived from that described as *b*. This sheath forms a complete covering to the carotid artery, the internal jugular vein, and the pneumogastric nerve. A thin fibrous septum is interposed between the artery and vein, thus forming a separate sheath for each.

(*d*) *The Omo-hyoid Fascia*, which encloses the lower belly of the muscle of the same name, is a strong fascia which passes over the muscle extending down to the first rib. It is from this layer of fascia that the band binding down the intermediate tendon of the omo-hyoid muscle is obtained.

(*e*) *The Submaxillary Fascia* consists of two triangular layers of the deep fascia which enclose a space containing the submaxillary salivary and lymphatic glands; the fascia is attached below to the intermediate tendon of the digastric muscles; the outer layer passes upward to be attached to the body of the lower jaw; the other layer passes inward to be connected with the fascia covering the mylo-hyoid, the hyo-glossus, and the stylo-glossus muscles; surgically speaking, it is attached to the

mylo-hyoid ridge of the lower jaw, the outer sheaths of these muscles being a continuation of this fascia.

A study of the arrangement and attachments of the fascia described above will show that abscesses forming in certain regions or between certain fascia can burrow into other regions. For instance, an abscess forming between *a* and *b* would be likely to burrow toward the mediastinum, or an abscess immediately in front of the spine and beneath the fascia *b* would probably pass downward to the posterior mediastinum, or laterally toward the posterior triangle, or even into the axilla, etc.

The Deep Fascia of the head is divided into three well-defined portions: (*a*) the occipito-frontalis aponeurosis, (*b*) the right, and (*c*) the left temporal fascia. The first extends between the occipital and frontalis muscles, and is attached laterally to the temporal ridge. The temporal fasciæ extend over the temporal muscles, being attached above to the temporal ridges and below to the zygomas.

Abscesses forming under the occipito-frontalis aponeurosis generally burrow backward to a V-shaped interspace near the external occipital protuberance, while those beneath the temporal fascia will burrow downward under the zygomas into the zygomatic fossæ.

The Deep Fascia of the Face, like the superficial, is indistinctly developed. Its place, however, is supplied by an abundant quantity of areolar connective tissue distributed through, and intricately associated with, the muscular tissue, though it does not form a distinct covering or fascia for the face, nor is it developed sufficiently to compose sheaths to the muscles. It is lax, and readily allows the diffusion of infiltrations, thus accounting for the sudden and marked swelling of the face during certain inflammatory affections.

This areolar tissue holds within itself a quantity of cushion-like masses of connective tissue which are prominent in the following localities: the hollow of the cheek; between the zygomatic and buccinator muscles; at the lower margin of the orbit, particularly where the orbicularis palpebrarum overlaps the elevators of the upper lip; beneath the muscles elevating the upper lip above the oral angle; at the groove where the facial artery passes over the inferior maxillary bone; and beneath the depressors of the lower lip.

As the skin of the face is thin and vascular, scars from plastic operations and other causes are comparatively inconspicuous. Prof. Allen in his work on *Human Anatomy* observes that a very different result follows extensive cicatrization of the deeper parts: here the connective tissue is abundantly present, and, as seen after ulceration from mercurial sore mouth or after destructive stomatitis from any cause, serves to convert the cheeks into false ligaments holding the jaws close together. A very marked case of this kind presented itself at the Hospital of Oral Surgery, Philadelphia, in 1883.[1]

Tendons.

The tendons, with but few exceptions, are made up of bundles of white fibrous connective tissue bound together by fasciculi from the

[1] See Garretson's *Oral Surgery*.

deep fascia, which form their sheaths. The sheaths not only enclose the individual fibres composing the bundles, but the entire tendon. This latter covering is called the *theca*.

The fibres which make up a tendon are arranged parallel with each other, and have an undulating course. Occasionally the fibrous bundles send off fasciculi, some running forward and others backward, interlacing with each other. The bundles proper, however, do not subdivide, but keep intact from one extremity to the other.

The connective-tissue cells of tendons, called tendon-cells, are arranged in parallel rows (Fig. 79), and follow the line of the fibrous bundles composing the tendon. They are so closely approximated that in a longitudinal section they have a stellate appearance, due to compression of the cells and the elongated processes characteristic of all connective-

FIG. 79.

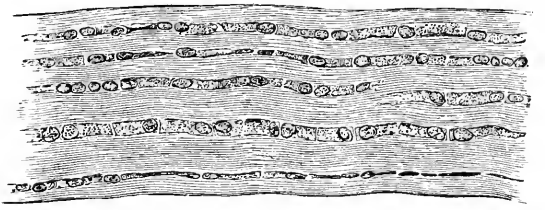

Tendon of Mouse's Tail, stained with logwood, showing chains of cells between the tendon-bundles (175 diameters).

tissue cells, which protrude from them, uniting one cell to another. These cells are minute protoplasmic bodies, thicker in the centre than at the circumference, and contain a round or oval nucleus with several nucleoli.

Tendons are found connected with muscles at either terminal extremity or between the two bellies of the same muscle. Their fibres usually run continuously with those of the muscle, but they may join the muscle at an angle. When the tendinous fibres unite with the muscular fibres end to end, the tendon is subdivided into as many fibres as there are fibres in the muscle to which it is united. Adherence to this law is so uniform that the fibres of the tendon seem to be but a continuation of those of the muscle. A close examination, however, of the muscular extremity of the fibres of the tendon will show that they suddenly end on coming in contact with the truncated extremity of the muscle-fibre.

The sheaths, formed by fasciculi from the deep fascia, which enclose the bundles of fibres forming the tendon, pass from the tendon-bundles to the muscular fasciculi, and are lost by overlapping the similar sheaths which enclose the muscular fibres, they all being continuous.

Where the fibres of the tendon are obliquely united to those of the muscle the small tendinous bundles are given off laterally just at their point of union, and extend between or over the muscular fibres, but their sheaths are lost in the muscle in a manner precisely similar to the union of the parallel fibres.

MUSCULAR TISSUE.

Muscular tissue is made up of fibres collected into distinct and separate masses. By means of this tissue all the active movements of the

body are produced. It is familiarly known as "flesh," and it is distributed over the entire framework of the body and in the coats of blood-vessels and the viscera.

In the higher vertebrates the color of the muscular tissue is generally red, varying in shade, however, according to the locality in which it is found and to other circumstances. The voluntary muscles, called into most constant action, are deeper in color than others of their class. A marked illustration of this is shown in the pectoral muscles of the bird and the common fowl. The former, being called into almost constant use in the act of flying, are dark in color, while the latter, being almost wholly inactive, are extremely light in shade.

Muscular tissue also constitutes a large proportion of the weight of the human body. It has been estimated by Liebig that a man weighing 150 pounds is 27 pounds skeleton, 60 pounds viscera (with skin, fat, blood, etc.), 63 pounds muscle.

Each muscle constitutes a separate organ, and either acts independently or in conjunction with other muscles as accessories. The great vital property of muscular tissue is contractility, which power is excited to activity by the influence of various stimuli.

The greater number of the muscles of the body, such as those of locomotion, respiration, mastication, the first part of deglutition, expression, etc., are compelled by the will acting through the nerves with which the parts are supplied. These are known as voluntary muscles.

Others, again, as those of the intestinal canal and the vascular system, cannot be brought into action by the force of the will. These are called involuntary muscles, and are controlled by the sympathetic nervous system.

These two classes of muscles differ also in their histological construction, and will therefore be considered separately.

The Voluntary Muscles are fibres appearing under the microscope transversely striated, and generally oblong in shape. Usually, tendons are attached to their extremities, by means of which they are united to bones, and sometimes to other tissues; for instance, the sphincter muscle of the mouth.

The fleshy part of a muscle is called its belly, and its terminal prolongations are its tendons of origin and insertion. The term *origin* of a muscle or tendon generally applies to that extremity which is stationary, and the term *insertion* is applied to the more movable point. Example: the origin of the temporal muscle is that portion arising in the temporal fossa on the side of the head, while its insertion is at the coronoid process of the inferior maxilla. The skull is the fixed point of the muscle, while the lower jaw is the movable one. This rule is not without exceptions, as in certain localities the fixed point of a muscle may become the movable point. The origin of a muscle may be large and its insertion small, and vice versâ; or the origin and insertion may be of equal size.

A thorough knowledge of the origin and insertion of muscles is absolutely necessary to a full understanding of the mechanical action of the parts to which they are attached. It is essential in diagnosticating fractures and dislocations. A knowledge, also, of the direction of the fibres composing muscles, and of the relation of muscles to adjoining parts, enables the surgeon to locate disease, and serves as a guide to the

position of blood-vessels and nerves. The power of a muscle depends upon the number of its contractile fibres. When contracted, it increases in thickness; its action, unless otherwise influenced by associate parts or by its tendon passing through loops of fascia or over a pulley, is in a direct line with the course of its fibres.

Fasciculi are the bundles of the fibres composing muscles. The fibres which make up the fasciculi vary greatly in length in different muscles. The fasciculi which form the bundles composing a muscle run parallel with each other, never interlacing, but extending from one terminal to the other, except when interrupted by the interposition of tendinous tissue, as in the case of the digastric muscle.

FIG. 80.

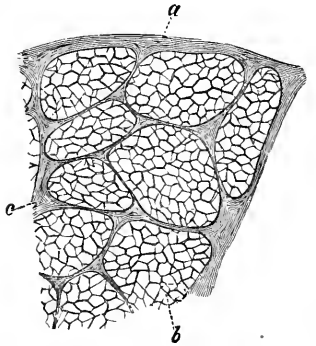

Transverse Section from the Sterno-mastoid in man (50 times magnified): *a*, perimysium; *b*, endomysium; *c*, fasciculi.

The Perimysium (Fig. 80) is the sheath of areolar tissue that invests the muscles and sends partitions inward between the fasciculi, providing each with a special sheath.

The Endomysium is the portion of the above membrane partially surrounding the fibres composing the fasciculi; the latter are not continuously invested with it. The chief uses of the perimysium and its partitions are to connect the fibres and fasciculi together, and to furnish spaces for the accommodation of blood-vessels and nerves that supply the parts.

The fasciculi (Figs. 81 and 82) are prismatic in form, and the number of fibres of which they are composed in different parts of the body causes the variations in their thickness.

The texture of a muscle, whether coarse or fine, depends upon this circumstance. The length of a fasciculus depends upon the length of the muscle, as well as upon the arrangement of the tendons to which the extremities of the muscle are attached. When the tendons are limited to

FIG. 81.

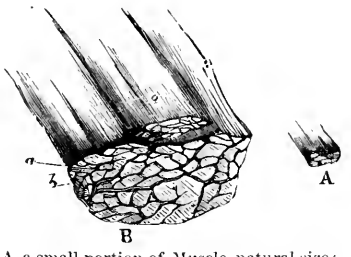

A, a small portion of Muscle, natural size; B, same magnified 5 diameters, of larger and smaller fasciculi, seen in a transverse section.

FIG. 82.

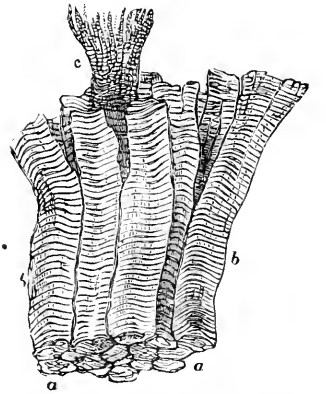

A few Muscular Fibres, being part of a small fasciculus (highly magnified).

the ends or extremities of long muscles, the fasciculi are of great length,

having to pass from one extremity of the muscle to the other. But a long muscle may be composed of a number of short fasciculi attached obliquely to the sides of its tendon, which may advance upon its surface or into its fleshy parts. Many short fasciculi, thus connected, produce by their combined operation a more powerful effect than a few fasciculi extending the entire length of a muscle. The latter arrangement, however, gives greater extent of motion.

The Fibres composing the Fasciculi are cylindrical or prismatic in form. Their size is generally uniform, being in the muscles of the trunk and limbs from $\frac{1}{750}$th to $\frac{1}{400}$th of an inch in diameter. It is less in those of the head, especially in the face, where they range from $\frac{1}{2400}$th to $\frac{1}{750}$th of an inch.

The general length of the fibres does not exceed an inch and a half. In long fasciculi, therefore, they do not extend from the tendon of one extremity to that of the other, but end in a rounded point invested by sarcolemma adhering to approximate fibres.

Muscle-fibres generally neither divide nor anastomose. In the tongue of the frog (Fig. 83), however, the muscular fibres as they approach the surface divide into numerous branches, which are attached to the under surface of the mucous membrane. This is also true of man and various animals.

Fig. 83.

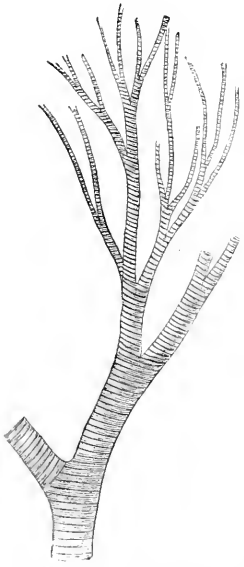

A Branched Muscular Fibre from the frog's tongue (magnified 350 diameters).

The fibres of the facial muscles of mammals and those of the panniculus carnosus follow the same rule. The numerous attachments of the latter muscle to the under surface of the skin causes the peculiar external twitching movement seen in these animals.

Muscular fibre is soft and contractile, and is enclosed in a tubular envelope known as the sarcolemma or myolemma. This envelope consists of a transparent, apparently homogeneous membrane, similar to elastic tissue. It is tough, and will occasionally remain entire when the fibres which it encloses are ruptured (Fig. 84). Nuclei are found on the inner surface of the sarcolemma, but they belong to the contractile substance of the fibre, and not to the sarcolemma.

Fig. 84.

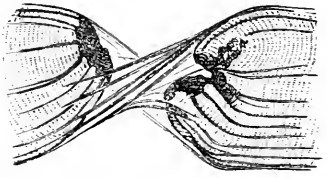

Fragments of an Elementary Fibre of the Skate, held together by the untorn but twisted sarcolemma.

The Contractile Substance of voluntary muscular fibre, when examined under a microscope of high power and with transmitted light, appears marked with parallel bands (Fig 85), alternating dark and light; the former are named the contractile discs, the latter the interstitial discs. These bands pass across the fibre with great regularity. They are of

equal breadth, but when the fibre is considerably extended a dotted line becomes visible in the centre of the light band. This characteristic cross-striped appearance is found in all voluntary muscles, but is not absolutely confined to them, as it is seen in the fibres of the heart, which

FIG. 85.

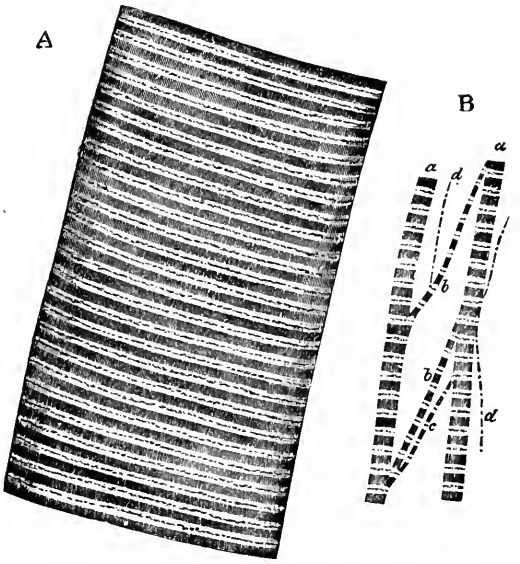

A, portion of a medium-sized Human Muscular Fibre (magnified nearly 800 diameters): B, separated bundles of fibrils, equally magnified; *a*, *a*, large, and *b*, *b*, smaller collections; *c*, still smaller; *d*, *d*, the smallest which could be detached.

is considered an involuntary organ, though it is claimed that some persons have partial control over it.

There is also a longitudinal striation seen in voluntary muscular fibre, better marked where the transverse striation is somewhat indistinct. After hardening in alcohol, voluntary muscular fibre may be broken up longitudinally into so-called fibrils. The fibre is not, however, composed entirely of fibrils, but contains a considerable quantity of an intermediate substance. After the action of dilute acids or of gastric juice on muscle, the fibres display a disposition to break up transversely in a direction parallel to the bands, and even into transverse plates or discs formed by the lateral adhesion of the particles of approximated fibrils. This separation of muscular fibre into discs is only possible after the coagulation of muscle-plasma or the action of reagents upon it.

Muscular fibres also exhibit a number of clear oval nuclei (Fig. 86). In the muscles of mammals these nuclei are situated upon the under surface of the sarcolemma. Surrounding these nuclei there is sometimes a certain amount of granular matter which is derived from the original primitive embryonic protoplasm.

The nuclei of muscular fibre are not readily seen without the addition of acetic acid. One or two nucleoli may also be found within each nucleus.

Blood-vessels in muscular tissue are extremely numerous. These carry the material for the nourishment of the tissues and for the chemico-vital changes which take place within them. When these vessels are filled with coloring matter, the fleshy part of the muscles supplied by them is in strong contrast with the tendons. Arteries, accompanied by veins, enter the muscle at various points, divide into branches, pass among the fasciculi, and break up more and more as they extend into the finer divisions of the muscle. Finally, they penetrate the smallest fasciculi and terminate in capillary vessels which run between the fibres. They are supported by the subdivisions of the perimysium, and supply it with capillaries. The diameter of these is extremely small, and they form a fine network among the fibres.

Fig. 86



Muscular Fibre of a Mammal, examined fresh in serum, highly magnified, the surface of the fibre being accurately focused. The nuclei are seen on the flat at the surface of the fibre, and in profile at the edges.

Lymphatics.—It is not known that there are any lymphatic vessels in the voluntary muscular tissue, but they are found in great abundance in the connective tissue of its sheaths and tendons. They have their commencement in connective tissue, and their office is to collect and convey the lymph from the muscular substance and tendons.

The Nerves of the voluntary muscles are of large size, and their branches pass between the fasciculi, often uniting to form plexuses, from which smaller nerve-filaments are given off and form finer plexuses, each containing not more than two or three dark-bordered nerve-fibres. Single nerve-fibres pass from these between the fibres of the muscles, divide into branches, and finally terminate in motor end-plates, which are situated upon the sarcolemma of the muscular fibres. Small nerves also accompany the branches of blood-vessels within the muscle.

Fig. 87.

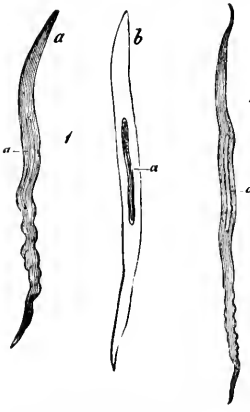

Involuntary Muscular Fibre-cells from Human Arteries.

Involuntary Smooth or Unstriped Muscle.—Excepting in the heart and a few other organs of the body, involuntary muscular tissue is unstriated, and its apparent fibres are made up of elongated contractile cells bound together by a homogeneous intercellular substance.

Unstriated muscular tissue is composed of contractile fibre-cells (Fig. 87). These cells may form fibrous bundles or they may be less regularly arranged. They are elongated, and usually pointed at the ends. They vary greatly in length in the different organs of the body, and may bifurcate at one or both extremities. Each cell has a nucleus, which is either oval or rod-shaped, and situated, as a rule, centrally.

Involuntary muscle fibre-cells are spindle or fusiform in shape. The wall or envelope, which may wrinkle on the contraction of the fibre and produce an indistinct

appearance of striation, is very delicate and homogeneous. The cells are united by an intercellular cementing substance. They are closely packed into fasciculi, which in most cases cross and interlace one with the other, the spindle-end of the cell fitting in between the bodies of the other cells. The fasciculi are united at their ends by connective tissue to the membranous parts, where such parts occur.

Unstriated muscular tissue is largely distributed in the coats of the arteries, veins, and viscera. It is also found in the ducts of the sweat-glands of the skin in the form of minute muscles attached to the hair-follicles, and in the subcutaneous tissue of the scrotum. This tissue is supplied by numerous nerves from the sympathetic system and abundant blood-vessels, though these are fewer in proportion than in voluntary muscular tissue. In the walls of the stomach and intestines numerous lymphatic vessels are found.

The fibres of the muscular tissue of the heart, however, differ from those of involuntary muscular organs generally, presenting as they do transverse striæ. These striæ are, however, less distinct, and the muscle-fibres are smaller in diameter, than those of voluntary muscles. The fibres are also made up of quadrangular cells joined end to end, each cell having a single oval nucleus situated near its centre; occasionally two nuclei are found. The fibres composing this variety of muscle divide and interlace, though they are not invested by sarcolemma.

Varieties of Muscles.—General names have been given to muscles significant of the arrangement of their fasciculi. Thus, when the fasciculi of a muscle are attached to a central tendon obliquely, like the feathers of a quill pen, the muscle is called *penniform*. If the fasciculi of a muscle converge from a broad surface and are attached to a narrow tendon, the muscle is called *radiated*. When the fasciculi of a muscle are turned or twisted upon themselves the muscle is called a *torsion* muscle. If the tendon of a muscle passes through a loop or around a bony process, and its action is thereby diverted from a straight line with the longitudinal axis of its body, it is called a *pulley* or *trochlear* muscle. Those situated at the opening of tubes which separate one compartment from another, and the fasciculi of which form circular bands, are called *sphincter* muscles; they generally have no osseous attachment, and their action is frequently antagonized by others.

Muscles also receive special names according to the regions which they occupy, their situation in the region, and their origin and insertion. Thus, the superficial muscles include the subcutaneous muscles, the panniculus carnosus; in man the rudiments of this muscle are the muscles of expression, those moving the ears, and the platysma myoides. These muscles contain a greater amount of contractile tissue than those composing the deeper layers.

Muscles yield to pressure produced by tumors, aneurism or abscess, and the products of inflammation pass with facility throughout their tissue, generally taking the course of the areolar partitions.

These organs can be increased in size and firmness, by the enlargement of the individual fibres, through judicious exercise or training, but they become smaller by an excess of physical activity or deteriorated by inaction. The complete rest of the parts following fractures and other

local injuries reduces the size and tonicity of muscles, and this atrophied condition often remains persistent. Modern surgery, to avoid this and other pathological sequences, attempts the adjustment and fixation of the ends of fractured bones with as little loss of muscular exercise as possible.

The Number of Muscles.—The whole number of muscles belonging to the voluntary system is about 229: those of the head, 52; of the neck, 24, exclusive of those belonging to the vertebral column.

The muscles of the head are divided into four groups—those of the face, auricle, orbit, and of mastication.

The facial muscles (Fig. 88) are subdivided into three sets, named, according to their location, the fronto-palpebral, the nasal, and the oral.

The fronto-palpebral muscles are the occipito-frontalis, the pyramidalis nasi, the orbicularis palpebrarum, and the corrugator supercilii.

The nasal muscles are the compressor nasi, the depressor alæ nasi, the dilator naris anterior, and the compressor narium minor.

The oral muscles are the orbicularis oris, the levator labii superioris alæque nasi, the levator labii superioris proprius, the depressor labii superioris, the zygomaticus minor, the zygomaticus major, the levator anguli oris, the risorius, the depressor anguli oris, the depressor labii inferioris, the levator labii inferioris, and the buccinator.

The muscles of the auricle consist of the attolens aurem, the attrahens aurem, and the retrahens aurem.

The muscles of the orbit are the levator palpebræ, the rectus superioris, the rectus inferioris, the rectus internus, the rectus externus, the obliquus superioris, and the obliquus inferioris.

The muscles of mastication are the masseter, the temporalis, the pterygoideus externus, and the pterygoideus internus.

The muscles of the neck are the platysma myoides, sterno-cleido-mastoideus, the depressors of the hyoid bone, the muscles of the suprahyoid space, those of the pharynx and soft palate, the deep lateral, and the prevertebrals.

The Facial Muscles.

The facial differ markedly from all other voluntary muscles of the body. In the first place, some of them have no bony origin; none have bony insertions. That is to say, some of the facial muscles have but one extremity attached to bone, the other being inserted into muscles; while, again, several have no osseous attachment whatever. Their fibres are more delicate, and, having no investing sheath of perimysium, merge one into the other.

The voluntary muscles of the face are not as wholly under the power of the will as are the voluntary muscles of the limbs, and are often affected by mental impressions.

The Occipito-frontalis is in reality two muscles divided by an aponeurosis. These are called the *Occipitalis* and the *Frontalis*.

The Occipitalis Muscle is thin and flat, arises from the outer two-thirds of the superior semicircular line of the occipital bone and the mastoid portion of the temporal bone above the attachment of the

sterno-cleido-mastoid, passes upward and forward, and terminates in distinct tendinous fibres, which are continuous with the epicranial or occipito-frontal aponeurosis.

The Frontalis Muscle is thinner and paler than the occipitalis, and is more intimately connected with the skin. It arises from the aponeurosis, on a transverse line, between the fronto-parietal suture and the

FIG. 88.

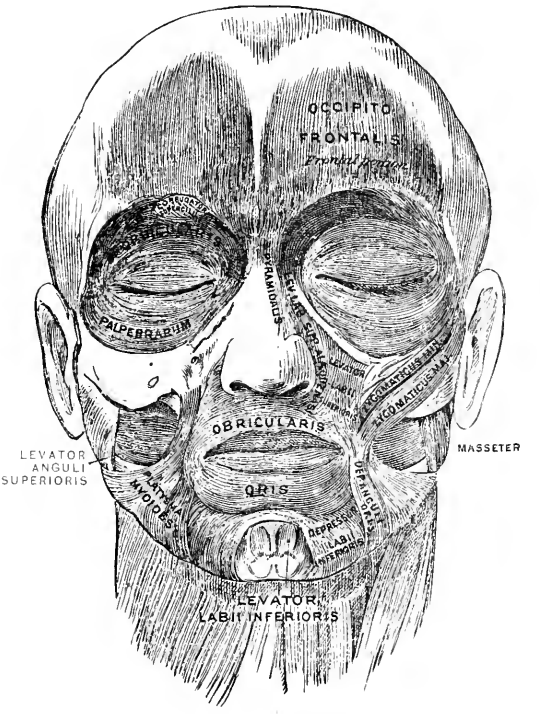

The Muscles of Expression.

frontal eminences. It is larger than the occipitalis, and arises by two heads slightly separated from the fibrous epicranial or occipito-frontal aponeurosis, and passes downward over the forehead. The fibres converge as they descend, the two portions of the muscle uniting just above the nasal eminence to be inserted into the eyebrows. The central portion of the muscle is continuous with the pyramidalis nasi, while a large number of its fibres are interlaced with the corrugator supercilii and orbicularis palpebrarum, and extend outward over the external angular process of the frontal bone.

The Epicranial or Occipito-frontal Aponeurosis is a fibrous connective extension of the above muscles, covering the upper portion or vertex of the skull from side to side, without division. Superiorly, it is intimately connected with the scalp, though interspaces will be found filled with granules of fat. So close is this connection that it is difficult to separate the two by dissection. Between the epicranial

aponeurosis and the pericranium there is a small amount of loose connective tissue, which permits easy movement and readily admits of dissection

Posteriorly, this aponeurosis is attached to the occipitalis muscle, a portion of the superior semicircular line, and the occipital protuberance. Anteriorly, it terminates in the frontalis muscle. Laterally, it presents no distinct marginal termination, but is gradually blended into the superficial temporal fascia, and affords attachment to the superior and anterior aural muscles. Its outer surface is closely attached to the skin by numerous bands of connective tissue.

Action.—By the contraction of the frontalis muscle the eyebrows are elevated or arched, as in expressing surprise, delight, or doubt. This elevation of the eyebrows causes the skin to wrinkle over the surface of the forehead.

By the contraction of the occipitalis muscle the scalp is drawn backward, and by an alternating action of the two muscles the scalp may be moved forward and backward. Most people have not the power of moving the scalp in both directions, the motion being limited to an anterior direction only.

The Pyramidales Nasi are two in number. Their form, as their name indicates, is pyramidal, and they are formed by the continuation of the fasciculi from the frontalis muscle. They extend downward on either side of the nose, widening as they descend, and, becoming tendinous, join the tendinous insertion of the compressor nasi.

Relations.—By its upper surface with the skin, and below with the nasal bones.

The Orbicularis Palpebrarum is a thin sphincteric or elliptical muscle having a bony attachment. It is closely adherent to the integument covering the eyelids and surrounding the orbits. It is divided into three portions—orbital, palpebral, and concentric.

The Orbital or Peripheral Portion arises from the internal angular process of the frontal bone, the nasal process of the superior maxilla, and the lachrymal groove. Its fasciculi diverge as they extend, the superior passing upward and outward over the superior orbital arch toward the temple, while the inferior pass downward and outward, inosculating with the superior fibres at the outer portion of the orbit. The orbital portion of the orbicularis palpebrarum is the strongest, while its fibres are of deeper color than the other two portions. Internally, its fibres are attached to the tarsal ligament, while next to the nose it has a bony attachment such as described above. Its superior border is partially held in position by descending fibres from the frontalis and by the corrugator supercilii muscles. Its lower and outer margins are free.

The Palpebral Portion arises from the superior and inferior margins of the tarsal ligament, passes outward over the eyelids, and is inserted into the outer and lesser tarsal ligaments. This portion is much thinner and its fibres are paler than the preceding.

The Concentric Ciliary or Inner Portion is somewhat stronger than that covering the eyelids, and is confined to the margins of the vela. The inner edges are free.

Relations.—By its upper surface with the integument; by its under

surface the orbital portion is in relation with the frontalis and corrugator supercilii muscles, their fibres interlacing, and with the supraorbital vessels and nerves, the lachrymal sac, the origin of the levator labii superioris, alæque nasi, and the levator labii superioris muscles; internally with the pyramidalis nasi, and externally with the temporal fascia. The under surface of the palpebral portion of this muscle is connected to the cartilage of the eyelid by fibrous connective tissue.

The Internal Tendo-palpebrarum (tendo-oculi) is a small white fibrous band about two lines in length and one line in breadth. It is attached to the nasal process of the superior maxilla in front of the lachrymal groove, and runs outwardly across the lachrymal sac to the inner commissure of the eyelids, where it divides into two portions, one going to each lid. As the tendon crossess the lachrymal sac it gives off from its under surface a strong aponeurotic lamina which covers the sac and is attached to the lachrymal bone.

The External Tendo-palpebrarum is much weaker than the internal, and is attached to the malar bone.

The Tensor Tarsi (Horner's muscle) is a thin layer of fibres arising from the lachrymal crest behind the lachrymal sac. It passes forward and outward, and divides into two fasciculi, which are lost in the concentric portion of the orbicularis palpebrarum.

The Corrugator Supercilii is a small, deeply-colored muscle arising from the inner extremity of the superciliary ridge, passing outward and upward, its fibres diverging, some extending into the orbicularis and frontalis muscles, terminating about the middle of the eyebrow. This muscle is intimately adherent to the integument.

Relations.—By the inner portion of its upper surface with the orbicularis and frontalis muscles, the outer extremities of its fibres being inserted into these muscles; by its under surface with the frontal bone, the supratrochlear branches of the ophthalmic nerve and accompanying vessels.

(The levatores palpebræ will be described with the motor muscles of the eye.)

Actions.—The orbicular portion of the orbicularis palpebrarum is wholly under the control of the will. Its upper fibres act by depressing the eyebrow and drawing down the integument of the forehead, antagonizing the frontalis muscle. The lower portion elevates the integument of the cheek, and both combined wrinkle the skin at the outer and inner angles of the orbital cavities. The office of this muscle is fully exerted when the eye is closed with force.

The Palpebral Portion gives the peculiar movement to the eyelids seen in winking or in sleep. It also draws forward the internal tarsal ligament and the anterior wall of the lachrymal sac, causing it to open for the reception of lachrymal fluid.

The Concentric or Ciliary Portion closes in the edges of the vela of the eyes, and draws the cilia or lashes of the respective lids against each other.

The Corrugator Supercilii muscle draws the skin over the forehead downward and inward toward the upper part of the nose, causing the vertical grooves made in frowning.

THE NASAL SET of muscles comprises the compressor nares, depressor alæ nasi, and the dilatores nares. These are unimportant muscles, composed of few fasciculi, and their actions are implied in their names.

FIG. 89.

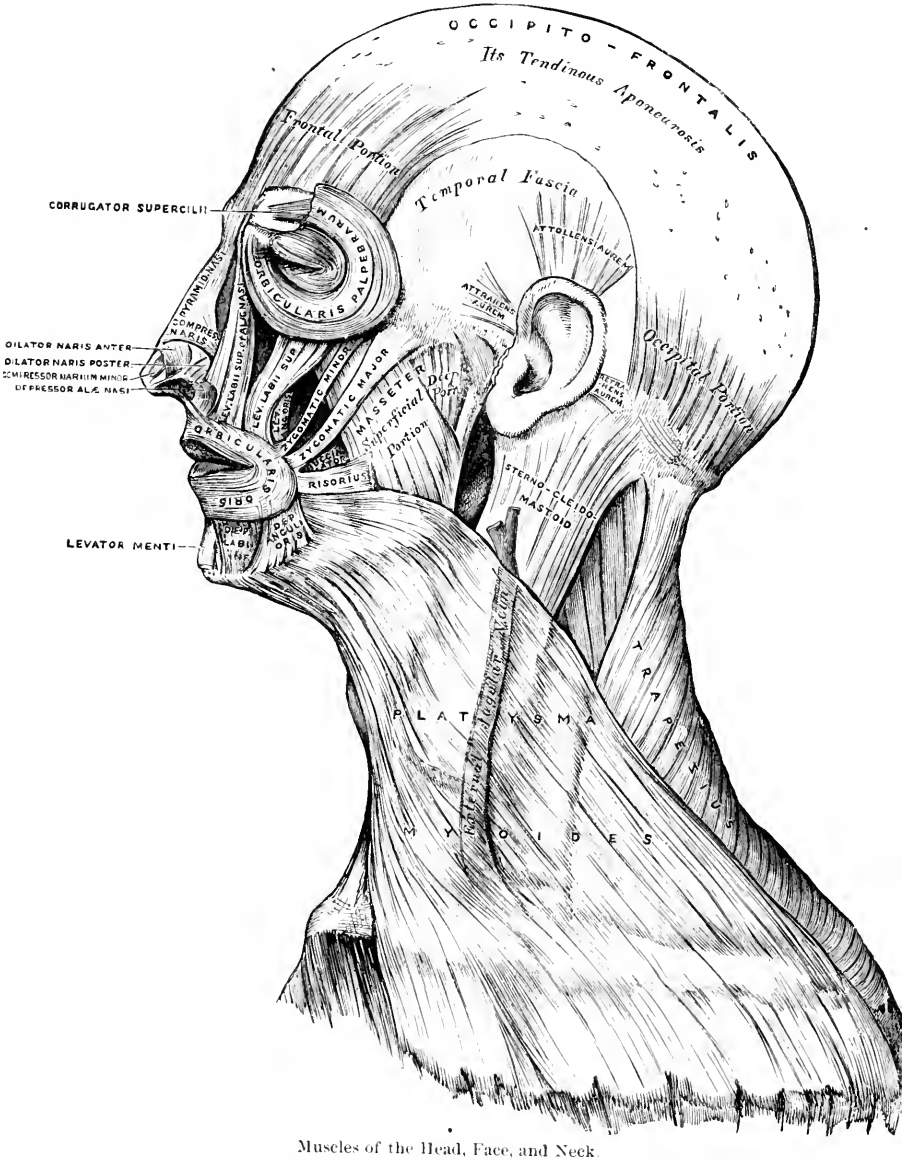

Muscles of the Head, Face, and Neck.

The Compressor Nares is a small triangular muscle arising by its apex from the inner portion of the canine fossa of the superior maxilla, its fibres passing inward and upward, gradually expanding into a thin

aponeurosis, uniting with the corresponding muscle of the opposite side and with the pyramidalis nasi.

The Depressor Alæ Nasi are short radiated muscles arising from the incisive fossæ of the superior maxillæ, the fibres passing upward to be inserted into the integument of the nasal septum and to the alæ of the nose.

Besides those just described, there are several other muscles, with irregular and indistinct fasciculi, which assist in enlarging the opening of the nose. Among these are the compressor narium minor and the dilatores naris anterior and posterior.

THE ORAL GROUP (Fig. 89) consists of the orbicularis and those muscles having their insertion into it.

The Orbicularis Oris is a thin layer of muscular fibres, forming the sphincter of the mouth. It is elliptical in form, its fibres being continued from one lip to the other around the angles of the oral opening. It is divided into two portions, labial and facial, the labial or marginal circle or rim forming the red portion of the lip. The facial or external portion blends with the muscles which converge toward the mouth, its fibres being inserted into them, and acting antagonistically to them. The portion of this muscle corresponding to the upper lip is composed of four slips of muscular fibres, two situated on each side of the central portion. The outer slips are thin and weak, pass downward, and are attached to the superior maxilla in the incisor fossa below the origin of the depressor alæ nasi. The inner two slips, thicker and stronger, pass upward, and are inserted into the septum of the nose. At the median line the space between these slips corresponds to the perpendicular groove on the lip immediately below the nose. The two fasciculi of the lower lip arise in the incisor fossa of the inferior maxilla external to the levator labii inferioris. They pass upward and outward toward the angles of the mouth, their fibres interlacing with the other muscles of the lip.

Relations.—By the inner margin of the superficial surface it is closely connected with the integument, whilst superimposed between the outer portion and the integument is a layer of fatty tissue; by its deep surface with the mucous membrane, labial glands, and coronary arch of vessels of each lip. Its internal circumference is immediately beneath the integument, and forms the free margins of the lips, whilst the outer circumference is blended with the several muscles that converge from various portions of the face to this point or muscle.

The Levator Labii Superioris Alæque Nasi is a thin triangular muscle situated along the side of the nose, extending from the inner angle of the orbital cavity to the upper lip. It arises by a pointed extension from the upper and outer part of the nasal process of the superior maxilla, passes downward and outward, and divides into two portions. The smaller of these is inserted into the ala of the nose, the other being prolonged downward and blending with the orbicularis oris and the special elevator muscle of the upper lip.

Relations.—By its superficial surface superiorly with the orbicularis palpebrarum, and below with the integument.

The Levator Labii Superioris Proprius is the special elevator muscle

of the upper lip. It is thin and quadrilateral in outline, arising immediately below the orbital cavity above the infraorbital foramen. Its origin is chiefly confined to the superior maxilla, but a few of its fibres extend from the malar bone. It passes downward and inward to be inserted into the orbicularis oris and the integument of the superior lip. It is situated on the same general plane as the levator labii superioris alæque nasi, and is connected with it throughout its lower third.

Relations.—By its superficial surface with the orbicularis palpebrarum and the integument; by its inner surface with the infraorbital nerve and its accompanying vessels as they emerge from the infraorbital foramen, a portion of the levator anguli oris, and the origin of the compressor nasi muscle.

The Depressor Labii Superioris is a small muscle arising from the lower portion of the incisive fossa of the superior maxilla and the alveolar process immediately below the fossa. Its fibres pass upward to the lower border of the nostrils and the partition of the nose. A portion of the fibres of this muscle are attached to the integument covering the wing of the nose; the balance pass downward and are inosculated with the fibres of the muscles of the upper lip. It, with its fellow and the mucous membrane, forms the frænum of the upper lip, and when the alveolar process is absorbed after the loss of the teeth, it is often found attached on the lower margin of the gum.

Relations.—Within the vestibule of the mouth it is covered by mucous membrane; above that portion it is covered with the muscles of the upper lip; its deep surface rests upon the bone, and the median border joins with its fellow of the opposite side.

The Zygomaticus Minor is an extremely slender muscle arising from the anterior inferior portion of the malar bone, just behind the malomaxillary suture. It passes downward and forward, its fibres becoming lost in those of the special elevator muscle of the upper lip near the angle of the mouth.

Relations.—By its superficial surface with the orbicularis palpebrarum and the integument; by its deep surface with the levator anguli oris.

The Zygomaticus Major is situated just external to the smaller muscle of the same name. It arises from the malar bone in close proximity to the zygomatic suture, and passes obliquely downward to the angle of the mouth, where it is attached to the integument and becomes blended with the fibres of the orbicularis oris and depressor anguli oris muscles.

Relations.—By its superficial surface with the subcutaneous adipose tissue; by its deep surface with the malar bone and the masseter and buccinator muscles.

Variations.—The zygomaticus minor is often absent, and occasionally its fibres are lost in the integument before reaching the muscle of the lip. At times also it arises in part or entirely from the orbicularis palpebrarum muscle, and is blended with the zygomaticus major and the levator labii superioris. Occasionally it is separated into two muscles. The zygomaticus major is also occasionally wanting, or it may be double, and arises at times from the masseteric fascia.

The Levator Anguli Oris (canine muscle) arises from the canine fossa immediately below the infraorbital foramen. It passes downward and

slightly outward to its insertion at the angle of the mouth. In this position its fibres become blended with those of the orbicularis oris, zygomaticus major and minor, and depressor anguli oris muscles.

Relations.—Its upper surface is in relation with the special elevator muscle of the upper lip, the infraorbital nerve, and vessels passing between these two muscles. At the point of its insertion it is intimately adherent to the integument; by its deep surface with the superior maxillary bone, the buccinator muscle, and the mucous membrane of the mouth.

The Risorius (smiling muscle), when present, consists of a few thin fasciculi which arise from the deep fascia covering the masseter muscle or the parotid gland, and occasionally as far back as the mastoid process of the temporal bone. From this point it passes transversely forward and inward, its fibres becoming blended with those of the depressor anguli oris and the orbicularis oris at the angle of the mouth.

The Depressor Anguli Oris (triangularis menti) is a triangular muscle arising by its base from the external oblique line of the inferior maxilla, becoming narrow as it ascends to the angle of the mouth, where its fibres become blended with the orbicularis oris and the other muscles of this region.

Relations.—By its superficial surface with the integument; by its deep surface with the buccinator and depressor muscles of the lip.

The Depressor Labii Inferioris (quadratus menti) is quadrilateral in shape, and arises from the inferior maxilla by a line of attachment extending from near the symphysis to a point a little posterior to the mental foramen. Its fibres pass upward and inward, uniting with its fellow of the opposite side and blending with the fibres of the orbicularis oris. It is continuous below with the platysma myoides, and above it is inserted into the integument. Between the fibres of this muscle will be found a considerable quantity of adipose tissue.

Relations.—By its superficial surface with a portion of the depressor anguli oris and the integument, with which it is intimately connected; by its deep surface with the mental nerve and vessels, the mucous membrane lining the lower lip, the labial glands, and the elevator muscle of the lower lip.

The Levator Labii Inferioris (levator menti) can be best exposed by everting the lower lip and removing the mucous membrane. It is a small conical fasciculus arising from the upper portion of the incisor fossa of the inferior maxilla, its fibres radiating as they pass downward between the depressors of the lower lip to be inserted into the integument covering the chin.

Relations.—By its superficial surface with the mucous membrane of the vestibule of the mouth, with the lower margin of the orbicularis oris and the integument covering the chin; by its deep surface with the bone and the depressor muscle of the lower lip, and on its median border with its fellow of the opposite side.

The Buccinator is a thin and flat though powerful muscle situated between the upper and lower jaws, and forming a considerable portion of the wall of the vestibule of the mouth. Correctly speaking, it is not a true facial muscle, belonging more properly to the pharyngeal con-

strictor muscles, being advanced forward into the face. It also differs from the facial muscles by being enclosed in a sheath of thin fascia, and is supplied by a different motor nerve. It arises from the lower margin of the outer surface of the alveolar processes of the superior and inferior maxillary bones opposite the molar teeth, from the anterior surface of the pterygo-maxillary ligament, which is a narrow band of tendinous fibres extending from the upper extremity of the hamular process of the internal pterygoid plate of the sphenoid bone to the mylo-hyoid ridge of the inferior maxillary bone, close to the position of the wisdom tooth. From this extensive origin its fibres pass forward, converge, and become thickened as they reach the lateral margin of the orbicularis oris. At this point its central fibres decussate, those from the upper portion becoming blended with the muscles of the lower lip, and those from the lower portion blending with the muscles of the upper lip. The superior and inferior fibres of the muscle continue forward without decussation, inosculating with the superficial fibres of the orbicularis oris, becoming lost on the opposite side of the mouth.

Relations.—By its superficial surface with a considerable quantity of soft adipose tissue, which separates it from behind forward from the ramus of the jaw, a small part of the temporal muscle, the masseter muscle, the muscles of expression connected with the angle of the mouth, the parotid duct, which pierces the muscle opposite the second molar tooth of the upper jaw, and the facial artery and vein; branches of the facial and buccal nerves pass over it. By its deep surface it is in relation with the buccal glands and mucous membrane of the vestibule of the mouth.

Actions of the Oral Muscles.—When the whole of the orbicularis oris muscle is brought into independent action, it closes the lips both vertically and transversely, and when a forced action is brought about, it projects the lips and wrinkles the integuments; when acting jointly with the buccinator, the lips are closed and elongated transversely. When the associated muscles which converge from nearly all points act singly, they draw the orbicularis oris in the longitudinal direction of their fibres. When two or more muscles act together, the line of traction will be between these muscles, the direction depending upon the relative power of each muscle.

The common elevators of the lip and nose and the depressors of the wing of the nose act upon these parts in opposition to each other, the former elevating, the latter depressing. The muscles which are inserted at the angles of the mouth not only elevate and draw the angle backward, but in doing so they push the cheeks upward and thus elevate the margin of the lower eyelid, as is shown by the expression of the mouth and cheeks in merriment; while those which depress the angles also depress the cheeks, as illustrated by the face in grief.

The Muscles of the Ear.

The auricular muscles are those that belong to the pinna of the ear. There are several minute bundles of muscular fibres which extend from one point to another in the pinna; also three larger muscles, two aris-

ing from the temporal aponeurosis, the other from the mastoid process of the temporal bone and inserted in the pinna: they are named the attolens aurem, the attrahens aurem, and the retrahens aurem. They are only slightly developed in man.

The Attolens Aurem, or Auricularis Superior, is the largest of the three. It is fan-shaped, arising by a broad head from the superficial fascia over the temporal muscle, and is inserted into the anterior part of the helix and the eminence upon the inner surface of the pinna. Its fibres are extremely delicate; it is furnished with branches from the occipital nerve.

The Attrahens Aurem, or Auricularis Anterior, is the smallest of the three; it is thin, fan-shaped, and its fibres are pale and indistinct, arising from the superficial fascia over the temporal muscle, and are inserted into the tragus. The nerve supplying it is derived from the facial and the auriculo-temporal branch of the inferior maxillary.

The Retrahens Aurem, or Auricularis Posterior, is stouter than the other two, and is composed of two or three fasciculi. The fibres are deeper in color and distinctly marked. It arises from the mastoid portion of the temporal bone; passing forward, it narrows slightly and is inserted into the posterior aspect of the concha. The nerve-supply is derived from the posterior auricular branch of the facial.

Muscular Action.—With few exceptions man has no power to move the ears; therefore the muscular action is of little or no consequence.

MUSCLES OF THE ORBIT.

The muscles of the orbit (Figs 90 and 91) are seven in number—six belonging to the movement of the eyeball: one is the elevator of the

Fig. 90.

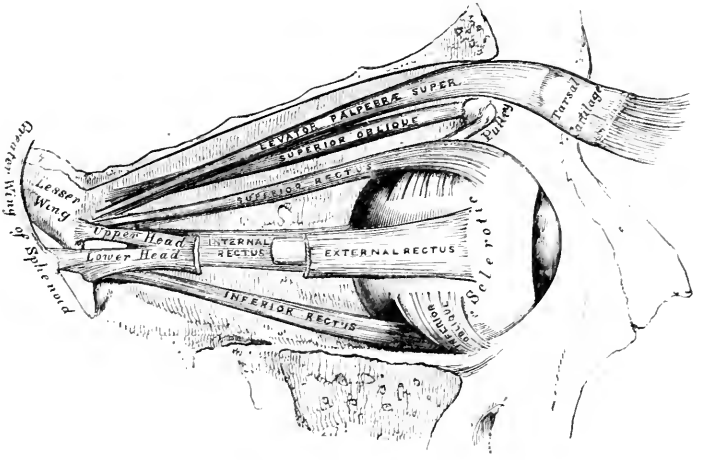

Muscles of the Right Orbit.

upper lid. With one exception, the seven muscles arise from the back part of the orbit, passing forward to their insertions. The other, the

inferior oblique, arises from the floor of the anterior portion of the orbit. They are named as follows:

The Levator Palpebræ,
The Superior Rectus,
The Inferior Rectus,
The External Rectus,
The Internal Rectus,
} Straight muscles of the eye.
The Superior Oblique,
The Inferior Oblique.

The Levator Palpebræ is thin, flat, and triangular in shape. It arises by a narrow ribbon-like band from the under surface of the lesser wing of the sphenoid bone above and in front of the optic foramen. It passes forward over the eyeball, expanding as it does so, and is inserted in the fibrous tissue on the anterior surface of the superior tarsal cartilage.

FIG. 91.

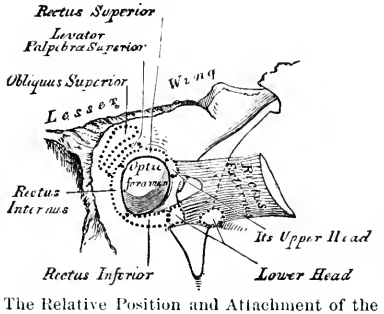

The Relative Position and Attachment of the Muscles of the Left Eyeball.

Relations.—Between the muscle and the roof of the orbit are situated the frontal nerve (branch of the ophthalmic or first division of the fifth), the fourth nerve, and the supraorbital vessels. Below it is the superior rectus and the globe of the eye where it joins the lid; it is situated behind the palpebral ligament, and its deep surface rests on the conjunctiva. A small branch of the third nerve controls its action and enters its under surface.

The Four Recti or Straight Muscles of the eye are straight, flattened bands which arise from the borders of the optic foramen; they then pass forward, as their names indicate, to be inserted into the sclerotic coat three or four lines from the cornea. With the exception of the superior rectus they may be said to have one common origin, which is in the form of an oval ring, the ligament of Zinn, which commences above, passing downward on the inner side to the lower margin of the optic foramen, thence transversely across the anterior lacerated foramen, where it is attached to the great wing of the sphenoid bone; from this it passes again to the lesser wing on the outer side of the optic foramen.

The Superior Rectus is the weakest of the four straight muscles. It has its origin between the levator palpebræ and the ring or ligament of Zinn, some of its fibres having their origin in the ring.

The Inferior Rectus principally arises from the ligament of Zinn on the inner margin of the anterior lacerated foramen.

The Internal Rectus arises from the ligament of Zinn on the inner and lower margin of the optic foramen.

The External Rectus is the strongest muscle of its group. It usually arises by two heads. *The lower head* is the stronger, and arises from the ligament of Zinn and a spine on the lower margin of the anterior lacerated foramen, and also joins the inferior rectus muscle at its origin. *The upper head* is the weaker, and arises between the anterior lacerated and

optic foramina. Fibres are given off from the two heads of the muscle, forming a tendinous arch over the foramen, through which pass the third, the nasal branch of the fifth, and the sixth nerves, also the ophthalmic vein.

The Superior Oblique, or Trochlearis, is a narrow elongated muscle situated at the upper and inner part of the orbit, internal to the levator palpebræ. It arises close to and in front of the inner margin of the optic foramen. It extends forward to the upper and inner angle of the orbit, where it becomes tendinous as it passes through a fibro-cartilaginous ring or pulley (trochlea) attached to the trochlear fossa or process, near the internal angular process of the frontal bone. The contiguous surface of the tendon and ring is lined by a delicate synovial membrane enclosed in a thin fibrous sheath. After the tendon passes through the ring it resumes its fleshy appearance; it is deflected backward, outward, and downward, and passes between the eye and the superior rectus, to be inserted into the sclerotic coat, a little beyond the outer margin of that muscle and midway between the cornea and the entrance of the optic nerve.

The Inferior Oblique is a thin, narrow muscle situated near the anterior margin of the orbit and close to the outside of the orifice of the lachrymal duct. It arises from a slight depression in the orbital plate of the superior maxillary bone near the lachrymal canal, from which it passes outward, backward, and upward between the inferior rectus and the floor of the orbit, and between the external rectus and the eyeball, terminating in a tendinous expansion which is inserted into the sclerotic coat between the external and superior recti muscles near to the insertion of the superior oblique.

Actions of the Orbital Muscles.—*The Levator Palpebræ Superioris* is the elevator of the upper eyelid, being antagonized by the upper palpebral part of the orbicularis muscle, which is the closer of the eye.

The eyeball is so suspended within the orbit that it is easily moved upon a fixed axis, but does not apparently change its position as a whole, nor do the actions of the muscles make any distinct alteration in its form. The fixed axis upon which the eye moves is nearly in the centre of the curvature of the posterior wall, and a little back of the middle of the antero-posterior axis of the eyeball.

The movement of the eye is best classified in four actions: (*a*) lateral movement (in and out): the inward motion is caused by the action of the internal rectus, the outward by the action of the external rectus; (*b*) perpendicular movement (up and down), the upward motion being caused by the superior rectus, and the downward by the inferior rectus muscles; (*c*) rotary movement, caused by the oblique muscles: the superior oblique rotates the eye inward, and at the same time turns it downward; the inferior oblique turns it outward and upward. The rotary movement of the eyeball is required when looking at an object with the head inclined to either side, in order that the vision may fall equally upon the retina of each eye. (*d*) Is a movement in which two or more muscles act together; for example, if the external and superior rectus muscles are acting with equal power, the eyeball will be directed in a line between the insertions of these muscles. It is by this

co-ordination of movement that the muscles of the orbit cause the eyeball to move in the desired direction.

Fascia of the Orbit.—The orbital space that is not occupied by the eyeball, muscles, vessels, nerves, ganglia, and glands is filled up with a soft cushion of fat and delicate yielding connective tissue. *The Capsule or Fascia of Tenon* is formed from this connective tissue. It is a thin membrane surrounding the greater part of the eyeball, and forms a socket for the globe to turn in. It arises from the borders of the orbit, passing behind the conjunctiva and giving it support, thence backward over the eyeball to the entrance of the optic nerve. The capsule is pierced behind by the optic nerve and the ciliary vessels and nerves. The tendons of the muscles of the eyeball also perforate it near their insertions, and it sends tubular prolongations over each muscle, these extensions gradually taking the appearance of simple areolar investment, except in the case of the superior oblique, to which it forms a sheath as far as the pulley of that muscle.

The sheaths of the recti muscles send prolongations from their outer surfaces to be attached to the outer margins of the orbits, which prevent too great contractions of the muscles. The prolongations from the inner and outer recti are stronger than those from the others, this being especially so with the external recti, which are attached to the malar bone and external tarsal ligament; the inner expansion is fixed to the crest of the lachrymal bone, and the upper one connected with the tendon of the levator palpebræ, thus enabling the superior rectus to have an influence in the movement of the eyelid.

The inner surface of the capsule is connected with the eye by delicate bundles of yielding connective tissue, allowing a large lymph-space to exist between the capsule and the eye, which appears to act as a synovial membrane in the movements of the globe.

The movements of the eye and its lids are to a certain extent governed by the sympathetic nerves supplying the involuntary (non-striated) muscular fibres which are found interspersed among the voluntary muscles of this region.

Nerves.—The levator palpebræ, inferior oblique, and all the recti muscles are supplied by the third nerve (motor oculi), the superior oblique by the fourth, and the external rectus by the sixth nerve.

MUSCLES OF MASTICATION.

The Masseter, the Temporal, the Internal Pterygoid, and *the External Pterygoid* are generally classed as the muscles of mastication, leading the student to infer that they are the only ones brought into action in the process. This is not correct; the first three act in closing the jaws together, while the fourth protrudes the lower jaw beyond the upper, none of them having power to open the mouth, although with the head erect the relaxation of the masseter, temporal, and internal pterygoid permits the lower jaw to drop by gravitation. The muscles of the neck open the mouth when the head is thrown backward. The mouth is rigidly closed during the tonic spasm of the first-named muscles, as in locked jaw or trismus.

The Masseter is a stout, thick, short, quadrilateral muscle extending from the zygomatic arch to the inferior maxillary bone. It is composed of two portions, *superficial* and *deep*, which differ in size and direction.

The Superficial Portion is the largest and strongest, and arises by a thick tendinous aponeurosis (which passes downward into the muscular fasciculi) from the lower border of the anterior two-thirds of the zygomatic arch and the lower margin of the malar bone: extending downward and backward, it is inserted into the lower and outer half of the angle of the jaw.

The Deep Portion is of triangular form; it is smaller and its muscular fibres are shorter than those of the superficial portion. It arises from the posterior third of the lower border and from all the internal surface of the zygomatic arch; passing downward and slightly forward, it joins some of the superficial portion, and is inserted by a tendinous aponeurosis into the upper half of the ramus and outer surface of the coronoid process of the lower jaw; only the upper and back part of the muscle is left uncovered by the superficial portion.

Relations.—It is principally covered by the skin and the fascia or platysma myoides and its own fascia, which latter adheres intimately to the tendon at its origin; at the back portion the parotid gland, the duct, which lies across the muscle, and at the anterior border turns inward, pierces the buccinator muscle and opens into the mouth through a little teat-like projection of the mucous membrane: the upper portion of the masseter muscle is overlaid by the orbicularis palpebrarum and zygomatic. A few branches of the facial nerve (seventh) and the transverse facial vessels pass over it.

The muscle lies in contact below with the ramus of the jaw and the buccinator muscle. Between the two muscles there is a large quantity of delicate fat covering a nerve and vessels which enter the muscle through the sigmoid notch.

Artery.—*The Masseteric Artery*, a branch from the second division of the internal maxillary, conveys the blood-supply.

Nerve.—The masseteric branch of the inferior maxillary (third division of the fifth).

The Temporal Fascia is a dense glistening layer of fibres forming an aponeurosis covering the temporal muscle above the zygoma, and giving origin to its superficial portion. The fascia is attached superiorly to the temporal crest of the frontal bone and to the upper of the two curved lines on the parietal bone, extending as far back as the parieto-occipito-temporal junction. It is thin and weak at its origin, becoming thicker and stronger as it approaches the zygomatic arch, near which it divides into two layers, these being separated by a quantity of compact adipose tissue; these layers are attached respectively to the inner and outer margins of the superior border of the zygomatic arch. The fascia is separated from the skin by a thin membrane which descends from the epicranial aponeurosis, and by the auricular muscles; also by some adipose tissue at the lower portion. If an abscess should form beneath this fascia or within the muscle, the pus would be directed to the coronoid process of the inferior maxilla, and thence into the mouth along the adipose tissue of this region.

The Temporal Muscle (Fig. 92) is a radiating or fan-shaped muscle situated in the temporal fossa and descending to the coronoid process of the inferior maxillary bone. It is composed of a *superficial* and a *deep* portion.

The Superficial Portion is thin and delicate, arising from the temporal fossa or aponeurosis; its fibres are continuous above with those of the

Fig. 92.

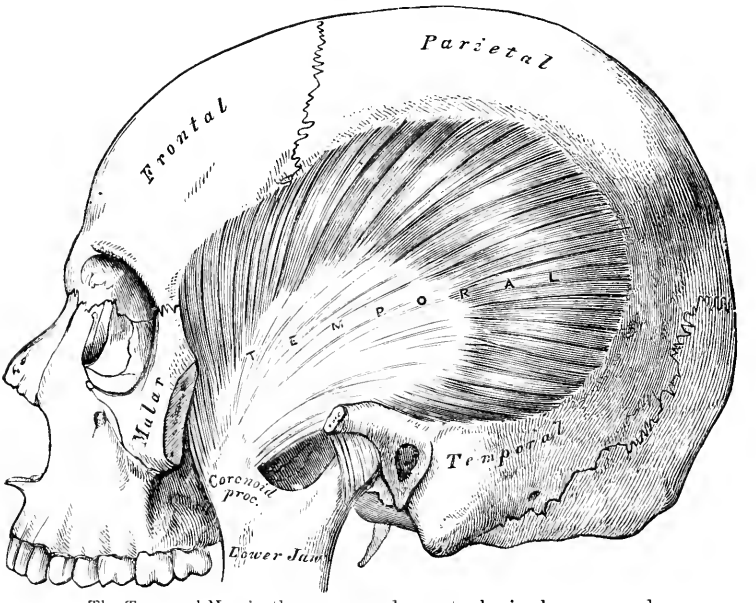

The Temporal Muscle, the zygoma and masseter having been removed.

deep portion, but are gradually lost below in the deep layer of the masseter muscle.

The Deep Portion is thick and powerful; its anterior fibres are almost vertical, while those behind pass obliquely forward. The muscle arises by fleshy fibres from all the surface of the temporal fossa except the anterior or that portion known as the orbital septum. The fibres gradually converge as they descend to form a central tendon, which is inserted chiefly into the inner surface of the coronoid process of the lower jaw.

Relations.—Its superficial surface is covered by the temporal fascia; the lower and anterior part is imbedded in fat which is a continuation of that which lies between the masseter and buccinator muscles. The upper part of its deep surface rests upon the bone; the deep temporal arteries and nerves which supply the muscle pass between the muscle and the bone; in its lower portion it is in relation with the external pterygoid and part of the buccinator, the internal maxillary artery, and temporal nerves.

Arteries.—It is supplied by the superficial temporal branches of the external carotid and the deep temporal arteries, branches of the internal maxillary.

Nerves.—Its supply is from branches of the inferior maxillary nerve.

The Internal Pterygoid (Fig. 93) is a thick quadrilateral muscle of coarse structure, interspersed with stout bands of fibrous tissue, extending from the pterygoid fossa to the inner angle of the jaw. It arises principally in the pterygoid fossa from the inner surface of the external pterygoid plate and from part of the tuberosity of the palate bone within the fossa; it also has a smaller muscular strip from the external portion of the tuberosity of the palate bone and the tuberosity of the superior maxillary bone. It passes backward, downward, and outward, and is inserted into the roughened portion on the inner side of the ramus of the jaws between the angle and the posterior dental foramen.

"The internal pterygoid muscle is an important factor in maintaining false ankylosis of the temporo-maxillary joint. After the division

FIG. 93.

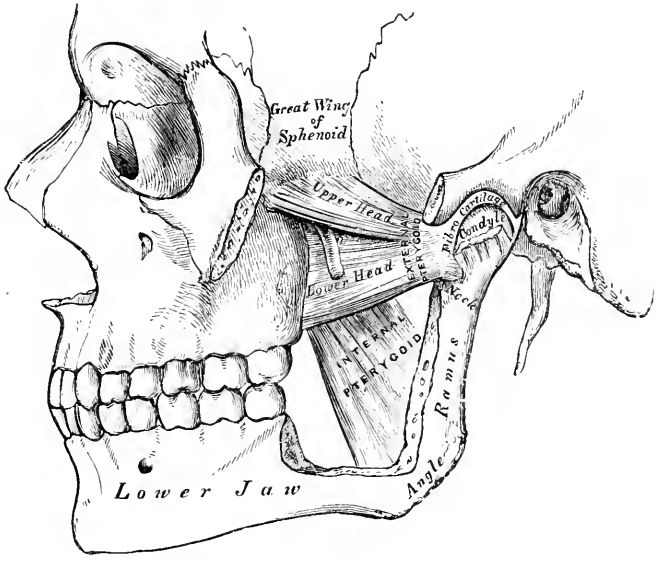

The Pterygoid Muscle: the zygomatic arch and a portion of the ramus of the jaw have been removed.

of the anterior border of the masseter muscle this condition may persist, but the ankylosis readily yields to the division of the internal pterygoid" (Allen).

Relations.—The muscle is situated on the inside of the ramus of the jaw, somewhat in the same manner as the masseter is on the outside. Between its outer or lateral surface and the ramus of the jaws are the accessory lateral ligament of the temporo-maxillary articulation, the internal maxillary vessels, and the inferior dental artery and nerve; at its upper part it is crossed by the external pterygoid muscle. Its inner or median surface is related to the tensor palati and superior constrictor of the pharynx, though there is a quantity of areolar tissue between the constrictor and the internal pterygoid muscles.

Arteries.—The internal pterygoid is supplied by branches from the second division of the internal maxillary artery.

Nerves.—Branches from the inferior maxillary division of the fifth.

The External Pterygoid is a short, thick, conical muscle, extending almost horizontally from the under surface of the great wing and the pterygoid process of the sphenoid bone to the condyle of the inferior maxilla and the interfibro-articulating cartilage of the temporo-maxillary articulation. It arises by two fleshy heads placed close together, an *inferior* and a *superior*.

The Superior Head arises from the zygomatic surface of the great wing of the sphenoid bone and the infratemporal ridge (pterygoid ridge) which separates the temporal and zygomatic fossæ.

The Inferior Head is the larger of the two, and arises from the outer surface of the external plate of the pterygoid process and the tuberosity of the palate and the superior maxillary bones.

The two heads soon unite, forming a short, stout muscle passing backward and outward almost horizontally to be inserted by two portions, *superior* and *inferior*.

The Superior Portion is inserted into the anterior portion of the interarticular fibro-cartilage of the temporo-maxillary articulation.

The Lower or Inferior Portion is attached to the depression on the anterior surface of the neck of the lower jaw.

Relations.—On its outer surface the internal maxillary artery is usually situated, passing between its two heads of origin: the buccal nerves also come out between them. The ramus of the jaws and the tendon of the temporal muscle are in relation with the outer surface. The deep surface rests upon the upper part of the internal pterygoid and the internal lateral ligament, the inferior maxillary nerve and middle meningeal artery. The superior border is crossed by the temporal and masseteric branches of the inferior maxillary nerve.

Arteries.—The muscle is supplied by a branch from the middle or second division of the internal maxillary.

Nerve.—Branch of the inferior maxillary (third division of the fifth).

Variations.—The external pterygoid sometimes receives a slip from the temporal muscle.

The Pterygoideus Proprius (Henle), not constant, is a longitudinal cleavage of the upper portion of the external pterygoid, forming a band of muscular and tendinous fibres, sometimes entirely tendinous, extending from the infratemporal crest over the external pterygoid muscle to the lower and outer portion of the external pterygoid plate, or to the tuberosities of the palate and superior maxillary bones. Occasionally it sends a slip to the pterygo-maxillary ligament or to the lower jaw.

The Pterygo-spinosus is a muscular strip occasionally found extending from the spine of the sphenoid bone to the posterior margin of the external plate of the pterygoid process, between the two pterygoid muscles. Sometimes this is replaced by a ligament, or even bone, leaving a large foramen between the pterygoid and zygomatic fossæ.

Action of the Muscles of Mastication.—With the exception of the external pterygoid, these muscles act as elevators of the inferior maxillary bone, and bring the teeth of the lower jaw forcibly into contact with the upper; the muscles which antagonize them (those which open the mouth) are of much less strength.

The external pterygoid, having its fibres directed backward, and nearly all of them horizontally, draws the condyle forward and brings the interarticular fibro-cartilage upon the eminentia articularis; when the muscles of both sides act in unison, they cause the lower jaw to project. Their action is usually alternate, causing a sort of oscillating or grinding motion of the molar teeth. The superficial portion of the masseter acts in conjunction with the external pterygoid muscle in drawing the jaw forward, while the posterior fibres of the temporal antagonize it, drawing the jaw backward, thus acting for the trituration of the food.

THE MUSCLES OF THE NECK.

The Platysma Myoides lies immediately below the skin on the side of the neck. It is a broad, thin, quadrangular, pale-colored sheet of muscular fibres, superficial to the deep cervical fascia, extending over the front and sides of the neck and the lower portion of the face. It arises by thin bands from the subcutaneous connective tissue over the deltoid, pectoral, and trapezius muscles: the fibres are directed obliquely upward and forward over the clavicle and acromion process to the side of the neck, gradually converging and approaching its fellow of the opposite side, the most anterior fibres crossing over and interlacing with each other in front of and below the chin. The greater number of fibres are inserted in the outer surface of the lower jaw, below the external oblique line anterior to the masseter muscle; others pass upward to the lower lip and angle of the mouth; while others are lost in the muscles of expression and the areolar connective tissue of the face.

Variations.—The platysma myoides of man is the rudiment of the panniculus carnosus, or great subcutaneous muscle, of quadrupeds; this may explain its many variations in the human subject. Sometimes the fibres extend upon the face and downward on the neck, shoulder, and breast farther than usual, occasionally having attachment to the clavicle, and also give off slips which pass from one muscle of expression to another. The upper part of the muscle is occasionally joined by a slip from the occipital bone or the mastoid process of the temporal; more rarely it is absent on one or both sides.

Vessels.—The numerous superficial branchings of the region.

Nerves.—The platysma myoides receives its principal nerves of motion from the descending branches of the facial; it is also influenced by some of the spinal nerves.

Relations.—Above with the skin, to which it is closely united, especially in its lower portion; by its internal surface with the pectoralis major, deltoid, trapezius, and the clavicle; in the neck with the deep cervical fascia, between which and the muscle passes the superficial cervical plexus of nerves, the external jugular vein and its tributaries, and the anterior jugular vein. In the supra-hyoid region the facial artery lies underneath it, separated by the deep cervical fascia; all the superficial cervical lymphatics, sterno-cleido-mastoideus, omo-hyoid, sterno-hyoid, and diagastric muscles are under it.

Actions.—The platysma elevates the skin of the breast and shoulder,

and when these parts are fixed it draws the angle of the mouth downward and outward. The muscle is brought into use in the act of deglutition, and also acts during sudden fright.

The Sterno-cleido-mastoideus (Fig. 94) is a long, strong muscle, extending obliquely across the neck, from the mastoid process of the temporal bone to the sternum and clavicle. It divides the surgical square of the neck into two great triangles, anterior and posterior, and is ensheathed

FIG. 94.

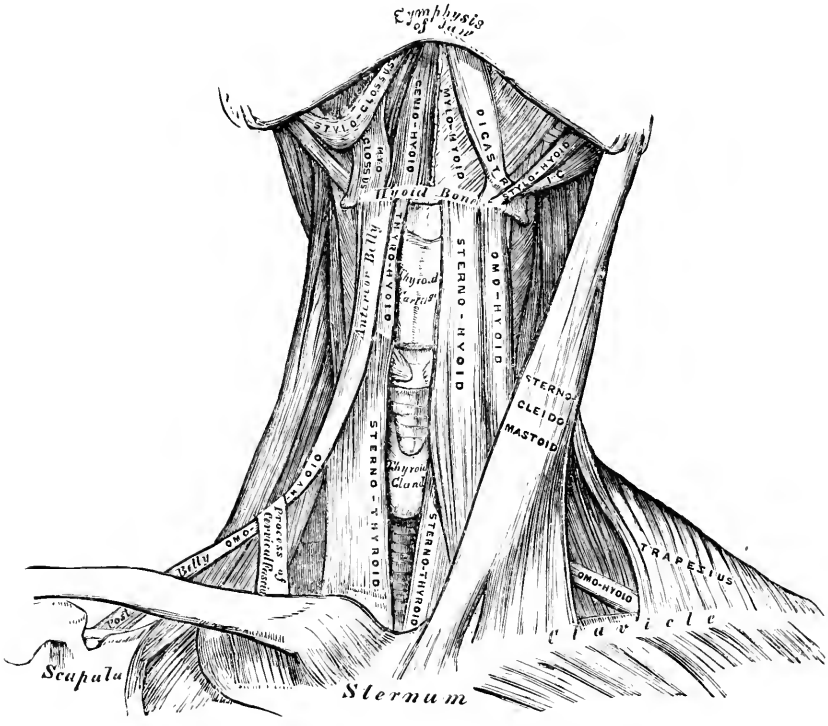

Muscles of the Neck, anterior view.

by two layers of the deep cervical fascia. It arises by two heads, the sternal and the clavicular.

The Sternal Head is thick and rounded, tendinous in front, fleshy behind, arising from the superior and outer part of the manubrium of the sternum.

The Clavicular Head is flat, and is composed of fleshy and tendinous fibres; arising from the inner third of the superior border of the clavicle, it passes almost directly upward. The triangular space between the two heads is filled up by areolar tissue. The two divisions gradually unite midway in the neck, forming a thick round prominent muscle, which extends upward and backward, and is inserted by short and strong tendinous fibres into the external surface of the mastoid process, commencing at its apex and extending upward and backward along the superior curved line of the occipital bone, or semicircular line of the

base of the skull, terminating in a thin aponeurosis where it is attached to the outer two-thirds of the line.

Relations.—Its middle three-fifths are covered superficially by the platysma myoides, the remainder by the integument, and it is crossed by the external jugular vein and the superficial branches of the cervical plexus. Its deep surface passes over the sterno-hyoid, sterno-thyroid, omo-hyoid, the posterior belly of the digastric, levator anguli scapulæ, the splenius, and the scaleni muscles; also the cervical plexus, the occipital artery, and a part of the parotid gland.

The common carotid artery, the internal jugular vein, and the pneumogastric nerve enclosed in their sheath, descendens noni, and communicaris noni nerves, pass under its anterior border, and the spinal accessory nerve pierces its upper third.

Nerves.—The muscle is supplied by the deep cervical plexus and the spinal accessory nerves.

Variations.—The muscle is sometimes divided longitudinally into two portions, called the sterno-mastoid and cleido-mastoid; they are not infrequently described as separate muscles. Part of the muscle is sometimes attached to the lower jaw; this condition is normal in the bone. Besides this, it has many other varieties (see Quain and Allen).

Action.—When both muscles are acting together, the head is brought forward, as in nodding; when extreme action is brought about, the head is drawn upon the neck and the neck upon the chest. When either muscle acts singly, especially when combined with the splenius, the head is drawn toward the shoulder of the same side, the face being rotated toward the opposite side. In the condition known as wry neck or torticollis, the muscle on one side is rigidly contracted, or the opposite muscle is paralyzed. When the head is fixed, these muscles become accessory muscles of respiration by assisting in the elevation of the thorax; it also serves to fix the clavicle, and in animals where the clavicle is lacking the muscles assist in the elevation of the arms, as their fibres are continued into the clavicular portion of the pectoralis major and the deltoid.

The Infra-hyoid Muscles.—The depressors of the hyoid bone and the larynx are the sterno-hyoid, the sterno-thyroid, the thyro-hyoid, and the omo-hyoid.

The Sterno-hyoid is a thin, flat band of longitudinal fibres, arising inconstantly from the upper and posterior portion of the sternum and the posterior sterno-clavicular ligament; from that ligament and the clavicle, or from the clavicle alone; and occasionally it partially arises from the cartilage of the first rib. The fibres pass upward, and are inserted into the body of the hyoid bone near the inner side of the omo-hyoid muscle.

Relations.—Its superficial surface below is covered by the sternum and sternal end of the clavicle, and by the sterno-cleido-mastoid and the platysma myoides muscles above. Its deep surface passes over the sterno-thyroid, crico-thyroid, and thyro-hyoid muscles, and in part the thyroid gland, the superior thyroid vessel, and the crico-thyroid and thyro-hyoid membranes. The mesial borders of the two muscles vary in their proximity: at the upper third there is a slight interval; in the middle

third they approach each other, and are again separated as they near the clavicle. Close to the hyoid bone the outer margin is in contact with the omo-hyoid muscle.

Action.—To depress the hyoid bone.

The Sterno-thyroid muscle is shorter and broader than the sterno-hyoid, and is under that muscle. It arises near its fellow of the opposite side from the posterior surface of the manubrium (first bone of the sternum), below and nearer the median line than the origin of the sterno-hyoid muscle, and inconstantly from the first and second costal cartilages. It ascends, and, diverging from its fellow of the opposite side, is inserted into the oblique line on the ala of the thyroid cartilage.

Relations.—Its superficial surface is in contact with the sternum, sterno-cleido-mastoid, and the sterno-hyoid muscles. The deep surface rests upon the innominate vein, the lower part of the common carotid artery, the trachea, and the thyroid gland.

Action.—It depresses the thyroid cartilage and indirectly the floor of the mouth.

The Thyro-hyoid is a small quadrilateral muscle, its fibres interlacing with the sterno-thyroid, of which it is, to all appearance, a continuation. It arises on the oblique line on the ala of the thyroid cartilage; it passes upward and is inserted into the lower border of the body and great cornu of the hyoid bone.

Relations.—Its superficial surface is in contact with the sterno-hyoid and omo-hyoid muscles. Its under surface rests upon the thyroid cartilage and thyro-hyoid membrane. The superior laryngeal nerve and artery pass between the membrane and muscle before entering the larynx.

Actions.—The thyro-hyoid muscle raises the thyroid cartilage, or, when that body is fixed, it lowers the hyoid bone.

Nerve.—The muscle is supplied by a branch of the hypoglossal nerve.

The Omo-hyoid is a long, ribbon-shaped muscle, with two bellies united by an intervening tendon; it extends from the shoulder to the hyoid bone, crossing the neck diagonally and dividing the anterior and posterior surgical triangles into four. The muscle arises from the upper border of the scapula, near the suprascapular notch; it passes forward and slightly upward, in a flattened narrow fasciculus, across the lower portion of the neck to the point at which it lies beneath the sterno-cleido-mastoid muscle, when it becomes tendinous, the tendon being held down by a loop formed from the deep fascia, which has an attachment to the cartilage of the first rib; it then passes nearly vertically close to the outer border of the sterno-hyoid muscle, to be inserted into the lower border of the body of the hyoid bone, in close proximity to, and outside of, the sterno-hyoid muscle.

Relations.—The superficial surface with the trapezius and sterno-cleido-mastoid muscles, the deep cervical fascia, the platysma myoides, and the integument. Its under surface passes over the scaleni, the brachial plexus, the sheath containing the common carotid artery, the internal jugular vein and pneumogastric nerve, the noni nerve, and the sterno-hyoid and sterno-thyroid muscles.

Variations.—The muscle is sometimes divided throughout or in part;

occasionally only one belly is present, or the anterior belly is sometimes fused with the sterno-hyoid muscle.

Action.—It depresses and carries the hyoid bone backward; it is also a tensor of the cervical fascia.

THE MUSCLES OF THE SUPRA-HYOID SPACE.

The muscles of the supra-hyoid space (Fig. 95) are the digastric, stylo-hyoid, mylo-hyoid, genio-hyoid, genio-glossus, lingualis, hyo-glossus, and stylo-glossus.

The Digastric, as its name implies, is a double-bellied muscle, one posterior and one anterior, extending from the mastoid portion of the temporal bone to the anterior part of the lower jaw. *The posterior belly*

FIG. 95.

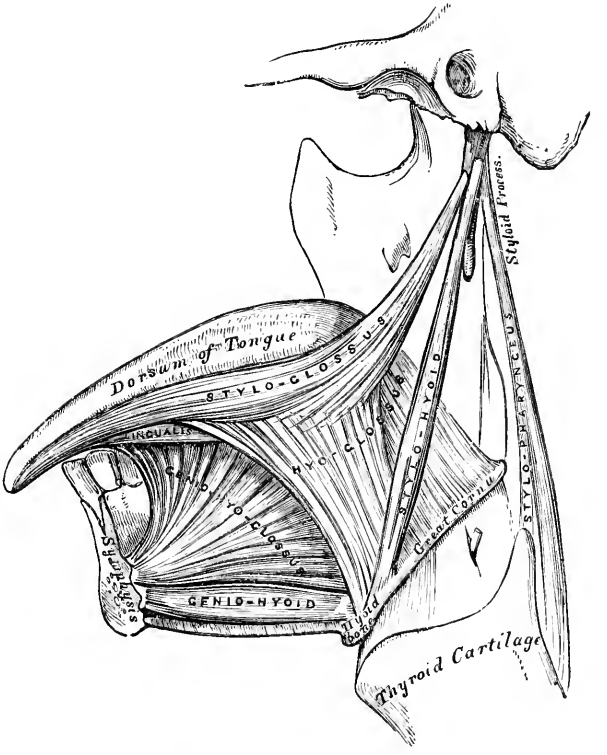

Muscles of the Tongue, left side.

is the longer and narrower of the two, and arises from the digastric groove of the temporal bone, close to the stylo-mastoid foramen; passing downward, forward, and inward, it gradually diminishes as it approaches the hyoid bone, and is lost in a tendon which usually passes through the stylo-hyoid muscle near its insertion, and also through its aponeurotic loop, which is lined by a synovial membrane,

and holds it in connection with the body and the great cornu of the hyoid bone. *The anterior belly* is shorter and broader than the posterior. It commences at the intermuscular tendon, passes upward and forward, and is inserted into the rough depression on the internal lower border of the inferior maxillary bone near the symphysis: its fibres sometimes decussate with those of its fellow-muscle on the opposite side.

Stretching between the intermediate tendons and sheaths of the anterior portions of these muscles of each side is a broad layer of fascia known as the *supra-hyoid aponeurosis*, which is also attached to the great cornu of the hyoid bone and the anterior bellies of each muscle; this gives a firm support for the other muscles in the supra-hyoid space. This aponeurosis corresponds to a layer of muscular fibres belonging to the digastric muscle of some of the lower animals.

The digastric muscle subdivides the anterior superior surgical triangle of the neck into the submaxillary and superior carotid triangles.

The Submaxillary Triangle is inverted, the base being above, and is bounded by the lower border of the inferior maxillary bone and a line to the mastoid process; the other or lower sides are formed by the two bellies of the digastric muscle, its tendon being held down by a loop of fibrous tissue which forms the inferior angle. The outer or superficial surface of this triangle is covered by a firm layer of the deep fascia attached below to the tendon and to the bellies of the muscle, above to the body of the inferior maxilla and to the fascia which extends over the parotid gland. The inner surface is bounded by a deep layer of the same fascia attached below to the tendon and muscle, while above it is lost in the sheaths of the muscles of the floor of the mouth. Surgically considered, it is continuous over these muscles, and is attached to the lower border of the mylo-hyoid ridge of the lower jaw. In the tumefaction of the submaxillary gland the enlargement exhibits a triangular form on account of the shape of this envelope.

The Superior Carotid Triangle is bounded above by the posterior belly of the digastric, below by the omo-hyoid, and behind by the sterno-cleido-mastoid muscle, its apex presenting anteriorly at the loop of the digastric and insertion of the stylo-hyoid muscle. The importance of this triangle to the surgeon is due to the fact that in it are found the points for ligation of many arteries.

Relations.—The anterior belly of the digastric muscle is more superficial than the posterior; its outer surface being covered by the platysma myoides and the deep cervical fascia, its deep surface rests upon the mylo-hyoid muscle. Its posterior belly is deeply covered by the mastoid process of the temporal bone, the sterno-cleido-mastoid, and part of the stylo-hyoid muscles, a lobule of the parotid gland, and part of the submaxillary gland. Its deep surface is in relation with the transverse process of the atlas, the internal jugular vein, the internal carotid artery, and the origins of the facial and lingual arteries. The hypoglossal nerve lies a little below the tendon.

Variations.—This muscle has many variations, and, like the omo-hyoid, the entire muscle may be divided through one or both bellies. The posterior belly may receive an accessory slip from the styloid process, the angle of the jaw bone, or the splenius muscle; it has been

known to arise entirely from the styloid process. In rare instances the muscle has been monogastric, in which case it is inserted into the middle of the lower jaw. Slips may pass from the anterior belly to the hyoid bone. The tendon does not always pass through the stylo-hyoid muscle.

The Mento-hyoid (Macalister) is an occasional slip found passing from the body of the hyoid bone to the chin. It is sometimes composed of parallel bands, and Macalister suggests that it may be a differentiated portion of the platysma myoides.

Nerves.—The posterior belly of the muscle is supplied by the facial (seventh), and the anterior by the mylo-hyoid branch of the inferior dental nerve.

Actions.—The digastric muscles act in antagonism to the muscles of mastication by assisting in depressing the inferior maxilla. When the lower jaw is firmly fixed by the masticatory muscles, the digastric assists in elevating the hyoid bone.

The Stylo-hyoid is a small slender muscle situated along the upper border of the posterior belly of the digastric. It arises by a narrow tendon from the upper half of the outer surface of the styloid process of the temporal bone. It passes downward, forward, and inward, to be inserted into the hyoid bone at the junction of the great cornu with the body. It is usually divided into two portions near its insertion for the transmission of the digastric muscle.

Relations.—These are almost identical with those of the posterior belly of the digastric muscle.

Variations.—The variations of the muscle are numerous: amongst them may be noted cleavage throughout its whole course, forming two muscles, in some instances three. It is occasionally placed on the inner side of the external carotid artery; the insertion is sometimes partially or wholly in the tendon of the digastric muscle. It may be fused with the omo-hyoid, thyro-hyoid, or mylo-hyoid muscles at the hyoid bone. It may send slips to the lower jaw. Its place of origin varies; sometimes there is an extra slip given off from the styloid process and inserted into the small cornu, and accompanying or taking the place of the stylo-hyoid ligament.

Nerves.—The muscle is supplied by the facial nerve.

Action.—To elevate and draw backward the hyoid bone.

The Stylo-hyoid Ligament.—This being so intimately associated with this group of muscles, it will receive next consideration. The ligament is a thin fibrous cord developed from the deep fascia attached to the lower portion of the styloid process, passing downward, forward, and inward, to be inserted into the lesser cornu of the hyoid bone. Sometimes this ligament is of a cartilaginous nature, and even ossifies. In many animals it is naturally osseous, and is named the epihyal bone.

The Mylo-hyoid is a triangular flat muscle placed between the inferior maxillary and hyoid bones, and with its fellow of the opposite side forms the muscular floor of the mouth (diaphragma oris, Meyer). It arises from the mylo-hyoid (internal oblique) ridge of the lower jaw, extending from about the third molar tooth to the symphysis. At its insertion it is divided into two portions, a posterior and an anterior.

The Posterior Portion consists of those fibres which give the muscle its name. They pass downward, inward, and backward, to be inserted into the body of the hyoid bone.

The Anterior Portion passes in a more oblique direction, and is not inserted into the hyoid bone, but into an indistinct intermuscular raphé which extends from the symphysis of the jaw to the centre of the hyoid bone; the muscular fibres are the longest near the hyoid bone, and gradually grow shorter as the symphysis of the jaw is approached.

Relations.—The mylo-hyoid muscle forms the floor of the mouth, and at the same time part of the roof of the neck, thus giving it an oral or superior and a cervical or inferior surface. The *cervical surface* is in relation with the submaxillary muco-salivary gland, the anterior belly of the digastric muscle, the facial artery and its submental branches, and the mylo-hyoid vessels and nerves. *The oral surface* is in relation with the genio-hyoid, genio-glossus, parts of the hyo-glossus and stylo-glossus muscles; also the lingual branch of the fifth and twelfth nerves, the sublingual gland, and the mucous membrane of the alveolo-lingual groove. Its posterior border is free, a part of the submaxillary muco-salivary gland curving around it to the upper surface, the duct of the gland (duct of Wharton) passing along the upper surface of the muscle.

Variations.—Sometimes the raphé is absent; in such cases the fibres of each muscle interlace. It may be fused with the anterior belly of the digastric muscle, or it may be entirely lacking and be substituted by the digastric. Slips are sometimes received from some of the other hyoid muscles. Occasionally the anterior portion of the muscle is deficient, its origin extending no farther than the cuspid teeth: this muscle is sometimes perforated and dissected by the lobules and duct of the submaxillary muco-salivary gland.

Nerves.—The mylo-hyoid nerve, a branch of the inferior maxillary.

Action.—The mylo-hyoid muscle draws the hyoid bone forward and upward, and slightly assists in opening the mouth.

The Genio-hyoid is a narrow muscle extending from the symphysis of the chin to the hyoid bone. It arises from the inferior genial tubercle (mental spine) on the inner side of the inferior maxillary bone, and passes downward and backward to be inserted into the anterior portion of the hyoid bone.

Relations.—Below with the mylo-hyoid muscle, above with the genio-glossus and with its fellow on the proximal border.

Variations.—The genio-hyoid may separate into two muscles, or it may be united with the muscle of the opposite side. Slight variations may be found between its origin and insertion.

Nerve.—The genio-hyoid is supplied by a branch of the hypoglossal nerve.

Action.—Same as the mylo-hyoid—to elevate and draw forward the hyoid bone and to depress the lower jaw.

The Genio-glossus (often called genio-hyo-glossus, from its supposed insertion on the body of the hyoid bone) is a thin, flat, radiating muscle, placed vertically on each side of the median line in front of the tongue. It arises by a short tendon from the superior genial tubercle (mental spine) on the inner aspect of the inferior maxillary

bone; from the tendon its fibres diverge from before backward, and are inserted mainly into the under surface and body of the tongue, constituting the bulk of the structure of that organ. Some of its fibres pass backward to the hyoid bone and to the side of the pharynx.

Relations.—On its median surface with its fellow of the opposite side, from which it is separated within the tongue by the median raphé. Its lateral surfaces are in contact with the lingualis, hyo-glossus, and stylo-glossus muscles, the sublingual, the ranine vessel, the gustatory nerve, and sublingual glands. The terminal portion of the hypoglossal nerve penetrates its posterior part. The frænum linguæ is formed by the union of the anterior upper borders of the two genio-glossus muscles, which are covered by mucous membrane.

Variations.—This muscle is sometimes united with the genio-hyoid muscle, or it may give a few fine bundles to the epiglottis, to the stylo-hyoid, or to the smaller cornu of the hyoid bone.

Nerve.—This muscle is supplied by the hypoglossal nerve.

Action.—To draw forward and protrude the tongue.

The Lingualis muscle is a longitudinal fasciculus placed in the substance of the tongue, arising at the base and extending between the hyo-glossus and genio-glossus muscles to the apex of the organ. Some of its fibres intermingle with the stylo-glossus and hyo-glossus. The ranine artery (the terminal portion of the lingual artery) passes along its under surface.

The Hyo-glossus is a thin quadrate muscle, arising from the upper border and the lateral portion of the great cornu of the hyoid bone, also from the lesser cornu. Its fibres pass upward and slightly forward to the posterior half and lateral portions of the tongue; they then spread inward and forward over the dorsum, joining those of the stylo-glossus toward the apex.

Relations.—The hyo-glossus is related by its external surface with the digastric, stylo-hyoid, stylo-glossus, and mylo-hyoid muscles, also the deep part of the submaxillary muco-salivary gland, and is crossed from below upward by the duct of Wharton and by the hypoglossal and lingual nerves. Its internal surface rests upon the posterior portion of the genio-glossus and the origin of the middle constrictor of the pharynx; it is crossed by the lingual artery and the glosso-pharyngeal nerve.

Variations.—The lingual artery occasionally passes through the muscle near the hyoid bone; it is at times composed of a number of separate bundles. The muscles sometimes receive a slip, tritieeo-glossus (Bochdalek), from the thyro-hyoid ligament, which passes upward and forward, lying on the inner side of the lingual artery and joining the hyo-glossus.

Nerves.—The muscle receives branches of the hypoglossal nerve.

Action.—To aid in depressing the tongue.

The Stylo-glossus is the shortest and smallest of the styloid muscles, and passes from the styloid process to the tongue. It arises from the outer and anterior portion of the apex of the process, and passes forward and slightly downward and inward to the posterior part of the tongue, where it divides into two portions, the *longitudinal* and the *oblique*.

The Longitudinal Portion passes forward, and is inserted along the

side of the tongue as far as the tip, blending with the fibres of the lingualis in front of the hyo-glossus.

The Oblique Portion passes slightly downward over the hyo-glossus, its fibres interlacing with those of that muscle and those of the palato-glossus.

Relations.—On its lateral surface the stylo-glossus is associated with the parotid gland, the internal pterygoid muscle, sublingual gland, gustatory nerve, and mucous membrane of the mouth; the internal surface with the tonsils, the superior constrictor of the pharynx, and the hyo-glossus muscle.

Variations.—The muscle has many variations, sometimes being absent; at others it has been found to be double. It may receive slips or may arise entirely from the angle of the jaw, the stylo-maxillary ligament, the internal pterygoid muscle, or the tympanic portion of the temporal bone. Slips may pass to the pharynx.

Nerves.—Its nerve-supply is derived from the hypoglossal.

Action.—To assist in retracting and elevating the tongue.

THE MUSCLES OF THE PHARYNX AND THE SOFT PALATE.

This group (Fig. 96) includes the superior constrictor, middle constrictor, inferior constrictor, stylo-pharyngeus, palato-pharyngeus, palato-glossus, palato-Eustachian or tensor palati, levator palati, and azygos uvulæ.

FIG. 96.

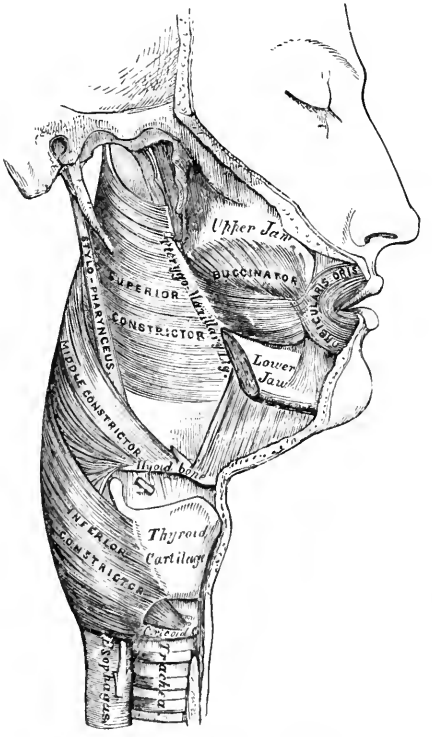

Muscles of the Pharynx, external view.

The Superior Constrictor muscle of the pharynx is a thin quadrilateral muscle, situated, as its name implies, at the upper portion of this muscular pouch: its fibres are paler than those of the middle and inferior muscles. It arises, commencing from above downward, from the lower third of the free margin of the internal pterygoid plate and its hamular process, the tuberosity of the palate bone, the reflected tendon of the palato-Eustachian or tensor palati muscle, and the pterygo-maxillary ligament—at which point some of its fibres are continuous from the buccinator; it also arises from the posterior extremity of the mylo-hyoid ridge, the mucous membrane of the mouth, and the sides of the tongue continuous with the genio-glossus muscle. The

fibres from these various points of origin pass backward and curve inward until they meet those of the opposite side, where many of the fibres interlace. The remainder are inserted into the median line of the pharyngeal raphé, in front of the cervical vertebræ, and a few of the fibres are inserted in the pharyngeal spine and the aponeurosis attached to the basilar process of the occipital bone.

The upper margin of the muscle is concave, being suspended at its corners by the pterygoid process in front and the pharyngeal aponeurosis behind. The surface between the border of the muscle and the base of the brain-case is occupied by the pharyngeal aponeurosis, the lower border of which becomes part of the wall of the pharynx, and is covered by the middle constrictor muscle.

Variations.—The different heads of origin may be from various muscles. The azygos pharyngis (Meckel) is a slip arising from the pharyngeal spine and inserted into the posterior pharyngeal wall.

Relations.—To the outer surface of the muscle are the cervical vertebræ, the internal carotid artery, the pneumogastric, the glosso-pharyngeal, and spinal accessory nerves, the middle constrictor and the stylo-pharyngeus muscles; related to its inner surface are the palato-pharyngeus muscle and the tonsils. The origin of the levator palati muscle and the Eustachian fossa are also near to this surface.

Nerves—The nerve-supply is derived from the pharyngeal plexus.

Actions.—When it contracts, the pterygoid portion, being fixed at both its origin and insertion, straightens the curvature of the superior border and, at the same time, narrows the diameter of the naso-pharynx. The pterygo-maxillary and inferior maxillary portions assist in drawing the posterior wall of the pharynx forward.

The Middle Constrictor of the Pharynx is a flattened radiating muscle situated on a plane below the superior constrictor. It arises from the greater and lesser cornua of the hyoid bone and the stylo-hyoid ligament. The fibres radiate as they pass backward, and, curving inward, are inserted in the posterior median raphé, some of them interlacing with those of the opposite muscle. The extent of their insertion is from below the level of the hyoid bone to a position near the occipital bone. The lower portions descend beneath the inferior constrictor as it passes backward, while the upper fibres ascend and overlap those of the superior constrictor, the middle portion passing directly backward.

Variations.—As in the previous muscle, the slips arising from different points of origin, as those from the greater and lesser cornua, may serve as separate and distinct muscles. Fibres may be received from the body of the hyoid bone, and a slip (cyndesmo-pharyngeus, Douglas) from the thyro-hyoid ligament is frequently present. Fibres may also arise from the tongue and posterior part of the mylo-hyoid ridge of the inferior maxilla, and interlace with the genio-glossus, as does the superior constrictor. The upper fibres may reach the occipital bone.

Relations.—The external and posterior surface with the longus colli and rectus anticus major; laterally, the carotid vessels, the pharyngeal plexus, and some lymphatic glands. The inferior constrictor overlaps its lower portion. The stylo-pharyngeus muscle passes between the superior and middle constrictors, and the superior laryngeal nerve lies

between the middle and inferior constrictors on its way to the thyro-hyoid membrane. The internal surface where it does not overlap the superior muscle is covered by mucous membrane and the stylo-pharyngeus and the palato-pharyngeus muscles.

Nerves.—The nerve-supply is from the pharyngeal plexus.

Actions.—The upper fibres assist in elevating the hyoid bone and all the structures connected with it; it also draws forward the posterior pharyngeal wall.

The Inferior Constrictor muscle of the pharynx is the broadest, thickest, and shortest of the three, and lies the most superficially. As its name implies, it is at the lower or inferior portion of the pharynx. It arises from various points, commencing below at the lower and posterior part of the cricoid cartilage, and from a tendinous arch between the cricoid and thyroid cartilages, from the inferior cornu and the oblique line and upper border of the thyroid cartilage. From these points of origin the fibres pass backward and upward, and, curving inward, join the raphé and the fibres of its fellow from the opposite side. The fibres of the lower portion are the shortest; their direction is horizontal, and they combine with those of the œsophagus without a line of demarcation. The balance of the fibres are about one-eighth of an inch below the basilar process, and pass upward and backward, with an increase of obliquity, to the posterior median line of the pharynx, covering more than half its length.

Variations.—The muscle sometimes receives a fasciculus from the thyro-hyoid, crico-thyroid, and sterno-thyroid muscles, or even from the trachea.

Relations.—The external surface posteriorly is in apposition with the cervical vertebræ and the muscles of this region; laterally with the thyroid gland, the carotid arteries, and the sterno-hyoid muscles, the internal surface of the middle constrictor, the stylo-pharyngeus, and the palato-pharyngeus muscles, also the mucous membrane of the pharynx. The superior laryngeal nerve and vessels pass over the upper border to the larynx, and the inferior ascend beneath its lower border.

Nerves.—The muscle is supplied by the pharyngeal plexus and the external laryngeal nerve.

Actions.—It assists in propelling the bolus of food into the œsophagus, reduces the size of the lower part of the pharynx, and can act independently of the other muscles of the set.

The Stylo-pharyngeus muscle is slender, though the largest and longest of the styloid set: above it is round; below it is broad and thin. It arises from the inner side and near the base of the styloid process, passes downward and inward between the superior and middle constrictors of the pharynx, and gradually expands under the mucous membrane, some of its fibres being inserted into the lateral walls of the pharynx and united with the palato-pharyngeus: these are inserted into the posterior border of the thyroid cartilage.

The glosso-pharyngeal nerve accompanies this muscle, commencing on the outer side, and crosses over on its way to the tongue.

Variations.—Cleavage or doubling of the stylo-pharyngeus muscle is frequent; occasionally it has been found divided into three. Super-

numerary elevators of the pharynx are frequently present; they arise from the base of the skull in juxtaposition to the styloid process, or from the petrous process of the temporal bone (anterior to the carotid foramen) or the vaginal process of the same bone. These muscles are named the petro-pharyngeus, which arises from the petrous portion; spheno-pharyngeus, from the spine of the sphenoid; pterygo-pharyngeus externus, from the hamular process; occipito-pharyngeus, from the basilar process; pharyngo-mastoideus, from the mastoid process: the last named is very rare. The azygos pharyngis is frequently classed in

FIG. 97.

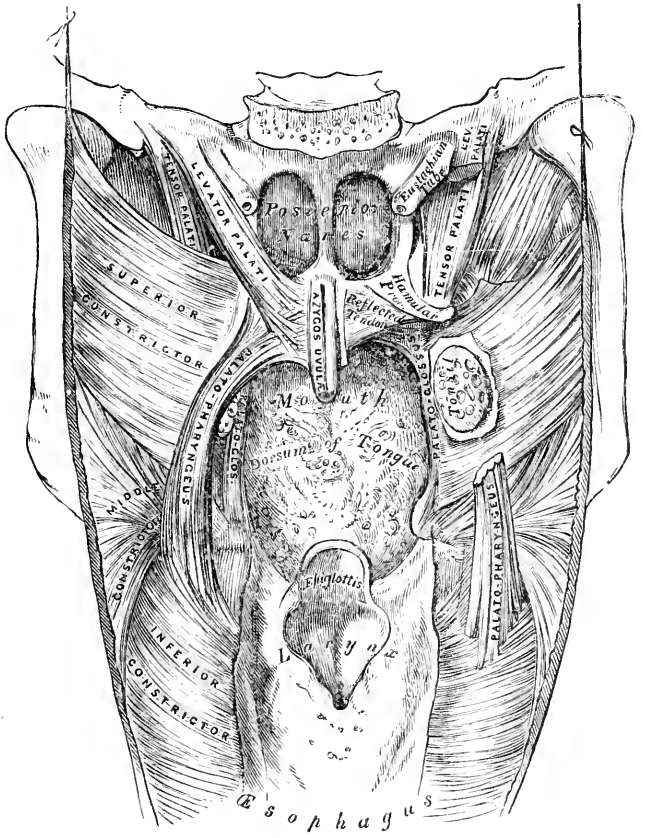

Muscles of the Soft Palate, the Pharynx being laid open from behind.

this group: a description of it is given with that of the superior constrictor of the pharynx.

Nerves.—This muscle receives branches from the glosso-pharyngeal nerve.

Action.—To assist in elevating the pharynx.

The Palato-pharyngeus muscle (Fig. 97) is long and narrow, wider at the extremities than in the middle, and extends from the soft palate to the pharynx; it arises in the soft palate by an anterior and a pos-

terior portion, which embrace the levator palati and the azygos uvulæ muscles.

The Anterior Head or Portion is the thickest; the fibres at the commencement near the median line of the palate are associated with those of the opposite side; they pass outward between the levator and tensor palati muscles; fibres are also received from the free edge of the hard palate and the aponeurosis of the velum.

The Posterior Head or Portion consists of scattered fibres, commencing in the median line and associating with those of the opposite side.

At the edge of the soft palate the two portions unite, and receive two slender bundles which arise from the inferior and anterior part of the Eustachian tube (salpingo-pharyngeus, Santorini); from this it passes outward, downward, and backward posteriorly to the tonsils; it spreads out, joining the fibres of the stylo-pharyngeus muscle, and is inserted mainly into the superior and posterior border of the thyroid cartilage. The remainder of its fibres are received into the fibrous layer of the inferior part of the pharynx, passing as far as, or crossing, the median line, and interlacing with those of the opposite side.

This muscle and the mucous membrane covering it form the palato-pharyngeal fold, or "posterior half arch."

Relations.—At its origin the soft palate. Its anterior and posterior surfaces are covered by mucous membrane, a layer of palatine glands resting between the membrane and the muscle. Its superior surface is related with the levator palati muscle. In the pharynx it passes between the mucous membrane and the constrictor muscles.

Nerves.—Branches of nerves from Meckel's ganglion (spheno-palatine).

Action.—To elevate the pharynx in deglutition, the palate having first been elevated by the levator palati. In its action it assumes a nearly vertical position in the posterior part of the pharynx. Allen[1] and Yule[2] conclude from observation that the palato-pharyngeus is the chief factor in opening the Eustachian tube; it also keeps the soft palate in position during respiration.

The Palato-glossus is a small muscle extending from the soft palate to the posterior part of the tongue; it is narrower in the middle than at its origin or insertion, and arises from the under surface of the soft palate near the base of the uvula, the fibres of each side interlacing at their origins. It passes downward, forward, and outward along the lateral wall of the pharynx, anterior to the tonsils, and is inserted, with the stylo-glossus, into the side and base of the tongue. This muscle and the mucous membrane covering it form the palato-glossus fold, or "anterior half arch."

Relations.—It passes downward along the outer wall of the pharynx, between the constrictors and the mucous membrane.

Nerves.—Branches of the facial.

Action.—To depress and draw slightly forward the palate and assist in elevating and drawing back the tongue. Allen[3] observes: "Both muscles, acting together, depress the soft palate and draw it forward,

[1] Allen's "Memoir on Soft Palate," *Trans. Amer. Med. Assoc.*, 1872, p. 537.
[2] *Journal of Anat. and Phys.*, viii., 1873. [3] Allen's *Human Anatomy*, p. 259.

and in the act of sucking constrict the nipple. Each muscle may be looked upon as a sphincter on a deeper plane than the lips, but like it in nature, and it is supplied by the same motor nerve—viz. the facial. It is also a noteworthy fact that the plane of the two muscles limits the region of involution of the epiblast, so that the palato-glossal muscles are less splanchnic than the pharyngeal muscles proper."

The Palato-Eustachian, or Tensor Palati, is a broad thin muscle extending from the orifice of the Eustachian tube to the palate, and having a vertical and a horizontal portion.

The Vertical Portion arises from the scaphoid fossa at the root of the pterygoid plates, the spinous process of the sphenoid bone, and the lower and outer side of the Eustachian tube. Its flattened belly descends perpendicularly between the inner side of the internal pterygoid muscle and the outer side of the inner pterygoid plate, at the lower portion of which it becomes a tendon and passes around the hamular process, and continues thence to its insertion, forming the horizontal portion of the muscle. There is a synovial bursa in connection with the tendon and the process which allows the tendon to work backward and forward.

The Horizontal Portion passes inward, and is inserted into the aponeurosis of the soft palate and transverse ridge on the under surface of the palate bone.

Relations.—Vertical portion, on its external surface, with the internal pterygoid muscle; internal surface with the levator palati muscle. Horizontal portion, at the point of its insertion into the soft palate; the aponeurotic expansion is anterior to the levator palati muscle; the under surface is covered by mucous membrane.

Nerves.—The muscle is supplied by branches from the otic ganglion.

Action.—The palato-Eustachian, or tensor palati, has generally been supposed to make the palate tense, and for this reason severance of the tendon at the hamular process previous to performing the operation of staphylorrhaphy was frequently favored. The principal function of the muscle is now considered to be to open the orifice of the Eustachian tube.

The Levator Palati is a long, thin, round muscle, extending from the temporal bone to the palate at the lateral borders of the posterior nares. It arises by a narrow tendon from the under surface of the petrous portion of the temporal bone, anterior to the carotid canal, and from the lower margin of the cartilage of the Eustachian tube, thence passing downward, inward, and forward into the pharynx over the concave margin of the superior constrictor, spreading out as it approaches the soft palate, where the anterior and lesser part is inserted into the aponeurosis of the palate; the posterior or larger part meets the fibres from the opposite side underneath the azygos uvulæ muscle.

Relations.—Its lateral surface with the tensor palati and superior constrictor muscles; the internal surface is covered with mucous membrane.

Actions.—"With reference to the soft palate: the muscle elevates the soft palate and makes it tense, since the right and left muscles act synchronously. With reference to the Eustachian tube: the shortening of the body of the muscle, together with the increase of its diameter, has a

tendency to close the orifice of the tube by elevating the lower border. The action of the levator palati can readily be studied in the living subject by the rhinal mirror. By such aid the course of the muscle, even when at rest, can be seen corresponding to an oblique fold of mucous membrane, which may receive the name of the salpingo-palatal fold. The levator palati receives much attention in the improved operation of staphylorrhaphy. Fergusson, having noticed the influence of this muscle in widening the cleft in the soft palate, essays its division before uniting the freshened edges. This procedure is now an established antecedent to the operation.

"The actions of the levator palati and tensor palati muscles have been the subject of controversy. Valsalva as long ago as 1742 described both the above muscles as dilators of the tube. Toynbee[1] in 1853 revived Valsalva's account, and later Rüdinger and other German writers have accepted this as the true action. Respecting the tensor palati, Henle[2] is inclined to adopt the view that the muscle closes the orifice; while, as seen in another part of the same volume (p. 117), he doubts the ability of the muscle to close the tube. His views upon the function of the levator palati agree with those expressed in the text.

"The author has long taught that the contraction of the levator palati narrows the pharyngeal orifice of the tube. This action can be readily seen in the living subject by the aid of reflected light. Cleland[3] studied the action of the same muscles in a man who had lost the soft palate by ulceration. He doubts the efficacy of the tensor palati in dilating the tube, while he assigns to the levator palati its proper function, in assisting to narrow the orifice. That the Eustachian tube (*q. v.*) is always patulous in health, and that while certain muscles tend to narrow its lumen none can obliterate it, seem to be fair deductions from its nature."[4]

The Azygos Uvulæ is not a single muscle, as its name implies, but consists of a pair of narrow fasciculi, arising, one on each side, from the posterior palatine spine of the palate bone and the aponeurosis of the soft palate, the fibres passing backward to be inserted into the uvula.

Nerves.—The muscle is controlled by the facial nerve.

Action.—To contract the uvula.

Mucous Membrane and its Glands.

Mucous membrane forms the lining of all cavities and canals having an external opening, such as the respiratory tracts, the passages transmitting food in its various forms, and all outlets for excretive and secretive fluids. The surface of the membrane is soft and yielding, and is covered by a thick glistening, tenacious, transparent fluid called mucus, which is secreted by numerous small glands hereafter to be described. The mucus protects the membrane beneath from any deleterious matter contained in foods, either in a solid state or in the form of solution.

The mucous membrane of the body can be divided into two great systems—the genito-urinary and the gastro-pneumonic—each being complete and continuous in itself.

[1] *Trans. Phil. Soc. Lond.*, 1853.
[2] *Anatomie*, i. 755.
[3] *Journal of Anat. and Phys.*, iii., 1869, 97.
[4] Allen's *Human Anatomy*, pp. 259, 260.

The Genito-urinary System is that which, commencing at the kidneys, lines the urinary passages of both sexes, passing through the ureters, bladder, and urethra, also the sexual organs, as the seminal ducts and vesicles of the male, the vagina, uterus, and Fallopian tubes of the female.

The Gastro-pneumonic System lines the alimentary canal and all ducts and glands which open into it; this system invests the air-passages from the opening of the nostrils to the air-vesicles of the lungs. It also lines the frontal sinuses and air-cells which communicate with them or the air-passages. The membrane passes from the nasal chamber through the Eustachian tube to the ear, also through the lachrymal ducts to the eyes and lachrymal glands. The latter gland is developed from a solid ingrowth of the conjunctiva.

The construction of the mucous membrane is very similar to that of the skin, being developed from two layers of the blastoderm—the skin from the epiblast and mesoblast, the mucous membrane (with certain exceptions) from the hypo- and mesoblast: it is divided into two layers, epithelium and corium, separated by an intermediate or basement-membrane.

Epithelium of Mucous Membrane.—The epithelial layer is the most constant part of mucous membrane—*i. e.* it passes over and into parts where the corium cannot be traced, as in the alveoli of the lungs and upon the cornea of the eye: it is developed, with the exception hereafter given, from the lower layer (hypoblastic) of the blastoderm. This layer is variously classified, either according to its function or to the shape and arrangement of the cells entering into its formation, as simple, stratified, and transitional, the simple variety being again subdivided into pavement, columnar, spheroidal or glandular, and ciliated.

When classified according to function, it is arranged as protective and secretory, the first division being made up of stratified, transitional, ciliated, and pavement varieties; the latter is divided into columnar and spheroidal (glandular).

The Epithelium of the Oral Cavity.—The epithelium within the oral cavity is regarded as squamous stratified epithelium: the same variety is also found in the lower part of the larynx, upon the edges of the epiglottis, the true vocal cords, and in the œsophagus; also in the anterior two-thirds of the nasal chamber.

The general arrangement of cells in the epithelium is very similar to that of the epiderm; its deep or Malpighian layer contains very little pigment, and is columnar in form, though this is not the case in embryonal life—the stratum granulosum and stratum lucidum of the epiderm are not present; but with this exception the development, growth, maintenance, and desquamation are the same. It is analogous with the skin, and is developed from the same layer of the blastoderm, which extends internally as far as the palato-glossal fold, and sometimes farther.

Should any portion of the mucous membrane of the mouth become constantly exposed to the action of the atmosphere as the result of surgical operations or other cause, it will assume the horny character of the skin. In like manner, should any part of the skin become part of the

oral cavity, or be continuously subjected to the action of the fluids of the mouth, it will take upon itself the functions and characteristics of mucous membrane, assuming greater translucency, its cells becoming comparatively thin, some of them having small nuclei.

In the olfactory portion of the nasal chamber, the upper part of the pharynx, also in the larynx, trachea, and bronchi, the cellular investment is made up of stratified cylindrical ciliated epithelium.

The epithelial cells of the mucous membrane are slightly separated, but, like those of the skin, are held together by an intercellular cement substance, and it is through this cement substance that absorption (very slight) takes place when medicaments are placed either on the skin or mucous membrane; as they pass through they enter the lymph-spaces in the areolar connective tissue, and in this way get into the circulation through the larger lymphatics.

The Corium of the mucous membrane lies immediately beneath the basement-membrane, but is not always demonstrable. It is made up very similarly to the corresponding layer of the skin—*i. e.* of areolar connective tissue, sometimes containing a large intermixture of lymphoid tissue. It also contains white and yellow fibrous connective tissue, muscular tissue, vessels, lymphatics, and nerves. The corium varies in thickness according to its locality. In the œsophagus, bladder, and vagina the fibrous tissue is abundant, forming almost a compact web and making the mucous membrane of these parts somewhat stout and tough. In other parts, as in the stomach and intestines, the tissue is retiform or lymphoid, lacking the white elastic tissue. Along the side and beneath the tongue in the alveolo-lingual groove, also at the base of the tongue and the epiglottis, and from that to the side of the pharynx, the corium is exceedingly loose and pliable.

On the alveolar processes of the inferior and superior maxillary bones this layer is made up of dense connective tissue, and is firmly attached to the membrane immediately upon the bone which forms the gum tissue or muco-periosteum (Allen). This muco-periosteum has both the function of mucous membrane and periosteum, and it is through it that the bone receives nourishment. When the membrane is lost or destroyed, necrosis takes place the same as in bones which are supplied with a true periosteum. Where cartilage is covered by mucous membrane, as in the septum of the nose, Eustachian tubes, the larynx, etc., it is called muco-perichondrium (Allen), and acts as a nourisher and protector to the cartilage similarly to the perichondrium of cartilage.

Upon the hard palate the muco-periosteum is united by a fine trabecula to the ridges of the bony surface. In the interspaces and within the muco-periosteum there are small racemose glands. Upon the soft palate it is more firmly adherent at the anterior surface than the posterior, where it comes in contact with the gland tissue. It is found on the roof of the pharynx attached to the aponeurotic membrane of the base of the skull, and upon the tongue it is firmly attached and forms the cortex.

Blood-vessels of the mucous membrane are generally very abundant. The branches of the arteries and veins divide and subdivide in the submucous tissue as in the skin, and pass into the corium, where they again

divide and form a complete network of capillaries. This network, when present, lies below the basement-membrane, projecting into the papillæ of the papillary layer. The tubular and other glandular apparatus are abundantly supplied with nourishment by this vascular rete, which surrounds them for that purpose.

Lymphatics are found in the form of a network in the mucous membrane, communicating with larger vessels in the submucous layer.

Nerves.—When muscular fibres exist in mucous membrane, the nerves are chiefly distributed to them, also to the glandular apparatus; there are also ganglionic plexuses in the submucous tissue. Some terminal nerves have been found to pass through into the epithelium and terminate between the epithelial cells: this appears to have been demonstrated in the epithelium of the mucous membrane of the palate of a rabbit.[1]

Papillæ and *Villi* are found upon some parts of the mucous membrane: the former are conspicuous upon the tongue, as hereafter described, and the latter are abundant and fully developed on the mucous membrane of the small intestines.

The Secretory Glands of the Mucous Membrane.—The secretory glands are organs which vary in structure and in their secretion; part of them are situated within the mucous membrane, while others are at various distances from it, though in all instances their ducts open upon its surface. Although they differ considerably in their function and locality, they have an embryonal derivation similar to that of the epithelial tissue upon which their ducts empty their fluid; their development usually begins during intra-uterine life. These glands are essentially made up of one or more layers of secreting cells, usually resting upon a basement-membrane. Immediately below the basement-membrane there is an abundant supply of fine blood-vessels; when the membrane is absent, the vessels are in close contact with the attached ends of the cells.

Enlargement of secreting surfaces of any part is generally by *recession* or *inversion* (there are examples in nature where the increase of surface is produced by protrusion or an elevation), which is carried from very simple forms to various degrees of complexity. The first or most rudimentary of these varieties is a recess, the result of the dipping down of the Malpighian layer into the subepithelial tissue, and forming what is sometimes called an epithelial sac, the shape of which is *tubular* or *saccular*. This simple tube sometimes lengthens considerably and coils upon itself, forming a ball, which is known as a *coiled tube*. The sweat-glands of the skin are of this kind, and are formed by the dipping down of the lower strata of the cells or the embryonal Malpighian strata. These embryonal cells are not columnar in shape, as found in adult tissue, and have been described by Zeigler[2] thus: "The cell by itself appears originally as a microscopic mass of pale, finely-granular matter, the so-called protoplasm. It usually contains within it a nucleus—that is to say, a structure like a tiny vesicle—whose form may be round,

[1] Quain's *Anatomy*.

[2] From a paper read by Dr. W. X. Sudduth before the Odontographic Society, Oct., 1884.

rod-like, or irregular, and in whose interior we can make out, by proper handling, (1) small definite bodies, the nucleus corpuscles; (2) a net-like framework of nucleus substances; and (3) a clear fluid, the nucleus juice. The young cell is at first naked; only in its matured stages does it develop on its surface an optically distinct membrane or other structure according to the special tissue of which it forms a part."

The cells of the embryonal Malpighian layer dip down into the subepithelial connective tissue (the corium) and form epithelial buds, which are the commencement of the mucous glands, although varying in shape according to their locality and function. The glands, judging from the nature of their epithelial lining, can be described under three general modifications: I. Simple tubular mucous glands; II. Compound tubular mucous glands; III. Compound tubular salivary glands.

I. Simple Tubular Mucous Glands (Fig. 98).—The crypts or follicles of Lieberkühn that are found in the intestinal canal may be taken as typical glands of this class. They usually present the shape of a test-tube, formed of the epithelium, the cæcal end pushing the basement-membrane into the corium or substance of the mucous membrane, the tube opening on the surface. The cells lining the tubes are of a single layer, and apparently of the same character and continuous with the columnar epithelial cells of the surface. They are well distributed within the mucous membrane, varying in number and kind according to locality. They are generally placed perpendicularly to the surface, and often close together, in which position they constitute the bulk of the mucous membrane, the thickness of the membrane often depending upon the length of the tubes, which differs in different localities. The cells are short, cubical, or columnar, possessing a spherical or oval nucleus. Although the gland-tubes are usually single, some are bifurcated at the deep extremity, and the lower end may be somewhat enlarged in its diameter.

Fig. 98.

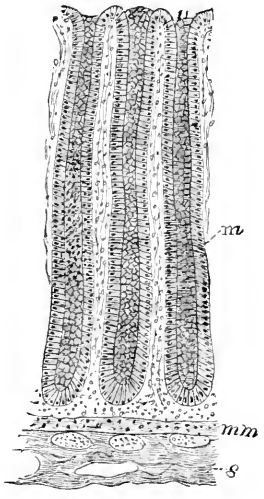

From a vertical section through the Mucous Membrane of the Large Intestines of a Dog showing, *m*, the crypts of Lieberkühn closely placed side by side, each crypt lined with a layer of columnar epithelium; *mm*, muscularis mucosæ; *s*, submucosæ.

These glands are found in large numbers in the stomach, large and small intestines, and the uterus.

Simple tubular glands occasionally have their secreting surfaces increased by becoming pouched or loculated.

II. Compound Tubular Mucous Glands.—The mucous glands found in the mouth and the glands of Brunner in the intestines are typical of this class, being small racemose glands. These glands open upon the surface of the mucous membrane with a funnel-shaped mouth, from which a duct passes in an oblique direction (the angle of obliquity not always being the same) through the corium into the submucous

tissue, at which point the duct divides into several smaller ones, each of which enlarges immediately after bifurcation and forms a separate infundibulum; the tubes again narrow and make several irregular turns or convolutions, and have a cæcal termination. It is these small twisted tubes that form the secreting part of the gland. The epithelium lining the glands varies in their different portions: the funnel-shaped mouth has in man a stratified or pavement epithelium.

The duct proper is lined by a single layer of long, narrow, columnar cells with intracellular and intranuclear network, giving a distinct longitudinal striation and slightly granular appearance to the cell. The calibre of the duct is of considerable width.

The infundibular portion is lined with more or less flattened epithelial cells, which gives comparatively a wide lumen to this portion of the gland. The epithelial cells lining the convoluted portion of the small tubes are columnar and very slightly granular, with a round or oval nucleus situated near the outer end of the cell. The cell and nucleus are made up of a network of fibrils, forming rather large meshes when the gland is fully developed.

When the gland is active the cell contains drops of mucin; but when it is inactive the cells are shorter, and become very granular and somewhat opaque; the lumen of this part of the gland is large.

The epithelium of these glands rests upon the basement-membrane, and is made up of connective-tissue cells which are more branched, some of the branches penetrating the septa between the intercellular cement which holds them together.

Sometimes in the convoluted portion of the glands several embryonal cells are found; these are located between the columnar epithelium and the cells forming the basement-membrane or connective tissue of the tubes.

These compound tubular glands sometimes assume a saccular form, thus giving us the names of tubular, saccular, or racemose glands.

Sacculo-tubular glands are those which are intermediate in form between saccular and tubular. The saccules or acini have a tubular form.

The racemose glands, so called from their resemblance to bunches of grapes, are modifications of the compound tubular glands, containing a multitude of saccules having a rounded, pyriform, or thimble shape; they are arranged in clusters, forming lobules and open into the extremities of the branched tubes; these tubes form ducts which join other saccular ducts, forming larger branches of the clusters or lobules; the lobular branches join together and form the main duct or ducts of the whole gland, which empties its fluid upon the mucous membrane. The size of the gland usually depends upon the number of lobules or clusters and the number of saccules in a lobule; thus there are the small racemose glands, as those of the roof of the mouth, and others of large size, like the parotid.

Mucus.—The fluid that is secreted by these glands is viscid, lubric, and transparent. Examined under the microscope, it is found to contain epithelial cells, also round cells or mucous corpuscles. They so closely resemble the white or pale blood-corpuscles that they are con-

sidered identical with them, having either migrated directly from the blood-capillaries or from the lymphoid tissue surrounding the glands. The number of mucous corpuscles depends on the glands which produce the mucus; they vary according to locality.

III. Compound Tubular Salivary Glands.—These, generally speaking, are six in number, three on each side, named sublingual, submaxillary, and parotid.

The minute anatomy and the physiological action of the salivary glands prompted Lavdowsky to classify them into three groups: 1. Mucous glands; 2. True salivary glands; 3. Muco-salivary glands.

Mucous Glands.—Examples: submaxillary and orbital glands of the dog (Fig. 99) and cat and the sublingual glands of man. They are similar to, though larger than, the compound tubular glands of the mucous membrane of the mouth; their general construction is the same, with the exception of the epithelial lining of the convoluted portion of the tube, which is composed of mucous cells—the same kind of epithelial cells as described in the mucous membrane—and the parietal cells, or crescents of Gianuzzi. These cells are somewhat similar to the embryonal cell already described; they stain deeper than the surrounding tissue with hæmotoxylin and eosin, thus showing their protoplastic condition; they are granular in appearance, and form semilunar masses without definite membrane, but with projections that fit into the irregular-shaped spaces between the epithelial mucous cells and the basement-membrane with which they are in contact. The lumen of the convoluted portion is open and of considerable size.

Fig. 99.

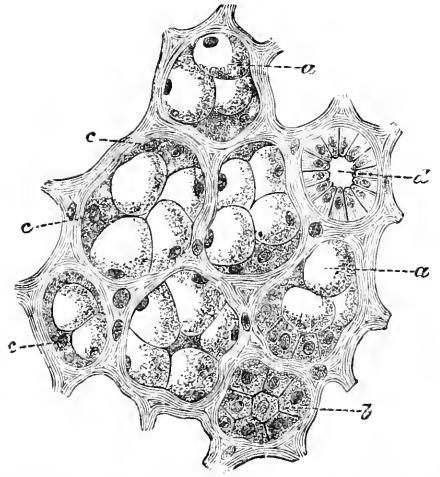

Submaxillary Gland of the Dog: *a*, mucous cells; *b*, protoplasm cells; *c*, demilune of Gianuzzi; *d*, transverse section of an excretory duct, with its peculiar columnar epithelial cells.

When these glands are stimulated to secretion, either through the natural source or by artificial means, the mucous cells at first increase in size, and a viscous fluid is secreted which passes out by the ducts; after the action has been continued a short time, the cell-nucleus changes its shape and position, becoming smaller and granular, more rounded and central, and the cell takes a deeper stain with carmine. If this stimulation be prolonged until the glands become exhausted, the mucous cells lose their identity, and are either lost by being carried off in the mucus, or they become granular and look like the parietal cells found next to the basement-membrane.

"Heidenhain and Lavdowsky have asserted that they are destroyed, and that their places are taken by a process of new cell-formation from the parietal areas; but Ewald regards these smaller granular cells as the

shrunken remains of the mucous cells, consequent on exhaustion; and Klein is of the opinion that such is in reality the case; for, arguing by analogy, he finds that excessive stimulation results in structural changes which have already been noted, and accompanied by watery secretion—*i. e.* the cells have evidently discharged all their mucin, and have collapsed and become both morphologically and physiologically like those of the true salivary glands. He also states that in the submaxillary gland of young animals all gradations are met with from small alveoli with small lumen lined only with small granular cells, and alveoli somewhat larger and lined either partly with mucous cells, partly with granular cells, or altogether with mucous cells, to which are applied from place to place groups of granular cells."[1]

The True Salivary Glands.—Examples: the parotid gland of mammals, parts of the submaxillary gland of man and the guinea-pig, the orbital and submaxillary glands of the rabbit. These are also compound tubular glands, and the general anatomical form is the same. The epithelial cells lining the convoluted secreting tubes or alveoli are different, consequently their function is not the same (Fig. 100). Its epithelial cells are cubical, though the angles are somewhat rounded; they are placed in a simple layer, contain a spherical nucleus placed near the basement-membrane, and are united with those of the cell proper, forming together irregular and small meshes. When the gland is inactive these meshes contain a small quantity of fluid substance. In osmic preparations the cell appears to be packed full of distinct granules of an albuminous nature which obscure the nuclei.

FIG. 100.

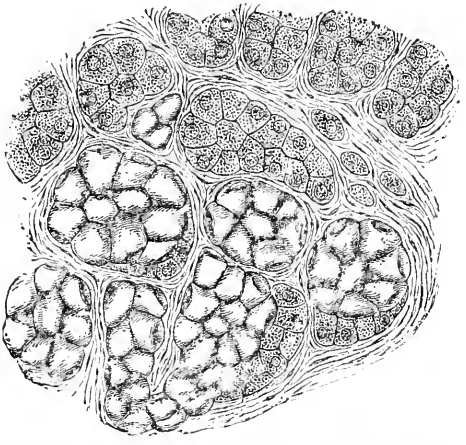

Section of part of the Human Submaxillary Gland. To the right of the figure is a group of mucous alveoli, to the left a group of serous alveoli.

Between the cells and basement-membrane there are quantities of embryonal cells (crescents of Gianuzzi), though not so abundant as in the glands last described.

The lumen in the convoluted portion of these glands is quite different from that of the mucous glands; it is doubted by some whether it is open at all. In the embryonal cell the protoplasm or intercellular cement so completely fills the tube that it is not discernible.

"After a short period of activity the granules are found to have disappeared in the outer part of the cell, the inner part being still distinctly granular, and some granules, being apparently free within the lumen of the alveolus [tube], now becoming distinct (Fig. 101). With more prolonged activity the clear outer part increases in extent, and the

[1] Coles's *Microscopical Science.*

granules are found only in the part of the cells which is close to the lumen, and in those parts which are contiguous to the adjacent cells (corresponding, perhaps, to fine capillary clefts which pass from the cavity of the alveolus between the cells). The nuclei have now become

FIG. 101.

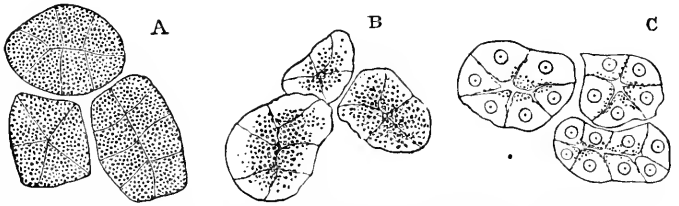

Alveoli of a Serous Gland: A, at rest; B, after a short period of activity; C, after a prolonged period of activity. In A and B the nuclei are obscured by the granules of zymogen.

distinct and the cells are smaller; we may suppose, therefore, that the granules, which no doubt contain the specific elements of secretion, are formed by or from the protoplasm of the cells during rest, and are discharged into the lumen and dissolved during activity. Probably, however, during activity, new granules are constantly being formed and passed outward toward the lumen. According to Langley, the three processes—of growth of the clear protoplasm, conversion of this into granules, and discharge of these into the lumen—are all proceeding simultaneously in different parts of the cell during activity."[1]

The Muco-salivary Glands.—Examples: the submaxillary glands of man and of the guinea-pig. They are all compound glands with a double function, which makes their anatomy complicated. Some of the lobules composing the gland are constructed and their functions are the same as those of the pure mucous glands (sublingual gland of man), while other lobules are constructed and their functions are the same as the pure salivary glands (the parotid of man); even some of the convoluted tubes in the same lobule differ, some having the function of secreting mucus, while others secrete saliva.

"Besides these three forms, Bermann has observed that in connection with a large gland of Wharton's duct in many mammals he has discovered a compound tubular mucous gland of unique structure."[2]

The special mucous and salivary glands associated with the mouth, nose, and pharynx are labial, buccal, molar, palatine, lingual, parotid, submaxillary, sublingual, and lachrymal.

The Labial Glands are of two kinds—the mucous and sebaceous. The mucous glands are small round racemose or compound tubular glands about the size of small peas, situated between the mucous membrane and the orbicularis oris muscle; their ducts open upon the mucous membrane. The sebaceous glands are small, and situated on the outer part of the red margin of the lip.

The Buccal Glands are small round racemose or compound tubular glands (smaller than the labial), situated between the mucous membrane and buccinator muscle; the ducts open upon the mucous membrane.

The Molar Glands are small round racemose or compound tubular

[1] Quain's *Anatomy*, 9th ed.

[2] Coles's *Microscopical Science.*

glands (larger than the buccal glands), situated between the buccinator and masseter muscles, and having separate ducts, which have their orifices near the third molar tooth.

The Palatine Glands are situated in the deep portion of the muco-periosteum of the hard palate and under the mucous membrane of the oral and nasal surfaces of the soft palate and uvula; they are small, round, racemose, or compound tubular glands, and form a continuous layer upon each side of the roof of the mouth, but are absent in the median line.

The Lingual Glands are of two kinds—the small racemose or compound tubular and the simple tubular variety—situated under the mucous membrane, principally on the posterior portion of the upper surface of the tongue near the circumvallate papillæ and foramen cæcum, several of the ducts of the glands opening into the foramen. Those which open near the circumvallate papillæ, and where the taste-buds are situated, secrete a watery fluid instead of mucus, as was formerly supposed. These glands are also found under the mucous mem-

FIG. 102.

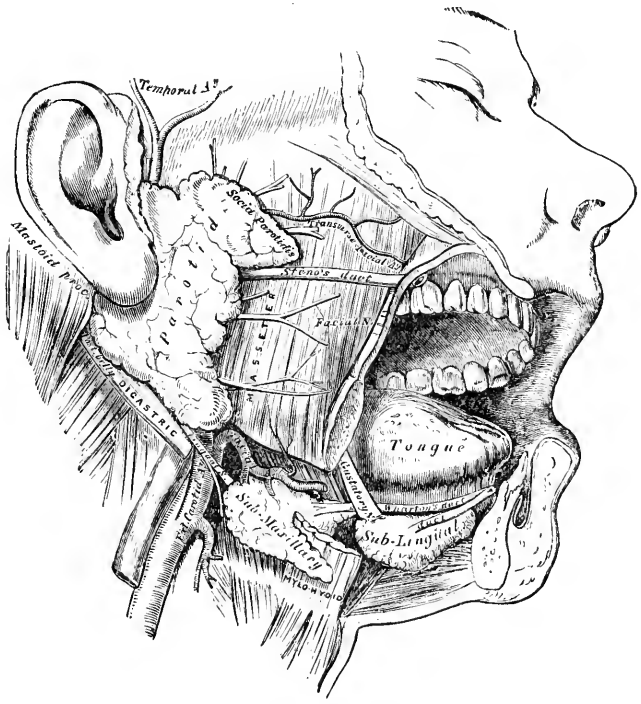

The Salivary Glands.

brane on the borders of the tongue. On the under surface of the tongue, near its apex, a number of these glands are grouped together, forming a small oblong mass having several ducts in a line, which open upon the mucous membrane.

The Parotid Gland (Fig. 102), so named from being situated near

the ear, is the largest of the salivary glands. Its size varies considerably in different people, the average weight being one ounce. It is a compound tubular racemose salivary gland.

Situation.—The Parotid Space is bounded in great part by a bony framework, although the gland is not confined by the lines of the bony structures. Anteriorly, it is bounded by the ramus of the inferior maxillary bone; posteriorly, by the mastoid and styloid processes and the tympanic portion of the temporal bone; its superior boundary is formed by the convergence of the above structures; below, the boundary is formed by an imaginary line drawn from the angle of the jaw to the sterno-cleido-mastoid muscle. Between the mastoid and styloid processes the gland comes in juxtaposition with the transverse processes of the upper cervical vertebræ, especially the atlas. Upon examination of an articulated skeleton it will be observed that by depressing the head upon the chest this bony space will be decreased by the jaw coming closer to the vertebræ, while in the movement of raising or extending the head it is enlarged. By protruding the lower jaw until the inferior teeth articulate outside the superior, the space also is enlarged. If the jaw is depressed the space becomes compressed below, while above it is increased by the slipping forward of the condyle.

The parotid gland has a very irregular shape; its superficial surface is convex and lobulated and in close relation with its external fascia. The anterior surface is divided by a perpendicular groove into an external and an internal portion, the external of which extends forward to a varied extent over the masseter muscle. It is from this anterior portion that the parotid duct (duct of Steno) is given off; the internal portion passes forward on the inside of the ramus between the pterygoid muscles.

The deep portion of the gland passes far inward toward the base of the skull, vertebræ, and pharynx; the upper portion passes into and occupies the posterior part of the glenoid fossa; the posterior and lower portion rests upon the styloid process and its muscles, the sterno-cleido-mastoid and digastric.

The Glandula Socia Parotidis, or Accessory Parotid, is a small separate lobe, not always present, situated at the anterior external border, below the zygomatic arch and upon the masseter muscle. The duct of this lobe enters the parotid duct, where it crosses the masseter muscle.

The Parotid Duct, or Duct of Steno (or Steno's canal), is about two and a half inches in length, its diameter varying at different portions, its orifice being the narrowest part, only permitting the entrance of a small probe. Where it pierces the buccinator muscle it is as large as a crowquill, and at the position where it passes over the masseter muscle it is from one-twelfth to one-eighth of an inch in diameter. The duct commences at the anterior portion of the gland, leads over the masseter muscle about one finger's breadth below the zygomatic arch, and passes forward beneath an imaginary line drawn from the lower margin of the concha of the ear to a point midway between the ala of the nose and the red margin of the upper lip, the transverse facial artery lying above it. At the anterior border of the masseter muscle the duct makes a short curve, almost at a right angle, inward; thence it passes through the cushion of fat and the buccinator muscle; continuing

obliquely forward a short distance beneath the mucous membrane, it has its outlet through a small papilla opposite the crown of the second superior molar tooth.

The Parotid Fascia.—The gland is closely encased in a covering derived from the deep cervical fascia. The superficial layer of the parotid fascia is dense and strong, arising posteriorly from the sheath covering the sterno-cleido-mastoid muscle; after passing over the gland it is continuous anteriorly with the sheath of the masseter muscle. Above, it is attached to the zygomatic arch; below, to its own deep leaflet.

The Deep Layer of the parotid fascia is neither so strong nor so dense as its superficial; below, it is formed from a division of the deep cervical fascia where it passes beneath the gland to be inserted into the base of the skull; it forms the stylo-maxillary ligament, and is connected with the sheaths of the pterygoid muscles, leaving a space or gap between the anterior edge of the styloid process and the posterior border of the external pterygoid muscle. Thus it will be seen that the gland is tightly bound down upon the outside by a close covering, while within it is not so. The opening in the deep fascia spoken of above gives communication between the parotid space and the connective tissue above the pharynx.

The *arteries* of the gland are very numerous, consisting of a branch direct from the external carotid, and branchlets from the divisions of that trunk in its immediate vicinity, as the internal maxillary, temporal, transversalis, facial, posterior auricular. The *veins* follow a similar course. The external carotid in passing behind the ramus of the jaw enters the gland, not at the lowest portion, but at its inner and anterior surface, and passes slightly backward and outward, becoming more superficial as it ascends.

The *lymphatic glands* join those of the deep and superficial parts of the neck, one or more being found in the substance of the parotid, and others upon its surface. These glands are liable to become enlarged and form a species of parotid tumor.

The nerves are derived from the facial, the auriculo-temporal, great auricular, and the sympathetic plexus of the external carotid artery. Experiments upon the dog and cat have shown that the cerebro-spinal nerve-supply to this gland is from the glosso-pharyngeal. In addition to the above are the lesser superficial petrosal nerve and the otic ganglion, the fibres finally being distributed to the gland through a branch of the auriculo-temporal. The facial nerve passes through the gland, though not so intimately bound up in its substance as is the carotid artery.

The Submaxillary Gland—so named from its position beneath the maxillary bone—is smaller than the parotid, and weighs about two or two and a half drachms. It is a muco-salivary gland, derived from epiblastic structure. The lobules comprising the gland are not held so tightly together as are those of the parotid, though they are more defined. The gland is situated below the mylo-hyoid ridge of the inferior maxillary bone in the submaxillary depression and in the submaxillary triangle of the neck, which is bounded by the mylo-hyoid ridge of the bone and a line drawn backward to the digastric groove of the temporal bone above. The lower boundaries are composed of the posterior and ante-

rior bellies of the digastric muscle. It is covered externally by the superficial layer of the submaxillary fascia, the platysma myoides muscle, and the skin; internally by its deep fascia, which separates it from the mylo-hyoid, hyo-glossus, and stylo-glossus muscles. The gland extends backward to the posterior border of the mylo-hyoid muscle, where it sometimes passes around its border to the upper surface, and is separated, at the posterior part, from the parotid gland by the stylo-hyoid ligament.

The Submaxillary Duct (Wharton's), through which the secretion of the above gland passes to the mouth, is about two inches in length, and its coats are not so thick as those of the parotid duct. It commences by the union of the ducts originating in the different lobules near the posterior surface of the gland, and with some of the tissue of the gland winds around the posterior border of the mylo-hyoid muscle. It then passes forward and inward over the muscle and beneath the hyo-glossus and the sublingual gland, terminating in a narrow opening through a soft papilla at the side of the frænum linguæ, near the duct on the opposite side. Occasionally isolated lobules of gland tissue are found along the duct.

The arteries which supply the gland are branches of the facial and lingual. The veins belong to the facial and lingual.

Its nerve-supply is derived from the submaxillary ganglion, which obtains its motor filaments from the chorda tympani, and its sensory from the lingual branch of the inferior maxillary—sometimes, though seldom, from the mylo-hyoid, a branch of the inferior dental; the sympathetic nerve branches from those accompanying the arteries in this vicinity.

Fig. 103.

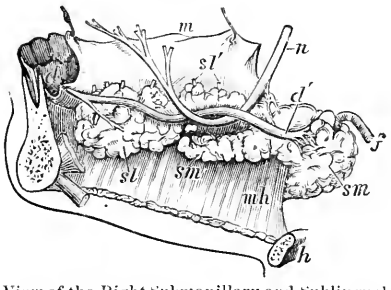

View of the Right Submaxillary and Sublingual Glands, from the inside. Part of the right side of the jaw, divided from the left at the symphysis, remains; the tongue and its muscles have been removed, and the mucous membrane of the right side has been dissected off and hooked upward, so as to expose the sublingual glands. *sm*, the larger superficial part of the submaxillary gland; *f*, the facial artery passing through it; *sm'*, deep portion prolonged on the inner side of the mylo-hyoid muscle, *mh*; *sl* is placed below the anterior large part of the sublingual gland, with the duct of Partholin partly shown; *sl'*, placed above the hinder small end of the gland, indicates one or two of the ducts perforating the mucous membrane; *d*, the papilla, at which the duct of Wharton opens in front behind the incisor teeth; *d'*, the commencement of the duct; *h*, the hyoid bone; *n*, the gustatory nerve; close to it is the submaxillary ganglion.

The Sublingual or Gland of Bartholin (Fig. 103) is so named from its position under the tongue. It is smaller than the submaxillary gland, and secretes mucus only. The lobules of this gland are not, as in the parotid and submaxillary, united into one with a single duct leading from it, but are divided into several smaller glands, each having an independent duct. They are arranged in a narrow, oblong form situated beneath the mucous membrane of the mouth, forming a ridge in the alveolo-lingual groove. The ridge commences in front of the tongue near the frænum, and in close proximity to the gland of the opposite side; it extends backward and outward about one and a half inches to near the first molar tooth. The inner surface of

the gland is in relation with the genio-glossus muscle, its lower surface with the mylo-hyoid, and closely relates with the submaxillary duct and the lingual branch of the fifth nerve.

The sublingual or ducts of Rivinus vary in number from eight to twenty, corresponding generally to the lobules contained in the gland; they open separately upon the surface of the mucous membrane over the ridge formed by the gland, and a few may open into the submaxillary duct.

The Duct of Bartholin is a single duct of the sublingual gland formed by the confluence of small ducts arising from the posterior lobules, which, at times, receive small branches from the submaxillary gland. It passes in close proximity to the submaxillary duct, and either opens into it or upon the mucous membrane near the orifice of the latter duct.

The *blood-vessels* of the sublingual gland are from the submaxillary and sublingual arteries and the veins.

The *nerve-supply* is derived from the submaxillary ganglion.

The Lachrymal Gland and its Ducts (Figs. 104, 105) *leading to the Nasal Chamber.*—The lachrymal gland is situated principally within

FIG. 104.

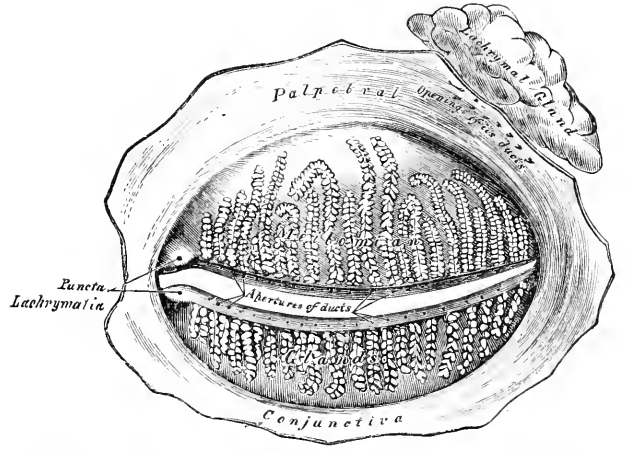

The Meibomian Glands, etc., seen from the inner surface of the eyelids.

the lachrymal fossa of the frontal bone, at the superior lateral angle of the orbit, behind the external angular process of the frontal bone, which affords it protection. It is about half an inch wide by three-fourths of an inch long. Its shape is somewhat that of a flattened almond. It is concavo-convex, and has two surfaces, inferior and superior.

The Inferior or Concave Surface is in relation with the capsule of Tenon or the fascia of the ball of the eye, and the superior and external recti muscles.

The Superior or Convex Surface is closely applied to the periosteum of the frontal bone, to which it is connected by a few tendinous fibres.

The lachrymal gland is racemose in structure, and is identical with the true salivary glands, such as the parotid in man. It is enclosed in

a capsule and divided into two unequal portions, a superior or larger and an inferior or smaller, with a thin layer of fascia between them.

The Superior Portion, which comprises the greater part of the gland, is firmer in structure than the inferior—made so by the larger size of its lobules and their greater compactness of arrangement. It is placed within the lachrymal fossa.

FIG. 105.

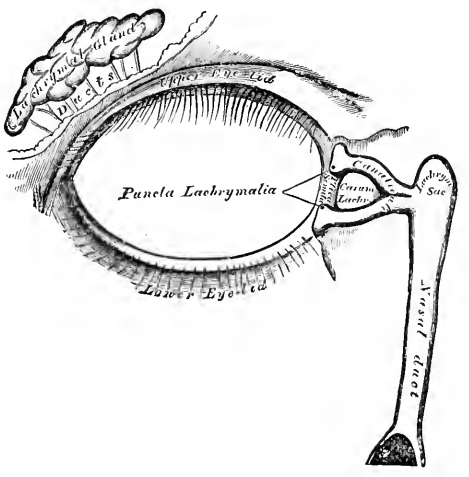

The Lachrymal Apparatus, right side.

The Inferior Portion (glandula lachrymalis inferior, Rosenmüller) is smaller than the superior. Its lobules are minute in size and loosely collected together, which gives it a softer appearance than the superior portion. It is situated in the subconjunctival connective tissue, just back of the lateral portion of the upper eyelid.

Harder's Gland, found in most mammals, is situated at the inner angle of the eye. In the ox, sheep, and pig, according to Wendt, it is similar in structure and function to the lachrymal gland, while in the musk-rat and guinea-pig it is like the sebaceous glands of the body. This gland is found in man and in the ape in a rudimentary state (Gracomini).

The Caruncula Lachrymalis is a small pinkish-red body situated at the inner angle of the eye—the rudiment of the nictitating membrane of birds, which forms a kind of third eyelid for protection, without obstructing the functions of the organ.

The Ducts of the Lachrymal Gland leading to the surface of the eye are from ten to fourteen in number. They pass obliquely downward beneath the mucous membrane, diverging slightly as they do so, and finally open into the outer third of the superior palpebral sinus on a line with each other. A few of the lobules composing the inferior portion of the gland have independent ducts which open separately, while others join the ducts coming from the superior or main portion of the gland.

Arteries.—The lachrymal gland is supplied with blood through the medium of the lachrymal artery, which is a branch of the ophthalmic.

Nerves.—The lachrymal gland receives its nerve-supply from the lachrymal nerve, which is a branch of the ophthalmic or first division of the fifth cranial nerve.

The Lachrymal Canals, or Canaliculi, are four in number, a superior and an inferior for each eye. They have their origin in small openings, the puncta lachrymalia, situated in the centre of a teat-like elevation at the inner edge of each eyelid near the inner angle of the eye, the lachrymal papilla. These canals terminate separately by open-

ing into the lachrymal sac, though they may open by one common duct. They are lined by pavement epithelium. They pass to their termination imbedded in connective tissue and surrounded by longitudinal fibres of the concentric or ciliary portion of the orbicularis palpebrarum muscle, and empty by independent openings into the lachrymal sac. Occasionally these canals merge into one another and terminate in one common duct. They are lined by pavement epithelium.

The Superior Lachrymal Canal is smaller in calibre than the inferior, though it is slightly longer, being nearly five lines in length and two lines in width. It commences on the inner margin of the upper eyelid, curves slightly upward, inward, and downward, and enters the orbital aspect of the sac a little below its summit.

The Inferior Lachrymal Canal is somewhat thicker and shorter than the superior. It commences at the inner margin of the lower eyelid, passes slightly downward, inward, and upward, and enters the lachrymal sac just below the superior canal.

The Lachrymo-nasal Passage is divided into two portions, the sac and the duct, the latter being lined by a ciliated epithelium similar to that of the nose.

The Lachrymal Sac is the upper enlarged portion of the lachrymo-nasal passage, and is situated in the sulcus formed by the upper portion of the lachrymal grooves in the lachrymal and superior maxillary bones. It is retained in position by connective-tissue fibres which unite with the periosteum of the bone, and by fibres with the internal tendo-palpebrarum and tensor tarsi. The sac is about half an inch long, being a little wider than long at its broadest portion. It is flat on its inner surface, which is that portion next the bone, but its external surface, or that next the orbit, where the canaliculi find entrance, is rounded and projects toward the eye. The superior portion of the sac is dome-shaped, while the inferior portion is smaller and passes into the nasal duct without any line of demarcation between them.

The Lachrymo-nasal Duct is formed by the lower portion of the lachrymo-nasal passage. It is slightly over half an inch in length, and extends from the lachrymal sac into the inferior meatus of the nose by passing through the lachrymal canal. The duct is larger at its extremities than in the middle, and is adherent to the bony walls, through which it passes, by connective-tissue fibres uniting it with the periosteum.

Valve-like folds of the lachrymo-nasal passage have been described as existing at the openings, within the canaliculi of the sac, in the duct, and at its termination in the nasal chamber.

The Tonsils.

The Tonsils (tonsillæ amygdalæ) are two glandular bodies situated on each side of the oro-pharyngeal space, which is in relation in front with the palato-glossal fold (anterior palatine arch); behind, with the palato-pharyngeal fold (posterior palatine arch); laterally, with the constrictor muscles of the pharynx; and proximally or internally it is open, this surface being covered by the mucous membrane of the oro-pharyngeal space above referred to. The fact that the palato-glossal and palato-

pharyngeal muscles arise from closely-related portions of the palate, and diverge as they descend to their insertions, causes the tonsillar space to be narrow at the top and wider at the bottom; and the further fact that the gland is about of equal width and thickness causes it to be compressed above, while below it is comparatively free from pressure.

The tonsils are about three-fourths of an inch long, half an inch wide, and about the same in thickness, their extremities being rounded. They vary considerably in size in different individuals, the two often being dissimilar in the same person. They are composed of masses of connective-tissue fibres and diffused adenoid tissue embracing lymph-follicles. On their free or proximal surface they are pitted with from twelve to twenty indentations or foldings, in such a way that they produce small recesses or crypts situated within the substance of the gland. These give the free surface of the gland a perforated appearance. The crypts are lined by a continuation of the stratified epithelium covering the mucous membrane of the mouth. The lymph-follicles above referred to are arranged around the walls of the crypts, and outside of the follicles are a number of small mucus-secreting glands. The secretion from these mucous glands is thick and gravish in appearance; it is discharged into the crypts. The retention of this fluid causes the breath to become fetid. Sometimes this secretion becomes inspissated, and is discharged in the shape of small balls of yellowish-gray matter having a very offensive odor. The retention of this matter may cause the tonsils to become highly inflamed.

When the tonsils are in normal condition, lymph-corpuscles migrate from the body of the gland, through the mucous membrane on its free surface, and enter the muco-salivary fluid of the mouth. These corpuscles, when detected in the saliva, are called by some writers mucous or salivary corpuscles. These corpuscles absorb water, become spherical in form, and finally disintegrate.

The Infratonsillar or Pharyngeal Tonsils are situated below the tonsils proper, in the upper part of the pharynx. As the mucous membrane in parts of this region is covered by ciliated columnar epithelium, it follows that some of the crypts of these glands are lined with the same structure.

Arteries.—The tonsils are extremely vascular bodies, being supplied with blood through the medium of the tonsillar and palatine branches of the facial artery, the descending palatine branch of the internal maxillary, and the ascending pharyngeal. From these arteries a fine plexus of capillaries is formed. These capillaries are distributed to the different tissues within the gland. The extreme vascularity of the gland causes its excision in whole or in part to be followed by considerable hemorrhage. Although the internal carotid artery passes to the outside of the superior constrictor of the pharynx, and is usually about three-fourths of an inch back of the gland, it has been cut in performing tonsillotomy, with very serious results. In operations upon the gland the surgeon should direct his knife away from the artery.

BLOOD-VESSEL SYSTEM OF THE HEAD AND ANTERIOR CERVICAL REGION.

THE head is supplied with blood by the two vertebral and the two common carotid arteries, besides numerous anastomotic branches from other trunks.

THE ARTERIES.

THE COMMON CAROTIDS (RIGHT AND LEFT).

The Common Carotids (Fig. 106) are very similar in position and in their course through the neck on either side. They give off the same

FIG. 106.

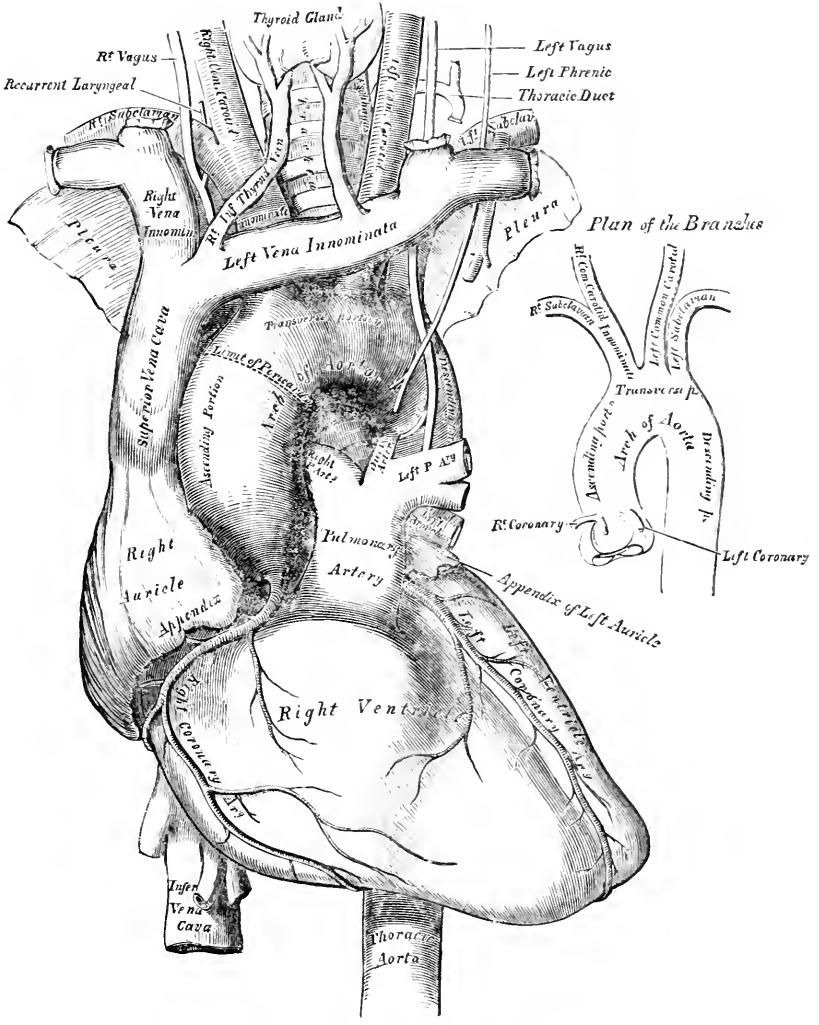

The Arch of the Aorta, and its Branches.

number of branches, though these may vary in size. They are about 8 mm. ($\frac{1}{3}$ inch) in calibre. They differ both in their length and origin, the left being the longer: it arises directly from the arch of the aorta, and is more deeply situated than the right.

The Right Common Carotid Artery is the shorter of the two, and at its origin is more superficially situated than the left. It is one of the terminal branches of the brachio-cephalic (innominate) artery, the other branch being the subclavian. The bifurcation of the brachio-cephalic into the right common carotid and subclavian arteries takes place within the thorax behind the sterno-clavicular articulation and above the level of the second dorsal vertebra. In front it is in relation with the right brachio-cephalic (innominate) vein, and externally with the subclavian vein and the pneumogastric and phrenic nerves.

The Left Common Carotid Artery arises from the left of the arch of the aorta, and, with the exeption of the coronary arteries, which supply the heart, is the second branch given off from that vessel. At its origin it is situated within the thorax. It then passes upward and a little outward to the left of the sterno-clavicular articulation, from which point its course is similar to the artery of the right side. It is situated just behind the upper portion of the sternum, and is covered by the sterno-hyoid and sterno-thyroid muscles, and in early childhood by a portion of the thymus gland. The left brachio-cephalic vein crosses it in front, and behind it is in relation with the trachea, œsophagus, and thoracic duct. Externally will be found the pleura, pneumogastric (tenth cranial), and phrenic nerves.

In the neck the common carotids are generally similar in course and situation, though they may differ slightly in size, and their termination may be at a point slightly higher or lower on one side than the other. They extend from the sterno-clavicular articulation on either side to their termination opposite the upper border of the thyroid cartilage, without giving off any branches. At the upper border of the thyroid cartilage they divide into two large branches, the external and internal carotids.

The Line of the Common Carotid Artery extends from the sterno-clavicular articulation to a point midway between the angle of the jaw and the mastoid process of the temporal bone. At the point where the carotid arteries emerge from the thorax and enter the neck they are closely approximated, being separated only by the anterior semicircumference of the trachea. As they ascend the neck they diverge, and at their termination are separated by the larynx and the pharynx, which structures are pushed forward between them. They are deeply seated at their origin, but become quite superficial in the region of the larynx.

The Sheath of the Common Carotid Artery is derived from the deep cervical fascia, and encloses, together with the artery, the pneumogastric nerve and internal jugular vein. The artery is situated to the median side of the nerve, while the vein is external to both artery and nerve. Each of these structures is separated from the others by a distinct investment of connective tissue. The descendens noni nerve is occasionally within the sheath of the common carotid, but more frequently it passes down the neck upon the sheath.

Superficial Relations.—At the base of the neck the common carotid artery is covered by the skin, platysma myoides, and deep fascia, and by the sterno-cleido-mastoid, sterno-hyoid, and sterno-thyroid muscles.

FIG. 107.

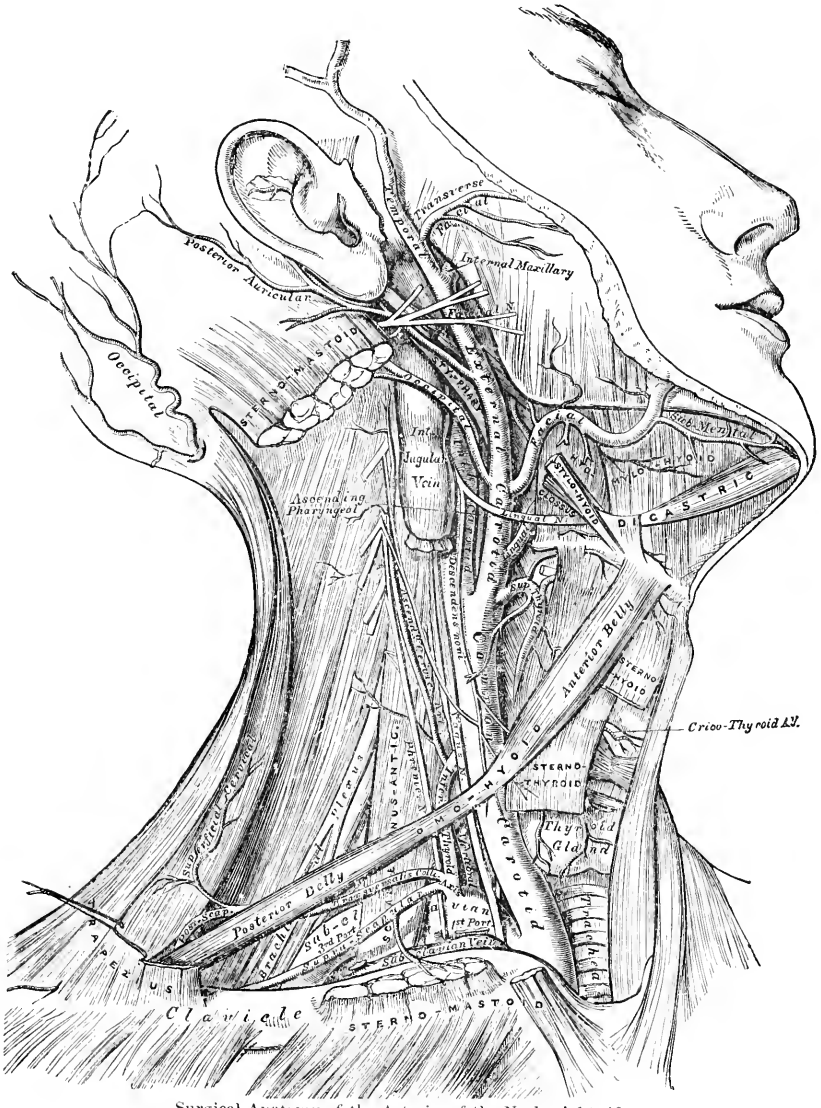

Surgical Anatomy of the Arteries of the Neck, right side.

It is crossed by the omo-hyoid muscle opposite the cricoid cartilage, and below this by the anterior jugular vein. The upper portion of the common carotid, or that portion which extends from the omo-hyoid muscle to its termination, is covered by the skin, platysma myoides, and deep

fascia, and by the anterior border of the sterno-cleido-mastoid muscle. On dissection, however, because of the shrinkage which takes place in the muscle after death, it is usually found that the anterior border of the sterno-cleido-mastoid does not cover the artery in this position, but it is found in the carotid triangle, which is bounded above by the posterior belly of the digastric muscle, in front by the anterior belly of the omo-hyoid muscle, and behind by the sterno-cleido-mastoid muscle, the sterno-mastoid branches of the superior thyroid artery, and by the facial, lingual, and superior thyroid veins, crossing it in this triangle. Occasionally it is partially covered by the thyroid gland.

Deep Relations.—The common carotid artery lies directly in front of the cervical vertebræ, separated from them by the longus colli and the rectus capitis anticus major muscles. The interval between the artery and the transverse processes of the vertebræ being small, compression backward in this situation to a great extent controls the flow of blood through the vessels. In the median line the vessel is related, as it passes from below upward, with the trachea, thyroid gland (the gland at times overlapping the artery), larynx, œsophagus, and pharynx.

Variations.—Normally, the common carotid artery gives off no branches, and it is of the same calibre from its commencement to its bifurcation. At other times either the superior or inferior thyroid artery may arise from it, the artery being reduced in size above the branches. The division of the common carotid into the external and internal carotids may take place as high or higher than the hyoid bone, or it may bifurcate lower down than its normal position; the common carotid may be entirely absent, when the external and internal carotids will generally arise directly from the aorta. At times, however, the right common carotid may arise directly from the aorta alone or in conjunction with the left—a condition common in some of the lower animals.

The origin of the left common carotid is more varied than that of the right. It may arise in either of the following ways: from or in conjunction with the brachio-cephalic or subclavian, or by a common trunk with the right common carotid, when the subclavian will arise directly from the aorta.

Collateral Circulation.—If the common carotid artery be ligated, the blood for the parts usually supplied by the internal carotid will be carried by the vertebral arteries and the internal carotid of the opposite side. These arteries, together with the other internal carotid, freely communicate with each other through the circle of Willis at the base of the brain. The blood for the parts supplied by the external carotid is carried by the superior and inferior thyroids, which freely anastomose; by the occipital and deep cervical, which also anastomose; and by the external carotid of the opposite side through its communication with the two superior thyroids, the lingual, facial, temporal, internal maxillary, and occipital arteries.

The External Carotid Artery is so called because it supplies the external portion of the head with blood. It is about 6 mm. ($\frac{1}{4}$ inch) in calibre, and arises from and is one of the terminal branches of the common carotid. This origin is within the carotid triangle opposite

the upper border of the thyroid cartilage. From this point it passes up the neck between the pharynx and the muscles resting upon the vertebra in this region, to a point opposite the surgical neck of the lower jaw, where it divides into two terminal branches, the internal maxillary and the superficial temporal. As it ascends the neck it decreases in size, the reduction in calibre being due to the number of large branches it gives off. In early life it is smaller than the internal carotid, but it gradually increases until adult life, when both arteries are of the same size.

Relations.—At its origin the external carotid artery is situated at the median side of the internal carotid, but soon becomes superficial to that artery. It is covered by the skin, the platysma myoides and sterno-cleido-mastoid muscles, and the deep fascia. The superior laryngeal nerve passes behind the artery in this situation. Its deep relation at its commencement is with the pharynx and hyoid bone. From this position it passes up internally to the stylo-hyoid and posterior belly of the digastric muscle and part of the parotid gland, which separates it from the back part of the ramus of the jaw. The posterior belly of the digastric muscle is a good guide in the ligation of the artery. Throughout its upper portion it is separated from the internal carotid by the stylo-glossus and stylo-pharyngeus muscles, the glosso-pharyngeal nerve, and part of the parotid gland.

The external carotid artery is usually unaccompanied by a vein, although the temporo-maxillary vein crosses it within the parotid gland, the anterior division of the temporo-maxillary vein passing downward to the facial. The facial and lingual veins cross the artery below the digastric muscle on their way to join the internal jugular. Higher up, in the substance of the parotid gland, the artery is crossed by the facial nerve, the hypoglossal nerve crossing it just below the posterior belly of the digastric muscle.

Branches of the External Carotid Artery.—The external carotid artery in its ascent through the neck gives off eight branches. Their names, in great measure, indicate their distribution. Three of the branches—viz. the superior thyroid, lingual, and facial—pass anteriorly; two—viz. the occipital and posterior auricular—pass posteriorly; one, the ascending pharyngeal, passes internally: it terminates in two branches, the superficial temporal and the internal maxillary.

Variations.—The general variations in the origin of the external carotid artery have been mentioned under the head of the common carotid. Other variations are caused by the manner in which its branches are given off. The external carotid may at times be entirely wanting. When this is the case the different branches which are usually given off by it arise from a common trunk which represents the internal and external carotids. The superior thyroid and the lingual arteries may arise from a single branch, instead of two separate branches, or the lingual and facial or the superior thyroid, lingual, and facial may originate in a similar manner. The superior thyroid may also arise from the common carotid. The external carotid artery occasionally divides at the angle of the jaw, reuniting again near the neck of the inferior maxilla to form the temporal artery.

The Superior Thyroid Artery is the first anterior branch of the

external carotid. It is about $3\frac{1}{2}$ mm. ($\frac{1}{7}$ inch) in calibre, and arises close to the bifurcation of the common carotid, on a level with or slightly below the great cornu of the hyoid bone. It is very superficially located within the carotid triangle. It passes slightly upward and forward at first, after which it passes forward and downward, to the upper margin of the thyroid cartilage, forming an arch. Here it passes beneath the omo-hyoid, sterno-hyoid, and sterno-thyroid muscles, supplying them with branches, and is finally distributed to the thyroid gland, breaking up into numerous terminal branches, which anastomose quite freely with the terminal branches of the inferior thyroid.

The Transverse Artery, which is not universal in its existence, is one of the terminal branches that pass along the upper border of the isthmus of the thyroid body within its capsule. The transverse artery may be of large size, and give off branches that overlie the isthmus.

The Superior Thyroid Artery gives off the following branches: the hyoid, superficial descending or sterno-mastoid, superior laryngeal, and crico-thyroid.

The Hyoid or Inferior Hyoid Artery is a small vessel that passes inward from the superior thyroid along the under surface of the hyoid bone beneath the thyro-hyoid muscle. It gives off branches that supply the muscles attached to the under surface of the hyoid bone, and anastomoses with similar branches of the opposite side.

The Superficial Descending or Sterno-mastoid Artery passes downward across the sheath of the common carotid artery. It is of importance to remember this fact in operations for the ligation of the common carotid in this region. This artery is distributed to the following muscles: the omo-hyoid, sterno-hyoid, sterno-thyroid, sterno-cleido-mastoid, and inferior constrictor of the pharynx.

The Superior Laryngeal Artery is the largest of the several branches of the superior thyroid, being about 2 mm. ($\frac{1}{12}$ inch) in calibre. It extends inward, accompanied by the superior laryngeal nerve; passes under the thyro-hyoid muscle to the thyro-hyoid membrane; pierces this membrane and enters the larynx, where it separates into two divisions, superior and inferior.

The Superior Division supplies the posterior surface of the epiglottis and its mucous membrane.

The Inferior Division supplies the intrinsic muscles of the larynx and its mucous membrane.

The Crico-thyroid Branch is a small artery about $\frac{1}{2}$ to 1 mm. ($\frac{1}{25}$ to $\frac{1}{50}$ inch) in calibre. It passes across the crico-thyroid membrane, and anastomoses with the corresponding artery of the other side. The position of this artery gives it importance, on account of the fact that hemorrhage often occurs from its division in the operation of laryngotomy.

Variations.—The superior thyroid artery may be larger or smaller than usual. When this difference exists either way, one or more of the other three thyroid arteries will be found to be increased or diminished in size. Occasionally it is found to arise in common with the lingual or facial, or both. It may also be a division of the common carotid. The branch of this artery which supplies the sterno-cleido-mastoid mus-

cle is sometimes a separate and distinct branch of the common carotid. It occasionally gives origin to the ascending pharyngeal artery, and its hyoid branch is often very small or entirely absent. The superior laryngeal branch also often arises from the external carotid, and occasionally from the common carotid, and may pierce the crico-thyroid space or pass through a foramen in the thyroid cartilage. The crico-thyroid branch is sometimes of considerable size, and may interchange with a branch to the thyroid body or a division of the inferior thyroid artery.

The Lingual Artery.

The lingual artery is about $3\frac{1}{2}$ mm. ($\frac{1}{7}$ inch) in calibre, and is the second anterior branch of the external carotid. It arises within the carotid triangle between the superior thyroid and facial arteries, and nearly opposite the great cornu of the hyoid bone. It passes upward a short distance, then turns downward, forming a concavity which is crossed by the hypoglossal nerve. Thence it extends beneath the digastric and stylo-hyoid muscles to reach the great cornu of the hyoid bone, running parallel with it, under cover of the hyo-glossus muscle, to a point near its anterior border, where it turns upward and passes to the under surface of the tongue, through which it extends to the tip, where it terminates in the ranine artery.

Relations.—This artery is divided into four portions, according to the regions through which it passes. The first or superficial portion is wholly within the carotid triangle, and is covered by the skin, platysma myoides, and fascia of the neck, and rests upon the connective tissue and middle constrictor muscle of the pharynx. The second or horizontal portion is covered externally by the sterno-hyoid, digastric, and the greater part of the hyo-glossus muscle, the hypoglossal nerve passing to the outer side of the muscles: this portion of the artery rests upon the middle constrictor muscle of the pharynx. The third or ascending portion is that part which extends upward to the under surface of the tongue: it passes between the hyo-glossus and genio-glossus muscles. The fourth or ranine portion is generally in relation with the intrinsic muscles of the anterior part of the tongue. Near its termination it becomes quite superficial and communicates with its fellow of the opposite side.

The branches of the lingual artery are the hyoid, dorsalis lingual, sublingual, and ranine arteries.

The Hyoid or Superior Hyoid Artery is the first branch of the lingual, and arises within the carotid triangle. It passes to the upper border of the hyoid bone, supplying the bone, the muscles attached to its upper portion, and the fibro-adipose tissue between the bone and the base of the epiglottis.

The Dorsalis Linguæ Artery, which is occasionally replaced by several smaller ones, arises from the second part of the lingual artery as it passes beneath the hyo-glossus muscle. It extends to the upper surface of the tongue, supplies the mucous membrane of this surface, as well as the substance of the organ, and communicates with its fellow of the

other side. Occasionally the artery will be found to be exceedingly large. When this is the case, in addition to the structures already mentioned it usually supplies the stylo-glossus muscle, the tonsils, epiglottis, and soft palate.

The Sublingual Artery is, in reality, one of the terminal branches of the lingual, the ranine artery being the other. It arises from the lingual at a point opposite the anterior margin of the hyo-glossus muscle. From this margin it passes forward between the genio-glossus muscle and the sublingual gland, supplying the gland, the mucous membrane of the floor of the mouth, the alveolo-lingual groove, and gums; also extending to the mylo-hyoid and other muscles of this region.

The Ranine Artery is one of the terminal branches of the lingual. It arises opposite the anterior margin of the hyo-glossus muscle, and passes in a tortuous course within the structure of the muscle to a point near the tip of the tongue, where it is quite superficial. In its course it gives off numerous branches and communicates with the corresponding artery of the opposite side. This anastomosis is the most important between the branches of the lingual artery, the others being capillary in character.

The nutrition of the two halves of the tongue supplied by each lingual artery and its branches is comparatively independent. The ranine artery being so superficially situated, and so close to the frænum linguæ, there is some danger of cutting it in the operation for so-called tongue-tie.

Variations.—The lingual artery may arise in conjunction with the facial or superior thyroid, or the three arteries may arise as a common trunk from the external carotid. Occasionally it arises from the internal maxillary artery. Sometimes it accompanies the hypoglossal nerve along the outer margin of the hyo-glossus muscle. The artery may be entirely absent, and its place supplied by branches from the internal maxillary, submental branches of the facial, or by the corresponding artery of the other side. It occasionally gives origin to the ascending pharyngeal artery, and the superior laryngeal, the submental, and the ascending palatine have been known to spring from it. Sometimes the superior hyoid branch of the lingual is entirely absent. When this is the case its place is supplied by the inferior hyoid. The sublingual branch of the lingual artery arises at times from the facial, and reaches its destination by piercing the mylo-hyoid muscle.

The Facial or External Maxillary Artery.

The Facial or External Maxillary Artery (Fig. 108) is about $3\frac{1}{2}$ mm. ($\frac{1}{7}$ inch) in calibre, and arises from the external carotid within the carotid triangle a little above the lingual artery. It extends upward, forward, and inward, passes beneath the posterior belly of the digastric and the stylo-hyoid muscles, and enters the posterior part of the submaxillary triangle. It then passes forward within the substance of the submaxillary muco-salivary gland, extending parallel with the base of the lower jaw, close to the mylo-hyoid muscle. Leav-

ing the gland, it makes a sharp turn upward over the body of the inferior maxillary bone, curving through a notch just in front of the insertion of the masseter muscle. From its origin to this point, where it curves over the body of the inferior maxilla, it constitutes the first or cervical division of the artery. As it passes over the body of the jaw the artery is quite superficial, being covered only by the skin and platysma myoides muscle. In this situation the pulsation of the artery

FIG. 108.

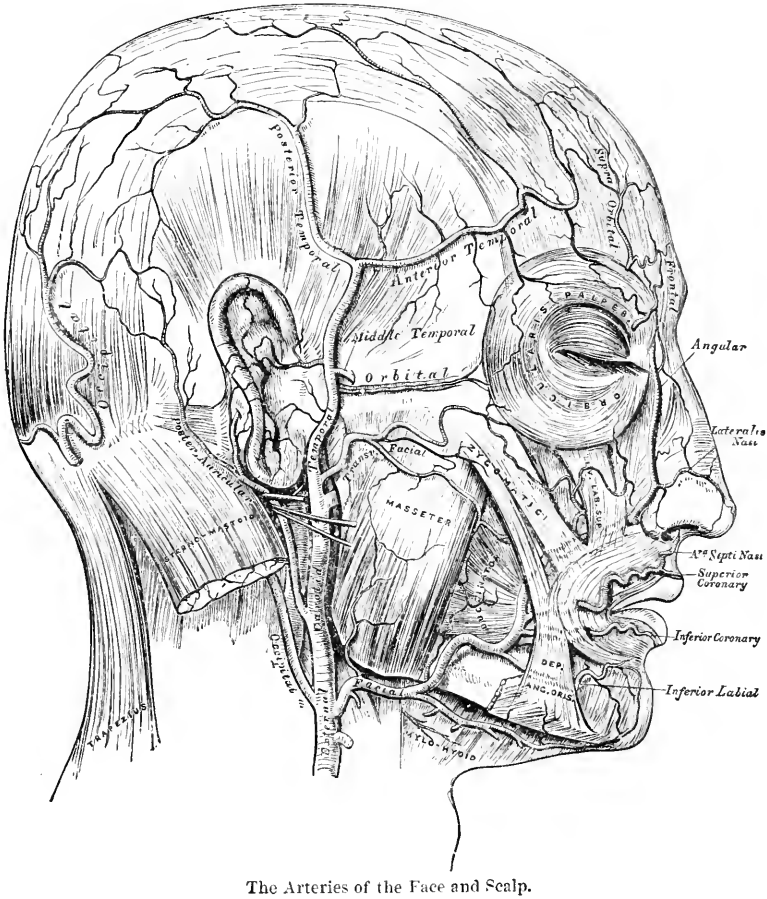

The Arteries of the Face and Scalp.

can be distinctly felt, and the flow of blood to parts above can be controlled by direct pressure of the artery against the bone. This is likewise a favorable location for the ligation of the artery. From the base of the jaw it passes obliquely upward and forward toward the inner canthus of the eye, where it terminates in the angular artery and communicates with branches of the ophthalmic artery. From the body of the jaw it passes between the masseter and depressor anguli oris muscles to near the angle of the mouth. It then extends beneath the two zygo-

matici muscles and the levator labii superioris, passing over the buccinator, the levator anguli oris, and occasionally over the levator labii superioris proprius. It terminates either upon the levator labii superioris, alæque nasi, or within the substance of the muscle.

The facial artery is very tortuous both in the neck and in the face; for if the course was a straight line from its origin to its termination the artery by its inelasticity would bind the different structures through or over which it passes, interfering with the free action of the jaws and the mobility of the lips and muscles of expression. The same winding of this vessel in the neck permits free movement of the larynx and its associate parts, and prevents interference with deglutition.

The Facial Vein is superficial to and accompanies the facial artery throughout its course; part of the submaxillary gland is interposed between them in the neck. As they cross the jaw the artery and vein are in close proximity, but in the face they are separated by the zygomaticus minor and the levator labii superioris. Branches of the facial nerve pass over the artery as it crosses the infraorbital nerve; these latter are usually separated by the elevator muscle of the upper lip.

Branches of the Facial Artery.—The branches of the facial artery are divided into two sets, cervical and facial, according to the locality through which they extend. They are as follows:

Cervical Branches.	Facial Branches.
Inferior or ascending palatine,	Inferior labial,
Tonsillar,	Inferior coronary,
Glandular,	Superior coronary,
Submental,	Lateralis nasi.
	Angular.

The Inferior or Ascending Palatine Artery is the first branch of the facial, though in some instances it arises from the external carotid. It extends upward, and passes beneath the stylo-glossus and stylo-pharyngeus muscles, above which it will be found running between the internal pterygoid and the walls of the pharynx to a level with the soft palate. In its course it distributes branches to the surrounding muscles, the tonsils, and the Eustachian tube. Near the levator palati muscle it divides into two branches, superior and inferior. The superior supplies the levator palati muscle, the soft palate, and the palatine glands. The inferior supplies the tonsils and anastomoses with the tonsillar artery. These two vessels also communicate with the posterior palatine branches of the inferior maxillary artery.

The Tonsillar Artery, a branch of the facial, extends upward superficially to the stylo-glossus muscles, passes through a perforation in the superior constrictor of the pharynx, and gives off small branches to the tonsils, side of the tongue, and mucous membrane of the surrounding parts. When the tonsillar branch of the facial artery is absent, the parts to which it is generally distributed are supplied by the descending palatine or ascending pharyngeal branches, or both.

The Glandular Arteries (submaxillary) are several short branches from the facial which are distributed to the muco-salivary submaxillary gland. Some of these branches extend through the substance of the

gland, and are distributed to the stylo-hyoid, internal pterygoid, and masseter muscles.

The Submental Artery is the largest and most important of the cervical branches of the facial artery. It arises at a point between the submaxillary gland and the position of the facial artery as it turns upward across the body of the jaw to reach the face. Occasionally it arises from the sublingual artery; it extends in a continuous line from the facial artery below the base of the jaw to its symphysis, where the artery turns upward to the chin, supplying the muscles of this region and anastomosing with the inferior labial and mental arteries and its fellow of the opposite side. The mylo-hyoid muscle is situated on its inner side, branches of the artery perforating the muscle and anastomosing with the sublingual artery. In its course it distributes branches to the neighboring tissues.

The Inferior Labial Artery is the first of the facial branches of the facial artery. It arises soon after the artery reaches the face, and passes forward beneath the depressor anguli oris muscle. Its branches are distributed to the integument and muscles of the lower lip, and anastomose with the inferior coronary, submental, and mental arteries.

The Inferior Coronary Artery supplies the lower lip. It arises at the outer margin of the depressor anguli oris muscle, a little below the level of the angle of the mouth, passes a short distance upward and inward beneath the depressor anguli oris, depressor menti, and the orbicularis oris muscles, and between the latter muscle and the mucous membrane close to the free margin of the lip. Its branches supply the muscles and mucous membrane of this region and the labial glands, anastomosing with its fellow of the opposite side, with the inferior labial, and the mental branch of the inferior dental artery.

The Superior Coronary Artery supplies the upper lip and arises beneath the zygomaticus major muscle. It is larger and more tortuous than the inferior coronary, and passes transversely between the muscles and mucous membrane of the upper lip close to its free margin, inosculating with the corresponding artery of the opposite side. It supplies the muscles, mucous membrane, and labial glands of the upper lip, and gives off two or three branches which pass to the nose. One, the artery of the septum, passes along the columna nasi as far as the tip of the nose, and supplies the septum. Another branch supplies the alæ of the nose.

The inferior and superior coronary arteries occasionally arise as a common trunk. If either or both are smaller than is generally the case, the arteries of the opposite side are correspondingly increased in size. It is by reason of their free anastomosis with each other that they receive the name "coronary arteries," though this anastomosis is not always present.

The Lateral Nasal Artery arises from the facial as it ascends along the side of the nose. Occasionally this artery is replaced by two or three smaller arteries. The branches of the lateral nasal supply the wing and dorsum of the nose, and anastomose with the nasal branch of the ophthalmic, infraorbital, artery of the septum, and corresponding artery of the opposite side.

The Angular Artery is properly the continuation of the facial. It ascends between the inner canthus of the eye and the nose, and its branches supply the tissues in this region, including the lachrymal sac. It anastomoses with the infraorbital and the nasal branch of the ophthalmic.

Variations.—The facial artery may arise in conjunction with the lingual and superior thyroid, and it may also have its origin above the carotid triangle. When this is the case, it descends to its normal position below the jaw. It may interchange with the internal maxillary (deep facial) artery. It varies in size and distribution. Rare instances are recorded where the artery has not passed upon the face, but has terminated in the submental. At times it extends in the face only far enough to supply the lower lip, and it frequently fails to give off the lateral nasal and angular branches. When the facial artery is abnormally short, and fails to extend to its usual termination upon the face, the blood-supply is received through the enlargement of the nasal branch of the ophthalmic and branches of the transverse facial (a division of the temporal artery), or through one or more of the terminal branches of the internal maxillary. In cases where any of these arteries are small in size or entirely absent the facial artery may be increased in size to supply the deficiency. Occasionally, while in the neck the facial may give off a branch to supply the sublingual gland, the gland in such case not receiving its usual supply from the lingual.

The Occipital Artery.

The occipital artery is about $3\frac{1}{2}$ mm. ($\frac{1}{7}$ inch) in calibre, and arises from the surface of the external carotid, opposite to, or slightly above, the facial. From this origin, which is beneath the sterno-cleido-mastoid and the posterior belly of the digastric muscle, it passes upward and backward, and is covered by the posterior belly of the digastric and the stylo-hyoid muscle and a portion of the parotid gland. The hypoglossal nerve crosses it on its outer side. It then passes to the outside of the internal jugular vein, the pneumogastric and spinal accessory nerves, to an interspace between the transverse process of the atlas and the mastoid process of the temporal bone. When it reaches the base of the skull it is directed backward, following the occipital groove situated to the inner side of the digastric fossa on the temporal bone. It lies beneath the muscles attached to the mastoid process, and above the superior oblique, complexus, and rectus posticus major muscles. When it reaches the extremity of the groove it turns upward, passing through the trapezius muscle, then over the occiput, being distributed to the structures in this region, and anastomoses with the temporal artery and corresponding artery of the opposite side.

The branches of the occipital artery are—

1. The muscular;
2. The auricular;
3. Descending cervical;
4. Posterior meningeal;
5. Mastoid;
6. Superficial or cranial.

The Muscular Arteries consist of several small branches which supply the posterior belly of the digastric, the stylo-hyoid, splenius capitis, and

trachelo-mastoid; a branch somewhat larger than the rest supplies the sterno-cleido-mastoid muscle. This branch usually arises a little above the origin of the occipital artery, though it may arise from the external carotid.

The Auricular Artery is a small branch which supplies the auricle and the tissues near the mastoid process. This branch is not always present.

The Descending Cervical, or Ramus Cervicalis Princeps Artery, is of large size, and arises beneath the splenius capitis muscle. Soon after its origin it divides into two branches, superficial and deep. The superficial branch perforates the splenius muscle, supplying it and the trapezius. The deep branch passes beneath the complexus and semi-spinalis colli, and inosculates with the vertebral and the deep branch of the superior intercostal. Through the anastomoses of these arteries a collateral circulation is maintained after the ligation of either the common carotid, external carotid, or subclavian arteries.

The Posterior or Meningeal Branch arises from the occipital, passes up along the internal jugular vein, and enters the brain-case through the jugular foramen; it supplies the posterior portion of the dura mater. This artery is not always present.

The Mastoid Artery is a small branch from the occipital, which enters the mastoid foramen of the temporal bone; it supplies the diploë, walls of the mastoid cells and lateral sinus, and the dura mater in the occipital fossa.

The Superficial or Cranial Arteries are terminal branches of the occipital, and pass between the integument and the occipital muscle, supplying the structures in this region. They anastomose freely with each other, with the corresponding artery of the opposite side, and the posterior auricular and superficial temporal arteries.

Variations.—The occipital occasionally arises from the internal carotid or in conjunction with the facial or from the cervical branch of the inferior thyroid. Its direction also may vary: instead of passing to the median side of the trachelo-mastoid muscle, it may extend laterally. It occasionally divides into a larger and smaller branch, the smaller assuming the usual direction of the artery, while the larger passes superficially to the sterno-cleido-mastoid muscle. The stylo-mastoid artery occasionally arises from the occipital instead of the posterior auricular artery.

The Posterior Auricular Artery.

The posterior auricular artery arises from the external carotid nearly opposite the apex of the styloid process of the temporal bone, above the digastric and stylo-hyoid muscles. It is about 2 mm. ($\frac{1}{12}$ inch) in calibre; it extends obliquely upward and backward beneath the parotid gland, and passes up the styloid process, where it is crossed by the facial nerve. It then ascends between the cartilage of the ear and the mastoid process of the temporal bone, becomes superficial, and divides into two terminals, the auricular and the mastoid.

The branches of the posterior auricular artery are the stylo-mastoid and the auricular.

The Stylo-mastoid Artery is long and slender, and enters the stylo-mastoid foramen in the temporal bone, the facial nerve passing out by the same opening. It gives off branches which supply the mastoid cells, the stapedius muscle, the tympanum, and the semicircular canals of the internal ear. The continuation and termination of the stylo-mastoid artery are very small; it extends forward within the aquæductus Fallopii, anastomosing with the petrosal branch of the middle meningeal, which is itself a branch of the internal maxillary. In young subjects the artery that supplies the tympanum communicates with the tympanic branch of the internal maxillary, thus forming a vascular circle around the tympanic membrane, from which delicate vessels concentrate to supply that structure.

The Auricular Artery, the other branch of the posterior auricular, ascends behind the ear and distributes branches to the retrahens aurem muscle, the posterior portion of the temporal region, and skin over the mastoid process; two branches to the auricle supply both the inner and outer surface of the pinna. Besides these, the posterior auricular artery gives off small muscular twigs which supply the digastric, stylo-hyoid, sterno-cleido-mastoid, and occipital muscles, the integument, and the parotid gland.

Variations.—The posterior auricular artery sometimes terminates in the stylo-mastoid. It is occasionally quite small; sometimes it is abnormally large, and takes the place of the occipital or superficial arteries. At times it is given off by the occipital artery, and the transverse facial may arise from the posterior auricular.

The Ascending Pharyngeal Artery.

The ascending pharyngeal artery is the smallest of the eight branches of the external carotid. It is long and slender, and extends in an almost straight course from its origin to its termination. It usually arises from the posterior part of the external carotid, from a half to one inch above the origin of this artery, and passes upward between the external carotid artery and the walls of the pharynx. The branches of the ascending pharyngeal artery are divided into three sets, as follows:

The prevertebral,
The pharyngeal,
The meningeal.

The Prevertebral Arteries are small and are distributed to the longus colli and rectus capitis anticus muscles, the lymphatic glands of the neck, sympathetic nerves and ganglia, and some of the nerves passing out of the base of the brain-case; finally anastomosing with branches from the subclavian artery.

The Pharyngeal Arteries, in large measure, supply the muscles and mucous membrane of the pharynx. The middle and inferior constrictor muscles are usually supplied by two branches, which anastomose with branches of the inferior thyroid artery. A larger and more constant branch is distributed to the superior constrictor muscle of the pharynx, and furnishes small twigs which pass to the Eustachian tube,

soft palate, palato-Eustachian, and levator palati muscles, as well as to the tonsils. The artery which supplies the tonsils and the soft palate is occasionally quite large, and divides into two smaller ones, anterior and posterior, which anastomose with the corresponding arteries of the opposite side. These branches supply the place of the inferior palatine artery when that is wanting or abnormally small.

The Meningeal Arteries are two or three in number, and pass into the brain-case through the jugular and anterior condyloid and posterior lacerated foramina to supply the dura mater of the brain.

The Superficial Temporal Artery.

The Superficial Temporary Artery is about $3\frac{1}{2}$ mm. ($\frac{1}{7}$ inch) in calibre. It is the smaller of the two terminal branches of the external carotid, the internal maxillary being the other. It originates at the bifurcation of the external carotid, which is situated a little below the level of the head or condyle of the inferior maxilla, and opposite the upper portion of the parotid gland. It here passes upward in a continuous line with the external carotid, over the posterior root of the zygomatic process. This is a favorite point to apply pressure to control hemorrhage from this artery. From this point to its termination it lies between the skin and the temporal fascia. It is usually about one inch in length, and terminates in the anterior and posterior superficial temporal arteries, which again divide into several branches.

The branches of the superficial temporal artery are—

The glandular,	The transverse facial,
The muscular,	The middle temporal,
The articular,	The anterior temporal,
The anterior auricular,	The posterior temporal.

The Glandular Arteries are several small branches which assist in supplying the parotid gland.

The Muscular Arteries are one or two small branches which pass to the masseter muscle.

The Articulating Arteries are small twigs which supply the temporomaxillary articulation.

The Anterior Auricular Arteries are distributed to the anterior portion of the auricle or pinna.

The Transverse Facial Artery arises from the temporal where that artery is imbedded in the parotid gland. It passes horizontally or transversely forward between the zygoma and the parotid duct, and rests upon the masseteric fascia. It terminates upon the face by breaking up into three or four branches, which are distributed to the orbicularis palpebrarum, zygomatici, levator anguli oris muscles and the integument, anastomosing with the facial, buccal, and infraorbital branches of the internal maxillary arteries. It also sends branches to the parotid gland and masseter muscle.

The Middle Temporal Artery is a branch of the superficial temporal, and is given off just above the zygoma. It passes inwardly through the temporal fascia to reach a groove in the squamous portion of the

temporal bone, in which it rests. It gives off branches to the temporal muscle, and communicates with the deep temporal branches of the internal maxillary artery. Occasionally it gives off an orbital branch, which passes along the superior border of the zygoma between the two layers of the temporal fascia. This branch is distributed to the orbicularis palpebrarum muscle, and inosculates with the lachrymal and palpebral branches of the ophthalmic artery.

The Anterior Temporal Artery is the larger of the two terminal branches of the superficial temporal. It passes obliquely forward and slightly upward in a tortuous manner upon the temporal fascia, extending slightly above the orbicularis palpebrarum muscle, and terminates in branches which anastomose with the corresponding artery of the opposite side and the supraorbital and frontal branches of the ophthalmic artery. Branches are also given off which supply the skin, muscles, and other structures in the anterior temporal region, the orbicularis palpebrarum and frontal muscles.

The Posterior Temporal Artery is smaller, and its course is straighter, than the anterior temporal. As it passes upward and slightly backward toward the vertex of the skull, it rests upon the temporal fascia, and anastomoses with ramifications of the corresponding artery of the opposite side. It also gives off branches posteriorly which anastomose with the occipital, and anteriorly which anastomose with the anterior temporal. It supplies the skin and other tissues of the vertex of the skull.

Variations.—Occasionally the anterior temporal artery passes vertically over the vertex of the skull, giving off branches which anastomose with the occipital artery. The transverse facial artery may arise directly from the external carotid instead of from the superficial temporal, and is sometimes very large, supplying the place of the facial artery. Occasionally the transverse facial is double. The orbital branch may be of large size and supply the eyelids and part of the forehead, and communicate with the supraorbital. In aged people the course of the temporal artery will be found to be more tortuous than in early life.

The Internal Maxillary or Deep Facial Artery.

The Internal Maxillary (Fig. 109) supplies all the deep portions of the face, including the teeth, part of the floor of the mouth, the palate, the nasal chambers, the maxillary sinus, the greater portion of the ethmoidal sinuses, part of the pharynx, and the dura mater of the brain. It is the larger of the two terminal branches of the external carotid, being about 5 mm. ($\frac{1}{5}$ inch) in calibre. It is given off from the external carotid, within the parotid gland, a little below and behind the condyle of the inferior maxilla, on a level with the lower part of the lobe of the ear. In the first part of its course it passes at right angles to the external carotid, and extends forward in a tortuous manner between the inferior maxillary bone and the internal lateral ligament, from which it passes obliquely upward and forward upon the outer surface of the external pterygoid muscle

(occasionally it passes on the inner side), until opposite the space between the two heads of this muscle. Here it turns inward between these heads into the spheno-maxillary fossa, where it terminates in various branches having close relation with the spheno-palatine (Meckel's) ganglion.

For facility of studying, the branches of this artery are arranged

FIG. 109.

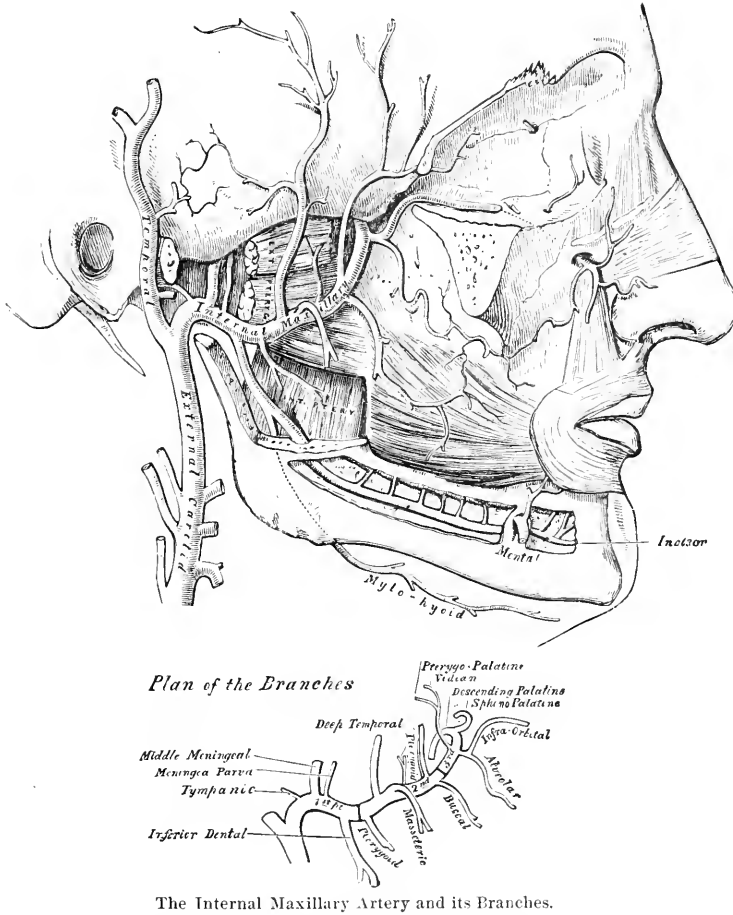

The Internal Maxillary Artery and its Branches.

under three heads, according to their anatomical relation to the parts which they supply:

The First or Maxillary Division extends from the external carotid to the internal lateral ligament, and gives off five branches, which pass into or through osseous foramina. These branches are the deep auricular, tympanic, middle (or great meningeal), small meningeal, and the inferior dental.

The Second or Pterygoid Division extends from the internal lateral ligament to the point at which the artery passes through the space

between the two heads of the external pterygoid muscle. This portion has four branches, which supply the masticatory and buccinator muscles. They are named, according to their distribution, the deep temporal, pterygoid, masseteric, and buccal.

The Third or Spheno-maxillary Division extends from the inner surface of the external pterygoid muscle to the termination of the artery in the spheno-palatine fossa. It gives off six branches, each passing into or through osseous foramina. They are likewise named, according to their course or the parts supplied by them, the alveolar (or superior maxillary), infraorbital, descending (superior) palatine, Vidian, pterygo-palatine, and nasal or spheno-palatine.

ARTERIES OF THE FIRST DIVISION.

The Deep Auricular Branch is of small size, occasionally arising in common with the tympanic branch, but usually it arises just external to it, and perforates the anterior wall of the external auditory meatus. It is distributed to the skin and the external portion of the tympanic membrane.

The Tympanic Artery is the second and one of the smallest branches of the internal maxillary. It passes to the tympanum through the glenoid fissure (fissure of Glaser), and is distributed to the structures of the middle ear and the tympanic membrane. It anastomoses with the stylo-mastoid and Vidian arteries.

The Middle or Great Meningeal Artery is the third and largest branch. It is also the largest artery supplying the dura mater. It has a calibre of about 2 mm. ($\frac{1}{12}$ inch) and arises from the upper side of the internal maxillary, passing upward behind and close to the insertion of the external pterygoid muscle through a loop of the auriculo-temporal nerve, and reaches the brain-case through the foramen spinosum in the spinous process of the great wing of the sphenoid bone. Within the cranial cavity it passes in the direction of the anterior inferior angle of the parietal bones along a groove anterior to and parallel with the spheno-squamosal suture. When about midway of the suture it divides into an anterior and a posterior branch. *The anterior branch*, the larger of the two, passes across the outer and upper extremity of the great wing of the sphenoid bone to the anterior inferior angle of the parietal bone, terminating in numerous branches which extend upward and backward toward the interparietal suture. Occasionally the grooves for the accommodation of this artery so deeply indent the bone as to be eventually built over, thus forming canals. *The posterior branch* of the great meningeal passes backward and upward along a groove, and crosses the squamous portion of the temporal bone to the posterior half of the parietal bone, where it usually divides into two, the anterior branch ascending toward the vertex, while the other branch passes backward toward the occipital bone.

The great meningeal artery before passing into the brain-case supplies through its branches a portion of the pterygoid muscle and the tissue in proximity to the foramen spinosum. After entering the cranium it supplies the dura mater, the bones, the diploë, the lachrymal gland, the

ganglion of Gasser of the fifth pair of nerves, and passes through the hiatus Fallopii to anastomose with the stylo-mastoid branch of the posterior auricular artery. It also anastomoses with branches of the ophthalmic artery.

The Small Meningeal Artery is a branch often arising from the great or middle meningeal artery before it enters the brain-case. In some instances it arises from the upper part of the internal maxillary artery, and passes into the brain-case through the oval foramen in the great wing of the sphenoid bone. Before entering the brain-case its branches supply the nasal fossa and soft palate. After passing into the cavity of the skull it supplies the dura mater, bones and diploë of the middle fossæ, and the ganglion of the fifth pair of nerves.

The Inferior Dental Artery arises from the under part of the internal maxillary. It passes downward and forward between the internal lateral ligament and the neck of the lower jaw to the posterior or inferior dental foramen, through which it passes, accompanied by the inferior dental nerve, into the inferior dental canal. Traversing this, it terminates at the anterior or mental foramen in two divisions, known as the incisor and mental branches. A small twig is given off close to its origin (sometimes arising from the internal maxillary), and, with the lingual nerve, is distributed to the mucous membrane of the mouth.

The Mylo-hyoid Branch is given off from the inferior dental artery immediately before entering the posterior dental foramen. It descends into the mylo-hyoid groove with the nerve and vessels of the same name, and is distributed to the under surface of the mylo-hyoid muscle. The portion of the inferior dental artery within the canal gives off numerous small branches to supply the teeth and their surroundings.

The Incisor Branch is a continuation of the inferior dental artery, and passes forward within the cancellated structure of the bone to supply the region of the chin and the anterior teeth.

The Mental Branch passes out through the anterior dental or mental foramen, accompanied by the nerve of the same name, and supplies the soft parts in the region of the chin, finally anastomosing with branches of the facial artery.

ARTERIES OF THE SECOND DIVISION.

The Deep Temporal Branches of the internal maxillary are two in number, anterior and posterior.

The Deep Anterior Temporal is situated in the anterior portion of the temporal fossa, advancing upward and forward along the temporo-sphenoidal suture between the muscles and pericranium, its course being indicated by the groove in the bone. In its ascent twigs are given off to the temporal muscle, the bone, and occasionally to the diploë. Small branchlets anastomose with the other temporal arteries. Offshoots also pass forward through the small foramina in the malar bone to anastomose with the lachrymal branch of the ophthalmic artery.

The Deep Posterior Temporal passes upward and slightly backward, to be distributed to the deep portion of the temporal muscle, the pericranium, and occasionally the diploë.

The Pterygoid Branches are not constant in number. They are small and short; as their name indicates, they are distributed to the pterygoid muscles.

The Masseteric Branch is small and regular. It passes outward through the sigmoid notch of the lower jaw, accompanied by the nerve of the same name, and is distributed to the masseter muscle. It anastomoses with the transverse facial artery, and may arise conjointly with the posterior deep temporal. Velpeau is of the opinion that in dislocations of the jaw this vessel is compressed, and may be ruptured.

The Buccal Branch is a small vessel which passes downward and forward between the internal pterygoid muscle and the jaw to the outer side of the buccinator muscle, to which it is distributed. It anastomoses with the transverse facial and branches of the facial artery.

ARTERIES OF THE THIRD DIVISION.

The Alveolar or Superior Maxillary Branch generally arises with the infraorbital branch. It passes downward along the zygomatic surface and tuberosity of the superior maxillary bone, and gives off small branches, the posterior dental arteries, which enter the posterior dental canals; twigs from these supply the superior molar and bicuspid teeth, and anastomose with the anterior dental portion of the infraorbital branch. The mucous membrane of the maxillary sinus is partly supplied by the posterior dental arteries, offshoots being also distributed to the alveolar process and gums.

The Infraorbital Branch usually arises conjointly with the alveolar branch. It passes forward, in company with the superior maxillary or infraorbital nerve, along the infraorbital canal, from which it finds exit upon the face through the infraorbital foramen. In the canal offshoots are supplied to the inferior rectus and inferior oblique muscles of the eye, the lachrymal gland, the connective tissue in the floor of the orbit, and the mucous membrane of the maxillary sinus. It also gives off the anterior dental artery, which descends through a canal in the bone to supply the incisor, cuspid, and bicuspid teeth. This artery anastomoses with the posterior dental of the alveolar branch, the union, however, taking place in such a way as to make it difficult to say which artery supplies the bicuspid teeth. On the face twigs from the infraorbital supply the lachrymal sac and the surrounding tissue near its exit. They also anastomose with branchlets of the facial, the nasal of the ophthalmic, and the transverse facial and buccal.

The Descending Palatine or Superior Palatine Branch passes downward in the posterior palatine canal, accompanied by the anterior palatine nerves (branches of the spheno-palatine (Meckel's) ganglion), and emerges upon the posterior and lateral part of the hard palate. It passes forward in a groove on the hard palate to the incisive foramen, at which point it anastomoses with a branch of the naso-palatine artery. While in the posterior palatine canal small twigs are given off to the mucous membrane of the nose and tonsils. It also supplies the hard palate, alveolar process, palatine mucous glands, mucous membrane, and the gum tissue of the superior maxilla, and anastomoses with the ascending palatine branch of the facial.

The Vidian Branch passes backward in the Vidian canal in the opposite direction to the Vidian nerve. Its branches are distributed to the upper part of the pharynx, the opening of the Eustachian tube, the levator palati muscle, and to the tympanum. It anastomoses with the ascending pharyngeal and stylo-mastoid arteries.

The Pterygo-palatine Branch is a small artery which passes backward and downward in the pterygo-palatine canal, accompanied by the pharyngeal nerve. It is distributed to the sphenoidal cells, Eustachian tube, and upper part of the pharynx.

The Nasal or Spheno-palatine Branch may be considered as the terminal of the internal maxillary artery. It passes in a forward direction, entering the nasal chamber through the spheno-palatine foramen, which is situated at the back part of the superior meatus, dividing into internal and external branches. The internal division is the continuation of the spheno-palatine, and holds the same name, though sometimes it is called the artery of the septum, as it runs downward and forward in the groove of the vomer, and terminates by anastomosing with the descending palatine artery at the incisive foramen. It is distributed to the bone, cartilage, and mucous membrane of the nasal septum. The external branches, several in number, are distributed to the lateral part of the nose, including the ethmoidal and sphenoidal cells, the maxillary sinus, and the mucous membrane covering these parts.

Variations.—The internal maxillary artery seldom varies in its origin, though it has been known to arise from the facial (Quain). The number of branches given off may vary, there being two or more, which arise by one common trunk. The branches may also convey blood to parts which are generally supplied by the facial and lingual, and by the branches of the ophthalmic and the temporal arteries. In the same way the cranial branches may interchange with those of the internal carotid.

The Internal Carotid Artery.

The Internal Carotid Artery (Fig. 110) is about 6 mm. ($\frac{1}{4}$ inch) in calibre, and, as its name indicates, is distributed in great part to the internal, middle, and anterior structures of the brain-case. It also supplies the eye and the parts within the orbit, and partially the nasal chamber, forehead, and nose. It is one of the terminal branches of the common carotid, arising from that artery at its bifurcation opposite the superior border of the thyroid cartilage, from which point it passes upward, generally with a slight curve, to the carotid foramen in the petrous portion of the temporal bone.

The internal carotid artery is divided anatomically into four portions —cervical, petrous, cavernous, and intracranial.

The Cervical Portion is situated within the neck, extending from the origin of the internal carotid in the superior carotid triangle to the carotid foramen. Its line is usually slightly curved, though almost vertical, but in some cases it will be found to be quite tortuous.

Relations.—At first it is located more superficially than the external carotid, and a little posterior to its outer side. It is covered by the

FIG. 110.

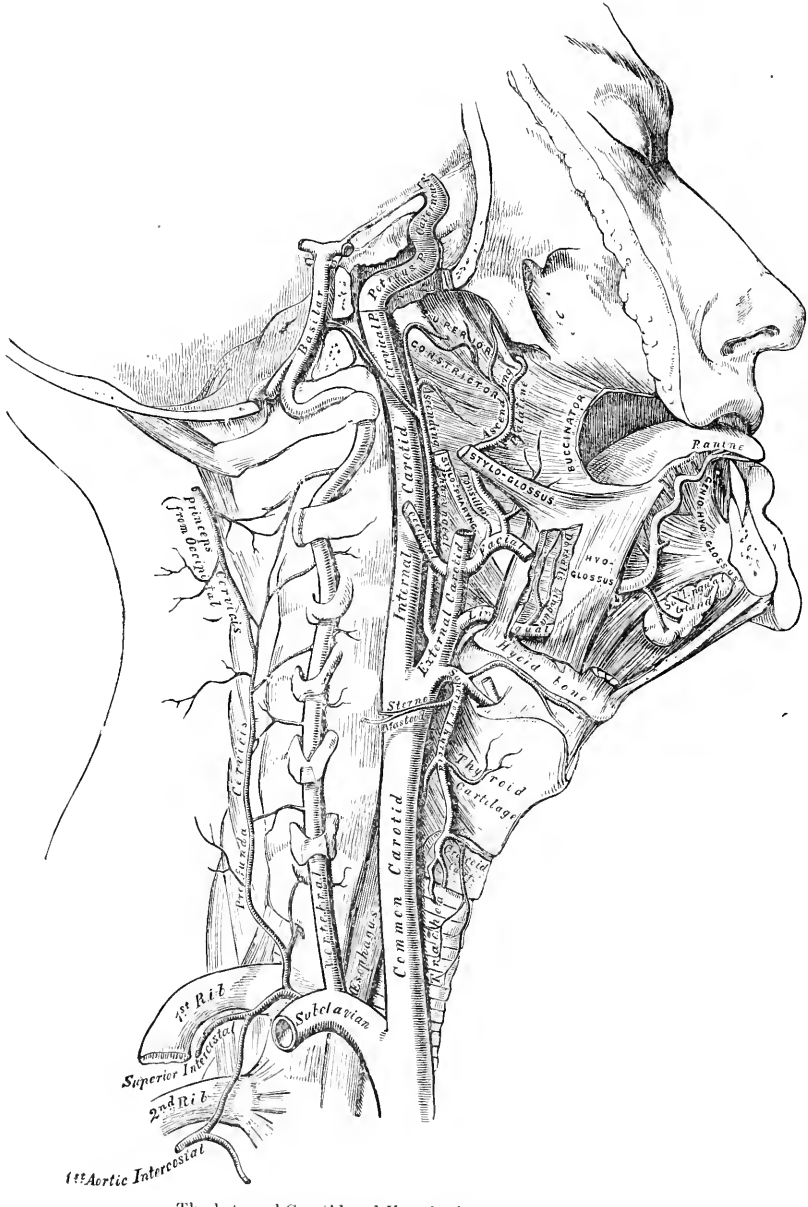

The Internal Carotid and Vertebral Arteries, right side.

fascia, the internal border of the sterno-cleido-mastoid muscle, platysma myoides, and skin. Upon reaching the posterior belly of the digastric muscle it passes beneath it and the stylo-hyoid, and continues to the inner side of the external carotid. Above this point it is deeply

situated in the neck, the parotid gland, the styloid process, and stylo-pharyngeus muscle being to its outer side. Its deep relations are with the tonsils, the superior constrictor muscle separating them, the walls of the pharynx, and transverse process of the upper three cervical vertebræ, the rectus capitis anticus major muscle being posterior to it. The artery is enclosed in a sheath in company with the internal jugular vein and pneumogastric nerve, the vein lying upon the outer side posterior to the artery. Upon reaching the skull the vein separates from the artery and passes through the jugular or posterior lacerated foramen, the artery passing through the carotid foramen. The glosso-pharyngeal, pneumogastric, spinal accessory, and hypoglossal nerves are situated between the two vessels near these foramina. The occipital and posterior auricular arteries cross it on the outside, the former below the digastric muscle, the latter above. The pneumogastric nerve and the upper cervical ganglion of the sympathetic are deeper than, and situated posterior to, the vessel. The hypoglossal nerve crosses to its outer side, near the lower margin of the digastric muscle; the glosso-pharyngeal nerve and pharyngeal branch of the pneumogastric pass between the external and internal carotids. The superior and external laryngeal nerves are internal to both arteries.

The cervical portion of the internal carotid seldom gives off any branches, though occasionally its lower portion supplies the occipital or ascending pharyngeal arteries. These, however, are rare variations.

The Petrous Portion of the internal carotid enters the carotid foramen on the under surface of the temporal bone, and passes through a canal to a point where it enters the cavernous sinus within the brain-case. Its course within the bone is at first upward, passing immediately in front of the tympanum or middle ear and the internal ear, being separated from them by a thin lamina of bone. It then passes horizontally forward and inward to the middle lacerated foramen, extending across the tissues filling in this aperture.

This portion of the artery gives off a small branch to the tympanum which anastomoses with tympanic branches from divisions of the external carotid.

The Cavernous Portion of the internal carotid commences immediately above the middle lacerated foramen, and passes upward to and along the sigmoid groove on the lateral surface of the body of the sphenoid bone. It terminates in the intracranial portion of the artery by passing through the upper wall (which is membranous) of the cavernous sinus close to the anterior clinoid process. The artery is situated on the inner portion of the cavernous sinus. It is surrounded by filaments of the sympathetic nerve, and is accompanied by the sixth nerve, which is situated to its outer side. These structures are all covered by an envelope derived from the lining membrane of the sinus. The third, fourth, and ophthalmic nerves pass through the sinus external to the envelope.

Branches of this portion of the artery are distributed to the dura mater, the pituitary body, Gasserian ganglion, and the walls of the cavernous and inferior petrosal sinuses. It also gives off a branch which anastomoses with the middle meningeal artery.

The Intracranial Portion of the internal carotid commences after the

artery passes through the upper wall of the cavernous sinus. Just above this point the optic nerve passes to the inside of the artery, while the third nerve passes externally. Near the anterior clinoid process this portion of the artery gives off its first large branch, the ophthalmic, while near the fissure of Sylvius it gives off the lateral (posterior) communicating artery of the circle of Willis. Above this point it finally divides into the middle and anterior cerebral arteries.

The branches of this portion of the artery are the ophthalmic, the anterior, and the middle cerebral.

The Ophthalmic Artery (Fig. 111) is about 2 mm. ($\frac{1}{12}$ inch) in calibre. It is the first large branch of the internal carotid, arising from that artery immediately after it passes through the dura mater, at the last curve of the sigmoid flexure, just internal to the anterior clinoid process. From this point it passes forward and a little outward over the anterior portion of the cavernous sinus, through the optic foramen into the cavity of the orbit, passing below and to the outer side of the

FIG. 111.

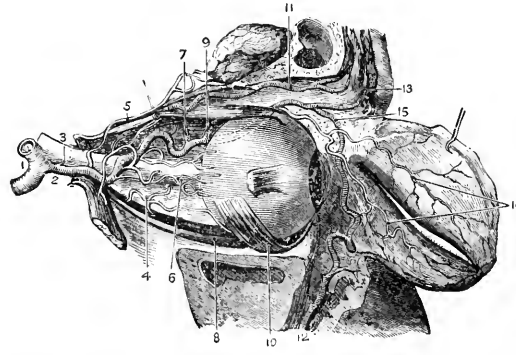

Arteries of the Orbit, from the outer side: 1, internal carotid; 2, ophthalmic artery; 3, arteria centralis retinæ; 4, muscular branches; 5, lachrymal artery; 6, ciliary artery; 7, posterior ethmoidal artery; 8, rectus inferior; 9, anterior ethmoidal artery; 10, obliquus inferior; 11, supraorbital artery; 12, facial artery; 13, frontal artery; 14, palpebral artery; 15, nasal artery.

optic nerve. The artery and nerve are enclosed within the same sheath, which is derived from the dura mater. Within the cavity of the orbit the artery leaves the sheath and passes obliquely over (occasionally under) the nerve to the inner wall of the cavity, along which it travels in a horizontal direction between the superior oblique and internal rectus muscles to the trochlear process or notch. Here it terminates by dividing into frontal and external nasal branches.

The branches of the ophthalmic artery are the lachrymal, supraorbital, central retinal, ciliary, posterior and anterior ethmoid, muscular, palpebral, frontal, and external nasal.

The Lachrymal Artery is the first branch given off by the ophthalmic. It arises from its outer side immediately after it enters the cavity of the orbit, and frequently while the artery is still within the optic foramen. Together with the lachrymal nerve it passes along the outer wall of the orbit below the external rectus muscle, and is distributed principally to the lachrymal gland. The branches of the lachrymal artery are its

terminal ones, which pass to the upper eyelid and the conjunctiva, and anastomose with branches of other arteries distributed to this region of the face. One or two small twigs pass from the artery through foramina in the malar bone to the temporal fossa, anastomosing with the deep temporal artery. Small branches also pass through the same bone and anastomose with the deep and superficial arteries of the cheek, which are branches of the transverse facial. A branch from the lachrymal, which is given off soon after its origin, passes backward through a notch in the margin of the anterior lacerated foramen, supplies the dura mater, and anastomoses with the middle meningeal artery. Other branches are distributed to the membrane covering the outer wall of the orbit, the external and superior recti muscles, and the levator palpebræ superioris muscles.

The Central Retinal Artery is a small branch arising from the ophthalmic soon after it passes out of the optic foramen. It passes obliquely through the centre of the optic nerve, about a quarter of an inch posterior to its point of entrance into the eyeball, and is distributed to the retina and the hyaloid membrane. During embryonic life this artery has a central branch which passes forward through the middle of the vitreous humor of the eye to the posterior portion of the lens, upon which it is lost.

The Ciliary Arteries are divided into a posterior and anterior set, the former being subdivided into short and long ciliary arteries.

The Short Ciliary Arteries number four or five, and arise from the ophthalmic as it crosses the optic nerve. They soon divide into twelve or fifteen small branches, which pass forward in a tortuous or spiral course through the adipose tissue surrounding the optic nerve to the posterior part of the eyeball, where they pierce the sclerotic coat in close proximity to the entrance of the optic nerve. Passing through the sclerotic, they enter the choroid coat, and immediately break up into a minute capillary plexus which forms the greater part of the internal coat of the choroid. From the anterior portion of this plexus small vessels are given off which pass to the ciliary processes.

The Long Ciliary Arteries are two in number, and but slightly larger than the short ciliary vessels. They pass forward, one on each side of the eyeball, and enter the sclerotic coat, passing between it and the choroid to the ciliary ligaments, where they each divide into two branches, superior and inferior. The four branches then diverge and pass forward to the periphery of the iris (circulus major), where they reunite and form an arterial circle. From this circle branches are distributed to the iris, some of the concentric extremities uniting to form an inner circle (circulus minor) on the free or pupillary margin of the iris.

The Anterior Ciliary Arteries number six or eight, and arise from the muscular and lachrymal branches. They communicate freely with each other, and form a vascular circle around the anterior portion of the eyeball between the conjunctiva and the sclerotic coat of the eye. From this circle small vessels pass through the sclerotic coat one or two lines posterior to the margin of the cornea, and join the external vascular circle of the iris.

The Posterior Ethmoid Artery arises from the inner side of the ophthalmic nearly opposite the posterior ethmoidal foramen. It passes through this foramen, and is distributed, by a small meningeal branch, to the portion of the dura mater situated in the anterior fossa of the brain-case, as well as to the mucous membrane lining the posterior ethmoidal cells and to the superior portion of the internal nose.

The Anterior Ethmoidal Artery is larger than the posterior. It arises from the inner side of the ophthalmic close to the anterior ethmoidal foramen. It passes through this foramen into the brain-case immediately above the cribriform plate of the ethmoid bone, and is accompanied by the nasal nerve. The artery and nerve pass together through the cerebro-nasal slit (anterior nasal foramen) of the ethmoid bone into the nasal chamber, where the vessel receives the name of the anterior nasal artery. The anterior ethmoidal artery is distributed through its branches to the antero-ethmoidal cells, the dura mater of the anterior fossa of the brain-case, the mucous membrane of the olfactory portion of the nasal chamber, including the superior and inferior turbinated bones, and to the roof and septum of the nose, the branch supplying the septum anastomosing with the naso-palatine artery. It is also distributed to the frontal sinus, a branch passing between the nasal bones and lateral cartilage in company with the nasal nerve, and anastomoses on the face with branches from the facial artery.

The Muscular Arteries, branches of the ophthalmic, consist of two principal ones, superior and inferior, and several smaller twigs.

The Superior Muscular Artery is the smaller of the two larger branches of the ophthalmic, and is distributed to the levator palpebræ superioris, superior rectus, and superior oblique muscles. The existence of this artery is not constant.

The Inferior Muscular Artery passes anteriorly from the ophthalmic, and is distributed to the external and inferior recti and inferior oblique muscles. Its existence is more constant than the superior branch, and it furnishes the principal number of the anterior ciliary arteries.

The Smaller Muscular Arteries arise from the ophthalmic at various points along its course, as well as from its lachrymal and supraorbital branches. They are distributed to the different muscles of the eye.

The Supraorbital Artery is the largest branch of the ophthalmic. It arises in the posterior portion of the cavity of the orbit as the artery crosses the optic nerve. It passes above the muscles of the eye, accompanied by the frontal nerve, and extends anteriorly between the periosteum covering the roof of the orbital cavity and the levator palpebræ superioris muscle to the supraorbital foramen in the frontal bone. It passes through this foramen and divides into two branches, superficial and deep. These branches anastomose with the temporal and angular arteries, and with their fellows of the opposite side.

The Superficial Branch is distributed to the frontal muscle and to the integument over this region.

The Deep Branch is distributed to the periosteum of the frontal bone.

The superficial and deep branches of the supraorbital artery also send branches to the muscles within the orbit, and, as the supraorbital passes out of the orbit, it supplies the diploë of the frontal bone by a branch

which enters a small foramen often seen within the supraorbital foramen or notch.

The Palpebral Arteries are two in number, superior and inferior. They usually arise together from the ophthalmic, nearly opposite the pulley of the superior oblique muscle. From this point they diverge, the superior branch passing above, the inferior below, the internal tarsal ligament. They distribute small branches to the conjunctiva and the lachrymal caruncle and sac. They then pass outward between the orbicularis palpebrarum muscle and the trochlea, and encircle the eyelids near their free margins. They anastomose with branches of the lachrymal as well as with the orbital branches of the temporal and infraorbital arteries. A branch from the palpebral artery generally accompanies the nasal duct into the nasal chamber.

The Frontal Artery is one of the terminal divisions of the ophthalmic, and arises in close proximity to the trochlear process or notch on the frontal bone. It passes out of the orbital cavity, curves around the internal angular process of the frontal bone or inner extremity of the supraorbital arch, and is distributed to the superior lid of the eye, integument, muscles, and pericranium of the forehead, as well as to the nasal slip of the frontal muscle. It anastomoses with its fellow of the opposite side and with the supraorbital artery.

The External Nasal Artery is the other terminal division of the ophthalmic. It arises close to the trochlear process or notch on the frontal bone, and passes forward over the internal tendo palpebrarum and through the orbicularis palpebrarum muscle. It then extends downward along the root of the nose, and communicates with the angular and nasal arteries, branches of the facial. Occasionally it communicates by a small branch with the artery of the opposite side, or it may pass down the nose and anastomose with the anterior nasal artery, a branch of the anterior ethmoidal. In its course it gives off branchlets to the lachrymal sac, canal, and caruncle and the orbicularis palpebrarum muscle.

Variations.—The lachrymal artery may arise directly from the middle meningeal. When it so arises it passes out of the brain-case through the notch in the border of the anterior lacerated foramen, and gives off a small recurrent branch, which communicates with the lachrymal and middle meningeal arteries, and again becomes part of the main trunk of the lachrymal. Occasionally the major portion, or even all, of the blood-supply of the lachrymal artery comes through this source. Where the facial artery is small or altogether wanting the nasal artery is of large size and supplies its place. The terminal branches of the ophthalmic artery have a large and varied communication with other arteries in this region, such as its fellow of the opposite side, the facial, infraorbital, transverse facial, temporal, middle meningeal, ethmoidal, and the spheno-palatine.

The Cerebral Arteries.

The Cerebral Arteries, branches of the internal carotid, are two in number, anterior and posterior, the posterior cerebral artery being a branch of the basilar.

The Anterior Cerebral Artery is about 3½ mm. (1/7 inch) in calibre. It is one of the terminal divisions of the internal carotid, and arises at the inner extremity of the fissure of Sylvius, close to the anterior clinoid process. It passes inward and forward nearly at right angles with the internal carotid, and at an obtuse angle with the middle cerebral, to a point in close proximity to its junction with its fellow of the opposite side, which occurs at the rostrum of the corpus callosum, anterior to the lamina cinerea, where it gives off the anterior communicating artery which forms a part of the circle of Willis. From this point it passes forward a short distance from and nearly parallel with its fellow of the opposite side until it reaches the anterior portion of the corpus callosum, around which it curves, and breaks up into several branches to supply the structures in the anterior portion of the brain-case.

The Middle Cerebral Artery is about 5 mm. (1/5 inch) in calibre, and is one of the largest of the terminal divisions of the internal carotid. It arises at the inner extremity of the fissure of Sylvius, and passes obliquely upward and outward within the fissure to the superior surface of the island of Reil. Here it subdivides into several branches, which are distributed to the brain. It also, on the anterior portion, gives off the lateral (posterior) communicating artery of the circle of Willis.

The Posterior Cerebral Artery is about 3½ mm. (1/7 inch) in calibre, and is one of the two terminal branches of the basilar, hereafter to be described. It arises with the corresponding artery of the opposite side at a point just anterior to the pons varolii, close to the posterior clinoid process of the sphenoid bone. It extends outward, and then curves backward around the crus cerebri, and passes outward and upward between the occipital lobe of the cerebrum and the cerebellum. It gives off numerous branches which supply the different structures of the brain, as well as the lateral (posterior) communicating artery of the circle of Willis.

The Circle of Willis is a system composed of several short arteries which communicate with each other and form a vascular circle which surrounds the following structures at the base of the brain: the lamina cinerea, optic commissure, infundibulum and tuber cinereum, corpora albicantia, and posterior perforated space.

The circle of Willis is composed of the following arteries: the two anterior cerebral, the anterior communicating, the upper portion of the two internal carotids, the two lateral (posterior) communicating, and the two posterior cerebrals.

The Two Anterior Cerebral Arteries form that portion of the circle of Willis which extends forward and inward from their origin, which is at the termination of the internal carotid, to the rostrum of the corpus callosum just anterior to the lamina cinerea.

The Anterior Communicating Artery is about two lines in length, and passes from one anterior cerebral artery to the other across the rostrum of the corpus callosum anterior to the lamina cinerea. It forms the anterior communicating branch of the circle of Willis between the two anterior cerebral arteries. It also gives off branches which supply some of the structures in close proximity to it.

Variations.—This artery is occasionally represented by two branches,

and at times it is absent. When this is the case the two anterior cerebrals are united into one in a similar manner to the two vertebrals which form the basilar artery.

The upper portions of the two internal carotid arteries are situated close to the anterior clinoid processes of the sphenoid bone, and in calibre are much the largest of any of the arteries which form the circle of Willis, though they constitute but a small part of its circumference. Anteriorly they give off the anterior cerebral arteries, while posteriorly they give origin to the posterior communicating arteries.

The Lateral (Posterior) Communicating Arteries are situated laterally instead of posteriorly, as the generally-used name would imply. They are seldom of equal size, the right being most frequently the larger. They extend from the upper extremity of the internal carotid backward and slightly inward, and pass beneath the optic tract and the crus cerebri to the posterior cerebral arteries. At their most anterior portion in front of the pons varolii they give off numerous branches to parts in close proximity.

Variations.—The two lateral (posterior) communicating arteries occasionally arise from the middle cerebral instead of the internal carotid.

The Two Posterior Cerebral Arteries form the posterior portion of the circle of Willis. They are larger in calibre than any of the other arteries which form the circle, except the terminal extremities of the internal carotids. They extend from the bifurcation of the basilar artery in front of the pons varolii outward and slightly forward to the point of junction of the lateral (posterior) communicating arteries.

Variations.—Occasionally this portion of the posterior cerebral artery is quite small. When this is the case the corresponding artery of the opposite side is proportionately large, thus equalizing the blood-supply.

The Basilar Artery is formed by the union of the right and left vertebrals, which are branches of the subclavian arteries at the base of the neck. This arrangement of vessels, together with the external carotids and the circle of Willis, forms such a continuous communication that if the common carotid be ligated or entirely obliterated on either side, the blood may yet circulate to all parts of the brain, and also pass out of the brain-case and supply the external parts of the head and face through the anastomotic unions of the vessels of these parts.

Subclavian Arteries.

The Subclavian Arteries are two in number, right and left, extending from their origin, the right from the innominate, the left from the arch of the aorta, to their terminations at the first ribs. Each forms an arch, the concavity of which is directed downward, and the greater portion of which is situated in the inferior posterior cervical triangle of the neck. The proximal portion rests in the thoracic cavity. The artery passes over the first rib and under the central portion of the clavicle into the axilla. The summit of the arch is situated within the neck posterior to the scalenus anticus muscle. The origin and relations of the proximal portion of the arteries on either side are dissimilar, and will therefore be separately described. The subclavian arteries are divided into three portions.

The first or ascending portion of the right subclavian artery arises from the innominate or brachio-cephalic artery at its point of bifurcation into the right subclavian and right common carotid, which latter is situated close to the trachea posterior to the sterno-clavicular articulation. From this point it passes upward, outward, and a little backward until it reaches the proximal border of the scalenus anticus muscle at the base of the neck.

The second or transverse portion is the shortest, and is situated higher in the neck than the remainder of the artery, thus forming the dome of the arch. It commences at the termination of the first portion of the artery, and passes outward behind the scalenus anticus muscle to its distal border.

The third or descending portion of the artery passes downward, outward, and forward from the distal border of the scalenus anticus muscle to a point where it passes from the neck over the first rib and under the clavicle into the axilla, where it becomes the axillary artery. The third portion of the subclavian artery is the most superficial. It passes through a triangular space formed by the clavicle below, the omo-hyoid muscle externally, and the anterior scalenus muscle internally.

Relations.—The first or ascending portion of the right subclavian artery is covered by the skin, platysma myoides, deep fascia, outer attachment of the sterno-cleido-mastoid muscle, the sterno-hyoid and sterno-thyroid muscles, and the sternal end of the clavicle. The internal jugular and the vertebral veins cross it on their way to empty into the right innominate vein. The pneumogastric nerve crosses to the inner side of the internal jugular vein, while the cardiac branches of the sympathetic and the phrenic nerves also pass over it. Its deep surface is in close relation to the pleura, and behind it is separated by a cellular interval from the longus colli muscle and the transverse process of the seventh cervical vertebra. The right innominate vein is situated below and slightly anterior to the artery, while the recurrent or inferior laryngeal nerve passes over it, returns upon itself, passes under the artery, and extends upward to the larynx.

The second or transverse portion of the subclavian is wholly covered by the scalenus anticus muscle, while more superficially it is crossed by the sterno-cleido-mastoid. The left phrenic nerve passes over the second portion of the left subclavian artery, in this differing from the right phrenic nerve, which crosses the first portion of the right subclavian. It is also covered by the integument, platysma myoides, and the deep fascia. The deep surface of the artery is in relation with the middle scalenus muscle posteriorly, the brachial plexus of nerves above, and below with the pleura. The scalenus anticus muscle is between the subclavian artery and vein, the latter being anteriorly situated.

Relations.—The third or descending portion of the subclavian artery is covered by the integument, platysma myoides, and deep fascia. The subclavian vein lies superficial to, though slightly below, it, while the external jugular and the veins of the shoulder pass over it to enter the subclavian vein. It is also in close relation to the brachial plexus of nerves, most of which pass over it, while one or two pass under it.

The first or ascending portion of the left subclavian artery is some-

what longer than the right, and is more deeply situated in the thoracic cavity. It usually arises directly from the left extremity of the transverse portion of the arch of the aorta, opposite the second dorsal vertebra. From this point it passes almost vertically upward, though slightly outward, and emerges from the thorax into the neck, where it makes a sharp curve outward over the apex of the left lung to reach the proximal margin of the anterior scalenus muscle, from which point its direction and relations correspond to the artery of the right side, and therefore need no special description.

Relations.—The first or ascending portion of the left subclavian artery is situated at its origin behind the pleura and upper portion of the left lung. It is crossed by the left innominate vein, the internal jugular, and vertebral veins. The pneumogastric nerve passes down in front of it, and comes in contact with it near its origin. The phrenic nerve crosses the artery close to the anterior scalenus muscle and external to the thyroid axis. The cardiac nerves also pass in front of the artery. Its deep surface is in close relation to the vertebræ, a portion of the œsophagus, the thoracic duct, and longus colli muscle. The cord of the sympathetic nerve passes up behind this surface. Internally are the left common carotid artery, trachea, a portion of the œsophagus, and thoracic duct. Externally is the pleura.

The Branches of the Subclavian Artery are four in number—vertebral, internal mammary, thyroid axis, and superior intercostal. The first three of these arise from the first portion of the subclavian before it reaches the scalenus anticus muscle, while the last is derived from the second portion. Occasionally a branch arises from the third portion of the artery, and is known as the posterior scapular.

The Vertebral Artery.

The Vertebral Artery is about 5 mm. ($\frac{1}{5}$ inch) in calibre, and is usually the first and largest branch of the subclavian. The artery on the right side generally arises from the upper and posterior portion, about three-fourths of an inch from the brachio-cephalic or innominate artery; that on the left usually arises from the first portion of the subclavian as it curves to the left at the base of the neck.

Variations.—This artery may arise from any portion of the subclavian or the common carotid, and even from the arch of the aorta, though this latter abnormality is rare. Cases are reported where the vertebral artery arises as two branches.

From its origin the vertebral artery passes upward and slightly backward, and usually enters the foramen in the transverse process of the sixth cervical vertebra. Occasionally, however, it enters the foramen in the fifth, fourth, third, or even as high as the second, cervical vertebra. Sometimes it enters the foramen in the transverse process of the seventh cervical vertebra. It then passes upward through the remainder of the vertebral foramina, curves backward along the upper surface of the atlas, and enters the skull through the foramen magnum of the occipital bone. It passes along the side of the medulla oblongata to its anterior portion, and joins the vertebral of the opposite

side at the posterior inferior extremity of the pons varolii to form the basilar artery.

The Branches of the Vertebral Artery are divided into cervical and encranial. The cervical branches are the lateral spinal and muscular; the encranial branches are the posterior meningeal, posterior spinal, anterior spinal, and the posterior cerebellar. The distribution of these branches is generally implied in their names.

The Basilar Artery is formed by the union of the right and left vertebral arteries, which takes place at the posterior inferior extremity of the pons varolii. From this point it passes forward and upward within a groove along the middle of the superior surface of the basilar process of the occipital bone to the anterior extremity of the pons, close to the posterior clinoid processes. Here it divides into the posterior cerebral arteries already described.

The Branches of the Basilar Artery are the transverse, six or eight in number, which supply the under surface of the pons; the right and left auditory, which pass through the internal auditory meatus of the temporal bone, together with the auditory nerve, and supply the labyrinths of the ear; the anterior or inferior cerebellar, right and left, which supply the anterior inferior portion of the cerebellum and other structures in juxtaposition, and anastomose with the inferior cerebellar branches of the vertebral; the superior cerebellar, right and left, which supply through their numerous branches the cerebellum and other structures in the vicinity; and the terminal or posterior cerebral arteries previously described.

The Thyroid Axis is about 6 mm. ($\frac{1}{4}$ inch) in calibre and but a few lines in length. It arises from the anterior superior surface of the first part of the subclavian artery, and passes upward a very short distance close to the proximal border of the anterior scalenus muscle. Here it breaks up into three branches, inferior thyroid, suprascapular, and transversalis colli.

The Inferior Thyroid Artery is about $3\frac{1}{2}$ mm. ($\frac{1}{7}$ inch) in calibre. It arises from the thyroid axis, and could be regarded as a continuation of this artery. From its origin it passes directly upward in front of the vertebral artery and under the central portion of the omo-hyoid muscle. Slightly above the muscle, opposite the fifth cervical vertebra, it curves inward in a tortuous manner, and passes beneath the sheath of the large vessels of the neck and sympathetic nerve to the inferior part of the thyroid body. Here it breaks up into fine branches which supply the gland and anastomose with branches of the superior thyroid artery, as well as the corresponding artery of the opposite side. The other branches of the inferior thyroid are the ascending cervical, inferior laryngeal, and tracheal.

The Ascending Cervical Artery is about 2 mm. ($\frac{1}{12}$ inch) in calibre, and arises from the inferior thyroid just as it curves inward behind the sheath of the large vessels of the neck. It passes upward immediately anterior to the phrenic nerve in the interspace between the anterior scalenus and the rectus capitis anticus major muscles, and is distributed through small branches to these muscles, a few branches extending across the neck to anastomose with offshoots from the vertebral. Other

branches pass through the intervertebral foramina in close relation with the cervical nerves, and supply the bodies of the vertebræ, the spinal cord and its membranes, and anastomose at the upper portion of the cord with the ascending pharyngeal artery.

The Inferior Laryngeal Artery is not uniform in size, and arises from the inferior thyroid in close proximity to the thyroid body. It passes upward, accompanied by the recurrent or inferior laryngeal nerve, behind the inferior angle of the thyroid cartilage, and is distributed to the muscles and mucous membrane of the larynx.

The Tracheal Artery is very constant in its existence. It arises from the inferior thyroid opposite the transverse process of the seventh cervical vertebra, and passes downward behind the trachea to a point in close relation to the bifurcation of the trachea. Here the artery divides into branches which supply the trachea, bronchial tubes, lymphatic glands, and lower portion of the longus colli muscle, and anastomoses with the intercostal and bronchial arteries.

The Suprascapular Artery (transverse scapular or transverse humeral) is about 3½ mm. ($\frac{1}{7}$ inch) in calibre. It arises from the thyroid axis, and passes outward and downward to the scapula. Its branches are the thoracic, acromial, supraspinous, and infraspinous.

The Transversalis Colli, or Transverse Cervical Artery, arise from the thyroid axis, and passes outward in a tortuous course to the superior angle of the scapula, where it divides into the superficial cervical and posterior scapular arteries.

The Internal Mammary and Superior Intercostal Arteries are important to the head and neck, as they by their relation with other arteries complete the system of collateral circulation. The superior gives off the deep cervical, which communicates with the arteria princeps cervicis of the occipital artery.

THE VEINS.

The veins are those vessels of the body through which the blood is returned to the heart. They originate at the termination of the capillaries (minute vessels between the arteries and veins) throughout the body, and unite and anastomose to form larger vessels as they approach the heart. They inosculate more freely than do the arteries, and, unlike these, contain throughout their course numerous valves which open toward the heart and prevent regurgitation of the blood. The veins are divided into two groups—systemic and pulmonary.

The Systemic Veins are those which collect the blood from all portions of the body excepting the lungs. They are divided into two sets—those that collect the blood from the head, upper and lower extremities, and the greater portion of the body; and those that collect the blood from the alimentary canal and its glandular apparatus below the diaphragm, and terminate in the portal system. The systemic veins are again divided into superficial and deep.

The Pulmonary Veins, four in number, two for each lung, collect the blood, which is arterial, from the capillaries of the lungs and convey it to the left auricle of the heart.

Superior Vena Cava, Innominate, and Thyroid Veins.

The Superior or Descending Vena Cava (see Fig. 106) is the large vessel that receives all the blood from the upper extremities, the head, and the walls of the thoracic cavity. It is from 2 to 3 inches in length, and commences at the junction of the right and left innominate veins, internal to and just below the attachment of the first costal cartilage of the right side to the sternum. It passes almost directly downward, curving slightly to the left, and enters the right auricle opposite the third costal cartilage at its upper anterior portion, its orifice looking downward and forward.

The Innominate or Brachio-Cephalic Veins are two in number, right and left. They each originate at the junction of the subclavian and the internal jugular veins, which are situated posterior to the sternal extremities of the clavicles, and extend downward to the origin of the superior vena cava, which they form by their union. They are of unequal length, and differ from most of the other veins of the body by being destitute of valves.

The Right Innominate Vein is the shorter of the two, being but slightly over 1 inch in length. It extends from its commencement almost vertically downward external to the origin of the subclavian and innominate arteries, the pleura being interposed between it and the lung on the right side. The vessels which empty into it are the right thoracic (lymphatic) duct, the right vertebral vein, right mammary, right inferior thyroid, and the right superior intercostal veins.

The Left Innominate Vein is larger and longer than the right, being about 3 inches in length. It extends from its origin on the left side of the sternum from left to right across the superior and anterior portion of the chest, inclining slightly downward to its union with the right innominate vein. It is in relation with the sterno-clavicular articulation, the upper portion of the manubrium, from which it is separated only by the lower extremities of the sterno-hyoid and sterno-thyroid muscles and the thymus gland, or its remains in the adult. The three arteries arising from the arch of the aorta and the phrenic and pneumogastric nerves pass down the neck in close proximity to it, the transverse portion of the arch of the aorta being situated below it.

The Tributaries of the Left Innominate Vein are the thoracic (lymphatic) duct, the left vertebral, left inferior thyroid, and the left superior intercostal veins.

The Inferior Thyroid Veins are generally two in number, right and left, though occasionally there are three or even four. They are formed by the union of numerous small veins which originate in the lower portion of the thyroid body, and which anastomose with similar branches from the middle and superior thyroid veins. They pass downward, and form a plexus in front of the trachea below the isthmus of the thyroid gland. This plexus often causes trouble from hemorrhage in the operation of tracheotomy. The inferior thyroid vein (or veins, if there are more than one) of the right side are situated a little to the right of the median line, while those of the left side are usually directly in the median line. As they descend in front of the trachea

they are in close proximity to the sterno-thyroid muscles. The vein of the left side empties into the left innominate vein, while that of the right side varies in its termination. It may empty into the left innominate vein in common with the vein of the left side or at the junction of the right and left innominate veins, or into the right innominate vein. Occasionally there exists a median vein which is independent of the others, and which passes down along the central portion of the trachea anteriorly. These veins are all supplied with valves, which are situated at their terminal extremities.

The Tributaries of the Inferior Thyroid Veins are the tracheal and inferior laryngeal.

Veins of the Head and Neck.

The blood of the head and the greater portion of the neck is returned to the heart through the medium of two veins on either side, the external and internal jugular (Fig. 112). Close to their termination these large veins have valves. The other veins of the head and neck are generally not supplied with valves. They are divided into external and endocranial veins.

The External Veins are the temporo-maxillary, facial, temporal, internal maxillary, posterior auricular, occipital, lingual, and pharyngeal.

The Facial or Anterior Facial Vein commences near the inner angle of the eye at the termination of the angular vein. It passes downward and outward along the side of the nose, then extends obliquely to the facial notch in front of the lower border of the masseter muscle, where it passes inward and backward under the platysma myoides and deep fascia, and crosses the digastric muscle, below which it joins the anterior division of the temporo-maxillary vein. This union forms the common facial vein, which is a short trunk terminating in the internal jugular vein on a level with the hyoid bone. The general course of the facial vein is similar to the facial artery, though it is more superficially situated and less tortuous. Upon the face it is imbedded in the subcutaneous fat, and passes above all the facial muscles excepting the zygomaticus major, beneath which it extends.

The Tributaries of the Facial Vein are the

Angular,
Frontal,
Supraorbital,
Inferior palpebral (two or three),
Superior labial,
Deep facial, or
Anterior internal maxillary,
Buccal,
Masseter,
Parotid,
Submental,
Submaxillary,
Inferior palatine.

The Angular Vein is formed by the union of the frontal and supraorbital veins at a point near the articulation of the nasal and frontal bones. It is quite superficially situated, and passes obliquely downward and outward between the side of the nose and the inner margin of the orbit.

The Tributaries of the Angular Vein are the nasal arch, which, when

present, spans the root of the nose and communicates with the angular vein of the opposite side, the superior palpebral which is found on its orbital side, the commencement of the ophthalmic vein with which pos-

FIG. 112.

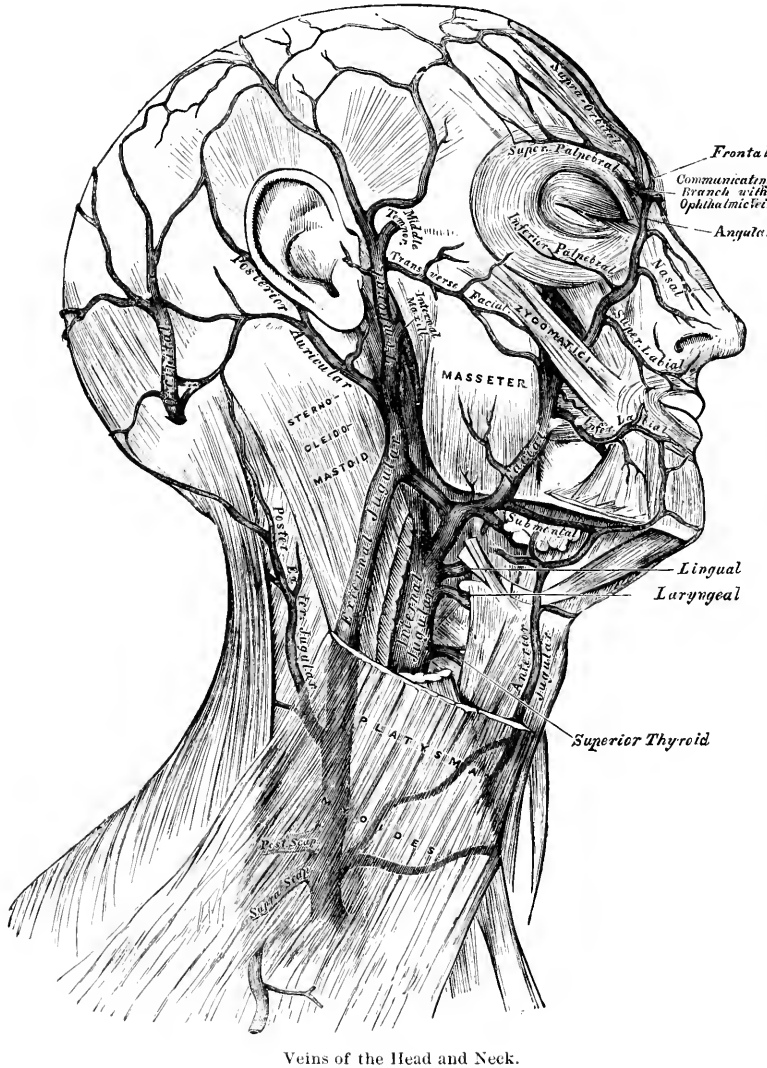

Veins of the Head and Neck.

teriorly it freely communicates, and anteriorly a few venules from the nose.

The Frontal Vein is formed by the union of numerous small branches situated over the greater part of the region of the frontal bone. It communicates with small branches from the temporal and supraorbital veins, as well as with branches from the corresponding vein of the opposite side. It passes downward beneath the proximal extremity of

the eyebrow and terminates in the angular vein. The right and left frontal veins occasionally communicate with each other, or they may unite to form a single trunk, separating again into two branches.

The Supraorbital Vein is much smaller than the frontal. It is formed by the union of small branches from the forehead, eyebrow, and eyelid, and inosculates with the temporal and ophthalmic veins, uniting with the frontal to form the angular vein.

The Inferior Palpebral Veins of either side originate in the lower eyelid, being formed by branches from adjacent parts anastomosing with the infraorbital veins. They terminate by emptying into the upper portion of the facial vein.

The Superior Labial Vein commences in a plexus situated in the upper lip, and anastomoses with the corresponding veins of the opposite side. It passes outward and upward, and enters the facial vein on a level with the ala of the nose.

The Deep Facial or Anterior Internal Maxillary Vein is of large size, and originates in the pterygoid plexus formed by the internal maxillary veins. It passes forward and downward in close apposition to the zygomatic surface of the superior maxillary bone, and terminates beneath the malar bone in the anterior facial vein.

The Buccal, Masseteric, and Parotid Veins are small branches that originate in the structures indicated by their names. They terminate by emptying into the lateral surface of the facial vein.

The Submental Vein is formed by branches which originate in the submental region. It passes backward along the base of the inferior maxillary bone, and terminates by emptying into the facial vein just as that vessel curves under the jaw. Its anterior branch communicates with the anterior jugular vein, and receives branches which come from the region of the submaxillary gland and the mylo-hyoid muscle.

The Submaxillary Veins originate in the submaxillary muco-salivary gland, and terminate either in the facial or submental vein.

The Inferior Palatine Vein originates in the structures in and about the tonsils and soft palate. It passes downward in close proximity to the pharynx, and generally terminates by emptying into the facial vein.

The following is from Allen's *Human Anatomy*, p. 417:

"It will be seen that the venous supply of the face differs in some important particulars from that of the trunk and limbs. In the last-named localities both deep and superficial currents flow in the same direction toward the heart. The facial trunk, however, is not formed by primal venules, as is commonly the case, but by branches communicating with the frontal and supraorbital veins, and by a transverse branch found at the bridge of the nose. It is highly probable that much of the blood of the interorbital space and of the locality about the inner canthus of the eye flows through the orbital conduits to the cavernous sinus. Farther down the face it is seen that the infraorbital artery alone of all the vessels of the face possesses venæ comites. These promptly join the orbital set of veins or aid in swelling the volume of the internal maxillary vein. The veins corresponding to the deep parts of the face, other than those mentioned, also seek an outlet in the same trunk, so that much of the superficial blood of the upper part and side

of the face passes *inward* to the brain-case and to the interior of the facial region, while the remaining portion flows *downward* to join the external and anterior jugular veins.

"It is of interest to note that in facial phlebitis the disease has a tendency to extend upward, except when the exciting cause lies at a point in or about the lower lip; in which case, as a rule, the inflammation extends downward. In a case reported by M. Bechez,[1] illustrative of of the fact just stated, a soldier, aged forty-two, was attacked with fever, followed by redness and slight swelling of the forehead. This swelling soon became more pronounced along the temporo-frontal veins, which were hard, prominent, and of a violet color. The eyelids were œdematous and the conjunctiva chimosed. The patient died about the seventh day. A somewhat similar case, recorded by Mr. T. H. Sylvester, is interesting from the fact that the frontal veins determined the extent of the inflamed tract. A puncture of the lip excited the phlebitis, which extended to a small vein at the outer side of the nose, thence to the inner canthus, and from that point along the frontal vein to the scalp, which became extensively infiltrated with pus. The case terminated fatally at the end of five weeks.

"The relations existing between the venous blood of the face and that of the brain-case are rendered evident by the fact that the state of the circulation of the external nose is sometimes an index of the condition of the vessels of the brain."

The Temporo-maxillary Vein is a short trunk which commences at the termination of the temporal and internal maxillary vein. It extends downward within the parotid gland and along the outer surface of the external carotid artery, between the sterno-cleido-mastoid muscle and the ramus of the jaw, to a point near its angle, where it divides into two branches. One branch passes downward and slightly forward, uniting with the facial to form the common facial vein; the other branch passes downward and backward, terminating in the external jugular vein.

The Common Temporal Vein is the medium through which, in great measure, the blood is returned from the region of the distribution of the temporal artery; the vein, however, does not accompany the artery in its course. It originates above the base of the zygoma at the termination of the superficial and middle temporal veins. It passes downward and inward beneath the parotid gland, and unites with the internal maxillary vein at the point of origin of the temporo-maxillary vein.

The Tributaries of the Common Temporal Vein are the superficial and middle temporals, the parotid, the articular, the anterior auricular, and the transverse facial veins.

The Superficial Temporal Vein originates through the union of numerous small branches in the form of a plexus which is situated over the region of the vertex and side of the head. It anastomoses with the corresponding artery of the opposite side, the frontal, supra-orbital, occipital, and posterior auricular veins. These branches pass downward, converge toward two central stems which finally unite, con-

[1] *Gaz. héb.*, 1863, 716.

tinue downward and pass forward in front of the ear to a point just above the zygoma, where it joins the middle temporal vein.

The Middle Temporal Vein originates in a plexus of veins situated in the temporal muscle. This plexus communicates with the deep temporal veins as well as with the pterygoid plexus. The vein then passes out of the muscle through the temporal fascia, and joins the superficial temporal vein just above the base of the zygoma. Its orbital branch originates from the union of a number of the external palpebral veins; it inosculates with the supraorbital and facial veins, passes backward, and terminates in the middle temporal vein.

The Parotid Veins are small vessels which pass from the parotid gland and empty into the common temporal vein.

The Articular Veins pass from the temporo-maxillary articulation and terminate in the common temporal vein.

The Anterior Auricular Vein passes from the external ear and empties into the common temporal vein.

The Transverse Facial Vein returns the blood from the region supplied by the transverse facial artery, and inosculates with the facial and infraorbital veins.

The Internal Maxillary or Posterior Facial Vein originates in a large plexus of veins which is situated between the temporal and external pterygoid muscles, as well as partly between the two pterygoid muscles. It passes backward and outward, accompanied by the internal maxillary artery, enters the parotid gland, and terminates by emptying into the temporo-maxillary vein about halfway between the zygoma and the angle of the jaw. The plexus from which the internal maxillary vein originates is formed by numerous tributaries which arise from the region supplied by the internal maxillary artery. These tributaries are the infraorbital, which commences on the face and anastomoses with the veins below the eye, and passes backward through the infraorbital canal and the spheno-maxillary fissure to join the pterygoid plexus; the posterior dental or alveolar, which commences on the surface of the superior maxilla and the posterior superior teeth; the superior palatine, spheno-palatine, and Vidian, which pass through the foramina indicated by their names to join the plexus; the inferior dental, which commences on the chin, receiving branches from the lower incisor teeth, and passes backward along the inferior dental canal, and emerges from the jaw at the posterior dental foramen, where it is joined by the mylo-hyoid vein. It then passes directly upward to the plexus; the deep temporal veins, three or four in number, descend to the plexus. There are also other muscular branches, such as the pterygoids, masseteric, and buccal, as well as a communicating branch from the inferior ophthalmic vein, which join the plexus. The middle meningeal veins are also tributaries. They are two in number, and are the venæ comites of the middle meningeal artery. They originate within the dura mater of the brain and inosculate with the cavernous sinus.

The Posterior Auricular Vein is much larger than the artery of the same name. It originates in a plexus formed by small veins situated at the posterior portion of the side of the head. This plexus

receives communicating branches from the temporal and occipital veins, and occasionally a branch from the mastoid vein. It passes downward behind the ear, crosses the mastoid process of the temporal bone and the upper portion of the sterno-cleido-mastoid muscle, and terminates by emptying into the external jugular vein.

The Occipital Vein commences on the back of the head, in the region supplied by the occipital artery. It is formed from a plexus of small veins and from the communicating branches of its fellow of the opposite side, as well as from branches which enter the posterior auricular and temporal veins. It generally communicates with the lateral sinus of the venous system of the brain through the emissary vein, a branch which traverses the mastoid foramen of the temporal bone. It extends downward and forward, accompanied by the occipital artery, and generally terminates by emptying into the internal jugular, though occasionally it joins the external jugular.

The Lingual Vein arises from three sources—the ranine, the two venæ comites, and the dorsal veins of the tongue.

The Ranine or Sublingual Vein is the largest of the branches which go to form the lingual. It commences by numerous superficial branches situated on the under surface of the tip of the tongue, and anastomoses with the corresponding vein of the opposite side. It extends backward, covered by the mucous membrane of the tongue, and, accompanied by the hypoglossal nerve, passes to the lateral surface of the hyo-glossus muscle. Small veins empty into it from the mucous membrane of the floor of the mouth, the substance of the tongue, and the sublingual gland.

The Two Venæ Comites are two small vessels which accompany the lingual artery, and terminate by emptying into the lingual vein.

The Dorsal Vein originates in a plexus which is situated on the under surface of the mucous membrane of the posterior part of the tongue. These veins occasionally unite to form one common trunk, or they may break up into several independent branches, which empty either into the external jugular or the common facial vein. Cases are reported in which they have emptied into the pharyngeal or internal jugular vein.

The Pharyngeal Vein originates in the pharyngeal plexus, which is formed by branches which pass from the lateral and posterior walls of the pharynx. It also receives branches from the soft palate and from the Vidian and meningeal veins, which pass through the oval and spinous foramina in the sphenoid bone, and from the pterygoid plexus. After receiving these branches it passes downward, and generally terminates by emptying into the internal jugular vein at the inferior extremity of the parotid gland, though occasionally it passes into the common facial vein or unites with the lingual or superior thyroid veins.

VEINS OF THE NECK.

The veins of the neck return the blood from the external and internal portions of the head and face, the neck, and part of the region of the shoulder. They are as follows:

External jugular, Internal jugular,
Anterior jugular, Vertebral.

THE EXTERNAL JUGULAR VEIN returns the principal portion of the blood from the internal surface of the face and the external surface of the head. It commences within the parotid gland near the angle of the inferior maxillary bone. It is formed by the confluence of the posterior auricular and the posterior division of the temporo-maxillary veins; it passes almost perpendicularly downward. Its position is indicated by a line drawn from the angle of the inferior maxilla to the middle of the clavicle. It is quite superficially situated, being covered only by the skin and the platysma myoides muscle. It is crossed about its centre by the superficial cervical nerve. After leaving the angle of the jaw it passes over the sterno-cleido-mastoid muscle, along its posterior margin, to a point just above the clavicle, where it pierces the deep fascia of the neck. It then extends slightly inward, and generally terminates by emptying into the subclavian vein in close relation to the external border of the anterior scalenus muscle. Occasionally it terminates by emptying into the internal jugular vein or at the point of junction of the internal jugular and subclavian veins. The external jugular is furnished with two sets of valves, one of which is imperfect and situated at its termination; the other set is perfect and located about an inch and a half above the clavicle.

Tributaries.—The tributaries of the external jugular vein are the posterior external jugular, transverse cervical, and suprascapular.

The Posterior External Jugular Vein commences by numerous branches, which are situated in the muscles, skin, and fascia in the region of the occiput and posterior portion of the neck. It terminates by emptying into the external jugular vein midway between the clavicle and the angle of the jaw.

The Transverse Cervical and Suprascapular Veins return the blood from the region of the shoulder, and closely follow the course of the suprascapular and transversalis colli arteries. These veins are supplied with valves.

THE ANTERIOR JUGULAR VEIN varies considerably in size, and is not constant in its existence. It commences below the chin, nearly in the median line, by branches situated in the suprahyoid region, the lower lip, and the chin. It also receives a communicating branch from the submental vein. It passes downward, in close relation to the middle of the neck, in a line with the sternal extremity of the clavicle. Slightly above the clavicle it pierces the deep fascia of the neck, passes outward and downward, behind the sterno-cleido-mastoid muscle, and generally terminates by emptying into the lower extremity of the external jugular vein, though occasionally it empties into the subclavian vein. Just after this vein pierces the deep fascia it generally receives a communicating branch from the facial vein, and also small branches from the larynx, and occasionally from the thyroid body. The transverse cervical and suprascapular veins sometimes terminate in the anterior jugular vein. The anterior jugular veins of both sides occasionally communicate through small branches which extend from the lower extremities, one branch usually being of considerable size, and passing through

the interfascial space just above the sternum. This vein is not supplied with valves.

The Internal Jugular Vein is the largest and most important of the veins which descend the neck, and returns the blood from the greater portion of the brain-case and superficial structures of the face and neck. It commences at the termination of the lateral and inferior petrosal sinuses in the enlarged and rounded portion of the posterior lacerated (jugular) foramen, from which it passes downward almost along a vertical line, and then slightly forward, and becomes superficial at the lower portion of the neck. Its position is indicated by a line drawn from the anterior portion of the mastoid process of the temporal bone to the sterno-clavicular articulation, beneath which it terminates by joining the subclavian vein to form the innominate vein. This vein is not of uniform calibre throughout its course. At its commencement is the dilatation known as its bulb or sinus. Opposite the hyoid bone it increases in size through its confluence with the common facial and several deep veins. Near its termination it is slightly diminished in calibre, and furnished with a single or double valve which is situated on its outer wall. This vein may be entirely absent on the left side (Gruber).

Relations.—At its commencement the internal jugular vein is situated posterior to the internal carotid artery, the ninth, tenth, eleventh, and twelfth nerves, and rests upon the rectus capitis lateralis muscle. It then passes to the lateral side of the internal carotid artery, the ninth (glosso-pharyngeal), and the twelfth (hypoglossal) nerves, passing between the vessels, while the tenth (pneumogastric) nerve passes downward posteriorly between the vein and the artery, within the common sheath, the eleventh, (spinal accessory) nerve passing backward to the inner side of the vein. After reaching the common carotid artery the vein extends downward, somewhat overlapping this vessel. The right internal jugular vein as it approaches its termination generally diverges slightly from the artery, while the vein of the left side crosses toward the median line.

Tributaries.—In addition to the lateral and inferior petrosal sinuses, the veins that empty into the internal jugular are as follows:

The pharyngeal,	Superior thyroid,
Lingual,	Middle thyroid,
Common facial,	Occipital (occasionally).

The pharyngeal, lingual, and common facial veins have already been described.

The Superior Thyroid Vein commences on the superficial surface of the thyroid body by numerous small branches which extend from its surface and the muscles in this region. It receives communicating branches from the superior laryngeal and crico-thyroid veins, and passes upward and backward to terminate in the internal jugular vein. Occasionally it empties into the common facial vein.

The Middle Thyroid Vein commences by branches situated in the lateral portion of the thyroid body, receiving tributaries from the larynx and the trachea. It passes outward over the common carotid

artery, and terminates by emptying into the internal jugular vein slightly above the level of the cricoid cartilage.

The Vertebral Vein commences by numerous branches situated in the occipital region, these branches anastomosing with the occipital, the deep cervical, and the posterior spinal veins. It passes downward along the vertebral artery through the foramina in the transverse processes of the first six cervical vertebræ, passes over the subclavian artery, and terminates by emptying into the innominate vein near its origin: it sometimes terminates in the subclavian. This vein is supplied near its termination by either a single or a double valve. Occasionally, as it passes down the body of the vertebræ, it receives two branches, one opening into the vessel as it enters the foramen in the transverse process of the atlas, while the other is received opposite the seventh or vertebral prominence.

The Venous Sinuses of the Cranium

are large canals (Fig. 113) analogous to veins, and into which the various veins of the brain, the ophthalmic vein, and several emissary veins

Fig. 113.

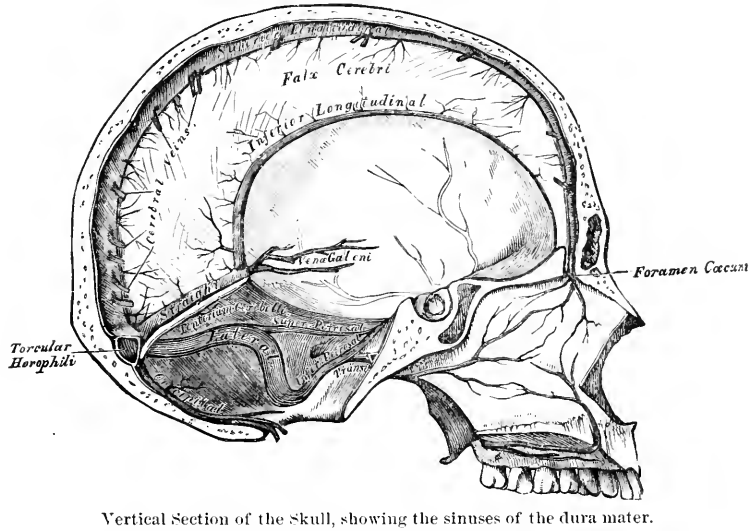

Vertical Section of the Skull, showing the sinuses of the dura mater.

empty. They are composed of two coats, internal and external. The internal coat is a delicate serous membrane, being a continuation of the lining membrane of the veins, while the outer coat is formed by the dura mater. From this fact they are known as the sinuses of the dura mater. They are fifteen in number, and are divided into two groups—the supero-posterior and the infero-anterior.

The Supero-posterior Group is composed of six sinuses:

Superior longitudinal,	Occipital,
Inferior longitudinal,	Right lateral,
Straight,	Left lateral.

Torcular Herophili.—Before passing to a description of the sinuses it will be well to describe what is known as the torcular Herophili. This is a dilatation formed by the confluence of the superior longitudinal, the straight, the occipital, and the two lateral sinuses, and is situated on the internal surface of the occipital bone at the internal protuberance, where the superior longitudinal sinus terminates and the lateral sinuses commence.

The Superior Longitudinal Sinus commences at the foramen cæcum in the frontal bone, just anterior to the crista galli. In infancy, and occasionally in adult life, this foramen is not a blind one, but opens into the nasal chambers. When this is the case the sinus commences within the nose. It passes upward, backward, and downward on the under surface and in the median line of the dome of the brain-case, its lower wall being formed by the upper border of the falx cerebri. It terminates in the torcular Herophili. In shape it is triangular, and it is crossed by numerous chords or trabeculæ (chordæ Willisii). At its commencement it is quite small, but increases gradually in size to its termination. In its course it occasionally deviates from the median line, especially as it passes along the occipital bone. It receives tributaries from the veins of the brain, which enter the sinus in a forward direction or opposite to the flow of blood along the sinus. Occasionally a few of these veins which enter the sinus at its anterior portion do so in the direction of the blood-current. The tributary from the external surface of the parietal bones which communicates with the veins of the scalp passes through the parietal foramen to empty into the sinus. It is small in calibre, and inconstant in existence on one or both sides.

The Inferior Longitudinal Sinus is shorter and much smaller than the superior. It is nearly cylindrical in form, and is often called the inferior longitudinal vein. It commences at the anterior portion of the free or inferior extremity of the falx cerebri, passes backward along its inferior border to the tentorium cerebelli, and terminates in the straight sinus. As it passes backward it receives several branches from the falx.

The Straight Sinus (sinus tentorii) commences at the termination of the inferior longitudinal sinus, which is situated at the anterior junction of the falx cerebri and the tentorium cerebelli. It passes backward and slightly downward in a straight line along the union of the falx cerebri and tentorium cerebelli, increasing in size as it extends, and terminates in the confluence of the sinuses. Its transverse section is triangular, a few crossing cords being found in it. Besides the inferior longitudinal sinus, its tributaries are the venæ Galeni magnæ, the inferior median cerebri, the superior cerebellar, and small branches from the tentorium cerebelli.

The Posterior Occipital Sinus is small and single, though occasionally it is represented by two sinuses. It commences by branches situated around the posterior border of the foramen magnum which communicate with the posterior spinal plexus; it passes backward along the inferior border of the falx cerebelli, and terminates in the confluence of the sinuses. It receives small branches from the cerebellum.

The Lateral Sinuses in either side are large, though seldom of equal size. This difference in calibre is caused to a certain extent by the deflection of the straight sinus to one side or the other of the torcular Herophili, and by its emptying into one or the other sinus. They begin at the confluence of the sinuses, pass outward, forward, and downward along the semicircular grooves to which the tentorium is attached, and extend from the internal occipital protuberance outward over the inferior posterior angle of the parietal bone, thence along the sigmoid groove of the mastoid process of the temporal bone, over the jugular process of the occipital bone, and terminate in the bulb of the internal jugular veins situated within the rounded or enlarged portion of the posterior lacerated (jugular) foramen. The tributaries of these sinuses are veins from the posterior part of the cerebrum, from the cerebellum, diploë, superior petrosal sinus, and emissary veins passing through the posterior condyloid and mastoid foramina, which are communicating veins between the sinuses and the veins of the external portion of the cranium.

The Infero-anterior Group is composed of seven sinuses:

Cavernous,	Superior petrosal,
Spheno-parietal,	Transverse,
Circular,	Anterior occipital.
Inferior petrosal,	

The Cavernous Sinuses (Fig. 114), two in number, receive their name from the fact of their being crossed or interlaced by numerous filaments of connective tissue, which give them the appearance of cavernous tissue. They are situated one on each lateral surface on the body of the sphenoid bone, and extend from the inner portion of the anterior lacerated foramina backward to the apex of the petrous portion of the temporal bones. They vary in width and shape, being narrow and pointed in front and wide behind.

Their tributaries are, anteriorly, the terminations of the ophthalmic veins. On their proximal surface they communicate with each other through the circular sinus. A communicating branch from the pterygoid plexus of either side empties by passing through the oval foramina in both wings of the sphenoid bone. They also receive branches from the cerebral veins, and communicating branches from the spheno-parietal sinuses. Posteriorly they terminate by emptying into the superior and inferior petrosal sinuses. The third, fourth, and the ophthalmic division of the fifth nerve on either side pass forward along the outer walls to make their exit through the anterior lacerated foramina. The internal carotid arteries, the sixth nerves, and the parotid sympathetic plexuses pass forward to the inner margins of the floors of the sinuses, the arteries and nerves passing through these cavernous sinuses; these nerves and vessels are separated from the blood of the sinuses by their thin lining membrane.

The Spheno-parietal Sinuses (two in number) are situated on the under surfaces of the lesser wings of the sphenoid bone. They receive communicating branches from the middle meningeal, anterior temporal, and diploic veins, and occasionally a small vein, the ophthalmo-meningeal. They terminate by emptying into the cavernous sinuses.

The Circular Sinus is situated around the pituitary body within the sella turcica. Its lateral portions communicate with the right and left cavernous sinuses, while its anterior and posterior portions have received the name of anterior and posterior intercavernous sinuses. They are not constant in their existence, one or both being sometimes absent.

FIG. 114.

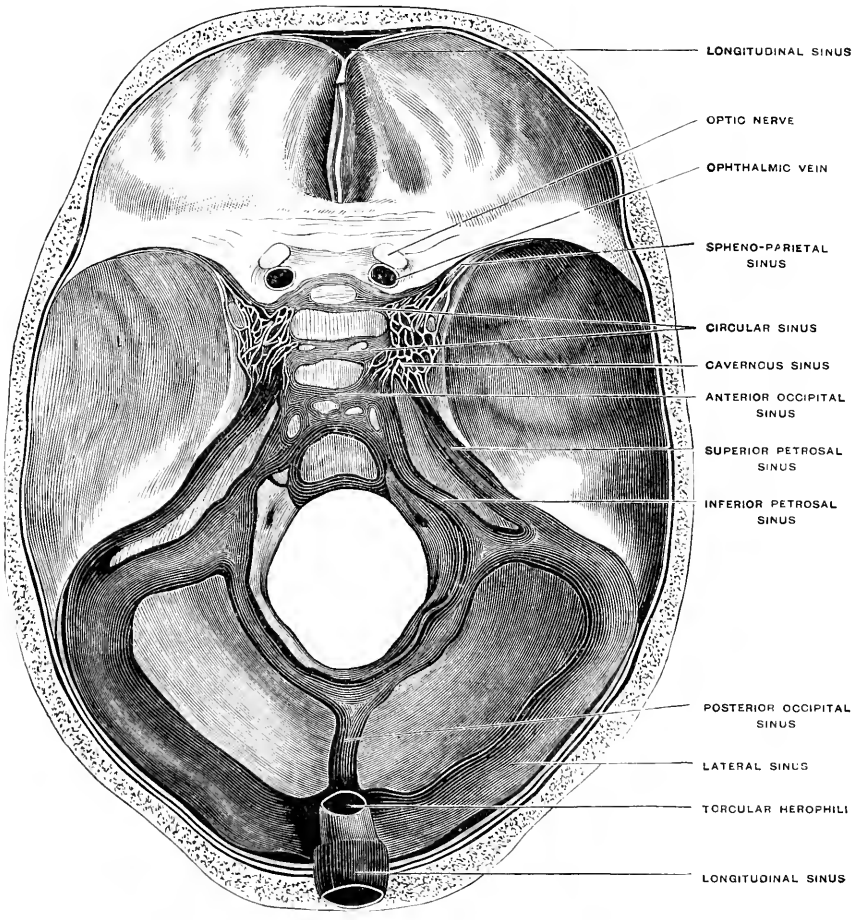

The Sinuses of the Dura Mater, seen in horizontal section of the skull.

Occasionally there is a third communicating sinus in this situation. When this is the case it passes under the pituitary body.

The Superior Petrosal Sinus is a small canal which commences at the posterior and lateral portion of the cavernous sinus, passes outward and backward along a groove situated on the ridge between the anterior and posterior surfaces of the petrous portion of the temporal bone, and within the attached margin of the tentorium cerebelli, and terminates by emptying into the lateral sinus as this large canal passes downward in the sigmoid groove between the mastoid and petrous portions of the

temporal bone. It receives tributaries from the cerebrum, cerebellum, and tympanum, the last-named vessels passing through the petro-squamous fissure.

The Inferior Petrosal Sinus is much shorter and wider than the superior. It commences at the posterior extremity of the cavernous sinus, passes downward and outward along a groove over the articulation of the petrous portion of the temporal bone with the basilar process of the occipital bone, extends through the anterior compartment of the posterior lacerated foramen, and terminates by emptying into the anterior portion of the bulb of the internal jugular vein.

The Anterior Occipital or Transverse Sinus (basilar plexus of Virchow) is a communicating canal or plexus of vessels situated between the right and left inferior petrosal sinuses in front of the foramen magnum. It receives branches from the anterior spinal veins.

Veins of the Orbit.

The veins of the orbit are two in number, superior and inferior ophthalmic.

The Superior Ophthalmic Vein is considerably larger than the inferior, and is by far the more important of the two. It commences by the confluence of the frontal vein and a large communicating branch from the angular vein, a tributary of the facial. It extends backward through the orbit, in company with the ophthalmic artery, to a point near the optic foramen, where it turns a little outward to enter the proximal extremity of the anterior lacerated foramen. Here it passes into the brain-case, and terminates by emptying into the cavernous sinus.

Its tributaries are the veins which return the blood from the region supplied by the ophthalmic artery as from the nasal chamber, the anterior and posterior ethmoidal cells, the muscles of the eyeball, the lachrymal gland, the eyeball, etc. These veins receive names corresponding precisely to the arteries of the same region, and anastomose freely with each other.

The Inferior Ophthalmic Vein is an accessory to the superior. It commences at the terminations of the posterior ciliary and inferior muscular veins, passes backward close to the floor of the orbit between the inferior and external recti muscles, and usually leaves the orbit by the spheno-maxillary fissure to terminate in the pterygoid plexus. It occasionally terminates by emptying into the superior ophthalmic vein, or it may pass through the anterior lacerated foramen to terminate independently in the cavernous sinus. It receives tributaries from the facial vein, from the temporal vein through the malar bone, and a communicating branch from the superior ophthalmic vein.

The Diploic Veins (Fig. 115) are those situated in the diploë of the cranial bones. They can be seen to best advantage by stripping off the pericranium, and then with a dental or surgical engine removing the outer plate of bone. They will then be seen in great numbers, running in various and tortuous directions, but with a general inclination downward, and joining larger main branches in their course. They are

simply tubes grooved in the bone, their lining membrane being composed of pavement epithelium, with some elastic tissue between the epithelium and the tubes. As they pass downward and join other tubes they increase in size and their lining tissue becomes more and more

FIG. 115.

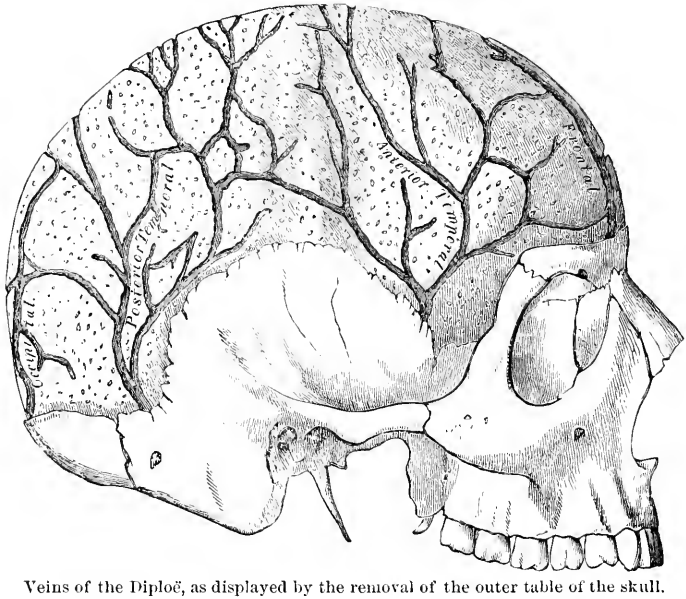

Veins of the Diploë, as displayed by the removal of the outer table of the skull.

defined. There are usually four of these veins on each side of the cranium—one frontal, two temporal, and one occipital.

The Frontal Diploic Vein is small, passes downward, makes its exit through the small foramen in the supraorbital notch, and terminates in the supraorbital vein.

The Anterior Temporal Diploic Vein commences in the frontal bone, passes downward into the great wing of the sphenoid bone, where it divides into two branches, one branch passing through to the outer side of the head and emptying into the anterior deep temporal vein; the other passing through the internal plate and emptying into the spheno-parietal sinus.

The Posterior Temporal Diploic Vein commences by numerous branches in the parietal bone, passes downward, and makes its exit either through an opening in the posterior inferior angle of the bone or through the mastoid foramen, to terminate in the lateral sinus.

The Occipital Diploic Vein is the largest of the four named. It commences within the occipital bone solely, passes downward, and terminates either externally in the occipital vein or internally by emptying into the confluence of the sinuses or into the lateral sinus.

THE EMISSARY VEINS are those which form communicating branches between the veins of the scalp and those at the base of the skull and the various sinuses of the brain-case. They pass through various foramina,

and receive names to correspond with this fact. All the foramina are not constant in their existence, and they vary in size. Named in the order of their size and constancy, they are as follows:

The Mastoid, which empties into the lateral sinus by passing through the mastoid foramen in the temporal bone.

The Parietal, which empties into the longitudinal sinus by passing through the parietal foramen in the parietal bone.

The Condylar, which runs through the cervical plexus, and empties into the lateral sinus by passing through the posterior condyloid foramen in the occipital bone.

The Occipital, which is quite inconstant, extends from the structures near the external occipital protuberance and empties into the torcular Herophili by passing through a small foramen in this situation.

There are several other small emissary veins which pass through different foramina, such as the ovale, middle lacerated, anterior condyloid, and the carotid canal.

THE NERVOUS SYSTEM.

The Nervous System consists of all that portion of the body engaged in the generation and transmission of nerve-force, through which sensation, volition, and vital influence are conveyed to or from the brain. It is made up of several organs known as *nerve-centres*, *nerves*, and *peripheral end-organs*. These are arranged in two great systems, the *Cerebro-spinal* and the *Sympathetic;* the former is frequently described as the nervous system of animal life, the latter of organic or vegetative life.

The Nerve-centres are found within the gray matter of the cerebro-spinal centres, the ganglia of the roots of the spinal, and some of the cranial nerves, also in the various ganglia of the sympathetic system. They are composed of gray matter, white fibrous structure, and intercellular substance known as neuroglia. Within the gray matter are found numerous nerve- or ganglion-cells (Figs. 116, 117, 118). These cells are apolar, unipolar, bipolar, or multipolar in form; some investigators claim those of the apolar variety to be undeveloped nerve-cells which eventually become polar.

The function of the nerve-cells is to generate nerve-force in a manner analogous to that of a galvanic cell or battery in the generation of electricity.

The Nerves are white fibrous cords of various sizes extending between nerve-centres and between nerve-centres and peripheral end-organs. They do not generate nerve-force, but act as conductors, similarly to the wires of a galvanic cell or battery in the transmission of electricity.

The nerves of the cerebro-spinal system are divided into three classes: (1) those which conduct nerve-force from the nerve-centres outward to the muscles, known as motor or centro-peripheral or centrifugal nerves;

(2) those conveying the impression received at the peripheral end-organs to the nerve-centres, known as the sensory nerves and nerves of special sense, or periphero-central or centripetal nerves; (3) those which unite one nerve-centre to another, as the wires passing from one cell to another in the same battery; these are known as intercentral nerves.

The Nerve-fibres are of two kinds, medullated and non-medullated.

The medullated or *dark-border fibres* are those which are found in the cerebro-spinal nerves, with the exception of the olfactory. They vary

FIG. 116.

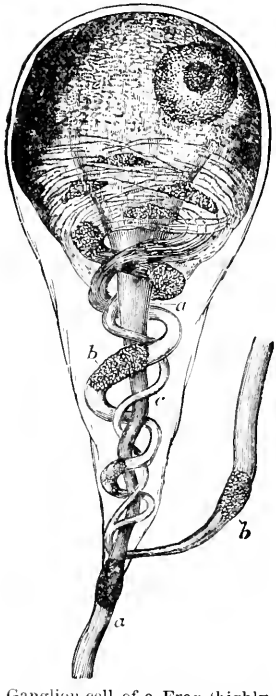

Ganglion-cell of a Frog (highly magnified): *a*, *a*, straight fibre; *b*, *b*, coiled fibre; *c*, smaller one joining it.

FIG. 117.

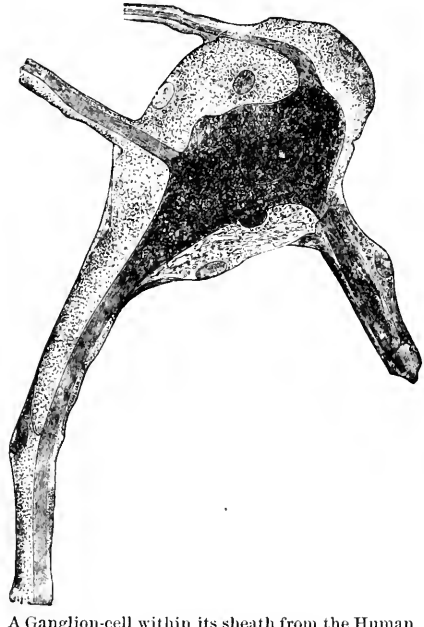

A Ganglion-cell within its sheath from the Human Sympathethic (highly magnified).

in size from $\frac{1}{2000}$th to $\frac{1}{12000}$th inch, and are not always of equal size in the same bundle. In fresh condition the fibre may be described as a bright, glistening cylinder having a dark double contour, but after death the outline of the fibre changes and is irregular, the result of decomposition. The action of water, reagents, or mechanical disturbance produces the same appearance.

By viewing, with a moderate power, a cross-section of a nerve-fibre, it is seen to be made up of a varying number of bundles or fasciculi of fibres (nerve-fibres Fig. 119). The number of fibres in each fasciculus, and of fasciculi in the nerve, increases or diminishes the size of the trunk. These fibres and bundles usually run parallel to each other in the same nerve, except at points where the nerve divides or bifurcates. The whole is surrounded by connective tissue known as

FIG. 118.

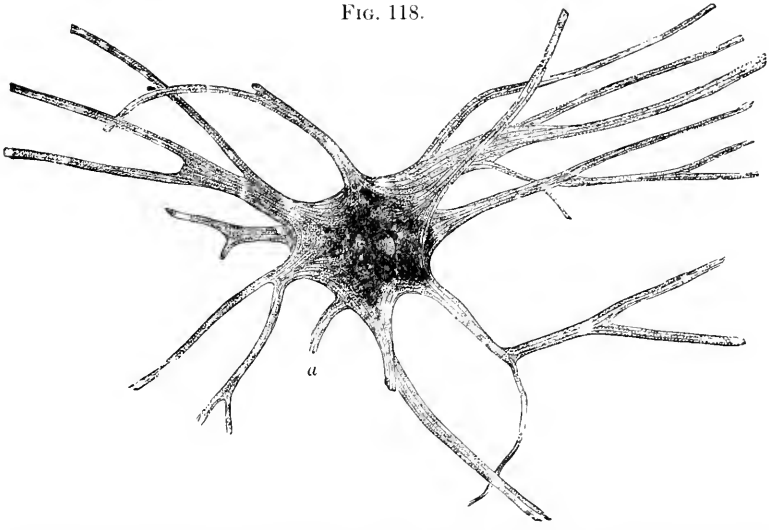

Nerve-cell from Spinal Cord of Ox, isolated after maceration in very dilute chromic acid (magnified 175 diameters). The cell has a well-defined, clear, round nucleus and a bright nucleolus. The cell-processes are seen to be finely fibrillated, the fibrils passing from one process into another through the body of the cell. *a*, axis-cylinder process, broken a short distance from the cell.

FIG. 119.

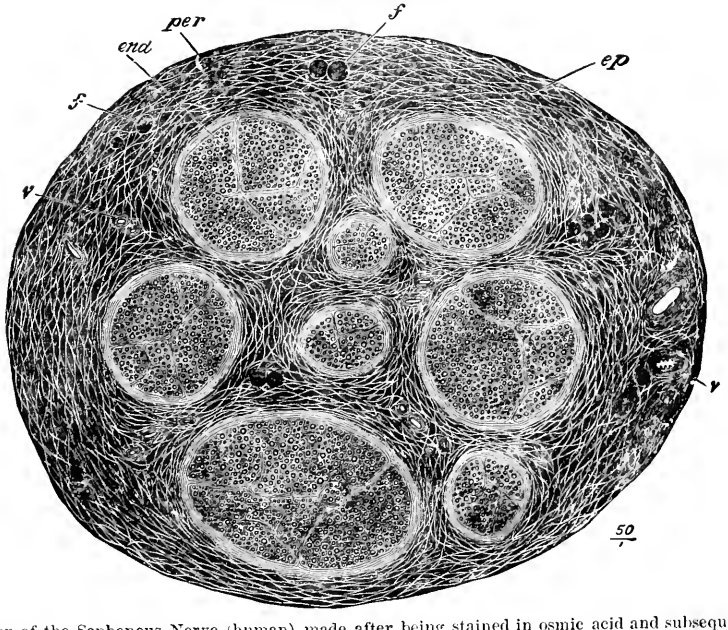

Section of the Saphenous Nerve (human), made after being stained in osmic acid and subsequently hardened in alcohol (drawn as seen under a very low magnifying power): *ep*, epineurium, or general sheath of the nerve, consisting of connective-tissue bundles of variable size separated by cleft-like areolæ, which appear as a network of clear lines, with here and there fat-cells and blood-vessels; *f*, *f*, funiculi enclosed in their lamellated connective-tissue sheaths (perineurium, *p*); *end*, interior of funiculus, showing the cut ends of the medullated nerve-fibres, which are imbedded in the connective tissue within the funiculus (endoneurium). The fat-cells and the nerve-fibres are darkly stained by the osmic acid, but the connective tissue of the nerve is only slightly stained.

the common sheath or *epineurium*. Immediately beneath this sheath are irregular lymph-spaces communicating with each other. A fibrous layer, the *perineurium*, surrounds and forms a sheath for the different bundles, giving room for the passage of blood-vessels supplying the nerves. This layer is similar to the sheath of a muscle which forms a covering to the bundles of muscular fibres. Within each bundle can be seen the nerve-fibres, consisting of axis-cylinder, medullary sheath, and neurilemma or sheath of Schwann, enveloped by a delicate tissue, the *endoneurium*.

The Axis-cylinder (axial-band, axial-fibres) is the essential portion of the nerve-fibre; it is nearly uniform in diameter, and undergoes no interruption from the nerve-centre to near its peripheral distribution. It is either cylindrical or flattened in shape, and passes nearly in the central axis of the tube. When in a fresh condition it appears pale and transparent, and when examined with a microscope, using a high power, it is demonstrated to be composed of very fine homogeneous or more or less beaded fibrillæ.

These elementary or *primitive fibrillæ of Max Schultz* are held together by a faintly granular albuminous cement or interstitial substance. At the termination of the axis-cylinder it is observed to divide up into numerous fine filaments or fibrils. Some investigators claim that the axis-cylinder has an independent or elastic sheath composed of *neuro-keratin*.

The Medullary Sheath (white substance of Schwann) (Figs. 120 and 121) is composed of a glistening fatty substance enveloping the axis-cylinder, and produces the double or dark contour associated with the nerve-fibres. Situated between the axis-cylinder and this sheath is a fine lymph-space containing a small quantity of albuminous fluid. This space is supposed to communicate with the lymph-space which exists between the sheath and neurilemma (Fig. 122) through the bevelled edges of the sections of the sheath. Histologists hold a diversity of opinion regarding the minute anatomy of the medullary sheath. It was formerly considered to be a *continuous* insulated tube, but is now claimed by many to be made up of short segments, each fitting into the other by imbricated ends (incisions of Schmidt) (Fig. 123). It is also divided into the internodal segments or constrictions of Ranvier. The sheath is not uniform in thickness, which is the chief cause of the uneven diameter of a medullated nerve-fibre. At certain points in each *internodal segment* of Ranvier (hereafter described), upon the outer surface of the sheath, are indentations or depressions for the lodgment of *nerve-corpuscles*.

Fig. 120.

Diagram of Structure of Nerve-fibre.

Fig. 121.

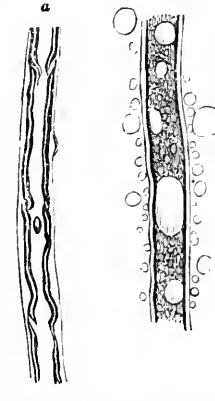

Nerve-substance (magnified 200 diameters): *a*, Nerve-tube of the common eel in water: the delicate line on its exterior indicates the tubular membrane; the dark inner one is the white substance of Schwann, slightly wrinkled; *b*, the same in ether. Several oil-globules have coalesced in the interior, and others have accumulated around the exterior of the tube. The white substance has in part disappeared.

FIG. 122.

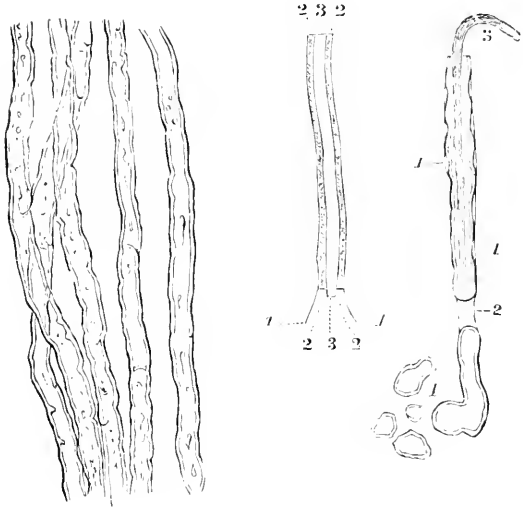

A, tubular nerve-fibres, showing the sinuous outline and double contours; *B*, diagram to show the parts of a tubular fibre—viz. 1, 1, membranous tube; 2, 2, white substance or medullary sheath; 3, axis or primitive band; *C*, figure (imaginary) intended to represent the appearances occasionally seen in the tubular fibres: 1, 1, membrane of the tube seen at parts where the white substance has separated from it; 2, a part where the white substance is interrupted; 3, axis projecting beyond the broken end of the tube; 4, part of the contents of the tube escaped.

FIG. 123.

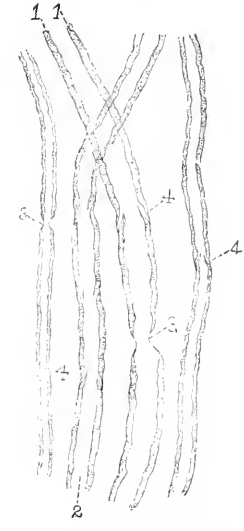

Nerve-fibres, fixed and stained by perosmic acid, from the posterior wall of dorsal lymph-sac of frog: 1, 1, medullary layer; 2, axis-cylinder; 3, 3, constrictions of Ranvier; 4, 4, incisions of Schmidt.

The Neurilemma or Sheath of Schwann is the outer covering of a nerve-fibre, and forms a continuous envelope; a narrow lymph-space extends between it and the medullary sheath. It is the analogue of the sarcolemma in a muscular fibre, and appears as a fine hyaline, homogeneous, elastic membrane, with flattened or oval-shaped nucleated corpuscles, known as nerve-corpuscles, situated between it and the medullary sheath. The nucleus is generally seen in a depression of the medullary membrane surrounded by a zone of granular protoplasm; this is especially the case in young subjects. The optic and auditory nerves have no neurilemma.

The Nodes and Internodes of Ranvier (Fig. 124) are caused by the annular constriction or breaks in the continuity of the medullary sheath or white substance of Schwann. The axis-cylinder, the neurilemma, and the lymph-spaces are not interrupted at these points, though the neurilemma curves sharply inward and comes in close apposition to the axis-cylinder. The point at which the constriction takes place is named the *node of Ranvier*, and the portions between, the *internodes of Ranvier* or interannular segments. Each internode or segment has usually one or more nerve-corpuscles situated between the medullary sheath and the neurilemma.

A fresh nerve treated with a solution of nitrate of silver or osmic acid and exposed to the light demonstrates distinctly the nodes of Ranvier (Fig. 125). After long exposure the silver salt penetrates

Fig. 124.

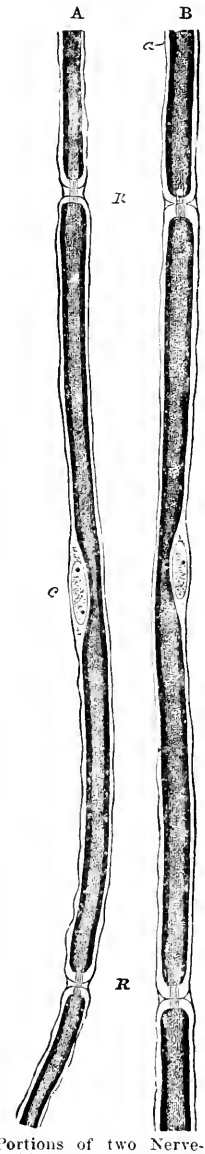

Portions of two Nerve-Fibres stained with Osmic Acid, from a Young Rabbit (425 diameters): *R, R*, nodes of Ranvier, with axis-cylinder passing through; *a*, primitive sheath of the nerve; *c*, opposite the middle of the segment, indicates the nucleus and protoplasm lying between the primitive sheath and the medullary sheath. In A the nodes are wider, and the intersegmental substance more apparent than in B.

the structure of the nodes and passes along the axis-cylinder, disclosing transverse markings named *lines of Frommann*. The action of osmic acid will cause the nodes to become almost colorless, while the medullary or white substance, except close to the nodes, will be stained a very dark color.

The Size of the Nerve-fibres varies, both in the thickness of the medullated sheath and the diameter of the axis-cylinder. This is dependent upon the distance which it extends from the centre of its origination: the greater the distance covered, the thicker will be the medullated sheath, though to this there are numerous exceptions. As the fibre approaches its termination the medullary sheath becomes gradually thinner, diminishing until lost altogether, leaving only the covering of the neurilemma with the nerve-corpuscles between the axis-cylinder and the membrane, thus producing *a non-medullated nerve-fibre*.

The Non-medullated or Pale Fibres (*fibres of Remak*) (Fig. 126) are made up of axis-cylinder, neurilemma, and the nerve-corpuscles, which are situated at certain distances between the other two structures, the axis-cylinder being faintly striated. These fibres are principally found in, and compose the greater part of, the sympathetic nerves, and are the termination of the medullary fibres. The olfactory nerve-filaments are non-medullated, though they cannot be classed as pale fibres, as they have a distinct nucleated sheath of their own. These fibres (pale fibres) differ also from the medullary fibres by branching and joining offshoots from other fibres, thus forming a fine network. Triangular nuclei are found at the nodal points, this being the situation at which these connections occur.

Fig. 125.

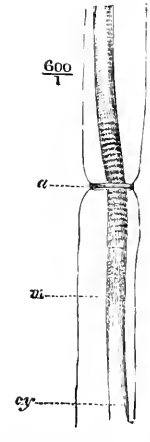

Nerve-fibre from the Sciatic Nerve of the Rabbit, after the action of nitrate of silver: *a*, ring formed by thickened membrane of Schwann; *m*, white substance of Schwann rendered transparent by glycerin; *cy*, cylinder-axis, which just above and below the level of the annular constriction presents the striæ of Frommann.

Before the final distribution of the nerve-fibre it loses its neurilemma, leaving nothing but the axis-cylinder.

The Division of Nerves and Nerve-fibres. — As the nerve-trunks extend from the centres toward the periphery, they divide and subdivide; some branches unite with those of

other trunks, thus forming a single bundle arising from two or more sources and possessing two or more functions; or they may break up and unite in various ways, forming plexuses, as the brachial or cervical.

The medullary fibres while in the nerve-cords or in the nerve-centres do not branch or unite with each other; when near their termination it is claimed they occasionally do so, in which case the branches are always at one of the nodes of Ranvier (Fig. 127). The new axis-cylinder thus formed has its own medullary sheath and neurilemma, being a continuation of the covering of the nerve-fibre from which it originates.

As the nerves approach their termination they divide and subdivide into bundles, until they become very minute, and consist of a single bundle of a few fibres encased in a perineurium made of

FIG. 126.

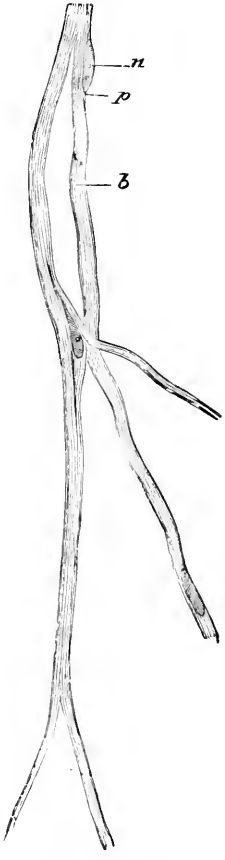

Portion of the Network of Fibres of Remak, from the pneumogastric of the dog: *n*, nucleus; *p*, protoplasm surrounding it; *b*, striation caused by fibrils.

FIG. 127.

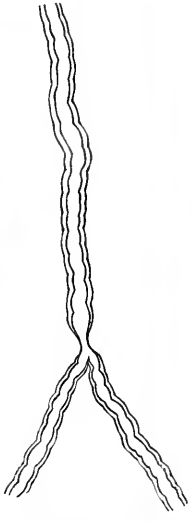

Division of a Nerve-fibre, from pulmonary membrane of frog's lung.

FIG. 128.

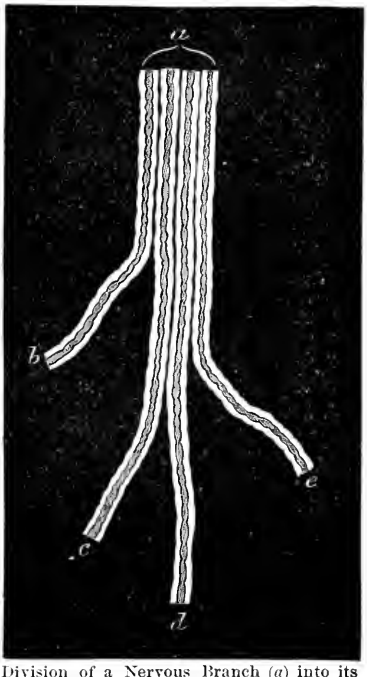

Division of a Nervous Branch (*a*) into its ultimate fibres, *b*, *c*, *d*, *e*.

a delicate film of connective tissue (Fig. 128). Finally, the nerve becomes a single medullated fibre, which soon loses its coat, exposing the axis-cylinder; this ultimately breaks up into primitive nerve-fibrillæ. These become beaded, branching and uniting with each other, and forming a very fine network, the density of which is dependent upon the number of nerve-fibres distributed to the parts; thus, in some portions

FIG. 129.



Plexus of fine Non-medullated Nerve-fibres of the Cornea: *a*, a thick non-medullated nerve-fibre; *b*, a fine one; *c*, *d*, elementary fibrils, anastomosing into a network.

of the body they have a closer woven network than others, as in the cornea, skin, and mucous membrane (Figs. 129 and 130). In the two latter tissues they are extremely abundant, forming two plexuses, a deep and a superficial, the latter being the finer and closer woven.

FIG. 130.

Intra-epithelial Nerve-termination in the Anterior Epithelium of the Cornea, as seen in an oblique section: *a*, an axis-cylinder; *b*, subepithelial nerve-fibrillæ; *c*, intra-epithelial network; *d*, epithelial cells.

If a nerve of sensation be traced from its network of distribution toward its centre, it will be first found composed of primitive fibrils,

which form in themselves small axis-cylinders without any membranes. These unite and form larger axis-cylinders, finally taking on the neurilemma or white sheath of Schwann, then the medullary envelope, the fibres uniting into bundles.

The Peripheral End-organs.

The peripheral end-organs are divided into two classes, those of sensation and those of motion.

The Peripheral End-organs of Sensory or Afferent Nerves.—Many of these nerves terminate in fine plexuses or have free ends (as those already described) under the final termination of the medullary nerve-fibres, which are distributed to the mucous membrane, cornea, and skin. Other terminations are found in various organs of special sense and function: amongst the most important of these are the *Pacinian* and *tactile* corpuscles (see Anatomy of the Skin for description), *the spheroidal end-bulbs of Krause*, hair-bulbs, and nerves ending in gland-cells.

The small *spheroidal end-bulbs* of Krause, resembling to a certain extent the Pacinian corpuscles, are found near the corneal margin of the deeper layers of the conjunctiva (Fig. 131) of man and apes; in other animals they are cylindrical. These have also been found in various parts of the skin and the mucous membrane of the mouth. The spheroidal end-bulbs are composed of polygonal cells and slightly granular substance, surrounded or invested externally by a connective-tissue capsule, which is a continuation of the sheath of Henle of the nerve-fibre, and internally by a nucleated membrane which is a continuation of the primitive nerve-envelope. Usually the axis-cylinder enters the bulb devoid of the medullary sheath, though occasionally it passes into the bulb with this covering. It may enter undivided or in several branches; if the latter, the branches twist and intermingle with each other before entering, making a number of turns, finally dividing into fibrillæ within the bulb; these, after making numerous convolutions, are ultimately lost within the substance.

Fig. 131.

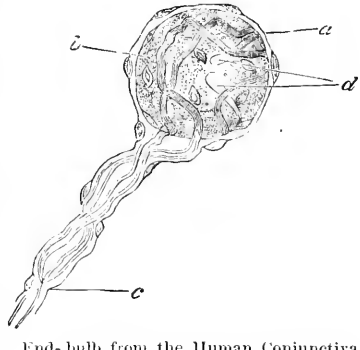

End-bulb from the Human Conjunctiva; *a*, nucleated capsule; *b*, core—the outlines of its cells are not seen; *c*, entering fibre, branching, and its two divisions passing to terminate in the core at *d*.

The Hair-bulbs contain terminations of fibres of the medullary nerves, giving extreme sensitivity in cases where the hair is used as a sentinel, as in the eyelashes and the whiskers of cats, dogs, and other animals.

Nerve-endings in the Gland-cells.

As by mental influences some glands can be excited to secretion, nerve-fibres must be directly connected with them. Plüger claims

Fig. 132.

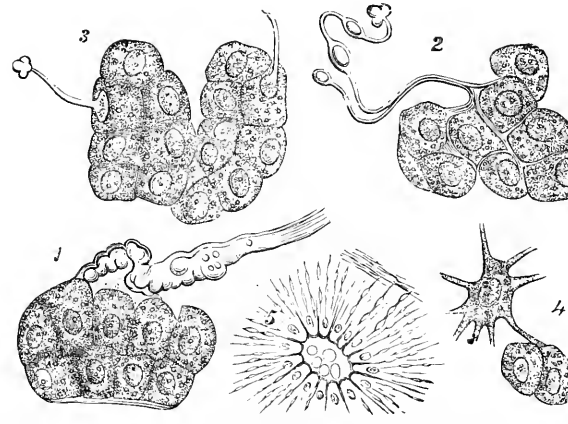

Modes of Termination of the Nerves in the Salivary Glands: 1 and 2, branching of the nerves between the salivary cells; 3, termination of the nerve in the nucleus; 4, union of a ganglion-cell with a salivary cell; 5, irregularly enlarged nerve-fibres entering the cylindrical cells of the excretory ducts.

that both medullated and non-medullated fibres pass directly into the secreting cells of the salivary glands of man (Fig. 132). Kupffer has described the same connection of nerves in some of the insects.

Fig. 133.

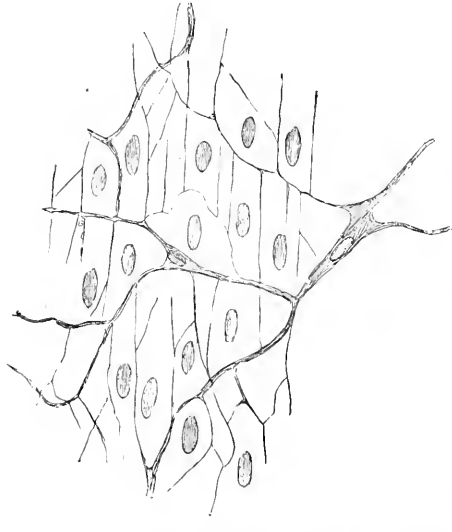

Termination of Nerves in Non-striped Muscular Tissue.

The Peripheral End-organs of Motor Nerves are of two kinds—viz. those supplying involuntary or non-striated muscular tissue, and those supplying voluntary or striated muscular tissue.

The first class, those of the involuntary or non-striated or smooth muscular tissue (Fig. 133), belong to the sympathetic nervous system or non-medullary nerve-fibres. The fibres of these nerves penetrate and divide in the connective tissue which surrounds the bundles and muscular fibres. In this position the axis-cylinder divides into its ultimate fibrillæ, these ending, according to Elischer, in a slight bulbous expansion opposite the nucleus of a contracting cell.

The peripheral end-organs of voluntary or striated muscular tissue belong to the medullary nerve-fibre, and are known as *motorial end-plates* or *end-plates of Kühne* (Fig. 134). As the nerve-trunk advances toward its distribution it divides and subdivides into its fibres, each

of which passes obliquely to a muscular fibre. Each muscular fibre receives one or more nerve-terminals or end-plates. Most authorities claim that at this point the medullary or white substance terminates, and the neurilemma or primitive sheath (sheath of Schwann) becomes continuous with the sarcolemma of the muscular fibre; others state that it (the medullary sheath) terminates immediately after passing through the sarcolemma. Ranvier says that it is the nucleated sheath of Henle, and not the neurilemma, which is continuous with the sarcolemma. After the axis-cylinder passes through the sheath of the muscular fibre, it divides and subdivides into numerous fibrillæ, forming a network

FIG. 134.

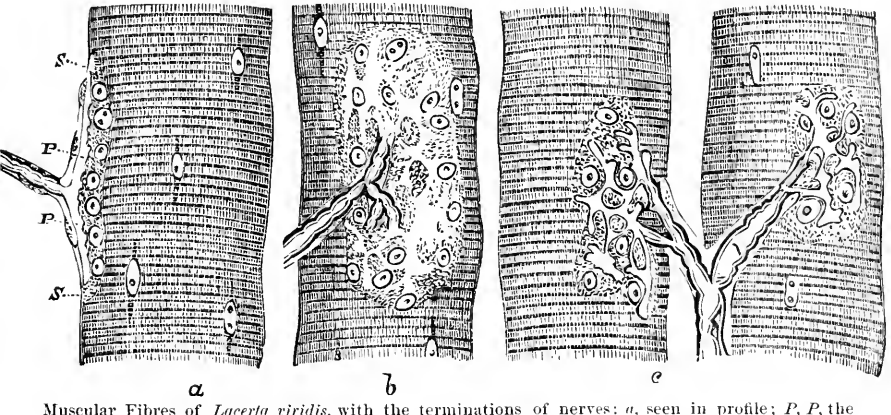

Muscular Fibres of *Lacerta viridis*, with the terminations of nerves: *a*, seen in profile; *P*, *P*, the nerve-end plates; *S*, *S*, the base of the plate, consisting of a granular mass with nuclei; *b*, the same as seen in looking at a perfectly fresh fibre, the nervous ends being probably still excitable (the forms of the variously-divided plate can hardly be represented in a woodcut by sufficiently delicate and pale contours to reproduce correctly what is seen in nature); *c*, the same as seen two hours after death from poisoning by curare.

which is imbedded in a more or less granular pale substance, usually containing a number of oval nuclei having bright nucleoli. The subdivision of the nerve-fibres, the granular substance, and the oval nuclei forms the *end-plates*, which usually have only one fibre terminating in them, though occasionally there are two.

THE CRANIAL NERVES.

The cranial nerves consist of one of the two divisions of the cerebro-spinal system, receiving their name (cranial) from their origin within the cranial cavity, with the exception of the spinal accessory, which originates, in part, outside the brain-case, though this portion passes into the cranium at the foramen magnum, and passes out in company with its accessory portion through the posterior lacerated foramen.

A cranial nerve has two origins, superficial and deep: the first is that portion of the nerve which can be traced to the circumference or periphery of the brain; while the deep origin is in relation with the deeper structure of that organ.

The cranial nerves (Fig. 135) pass out of the brain-case through the foramina in the cranial bones at the base of the skull. Internally they

are all situated near the median line, and as they pass out of the brain-case there is reflected over them a prolongation of the dura mater, which forms an enclosing sheath.

There are twelve pairs of cranial nerves. Anatomists have desig-

FIG. 135.

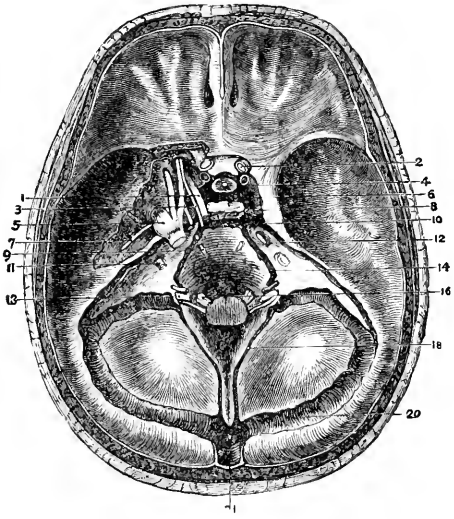

Dissection of the Sinuses of the Skull and Cranial Nerves—the cavernous sinus dissected on the left side; 1, third nerve; 2, optic nerve; 3, fourth nerve; 4, internal carotid artery; 5, Gasserian ganglion of the fifth nerve, with its three divisions; 6, circular sinus; 7, superficial petrosal nerve; 8, cavernous sinus; 9, sixth nerve; 10, transverse or basilar sinus; 11, seventh pair; 12, superficial petrosal sinus; 13, eighth pair; 14, inferior petrosal sinus; 16, ninth nerve; 18, occipital sinus; 20, lateral sinus; 21, torcular Herophili.

nated them by numbers corresponding with their superficial origin, beginning at the anterior pair and passing backward on the under or anterior surface of the brain (Figs. 136 and 137). These nerves are known as motor nerves, sensory nerves, nerves of special sense, and compound nerves. Their names and functions are as follows:

Number.	Name.	Function.
First pair	Olfactory	Special sense, smell.
Second pair	Optic	Special sense, sight.
Third pair	Motor oculi	Motion to five orbital muscles.
Fourth pair	Pathetic	Motion to one orbital muscle.
Fifth pair	Trifacial	Sensation and motion, possibly special sense—taste.
Sixth pair	Abducens	Motion to one orbital muscle.
Seventh pair	Facial	Motion to muscles of face.
Eighth pair	Auditory	Special sense, hearing.
Ninth pair	Glosso-pharyngeal	Sensation, motion, and special sense—taste.
Tenth pair	Pneumogastric	Sensation and motion.
Eleventh pair	Spinal accessory	Motion.
Twelfth pair	Hypoglossal	Motion to muscles of tongue.

Nerves of Motion (or centrifugal nerves) are those which preside over the action of the muscles of the body. They have their origin in the

deeper parts of the brain, extend outwardly, and terminate in the muscular tissue; example, the facial (the nerve of motion to the muscles of the face).

Nerves of Sensation (or centripetal nerves) are those which convey the impression received at their peripheral ends to the substance of the

FIG. 136.

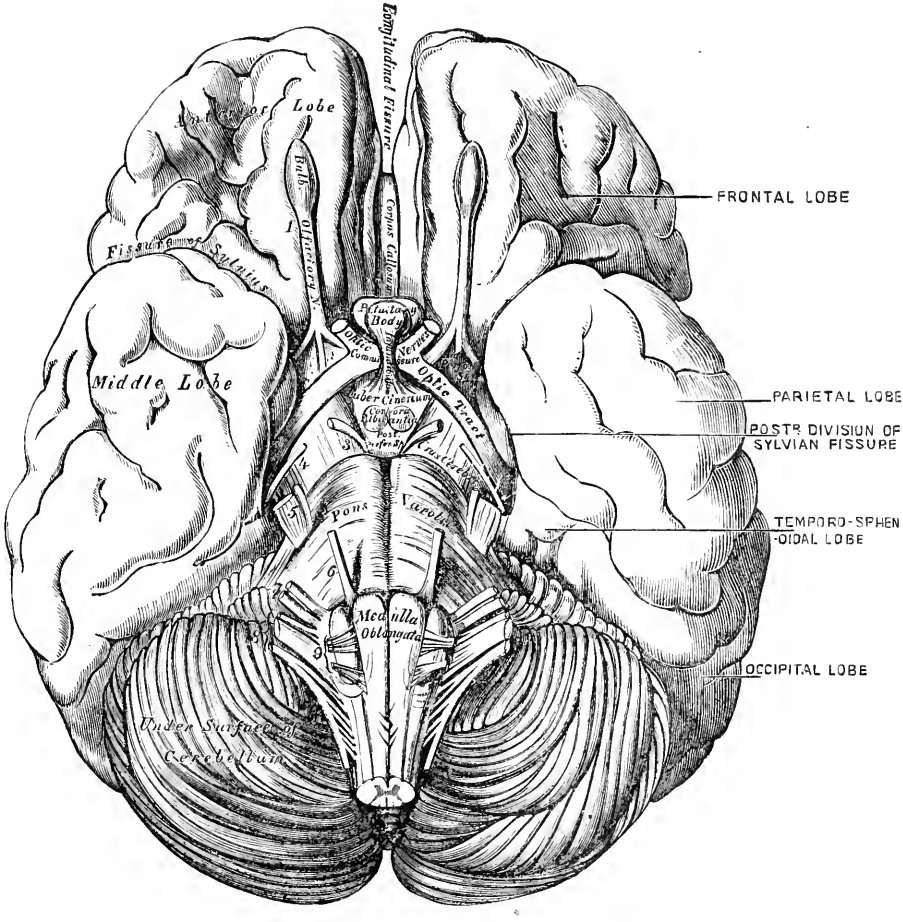

Base of the Brain.

brain. (In the anatomical description of these and other nerves their course is given from the brain outward.) Example, the first two divisions of the fifth pair, which gives sensation to the upper two-thirds of the face.

Nerves of Special Sense (centripetal) are those which convey the impression made upon their peripheral ends, conveying such impression to a particular cell of the brain; example, the optic receiving impressions from the retina and conveying them to certain centres within the brain.

FIG. 137.

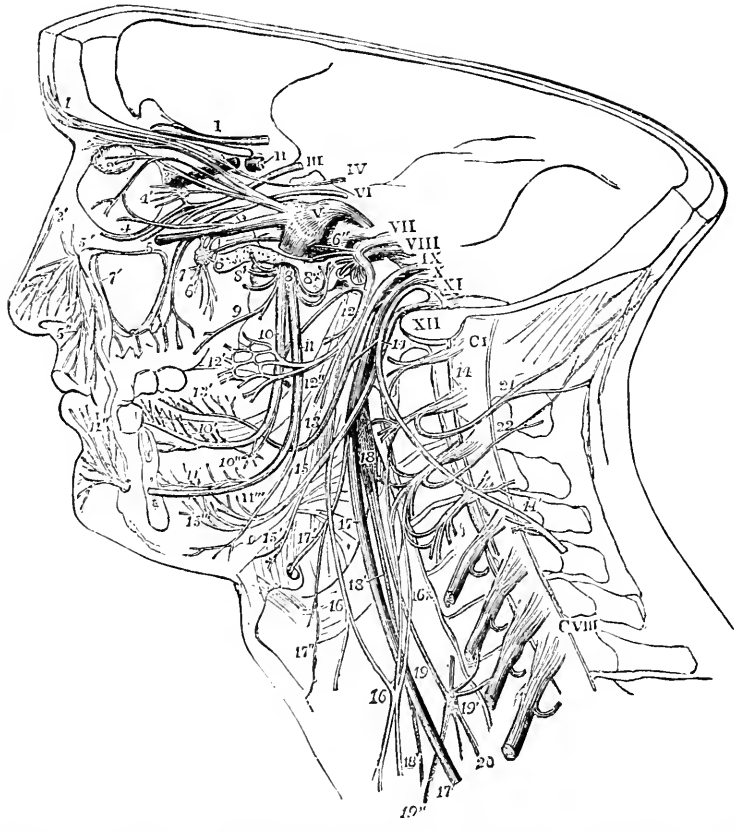

Semi-diagrammatic View of a Deep Dissection of the Cranial Nerves on the Left Side of the Head (Quain). The Roman numerals from I to XII indicate the roots of the several cranial nerves as they lie in or near their foramina of exit. V is upon the large root of the fifth, with the Gasserian ganglion in front; C1, the suboccipital or first cervical nerve; CVIII, the eighth. The branches of the nerves are—1, supraorbital branch of the fifth; 2, lachrymal passing into the gland; 3, nasal, passing toward the anterior internal orbital canal, and giving the long root to the ciliary ganglion, 4′; 3′, termination of the nasal nerve; 4, lower branch of the third nerve; 5, superior maxillary division of the fifth passing into the infraorbital canal; 5′, the same issuing at the infraorbital foramen, and being distributed as inferior palpebral, lateral nasal, and superior labial nerves; 5″, 6, ganglion of Meckel and Vidian nerve passing back from it; 6′, palatine and other nerves descending from it; 6″, large superficial petrosal nerve; 7, posterior dental nerves; 7′, placed in the antrum, which has been opened, points to the anterior dental nerve; 8, inferior maxillary division of the fifth; 8′, muscular branches coming from it; 8x, the auriculotemporal branch cut short, and above it the small superficial petrosal nerve connected with the facial; 9, buccal and external pterygoid; 10, lingual or gustatory; 10′, its distribution to the side and front of the tongue and sublingual gland; 10″, submaxillary ganglion; below 10, the chorda tympani passing forward from the facial to join the lingual; 11, inferior dental nerve; 11′, the same and part of its dental distribution exposed; 11″, its termination as the mental nerve; 11‴, its mylo-hyoid branch; 12, twigs of the facial nerve immediately after its exit from the stylo-mastoid foramen, distributed to the posterior belly of the digastric and stylo-hyoid muscles; 12′, temporo-facial division of the facial; 12″, cervico-facial division; 13, trunk of the glosso-pharyngeal; 13′, its distribution on the side and back part of the tongue; 14, spinal accessory nerve; 14′, the same after having passed through the sterno-mastoid muscle, uniting with branches from the cervical nerves; 15, hypoglossal nerve; 15′, its twig to the thyro-hyoid muscle; 15″, its distribution to the muscles of the tongue; 16, its descending branch, giving a branch to the anterior belly of the omo-hyoid muscle, and receiving communicating branches at 16x from the cervical nerves; 17, pneumogastric nerve; 17′, its superior laryngeal branch; 17″, external laryngeal twig; 18, superior cervical ganglion of the sympathetic nerve, uniting with the upper cervical nerves, and giving at 18′ the superficial cardiac nerve; 19, the trunk of the sympathetic; 19′, the middle cervical ganglion, uniting with some of the cervical nerves, and giving at 19″ the large or middle cardiac nerve; 20, continuation of the sympathetic nerve down the neck; 21, great occipital nerve; 22, third occipital.

Compound Nerves are those composed of motor and sensory filaments, and in some instances combining motion, sensation, and special sense; example, the inferior maxillary or third division of the fifth.

With the exception of the ninth, tenth, and eleventh pairs, the cranial nerves are distributed to the head alone; those excepted have also a distribution to the neck, the tenth pair passing to the thorax and abdomen.

The regions supplied by the cranial nerves are diagrammatically represented in Fig. 138, from which it will be seen that nine of the fourteen regions upon the head and neck are supplied with sensation by some of the branches of the fifth pair of nerves.

FIG. 138.

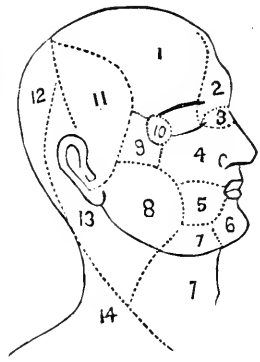

The Nervous Distribution of the Head (Ranney): 1, region supplied by the supraorbital branch of the fifth nerve; 2, supplied by the supratrochlear branch of the fifth nerve; 3, supplied by the infratrochlear branch of the fifth nerve; 4, supplied by the infraorbital branch of the fifth nerve; 5, supplied by the buccal branch of the fifth nerve; 6, supplied by the mental branch of the fifth nerve; 7, supplied by the superficial cervical from the cervical plexus; 8, supplied by the great auricular from the cervical plexus; 9, supplied by the temporomalar branch of the fifth nerve; 10, supplied by the lachrymal branch of the fifth nerve; 11, supplied by the auriculo-temporal branch of the fifth nerve; 12, supplied by the great occipital (a spinal nerve); 13, supplied by the small occipital from the cervical plexus; 14, supplied by the supraclavicular from the cervical plexus.

Olfactory Nerves.

The olfactory or first pair of nerves (Fig. 139) are those concerned in the special sense of smell. They are about twenty in number, and derive their superficial origin from the under surface of the olfactory bulb of the brain, which is situated on the under, proximal, and forward portion of the anterior lobe of the cerebrum. These bulbs rest upon the olfactory sulcus of the cribriform plate of the ethmoid bone, being separated from each other by the crista galli. The nerves pass downward through the numerous foramina in the cribriform plate into the superior nasal chamber. They are invested by a covering derived from the membranes of the brain, and are distributed to the mucous lining of the superior meatus of the nose. The nerves are divided into three sets—inner, outer, and middle. The inner set is composed of the largest nerves: they are situated next to the median line, and pass into delicate grooves or canals which descend on either side of the perpendicular plate of the ethmoid bone. Some of these canals run obliquely forward, and others obliquely backward. Those that arise from the lateral portions of the olfactory lobes pass into fine canals, which subdivide as they penetrate the lateral masses of the ethmoid. A few of the more central of these nerves are distributed to the roof of the nasal chamber. No filaments extend to the vomer or inferior turbinated bones. The olfactory nerves differ from all other cranial nerves in being composed of non-medullated fibres. Their terminal branches communicate freely with each other and form a plexus beneath the nasal mucous membrane.

Fig. 139.

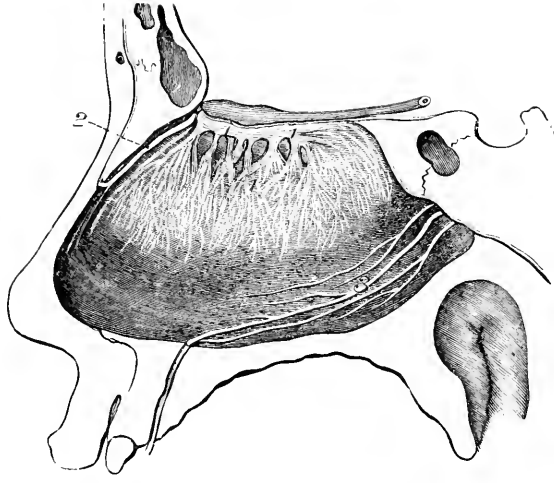

Nerves of the Septum of the Nose: 1, olfactory bulb and its ramifications in the septum; 2, nasal nerve of the ophthalmic trunk; 3, naso-palatine nerve from Meckel's ganglion (too large in the cut).

Optic Nerve.

The optic or second pair of nerves (Fig. 140) are the special nerves of vision. Their encranial portion—viz. that which extends from the superficial origin to where they pass out of the brain-case—is divided into three parts, the optic tract, the optic chiasm, and the optic nerve.

The Optic Tract is that portion which commences in the posterior part of the optic thalamus, the anterior or superior lobes of the corpora quadrigemina, and the corpora geniculata. The fibres from these different sources unite and form a flattened or ribbon-like band (without being invested by neurilemma), which passes obliquely forward and inward, closely attached to the under surface of the superior portion of the crus cerebri. Here it becomes more cord-like in appearance, and is attached to the tuber cinereum and lamina cinerea. It receives additional fibres from these bodies, passes forward, and joins the optic chiasm at its posterior lateral angle.

The Optic Chiasm or Commissure is an oblong body, nearly half an inch in diameter, formed by the union of the optic tracts. It is lodged in the optic groove, which is situated upon the olivary process on the superior surface of the sphenoid bone. Its extremities are in close apposition to the internal carotid artery of both sides. The fibres of each optic tract are divided into three sets—decussating, straight, and intrageniculate.

The decussating set is composed of the greater number of the fibres of each optic tract. These fibres cross from one side to the other through the chiasm, and thus the greater part of the optic nerve of the left side is formed by fibres from the optic tract of the right side.

The straight set form the outer part of the optic tract. They pass forward, and help to form the optic nerve of the same side.

The intergeniculate set (inferior commissure of Gudden) form the inner part of the optic tract. They cross from one side to the other, forming the posterior margin of the chiasm, and unite the fibres which spring from the geniculate bodies. Many anatomists describe a set of fibres which pass from one side to the other across the anterior margin of the chiasm and form an inter-retinal set. The existence of this set of fibres is still a matter of doubt, though Stilling has recently claimed to have found them.

The optic nerve is a rounded cord which commences at the anterior lateral angle of the optic chiasm. It extends outward and forward, and

FIG. 140.

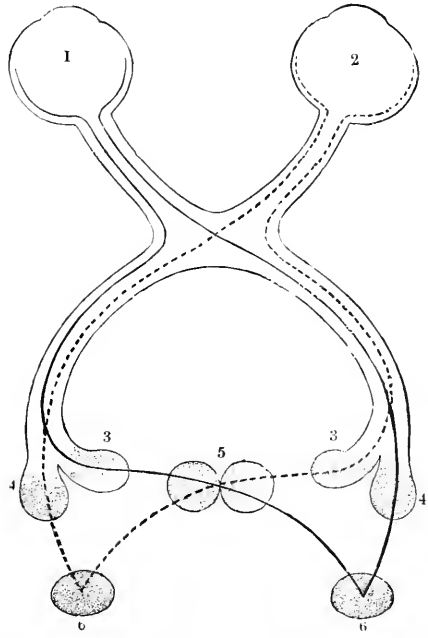

Diagram of the Optic Nerves and Tracts in Man: 1, left eyeball; 2, right eyeball; 3, 3, corpora geniculata interna; 4, 4, corpora geniculata externa; 5, tubercula quadrigemina; 6, 6, centres of vision in the cerebral hemispheres.

passes from the brain-case through the optic foramen in the sphenoid bone, accompanied by the ophthalmic artery, which runs along its outer and lower side. Before entering the optic foramen it is invested by a slender sheath from the arachnoid membrane of the brain, but as it passes into the foramen it is strongly enveloped by a prolongation from the dura mater. Upon reaching the orbit this covering divides into two, the outer blending with the periosteum, while the inner continues to invest the nerve until it pierces the sclerotic coat of the eye. When the nerve enters the orbit it passes outward and downward between the origins of the recti muscles to the posterior aspect of the eyeball, being surrounded by the adipose tissue of the orbit. It enters

the eyeball about one-tenth of an inch to the inner side of its centre, passes through the sclerotic and choroid coats, and terminates by expanding into the retina. Within the orbit it is surrounded by adipose tissue, ciliary vessels, and nerves, the central retinal artery entering the nerve about one-fourth of an inch from where it passes into the sclerotic coat.

Variations.—The optic tracts occasionally pass through the optic foramina without decussation. When this is the case the chiasm is entirely absent.

Oculo-motor Nerve.

The oculo-motor or third nerve (Fig. 142) is a large, round, firm cord which presides over the movements of the eye. It is the most

Fig. 141.

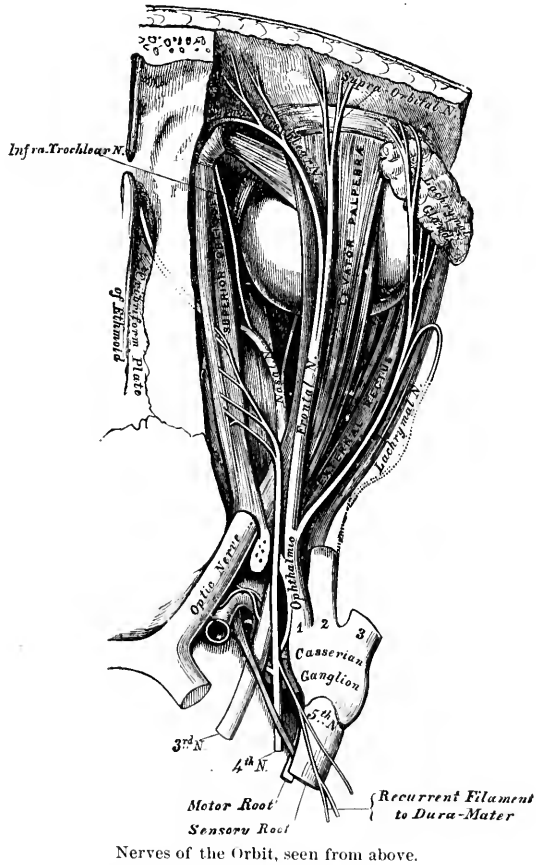

Nerves of the Orbit, seen from above.

anterior motor nerve of the cerebro-spinal axis, and supplies all the muscles of the orbit, including the sphincter muscles of the iris and the ciliary muscle of the eyeball, with the exception of the superior oblique

and the external rectus. It arises superficially from the walls of the interpeduncular space on the median surface of the crus cerebri, just above the pons varolii. It extends forward and slightly outward to the side of the posterior clinoid process, soon after passing which it enters the superior lateral portion of the cavernous sinus, being invested by a sheath from the dura mater. It runs through this portion of the sinus, passes below the anterior clinoid process, and on to the proximal extremity of the anterior lacerated foramen. Here it enters the orbit by passing between the two heads of the external rectus muscle. As it extends through the anterior lacerated foramen it divides into two branches, superior and inferior.

The Superior Division of the Oculo-motor Nerve is the smaller of the two. It passes inward over the optic nerve, and again divides into two sets of branches, one being distributed to the superior rectus muscle, while the other supplies the levator palpebræ superioris.

The Inferior Division of the Oculo-motor Nerve is the larger of the two. It divides into three branches—the internal rectus, inferior rectus, and inferior oblique.

The Internal Rectus Nerve passes beneath the optic nerve and supplies the internal rectus muscle.

The Inferior Rectus Nerve supplies the inferior rectus muscle.

The Inferior Oblique Nerve is the longest of the three branches. It passes forward between the inferior and external recti muscles to the inferior and anterior portion of the orbit, and is mainly distributed to the inferior oblique muscle. It also sends a few filaments to the inferior rectus, and a short, thick communicating branch to the ophthalmic or lenticular ganglion.

Trochlear Nerve.

The trochlear, fourth, or patheticus nerve (Fig. 141) is the smallest and the most slender of all the cranial nerves, though it has the longest encranial course. It presides over the motion of the superior oblique or trochlear muscle of the eye. It arises superficially from a point just below the corpora quadrigemina and near the valve of Vieussens. From this point it passes outward over the superior peduncle of the cerebellum, then forward, curves around the lateral margin of the crus cerebri, and penetrates the dura mater below the tentorium cerebelli. Near the posterior clinoid process it enters the cavernous sinus, extends along its outer and upper wall, and passes through the proximal portion of the anterior lacerated foramen into the orbit. It then passes forward and inward over the superior rectus and levator palpebræ superioris muscles, and is distributed to the upper surface of the superior oblique.

Branches.—Recurrent branches of this nerve are given off as it passes through the tentorium cerebelli. They are distributed to the tentorium, some of them extending backward to the lateral sinuses. In the cavernous sinus it gives off branches which communicate with the carotid plexus of the sympathetic nerve, and occasionally with the ophthalmic division of the fifth nerve. It sometimes sends a branch which anasto-

Fig. 142.

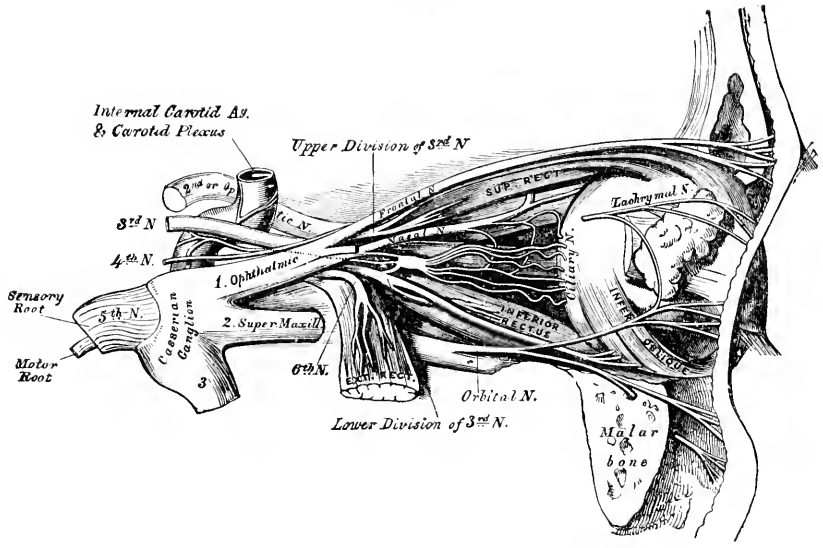

Nerves of the Orbit and Ophthalmic Ganglion, side view.

moses with the lachrymal nerve. The trochlear nerve is supplied by a small branch from the anterior cerebral artery.

Abducent Nerve.

As the abducent, sixth, or external oculo-motor nerve is distributed to a muscle of the orbit, it is here described with those that are associated with it. This nerve presides over the motion of the external rectus muscle, and arises superficially between the anterior pyramids of the medulla oblongata and the pons varolii. Generally, a few bundles of its fibres spring from the lower margin of the pons. At first it is flat, but as it extends it soon becomes rounded. It passes forward, and penetrates the dura mater at the side of the dorsum sellæ of the sphenoid bone. It enters the cavernous sinus, and passes along its outer and inner portion, covered by a thin membrane. It enters the orbit through the anterior lacerated foramen, between the two heads of the external rectus muscle, and is distributed to this muscle, entering its proximal or orbital surface.

Branches.—In the cavernous sinus it sends communicating filaments to the carotid sympathetic plexus. On passing into the orbits it gives off a branch which extends between it and the ophthalmic nerve. This nerve is occasionally entirely absent. When this is the case the external rectus muscle is supplied by a branch from the third nerve.

Trifacial Nerve.

The trifacial, trigeminus, or fifth nerve is the largest of all the cranial nerves. Through its wide distribution within the face and

over the head, its close relation to other nerves and to the plexuses and ganglia of the sympathetic nerve, it becomes involved in nearly all the diseases of the external portion of the head as well as the superficial and deep parts of the face. "The intimate relations which the nerve bears with the points of origin of the sixth, seventh, eighth, ninth, tenth, eleventh, and twelfth cranial nerves in the floor of the fourth ventricle possibly explain many of those phenomena which are considered as reflex in character, and whose starting-point seems to depend upon some irritation of the fifth nerve by means of various branches" (Ranney). It resembles a spinal nerve, in that it arises by two roots, anterior and posterior. The posterior root is sensory in character, and has a ganglion upon it, while the anterior root has no ganglion and is motor in character.

The large, sensory, or posterior root emerges from a point in close proximity to the centre of the lateral surface of the pons varolii, but nearer its superior than its inferior border (Fig. 136).

FIG. 143.

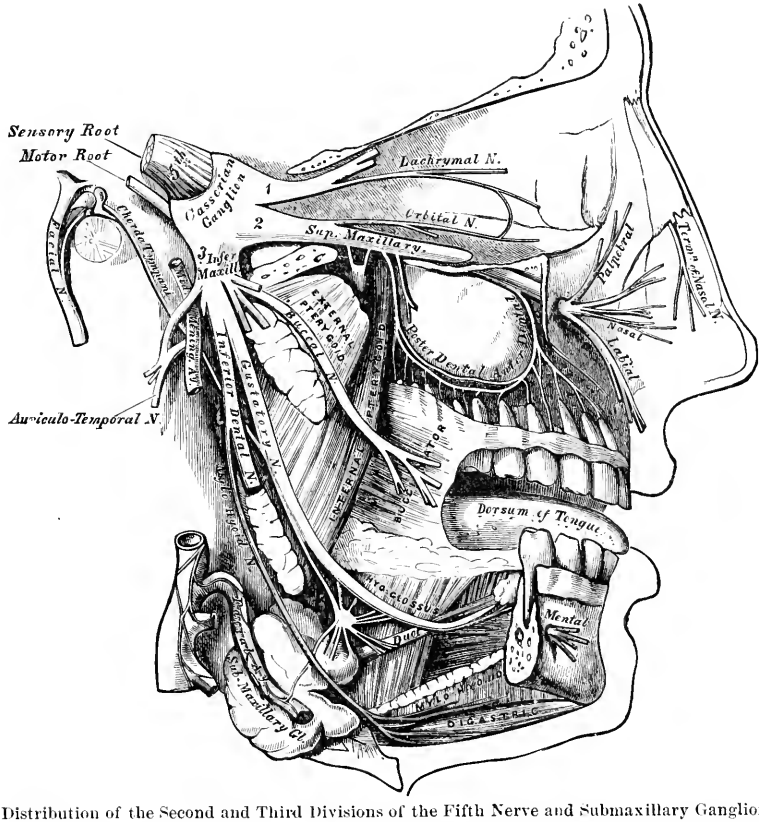

Distribution of the Second and Third Divisions of the Fifth Nerve and Submaxillary Ganglion.

The small, motor, or anterior root is made up of six or eight rounded filaments (Vulpian), and emerges from the pons a little above the larger posterior root, being separated from it by a few transverse fibres of

white substance. It is entirely distinct and separate from the larger sensory root from its deep origin until it passes out of the cranial cavity through the foramen ovale, when it becomes closely united with its third or inferior maxillary division, hereafter to be described.

The deep origin of these two roots is widely separated from their superficial origin. Following them backward from the anterior surface of the pons varolii, they pass directly through the pons to the medulla oblongata, without any connection whatever with its fibres. On reaching the medulla they form three main divisions, one anterior and two posterior.

The Anterior or Motor Division arises from the motor nucleus of the fifth nerve, which is composed of large, ramified, and pigmented cells situated below the lateral angle of the fourth ventricle, anterior to the inferior facial nucleus, and on the proximal side of the large sensory nucleus of the fifth nerve. It also arises from the gray matter at the anterior portion of the *iter* beneath the corpora quadrigemina. As it passes toward the pons it receives fibres which arise from the raphé. The fibres have their origin in the nucleus of the opposite side or in the pyramidal tract.

The Two Posterior or Sensory Divisions give general sensibility to the face and head, extending as far back as its vertex. These divisions are the superior and inferior.

The Superior or Larger Division arises from the superior sensory nucleus of the fifth nerve. This nucleus is situated at the side of the motor nucleus, and is composed of nerve-cells which are less compactly arranged, but in greater numbers than the motor nucleus.

The Inferior or Smaller Division is a well-defined bundle of nerve-fibres which arises from the inferior nucleus of the fifth nerve. This is composed of cells situated in the gelatinous substance which constitutes the tubercle of Rolando.

From their superficial origin these two roots extend obliquely upward and forward across the summit of the petrous portion of the temporal bone, and pass through an oval opening in the dura mater into the middle fossa of the brain-case. The larger posterior sensory root terminates in the ganglion of Gasser,[1] which is situated in a depression on the superior part of the anterior surface near the apex of the petrous portion of the temporal bone. This ganglion is broad, flattened, and somewhat semilunar or crescent-shaped, and from this fact is often called the semilunar ganglion of the fifth nerve. Its convexity is directed forward and slightly upward. The cells of this ganglion are unipolar in shape. Its surfaces are striated, and it receives on its inner side filaments of communication from the carotid plexus of the sympathetic nervous system.

[1] The structure of this ganglion was first recognized by Gasser, professor of anatomy in Vienna. His observations, however, were published by Hirsch, a pupil of Gasser, in 1765 (Hirsch, *Paris Quinti Nervonum encephali*, Viennæ, 1765), in Ludwig (*Scriptores Nervologici minores selecti*, Lipsiæ, 1791, tomus i. pp. 244 *et seq.*). Hirsch first gave it the name of Gasserian ganglion.

Some authors call it Casserian ganglion, probably confounding Gasser with Casserius. Casserius in his anatomical figures describes many parts of the brain and nerves, but says nothing of the ganglion of the fifth (Casserius, *Anatomische Tafeln*, Franckfurt-am-Mayn, 1756). (Flint's *Physiology of the Nervous System*, vol. i. p. 185.)

Flint claims "this anatomical point as of importance in view of some of the remote effects which follow division of the fifth nerve through the ganglion in living animals." A few small branches emanate from the ganglion, and are distributed to the dura mater and the tentorium.

From the anterior or concave margin of this ganglion the three large divisions of the fifth nerve commence. It is from this that the nerve receives the name of trifacial. These divisions again divide and subdivide as they pass forward to their terminations (Fig. 144).

FIG. 144.

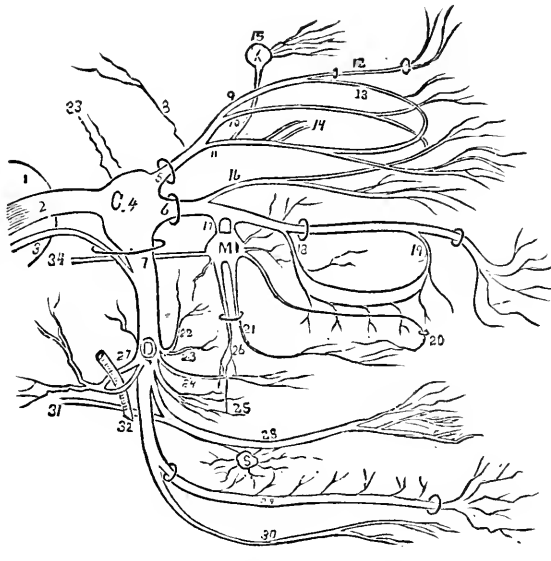

A Diagram of the Distribution of the Fifth Nerve (Ranney): 1, the crus cerebri; 2, the sensory root of the nerve; 3, the motor root of the nerve; 4, the Gasserian ganglion, upon the sensory root only; 5, the ophthalmic nerve passing through the sphenoidal fissure; 6, the superior maxillary nerve passing through the foramen rotundum to enter the spheno-maxillary fossa; 7, the inferior maxillary nerve passing through the foramen ovale in company with the motor root; 8, a filament sent backward from the ophthalmic nerve to the tentorium cerebelli; 9, the frontal nerve; 10, the lachrymal nerve; 11, the nasal nerve; 12, the supraorbital nerve passing through the foramen of the same name; 13, the supratrochlear nerve; 14, the long ciliary nerves to the iris; 15, the lenticular or ciliary ganglion; 16, the temporo-malar nerve, dividing into temporal and malar branches; 17, the spheno-palatine nerve, going to Meckel's ganglion; 18, the posterior dental nerves; 19, the anterior dental nerves, given off in the antrum; 20, the naso-palatine nerve, escaping at the anterior palatine foramen after passing through the antrum; 21, the anterior palatine nerve after escaping from the posterior palatine foramen; 22, the deep temporal nerve; 23, the masseteric branch; 24, the buccal branch, which also often supplies the external pterygoid muscle; 25, the pterygoid branch, going chiefly to the internal pterygoid muscle; 26, the posterior palatine nerves after leaving the posterior palatine foramen, going to the muscles of soft palate; 27, the auriculo-temporal nerve, splitting, and thus embracing the middle meningeal artery; 28, the gustatory or lingual nerve, distributed to the anterior two-thirds of tongue; 29, the inferior dental nerve, passing through the inferior dental canal beneath the teeth of the lower jaw; 30, the mylo-hyoid nerve; 31, the chorda tympani nerve, joining the gustatory nerve, and possibly bringing to it the perception of taste; 32, the middle meningeal artery; 33, the fibres going to the cavernous plexuses of the sympathetic system; 34, the Vidian nerve, going from Meckel's ganglion to the Vidian canal.—Ganglion of the Fifth Nerve: L, the lenticular ganglion, sending fibres to the iris and ciliary muscle; C, the Gasserian ganglion; O, the otic ganglion, lying on the inferior maxillary nerve below the foramen ovale; E, the submaxillary ganglion, connected with the gustatory and chorda tympani nerves; M, Meckel's ganglion, lying in the spheno-maxillary fossa.

"By tracing the various distributions of this nerve it will be seen that it gives motor power to the muscles of mastication—viz. the temporal, masseter, and pterygoids; also the anterior belly of the digastric and mylo-hyoid muscles, and tensor palato" (palato-Eustachian) "and tensor

tympani, thus controlling the act of mastication and to some extent deglutition and hearing. Fibres of the fifth nerve afford general sensation to the entire skin of the head and face, except in the occipital region and the back and lower part of the ear, also to the mucous membranes of the mouth, with the exception of the posterior pillar of the fauces and the posterior third of the tongue, which derive their sensation by means of the glosso-pharyngeal nerves (Ranney).

The Ophthalmic, or first division of the fifth nerve, is the smallest of the three cords, being but about an inch in length. The table on page 287 will show that it is derived wholly from the sensory root. Its function is to impart sensation to the eyeball, the lachrymal gland, the mucous lining of the eye, and a portion of the nose and of the eyebrow and forehead. It commences from the upper, inner, and anterior portion of the margin of the Gasserian ganglion. It is a flattened cord, and passes forward along the outer wall of the cavernous sinus, and terminates before or just as it is about to pass through the anterior lacerated foramen by dividing into three main branches, the frontal, lachrymal, and nasal.

Branches of the Ophthalmic Nerve.—

Those within the cavernous sinus,	Lachrymal,
Frontal,	Nasal.

The ophthalmic nerve gives off two small branches within the cavernous sinus.

The Frontal Nerve is the largest of the branches given off by the ophthalmic, and is in reality its axial continuation. It enters the orbit through the most superior portion of the anterior lacerated foramen, and passes forward in the median line above the muscles and below the periosteum. It terminates midway between the apex and base of the orbital cavity, above the levator palpebræ superioris muscle, by dividing into two branches of unequal size, the supratrochlear and the supraorbital.

The Supratrochlear Nerve is much the smaller of the two terminal branches of the frontal. It extends obliquely inward and forward over the trochlear muscle, passing out of the orbit, and curves around the supraorbital arch between the supraorbital foramen and the trochlear fossa. It then extends beneath the corrugator supercilii and frontalis muscles, and divides into two terminal branches. These branches pierce the orbicularis and frontalis muscles, supplying them as well as the integument; also the lower and median portion of the forehead, interlacing with the corresponding nerve of the opposite side. This nerve also gives off two distributing branches, one extending from the nerve near the trochlear muscle, which passes downward and joins the infratrochlear branch of the nasal nerve, and the other near its exit from the orbit, which passes to the eyelid and bridge of the nose.

The Supraorbital Nerve is really a continuation of the frontal. It passes forward, and emerges from the orbit through the supraorbital notch or foramen. It then curves upward on the forehead, and divides into a median and a lateral branch, which pierce the muscles and become the cutaneous nerves. Its branches of distribution are several small cords which descend to the structures of the upper eyelid, and one

The following table will serve to demonstrate the original trunks of this nerve, with their different branches:

Motor Root.	Ganglion of Gasser (Sensory Root).	
Ophthalmic	Frontal	Supra-trochlear.
		Supra-orbital.
	Lachrymal	Superior branch.
		Inferior branch.
	Nasal	Branch to dura mater.
		Branch to ophthalmic ganglion.
		Long ciliary branch.
		Infratrochlear.
		Internal nasal branch
		External branches.
Superior maxillary	In the pterygo-maxillary fossa	Orbital
		Spheno-palatine nerves (to Meckel's ganglion).
		Posterior superior dental
	In the infraorbital canal	The middle superior dental.
		The anterior superior dental
	On the face or terminal	Palpebral.
		Nasal.
		Labial.
Inferior maxillary	Sensory or posterior root through ganglion of Gasser	Auriculo-temporal.
		Lingual or gustatory.
		Inferior dental
		Buccal.
	Motor branches from anterior root	Deep temporal
		Masseteric.
		Internal pterygoid.
		External pterygoid.
		Mylohyoid.

Internal or septal branch.	
Lateral branch.	
Anterior superficial branch.	
Lachrymal.	
Temporo-malar.	
The superior set.	
The inferior set.	
Ascending.	
Descending.	
Incisor.	
Mental.	
Anterior.	
Posterior.	

which passes outward under the orbicularis palpebrarum, interlacing with the facial nerve. The muscular branches are distributed to the corrugator supercilii, frontalis, and orbicularis palpebrarum. The cutaneous branches are two in number, median and lateral. These extend posteriorly as far as the occiput. The deep or pericranial branches are distributed to the frontal and parietal bones. This nerve also sends a filament which supplies the mucous membrane of the frontal sinus. Occasionally the division of the supraorbital nerve takes place within the orbit, the larger branch passing through the supraorbital foramen, while the smaller branch extends internally around the supraorbital arch or through the frontal notch, which is occasionally present.

The Lachrymal Nerve is the smallest of the three divisions of the ophthalmic. It passes along the outer side of the frontal nerve into the orbit through the anterior lacerated foramen, encased in an individual sheath derived from the dura mater. It passes forward and outward near the periosteum of the orbit above the external rectus to the lachrymal fossa of the frontal bone, accompanied by the lachrymal artery. It then penetrates the external tendo palpebrarum of the eye and terminates in the upper eyelid.

Branches of Distribution.—On approaching the lachrymal fossa the lachrymal nerve sends a communicating cord to the orbital branch of the second or superior maxillary division of the fifth. This branch is sometimes called the inferior division of the lachrymal nerve, and occasionally passes backward through a canal in the outer wall of the orbit, its divisions forming an arch from which branches are distributed to the lachrymal gland and the conjunctiva. Within the lachrymal fossa it sends branches to the lachrymal gland and the conjunctiva.

THE NASAL OR OCULO-NASAL NERVE is intermediate in size between the other two divisions of the ophthalmic nerve. It commences from the under surface of the ophthalmic nerve, and passes through the widest portion of the anterior lacerated foramen into the orbit between the two heads of the external rectus muscle, accompanied by the fourth nerve. On either side of it are the two divisions of the third nerve. From the anterior lacerated foramen it passes obliquely inward and forward over the optic nerve below the superior muscles of the orbit to the anterior ethmoidal foramen on the inner wall of the orbital cavity. It here divides into the internal nasal and infratrochlear nerves.

Branches of the Nasal Nerve.—

Branch to the dura mater,	Long ciliary,
Communicating branches to sympathetic nerve,	Spheno-ethmoidal,
Ganglionic,	Internal nasal,
	Infratrochlear.

The Branch to the Dura Mater is a small filament which turns backward and is distributed to the dura mater of the anterior cerebral fossa.

The Communicating Branches to the Sympathetic are a few distinct filaments which communicate with the sympathetic network about the ophthalmic artery (Allen).

The Ganglionic Branch is quite slender and about half an inch in length. It usually commences from the nasal nerve as it extends between the two heads. It passes along the outer side of the optic

nerve, and terminates at the posterior superior portion of the ophthalmic (lenticular) ganglion, constituting its long or sensory root.

The Long Ciliary Nerves are two or three in number, and commence from the nasal nerve as it extends across the optic nerve. They pass along the inner margin of this nerve, and unite with some of the short ciliary nerves from the ophthalmic ganglion. They then pierce the sclerotic coat of the eye, pass forward between it and the choroid coat, and are distributed to the ciliary muscles, the cornea, and the iris.

The Spheno-ethmoidal (Luschka) *or Posterior Ethmoidal* (Krause) *Nerve* passes from the nasal nerve to the posterior ethmoidal foramen (posterior internal orbital canal), and is distributed to the mucous membrane of the sphenoidal sinus and the posterior ethmoidal cells in front of the body of the sphenoid bone.

The Internal Nasal or Ethmoidal Nerve is in the line of continuation of, and generally described as, the nasal nerve. It passes through the anterior ethmoidal foramen, situated between the frontal and ethmoidal bones, into the brain-case, just external to the cribriform plate. It then extends in a shallow groove along the outer wall of this plate to the cerebro-nasal slit near the crista galli, passes through this slit, enters the nasal chamber, and divides into three branches—the internal or septal branch, the lateral, and the anterior superficial branch.

The Internal or Septal Branch of the internal nasal nerve passes downward and forward, and supplies the anterior portion of the septum of the nose.

The Lateral Branches of the Internal Nerve usually comprise two or three filaments which are distributed to the anterior portions of the lateral walls of the nasal chambers, including the extremities of the middle and inferior turbinated bones.

The Anterior or Superficial Branch passes downward in a longitudinal groove or canal on the internal surface of the nasal bone until it reaches the lateral cartilage of the nose. Here it extends between the bone and the cartilage, runs beneath the compressor naris, and becomes superficial, terminating in the spine, the wing, and the tip of the nose.

The Infratrochlear Nerve is one of the terminal branches of the nasal nerve, it being given off near the anterior ethmoidal foramen. It passes forward along the inferior border of the superior oblique muscle and parallel to the supratrochlear nerve, and receives a communicating branch from it. As it approaches the trochlea it passes to the inner angle of the eye and divides into two sets of branches. Those of the superior set are distributed to the superficial structures of the superior eyelid; while those of the inferior set are distributed to the superficial structures at the root and side of the nose, the superficial portion of the inferior eyelid, the caruncle, conjunctiva, the lachrymal sac, and the lachrymal duct.

Variations.—"The nasal nerve occasionally (frequently, Krause) gives filaments to the superior and internal recti. A branch to the levator palpebræ superioris has been met with (Fäsebeck); offsets from the nasal nerve as it traverses the anterior internal orbital canal to

the frontal sinus and ethmoidal cells are described by Meckel and Langenbeck."[1]

Superior Maxillary Nerve.

The superior maxillary or second division of the fifth nerve is the second in size of its three great divisions. It is composed entirely of sensory fibres, and gives sensation to nearly all the structures of and around the superior maxillary bone. It commences in the centre of the convex or anterior margin of the Gasserian ganglion by a flattened and plexiform band, passes horizontally and directly forward, and leaves the cranium through the foramen rotundum in the great wing of the sphenoid bone. It then enters the pterygo-maxillary (spheno-maxillary) fossa, and becomes more rounded and firmer in texture. It passes across this fossa surrounded by adipose tissue, and enters the infraorbital or superior maxillary canal, and receives the name of infraorbital nerve. It passes through this canal, and emerges upon the face through the infraorbital foramen. The branches of this nerve can be divided into four groups, according to the locality of their origin.

The Orbital or Temporo-malar Branch (subcutaneous malæ) is a small nerve which arises from the upper portion of the superior maxillary nerve just after it emerges from the foramen rotundum. It passes forward into the orbital cavity through the spheno-maxillary fissure, and immediately divides into two branches, temporal and malar.

The Temporal Branch passes forward in a groove on the outer wall of the orbit until it reaches the temporal canal in the malar bone. It passes through this canal into the anterior portion of the temporal fossa, ascends between the bone and the temporal muscle a short distance, pierces the muscle and its aponeurosis about an inch above the zygoma, and terminates in filaments which supply the cutaneous structures of the temporal region and the side of the forehead. It interlaces with the facial and occasionally with the third division of the fifth nerve. That portion of the nerve within the orbit sends one or two filaments of communication to the lachrymal nerve, a branch of the ophthalmic division of the fifth.

The Malar Branch at its commencement passes through the loose adipose tissue at the lower angle of the orbit to the malar bone, through which it extends in the malar canal in its lower portion, and emerges upon the face usually by two branches. It is distributed to the cutaneous tissues in this region of the cheek, and interlaces with the facial nerve.

The Spheno-palatine Branches are usually two in number, and are given off from the middle of the lower surface of the pterygo-maxillary portion of the second division of the fifth nerve. They pass downward to the spheno-palatine or Meckel's ganglion.

The Posterior Superior Dental or Alveolo-dental Nerve usually arises by one root, though occasionally it has two, from the second division of the fifth nerve just before it passes into the infraorbital canal. When it arises by one root it almost immediately divides into two, and forms a superior and an inferior set of branches.

[1] From Quain's *Anatomy*.

The Superior Set passes forward, and enters canals in the zygomatic surface of the superior maxillary bone, traverses the base of the malar process of this bone, and terminates in the canine fossa, interlacing with the anterior dental nerves.

The Inferior Set is somewhat larger than the superior, and passes downward, slightly outward and forward, to enter the posterior dental canals. One of these canals traverses the outer wall of the maxillary sinus, and joins the anterior dental canal extending from the infraorbital. As the nerve passes forward in this canal it gives off branches which form loops or plexuses, from which filaments are given off to enter the roots of each of the molar teeth, and are distributed to their pulps, the outer wall and mucous membrane of the maxillary sinus, the alveolar process and the gums, and a few fibres to the bony structure of the antrum of Highmore. Occasionally the posterior dental nerve is of large size, and replaces an absent buccal nerve, a branch of the inferior maxillary.

The Middle Superior Dental Nerve is given off from the infraorbital soon after it enters the infraorbital canal. It passes outward, downward, and forward in a special canal in the outer wall of the maxillary sinus, interlacing with the posterior dental nerve, and forms loops or plexuses from which filaments are given off to enter the roots of the bicuspid teeth.

The Anterior Superior Dental Nerve is larger than either of the other two divisions. It is given off from the infraorbital nerve a little before it emerges from the infraorbital foramen. It passes in a special canal of its own which begins in the anterior wall of the maxillary sinus, extends at first inward, then downward, and is reflected upon the floor of the nasal fossa. It then passes in a lateral direction, and communicates with the canals of the middle and posterior dental nerves. This nerve gives off two sets of distributing branches, the ascending and the descending.

The Ascending Nasal Set is distributed to the nasal spine of the superior maxillary bone, the mucous membrane of the anterior portion of the inferior meatus, and to the floor of the nose.

The Descending or Dental Set is distributed through loops or plexuses to the incisor and canine teeth, and interlaces with the middle and posterior dental nerves.

The three superior dental nerves interlace or communicate with each other in such a manner as to form loops or plexuses. These plexuses (superior dental) are situated above the roots of the teeth, and it is often, if not always, difficult to say where one begins and the other ends. It is extremely probable that filaments from each of the three nerves pass into the same tooth. This may account for the fact that some of these nerves can be severed and the pulps of the teeth remain vital.

The Facial or Terminal Set is composed of three nerves—the palpebral, nasal, and labial. They arise from the infraorbital just as nerve emerges from the infraorbital foramen.

The Inferior Palpebral or Ascending Set is generally mad
nerves. They ascend in a groove or canal, pass through
tion of the proper elevator muscle of the upper lip,

to the orbicularis palpebrarum, the skin, the conjunctiva of the lower eyelid, and interlace at the outer angle of the orbit with the malar branches of the orbital and facial nerves. A branch also passes inward and interlaces with the external nasal nerve, a division of the ophthalmic.

The Nasal or Internal Branches, two or three in number, pass inward and outward between the fibres of the levator labii superioris alæque nasi muscle, and are distributed to the skin of the nose and the lining membrane of the nostril, and interlace with the nasal branches of the ophthalmic nerve.

The Labial or Descending Branches are more numerous than the branches of the other sets from the infraorbital nerve. They pass downward beneath the levator labii superioris muscle, and are distributed to the upper lip, its skin, mucous (labial) glands, and mucous membrane. They also extend to the anterior portion of the gums.

The Infraorbital Plexus of nerves is situated below the orbit, and is composed of branches from the infraorbital and facial nerves.

The Inferior Maxillary Nerve.

The Inferior Maxillary, or Third Division of the Fifth Nerve, is the largest of its three divisions. It differs from the other two divisions in the fact that its function is mixed, being both sensory and motor; it also probably supplies in a measure the special sense of taste. This nerve is distributed to the inferior portion of the face, the inferior maxillary bone, the inferior teeth, a portion of the tongue, and the muscles of mastication. Its origin is composed of two portions, the sensory and motor.

The Sensory (or larger) *Portion* arises from the inferior lateral and anterior part of the margin of the Gasserian ganglion. It passes downward through the foramen ovale in the sphenoid bone, accompanied by the smaller anterior or motor root. Immediately after its exit from this foramen the two portions unite, their fibres interlacing, to form one nerve, the mixed function of the nerve being thus accounted for. It then descends vertically internal to the external pterygoid muscle, and divides into two sets of branches, anterior and posterior.

The Anterior Motor Branch or trunk of the inferior maxillary nerve is the smaller of the two, and is composed almost entirely of motor filaments, which are distributed to the muscles of mastication. It is divided into four branches:

Deep temporal,	Pterygoid,
Masseteric,	Buccal.

The Deep Temporal Branches are usually two in number, though occasionally there are three—anterior, middle, and posterior.

The Anterior Branch before piercing the external pterygoid muscle is joined by a communicating filament from the buccal nerve. It ascends across the infratemporal (pterygoid) ridge of the sphenoid bone, passes to the anterior portion of the temporal fossa, and supplies that part of the temporal muscle situated in this region.

The Middle Deep Temporal Branch passes outward above the exter-

nal pterygoid muscle, then curves upward, running close to the temporal bone, and is distributed to the deep and internal portions of the temporal muscle.

The Posterior Temporal Branch is made up entirely of motor filaments. During the first portion of its course it is often associated with the masseteric nerve. It passes in a tortuous manner upward and outward, then upward through the proximal surface of the temporal muscle; it passes out of this muscle and through its fascia from a half to three-quarters of an inch above the zygoma, and then turns upward beneath the skin and interlaces with the auriculo-temporal and facial nerves.

The Masseteric Nerve is larger than the deep temporal, and arises in close proximity to it. Occasionally these two nerves arise as a common trunk from the third division of the fifth nerve. It passes backward and outward between the upper portion of the zygomatic fossa and the superior border of the external pterygoid muscle, curves slightly downward and outward, and passes through the sigmoid notch in the inferior maxillary bone. It then extends downward between the ramus of the bone and the masseter muscle, to which muscle it is mainly distributed. Its other branches of distribution are, first, a small communicating filament which interlaces with the deep temporal and independent deep posterior temporal branch, and an articulating branch which passes to the temporo-maxillary articulation.

The Internal Pterygoid Nerve is the shortest branch of the third division of the fifth nerve. It is given off from its anterior and proximal side on a level with the otic ganglion. It passes backward between the ganglion and the lingual nerve, occasionally extending through the ganglion to the inner side of the internal pterygoid muscle, to which it is mainly distributed. Its other branches of communication are, first, a motor root to the otic ganglion; second, a filament to the palato-Eustachian (tensor palati) muscle; third, a branch to the tensor tympani.

The External Pterygoid Nerve is not constant in its origin; it seldom arises from the main trunk of the inferior maxillary, but generally in conjunction with the buccal branch or from the internal pterygoid nerve. It is distributed to the external pterygoid muscle.

The Buccal Nerve, though described under the head of the motor branches of the inferior maxillary nerve, is almost entirely composed of sensory fibres. It arises from the lateral margin of the main trunk of the inferior maxillary by from one to three bundles, and is usually joined at its origin by the anterior deep temporal and the external pterygoid nerves. It passes outward, either between the two heads of the external pterygoid or between the two pterygoid muscles; extends downward to the inner surface of the coronoid process of the inferior maxilla, thence forward between this process and the tuberosity of the superior maxillary bone, occasionally passing between the fibres of the temporal muscle close to its insertion. Midway between the lobe of the ear and the angle of the mouth it becomes superficial, and terminates by dividing into superior and inferior branches.

Branches of distribution are—

(*a*) *Two or three external pterygoids*, which are given off as the nerve passes through the external pterygoid muscle.

(*b*) An *anterior deep temporal branch*, which usually joins the deep temporal nerve. It passes upward to the thick portion of the temporal muscle.

(*c*) A *descending branch*, which passes to the insertion of the temporal muscle.

(*d*) *Superior terminal branches*, which supply the upper portion of the buccinator muscle, the skin of the malar and buccal region. These branches interlace with the facial nerve near the parotid duct.

(*e*) *Inferior terminal branches*, which pass forward to the angle of the mouth, and are distributed to the skin, the lower portion of the buccinator muscle, as well as the buccal mucous membrane and glands. These branches, together with buccal branches of the facial nerve, form a plexus around the facial vein.

Variations.—The buccal nerve occasionally arises from the superior maxillary nerve. Turner reports a case in which it arose from the inferior dental nerve and passed through a foramen in the alveolar border near the ramus of the inferior maxillary bone. Gillette has seen it arising in one case from the Gasserian ganglion, passing through a special foramen situated between the round and oval foramen in the great wing of the sphenoid bone.

The posterior or sensory branches of the third division of the fifth nerve are—

Auriculo-temporal, Inferior dental.
Gustatory or lingual,

The Auriculo-temporal Nerve usually arises by two roots, of unequal size, situated close to the foramen ovale. At first they pass backward and outward, one on either side of the middle meningeal artery. They then unite and form a flattened trunk, which passes backward beneath the external pterygoid muscle to the inner side of the neck of the condyle of the inferior maxilla. It curves around the condyle of the lower jaw in company with the superficial temporal artery, passes upward between the ear and the temporo-maxillary articulation, thence over the zygoma and beneath the superficial temporal artery, terminating in several filaments which are distributed to the skin over the greater portion of the temporal region, extending to its superior extremity. They interlace anteriorly with the facial nerve.

Branches of the auriculo-temporal nerve are—

Communicating, Parotid,
Articular, Anterior auricular.
Branches to external auditory meatus,

The Communicating Branches are slender filaments which pass between the otic ganglion and the third division of the fifth nerve near its origin. One or two branches which are given off near the neck of the condyle of the lower jaw pass forward beneath the facial nerve, unite with it near the posterior border of the masseter muscle, and form one of the principal communicating branches between the facial and trifacial nerves.

The Articular Branches are one or two fine filaments which pass to the temporo-maxillary articulation.

The Branches to the External Auditory Meatus are two in number, superior and inferior. They pass between the bone and the cartilage to enter the meatus, and are distributed to the lining of the ear. The superior branch gives off a filament to the membrana tympani.

The Parotid Branches supply the parotid gland. They are frequently connected with the facial nerve.

The Anterior Auricular Branches are usually two in number. They pass between the tragus and helix, and are distributed to the concave surface of the auricle.

The Lingual Nerve.

The lingual or gustatory nerve is second in size, and an important branch of the third division of the fifth. From its origin it passes down on the internal surface of the external pterygoid muscle, anterior and a little to the inner side of the inferior dental nerve. These two nerves have been observed arising from a common trunk and bifurcating near the posterior dental foramen. As the lingual nerve reaches the lower border of the external pterygoid muscle it curves forward between the internal pterygoid muscle and the ramus of the lower jaw, inclines inward over the superior constrictor of the pharynx, under the stylo-glossus muscle and above the deep portion of the submaxillary muco-salivary gland. It then extends forward, crosses Wharton's duct, passes below the mucous membrane of the alveolar lingual groove, and terminates at the apex of the tongue.

Branches of Communication.—Near the origin of the lingual nerve a communicating branch passes over the internal maxillary artery to the inferior dental nerve. There is also a small branch which passes to the hypoglossal nerve. This nerve also forms a plexus, from which branches are distributed to the walls of the internal jugular vein, a portion of the sinuses and the cancelli of the occipital bone, and interlace with branches which pass through the anterior condyloid foramen. The chorda tympani branch, which is a small nerve, arises from the facial, and descends from the proximal extremity of the squamoso-tympanic suture (fissure of Glasserius) to the acute angle of the lingual nerve as it passes forward close to the lower border of the external pterygoid muscle. At first there is only a mechanical union between these two nerves, but subsequently they are intimately associated. Branches pass directly to the submaxillary ganglion where it is in close relation with the submaxillary muco-salivary gland. Anterior to the last branch, one or two communicating filaments descend over the first portion of the hypoglossal muscle to interlace with filaments from the hypoglossal nerve.

The branches of distribution of the lingual nerve are—

A small branch to the palato-glossal fold (anterior palatine arch) and the tonsils.

A sublingual branch, which is distributed to the mucous membrane of the floor of the mouth, the gum tissue on the inner surface of the inferior maxillary bone, and the sublingual mucous gland.

The lingual or terminal branches, which pass upward between the

fibres of the tongue, divide into finer filaments, which are distributed to the mucous membrane of the anterior two-thirds of the tongue and terminate in the conical and fungiform papillæ.

A few plexiform filaments, which pass beneath the tongue, some terminating on the under surface of the tip and in the glands of Nühn.

The Inferior Dental Nerve.

The Inferior Dental Nerve is the largest of the branches of the third or inferior maxillary division of the fifth nerve (Fig. 145). From its origin it passes downward, accompanied by the inferior dental artery, on the internal surface of the external pterygoid muscle posterior and a little to the side of the lingual nerve. After reaching the lower border of the external pterygoid muscle it passes between the lateral ligament and the ramus of the jaw, and enters the inferior dental canal through the posterior dental foramen. It then passes through this canal, and terminates opposite the anterior or mental foramen by dividing into incisor and mental branches.

Fig. 145.

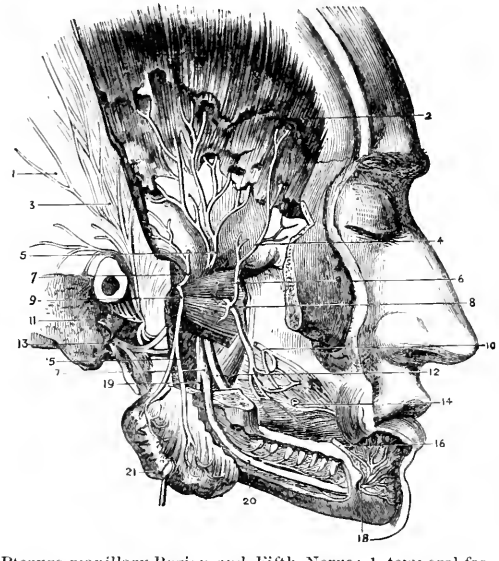

Pterygo-maxillary Region and Fifth Nerve: 1, temporal fascia; 2, temporal muscle; 3, temporal branches of auriculo-temporal nerve; 4, deep temporal branch of buccinator nerve; 5, deep temporal nerves; 6, pterygoideus externus; 7, deep temporal branch of masseteric nerve (inconstant); 8, buccinator (or long buccal) nerve (fifth); 9, masseteric nerve; 10, buccal branch of seventh; 11, auriculo-temporal nerve; 12, lingual nerve; 13, facial nerve (seventh) at stylo-mastoid foramen; 14, buccinator muscle; 15, pterygoideus internus; 16, supramaxillary branch of seventh; 17, inferior dental nerve; 18, its mental branches; 19, its mylo-hyoid branch; 20, inferior dental nerve in inferior dental canal (opened); 21, masseter (turned down).

The branches of the inferior dental nerve are—

A Communicating Branch, which passes over the internal maxillary artery to the lingual nerve.

A Mylo-hyoid Branch, which is generally described with the inferior dental, which latter is a sensory nerve, while the former is in reality motor in character. Its fibres can be traced from its point of distribution backward to the anterior or motor root of the fifth nerve. It is given off from the inferior dental nerve just as it is about passing into the posterior dental foramen, and passes downward and forward, accompanied by the mylo-hyoid artery in the mylo-hyoid groove of the inferior maxillary bone. It is distributed to the inferior surface of the mylo-hyoid and the anterior belly of the digastric, also the tensor palati and tensor tympani muscles. A few filaments from this branch pass through the mylo-hyoid muscle and interlace with the lingual nerve. Branches are also de-

scribed as passing to the depressor anguli oris and platysma myoides muscles (Henle), to the integument below the chin (Krause and Schwalbe), and to the submaxillary gland (Meckel, Henle, Curnow).

The Inferior Dental Branches are numerous, and form loops or plexuses beneath the roots of the teeth similar to those found above the superior teeth. From these loops fine filaments pass through the apical foramina in the roots of the teeth of the lower jaw to supply the pulp and tooth with sensation. There are also filaments which pass upward and supply the alveolo-dental membranes and gum tissue.

The Incisor Branch is the continuation of the main trunk of the inferior dental nerve. It passes forward under the inferior canine and incisor teeth, and forms loops or plexuses similar to those formed by the main branch, from which filaments are distributed to the teeth and surrounding tissues in like manner.

The Mental or Labial Nerve is the larger of the two terminal divisions of the inferior dental nerve. It passes outward from the canal through the anterior dental (mental) foramen, and immediately breaks up into three branches beneath the depressor anguli oris muscle. The inferior branch descends, and is distributed to the chin. The two superior branches ascend to supply the lip, its mucous membrane, and the labial glands. These three branches freely interlace with the supramaxillary branch of the facial nerve.

The inferior dental nerve occasionally receives one or two communicating filaments from other branches of the inferior maxillary nerve.

The Lesser Inferior Dental Nerve (Sapolini) is frequently present. It arises from the Gasserian ganglion, and unites with the inferior dental nerve after entering the inferior dental canal.

SYMPATHETIC GANGLIA CONNECTED WITH THE FIFTH NERVE.

The sympathetic ganglia (ganglia of the fifth nerve) found in connection with the trifacial nerve belong to the general sympathetic system found throughout the body. This sympathetic system is composed of a large number of ganglia, cords, and plexuses.

The Ganglia are separate centres for the conveyance and distribution of various cords and filaments, consisting of motor, sensory, and sympathetic fibres. They contain nerve-cells very similar to those found in the encephalon and spinal cord. These ganglia are arranged in two chains situated on each side of the body near the central line. They commence with the ophthalmic ganglion in the orbit, and extend downward along each side of the vertebral column, and terminate below in the ganglion impar in the coccygeal region.

The ganglionic or sympathetic system is independent and separate from the general nervous system, but is intimately connected with it by communicating branches which pass from the motor and sensory roots of the cerebro-spinal nerves, as well as by direct filaments which extend between it and the cerebro-spinal centres. The sympathetic nervous system is distributed to the mucous membranes, the viscera, the coats of blood-vessels, and to the non-striated or involuntary muscular fibres.

The nerves of this system form plexuses in various parts of the body, especially around the arteries. They are not found in connection with striated voluntary muscular fibres. The cardiac muscle, being partially striated, yet involuntary, is an exception. Numerous ganglionic cells are found situated at the terminal ends of sympathetic nerve-fibres.

THE CRANIAL GANGLIA, OR GANGLIA OF THE FIFTH PAIR OF NERVES.[1]

	Name.	Situation.	Sensory Root.	Motor Root.	Sympathetic Root.	Branches of Distribution.
Cerebral Ganglia.	Ophthalmic or Ciliary.	Between the optic nerve and external rectus.	Fifth nerve, nasal branch.	Third nerve.	Cavernous plexus.	To ciliary muscle and iris.
	Spheno-palatine or Meckel's.	Spheno-maxillary fossa.	Fifth nerve, spheno-palatine branches.	Seventh nerve, through Vidian and large petrosal branches.	Carotid plexus, by means of Vidian nerve.	Orbital, nasal, naso palatine, anterior or large palatine, middle or external palatine.
	Otic.	Below the foramen ovale.	Fifth nerve, auriculo-temporal branch.	Seventh nerve, through small petrosal. Fifth nerve, through internal pterygoid branch.	Plexus on the middle meningeal artery.	To tensor tympani and tensor palati muscles.
	Submaxillary.	Above the submaxillary gland.	Fifth nerve, lingual or gustatory branch.	Seventh nerve, through chorda tympani branch.	Plexus on the facial artery.	To submaxillary gland and mucous membrane of the mouth.

The cranial ganglia, or ganglia of the fifth pair of nerves tabulated above, are four pairs—viz.:

Ophthalmic, Otic,
Spheno-palatine, Submaxillary.

The Ophthalmic, Lenticular, or Ciliary Ganglion is situated in the posterior portion of the orbital cavity, between the external rectus muscle and the optic nerve, in close apposition to the ophthalmic artery. It is a small, flattened, and reddish body, surrounded by adipose tissue, its flattened surfaces being the proximal and the distal. It measures about one line in length from before backward.

Its branches or roots of communication are—

1. *The Sensory or Long Root*, which is a slender filament arising within the cavernous sinus from the nasal branch of the ophthalmic division of the fifth nerve. It enters the posterior superior angle of the ganglion. Occasionally a filament is found which extends from the lachrymal nerve to the ganglion.

2. *The Motor or Short Root*, which is shorter and thicker than the sensory root, and occasionally divides into two branches. It is derived from the inferior oblique branch of the motor oculi or third nerve, and joins the ganglion at its posterior inferior angle.

3. *The Sympathetic or Middle Root*, which is derived from the system to which the ganglion belongs. This root is smaller than either of the others, and originates in the cavernous sinus, being derived from the

[1] After Ranney.

carotid plexus. Through this plexus it communicates with the cervical ganglion. As it extends forward to the posterior border of the ganglion, it occasionally unites with the long or sensory root, forming a common trunk.

Variations in the Roots.—The ophthalmic ganglion may receive accessory roots from the superior division of the motor oculi, the lachrymal, abducens, or spheno-palatine ganglion (Henle, Tiedemann).

"According to Reichart, the ophthalmic ganglion does not receive its sympathetic fibres by a single root, but by several fine filaments, the majority of which accompany the third nerve.

"It appears from the mode of development and arrangement in many of the lower vertebrates that the ophthalmic ganglion is morphologically associated more intimately with the third nerve, having, in fact, the significance of a spinal ganglion of that nerve (M. Marshall, Schwalbe)."[1]

Its branches of distribution are to the iris and ciliary muscles. The short ciliary nerves, ten to fifteen in number, arise in two sets, superior and inferior.

The Superior Set arises from the anterior superior angle, and passes forward, in a wave-like manner, between the optic nerve and the superior rectus muscle to the posterior part of the eyeball.

The Inferior Set is more numerous than the superior, and arises from the anterior inferior angle of the ganglion. It passes in a wave-like manner below the optic nerve and above the inferior rectus muscle to the posterior part of the eyeball. It is accompanied by the long ciliary nerves which are derived from the nasal branch of the ophthalmic division of the fifth. One or more of its fibres join the short ciliary nerves.

Both the superior and the inferior sets pass forward through the sclerotic coat of the eye in delicate grooves on its inner surface, next to the choroid coat, and are distributed to the ciliary muscle, the iris, and the cornea. A small filament penetrates the optic nerve to the arteria centralis retinæ (Tiedemann).

Spheno-palatine Ganglion.

The spheno-palatine ganglion (ganglion of Meckel) (Fig. 146) is the largest of the cranial ganglia. It is situated in the pterygo-maxillary fossa in front of the anterior opening of the Vidian canal, close to the spheno-palatine foramen. It is triangular in form, with its apex pointing backward in the direction of the Vidian canal, and is surrounded by adipose tissue. Its outer surface is convex, and averages about one-fifth of an inch in diameter. It is reddish-gray in color, excepting at its broadest part, where it is composed entirely of gray matter.

The branches or roots of communication of the spheno-palatine ganglion are—

1. *The Sensory Roots*, two in number, which arise from the superior maxillary nerve as it passes through the pterygo-maxillary fossa. They enter the ganglion separately, one at the anterior and the other at the posterior corner of the upper surface. Many of the fibres of these roots pass through the ganglion without becoming incorporated with

[1] Quain's *Anatomy*.

it, and receive no influence from it. These fibres form the palatine nerves.

2. *The Motor Root*, which is quite long, and arises from the facial nerve or the large superficial petrosal nerve at the geniculate ganglion (intumescentia gangliaformis) within the aqueduct of Fallopius. From this point it passes forward through the hiatus Fallopii on the anterior surface of the petrous portion of the temporal bone, then inward beneath the Gasserian ganglion, being separated from it by a thin layer of dura mater. It then pierces the fibro-cartilage occupying the middle lacerated foramen, and passes to the outer side of the internal carotid artery.

Fig. 146.

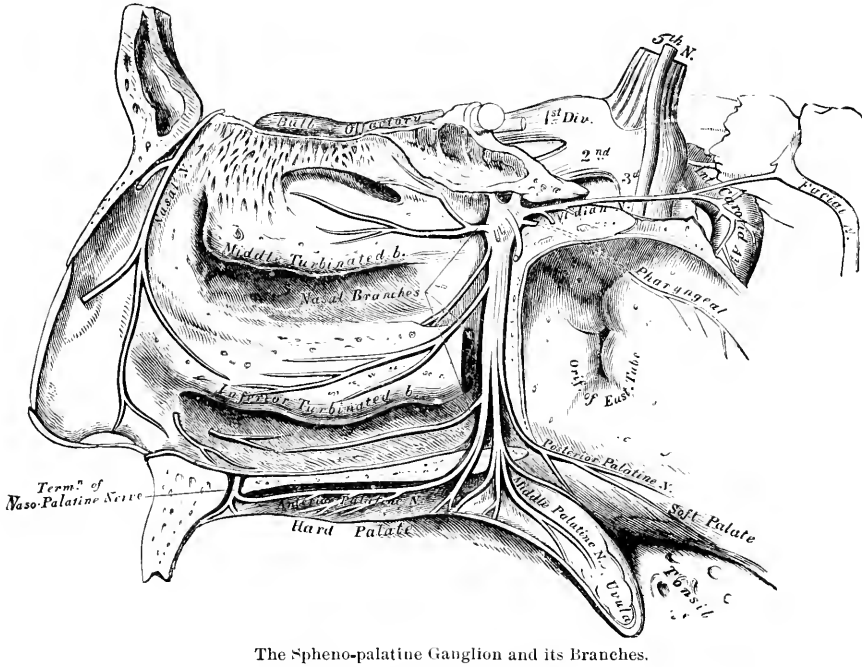

The Spheno-palatine Ganglion and its Branches.

At this point it is joined by the sympathetic root or the large deep petrosal nerve of the spheno-palatine ganglion, and the two conjointly receive the name of the Vidian nerve. They pass into the Vidian canal in the sphenoid bone, extend through this canal, and at the exit enter the posterior or apicial extremity of the ganglion. The gray matter of the ganglion extends along the nerve as far as the origin of the sympathetic at the carotid plexus.

3. *The Sympathetic Root*, or the large deep petrosal nerve, commences from the carotid plexus which surrounds the internal carotid artery. These filaments unite and form a short branch of reddish color and soft texture, which passes forward and joins the motor root of the ganglion to form the Vidian nerve, above described. Occasionally these two roots remain separate throughout their course, and enter the ganglion ununited.

The branches of distribution of the spheno-palatine ganglion are—

1. *Ascending or Orbital Branches*, consisting of three or four fine filaments which pass into the orbit through the spheno-maxillary fissure, and are distributed to the periosteum and mucous membrane of the posterior ethmoidal and sphenoidal sinuses by passing between the sphenoid and ethmoid bones.

Some of the branches which pass upward are distributed to the neurilemma of the optic nerve (Arnold and Longet).

A branch from the ganglion ascends to the sixth nerve (Bock and Valentin).

Also a branch to the ophthalmic ganglion (Tiedemann).

Two or three branches, spheno-ethmoidal, ascend to the superior portion of the internal orbital wall, pass through the posterior ethmoidal foramen, and enter the brain-case (Luschka).

2. *The Descending or Palatine Branches*, three in number—anterior, posterior, and external. These three branches pass from the superior maxillary nerve through that portion of the ganglion in which there is little ganglionic or gray matter. They thus pass to their distribution without becoming involved or influenced by the ganglion, except it be to a very slight extent.

The Anterior or Large Palatine Nerve passes downward in the posterior palatine or palato-maxillary canal, and enters the oral cavity at the posterior palatine foramen. It then passes forward in a groove on the side of the hard palate to its anterior portion, where it joins the naso-palatine nerve. It is distributed to the gums, mucous glands, and membrane of the hard palate. This nerve gives off a separate branch (middle palatine), which passes downward to the soft palate in a separate canal. It also gives off branches (inferior nasal) while in the canal, which are distributed to the middle and inferior turbinated bones.

The Posterior or Small Palatine Nerve passes downward, accompanied by a small artery in the small palatine canal, to the soft palate, and divides into two sets of branches. One set is distributed to the levator palati and azygos uvula muscles, and may be composed entirely of motor filaments coming from the great superficial petrosal branch of the motor, facial, and the Vidian nerves. The other set, which is sensory, is distributed to the mucous membrane of the superior surface of the soft palate, the glands of the soft palate, as well as to the tonsils.

The External Palatine Nerve is the smallest of the three descending branches, and is not always constant in its existence. It passes downward through the external palatine canal, which is situated between the tuberosity of the superior maxilla and palate bones, and is distributed to the tonsils, uvula, and outer portion of the soft palate.

The Internal or Nasal Branches consist of two divisions, upper nasal and naso-palatine.

The Upper Nasal Branches, four or five in number, are small, and pass horizontally inward through the spheno-palatine foramen into the posterior superior portion of the nasal chamber. They are distributed to the posterior superior portion of the nasal septum, to the mucous membrane covering the superior and middle turbinated bones, and to the posterior ethmoidal cells.

The Naso-palatine Branch (nerve of Cotumnius, Scarpa) is larger than the upper nasal branches, and is an important division of the nasal nerves. It is long and slender, and arises from the proximal surface of the spheno-palatine ganglion. It passes through the spheno-palatine foramen across the roof of the nasal chamber to the septum, where it turns downward and forward, and extends in a groove or canal on the vomer to the foramina of Scarpa or naso-palatine foramina. These are two in number, anterior and posterior, and are situated in the inter-maxillary suture. The nerve of the right side usually passes through the posterior foramen, while the nerve of the left side passes through the anterior. These two nerves (right and left naso-palatine), meeting in the common or anterior palatine meatus or canal, form a fine plexus, from which minute filaments are distributed to the palate posterior to the incisor teeth and interlace with the anterior or great palatine nerve. "In its course along the septum small filaments are furnished from the naso-palatine to the pituitary membrane."[1]

The Posterior Branches generally assume the name of the Vidian nerve (already described) and the pharyngeal nerve.

The Pharyngeal or Pterygo-palatine Nerve consists of several fine filaments which frequently arise from the Vidian nerve, instead of from the posterior portion of the ganglion. It passes downward through the pterygo-palatine canal, accompanied by an artery of the same name, and is distributed to the mucous membrane of the upper portion of the pharynx and neighborhood of the Eustachian tube.

Otic Ganglion.

The otic ganglion (ganglion of Arnold) (Fig. 147) is a reddish-gray body situated just below the foramen ovale, and in close apposition to the proximal surface of the inferior maxillary nerve at the point of union of its motor root with the third sensory division arising from the Gasserian ganglion, the cartilaginous portion of the Eustachian tube to its inner surface, while the middle meningeal artery passes up into the brain-case just posterior to it. It is a flattened oval body, its widest diameter, which is about one-sixth of an inch, being antero-posterior.

Its branches or roots of communication are—

1. *The Long or Sensory Root of Arnold* is composed of the lesser superficial petrosal nerve, which is a continuation of the tympanic branch of the glosso-pharyngeal, and a branch from the geniculate ganglion of the seventh. The ganglion also receives an important sensory branch from the auriculo-temporal nerve of the fifth.

2. *The Motor or Short Root of Arnold* is derived from the internal pterygoid branch of the inferior maxillary division of the fifth. It also receives motor filaments through the lesser superficial petrosal derived from the geniculate ganglion of the seventh nerve.

3. *The Sympathetic Root*, which is derived from the plexus around the middle meningeal artery.

The branches of distribution of the otic ganglion supply in part the

[1] Quain's *Anatomy*.

parotid gland, the chorda tympani, tensor tympani, palato-Eustachian muscles, and the mucous membrane of the middle ear.

The Submaxillary Ganglion.

The submaxillary or lingual ganglion is situated above the deep portion of the submaxillary muco-salivary gland, close to the outer portion of the hyo-glossus muscle. It varies in shape and size, usually

Fig. 147.

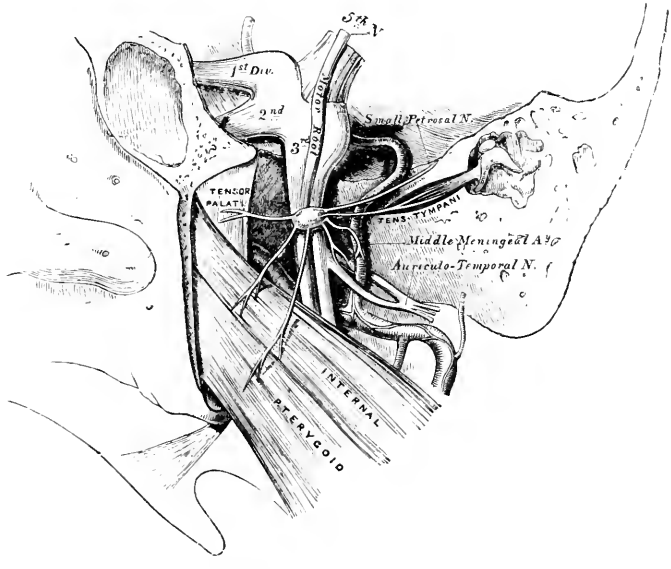

The Otic Ganglion and its Branches.

being triangular, but occasionally it is fusiform or plexiform, or absent altogether.

Its branches or roots of communication are—

1. *The Sensory Root*, which arises from the lingual branch of the inferior maxillary nerve and enters the posterior portion of the ganglion.

2. *The Motor or Long Root*, which is formed from the motor filaments of the lingual nerve received from the chorda tympani branch of the facial.

3. *The Sympathetic Root*, which arises from the sympathetic plexus around the facial artery.

The branches of distribution of the submaxillary ganglion are principally those that supply the submaxillary muco-salivary gland and its duct (duct of Wharton). Other branches pass upward, and interlace with the lingual nerve, forming a plexus on the side of the tongue, from which filaments are given off which supply the mucous membrane of the mouth. Baldwin and other anatomists describe a sublingual ganglion which is situated on the branch of the submaxillary ganglion which

passes to the lingual nerve. Occasionally one or two small branches are found which communicate with the hypoglossal nerve (Meckel and Bose). None of the branches of the submaxillary ganglion are distributed to muscles, which is in marked contrast with the branches from the otic ganglion.

The Facial Nerve.

The facial, seventh, or nerve of expression (the portio dura of the seventh pair of nerves, according to the arrangement of Willis) (Fig. 148) controls the muscles of expression. This fact alone would make it a nerve of vast importance to all those who study the face either from a surgical or an artistic standpoint. It not only transmits the motor stimulus to all the superficial muscles of the face, except the levator

Fig. 148.

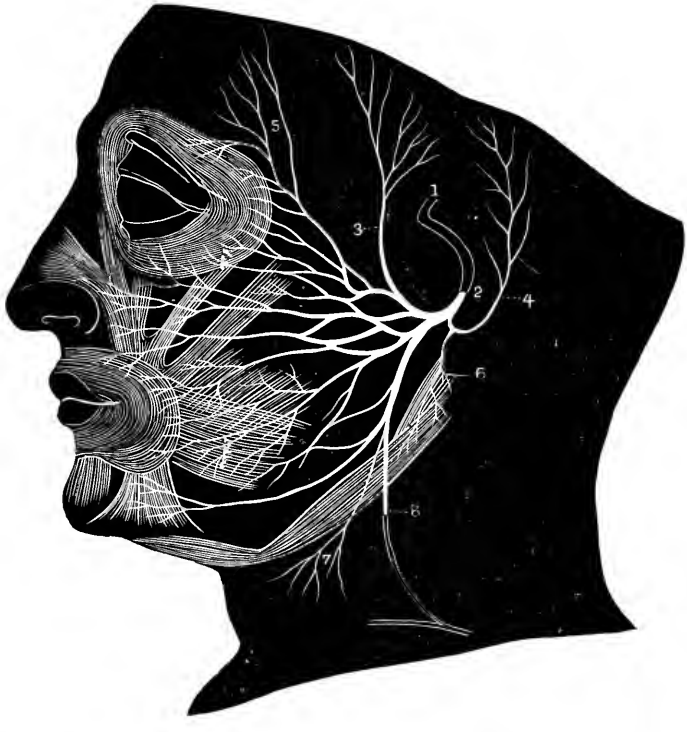

Diagram of the Facial Nerve and its Distribution: 1, Facial nerve at its entrance into the internal auditory meatus; 2, its exit at the stylo-mastoid foramen; 3, 4, temporal and posterior auricular branches, distributed to the muscles of the external ear and to the occipitalis; 5, branches to the frontalis muscle; 6, branches to the stylo-hyoid and digastric muscles; 7, branches to the upper part of the platysma myoides; 8, branch of communication with the superficial cervical nerve of the cervical plexus.

palpebræ superioris, but likewise to the scalp, the external ear, platysma myoides, buccinator, posterior belly of the digastric, and stylo-hyoid muscles. Through communicating branches it unites the anterior and

posterior cranial nerves, and by so doing increases the functional power of some of these nerves.

The following are some of its communicating branches:

It communicates with the three divisions of the fifth nerve;

With the spheno-palatine, submaxillary, and otic sympathetic ganglia;

A branch to the auditory nerve;

A branch to the glosso-pharyngeal nerve;

Through its auricular branch it also communicates with the pneumogastric nerve. It will be seen that through this large communication it supplies other structures, which will be described hereafter.

The superficial or apparent origin of the facial nerve is from the uppermost lateral portion of the medulla oblongata in a groove between the olivary and restiform bodies, just below the pons varolii. The eighth or auditory nerve is in close apposition to its outer side, the two being separated only by a couple of filaments which are known as the intermediary nerve of Wrisberg (portio inter duram et mollem).

This intermediary nerve is more or less connected with the facial and auditory nerves, but from the fact of its greater connection with the facial it has been classed as one of its roots (accessory root of Sappey). It passes between the two nerves into the internal auditory meatus, and terminates in the geniculate ganglion.

The facial nerve passes from its origin, in company with the eighth or auditory nerve, forward and outward between the pons varolii and the middle peduncle of the cerebrum, around which it curves to enter the internal auditory meatus, situated in the posterior surface of the petrous portion of the temporal bone. It rests in a groove on the upper part of the meatus, the auditory nerve being below, while the nerve of Wrisberg still retains its position between the two. On reaching the upper extremity of the meatus, the seventh nerve passes into and through the aqueduct of Fallopius. This aqueduct runs an extremely tortuous course through the petrous portion of the temporal bone. It is at first directed outward for a short distance between the cochlea and the vestibule to the wall of the middle ear; then it bends backward over the fenestra ovalis, then downward behind the pyramid and the middle ear, and terminates at the stylo-mastoid foramen, at which point the nerve makes its exit on the face. It passes from this point downward and forward in the substance of the parotid gland, and breaks up into numerous branches to supply the muscles of expression.

The branches of the facial nerve are tabulated as follows by Prof. Allen:[1]

Branches of the geniculate ganglion, six in number,	The great superficial petrosal nerve. The lesser " " " Branches to the sympathetic system. " " tympanic plexus. " " pneumogastric nerve. " " glosso-pharyngeal nerve.
Before escaping at the stylo-mastoid foramen,	Stapedius. Chorda tympani. Connecting branches with pneumogastric. " " " glosso-pharyngeal.

[1] Allen's *Anatomy*, p. 529.

After escaping from the stylo-mastoid foramen,
- Posterior auricular, { Auricular. / Occipital.
- Stylo-hyoid.
- Digastric.
- Stylo-glossal.
- Temporo-facial, { Temporal. / Malar. / Infraorbital.
- Cervico-facial, { Buccal. / Supramaxillary. / Cervical.

The Geniculate Ganglion (intumescentia ganglioformis) is a reddish enlargement on the foremost part of the facial nerve, which contains numerous nerve-cells. It is situated on the curve as the nerve turns from the horizontal to the perpendicular direction in the aqueduct of Fallopius. It does not receive all the fibres of the facial nerve, but receives the terminal ends of the nerve of Wrisberg. The nerves arising from this ganglion are six in number, the names of which will be found in the preceding table.

FIG. 149.

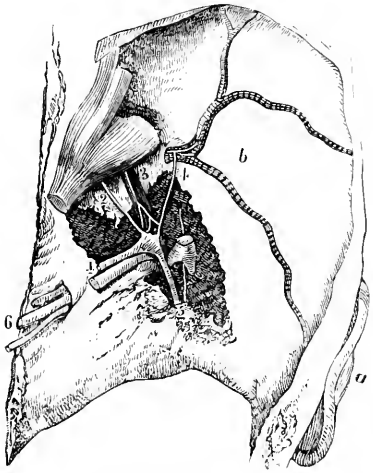

This drawing represents the Middle Fossa of the Base of the Skull, with the petrous part of the temporal bone cut through so as to expose the nerves joining the facial (from Bidder): *a*, external ear; *b*, middle fossa of the skull, with the middle meningeal artery branching on it; 1, facial nerve by the side of the auditory; 2, large superficial petrosal nerve; small superficial petrosal nerve lying over the tensor tympani muscle; 4, the external superficial petrosal nerve; 5, chorda tympani; 8, eighth nerve.

The Great Superficial Petrosal Nerve (Fig. 149) arises from the geniculate ganglion of the seventh nerve, and is the largest of the ganglionic branches. It passes forward through the hiatus Fallopii on the superior portion of the anterior surface of the petrous portion of the temporal bone, from which it passes inward beneath the Gasserian ganglion, being separated from it by a thin layer of the dura mater. It then pierces the fibro-cartilage occupying the middle lacerated foramen, and passes to the outer side of the internal carotid artery. At this point it is joined by the sympathetic root or the large deep petrosal nerve of the spheno-palatine ganglion, and passes into the Vidian canal in the sphenoid bone under the name of the Vidian nerve. It extends through this canal, and enters the apex of the spheno-palatine ganglion.

The Lesser Superficial Petrosal Nerve extends from the geniculate ganglion of the seventh nerve and unites with a branch from the nerve of Jacobson. It then passes through a small foramen and joins the otic sympathetic ganglion.

The Branch of Communication with the Sympathetic System, or the External Superficial Petrosal Nerve (Bidder), is not always present (Ruber). It forms a communicating filament between the geniculate ganglion and the sympathetic plexus around the middle meningeal artery.

The Branch of Communication with the Tympanic Plexus is a small nerve which connects the geniculate ganglion with the sympathetic tympanic plexus.

The Communicating Branch with the Pneumogastric Nerve passes out of the stylo-mastoid foramen, and communicates with the pneumogastric nerve through its articular branch.

The Communicating Branch with the Glosso-pharyngeal Nerve arises from the facial as it leaves the stylo-mastoid foramen. It communicates with the glosso-pharyngeal nerve below its petrosal ganglion.

The branches of the facial nerve before it escapes from the stylo-mastoid foramen are—

1. Stapedius;
2. Chorda tympani;
3. Connecting branches with pneumogastric nerve;
4. Connecting branches with glosso-pharyngeal nerve.

The Stapedius or Tympanic Nerve is the most slender branch given off by the facial nerve. It arises opposite the pyramid of the internal ear, passes through a fine canal, and is distributed to the stapedius muscle.

The Chorda Tympani Nerve arises from the facial nerve on the proximal side of the geniculate ganglion, though apparently it arises back of the tympanum close to the outer extremity of the aqueduct of Fallopius. From its origin it passes upward in a special curved canal nearly parallel to the aqueduct of Fallopius, and enters the posterior wall of the tympanic cavity close to the tympanic membrane. It here becomes invested by mucous membrane, arches upward between the long handle of the malleus and the vertical process of the incus to its anterior angle. It then passes out of the tympanum through a foramen (canal of Hugui) at the side of the glenoid (Glasserian) fissure, extends downward on the proximal side of the internal lateral ligament of the inferior maxillary bone, and forms a union with the lingual branch of the fifth nerve at a point where the nerve forms an acute angle by bending forward under the inferior border of the external pterygoid muscle. It is then distributed to the submaxillary mucosalivary gland and to the tongue. The chorda tympani nerve receives a communicating branch from the otic ganglion just before joining the lingual nerve. There is considerable discussion among anatomists and physiologists as to the origin and functions of this nerve. Some claim that it is a continuation of the nerve of Wrisberg, while J. Sapolini claims it as an independent cranial nerve, entitled to be classed as the thirteenth cranial nerve. Its function is also still in doubt, some claiming it to be a motor nerve, others a nerve of sensation, while others regard it as a special nerve of taste.

The Communicating Branch with the Pneumogastric Nerve arises from the facial nerve a little before its exit from its canal to join the upper ganglion of the pneumogastric. This branch is not constant.

The Communicating Branch with the Glosso-pharyngeal Nerve arises from the facial just as that nerve makes its exit from the stylo-mastoid foramen. It passes to the petrosal ganglion of the glosso-pharyngeal.

The branches that arise from the facial nerve after it has passed out of the stylo-mastoid foramen are six in number—viz.:

Posterior auricular,	Stylo-glossal,
Stylo-hyoid,	Temporo-facial,
Digastric,	Cervico-facial.

The Posterior Auricular Nerve arises from the facial near the stylo-mastoid foramen. It passes backward in close apposition to the lateral border of the posterior belly of the digastric muscle, and then curves outward and upward between the ear and the mastoid process of the temporal bone, where it divides into two branches, auricular and occipital.

The Auricular Branch passes upward behind the ear, and is distributed to the retrahens aurem, the small muscles, and the skin on the back part of the pinna. Occasionally it sends a filament to the attollens aurem muscle.

The Occipital Branch passes upward in a curved direction along the superior semicircular line, the posterior boundary of the base of the skull. It is distributed to the occipital muscle.

The branches of communication of the posterior auricular nerve are with the great auricular and the small occipital nerve of the cervical plexus, and with the auricular branch of the pneumogastric nerve.

The Stylo-hyoid Nerve is a long slender branch which is distributed to the stylo-hyoid muscle, and interlaces with the sympathetic plexus of the external carotid artery.

The Digastric Nerve frequently arises in common with the stylo-hyoid. It soon divides into two or three small filaments which are distributed to the posterior belly of the digastric muscle and interlace with the glosso-pharyngeal nerve near the base of the skull, and occasionally with the spinal accessory and pneumogastric nerves.

The Stylo-glossal Nerve (lingual nerve of Hirschfeld) is a long and exceedingly delicate branch which arises from the facial nerve near the base of the styloid process of the temporal bone. It passes downward and forward behind the stylo-pharyngeus muscle to the side of the pharynx and the base of the tongue. It receives several branches of communication from the glosso-pharyngeal nerve, and is distributed to the stylo-glossus and palato-glossus muscles, being lost in the mucous membrane at the base of the tongue.

The Temporo-facial Division of the seventh nerve is the larger of its two terminals. It passes forward and upward in the substance of the parotid gland on a level with the neck of the lower jaw. The external carotid artery and the temporo-maxillary vein are situated to its inner side. At the neck of the lower jaw the nerve breaks up into three branches, temporal, malar, and infraorbital. Before it branches, however, it receives filaments of communication from the auriculo-temporal nerve. After its division it receives communicating branches from the fifth nerve. The temporo-facial nerve and its communicating branches, together with numerous small branches from its three main divisions, form an irregular network of nerves known as the pes anserinus.

The Temporal Branch passes upward over the zygoma nearly at right angles to it, and soon breaks up into numerous branches which are distributed to the region of the temple and side of the forehead, including

the following muscles: attrahens and attolens aurem, frontalis, part of the orbicularis palpebrarum, and the corrugator supercilii. It communicates with the three divisions of the fifth nerve, the auriculo-temporal, a branch of the inferior dental, the temporal branch of the superior maxillary, and the supraorbital and lachrymal branches of the ophthalmic nerve.

The Malar or Ocular Branch passes forward, inward, and slightly upward to reach the external portion of the orbital cavity, and is distributed to the orbicularis palpebrarum and the corrugator supercilii. On the upper eyelid communicating filaments of this nerve interlace with the lachrymal and supraorbital branches of the ophthalmic, while on the lower eyelid they communicate with branches of the infraorbital.

The Infraorbital or Transverse Branch is larger than the other two divisions. It passes nearly horizontally forward and inward over the masseter muscle to the space between the orbit and the mouth, and divides into a superficial and deep set of branches.

The Superficial set passes between the integument and the muscles of the face; its filaments are distributed to the zygomatic, levator labii superioris alæquæ nasi, and the small nasal muscles.

The Deep Set passes beneath the levator labii superioris, and is distributed to the levator anguli oris and buccinator muscles. The terminal filaments of this set of nerves interlace with the filaments of the infraorbital and superior maxillary and infratrochlear nerves to form the infraorbital plexus, which is situated beneath the levator labii superioris proprius.

The Cervico-facial Branch is smaller than the temporo-facial, and passes obliquely downward and forward through the substance of the parotid gland to the angle of the inferior maxillary bone. It then extends on to the face below the other divisions of the facial nerve, and passes to the superior portion of the neck. At the angle of the jaw it terminates by dividing into three branches, buccal, supramaxillary, and cervical. When this nerve is within the parotid gland it receives a communicating filament from the great auricular nerve of the cervical plexus.

The Buccal Nerve in the first portion of its course passes between the parotid gland and the masseter muscle, then extends over the muscle in the direction of the angle of the mouth. It is distributed to the buccinator, palato-glossus and orbicularis oris, and receives communicating branches from the buccal and temporo-facial divisions of the inferior maxillary nerve.

The Supramaxillary Nerve is often double—that is, it is represented by two distinct nerves. It passes forward along the deep surface of the depressor anguli oris, and is distributed to the muscles of the lower lip and chin. A branch from this nerve extends forward along the margin of the lower jaw to the symphysis menti. It communicates with the mental branches of the inferior dental nerve and a branch from the inferior maxillary division of the fifth nerve.

The Cervical Nerve (inframaxillary) passes downward and forward, pierces the deep cervical fascia, and breaks up into slender branches

which form a series of arches beneath the platysma myoides muscle, extending inward to the suprahyoid region. It supplies the platysma myoides and the skin in this region, and communicates with the superficial cervical plexus.

Auditory Nerve.

The Auditory or Eighth Nerve (portio mollis of the seventh nerve, according to Willis) is the special nerve of hearing, and is distributed to the ear alone. It arises superficially or apparently by two roots, which are situated between the olivary and restiform bodies just posterior, though closely in apposition, to the facial or seventh nerve. On leaving the medulla oblongata the two roots unite, and the nerve then passes, together with the facial, to the bottom of the internal auditory meatus. Here it terminates by separating into superior and inferior divisions.

The Superior Division breaks up into three branches, which pass to the utricle, and ampullæ of the superior and external semicircular canals of the ear.

The Inferior Division is chiefly distributed to the cochlea, though it also supplies the saccule and posterior semicircular canal.

The Nerve of Wrisberg is situated between the auditory and facial nerves from their origin to the termination of the auditory nerve. Some of its fibres unite with those of the auditory nerve, while the nerve itself is connected with the geniculate ganglion of the facial nerve.

Glosso-pharyngeal Nerve.

The Glosso-pharyngeal or Ninth Nerve (the first and smallest trunk of the eighth pair, according to Willis) (Fig. 150) is the sensory nerve of the mucous membrane of the pharynx, the posterior third of the tongue, and the middle ear. It is also the nerve which controls the motions of the stylo-pharyngeal muscle. It communicates through the otic ganglion with the inferior maxillary division of the fifth nerve, the facial and pneumogastric nerves, and the sympathetic system. Its superficial or apparent origin is from the upper or anterior surface of the medulla oblongata, in the groove between the olivary and restiform bodies, and between the pneumogastric and auditory nerves. It arises by four or five filaments, which are collected into two bundles, the anterior being the larger. It passes from its origin outward and forward beneath the anterior portion of the flocculus, and makes its exit from the brain-case through the middle compartment of the posterior lacerated foramen in company with the pneumogastric and spinal accessory nerves. It has a separate sheath of its own, however, formed from the dura mater. Within the foramen the nerve assumes the form of a slender rounded cord, and passes through in a groove which is occasionally transformed into a canal, the most anterior of the three nerves. While in this groove or canal the nerve is characterized by two enlargements, the superficial being the jugular, and the inferior the petrous ganglion. From the posterior lacerated foramen the nerve passes forward between the inter-

nal jugular vein and internal carotid artery, crosses over the artery to its anterior aspect, and descends behind the styloid process and the stylo-pharyngeus muscle. It then curves gradually forward over the lower portion of this muscle and beneath the hyo-glossus, and reaches the base of the tongue.

The Superficial or Jugular Ganglion (ganglion of Ehrenritter) is situated in the upper portion of the posterior lacerated foramen to the outer side of the nerve, only the portion of the nerve in juxtaposition being involved in the ganglion, the other portions passing down to join below with the fibres that have emerged from the ganglion. It is from a half to one line in length, and sends a filament of communication to the superior cervical ganglion.

FIG. 150.

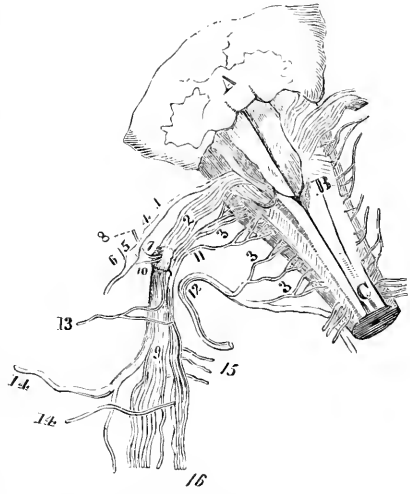

Diagram (from Bendz) of the Ganglia and Communications of the Divisions of the Ninth, Tenth, and Eleventh Pairs: *A*, cerebellum; *B*, medulla oblongata; *C*, spinal cord; 1, root of glosso-pharyngeal nerve; 2, roots of vagus; 3, roots of spinal accessory; 4, jugular ganglion; 5, petrous ganglion; 6, tympanic arch; 7, ganglion of the root of the vagus; 8, auricular branch; 9, ganglion of the trunk of vagus; 10, branch from the last to the petrous ganglion; 11, inner portion of spinal accessory; 12, outer portion of the same; 13, pharyngeal branch of vagus; 14, upper laryngeal branch; 15, branches to the sympathetic; 16, fasciculus of spinal accessory prolonged with vagus.

The Inferior or Petrous Ganglion (ganglion of Andersch) is larger and more important than the jugular ganglion, and is constant in its existence. It is about three lines in length, and involves all the fibres of the nerve. It is situated in a depression near the lower margin of the petrous portion of the temporal bone, and communicates by branches with the auricular branch of the pneumogastric nerve, with the ganglion at the root of the pneumogastric, though this branch is not constant, and frequently the nerve below the ganglion sends communicating branches to the facial nerve.

A TABLE OF THE BRANCHES OF THE GLOSSO-PHARYNGEAL NERVE, AND THEIR DISTRIBUTION.

GLOSSO-PHARYNGEAL (NINTH CRANIAL) NERVE.

1. Tympanic branch, or Jacobson's nerve,
   - Communicating filaments to
     - Large petrosal nerve.
     - Carotid plexus.
     - Small petrosal nerve.
   - Branches of distribution to
     - Fenestra ovalis.
     - Fenestra rotunda.
     - Eustachian tube.
2. Carotid.
3. Pharyngeal branches (help to form the pharyngeal plexus).
4. Muscular branches (to muscles of the pharynx).
5. Tonsillar branches (help to form the tonsillar plexus).
6. Lingual branches.

The Tympanic Nerve (nerve of Jacobson) (Fig. 151) is a long, slender filament which arises from the petrous ganglion of the glosso-pharyngeal, and passes into a canal, the opening to which is situated on the ridge

between the posterior lacerated foramen and the entrance to the carotid canal. From this point it ascends through the canal to the inner wall of the tympanum, thence along a groove on the surface of the promontory, and leaves the middle ear at its superior and anterior portion. It then becomes the superficial petrosal nerve, and passes through a small canal under the tensor tympani muscle. This canal terminates in one of the small openings external to the hiatus Fallopii. The nerve from this point extends downward through the petro-sphenoidal fissure or a small foramen in the great wing of the sphenoid bone, and terminates in the otic ganglion.

Fig. 151.

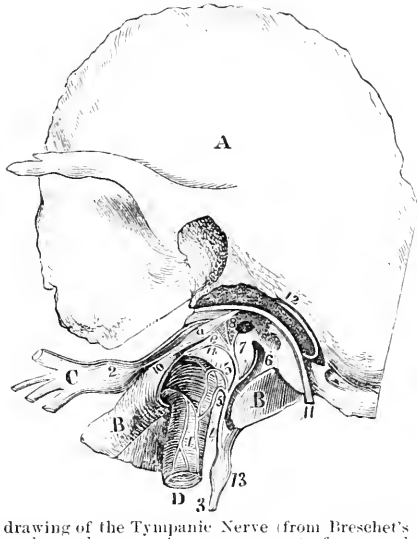

A drawing of the Tympanic Nerve (from Breschet's work on the ear): A, squamous part of temporal bone; B, petrous portion of same; C, lower maxillary nerve; D, internal carotid artery; *a*, tensor tympani muscle; 1, carotid plexus; 2, otic ganglion; 3, glosso-pharyngeal nerve; 4, tympanic nerve; 5, branches to carotid plexus; 6, branch to fenestra rotunda; 7, branch to fenestra ovalis; 8, branch to join the large superficial petrosal nerve; 9, small superficial petrosal nerve; 10, nerve to tensor tympani muscle; 11, facial nerve; 12, chorda tympani; 13, petrous ganglion of the glosso-pharyngeal; 14, branch to the membrane lining the Eustachian tube.

Its branches of communication are two in number—one with the carotid sympathetic plexus, and the other with the tympanic plexus. After the nerve assumes the name of the small superficial petrosal it is joined by a filament either from the geniculate ganglion of the facial nerve or by the large superficial petrosal nerve from the facial.

Its branches of distribution are to the tympanic plexus, the fenestra rotunda, fenestra ovalis, the promontory, and the mucous membrane of the tympanum and Eustachian tube.

The pharyngeal branches (carotid branches, Henle) are three or four in number, the largest of which passes along the internal carotid artery to communicate with the pharyngeal branch of the pneumogastric nerve and the sympathetic system, and form the pharyngeal plexus. This plexus supplies the superior and middle constrictor muscles and mucous membrane of the pharynx.

The Muscular Branches supply principally the stylo-pharyngeus muscle, though filaments pass to the mucous membrane of the pharynx, and occasionally to the borders of the base of the tongue. They may communicate with the facial nerve (Rudinger).

The Tonsillar Branches are slender filaments which pass to the mucous membrane of the lower portion of the tonsillar space, where they form a plexus (circulus tonsillaris). From this plexus branches extend to supply the mucous membrane covering the tonsils, the palatal folds, soft palate, and the palato-glossus muscle.

The Lingual or Terminal Branches are two in number. The larger

one passes to the upper portion of the posterior third of the tongue, and breaks up into numerous branches which supply the circumvallate papillæ and mucous membrane over this region, extending back as far as the anterior surface of the epiglottis. The smaller branch extends forward to the posterior half of the side of the tongue and interlaces with the lingual nerve. It supplies the mucous membrane of this portion of the tongue.

Pneumogastric Nerve.

The pneumogastric or tenth nerve (nervus vagus, par vagum, or second trunk of eighth nerve, according to Willis) (Fig. 152) at its origin is purely a sensory nerve, but through its communication with at least five motor nerves it takes on motor functions, and distributes both sensory and motor filaments to different organs and tissues. It is the most widely distributed of all the cranial nerves, having more communicating branches. Its general distribution is to the pharynx, œsophagus, stomach, and alimentary canal, the larynx, trachea, heart, and blood-vessels. It is thus intimately connected with the digestive, respiratory, and circulatory systems.

Its superficial or apparent origin is from the anterior surface of the upper portion of the medulla oblongata, between the olivary and restiform bodies, and also immediately between the glosso-pharyngeal and the spinal accessory nerves. It is made up of from fifteen to twenty filaments, which unite and form a flattened band. It passes transversely outward across the flocculus to the middle compartment of the posterior lacerated foramen, through which it makes its exit from the brain-case. It is enclosed with the spinal accessory nerve in a single sheath made up of dura mater and arachnoid membrane, and is separated from the glosso-pharyngeal nerve by fibrous and occasionally by osseous tissue.

The ganglia of the pneumogastric nerve are two in number, jugular and cervical.

The Jugular or Superior Ganglion (ganglion of the root) is situated within the posterior lacerated foramen. It is grayish in color, oval or nearly spherical in shape, about two lines in diameter, and embraces all the fibres of the nerve. It has branches communicating with the facial nerve while the latter is in the aqueductus Fallopii, and with filaments from the glosso-pharyngeal nerve and from the nerve of Arnold—with the petrous ganglion of the glosso-pharyngeal, the spinal accessory nerve, and the sympathetic system.

The Cervical or Inferior Ganglion (ganglion of the trunk or plexiform ganglion) is situated upon the pneumogastric nerve a little below the base of the skull, a half inch beneath the superior ganglion. It is of a reddish-gray color, loose or plexiform in texture, and contains gray fibres and nerve-cells interspersed between its white fibres. It is flattened and cylindrical in shape, and measures from six to ten lines in length and two lines in width. Its communication with other nerves is complicated, all of its fibres not passing through to become involved in their functions. Its branches of communication are—

1. *The Accessory Portion of the Spinal Accessory.*—This is the most

FIG. 152.

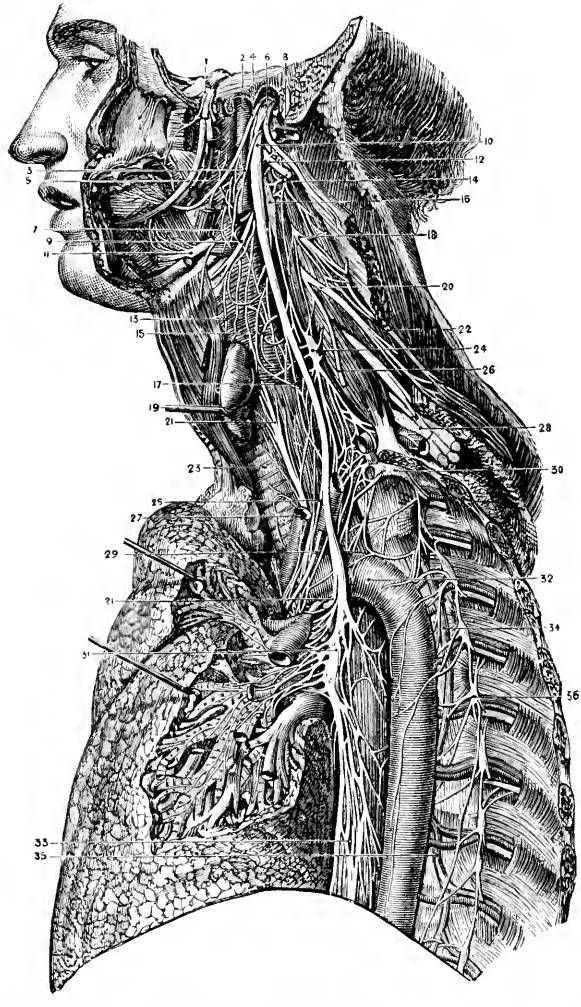

Distribution of the Ninth, Tenth, and Eleventh Pairs of Nerves on the Left Side: 1, Gasserian ganglion of fifth nerve; 2, internal carotid artery; 3, pharyngeal branch of pneumogastric; 4, glossopharyngeal nerve; 5, lingual nerve (fifth); 6, spinal accessory nerve; 7, middle constrictor of pharynx; 8, internal jugular vein (cut); 9, superior laryngeal nerve; 10, ganglion of trunk of pneumogastric nerve; 11, hypoglossal nerve (cut) on hyo-glossus muscle; 12, ditto (cut), communicating with eighth and first cervical nerve; 13, external laryngeal nerve; 14, second cervical nerve, looping with first; 15, pharyngeal plexus on inferior constrictor; 16, superior cervical ganglion of sympathetic; 17, superior cardiac nerve of pneumogastric; 18, third cervical nerve; 19, thyroid body; 20, fourth cervical nerve; 21, 21, left recurrent laryngeal nerve; 22, spinal accessory communicating with cervical nerves; 23, trachea; 24, middle cervical ganglion of sympathetic; 25, middle cardiac nerve of pneumogastric; 26, phrenic nerve (cut); 27, left carotid artery (cut); 28, brachial plexus; 29, phrenic nerve (cut); 30, inferior cervical ganglion of sympathetic; 31, pulmonary plexus of pneumogastric; 32, [arch of the] thoracic aorta; 33, œsophageal plexus; 34, vena azygos superior; 35, vena azygos minor; 36, gangliated cord of sympathetic.

important branch, and passes over the surface of the ganglion, many of its fibres becoming involved in the pharyngeal and laryngeal branches of the pneumogastric nerve, the remainder uniting with the main trunk and passing to the cardiac and inferior laryngeal nerves.

2. With the hypoglossal nerve, by two or three filaments.

3. Generally with the arcade formed by the anterior branches of the first and second cervical nerves.

4. With the sympathetic system through branches from the superior cervical ganglion. (Fibres from this ganglion extend to join the main trunk as it passes downward.)

The pneumogastric nerve passes from its inferior ganglion vertically down the neck upon the outer wall of the pharynx, behind the internal jugular vein and internal carotid artery above and the common carotid below, the nerve, vein, and artery being enclosed in a common sheath. On passing from the neck into the thorax the right and left nerves do not follow a similar course or bear the same relations with the tissue with which they come in contact.

The Right Pneumogastric Nerve enters the thorax between the subclavian vein and the first portion of the subclavian artery. It then passes between the right innominate vein and the innominate artery, then behind the arch of the aorta in a groove between the trachea and the œsophagus to the root of the lung, where it becomes somewhat flattened and gives off numerous branches, which are joined by similar branches from its fellow of the opposite side. These branches together form the right posterior pulmonary plexus. The nerve is then continued downward by two cords to the posterior surface of the œsophagus, where it subdivides and communicates with similar subdivisions from the corresponding nerve of the left side forming the œsophageal plexus. From this plexus the nerve, after receiving fibres from the left pneumogastric, is formed into a single cord, and passes down the neck in close apposition with the posterior surface of the œsophagus, through the diaphragm, and reaches the posterior surface of the stomach, where it spreads out and distributes branches to the liver and the solar plexus.

The Left Pneumogastric Nerve enters the thorax between the left common carotid and subclavian arteries, crosses the inner surface of the innominate vein, and passes down in front of the descending portion of the arch of the aorta. It will thus be seen that it holds a more anterior position in the thorax than the nerve of the right side. From the arch of the aorta it passes behind the root of the left lung, spreads out to receive branches from the right nerve, and forms the left posterior pulmonary plexus. From this plexus it descends in close apposition to the anterior surface of the œsophagus, giving off branches to form the œsophageal plexus. It then passes as a single trunk in front of the œsophagus, through the diaphragm to the anterior surface of the stomach, to which it is distributed. It sends branches to the spleen, pancreas, liver, and small intestines.

The following tabulated arrangement of the branches of the pneumogastric nerve is taken from Prof. Allen's *Anatomy:*

Encranial,	Auricular.	
	Meningeal.	
Excranial,	Anastomotic,	With the spinal accessory nerve.
		With the glosso-pharyngeal nerve.
		With the hypoglossal nerve.
		With the sympathetic nerve.

Excranial (*cont.*)	Pharyngeal and laryngeal,	Pharyngeal.
		Superior laryngeal.
		Inferior laryngeal.
	Thoracic,	Thoracico-cardiac.
		Pulmonary.
		Œsophageal.
	Abdominal,	Hepatic.
		Gastric.
		Intestinal.

The Auricular Branch (auricularis vagi nerve of Arnold) arises from the superior ganglion, or ganglion of the root of the pneumogastric nerve, situated within the posterior lacerated foramen, and immediately receives a communicating filament from the petrous ganglion of the glosso-pharyngeal nerve. It then passes backward behind the bulb of the internal jugular vein, and enters a foramen near the base of the styloid process of the temporal bone, which is situated to the inner side of the aqueduct of Fallopius. Within the canal it forms a communication with the facial nerve, after which it passes through a canal situated close to the internal auditory meatus between the tympanic and mastoid processes of the temporal bone. At that point it emerges from the bone, divides into two branches, the posterior division joining the posterior auricular branch of the facial nerve, while the anterior division is distributed to the integument and cartilage of the back of the ear and the posterior and inferior portion of the auditory canal.

Variations.—In rare instances the auricular branch of the pneumogastric nerve is entirely absent, or it may have no communication with the facial nerve. Occasionally its individuality is lost by uniting with the facial nerve, in which case its fibres are distributed with the posterior auricular branch of the facial.

The Meningeal Branch is quite small, and arises from the anterior border of the superior ganglion of the pneumogastric. It passes upward, and is distributed to the dura mater in the vicinity of the posterior lacerated foramen.

Anastomotic Branches.—The larger number of anastomosing branches of the pneumogastric nerve are distributed to the circulatory, respiratory, and digestive systems. In the jugular foramen small branches are given off to the dura mater and to the ear; in the neck branches are distributed to the pharynx, larynx, and heart; in the thorax branches are supplied to the heart as well as the lungs and œsophagus; in the abdomen its terminal branches are distributed to the stomach, liver, and other organs.

The Pharyngeal Branches (Fig. 153) are the principal motor nerves of the pharynx. They are usually two in number, but there may be more than two; occasionally there is but one. They arise from the superior and inner portion of the inferior or cervical ganglion of the pneumogastric nerve, or, more properly, they are composed of fibres which come from the accessory portion of the spinal accessory nerve, which passes over this portion of the ganglion. They pass downward and inward, generally behind the internal carotid artery, but occasionally in front of it, to the superior border of the middle constrictor muscle of the pharynx, where they divide into numerous branches which interlace

with branches from the glosso-pharyngeal, superior laryngeal, and the sympathetic system, through the superior cervical ganglion, to form the pharyngeal plexus. This plexus is extremely important, and is situated on the lateral surface of the middle constrictor muscle. It usually contains one or more ganglia. Branches are distributed from this plexus to the muscles and mucous membrane of the pharynx. It also gives off the lingual branch of the vagus nerve (Luschka). They receive branches from the glosso-pharyngeal and pneumogastric nerves, pass downward, and join the hypoglossal nerve where that nerve curves around the occipital artery.

FIG. 153.

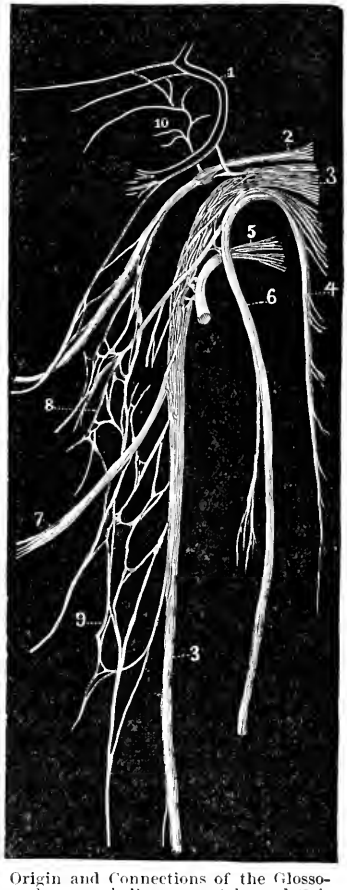

Origin and Connections of the Glosso-pharyngeal, Pneumogastric, and Spinal Accessory Nerves: 1, facial nerve; 2, glosso-pharyngeal; 3, pneumogastric; 4, spinal accessory; 5, hypoglossal; 6, external (muscular) branch of the spinal accessory; 7, superior laryngeal branch of the pneumogastric; 8, pharyngeal plexus; 9, laryngeal plexus and upper cardiac branches of the pneumogastric; 10, tympanic plexus, from a branch of the glosso-pharyngeal.

The Superior Laryngeal Branch arises as a rounded cord from the middle and inner side of the inferior ganglion or ganglion of the trunk of the pneumogastric nerve, or "from the side opposite to the point of junction of the pneumogastric with communicating branches of the spinal accessory, so that probably the superior laryngeal nerve contains few if any motor fibres from this nerve" (Flint). Quain, in describing the lower ganglion, says: "The accessory part of the spinal accessory nerve runs over the surface of the ganglion, and is in a great measure continued directly into the pharyngeal and superior laryngeal nerves."

The superior pharyngeal nerve is the important sensory nerve of the larynx, especially in the region of the glottis. It acts as the sentinel to the opening of the air-passage to guard against foreign matter, such as food, solid or liquid, from entering during deglutition. It is also motor in its function, and distributes motor filaments to the crico-thyroid muscle, as well as small filaments to the inferior constrictor and arytenoid muscles. It passes downward and inward behind both the internal and external carotid arteries, thence along the superior margin of the inferior constrictor muscle of the pharynx, where it divides into two branches, external and internal. Previous to its division it receives filaments from the upper cervical sympathetic ganglion and from the pharyngeal plexus.

The External Laryngeal Branch is smaller but longer than the superior laryngeal. It passes downward and forward under the depressor

of the hyoid bone, and is distributed to the crico-thyroid muscle. It also sends branches to the inferior constrictor of the pharynx and the arytenoid muscles. It receives communicating filaments from the upper cervical sympathetic ganglion, and interlaces with branches from the inferior laryngeal nerve. It also sends communicating or cardiac branches to the cardiac plexus. Occasionally communicating branches from this nerve pass to the pharyngeal plexus, distributing branches to the thyroid body, the mucous membrane of the true vocal cords, and the depressor muscles of the hyoid bone.

The Internal Laryngeal Branch is shorter though thicker than the external laryngeal. It passes forward along the thyro-hyoid membrane to the median line of the neck, pierces that membrane in company with the superior thyroid artery, and enters the internal portion of the larynx, being situated beneath the mucous membrane. Here it divides into numerous branches, which are distributed as follows:

1. A branch which passes upward in the aryteno-epiglottic fold to the posterior surface of the epiglottis. Some writers claim that a few filaments of this nerve pass through the epiglottis to its anterior surface.
2. A branch which passes to the base of the tongue as far as the circumvallate papillæ.
3. Several small branches which pass downward and supply the mucous membrane of the aryteno-epiglottic fold in the region of the glottis, and as far downward as the false vocal cords and the back of the larynx.
4. There is also a long branch which passes beneath the ala of the thyroid cartilage, and unites with a branch from the recurrent or inferior laryngeal nerve at the lower portion of the larynx.

The Inferior or Recurrent Laryngeal Nerve is the principal motor nerve of the larynx, and supplies all its intrinsic muscles excepting the crico-thyroid. The right and left inferior laryngeal nerves differ in their origin and in their relation to the tissues of the neck.

The Right Inferior Laryngeal Nerve arises from the main trunk of the pneumogastric, close to the point where this nerve crosses the right subclavian artery. It curves around the under and posterior surface of this artery, passes obliquely upward and inward behind the common carotid and inferior thyroid arteries, and reaches a groove between the trachea and the œsophagus, ascending in this groove to the level of the crico-thyroid articulation.

The Left Inferior Laryngeal Nerve arises from the main trunk of the pneumogastric as that nerve passes over the left extremity of the transverse portion of the arch of the aorta. It curves around the lower surface of the arch just external to the ductus arteriosus or its remains after birth, when it becomes a ligament. It then passes upward on its posterior surface, and similarly to the nerve of the right side; extends behind the common carotid and inferior thyroid arteries to the groove between the trachea and the œsophagus, terminating on a level with the crico-thyroid articulation, where both nerves break up into branches. Their terminal branches are distributed to all the intrinsic muscles of the larynx excepting the crico-thyroids, these muscles being supplied by the superior laryngeal. It also distributes a few filaments to the

mucous membrane below the rima glottidis. In their passage upward these nerves distribute small branches to the structure and mucous membrane of the trachea and œsophagus and to the inferior constrictor muscle of the pharynx. As the nerves pass beneath the large arteries of the neck they send communicating branches to the inferior cervical sympathetic ganglion and to the cardiac plexus, which is formed by the interlacing of branches from the pneumogastric nerve and sympathetic system. The right inferior laryngeal nerve occasionally sends a filament to the pericardium.

The Cardiac Branches arise as two sets, and receive the name of cervical and thoracic branches.

The Cervical Cardiac Branches are two or three in number (usually three), two of which arise from the main trunk of the pneumogastric in the upper region of the neck, and unite with the cardiac branches of the sympathetic system as they descend. The third branch arises from the pneumogastric nerve just before it enters the thorax. On the right side the nerve passes in front of the brachio-cephalic artery, and unites with the superior cardiac nerve in its passage to the deep cardiac plexus, a few filaments passing to the coats of the aorta. On the left side the nerve passes in front of the arch of the aorta, and unites with the superior cardiac nerve or passes directly to the superficial cardiac plexus.

The Thoracic Cardiac Branches of the right side arise partially from the trunk of the pneumogastric nerve below the origin of the right recurrent laryngeal as the nerve lies close to the trachea, and partially from the recurrent branch of the pneumogastric. They terminate in the deep cardiac plexus. The branches of the left side usually arise from the recurrent or inferior laryngeal nerve and terminate in the superficial cardiac plexus.

The Pulmonary Branches are separated into two sets, anterior and posterior.

The Anterior Pulmonary Branches are the smaller of the two sets, and consist of two or three slender filaments which arise from the pneumogastric nerve below its cardiac branches. A few of these filaments pass to the trachea before they form, together with the sympathetic system of the pulmonary artery, the anterior pulmonary plexus. Fibres from this plexus encircle and pass along the bronchial tubes to their terminations in the air-cells of the lungs.

The Posterior Pulmonary Branches are larger and more numerous than the anterior. They arise from the flattened portion of the pneumogastric nerve behind the root of the lung. They unite with filaments from the second, third, and fourth thoracic sympathetic ganglia to form the posterior pulmonary plexus. From this plexus a few filaments are distributed to the inferior and posterior portion of the trachea, to the muscular tissue and mucous membrane of the central region of the œsophagus, and a few to the posterior superior portion of the pericardium. The principal portions of these branches, however, surround the bronchial tubes, and pass along them to the air-cells of the lungs in the same manner as the branches from the anterior pulmonary plexus. The anterior and posterior pulmonary plexuses of each side give off a large number of communicating branches which pass between each other, so

that filaments from both the right and the left pneumogastric nerve pass to the right and left lungs.

The Œsophageal Branches arise from the pneumogastric nerve, both above and below its pulmonary branches. Those which arise below are the larger and spring from the œsophageal plexus. The nerves from the right and left side interlace quite freely, and are distributed to the muscular tissue and mucous membrane of the lower third of the œsophagus.

The Abdominal or Terminal Branches of the right and left sides differ in their distribution. Those of the left side enter the abdominal cavity upon the anterior surface of the œsophagus, and when opposite the cardiac orifice of the stomach divide into numerous branches. These branches are distributed to the muscular tissue of the walls of the stomach and to the mucous membrane of its anterior portion, lesser curvature, and great cul-de-sac, interlacing with branches of the right nerve and the sympathetic system. There are also branches (hepatic) which pass from the lesser curvature of the stomach, between the folds of the gastro-hepatic omentum, reach the transverse fissure of the liver, to be distributed to the hepatic substance.

The abdominal branches of the right side enter the abdomen on the posterior surface of the œsophagus. On reaching the stomach they break up into branches, some of which are distributed to the muscular tissue and mucous membrane of its posterior portion, interlacing with branches from the left nerves; while others pass to the liver, spleen, kidneys, suprarenal capsules, and to the whole of the small intestine, and communicate with the solar plexus.

Spinal Accessory Nerve.

The spinal accessory or eleventh nerve (the third trunk of the eighth nerve according to the arrangement of Willis) (Fig. 154) is a motor nerve, which is separated into two divisions. The first division controls the action of the sterno-cleido-mastoid and part of the trapezius muscle; the second division, after uniting with the pneumogastric nerve, supplies motor filaments to muscles, and, as was demonstrated by Bischoff in 1832, presides over phonation. This fact was also proved by Bernard.

A TABLE OF THE BRANCHES OF THE SPINAL ACCESSORY NERVE.

The Spinal Accessory or Eleventh Cranial Nerve.	Accessory portion,	Branches to the pharyngeal plexus. " " superior laryngeal nerve. " " recurrent laryngeal nerve (thus supplying the muscles of phonation). Branch to the sterno-mastoid muscle. " " trapezius muscle.
	Spinal portion,	Branch to the sterno-mastoid muscle. " " trapezius muscle. Communicating branches to: First cervical nerve. Second cervical nerve. Third cervical nerve. Fourth cervical nerve.

The name "spinal accessory" was given to this nerve by reason of its relations with the pneumogastric nerve, and also because of its origin,

which is quite extensive and divided into two portions or roots. One root arises from the lower portion of the medulla oblongata, and the other from the cervical portion of the spinal cord.

Fig. 154.

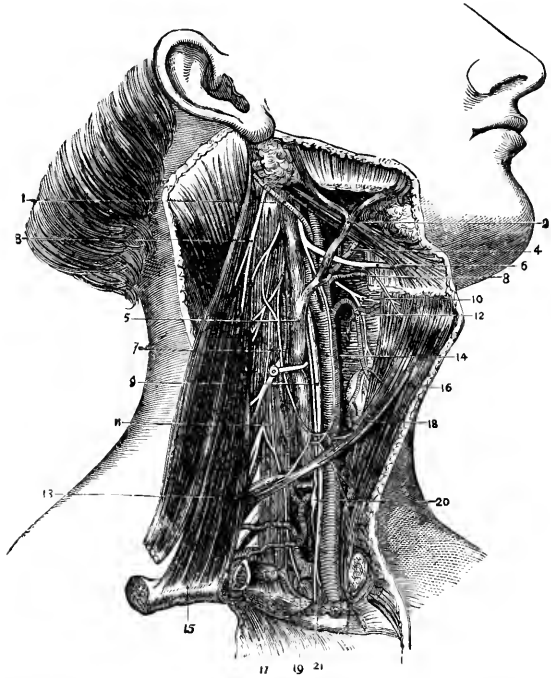

The Side of the Neck: 1, occipital artery; 2, facial vein; 3, spinal accessory nerve; 4, facial artery; 5, internal jugular vein; 6, hypoglossal nerve; 7, communicans noni nerve; 8, lingual artery; 9, pneumogastric nerve; 10, superior laryngeal nerve; 11, phrenic nerve; 12, superior thyroid artery; 13, sterno-cleido-mastoideus (reflected); 14, common carotid artery with descendens noni nerve; 15, inner end of clavicle reflected; 16, sterno-hyoid; 17, subclavian vein (cut); 18, omo-hyoid; 19, subclavian artery giving off the thyroid axis and the internal mammary artery; 20, inferior cervical ganglion of sympathetic; 21, apex of pleura.

The Medullary or Accessory Portion or Root.—The superficial or apparent origin is by four or five delicate filaments situated in the groove between the olivary and restiform bodies on the side next the medulla oblongata, just below the superficial origin of the pneumogastric nerve.

The Cervical Portion or Root arises by six or eight filaments from the lateral tract of the entire length of the cervical portion of the spinal cord, though its superficial origin is not generally distinguishable below the fourth or fifth cervical nerve. The lowest filament is generally single; the others, however, emerge from the cord in pairs. These filaments ascend along the cord, increasing in size as each additional filament is added, and extending between the ligamentum denticulatum and the posterior roots of the spinal nerves. The first and second spinal nerves are often connected to these filaments. After reaching the foramen magnum, through which it enters the brain-case, it curves outward to the middle compartment of the posterior lacerated foramen, in which it joins the medullary root. The two roots then interchange fibres with

each other, and occasionally form a single trunk. In this region the two roots are contained in a single sheath of the dura mater with the pneumogastric nerve. A branch of communication extends between the accessory and medullary portions of the superior ganglion of the pneumogastric nerve.

The cranial portion of the spinal accessory is separated into two divisions, internal and external, which are almost identical in origin with the two roots of the main nerve.

The Internal Medullary or Accessory Portion, which contains nearly all the fibres arising from the medulla, passes over the inferior ganglion of the pneumogastric nerve (ganglion plexiformis), and becomes intimately associated with it. It is distributed through the pneumogastric nerve to the larynx, pharynx, and other structures. (See Pneumogastric Nerve.)

The External or Spinal Portion (muscular branch) is the longer of the two branches, and contains nearly all the filaments which arise from the spinal cord, and may receive all the fibres of the posterior root of the first cervical nerve. It passes from the posterior lacerated foramen downward, backward, and outward in front of the internal jugular vein, but occasionally behind the vein, over the transverse process of the atlas, to the superior third of the sterno-cleido-mastoid muscle. It generally pierces this muscle, though it may pass beneath it and appear in the posterior cervical triangular space beneath the trapezius muscle. It communicates by branches with the medullary portion in the posterior lacerated foramen, with the first cervical nerve, and the superior ganglion of the pneumogastric nerve, while beneath the trapezius muscle it gives off branches which unite with branches from the third, fourth, and fifth cervical nerves which assist in forming the cervical plexus. It also distributes branches to part of the sterno-cleido-mastoid muscle and to the clavicular portion of the trapezius muscle.

Hypoglossal Nerve.

The hypoglossal, twelfth, or sublingual nerve (the ninth nerve according to the arrangement of Willis) (Fig. 152) is the last of the cranial nerves. Its chief function is in connection with the movements of the tongue in deglutition and articulation. It is also distributed to all the muscles which are attached to the hyoid bone. It arises superficially or apparently by twelve or fourteen filaments, which pass from the groove situated between the olivary body and the anterior pyramid of the medulla oblongata. The filaments are collected into two separate bundles, superior and inferior, which are directed outward, pass behind the vertebral artery, and extend toward the anterior condyloid foramen; and as they enter this foramen or foramina[1] they receive a separate sheath from the dura mater, and unite into a single trunk as they emerge from the brain-case and pass into the deep portions of the neck. From this point it extends to the median side of the internal jugular vein and the pneumogastric nerve. It then descends the neck nearly

[1] Occasionally there are two foramina in the occipital bone. When this is the case the bundles pass through separate openings.

in a vertical (slightly forward) direction on the median side of the internal jugular vein, and between it and the internal carotid artery, to a level with the lower margin of the digastric muscle. It here, in the superior carotid triangle of the neck, becomes superficial, and curves around and under the occipital artery near its origin. It then passes forward over the external carotid artery, above the hyoid bone, beneath the tendon of the digastric and the lower portion of the stylo-hyoid, and between the mylo-hyoid and the hyo-glossus muscles, terminating by dividing into branches in the genio-glossus muscle.

TABLE OF THE BRANCHES OF THE HYPOGLOSSAL NERVE.

The Hypoglossal or Twelfth Cranial Nerve.	Branches of communication.	To the ganglion of the trunk of the pneumogastric nerve.
		To the superior cervical ganglion of the sympathetic.
		To the loop between the first and second cervical nerves.
		To the gustatory nerves.
	Branches of distribution.	Descendens noni nerve.
		To thyro-hyoid nerve.
		To genio-hyoid nerve.
		To stylo-glossus muscle.
		To hyo-glossus muscle.
		To genio-hyo-glossus muscle.
		To the intrinsic muscles of the tongue.

The branches of communication of this nerve as tabulated above are—

1. With the pneumogastric nerve, which passes between the inferior ganglion of that nerve and the hypoglossal nerve immediately after it leaves the skull. There is also a communicating branch which passes between these two nerves near to the point where they cross the occipital artery.

2. With the sympathetic system by a filament of considerable size, which passes between the superior cervical ganglion of that system and the hypoglossal nerve.

3. With the first and second cervical nerves, which pass between the loop connecting these two nerves, the spinal nerves, and the hypoglossal nerve together.

4. Two or three branches of communication with the gustatory nerve, which pass between the hypoglossal nerve and the gustatory or lingual branch of the fifth nerve in the region of the anterior border of the hyo-glossus muscle.

The branches of distribution of the hypoglossal nerve are the—

Recurrent,
Descending thyro-hyoid,
Branches to the tongue,
Genio-hyoid.

The Recurrent Branch arises from the hypoglossal nerve within the anterior condyloid foramen. It passes into the brain-case, and is distributed to the dura mater and walls of the vascular sinus close to the foramen magnum. It is also distributed to the diploë of the occipital bone (Luschka).

The Descending or Descendens Noni Branch is a long, slender filament which arises from the hypoglossal nerve as it curves under the occipital artery. From this point it descends the neck, at first in front of the internal carotid artery, either within the common sheath with

the vessel, or upon its outer surface, to a point just above the tendon of the omo-hyoid muscle. In its descent it distributes a small branch to the anterior belly of this muscle. It then divides into two or three branches, and receives one or two communicating branches from the second and third cervical nerves (communicans noni). By this union a plexiform loop is formed, with its concavity upward. This loop occasionally receives another small branch from the cervical nerves. From this plexiform loop branches are distributed to the sterno-hyoid, sterno-thyroid, and omo-hyoid muscles, and sometimes to the cardiac and phrenic nerves within the thorax.

The Thyro-hyoid Branch arises from the hypoglossal nerve in front of the external carotid artery, from which point it descends, and is distributed to the thyro-hyoid muscle.

The Branches to the Tongue are the stylo-glossus, hyo-glossus, and genio-glossus, which are given off from the hypoglossal nerve while it is located between the mylo-hyoid and the hyo-glossus muscles. They are distributed to the muscles indicated by their names, and send branches to other muscles in the substance of the tongue, as well as to the genio-hyoid muscle.

Variations.—Occasionally the right and left hypoglossal nerves communicate by a branch which passes between them in the neighborhood of the genio-hyoid muscle. In rare cases filaments are distributed to the mylo-hyoid muscle (Krause). According to Luschka, E. Bischoff, Holl, and others, the descendens noni nerve does not in reality arise from the hypoglossal nerve, but is derived from the upper cervical nerves, which are temporarily associated with the hypoglossal. Holl states that the branches going to the thyro-hyoid and genio-hyoid muscles are composed of fibres which arise from the spinal nerves.

LYMPHATIC VESSELS OF THE HEAD AND NECK.

By ALBERT P. BRUBAKER, A.M., M.D., D.D.S.

THE LYMPHATICS.

The Lymphatics, and the glands in connection with them, constitute a system of vessels most important to the nutrition of the body. In all the vertebrate animals this system is superadded to the circulatory, and is designed to carry back into the general blood-current the excess of nutritious fluid which has been exuded from the capillary blood-vessels for the purposes of nutrition. The fluid which the lymphatic vessels contain is known as lymph, and resembles in its physical and chemical constitution the liquor sanguinis or blood-plasma.

The lymphatic vessels have a very extensive distribution, being found in nearly all the tissues and organs of the body which receive blood. They are absent, or at least have not yet been discovered, in the hair, nails, epidermis, and other structures usually regarded as non-vascular.

Lymphatics are widely distributed throughout the body, but are more abundant in some situations than in others. The inner surfaces of the limbs are more abundantly supplied than the outer surfaces, while the lines of junction of the limbs with the trunk are especially rich in both vessels and glands. In the thoracic and abdominal cavities they are very numerous. In the majority of situations in which the lymphatics are found they are arranged into a superficial and a deep set, the former being very fine and situated in and beneath the skin and mucous membranes, while the latter are much larger and follow the course of the large blood-vessels.

The lymph, when examined microscopically, is seen to consist of a clear colorless plasma, in which are imbedded an immense number of corpuscular elements. The lymph which has been obtained from man and inferior animals is usually colorless and transparent, although at times it presents a faintly yellowish hue. It is odorless, slightly saline in taste, alkaline in reaction, and possesses in the dog a specific gravity of 1022. Like the blood, lymph undergoes a spontaneous coagulation when withdrawn from the body, although the coagulum is never so firm as in the case of the blood. In its chemical composition lymph also resembles the blood. Analyses made by Lassaigne of the lymph obtained from a cow demonstrated that it contains, in 1000 parts, water, 964; fibrin, 0.9; albumen, 28.0; fatty matter, 0.4; inorganic salts, 6.7.

The corpuscular elements of the lymph, known as lymph-corpuscles or leucocytes, are found floating in the lymph-plasma. When examined

microscopically they resemble in many respects the white corpuscles of the blood, but they are smaller and less uniform in size, varying from $\frac{1}{2500}$ to $\frac{1}{5000}$ inch in diameter. In addition to the lymph-corpuscles there are present in almost every specimen of lymph small granules, regarded by some as free nuclei, which have a gray color and exhibit the Brownian movement. Red corpuscles are also found, particularly in the large lymphatic trunks and in the thoracic duct.

The lymph-corpuscles vary much in size, shape, and general appearance. Some are quite small, spheroidal in shape, and consist of a single nucleus surrounded by a small quantity of protoplasmic matter. Others are larger, and frequently contain several vesicular or spheroidal nuclei which are surrounded by a limiting membrane, while the enveloping mass of protoplasm is quite abundant. Many leucocytes contain collections of granules which are highly refractive and impart to the corpuscle a distinctly granular character. The lymph-corpuscles are made up of a fine network of an albuminous material, in the meshes of which is found a colorless semifluid substance apparently of an albuminous character. There is no cell-wall present in any of the true lymph-corpuscles. They originate either by subdivision of pre-existing cells or are developed within the lymphatic glands.

Origin of Lymphatics.—The mode of origin of the lymphatics has until recent years been involved in the greatest obscurity. But the investigations of Von Recklinghausen, Klein, Ludwig, and many others have gone far toward demonstrating the true origin of these vessels. The following modes of origin are now well known:

1. *Origin in Lymph-spaces or Juice-canals.*—Throughout the connective-tissue system of the body are located numbers of small, irregular, stellate spaces which communicate very freely with each other. These are the so-called juice-canals of Von Recklinghausen, and are supposed to represent the ultimate radicles of the lymphatic vessels. They vary considerably in size, and their shapes are determined by the nature of the tissues in which they are placed. They do not possess an endothelial lining, but contain one or more connective-tissue corpuscles which exhibit characteristic amœboid movements. As these spaces communicate very freely with each other, the movement of the lymph through them and around the islets of tissue readily takes place.

The lymph-spaces communicate directly with the *lymph-capillaries*, as was also demonstrated by Von Recklinghausen. The lymph-capillaries constitute a plexus of fine vessels which give rise to the smallest lymphatic trunks; they vary in shape according to the tissue in which they are found, and also in size, but are always larger than the capillary blood-vessels. Their walls are formed by a lining of simple endothelial cells with characteristic sinuous margins.

2. *Origin in Openings on the Surface of Serous Membranes.*—The large serous cavities, such as the peritoneal, pleural, pericardial, subarachnoid, etc., have been shown by Klein, Von Recklinghausen, and many others to communicate with the lymphatic vessels. Their mode of origin can best be studied upon the peritoneal surface of the central tendon of the diaphragm. This surface is covered with a layer of endothelial cells, whose sinuous margins can be readily exhibited by

staining the surface with a solution of nitrate of silver. At intervals between these cells are found large free openings which have received the name of *stomata*. These openings communicate by means of short canals with the lymph-capillaries that are found among the fibrous tissue of which the diaphragm is composed. Upon the pleural surface similar openings have also been demonstrated. The serous cavities of the body may therefore be regarded as true lymph-spaces, which communicate primarily with the lymph-capillaries, and secondarily with the lymphatic trunks. Stomata in all respects similar to those found on serous membranes have been shown to be present on the surfaces of mucous membranes, which in all probability are directly connected with the lymph-capillaries.

3. *Origin in Perivascular Lymph-spaces.*—Within the substance of the brain, spinal cord, bone, and other tissues His and Robin have shown that the capillary blood-vessels are surrounded by a lymph-space bounded and limited by a cylindrical sheath formed of endothelial cells, which is in frequent communication with the lymph-capillaries. The blood-vessel thus floats in the lymph-stream. In addition, the tunics of the large blood-vessels, both the intima and adventitia, are traversed by lymph-channels which open very freely into each other. This arrangement of the blood-vessels permits of a free interchange by osmosis of the fluid portion of both blood and lymph.

Structure of Lymphatic Vessels.—The lymphatic trunks have their origin in the fine plexus of lymph-capillaries previously described. In their course toward the centre of the body they pursue generally a direct route. They anastomose by bifurcation very freely with neighboring vessels, pass through the lymphatic glands, and vary but little in size from origin to termination. Their walls are so exceedingly transparent and delicate that when empty it is with difficulty they can be seen. Their diameter varies from $\frac{1}{25}$ to $\frac{1}{12}$ inch. After the lymphatic trunks have emerged from the lymph-capillaries they acquire three distinct coats, which resemble in their structure and arrangement the coats of the veins.

The internal coat is delicate and elastic, and is composed of a layer of longitudinal elastic fibres covered with a layer of flattened nucleated endothelial cells with wavy or sinuous margins. The middle coat consists of white fibrous tissue, which is arranged longitudinally, and of unstriped muscular and elastic fibres, which are disposed transversely. The external coat is composed of identically the same structures, but the muscular fibres pursue rather a longitudinal than a transverse direction. These three coats are known respectively as the tunica intima, tunica media, and tunica adventitia. The walls of the lymphatic trunks are abundantly supplied with blood-vessels (*vasa vasorum*), and it is highly probable that they are also supplied with nerves (*nervi vasorum*), though the latter have not been indisputably demonstrated. On physiological grounds their existence might be inferred.

Valves.—The lymphatics generally are provided with valves, which have the same structure and fulfil the same function as the valves with which the veins are furnished. These valves are very numerous, and are located at such short intervals along the course of the vessel as to give

rise to a beaded appearance. They are not farther apart than $\frac{1}{12}$ to $\frac{1}{8}$ inch. The superficial vessels are most abundantly supplied with valves, those of the arm containing from sixty to eighty between the fingers and axillary glands, while the corresponding vessels of the lower limbs contain from eighty to one hundred. The valves are generally arranged in pairs, and consist of two semilunar folds, with their concavities directed toward the larger vessels. They are formed by a reduplication of the lining membrane, the two folds being strengthened by fibrous tissue from the middle coat.

Lymphatic Glands.—The lymphatic glands are small lenticular bodies placed along the course of the lymphatic vessels as they pass from their points of origin toward the thoracic duct. They are exceedingly numerous, the total number being estimated at from five to seven hundred. They vary considerably in size, some not being larger than a pin's head, while others attain a size equal to that of a kidney bean. As the lymphatic glands are in connection with the vessels, they may, like them, be divided into a superficial and a deep set; the former are most abundant around the head and neck and at the lines of union of the limbs with the body; the latter are found most abundantly in the thorax and abdomen along the course of the deep-seated vessels. The glands situated between the folds of the mesentery are known as the mesenteric glands. The lymphatic vessels as they approach a gland break up, before entering it, into a number of small branches—the *vasa afferentia*, which penetrate its investing membrane. From the opposite side of the gland the lymphatics again emerge, as the *vasa efferentia*, and a short distance beyond it unite to form trunks larger, but fewer in number.

The lymphatic glands present at one point a depression which is termed the hilum, through which the blood-vessels pass into and out of the gland, and through which also emerge the efferent vessels. Except at the hilum the gland is entirely covered externally by a membrane composed of dense connective tissue. The interior of the gland is soft and pulpy, of a dark color, and mottled in appearance. The superficial part of the gland is termed the *cortical*, the deeper part the *medullary* portion (Fig. 155).

FIG. 155.

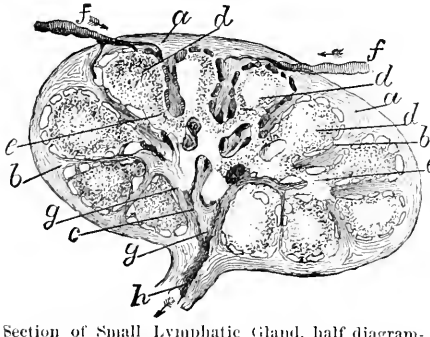

Section of Small Lymphatic Gland, half diagrammatically given, with the course of the lymph: *a*, the envelope; *b*, septa between the follicles or alveoli of the cortical part; *c*, system of septa of the medullary portion down to the hilum; *d*, the follicles; *e*, lymph-cords of the medullary mass; *f*, afferent lymph-vessels, the different lymphatic streams from which surround the follicles and flow through the interstices of the medullary portion; *g*, confluence of these to pass through the efferent vessel (*h*) at the hilum.

From the inner surface of the investing membrane there pass inward partitions or septa of lamellated connective tissue which divide the outer zone of the gland into small compartments, which are conical in shape in consequence of the convergence of the partitions toward the centre of the gland. These

spaces or alveoli are from $\frac{1}{60}$ to $\frac{1}{24}$ inch in diameter, and are connected with each other through openings in the septa. When the septa reach the medullary portion they subdivide and form bands or cords which interlace in every direction and constitute a loose meshwork, the spaces of which communicate with each other and with the alveoli. Within the meshes of the gland is contained the proper gland-substance. In the conical compartments it is moulded into a pear-shaped mass, while in the medullary part it assumes the form of rounded cords, which, like the trabecular meshes, are connected with each other. In both the cortical and medullary regions, however, there is a clear space between the gland-pulp and the trabeculæ, which is termed the *lymph-sinus*, through which the lymph flows as it passes through the gland. This lymph-sinus is crossed by a fine network of retiform connective tissue in which the nuclei of the endothelial plates covering it are distinctly seen (Fig. 156). This reticulation offers considerable resistance to the flow of lymph through it. The glandular substance itself consists of essentially the same elements. It is supported by a framework of retiform tissue, in the meshes of which are found immense numbers of lymph-corpuscles. The glandular substance is separated from the lymph-sinus by a denser layer of reticulum, although it is not so compact as to prevent the lymph, and even the corpuscles, from passing out into the lymph-sinus. The lymphatic glands are abundantly supplied with blood-vessels. Arteries enter the gland at the hilum, penetrate into the medullary substance, and terminate in a fine capillary plexus, which is surrounded and supported by the retiform tissue. The veins arising from this plexus leave the gland also at the hilum.

FIG. 156.

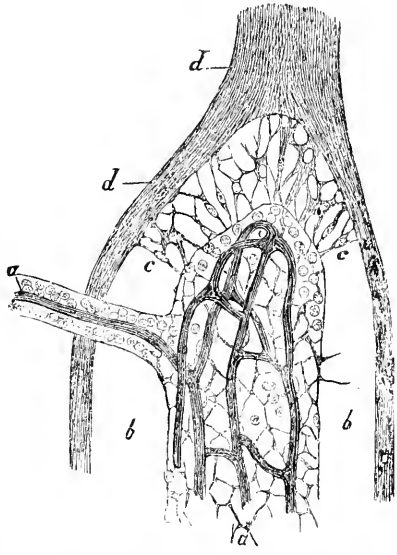

Portion of the Medullary Substance of the Mesenteric Gland of an Ox, the artery injected with chromate of lead (highly magnified): *a*, medullary cylinder with capillary network, fine reticulum of connective tissue, and a few lymph-corpuscles; *b*, *b*, superficial lymph-path or medullary sinus traversed everywhere by a reticulum of nucleated cells; this reticulum has been represented only at *c*, with numerous anastomosing prolongations; the lymph-corpuscles have for the most part been removed with a camel's hair brush; *d*, *d*, trabeculæ composed almost exclusively of unstriped muscular tissue. A small medullary cord or bridge, containing a blood-vessel and numerous lymph-corpuscles, is shown at the left of the figure as springing from the medullary cylinder.

The lymphatic vessels which enter a gland ramify in the investing membrane, and then open directly into the lymph-sinus. The efferent vessels begin by fine branches, which also communicate directly with the lymph-sinus. When the lymphatic vessels enter a gland they lose their external and middle coats, and retain only the endothelial, which lines the inner surface of the lymph-sinus. The current of lymph, therefore, can pass directly from the afferent vessel through the lymph-sinus into the effer-

ent vessel. In addition to this primary current there is a secondary current always flowing from the capillary blood-vessels outward into the lymph-sinus which carries with it immense numbers of lymph-corpuscles, which enter the efferent lymphatic vessels.

The thoracic duct is the general trunk of the lymphatic system, into which most of the lymphatic vessels of the body empty. It is from eighteen to twenty inches in length, extending from the root of the neck downward to the second lumbar vertebra. It measures in diameter about one-eighth of an inch, though at its inferior extremity, where it expands into the receptaculum chyli, it is somewhat wider. Its walls have the same general structure as the walls of the lymphatic vessels, consisting of three coats—an internal, or endothelial; a middle, elastic and muscular; and an external, or fibrous. The inner surface of the duct is abundantly supplied with valves. This general duct empties into the venous circulation at the junction of the left internal jugular and subclavian veins.

Lymphatic Vessels of the Head and Neck.

The lymphatic glands and vessels of the head and neck may be divided into a superficial and a deep set. The superficial set may again be subdivided, according to their location, into—

1. *A Facial Group*, consisting of two or three small glands situated in front of the ear at the root of the zygoma and upon the outer aspect of the parotid gland. A small gland is occasionally found near the side of the root of the nose, though the rest of the facial region is singularly free of glands, none being found above the line of the mouth (Fig. 157).

2. *A Post-aural Group*, consisting of three or four glands situated slightly above the insertion of the sterno-cleido-mastoid muscle, and one other at the base of the occipital bone.

3. *A Submaxillary Group*, from eight to ten in number, situated beneath the base of the inferior maxillary bone. The largest of this group is in close relationship with the outer surface of the submaxillary salivary gland. This group lies quite superficially, being only covered in by the skin and superficial fascia.

4. *A Cervical Group*, more numerous than the preceding, which is arranged along the course of the external jugular vein. At the inferior boundary of the neck these glands are found in greatest number, especially in the space behind the insertion of the clavicular portion of the sterno-cleido-mastoid muscle. At this point they penetrate the deeper region of the chest and become connected with the axillary glands.

The deep glands may also be divided, according to their location, into—

1. *A Facial Group*, from six to eight in number, situated in the spheno-maxillary space and alongside of the pharyngeal wall.

2. *A Cervical Group*, located along the course of the carotid artery and jugular vein, and extending from the upper limit of the neck downward as far as the thorax.

The lymphatic vessels of the head and neck may be divided into a

superficial and a deep set. The superficial may be subdivided, according to their location, into—

1. *A Facial Group*, which arises from the central part of the forehead and descends obliquely along the course of the facial vein, and enters the submaxillary glands.

FIG. 157.

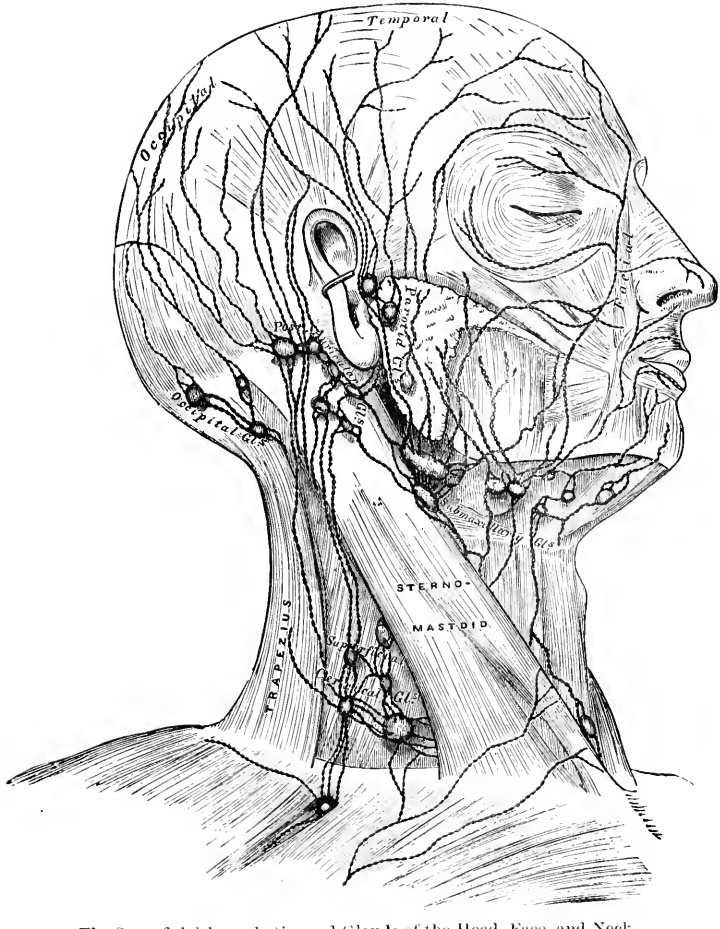

The Superficial Lymphatics and Glands of the Head, Face, and Neck.

2. *A Cranial Group*, which consists of a temporal and an occipital set. The former, arising from the superior portion of the cranium, descends in front of the auricle, passes through the facial glands, and finally terminates in the glands of the neck; the latter, receiving the lymph from the occipital region of the cranium, converges and descends along the course of the occipital artery, and enters the post-aural glands on the mastoid process, and subsequently joins the lymphatics of the neck (Fig. 158).

The *deep facial* group of lymphatics has its origin in the temporal fossa, the orbital and nasal cavities, and the mouth. Some of the lymphatic vessels of the brain-case emerge through the oval and spinous foramina in the sphenoid bone and join this series of lymphatics. All of the vessels constituting this series then pass outward along the course of the internal maxillary vein, and enter the glands in the neighborhood of the angle of the inferior maxillary bone.

FIG. 158.

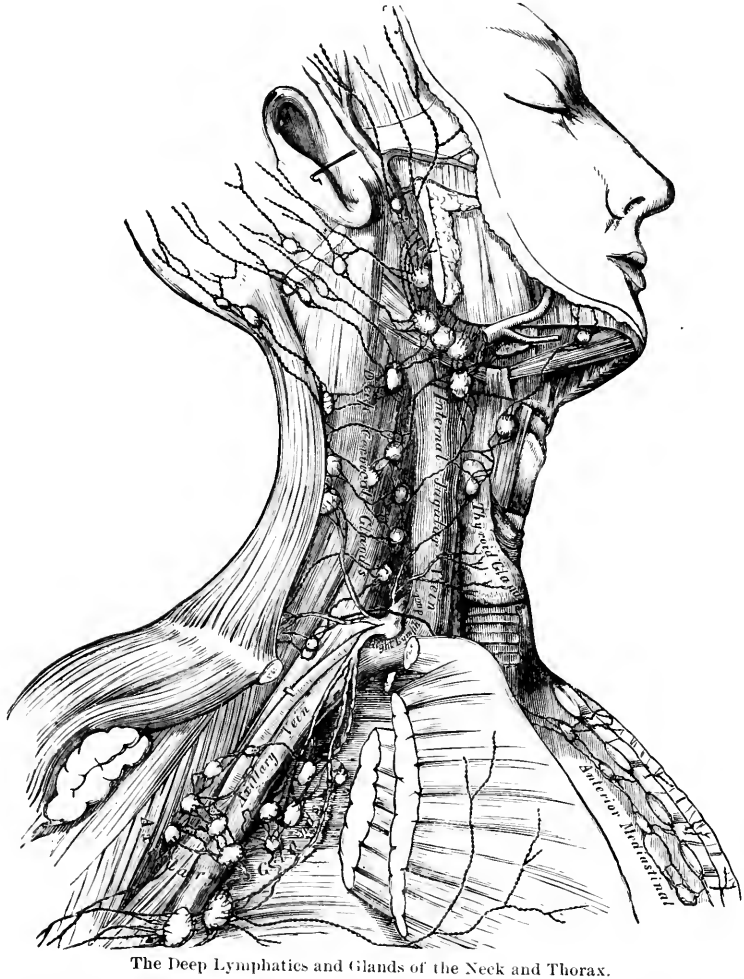

The Deep Lymphatics and Glands of the Neck and Thorax.

The *deep cranial* group of lymphatics contains those vessels which come from the brain-case, the pia mater, and the arachnoid through the foramen lacerum posterius.

The superficial and deep lymphatics of the neck, formed by the union of the facial and cranial vessels, also receive branches from the tongue, pharynx, larynx, thyroid body, and other regions of the neck. They

descend the neck and follow the course of the veins and carotid artery. At the same time they progressively decrease in numbers. Those on the right side empty by a short trunk into the right lymphatic duct, which enters the venous circulation at the junction of the right internal jugular and subclavian veins. Those on the left side enter the main thoracic duct.

PART II.

DENTAL ANATOMY.

TEETH OF THE INVERTEBRATES.

TEETH OF THE VERTEBRATES.

THE TEETH OF INVERTEBRATES.

By W. H. DALL.

Almost every large group of organisms below the vertebrates, until we reach the Molluscoidea and lower radiated animals, exhibits in some of its members one form or another of prehensile or masticatory apparatus connected with the alimentary canal. None of these exhibit true homologies with vertebrate teeth, though sometimes presenting remarkable similarity to the latter in external form. Before considering these organs in detail it is desirable to formulate some appropriate definition which shall distinguish between mandibular and dental appendages in the sense in which the latter may be said to exist in the invertebrates.

For our purposes we shall consider as teeth only such appendages as spring from the interior of the oral orifice; are differentiated by their chemical constitution and mechanical attachments from the surrounding tissues; perform their functions in a vertical plane as distinguished from a lateral or horizontal one; and are opposed either to similar teeth, to a superior mandible, or to the roof of the oral cavity.

This excludes the modified limbs which form the paired and laterally opposed oral appendages of insects and crustacea, and a great variety of other appendages which are more naturally classed as jaws, mandibles, fangs, or stomacholiths. While not homologous, many of these present such striking similarity of form with vertebrate oral appendages that the same vernacular name seems more appropriate than a new designation. No one would hesitate to call the mandibles of a parrot or hawk and those of the cuttlefish by the same name, even if they were not aware that they are put to an identical use.

Throughout the invertebrates teeth are dermal structures, however much special modifications may mask their relations. They may consist of calcified connective tissue, of horny matter, or of chitin or an allied substance. Chitin and substances with very similar qualities are almost characteristic products of invertebrate organization. Of them are formed the wing-cases of beetles and most of the hard elastic tissues of the exterior of insects. A chitinoid substance is insoluble in boiling liquor potassæ, and hardly affected by immersion in the strongest acids. Its lightness, elasticity, and strength fit it remarkably for the work required of the insect exoskeleton and similar uses. The teeth and jaws of mollusks, the nippers, mandibles, and setæ of worms, and many similar invertebrate organs, are composed to a greater or less extent of chitinoid material. This aids materially in the preparation of these structures for microscopical examination and study. By heat-

ing in potash solution they can be freed with little trouble from adherent muscles or other organic material. Chitinous substances are, however, rather difficult to stain, and in time, unless naturally colored, become in Canada balsam almost transparent. The student who may wish to preserve an interesting specimen in a permanent mount for the microscope should bear this in mind, and, if necessary, use some other medium. Part of the difficulty about staining may be met by mounting in a tinted medium, which will then contrast with the object itself. With regard to the teeth and jaws of mollusks, special details will be mentioned farther on. Many of these appendages are so thick or of such contorted form as to require a deep cell and low powers in order to bring the whole in focus at once. The beauty and multitudinous variety of these organs, and the fact that they are within easy reach of anybody, make them very attractive objects for the microscopist, who has a wide field for investigation in their study.

In the annelids, so-called teeth occur in many groups, but, on the whole, partake rather of the nature of jaws than teeth, though frequently double on each side, or even more numerous. This group comprises most of the creatures commonly called worms, as well as the leeches, etc. Their bodies, as well shown in the common earth-worm, are divided into more or less well-defined rings of muscular tissue, which correspond internally to segments, often more or less partitioned off from each other. These rings or annulæ for the most part contain successive groups of similar organs, but the anterior segments are usually modified to bear special organs.

In general the jaws are developed on the second or buccal segment, or on a proboscis which is itself an appendage of this segment, and may be protruded from the mouth to a considerable distance. They are chitinous, most commonly paired, lateral and opposite, of almost infinitely varied form, resembling in a general way the maxillæ of insects, and mimicking, in miniature, combs, saws, rasps, claws, etc. etc.

Fig. 159.

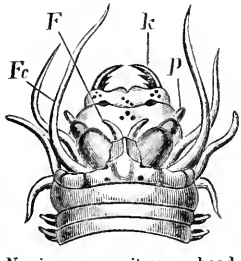

Nereis margaritacea, head with protruded jaw-apparatus of the pharynx, from the dorsal surface (after M. Edwards): *k*, jaws; *F*, tentacles; *p*, palpi; *Fc*, tentacular cirri (from Claus's *Zoology*).

Fig. 160.

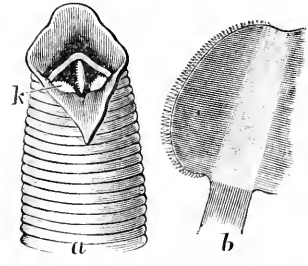

a, cephalic region of the medicinal leech (the three jaws are visible); *b*, one of the jaws isolated, with the finely-serrated free edge.

In the leeches (*Hirudinæ*) the mouth is provided with three lenticular jaws, with the projecting edges finely serrate, and having a partly rotatory motion about a point central to the three. The medicinal

leech has two rows of serrations on each jaw; other species doubtless vary in the buccal armature.

In all the annelids reparation of amputated parts, including the buccal organs, is common and apparently easy. These animals have existed from very early geological time, and small bodies, supposed to be the fossilized jaws or "teeth" of annelids, have been found in the Palæozoic rocks of both Europe and America.

In insects no true teeth exist. Mandibles and jaws occur in infinite variety, usually essentially lateral in position and motion, and easily observed, especially in such forms as the larger grasshoppers and beetles. Among the spiders teeth are equally absent, the poisonous fangs being merely modifications of limbs or segmental appendages, as, indeed, are nearly all the buccal appendages of the annulated or articulated invertebrates.

Among the Crustacea, lobsters, shrimps, crabs, etc., the maxillary organs are but modifications of entire limbs translated from the locomotive series and set apart as special mouth-organs. Most of the Crustacea have a suitable masticatory apparatus of this sort, but in certain parasitic forms become organs of attachment or are altogether wanting. If we examine the digestive organs of one of the higher Crustacea, such as the crab or lobster, we find the stomach divided into two regions, the anterior or cardiac and the posterior or pyloric region. These are sepa-

FIG. 161.

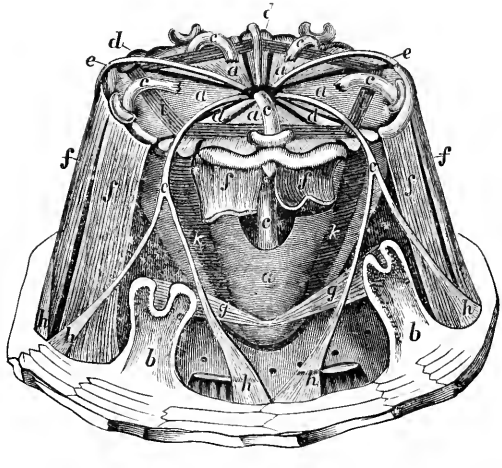

(From T. Rymer Jones's *Outline of the Animal Kingdom.*) Oral Apparatus of *Echinus*: *a a a a a*, pyramidal pieces forming the lantern of Aristotle; *b b*, internal projections from shell; *c c c c c*, teeth enclosed in their sockets; *d d*, interposed osseous pieces; *e e*, curved processes; *f f*, *g g*, *h h*, *i i*, *k k*, muscular fasciculi for the movements of the jaw.

rated more by their functions than by their form. The anterior part is provided with certain masticatory appendages or stomacholiths, often termed teeth, though more analogous to a sort of calcareous gizzard. These consist of several calcareous pieces, moved by appropriate muscles, inserted in the membranous wall of the stomach, armed with a

smooth median plate and lateral molar-like organs, whose mimetic resemblance to the molar teeth of some forms of Mammalia affords a beautiful illustration of the way in which, through the selective influence of similar functions, analogous structures may be built up in organs which have no homology whatever. Two smaller points, bicuspid in the lobster, tricuspid in the crab, complete the calcareous apparatus; in the pylorus a series of fine hairs is placed, which doubtless act as a strainer, preventing the escape of coarser particles of food until they have been sufficiently comminuted by these grinding organs. The "lady" in the lobster, with which children amuse themselves, is part of this apparatus, which of course differs in detail in different genera and species.

The denticulations on the claws of Crustacea have of course no claim to be considered as teeth, though they assist in breaking up the food.

Among the echinoderms, sea-urchins, starfish, crinoids, etc. certain forms possess an apparatus commonly known as *Aristotle's lantern*, which contains what may fairly be regarded as true teeth (Fig. 161). Among the sea-urchins the *Echinidæ* and *Clypeastridæ* possess such an apparatus, the mouth being central; in the *Spatangidæ* the mouth is at one side, and there are no teeth. Among the other echinoderms, the starfishes (*Asteridæ*) have no teeth; the brittle stars (*Ophuridæ*) have short, flat, calcareous processes which are moved by muscles and have the name of *palæ angulares*. They are attached to the mouth-skeleton, and are supposed to be used for mastication.

Among the recent crinoids or sea-lilies the mouth is closed by lobes of the perisome, which may contain calcareous plates hardly to be called teeth. The other groups are edentulous.

FIG. 162.

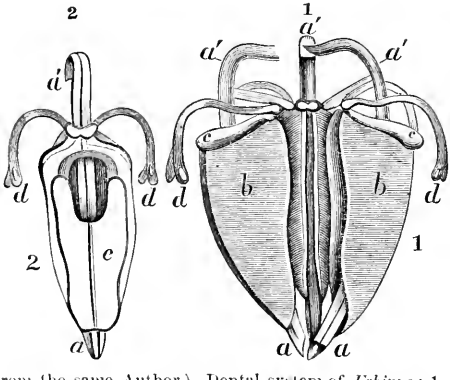

(From the same Author.) Dental system of *Echinus*: 1, represents three of the pyramidal pieces forming the "lantern of Aristotle," *in situ*: *a a*, cutting extremities of the incisor teeth, which are of enamel-like hardness; *a'*, *a'*, *a'*, fibrous roots of the same; *b b*, opposed flat surfaces of the jaws; *d d*, arched processes. 2, an isolated pyramid: *c*, its external surface; *a*, same as in 1.

The singular and remarkable mouth-apparatus (Fig. 162) in our common sea-urchin or sea-chestnut (*Echinus*) has been observed by every one who has passed any time at the seaside. It is frequently detached from the test of the animal, and retains its form for some time, even while washed about by the waves on the beach. It is very complicated in its arrangement, but in essentials consists of five hard, calcareous, wedge-shaped sockets or alveoli (Fig. 162, *b*, *b*), each containing one porcelainous chisel-shaped tooth. The teeth (Fig. 162, *a*, *a*) are, like those of rodents, softer on the inner than on the outer side, and therefore in wearing always preserve a sharp edge. The union of the alveoli produces a pentagonal cone with its apex pointing downward, and formed by the

coming together of the points of the five teeth. Each alveolus consists of two halves united in the middle line, and each half of an upper and lower portion. In life the alveolus is concealed within the tissues, only the point of the tooth projecting. The socket is interradial in position with relation to the test of the echinus, or opposite the interambulacra or spaces between the rows of walking suckers. Above and between the upper ends of the alveolar pieces are certain rather thick radial pieces called *rotulæ* or *falces*, each of which in the *Echinidæ* bears a bifurcated piece known as the *radius* (Fig. 162, *d*, *d*). In this group, at the oral end of the ambulacra (of the interambulacra in *Cidaris*), are calcified internal arched processes called *auriculæ*, each formed of two pieces (Fig. 161, *b*, *b*). The auriculæ are supposed to be homologous with the internal ambulacral ossicles of the starfishes and ophiurans or brittle stars. Retractor muscles pass to the outer edge of the alveoli from the auriculæ; the former are also connected with transverse muscular fibres. The oral framework is also provided with protractor muscles proceeding from the alveoli to the lower edge of the corona, besides special muscles connected with the radii.

The food of the *Echinidæ* consists of seaweed or small shellfish and crustaceans, or, in the case of those forms which are edentulous, of sea-mud and coral sand, which contains much nutritive material. While the teeth are useful in breaking up the harder parts of the food, no grinding or true mastication is possible, as they only meet near their sharp and slender points.

The study of this complicated and wonderful oral apparatus, which may be easily indulged in at any watering-place by the sea, will afford many hours of amusement and instruction to the curious student of nature.

Among all the invertebrate animals a parallel to the variety in form and importance in systematic classification of the teeth of vertebrates is alone to be found with the Mollusca, and among them only with certain groups.

The Mollusca have been divided into two principal groups by later writers—the *Cephalophora* or *Glossophora* on the one hand, and the *Acephala* or *Lipocephala* on the other. These have a general correspondence with the possession or non-possession of a "head" or its concomitant, a muzzle and dental apparatus. Not every species of the many thousands which comprise the Cephalophora (whelks, snails, periwinkles, coat-of-mail shells, limpets, tooth-shells, sea-butterflies, nautilus, squid, or cuttle- and devil-fishes) are provided with teeth, but these special instances are the exceptions to the rule. On the other hand, no single member of the Acephala (clams, oysters, mussels, cockles, fresh-water clams, scallops, etc.) has either a head or a dental apparatus.

The apparatus, reduced to its simplest terms (Fig. 163), consists of a tube entering the floor of the gullet in the median line behind the mouth, called the *radular sac*. The odontophore, or chitinous band upon which the teeth are set, pointing upward and backward like the papillæ on a cat's tongue, grows out of the radular sac like a finger-nail from its sheath. The odontophore and teeth collectively form the *radula*. The floor of the sac is carried forward by natural growth in that direction, bearing

the radula upon it, generally over an arched, cartilaginous mass known as the buccal cartilage, and down to the front edge of the buccal cartilage immediately behind the mouth. This serves as an elastic pad by which the denticulate surface of the radula may be pressed against any object to be drilled or torn with the teeth. It is controlled by retractor and protractor muscles, by which it can be pulled forward into the oral opening or even be somewhat protruded—a fact which can easily be observed by giving a common wood-snail or large slug a bit of bread or lettuce to eat. The tissues about the cartilage are so loose and flexible as to offer no obstacle to the transfer. Beyond this, in certain groups (as the common whelk), the radular floor, to which the odontophore adheres closely, and with which it moves, may be so loosely attached to the buccal cartilage as to slide over it like a towel over a roller, and, controlled by a complicated set of muscles, may be made to move back and forth, or even go through with a semi-rotary motion upon the buccal cushion. The radula in this way may be made to act the part of the strip of emery or pumice cloth sometimes used in dentistry, only the rasping effect is on the convex and not on the concave side. The annexed schematic diagram will indicate the relations of the parts.

FIG. 163.

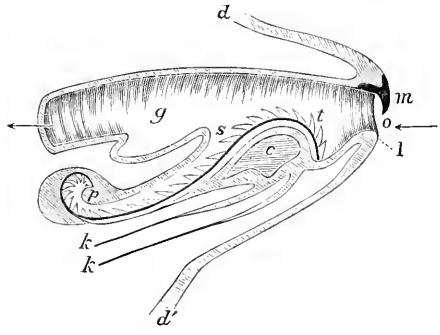

Sectional Diagram of Molluscan Radular Apparatus, vertically divided: *o*, mouth; *m*, jaw or mandible; *l*, lower lip; *d*, *d'*, upper and lower epidermis of the muzzle; *g*, gullet; *t*, teeth set on the odontophore, which rests on the muscular radular floor, supported by the muscular buccal mass, from which extend backward retractor muscles (*k*, *k*), and in which is (*c*) imbedded the buccal cartilage; *s*, the opening of the radular sac; *p*, papilla which secretes the teeth and odontophore.

In addition to the radula, the mouth of the cephalophorous mollusks is often provided with a chitinous[1] armature of another sort. In many mollusks a jaw or jaws are present, which may be a strong black pair, recalling the jaws of a parrot, opposed to one another in the vertical line and largely composed of a substance allied to chitin, as in the squids and cuttles (reinforced with calcareous matter in the case of the pearly nautilus); or merely an arch of delicate chitinous matter without a lower jaw, as in some pulmonates; or a number of pieces composing an arch, as in other land-snails; or a central upper piece of horny matter with a lateral accessory piece on each side, as in the pond-snails (*Limnæa*, etc.). There are large groups, however, without a jaw.

[1] Investigations by Troschel show that the teeth of most gastropods consist almost wholly of chitinous matter. The radular floor or ribbon upon which they are inserted contains about 94 per cent. of chitin and 6 per cent. phosphate of lime. The jaws of *Dolium* and *Helix pomatia* show a 1 or 2 per cent. greater proportion of lime; other helices would show hardly a trace. The references of previous naturalists to the presence of iron and silicon in the radula is supposed by Troschel to have been due to the presence of a few sand-grains among the teeth analyzed. Slight differences doubtless exist between different kinds of mollusks, which would explain the differing results of various analyses.

Some of the nudibranchs, or naked sea-snails, and cuttlefish have a sort of spiny internal collar in the form of an oval ring, as well as a well-marked mandible. The trumpet-conch (*Tritonium*) has two heavy black spinous pieces hinged above with cartilage. The forms of the jaw are numerous and afford good characters for classification, but they all differ from the jaws of other invertebrates, in that the motion and action of the jaws are essentially vertical, and not from the sides toward the middle, as in insects and annelids, though the accessory pieces may have a lateral motion. In some of the Glossophora there is also a gizzard, which may be supplied with small calcareous plates or stomacholiths, recalling the "gastric teeth" of Crustacea.

FIG. 164.

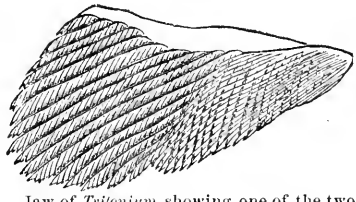

Jaw of *Tritonium*, showing one of the two pieces of which the arch is composed.

Returning to the radula, we find in the innermost extreme of the of the radular sac a papilla which forms the matrix of the teeth and odontophore. This latter organ, whose situation has already been described generally, consists of a ribbon of chitin longitudinally divided into three areas. The central area or *rhachis* is bordered on each side by a margin or *pleura*, which in many cases is bent up on each side so as to form a gutter, with the rhachis at the bottom. In front of the buccal cartilage the pleuræ are much widened laterally, so as to cover and defend the front of the cartilage. In the Toxoglossa the teeth are few in number, and appear to be inserted directly on the muscular radular floor without an odontophore. The teeth are cemented to or spring from the odontophore, in most cases having their points directed upward and backward. They are arranged in longitudinal and transverse rows, the former in straight lines; the transverse rows being generally curved or angulated symmetrically on each side of the median line or tooth. Any of the longitudinal rows may be absent. In a very few genera the radula is absent or the odontophore is edentulous.

The teeth are composed of a base, a shank or stem, and a cutting edge or point, the latter simple or variously denticulated. The base is conspicuous in some forms, hardly evident in others; in some the surface of the odontophore is elevated into a sort of boss beneath each tooth, and among the limpets, etc., such bosses sometimes exist without a tooth upon them. The shank may be short or long, simple or curiously ornamented, or perforated. The form of the cutting points is very varied, and they are sometimes furnished with a minute brush-like appendage. As a rule, the carnivorous forms have simpler and more claw-shaped teeth.

The central tooth of each transverse row is normally symmetrical, and the succession of them forms the median longitudinal row. These teeth are called median or rhachidian teeth. They are generally present, but are absent in a number of genera. On each side of the median tooth are the *lateral* or *pleural* teeth. These are asymmetrical, being rights and lefts, and having a tendency to bend toward the median line. The number of longitudinal rows of laterals varies a good deal. They

are most numerous in the land-snails, and may be wholly absent or reach into the hundreds. Outside of the lateral teeth on each side are frequently several series of flat, plate-like, or slender spiny teeth, which are called *uncini*. They too may be very numerous, especially in the vegetable-feeding sea-snails, or may be wholly absent. But in normal cases, when one series is absent on one side of the median line it is also absent on the other, so that the radula with respect to the teeth is bilaterally symmetrical. Abnormal radulæ are met with where the teeth will be deformed or asymmetrical; in normal radulæ the anterior teeth are usually broken and worn with use, and those in the posterior extreme are soft, light-colored, and half formed, each longitudinal row of teeth being secreted by the same pair of the radular papilla; if it is abnormal at all, the abnormality extends through the whole row during the life of the mollusk. The adult perfect teeth vary from nearly transparent to an amber-yellow or reddish-brown, and sometimes the cutting points are black. In any large whelk they are easily visible to the naked eye; in large cuttlefish the radula may be an inch wide. On the other hand, in some minute land-shells (*Vertigo*, etc.), where the whole shell is hardly bigger than a pinhead, high powers are needed to observe them. The radula may be quite short, reduced even to a single pair of teeth in a few cases, while in the limpets it is very long, and in one periwinkle (*Tectarius pagoda*) it has been found to be seven times as long as the length of the animal's body. Such radulæ are of course always coiled up, and only the anterior portion comes into use at any one time.

The form and arrangement of the teeth are of great use in classification—a fact discovered by Prof. S. Lovèn of Stockholm in 1846. Since this time many authors have studied them, and great advances have thus been made in the systematic arrangement of mollusks; but the number of species is so great and the workers are so few that a vast amount remains to be done before we can consider the classification of our American species to be placed on a sound foundation. The great development of the groups of fluviatile and land snails (*Helix*, *Limnæa*, *Physa*, *Viripara*, *Ammicola*, etc. etc.) in the woods and fresh waters of the United States puts it in the power of any one possessed of a tolerable microscope to add solid facts to the treasury of science. Trusting that this brief survey of the subject may lead some reader to interest himself in it, I add the following instructions for examining the radula of mollusks:

In large snails the radula and buccal mass may be easily dissected out; in small ones the anterior part of the body, and in minute ones the whole body (after breaking the shell), may be taken. With a pair of forceps, a test-tube, an alcohol lamp, some watch-glasses, and some needles fastened in little wooden handles, a little caustic potash, and a microscope, the student is prepared for work.

The radula, or the part of the snail containing it, should be dropped into about a teaspoonful of half-saturated solution of caustic potash in water in the test-tube. This may then be gently boiled over the lamp; too violent boiling may spill the contents of the tube. Held in the forceps, the tube may be moved in and out of the flame as experience

will soon indicate. In a few moments the soft parts disappear, leaving the jaw and radula in the solution, which may be poured into a watch-glass and the radula taken out on the point of a needle, washed in pure water, and then put under the microscope. It will be found so curved, except in very small mollusks, as to need the presence of a cover-glass to bring it into focus: an ordinary live-box answers well. It may be best examined in water as a medium. To get at the form and number of the separate teeth, it will generally be necessary to tease the radula to pieces with the points of two needles. When the radula is microscopic and cannot be seen in the liquor potassæ, the watch-glass may be put on the stage and twirled round a little, when all the solid particles will be impelled toward the centre and the radula found and picked out under the microscope.

After drawing the various parts, so as be able to construct a diagram of the teeth, the object should be preserved in a little tube or vial with some weak alcohol and a tight stopper (rubber is the best), and suitably labelled; or it may be mounted on a slide in the usual way, avoiding Canada balsam, which will soon make it invisible unless stained.

The number of transverse rows of the teeth is of slight importance compared with the exact representation diagrammatically of a single transverse row or of the median tooth and one side of the row, which is in most cases all that is required.

The jaw is often too horny to bear much treatment with potash; the teeth (except in some marine forms) are much more refractory; experience will soon guide the student, who may practise on common species until he gains proficiency. The character of the jaw, especially of the land-snails, is also important for classification, and it should be carefully delineated.

As the number of transverse rows may be large, and the number of teeth in each row sometimes great, the total number of teeth is occasionally surprising, and has been computed for some species at from twelve thousand to forty thousand.

To describe the teeth of mollusks in detail would require several volumes,[1] even in the present imperfect state of our knowledge. The annexed illustrations will give a general idea of their character in some of the chief groups of mollusks.[2]

It is a remarkable fact that if we divide the crawling mollusks, or Gastropoda, into two great groups, one containing the hermaphrodite and the other the unisexual forms, we shall find that in the former (*Monœca*) the auditory sacs contain numerous small otoconia, and the form of the radula is short and broad, the pleuræ imperfectly distinguished from the rhachis, and the teeth usually numerous and possess-

[1] Much assistance may be gained from Troschel's *Gebiss der Schnecken*, Berlin, 1856–80, and in the works of Binney, Bland, Stimpson, and others on the land- and fresh-water shells of the United States, published by the Smithsonian Institution at Washington. Woodward's *Manual of Recent and Fossil Shells* may also be advantageously consulted. These are all cheap works. References to other literature of the subject may be found in the annual volumes of the *Zoological Record*, published by Macmillan, London.

[2] The figures are placed in the text as if fronting the observer, with their cutting points upward as in life (except Fig. 166); the right side of the radula is the left side of the figure in each case.

ing a general similarity to one another on either side of the rhachidian row. In the mollusks where the sexes are divided (*Diœca*) we find single otoliths in the auditory sac, and the radula tending to a more long and narrow form, with the lateral teeth, in general, less numerous and showing much more diversity of form among themselves. To these generalizations there are a few exceptions, as in most laws of wide application, but which may be accounted for on other grounds. The former type of dentition has been termed "pavemental," as recalling the uniform blocks of a granite pavement, and the other "ribbon-" or "strap-like."

The highest type of dentition is that which has been called *toxoglossate* (or arrow-toothed), and which consists of two longitudinal rows of slender hollow or grooved teeth, each row set on a slender, flexible chitinous thread, apparently representing the pleuræ of the odontophore. Each tooth is usually provided with a duct, which conveys a poisonous fluid to near the point, and the latter is frequently barbed or arrow-shaped, from which the name is derived. Examples of this group are *Conus* and *Bela*, both marine forms, the former tropical, the latter

Fig. 165.

Teeth of *Bela*.

Fig. 166.

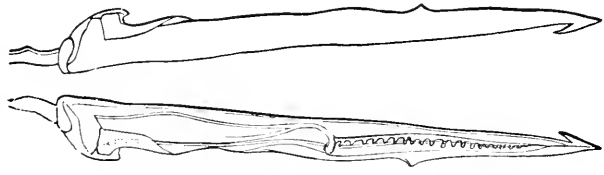

Teeth of *Conus*, showing barbs and poison-duct.

northern, in distribution. The animal of *Conus aulicus* of the Moluccas can give a severe bite. Admiral Sir Edward Belcher of the British navy was bitten by one of them as he picked it out of the water, and compared the acute pain which followed to the burning of phosphorus under the skin. The bite, which was soon followed by a kind of blister, was small, triangular, and deep. Troschel[1] has described the apparatus of the gland and duct.

The *Toxoglossa* have no rhachis or rhachidian tooth, and no jaws; in some of them the series is reduced to a single pair of teeth, and for a time these were supposed to be edentulous.

Next to these come the *Rhachiglossa*, of which the typical forms (*Voluta*) have only a rhachidian tooth, but the larger number, such as

Fig. 167.

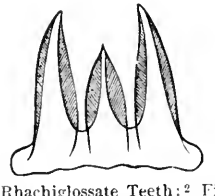

Fig. 168.

Fig. 169.

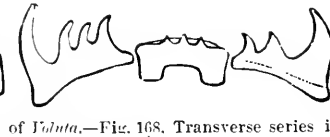

Rhachiglossate Teeth:[2] Fig. 167. Single rhachidian tooth of *Voluta*.—Fig. 168. Transverse series in *Cynodonta*.—Fig. 169. Transverse series in *Fusus antiquus*.

[1] *Geb. der Schnecken*, ii., 1866, p. 15 *et seq.*

[2] All the figures of teeth show single transverse rows, unless otherwise stated.

the common whelk (*Buccinum ; Fusus*, and *Cynodonta* are also examples) have one lateral tooth on each side of the rhachidian. These teeth are straight, are usually prettily denticulated on the cutting edge, and the radula is long and strap-like. The jaw is represented by two lateral rudiments, as in the next group. There are a few exceptional cases where the tooth on the rhachis is reduced to an edentulous flat plate. The bases of the teeth point forward in this group.

The *Tænioglossa* (bent-toothed) are a very extensive assembly, which, amongst others, contains the largest part of our gill-breathing fresh-

Fig. 170.

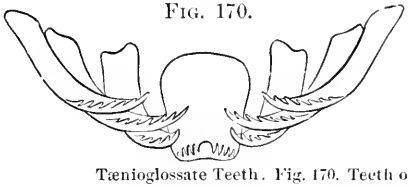

Fig. 171.

Tænioglossate Teeth. Fig. 170. Teeth of *Rissoa*.—Fig. 171. Teeth of *Viripara*.

water snails. The teeth are bent so that their cutting edges turn toward the base of the tooth, which is consequently set on the odontophore with the base as well as the point turning backward, as otherwise the creatures would bite out of, instead of into, their own throats. They have a rhachidian and three lateral teeth on each side of it, and in a few cases a few uncini, but these are very exceptional. *Rissoa* and *Viripara* are good examples of this sort of dentition.

A small group which has been called *Ptenoglossa* (feather-toothed) is generally supposed to lie between the *Rhachi-* and *Tænioglossa*. *Sca-*

Fig. 172.

Ptenoglossate Teeth: teeth of *Scalaria*.

laria, or the wentle-trap, is an example of this kind. The animals are marine, carnivorous, and have numerous slender similar lateral teeth with a bare rhachis and no uncini.

The *Rhiphidoglossa* (needle-toothed) comprise an immense variety of marine snails and a few operculated land- and fresh-water snails, such as *Helicina*, *Neritina*, *Gibbula* and *Haliotis*. The name is derived from

Fig. 173.

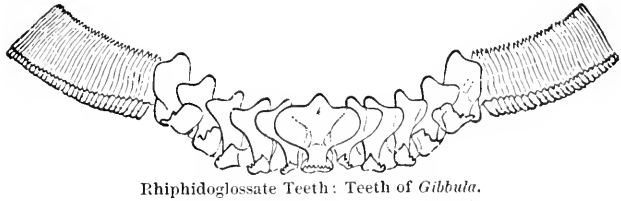

Rhiphidoglossate Teeth: Teeth of *Gibbula*.

the immense number of needle-like uncini which exist in many of the species. The rhachidian is usually present; the number of laterals is variable; the uncini always numerous and similar. They are set on the

odontophore as in the *Tænioglossa*. In this group most of the species have a well-developed mandible or jaw, usually hinged in the middle line with a softer cartilaginous portion.

FIG. 174.

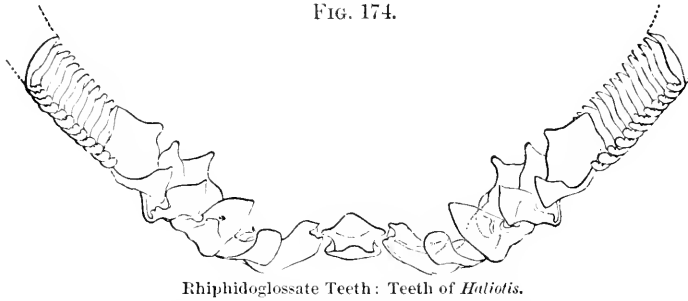

Rhiphidoglossate Teeth: Teeth of *Haliotis*.

The last of the great groups among the diœcious mollusks is that of the *Docoglossa* (plate- or chevron-toothed), which includes the limpets, and is divided into three principal subdivisions—one (*Acmæa*, etc.) without a rachidian tooth, and rarely with uncini; another (*Patella*, etc.), with well-developed uncini and laterals, and generally no rachid-

FIG. 177.

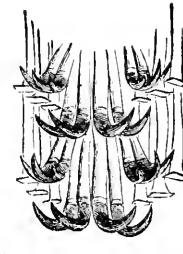

FIG. 175.

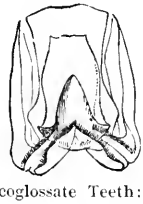

FIG. 176.

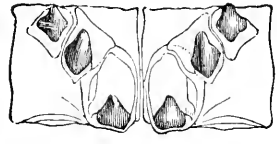

Docoglossate Teeth: Fig. 175.—Teeth of *Lepeta fulva*.—Fig. 176. Teeth of *Acmæa virginea*.—Fig. 177. Teeth of *Patella vulgata*.

ian; the third (*Lepeta*), with a large rhachidian, without laterals, but having uncini. All these forms have a well-developed jaw, and all are marine. They are very archaic in their characters.

It merely remains to indicate the types of dentition among the hermaphrodite mollusks, the majority of which are air-breathers, but which have also many marine representatives, and a few which, like *Limnæa*, the common pond-snail, breathe air, but live in the water, or, like *Siphonaria*, live by the borders of the sea, and are prepared with gill and lung to breathe whatever comes handiest.

The Helices (which are found under rotten logs, etc. in almost any wooded place, and are recognizable by their depressed spiral shell and slug-like body) have a typically pavement-like dentition. This resemblance is common to many allied groups, such as *Achatina*, *Siphonaria*, *Succinea*, etc., and the pond-snails, *Limnæa*, *Planorbis*, and others. The most interesting and little known are the *Physas*, a group of beautifully polished pond-snails with a sinistrally wound shell.

The annexed figures indicate the character of the jaw and teeth in several of the air-breathing mollusks. In some others the jaw is formed

of several pieces, more or less overlapping and making the arch flexible, thus facilitating the protrusion of the buccal mass in feeding. The

FIG. 178.

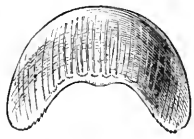

FIG. 179.

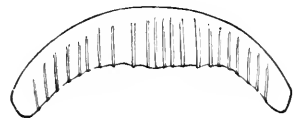

FIG. 180.

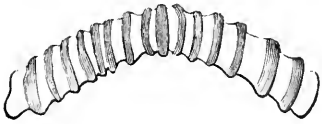

FIG. 182.

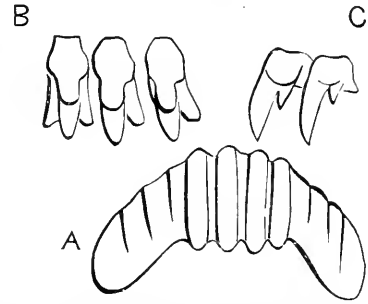

FIG. 181.

Jaws of Pulmonates: Fig. 178. Jaw of *Tebennophorus*.—Fig. 179. Jaw of *Arion*.—Fig. 180. Jaw of *Glyptostoma*.—Fig. 181. Jaw of *Zonites*.—Fig. 182. Jaw (A) of *Geomalacus*; B, rachidian and two lateral teeth; C, outer laterals.

pieces are united by strong muscular tissue. In many of the marine forms the arch of the jaw is, as it were, hinged at the keystone by car-

FIG. 183.



FIG. 184.

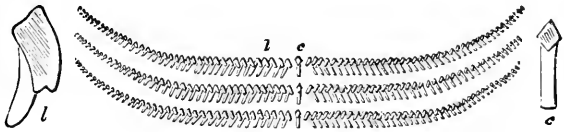

FIG. 185.

FIG. 186.

Teeth of Pulmonates: Fig. 183. Teeth of *Achatina*.—Fig. 184. Teeth of *Siphonaria*.—Fig. 185. Teeth of *Succinea*.—Fig. 186. Teeth of *Limnæa*; *c*, rachidian; *l*, lateral teeth. In these figures the teeth are represented as if seen from above and behind.

tilage, doubtless for the same purpose. In the pond-snails (*Limnæa*) the arch has two small, delicately-hinged lateral pieces, which have a

lateral movement in connection with the vertical movement of the true mandible.

Having indicated the character of the teeth in divers forms of molluscan animals, it remains only to refer to their functions. As already stated, they are used for masticating vegetable or tearing animal matter on which the creatures feed, and, in some cases, as weapons of offence and defence. They have still another use—that of drilling through hard substances, such as the shells of other mollusks for the purpose of devouring the inhabitant. This causes the small round holes so commonly seen in dead shells on the beach. This process has been watched, and is very slow in most cases, two or three days being required by a *Purpura* to drill through a small clam-shell. Many young oysters are annually destroyed in this way by a mollusk known to the oyster-men as the "drill." Some of the tropical forms secrete an acid which must hasten the process a good deal, but in most cases the work is done by pure friction with the radula in a rotary manner. After the hole is drilled the destroyer inserts his proboscis and sucks the fluids of his victim. The traces of the teeth are perfectly visible on the sides of the perforation. Their action may be watched by putting a pond-snail on the glass walls of an aquarium where it has become overgrown with green confervoid slime. A few of these snails are frequently placed in aquaria for the purpose of keeping the walls clean.

THE COMPARATIVE ANATOMY OF THE TEETH OF THE VERTEBRATA.

By JACOB L. WORTMAN, A. M., M. D.

A STUDY of the dental organs of the Vertebrata is one replete with much interest when viewed from the standpoint of the naturalist. The circumstance that their modification is so intimately associated with the food-habits of the animal, being principally concerned in the prehension and comminution of the food, and that to these same habits we must look for the most powerful influences and incentives to modification in general, causes them to assume more than ordinary importance in the estimation of the philosophic anatomist who earnestly addresses himself to the problem of vertebrate evolution.

The fact, too, that the perfect condition in which they have been so often preserved in the fossiliferous strata of the earth's crust has frequently furnished the only evidence which we possess of the existence of forms long since extinct, causes them to be regarded as objects of still greater interest. When we reflect that with nothing more to guide his judgment than the dental series of an animal the expert palæontologist can, generally, not only indicate with great certainty the character of the food upon which the animal subsisted, but its general characteristics and relationships as well, even though the date of its existence be removed to a remote period in geologic history, but little surprise can be felt that so much thoughtful attention has been bestowed upon this set of organs.

No series of anatomical structures has proved of greater utility to the systematist who has endeavored to indicate the exact relationship or philogenetic history of mammalian forms than the teeth. Generally, the student who attempts to master the subject is discouraged almost at the very threshold of his undertaking by the apparently great diversity of tooth-forms to be met with in the mammalian class; but if looked at from a developmental point of view, and if a little careful attention is bestowed upon the plan of organization of the teeth of certain groups, it is not difficult to discover that there are certain central or primitive types from which it is easy to derive other related forms of dentition by simple addition, subtraction, or modification of parts already possessed.

Careful attention to this subject for several years past, with the assistance of the light which American palæontology is now able to throw upon the question, has convinced me more and more of the truth of this assertion; and I feel well assured that we are now in a position to

lay down some broad principles in regard to dental evolution, at least among certain groups of the Mammalia, where they have been subjected to the greatest amount of modification.

Although there are many questions concerning the origin and details of tooth-evolution of many aberrant forms which remain to be solved, yet the discoveries which have been made in palæontology within the last twenty-five years leave scarcely a living group of animals, the development of whose teeth has progressed beyond the primitive stages, from which we have not gained some important information relative to the phases through which they have passed to reach their present condition. The possibility of reducing our knowledge of the dental structures of the Mammalia to a broad and comprehensive basis was long since recognized by Prof. Cope, to whom probably more than any one else we are indebted for a genuine philosophic insight into the forms and structure of these teeth. Scarcely less important are the contributions of John A. Ryder and Dr. Harrison Allen, whose learned researches into the probable causes of tooth-modification have marked notable stages in the progress of the subject and have opened new and interesting fields for investigation. Nor should we omit a mention of the researches of Flower, nor those of Tomes, Waldeyer, Frey, Hertwig, Magitot, and Legros, into the histology and development in later times.

Commonly, teeth are defined as hard bodies attached to the parietes of the mouth or oral extremity of the alimentary canal, whose chief function is the seizure and comminution of the food. Morphologically considered, however, they are specialized dermal appendages situated in the buccal cavity, and characterized by the presence of certain calcified tissue developed from the true derm or corium of the integument, known as *dentine*. It will be seen from this definition that the term "tooth," strictly speaking, is limited to those structures of the oral cavity which alone possess such tissue, although it is a recognized fact that to other epithelial or cuticular structures, found in many invertebrate and some few vertebrate forms, the term "tooth" has likewise been applied.

While they all subserve the same purpose, and are therefore analogous, their chief distinction consists in this—viz. in the latter, so far as they have been investigated, these organs consist of a corneous or horny substance, which is invariably derived from the more superficial epidermal layer, and is therefore *ectodermic* in origin. In the former a papilla arises from the corium, being sunk into a fold or pit, and eventually undergoes more or less calcification from its summit downward by a deposition in its substance of lime salts, forming *dentine*. The dentine thus formed is a hard, elastic substance, consisting of closely-set parallel tubuli, branching as they go, and whose crown may or may not be invested with an exceedingly hard and unyielding substance derived from the deeper layers of the epidermis, known as *enamel*. These are, then, *endermic* in origin.

Those of ectodermic source include the so-called teeth of Annulosæ, Mollusca, Insectæ, etc. among the invertebrates, as well as the horny teeth of *Ornithorhynchus*, palatal plates of the *Sirenia*, and the horny

teeth of the lampreys among vertebrates. If the term "tooth" is applicable to these structures, then we must likewise include the "baleen" of the *Cetacea* and the beaks of birds and reptiles, which by common consent are far removed from true teeth. For all such I think the term *oral armature* is preferable, from the fact that their production not infrequently depends upon the modification of organs widely different in origin.

On the other hand, those of enderonic source are found only within the limits of the Vertebrata, and range in form from the simple cone usual among fishes to the higher complex grinding organs of certain herbivorous mammals. They all agree in being developed from the corium of the lining membrane of the mouth, which is continuous with, and really a part of, the integument, invaginated at an early period. There is a possible exception in the pharyngeal teeth of fishes, which Ryder considers to be of hypoblastic origin or developed from the basement-layer of the mucous membrane of the alimentary canal, and which are practically the same as those of epiblastic origin, as far as their relation to the surface is concerned.

When we speak of teeth being modified dermal appendages, it will not be amiss to cite the evidence upon which such a generalization rests. This is best afforded by a study of the relationship and development of the dermal armature of certain elasmobranch fishes, of which the shark is a good example and furnishes us with one of the earliest, and therefore one of the most primitive, conditions of the Vertebrata.

In these fishes the defensive power of the integument is augmented by the production of numerous hard bodies in its substance, which have been termed "dermal denticles" by Gegenbaur. These structures, which are likewise known as "placoid scales," are distributed over the whole of the integument in shark-like fishes, and are ordinarily

FIG. 187.

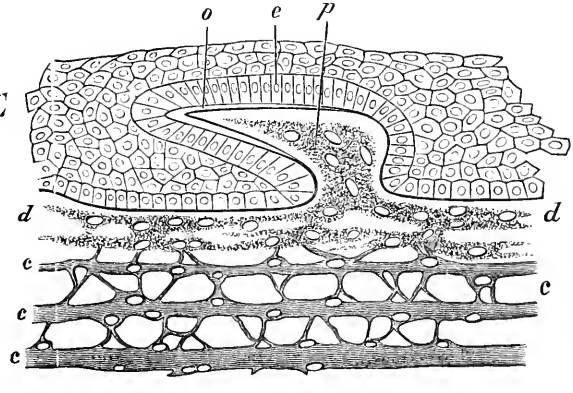

Vertical Section through the Skin of an Embryonic Shark: *c*, corium; *c*, *c*, *c*, layers of corium; *d*, uppermost layer; *p*, papilla; *E*, epidermis; *e*, its layer of columnar cells; *o*, enamel layer (from Gegenbaur, after Hertwig).

rhomboidal in form, with their apices directed obliquely backward. They consist of a solid body, which is inserted by its base into the

corium, with an exposed part, which is covered with a substance indistinguishable from the enamel of the teeth. The structure of the body is likewise coincident with true dentine, and becomes fused with a basal plate of osseous material. Their development is as follows: First, a papilla arises from the uppermost layer of the corium, being covered in by the epidermis (see Fig. 187). From the deepest layer of the epidermis, or that which corresponds with the Malpighian layer, a special epithelial covering is furnished, which eventually becomes, by a process of histological differentiation, the enamel of the exposed part. The papilla, before the conversion of its substance into dentine, exhibits a central cavity, from which fine branched canals radiate to the surface. Eventually, calcification takes place, beginning at the summit, and the salts of lime are deposited in the substance of the papilla, giving rise to the dentine. Gegenbaur observes:[1] "The placoid scale has therefore the structure of dentine, is covered by enamel, and is continued at its base into a plate formed of osseous tissue; as they agree with the teeth in structure, they may be spoken of as dermal denticles."

Now, in the early embryonic stages the integument bearing these dermal denticles is pushed into the oral cavity, where they become somewhat enlarged, and appear in the adult form as teeth. Tomes says:[2] "No one can doubt, whether from the comparison of the adult forms or from the study of the development of the parts, that the teeth of the shark correspond to the teeth of other fish, and these again to those of reptiles and mammals; it may be clearly demonstrated that the teeth of the shark are nothing more than highly-developed spines of the skin, and therefore we infer that all teeth bear a similar relation to the skin." Thus the generalization is reached that teeth are but specialized dermal appendages.

With this statement of the nature of teeth in general, we are now prepared to begin a more special inquiry into the organization of a single tooth. For this purpose I have selected the third lower premolar of the dog as an average and easily-procurable example of a generalized type among the higher forms, which will serve to illustrate the composition and nomenclature of the several parts of which all teeth, with few exceptions, are made up.

For convenience of description, the several parts of most teeth can be divided into crown, fang, and neck, although there are many in which no true fangs are formed, owing to the persistent and continuous growth of the tooth; in all such no distinctions of this kind can be recognized. In the particular tooth under consideration, however, we can distinguish without difficulty an enamel-covered crown, which corresponds with the exposed part of the tooth in the recent state; two more or less cylindrical fangs or roots, by which the tooth is implanted in the alveoli and attached to the jaw bone; and a slight constriction at the point where the fangs join the crown, known as the neck (see Fig. 188). The crown in form resembles a laterally compressed cone, with an anterior and posterior cutting edge. It is covered by a dense shiny white substance of great hardness, the enamel, which ceases at the point where the fangs com-

[1] *Elements of Comparative Anatomy.* [2] *A Manual of Dental Anatomy.*

mence. At the base of the crown the enamel is thrown into a conspicuous fold or ridge, which completely encircles the tooth at this point, and is called the *cingulum*. Of the two cutting edges, the posterior is the more extensive, and is interrupted in its descent from the summit of the crown by a deep transverse notch, which constricts off a prominent cusp known as the *posterior basal tubercle*. A slight indication of a second cusp of this kind is seen immediately behind it as an elevation of cingulum. The anterior is the shorter, and descends from the apex of the crown to the cingulum without interruption. It is placed nearer the inner than the outer border of the tooth, and curves somewhat inward at its lower extremity.

FIG. 188.

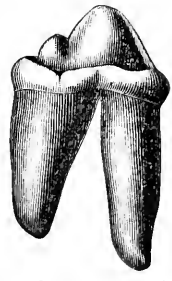

Third Lower Premolar of a Dog (*Canis familiaris*), enlarged.

The fangs are two in number, occupying an antero-posterior position, and give firm support to the crown. They are covered by a softer substance, resembling bone-tissue, known as *cementum* or *crusta petrosa* of human odontography. This material is continued over the entire surface of the crown as an excessively thin stratum in the unworn teeth of the Carnivora and several other orders, but can be demonstrated only by the most delicate manipulation and the use of the microscope. It assumes a more important relationship with the crown, as we shall presently see, in the herbivorous species of mammals.

Of the two fangs, the posterior is the larger, but the shorter, and takes the greater share in the support of the crown, although the cleft which separates them at their summits is placed directly beneath the summit of the crown. It is broad at its base, and tapers somewhat abruptly to an obtuse point. It is traversed by a vertical groove upon its anterior moiety, which fits into a corresponding ridge on the side of its socket. The anterior root is the more slender and the longer of the two. It tapers more gradually, and is likewise traversed by a broad, shallow groove upon its posterior aspect. At the point of each fang will be seen a small aperture, the *apical foramen*, through which the nerves and nutrient vessels pass to the pulp.

So far, we have spoken only of the external appearance of the tooth and of those substances which make up its outer coverings; but if both the cementum and enamel were removed, it would still preserve its original form, so great is the preponderance of the dentine as a constituent element. This can best be seen in a longitudinal vertical section, since at no part in an unworn tooth is the dentine exposed in these animals. Although the dentine is quite thick, and constitutes by far the greatest part of the tooth, it nevertheless does not form a solid body; on the contrary, a considerable cavity is hollowed out in its centre, this being largest in the part which makes up the body of the crown, and extending down each fang. This cavity lodges the dentinal pulp, the formative and nutrient organ of the tooth, and is in communication with the exterior by means of the apical foramina of the fangs.

While this structure, in common examples of enamel-covered teeth, is observable with the unassisted eye, a more minute study of the organization of the various tissues must be conducted with the aid of the micro-

scope. This necessarily requires a considerable amount of experience and skill in the manipulation and preparation of material, so that to the unpractised observer a proper determination of the things which one may see is not always an easy matter. On this account I have chosen to follow the conclusions of the recognized authorities, especially the excellent treatise on dental anatomy by Charles S. Tomes, in this brief statement of the histology, rather than trust the accuracy of my own observations on the same. Since the histology of human teeth has been more fully made out than perhaps the histology of those of any other animal, it is here taken for illustration, although I am fully aware that important deviations from the structure here described are to be met with among the Vertebrata.

Dentine.—As we have already seen, the tooth consists of a dentine body with a central cavity lodging the pulp, an enamel-capped crown, and cementum-covered roots. The dentine is a hard, highly elastic, translucent substance of a yellowish-white tinge, having a silky lustre upon fracture. It is composed of an organic matrix highly impregnated with calcareous salts; through this matrix closely-set parallel tubuli radiate from the pulp-cavity toward the periphery in a direction at right angles to the surface of the tooth.

Of perfectly dry dentine the following chemical analysis is given by Von Bibra:

Organic matter (tooth-cartilage)	27.61
Fat	0.40
Calcium phosphate and fluoride	66.72
Calcium carbonate	3.36
Magnesium phosphate	1.18
Other salts	.83

The organic basis of the matrix, although closely related to that of bone, is said not to be identical with it, and is hence called "dentine" or "tooth-cartilage;" it is perfectly structureless and transparent. After the tooth has been decalcified by submitting it to the action of dilute acid for a few days, the matrix will still preserve the characteristic shape of the tooth, and can readily be studied.

As already stated, the tubuli, which are likewise known as *dental tubes*, permeate the matrix in all directions, opening freely upon the walls of the pulp-cavity, by which arrangement all parts of the dentine are brought into direct communication with the central nutrient organ, the pulp. They are most nearly approximated and their diameters greatest at their commencement on the walls of the pulp-cavity, but, pursuing a somewhat wavy course, gradually diminish in size, owing to the numerous branches which they give off. These branches, although not uniform in size, anastomose freely with those of the neighboring tubuli, and frequently show varicosities in their course. They terminate either by gradually fading out, by anastomosing with other branches, by ending in loops, or by entering the enamel and cementum layers.

While the dental tubes may be said to be channelled out in the substance of the dentine cartilage, the walls of the tubuli are not formed by this cartilage, but each tubuli is furnished with a structure known as

the *dentinal sheath*, which accompanies it throughout all its plexiform radiations. The structure of these dentinal sheaths is not certainly known, owing to the impossibility of isolating them without decalcification of the dentine. Some histologists believe that they are calcified, while others express doubt as to the correctness of this conclusion. One very marked peculiarity which they possess is their great indestructibility. Dentine when submitted to the action of strong acid for a sufficient length of time to completely destroy the intervening cartilage, or when boiled in caustic alkali, will still exhibit these dentinal sheaths, for it is indeed only in this way that their presence can be demonstrated satisfactorily. One writer (Magitot) denies their existence altogether.

Enclosed within each dentinal sheath is a soft fibril, the *dentinal fibrils*, which take their origin from the cells of the odontoblastic layer of the pulp, presently to be noticed, and of which there are sufficient reasons for believing them to be nothing more than processes or prolongations. There is, however, considerable discussion upon the exact nature and relationship of these fibrils. Magitot maintains that they are continuous with a layer of reticulate cells which lie beneath the odontoblasts; these freely communicate with processes of the odontoblasts, so that there is a very direct communication between the dentinal fibrils and the nerves of the pulp. He would therefore ascribe to them a sensory function. Klein, on the other hand, holds that the odontoblasts are concerned only in the formation of the dentine matrix, and that the dentinal fibrils are long processes of deeper cells extended between the odontoblasts. Whichever of the various views now held may ultimately prevail, this much appears to be settled—viz. that the dentine is extensively invaded, so to speak, by soft plasmic material derived from the pulp, by which it is not only nourished, but also rendered highly sensitive.

In the outermost layer of the dentine, which underlies the cementum, numerous globular spaces are found, in which many of the dentinal tubes end; these are filled with soft living plasma. These spaces, if such indeed they may be properly termed, give to this layer a distinctly granular appearance, whence it was called by Tomes the "granular layer." Other structures, known as the interglobular spaces, possessing a ragged outline and short pointed processes, may frequently be seen in dried sections of dentine. They are said by Tomes to be most abundant at a little distance below the surface, and he believes them to pertain rather to a pathological than to a normal condition.

The Tooth-pulp.—It appears best to describe in connection with the dentine the *pulp* or *formative organ*, in consequence of the intimate relation which exists between them. As has already been stated, it is lodged in the pulp-cavity, and is the principal, if not the only, source of blood- and nerve-supply to the dentine. In the young and growing tooth, especially about the time calcification begins, it is largest and assumes its greatest functional activity and importance, from the fact that it is through its mediation that the dentine is formed; in fact, in the early stages of dental development, as we shall hereafter see, it is coincident with the dentine organ itself, of which in the adult tooth it is the inconsiderable remnant. As senile changes supervene it gradually

loses its formative energy, and may become entirely obliterated. Taken at the adult stage of the tooth, it is seen to consist of indistinct finely fibrous connective tissue containing numerous cells. The outermost layer of the pulp is known as the *membrana eboris*, and is made up of a single layer of highly specialized cells of a dark granular appearance, somewhat elongated, termed *odontoblasts*. These odontoblasts possess large oval nuclei, and are provided with three sets of processes, as follows: the *dentinal processes*, which are identical with the dentinal fibrils, and, as we have already seen, enter the dental tubes; the *lateral processes*, by which they are connected with each other; and, lastly, the *pulp processes*, extending down to a deeper layer of cells. This latter layer of cells is somewhat intermediate in size between those more deeply seated and the odontoblasts. Three or more arteries enter at the apical foramen, and form a rich capillary plexus a short distance beneath the membrana eboris. The nerves enter by several trunks along with the arteries, and soon break up into a fine network in the substance of the pulp. According to Boll, nerve-fibres penetrate the dentinal tubuli in company with the dentinal fibrils, but this view is not fully accepted.

Cementum.—The cementum in human and many other teeth of similar structure may be said to be confined to the roots, investing them externally, unless the enamel cuticle or membrane of Nasmyth, mentioned above, pertains to it, which C. S. Tomes and others believe to be the case. It, like ordinary bone, consists of a gelatinous base combined with calcareous salts, and is permeated by vascular canals. Its histological structure presents so many characters common to bone that it is difficult to consider it anything more than a slight modification of that tissue. Just as in bone, large irregular spaces (*lacunæ*), filled with protoplasmic substance and presenting numerous minute radiating canals (*canaliculi*), which anastomose with those of neighboring lacunæ, are found in ordinarily thick cementum; certain differences are, however, seen to exist.

The lacunæ of cementum, for example, are more variable in size and are noted for the great length of their canaliculi. The direction, too, of the canaliculi is generally parallel with that of the dentinal tubuli, radiating from two sides only, whereas in bone-tissue they radiate in all directions. It has been already stated that the dentinal tubuli sometimes enter the cementum layer. When this is the case they become continuous with the canaliculi of the most deeply distributed lacunæ. The outermost or granular layer of the dentine goes so far toward establishing a complete transition in structure between the cementum and the dentine that it is generally impossible to draw a dividing-line and say where the one ends and the other begins. As to limit of distribution of the cementum on the surface of the teeth in man, monkeys, carnivores, and insectivores, different views have been expressed, owing to the various constructions that have been placed upon the nature and relationship of the enamel cuticle or Nasmyth's membrane, already mentioned. Waldeyer, Huxley, and Kölliker hold that it is no way connected with the cementum, but that it is a product derived from the enamel, and is therefore epithelial in origin. C. S. Tomes, Magitot, and Wedl, on the other hand, maintain that it is a part of the cementum

extended over the entire crown of the tooth, and becomes continuous with its outermost layer in the vicinity of the neck. It is one of those excessively thin membranes (not over $\frac{1}{20000}$ inch in thickness, according to Kölliker) which are peculiarly indestructible and resist the action of the strongest acids and alkalies. When stained with the nitrate of silver, it shows a peculiarly reticulated structure resembling epithelium, which is believed by Tomes to be due to the pitted surface on its interior, by which it is applied to the enamel-prisms. Encapsuled lacunæ are likewise found in its substance, which would be difficult to explain if it were not a part of the cementum layer. Tomes has likewise traced its connection with the outer layer of the cementum on several occasions, and is therefore firmly of the opinion that it is a continuation of this tissue.

Enamel.—The excessively hard, shiny substance investing the crown of the tooth is the enamel. It is by far the hardest tissue to be met with in the animal body, being at the same time the poorest in organic constituents. Where it exists at all, it generally forms a cap of varying thickness over the exposed part of the tooth, except in those instances where there is an excessive development of cementum in this situation, which causes it to occupy a position between the cementum and dentine, as seen in the most exclusively herbivorous feeders, of which the horse, cow, and elephant are good examples. Even here palæontological evidence is quite conclusive in support of the proposition that their earlier representatives possessed teeth with naked enamel-covered crowns. This condition of nudity of the enamel is coincident with shorter cusps and less elevated ridges of the crown, and, as we have good reasons to infer from analogy, with more omnivorous habits of feeding. It can thus be shown that this anomalous arrangement of the tissues is one acquired comparatively late in the development of these forms for the exclusive purpose of giving greater strength to the lengthened cusps, thereby affording immunity from fracture during the act of mastication.

Von Bibra gives the following chemical analysis of the enamel of an adult human tooth:

Calcium phosphate and fluoride	89.82
Calcium carbonate	4.37
Magnesium phosphate	1.34
Other salts	.88
Cartilage	3.39
Fat	.20

The proportion of the organic to the inorganic material is therefore 3.59 to 96.41, while in dentine it is 28.01 to 71.99. Its structure consists of minute hexagonal prisms, known as *enamel-fibres* or *enamel-prisms*, whose long axes, broadly speaking, have a direction at right angles to the surface of the tooth. It is a comparatively rare occurrence to find the fibres pursuing a perfectly straight course from the dentine to the surface, but such is found to be the case in the enamel of the manatee or sea-cow and several other forms. Usually, they are tortuous, and frequently decussate, as in the human subject, which renders it difficult to trace the course of an individual fibre. A variety of patterns is pre-

sented by the arrangement of these prisms in the enamel of different animals, especially of the "gnawing quadrupeds," or rodents.

The prisms, when decalcified and isolated, exhibit slight varicosities or enlargements, giving them a distinct transversely striated appearance, not unlike that of voluntary muscular fibres. They are otherwise structureless. It is maintained by Bödecker that the prisms are not absolutely in contact, but that minute spaces exist between them which are filled with active protoplasmic material, which becomes continuous with that of the dentinal tubuli, thereby furnishing a means of nutrition. Some investigators admit this interstitial substance, but attribute to it no greater function than that of simple cementing material, while others, again, claim that the prisms are in absolute contact, and that no intervening substance is demonstrable. Owing to the disparity in extent between the outer and inner surface of the enamel, as well as the fact that the individual prisms do not decrease in size nor branch in their course outward to the surface, considerable spaces would be left if it were not that they are occupied by numerous prisms which do not penetrate to the dentine. The prisms end in sharp-pointed extremities which are received into corresponding pits in the enamel cuticle or membrane of Nasmyth.

Development.—Next in order will be briefly noticed the development, so as to complete in this connection an entire statement of the anatomy of a single tooth. It may be said that although teeth of different types differ to a wonderful degree in their forms, which would seem to indicate differences quite as great in other respects, yet, in fact, the plan of their development is substantially the same wherever found. So far is this true that the description of the embryology of one tooth will, with little modification, answer fairly well for all teeth. The more important of these modifications in the details of development will be discussed in connection with the teeth of the various subdivisions of the Vertebrata.

We have already stated that the teeth are derived from the lining membrane of the oral cavity, which blends with the integument at the lips. The principal differences between the integument which covers the surface of the body and the mucous membrane which lines the alimentary canal are those of function and origin, the structure being essentially the same. In the one the individual cells of the epidermal layer become devitalized and scale off, while in the other they are actively engaged in the secretion of mucous, gastric, intestinal, and other juices during alimentation. The devitalization and consequent "shedding of the skin" is greater in some forms than in others. In the frogs and salamanders, for example, the skin is kept constantly moist by an abundant mucoid secretion, and the epithelium of the integument may be said to be more "alive" in these animals than in birds, reptiles, or mammals. The difference in origin consists in the important fact that the integument is formed from the epiblastic or outermost layer of primitive embryonic growth, while the mucous membrane of the alimentary canal is derived from the hypoblastic or innermost layer of the same. In the early stages of the development of the embryo the skin is more or less invaginated into the mouth-cavity, and partakes

somewhat of the nature of mucous membrane proper. The real point of blending is, in the embryo at least, not at the lips, but lies inside the borders of the jaws. If, therefore, we limit the term "mucous membrane" in this situation to that tissue which is of hypoblastic origin, then the teeth of the jaws cannot be said to be developed from the mucous membrane of the mouth, as is commonly stated, but from the invaginated integument.

In many fishes teeth are found far back in the pharynx, and are attached to the gill-arches and pharyngeal bones. I am informed by Mr. J. A. Ryder, whose extensive knowledge of the embryology of fishes renders his statements highly authoritative, that these teeth lie beyond the limits of the invaginated integument, and are truly of hypoblastic derivation. If this be true, the generalization that *all* teeth are modified dermal spines is certainly incorrect. It affords us, however, an example in which identical structures have been produced from tissue of vastly different origin in a similar manner, and in all probability attributable to the same causes—viz. repeated stimulation of a particular point, which eventually gave rise to a calcified papilla.

The point at which a tooth is about to be developed is marked by a proliferation of the cellular elements of the tissue in which it will ultimately appear. These eventually arrange themselves into three organs, which have been denominated the *dentine organ*, the *enamel organ*, and the *dental sacculus*. This latter organ becomes so modified in some animals, in which coronal cement is extensively developed, as to merit the distinction of *cementum organ*. Taken collectively, they represent the tooth-germ. C. S. Tomes very justly remarks that "the tooth is not secreted or excreted by the tooth-germ, but an actual metamorphosis of the latter takes place." The three principal tissues, dentine, enamel, and cementum, thus produced, are formed from their respective organs, and consequently separate parts of the tooth-germ. Although many adult teeth do not possess enamel upon their crowns (*e. g.* edentates or sloths, armadillos, etc.), yet the presence of an enamel organ in the early stages of growth is believed to be a universal feature of the development of all teeth, and is one of the strongest arguments for their community of origin, however much they may have been subsequently modified.

The Enamel and Dentine Organs.—In the earliest stages of the development of a mammalian tooth, which is here taken for description, a slight longitudinal depression in the epithelium covering the borders of the jaws is noticeable; this is somewhat augmented in depth by the addition of a ridge upon either side of it. At the bottom of this groove the deepest or Malpighian layer of the epithelium grows down into the corium as a continuous fold or lamina, being directed downward and a little inward. In cross-section this fold resembles a tubular gland and extends throughout the entire length of the jaw. In the positions where teeth are to be formed the lower extremity of this lamina is considerably enlarged by the rapid multiplication of its constituent cells. The continuity of the fold is now broken up, and the structure which is destined to become the enamel organ appears as a process of epithelium comparable in shape to a Florence flask (Fig. 189). The outermost layer of the organ at this stage is made up of cells of

the columnar variety which still retain their connection with the Malpighian layer above, from which they were orignally derived, while the interior of the enlarged extremity is composed of polygonal cells.

Fig. 189.

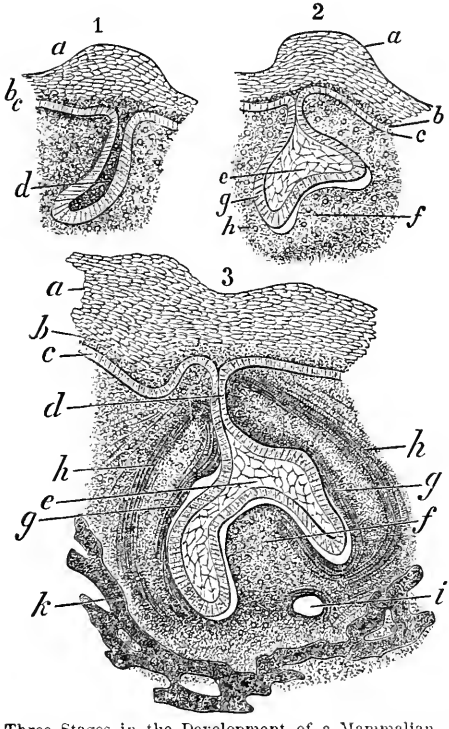

Three Stages in the Development of a Mammalian Tooth-germ: *a*, oral epithelium heaped up over germ; *b*, younger epithelial cells; *c*, deep layer of cells or rete Malpighii; *d*, inflection of epithelium for enamel germ; *e*, stellate reticulum; *f*, dentine germ; *g*, inner portion of future tooth-sac; *h*, outer portion of future tooth-sac; *i*, vessels cut across; *k*, bone of jaw (from Tomes, after Frey).

As development proceeds, the edges of the enlarged extremity grow more rapidly downward than the centre, which causes it to assume a bell-shaped form, with the concavity directed downward. Synchronous with this growth, a papilla arises from the corium beneath and is closely invested by the enamel organ. The appearance of this papilla marks the earliest stage in the development of the dentine organ, but it will be well to examine more closely at this stage the structure of the enamel organ. While it retained the shape of the Florence flask its periphery consisted of columnar epithelium, the interior being made up of polygonal cells. Coincidentally with its assumption of the bell shape those cells of the peripheral layer which are brought into juxtaposition with the dentine bulb or organ undergo great elongation and enlargement, forming very regular six-sided prismatic bodies, and are known as the *enamel-cells*. The polygonal cells of the interior are transformed into a stellate reticulum composed of cells with remarkably elongated processes; these pass through a series of unaltered cells known as the *stratum intermedium* into the enamel-cells. Lastly, we have the outer layer, which is little changed, and still remains connected with the Malpighian layer by a slender cord of epithelium. This layer is called the external epithelium of the enamel organ.

Before the dentine papilla makes its appearance "a dark halo," more vascular than the surrounding parts and corresponding to the epithelial lamina or fold which gives rise to the enamel organ, is to be seen in the submucous tissue or corium. Immediately beneath the enlarged extremity of the enamel organ the dentine papilla is developed at about the time this stage is reached by the enamel organ. In its peripheral layer highly specialized cells with several sets of processes, *odontoblasts*—already described in connection with the tooth-pulp—make their appear-

ance, while in the remainder of the bulb numerous other cells, identical with those of the tooth-pulp, are developed. It also becomes highly vascular. Very soon the odontoblasts nearest the surface undergo metamorphosis into a gelatinous matrix, and their nuclei disappear; they are next calcified from the summit downward, and we soon recognize a thin dentine cap over the entire bulb, which gradually increases as development proceeds. The central portions of the odontoblasts remain uncalcified and form the dentinal fibrils, while the lateral processes occasion the numerous anastomoses of the dentinal tubuli and fibrils seen in the adult tooth. The dentine mass is gradually thickened by successive increments from within by a repetition of the process above described, so that it will thus be readily seen that the configuration of the dentine body, and consequently the entire tooth, is established as soon as calcification has fairly set in.

Returning to the enamel organ, we can now briefly follow its development to completion. We have already seen that it consists of an outer layer of columnar epithelium covering the convex portion, and is connected by a slender cord with the Malpighian layer above. It consists also in part of an internal stellate reticulum which passes by means of a layer of rounded cells (stratum intermedium) into the enlarged, greatly-elongated prismatic cells lining the concave lower surface, which invests the dentine organ like a cap. Before the enamel is completed the external epithelium, the stellate reticulum, and stratum intermedium disappear altogether, but before this atrophy takes place the neck or epithelial cord of the enamel organ gives rise to the tooth-germ of the permanent tooth as a diverticulum which is developed in the same way as the germ of the first or deciduous tooth just described.

The essential part of the enamel organ, or rather that which ultimately results in the formation of enamel, consists of enamel-cells. These, as we have said, become greatly elongated and assume the form of regular hexagonal prisms, which agree in shape with the calcified enamel-prisms of the complete tooth. Just as in the odontoblasts of the dentine, they are transformed into a gelatinous matrix, the nucleus disappears, and calcification begins from above, the only difference being that the enamel-prisms calcify completely, and are therefore not tubular, while in the corresponding structures of the dentine dentinal tubuli are left. Different views have been advanced in regard to the exact destination as well as the function of the several parts of the enamel organ spoken of above as disappearing by atrophy. As to the fate of the external epithelium, Waldeyer holds that after the disappearance of the stellate pulp it becomes applied to the outer surface of the enamel as the membrane of Nasmyth, which would certainly seem to be its most natural fate; but Kölliker, Magitot, and Legros claim, on the other hand, that it disappears altogether. Most authors believe that the enamel organ is devoid of vascularity, but Beal asserts that there is a vascular network in the stratum intermedium. If it be non-vascular, then it is more than probable that the pulp represents stored-up pabulum from which the requisite formative energy is derived. If vascular, it then probably subserves a mechanical purpose only, as some authorities believe.

The Dental Saeculus and Cement Organ.—So far, no mention has been made of the development of the dental saeculus. At an early period in the growth of the dentine papilla a process of the submucous tissue arises from its base and seems to grow upward on the outside of both dentine and enamel organs, finally coalescing on top, so as to enclose the growing tooth-germ in a shut sac, the dental saeculus. Whether there is an actual growth of processes from the base of the dentine bulb, or whether the adjacent connective tissue is transformed into it, appears not to have been very accurately determined; at all events, the connective tissue immediately in contact with the germ soon becomes distinguishable from that external to it by becoming richer in cells, vessels, and fibrillar elements. When the saeculus is fully formed, it is made up of an outer and an inner wall, both richly vascular. The outer wall becomes the dental periosteum, while in the inner wall, especially in the vicinity of the roots, osteoblasts appear and are calcified into cementum, as in the formation of ordinary bone-tissue. Its close application to the surface of the enamel, and partial or imperfect calcification in most teeth, give rise to the membrane of Nasmyth. In those animals, however, in which coronal cement is formed, such as the Herbivora, there is developed in connection with the inner wall, between it and the enamel, a fibro-cartilaginous structure containing characteristic cartilage-cells. These undergo calcification in a manner not different from that seen in the formation of cartilage bone, and produce the cementum in the teeth of these animals. It is then known as the *cementum organ*.

We have now made clear, we trust, as complete a statement of the anatomy of a single tooth as is consistent with brevity, but which will serve as a basis for the comprehension of the more special part of our subject—viz. the morphology of the teeth in the various subdivisions of the Vertebrata.

The Accessory Organs—the Teeth, their Structure, Development, Replacement, and Attachment, in Fishes.

It will be impossible to gain anything like a concise understanding of the dental organs of this extensive assemblage of vertebrate forms until we have first briefly outlined their classification. In this I have followed Prof. Gill, believing that his interpretations more nearly coincide with a natural arrangement.

It is a common practice of naturalists to consider the Vertebrata as divisible into five classes, as follows: *Pisces*, or fishes; *Batrachia*, or frogs, salamanders, etc.; *Reptilia*, or snakes, turtles, lizards, etc.; *Aves*, or birds; and *Mammalia*, or mammals; but according to Prof. Gill there are differences quite as great, if not greater, between certain members of the old class Pisces as there are, for example, between some fishes and frogs. For this reason he divides the permanently gill-bearing vertebrates, or those which aërate the blood throughout the entire life of the individual by means of specially adapted organs known as "gills," into four classes, which he defines as follows:

I. Skull undeveloped, with the notochord persistent and extending to the anterior end of the head. Brain not distinctly differentiated. Heart none.
LEPTOCARDII.

II. Skull more or less developed, with the notochord not continued forward beyond the pituitary body. Brain differentiated and distinctly developed. Heart developed and divided at least into auricle and ventricle.

A. Skull imperfectly developed, with no lower jaw. Paired fins undeveloped, with no shoulder-girdle nor pelvic elements. Gills purse-shaped.
MARSIPOBRANCHII.

B. Skull well developed, with a lower jaw. Paired fins developed (sometimes absent through atrophy), and with shoulder-girdle (lyriform or furcula-shaped, curved forward, and with its respective sides connected below), and with pelvic elements. Gills not purse-shaped . . . . . LYRIFERA.

a. Skull without membrane bones ("a rudimental opercular bone" in *Chimæra*); gills not free, the branchial openings slit-like, usually several in number; exoskeleton placoid, sometimes obsolete; eggs few and large.
ELASMOBRANCHII.

b. Skull with membrane bones; gills free; branchial openings a single slit on each side, sometimes confluent; exoskeleton various, not placoid; eggs comparatively small and numerous . . . . . PISCES.

The first of these classes, *Leptocardii*, includes a few small fish-like animals, such as the well-known amphioxus or lancelet occurring on our coast, in which no skull exists. They are in many ways most remarkable forms, being the most primitive of all vertebrates, but as they are devoid of teeth, this class can be dismissed without further consideration. The next, *Marsipobranchii*, embraces the lampreys, whose "horny teeth" have already been alluded to. The relationship as well as examples of each order of the remaining two classes is expressed in the subjoined table (p. 366), which is compiled from Dr. Gill's papers on the classification of fishes.

The Accessory Organs.—A consideration of these organs necessarily involves not only a study of the bones and cartilages taking share in the boundary of the oral cavity, but of all bones and cartilages in connection with which teeth are developed. It would likewise properly include a mention of the muscles which move these parts, together with the vascular and nervous supply; but owing to their great range of variation, as well as the limited space at my disposal, these latter will not be considered. This, in my judgment, is best accomplished by describing the normal arrangement in some typical fish and comparing all others with it. For this purpose a gadoid fish, or one of the cod tribe, is most suitable, since it exhibits the structure which obtains in a large majority of ichthyic forms.

If a well-cleaned skull be examined, it will be seen to consist, in the first place, of a cranium or brain-box, or that part which remains intact after the skull has been boiled or macerated a sufficient length of time to cause the soft parts to disappear and the arches and appendages to become disarticulated. This contains the brain, and becomes continuous at its lower back part with the vertebræ or axial pieces of the body skeleton into which the spinal cord passes. Suspended from either side of its posterior portion there is a chain of bones which extends down beneath the throat and bears the pectoral fins; this is known as the *shoulder-girdle* or *scapular arch* (see Fig. 190).

A short distance in front of this, or at a point about midway between the root of the scapular arch and the eye-socket, another arch springs

Class, LEPTOCARDII: example, lancelet.

Class, MARSIPOBRANCHII: ex. lampreys.

Class, ELASMOBRANCHII
- Sub-class, HOLOCEPHALI: ex. chimera.
- Sub-class, PLAGIOSTOMI — Orders,
  - *Raiæ:* ex. rays, sawfishes, and torpedos.
  - *Squali:* ex. sharks.

Class, PISCES
- Sub-class, GANOIDEI — Super-orders,
  - *Hyoganoidei* — Order,
    - *Cyeloganoidei:* ex. bowfin.
    - *Rhomboganoidei:* ex. bony gars.
  - *Brachioganvidei* — Order,
    - *Crossopterygia:* ex. polypterus.
  - *Dipnoi* — Order,
    - *Sirenoidei:* ex. mudfishes.
  - *Chondroganoidei* — Order,
    - *Sclachostomi:* shovel-nose sturgeon.
    - *Chondrostei:* sturgeons.
- Sub-class, TELEOSTEI — Orders,
  - *Opisthomi:* spiny eels.
  - *Apodes:* ex. eels.
  - *Scyphophori.*
  - *Nematognathi:* ex. catfishes.
  - *Telecocephali:* ex. carp, herring, salmon, pike, perch, etc.
  - *Pediculati:* ex. batfishes, anglers, etc.
  - *Lophobranchii:* ex. sea-horses.
  - *Plectognathi:* puffers, foolfishes, etc.

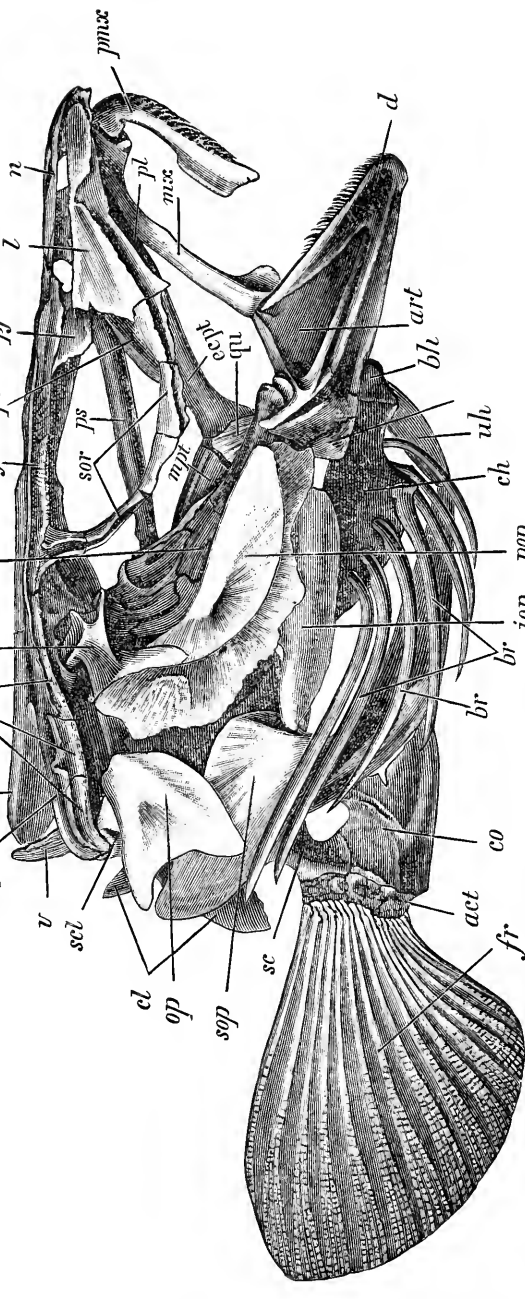

Fig. 190.

Skull of the Codfish (*Gadus morrhua*): *pmx*, premaxillary; *n*, nasal; *l*, lachrymal; *pf*, prefontal; *cpt*, ecto-pterygoid; *fr*, frontal; *sy*, symplectic; *hy*, hyo-mandibular; *co*, epiotic; *stm*, supratemporals; *so*, supraoccipital; *pto*, post-temporal; *v*, first vertebra; *scl*, supraclavicle; *cl*, clavicle; *op*, operculum; *sop*, suboperculum; *sc*, scapula; *fr*, fin rays; *act*, actinosts; *co*, coracoid; *br*, branchiostegal rays; *iop*, interoperculum; *pop*, preoperculum; *ch*, cerato-hyal; *uh*, uro-hyal; *bh*, basi-hyal; *art*, articular; *d*, dentary; *mx*, maxillary; *pl*, palatine; *qu*, quadrate; *ecpt*, ecto pterygoid; *mpt*, meso-pterygoid; *so*, suborbital; *ps*, parasphenoid.

from the side-wall of the cranium and passes downward and forward to the proximal portion of the lower jaw, which is attached to it; this is known as the *hyo-mandibular arch* (see Fig. 204). Attached to the pos-

terior portion of this arch are several broad, flat, scale-like bones which cover the gills and are called opercular bones. The upper posterior one is the *operculum*. The one in front of this, presenting a curved outline anteriorly and a posterior serrate border, is the *preoperculum*, while the two beneath are the *interoperculum* and *suboperculum* respectively. The arch itself is composed, first, of the *hyo-mandibular* bone (Fig. 190, *hy*), which by its proximal extremity is attached to the side-wall of the cranium, being lodged in a distinct oblong socket; secondly, of the *quadrate* (*qu*, Fig. 190), which articulates with it by suture at its lower extremity; thirdly, the *symplectic*, a small splint occupying a groove in the inner side of the quadrate; and, lastly, the lower jaw, which is movably articulated with the quadrate and which normally supports teeth. Each half is made up of the *dentary* or tooth-bearing piece, meeting its fellow of the opposite side in the median line or symphysis, and an articular piece which connects the dentary with the quadrate. To this may be added the *coronoid*, a small bone superimposed above the junction of the articular and dentary, and an *angular* which lies just beneath the articulation of the quadrate and articular.

From the region of the quadrate another chain of bones extends upward, forward, and inward to the anterior part of the roof of the mouth, where it is attached by ligament to the side of the vomer, or that bone which forms the prominent rostrum of the cranium after the removal of the arches. This chain is known as the *palato-quadrate* arch, and the bones entering into its composition are the *ento-*, *meso*, *ecto-pterygoids* and the palatine. The ento-pterygoid is applied to the hyo-mandibular and quadrate upon their anterior margins; the meso-pterygoid starts out from the quadrate and ento-pterygoid, and extends toward the vomer, where it meets the palatine, which completes the arch. The ecto-pterygoid lies above the junction of the meso-pterygoid and the palatine (Fig. 190).

Immediately in front of the vomer, and attached to it and to the palatines, are two considerable bones which project downward and backward, bounding the upper posterior portion of the canthus of the mouth—the *superior maxillaries*. In front of these, again, are the *pre-* or *intermaxillaries*, limiting the anterior boundary of the oral cavity above. Another bone, which in some forms (ex. catfishes) reaches the roof of the mouth, needs to be noticed in this connection. The suborbital ring, or those bones which encircle the orbit below, articulates by its most anterior piece (lachrymal) with a bone suturally united to the cranium and taking part in the boundary of the orbit in front and above. This is the *prefrontal*, and, as already remarked in the catfishes, owing to the width of the mouth takes part in the formation of its bony roof, and in some species bears teeth. This bone is frequently mistaken for the vomer, but, as I have recently ascertained, is certainly the prefrontal, which must likewise be added to the category of tooth-supporting bones in fishes.

The several arches and bones so far enumerated, with the exception of the scapular arch—which never, to my knowledge, is dentigerous—are in direct relation with the mouth, and are exclusively concerned in prehensile and crushing functions; but those which are to follow, especially

the branchial arches, were primarily used in connection with respiration, so that any relations with the teeth which they may have subsequently acquired must be looked upon as a secondary modification. This peculiarity, moreover, is of such wide application in the class *Pisces* that a description of these parts cannot well be omitted in a consideration of the accessory organs.

The hyo-branchial skeleton lies beneath the base of the cranium, and is pretty well concealed in a side view by the opercular, hyo-mandibular, and quadrate bones. It is connected with the rest of the skull at two points—viz. by the articulation of the stylo-hyal bone with the hyo-mandibular, and the other by means of loose connective tissue which binds the upper portion of the branchial arches to the base of the cranium. Its general structure will be best understood by describing it as composed of a series of transverse bony arches placed one in front of the other, rising up from the floor of the mouth and meeting in the median line above.

The most anterior of these is the *hyoid arch*, which is formed by two median basilar pieces upon either side, the *basi-hyals*. Passing from within outward, we have first the *cerato-hyals*, to which are appended the *branchiostegal rays*. The next piece in the arch is the *epi-hyal*, following which is the *stylo-hyal*. This latter bone is a slender rod, and serves to complete the connection of the hyoid arch with the hyo-mandibular bone. From the interval between the two most anterior basi-hyals there projects a small bone forward which supports the tongue, and is hence called the *ento-* or *hyo-glossal*. Projecting backward from the inferior surface of these same basi-hyals is another piece, the *uro-hyal*.

Behind the hyoid, and similarly composed, are the five branchial arches, of which the last two are somewhat modified. The three anterior ones are made up of median basilar bones, the *basi-branchihyals*. With these are articulated the *hypo-branchials* upon the outside, after which follow the *cerato-branchial* and *epi-branchial* pieces. In the fourth branchial arch, counting from before backward, the hypo-branchials are absent, and the uppermost segments are considerably dilated and support teeth; they are then known as the superior pharyngeal bones. The fifth arch is quite rudimentary, containing only the cerato-branchial elements, which are generally much enlarged and bear teeth; these are the inferior pharyngeal bones.

The arrangement here described is found without substantial modification except as regards relative size and the degree of ossification of the several parts in nearly all the sub-class *Teleostei*. In the *Elasmo-branchii*, however, the skull remains largely cartilaginous, and the hyo-mandibular arch is always more or less imperfectly represented. The maxillæ and premaxillæ are likewise absent. In the chimeroid division (*Holocephali*) neither the hyo-mandibular nor quadrate elements can be made out, the mandible being attached directly to a broad triangular cartilaginous lamella which stretches out from the sides of the base of the skull, and whose anterior part bears the teeth of the upper jaw. It will thus be readily understood that this cartilaginous plate, continuous with the chondro-cranium, represents both the undifferentiated upper portion of the hyo-mandibular and all of the palato-quadrate arches.

In the *Plagiostomi* (sharks and rays), on the other hand, a separate cartilaginous element representing the hyo-mandibular bone is always present, and affords an articular surface to the lower jaw or mandible, which, moreover, in all the elasmobranchiates consists of a single cartilaginous bar, the primitive Meckelian cartilage. The palato-quadrate arch is likewise present and forms the dentigerous border of the upper jaw (see Fig. 204). Since the hyo-branchial skeleton in these forms is not concerned in the support of teeth, it can be dismissed without further mention.

The principal deviations in the structure and relationship of the dentigerous apparatus from the typical teleostean one to be met with in the sub-class *Ganoidei* are furnished by the *Dipnoi* and *Chondroganoidei*. The former of these orders includes the three living genera *Ceratodus*, *Protopterus*, and *Lepidosiren* of Australia, Africa, and South America respectively. They are most remarkable and interesting representatives of types in some respects low down in the scale of ichthyic organization, while in others high, in that they furnish many transitional characters between true fishes and the Batrachia (frogs and salamanders). It is highly probable that from some as yet undiscovered relative of this group the Batrachia have been derived by descent.

In this order the skull is devoid of both maxillæ and premaxillæ, and, as in the chimeroid elasmobranchiates, the hyo-mandibular arch is not completely differentiated, the lower jaw being articulated directly to the cranium. There is, however, a well-defined palato-quadrate arch supporting teeth. The hyo-branchial skeleton, although resembling the teleostean type of structure considerably, is edentulous. In the *Chondroganoidei* (sturgeons) the skull as well as the arches remain largely cartilaginous. The suspensorium (proximal part of the hyo-mandibular arch) presents two elements, usually homologized with the hyo-mandibular and quadrate pieces of the teleostean skull; the latter of these pieces affords attachment to the mandible. There is also a palato-quadrate arch. Only one species of this group, the shovel-nose sturgeon, possesses teeth, and these, according to Owen, appear only in the young.

The remainder of the *Ganoidei* agree with the *Teleostei* in the structure and arrangement of the accessory organs. The latter sub-class, however, exhibits numerous minor variations, which are confined principally to modifications of the hyo-branchial skeleton, such as the loss or atrophy of certain of its component elements; these are so numerous and varied in their nature that it would be impossible, and quite foreign to the object of the present article, to enumerate them.

Teeth of the Elasmobranchii.—As already observed, this class is divisible, not only by the differences which obtain in the arrangement of the several arches, but by the disposition, structure, and manner of replacement of the teeth, into two primary groups, of which the sharks and rays constitute one, and the Chimæræ the other. Of these, the former is the more primitive, and in all probability gave origin to the typical fishes, while the latter resembles more closely the dipnoans, and may indeed prove to have been their ancestors.

The teeth of the sharks are always numerous, and are pre-eminently adapted to the predaceous habits of their possessor. They are borne

upon the cartilaginous mandibuli and palato-quadrate arches, being attached not to the cartilages themselves, but to a thick, dense fibrous membrane which forms an external investment. They are arranged in concentric rows on the summit and inner surface of the jaws, being developed from the bottom of a longitudinal fold of the lining membrane in this situation, known as the *thecal fold*. The teeth of the uppermost row, or those occupying the margins of the jaws, stand upright and do service as the functional ones until discarded; those of the next row, as well as all the succeeding ones, usually occupy a recumbent position, with their apices directed downward or upward according as they belong to the upper or lower series; but it not unfrequently happens in some species that the second, and even the third, rows may exhibit different degrees of erection. As a general rule, but a single row of teeth are in use at one time. The individual teeth composing the longitudinal rows may be disposed with reference to those of the succeeding ones so as to be parallel vertically, as is well exemplified in the genus *Lamna*, or they may be placed in such a manner as to alternate with each other, a condition seen in the blue shark (*Carcharias*). As would naturally be surmised from this arrangement, the way in which succession takes place is for the row beneath to rise up and take the place of those in use. This is accomplished by the fibrous gum in which their bases are imbedded sliding bodily over the curved surface of the jaws from within outward, continuously bringing fresh rows into position, as was long since demonstrated by Prof. Owen.

It thus happens, on account of this peculiar and, in my judgment, remarkably primitive manner of succession, that large numbers of teeth little worn are cast off during the life of each individual, and that replacement goes on far in excess of the actual requirements of the animal, and quite independently of their temporary use as organs of prehension and mastication—a fact which in itself demonstrates their dermal relationship. The only assignable cause for this extravagant development of teeth, it appears to me, is due to inequalities in the rapidity of growth in different parts of the body, which causes the integument invaginated during embryonic development to be restored or evaginated during adult growth. If this hypothesis be correct, then the whole question of the force concerned in the succession of the teeth is reduced to the simple explanation of inequalities of growth primarily, however much it may have been subsequently complicated and obscured in the higher forms. Looked at from this standpoint, it is not such an inscrutable mystery as C. S. Tomes and others would have us believe.

Considerable variety of form exists in the teeth of the different species; they may be *heterodont* (that is, different in various parts of the jaws); *isodont* (alike throughout); or *hemihomodont* (in which the individual teeth of the lower jaw are alike, but different from those of the upper jaw, and reciprocally). In all, the teeth nearest the back part of the mouth are smaller than those in front. The simplest form to be met with is the unmodified cone with a sharp point and a broad base. Such is found in the large *Rhinodon* and some "dog-fishes;" to this may be added basal denticles, as in the genus *Lamna;* or it may have a compressed triangular outline with serrate edges, as in the upper teeth of

the blue shark (*Carcharias*). These lateral serratures may become so strongly developed as to give to the tooth a distinct comb-like appearance—*e. g.* lower teeth of *Notidanus* (Fig. 191).

Fig. 191.

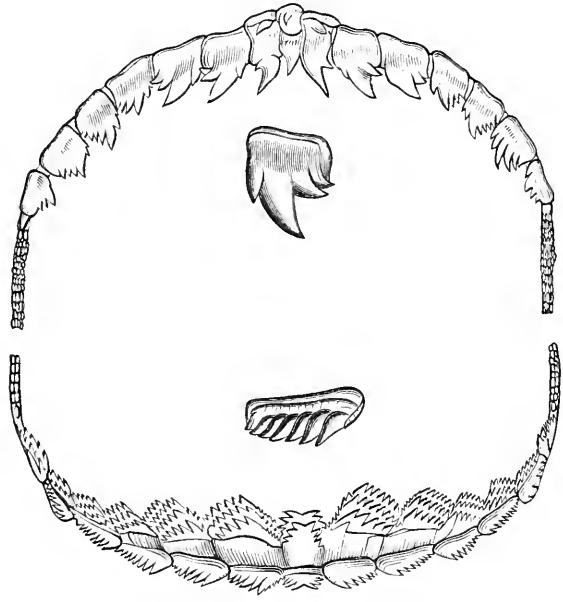

Teeth of *Notidanus* (after Gunther).

The most remarkable modification in the dental organs of sharks is exemplified by the Port Jackson shark (*Cestracion*), in which the posterior teeth gradually become broad and form a regular pavement on the surface of the jaws similar to that seen in many rays. This structure exists in consonance with the shellfish-feeding habits of the animal, in the exercise of which great crushing and comminuting power is required to be exerted. These fishes are of especial interest, inasmuch as they are the only living representatives of an extensive and widely-distributed group which appeared on the earth far back in the Devonian Epoch, and whose remains, as Owen justly remarks, "would have been scarcely intelligible to us unless the key to their nature had been afforded by the teeth and spines of the living cestracionts."

The teeth of the anterior part of the jaw (Fig. 192) are the smallest, and present a compressed conical form with the apex produced into a sharp point. Proceeding backward, they gradually assume an oblong oval outline, progressively increasing in size, their sides becoming applied to each other in such a manner as to form a regular pavement. The maximum size is attained at about the fourth tooth from the posterior end of the series, after which they decrease rapidly, although still preserving their modified crushing form.

The progressive changes in size and form, as well as the disposition, of the most highly modified teeth in this animal, are seen to be in direct accord with the uses to which they are put, and serve to illustrate, as so

many other dentitions do, the reasonableness of the view originally proposed by J. A. Ryder, to the effect that mechanical causes have been largely instrumental in bringing about the modifications of the teeth. It will be readily understood that the greatest mechanical advantage would be gained and the greatest pressure exerted by passing the morsel to be crushed to the posterior part of the mouth. The teeth in this situation or in its vicinity have sustained the greatest amount of strain, and are consequently most modified, while those of the anterior part of the mouth have been largely exempt from such influences, and are therefore little modified. I will have occasion to recur to this hypothesis on a future page.

The teeth of the rays present quite as great, if not a greater, range of variety than do the sharks. In general, they are more numerous, more closely crowded together, and possess forms better adapted for crushing than for seizing and lacerating. They are developed in the same way as in sharks, rising up from the bottom of a thecal fold on the inner surface of the jaw and being carried upward by a rotation outward of the

FIG. 192.

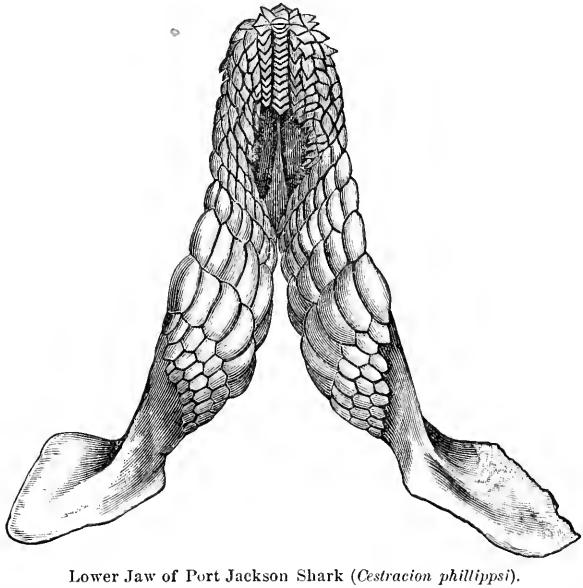

Lower Jaw of Port Jackson Shark (*Cestracion phillippsi*).

membrane in which they are imbedded. In *Raia stelluata*, from the California coast, the teeth succeed one another vertically, as in *Lamna* among the sharks, and do not form a close pavement on the biting surface of the jaws, they being separated from each other by slight intervals. In form the base of the crown represents an equilateral triangle, with the apex directed forward; from this a prominent ridge passes backward across the middle line of the base, and is produced into a sharp conical point. The teeth of the anterior part of the mouth are the largest, and gradually decrease in size as the canthus or angle of the mouth is reached. In the "barndoor skate" (*Raia lævis*) the teeth

are more closely set, but are not in absolute contact; as in *Raja stelluata*, those of the several rows are arranged vertically, but their bases are more rounded, with only a faint indication of the backwardly projecting cusp, which is confined to the teeth of the anterior part of the jaws.

In the common "stingray" (*Trygon centrurus*) the teeth are somewhat quadrangular, and have their sides directly applied to each other, forming a dental sheath of continuous pavement over the working surface of the jaws; those of the successive rows are disposed diagonally. Their crowns are of an oval form, well adapted for crushing and grinding hard substances. The "eagle rays" or "sea-devils" present a series of modifications of the teeth which diverges from that of the stingrays, and terminates in the most unique of all dentitions to be found amongst the Vertebrata—viz. that of *Aëtobatis*. Of this group the genus *Rhinoptera* possesses tessellated teeth with flat hexagonal crowns, of which

FIG. 193.

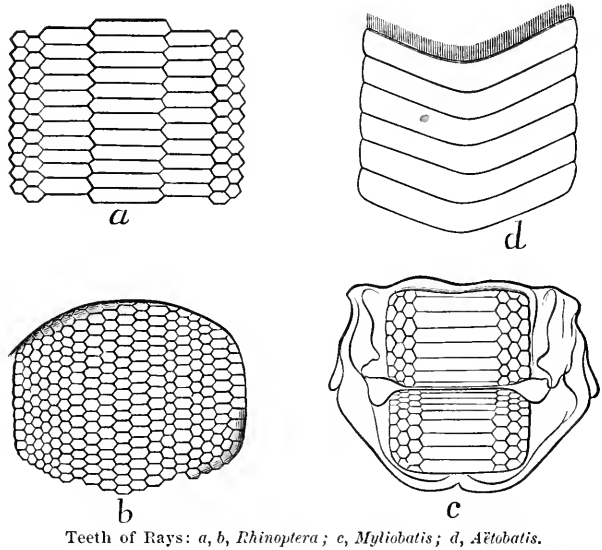

Teeth of Rays: *a, b, Rhinoptera; c, Myliobatis; d, Aëtobatis.*

the median or anterior ones may be elongated transversely. The fossil species, *R. Woodwardi*, has the three median vertical rows enlarged. In *Myliobatis* there is only one large median row, with three smaller ones upon either side, while in *Aëtobatis* the teeth of the median row alone remain, and are articulated to each other by a finely serrate border. These modifications are well shown in the accompanying figures. The anomalous sawfish (*Pristis*), although in no way peculiar as far as the teeth of the mouth are concerned, nevertheless possesses a remarkably elongated snout, armed upon either side by a row of hard, conical bodies usually referred to as teeth. In their histological structure they agree with true teeth, but exhibit the peculiarity of being lodged in separate sockets and growing from persistent pulps—a condition unusual among fishes. It is more than probable that they are dermal spines specially developed in this situation for some important purpose which is not at present fully determined.

I proceed next to consider the teeth of the Chimæræ (*Holocephali*), which group some authors make equal in rank with the *Elasmobranchii*, which then include the sharks and rays only. The peculiarities of the dental succession alone of this latter group, it appears to me, is quite sufficient to separate them widely from all others, and it seems somewhat remarkable that this character has never been utilized by the systematists in their schemes of classification.

The teeth of the "ratfish" (*Chimæra plumbea*) are six in number, of which two belong to the lower and four to the upper jaw. The two inferior ones may be described as broad, slightly-curved plates of moderate thickness in the form of a right-angled triangle. That border which corresponds to the perpendicular is almost straight, and is lodged in a shallow groove which runs lengthwise along the inner surface of the jaw; that which represents the base is applied to the corresponding surface of the opposite tooth; while the border representing the hypothenuse forms the free cutting edge of the tooth. This border is somewhat devious, being interrupted by three prominences. The inner surface is also slightly ribbed. The two posterior upper teeth are similar plates of a quadrilateral form with their free edges roughly serrate. The two anterior teeth above somewhat resemble ordinary mammalian incisors, and are large and scalpriform. This peculiarity has given them the name "rabbit-fish" or "ratfish." Each tooth has a cavity in the edge by which it is attached and in which the pulp is lodged. But a single set of teeth are developed during the life of the individual, and these are of persistent growth. Another living allied genus, *Callorhynchus*, is found in Australian seas, in which the teeth are similar to those of Chimæra, but in the two fossil genera, *Edaphodon* and *Passalodon*, supposed to belong to this group, the teeth are ankylosed to the jaw, which is more or less bony. On this account it is more than probable that they are to be referred to the dipnoans rather than to the chimæroids.

The Teeth in True Fishes.—The teeth of the class *Pisces*, although apparently presenting an extensive range of modification, have not, debarring the dipnoan ganoids and the plectognath teleosts, as a general rule, departed very widely from the simple conical pattern. There are some forms, however, in which the structure and arrangement are quite anomalous. It is in this group that the maximum development, as far as numbers is concerned, is reached. The salmon, pike, and some percoids may be cited in which teeth are developed in almost every conceivable part of the mouth and number many thousands; while in others, as the carps and suckers, they are few and confined to the pharyngeal bones. In others, again, as the pipefishes and sea-horses, teeth are entirely absent.

The teeth of the dipnoans are unique among fishes, and, like those of the chimæroids, are limited in number and grow from persistent pulps. The teeth of the dipnoans, the dental plates of the chimæroids, and the so-called "rostral teeth" of the sawfish are the only examples so far known of permanent teeth to be met with among piscine forms.

The dental armature of *Ceratodus Fosteri* (Fig. 194), which may be taken as illustrative of this peculiar group, has six teeth, of which four

Fig. 194.

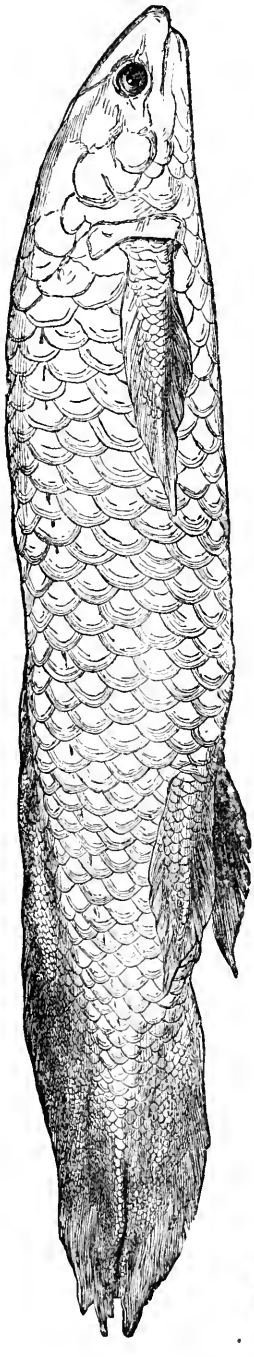

belong to the upper and two to the lower jaws. Those of the upper series are supported upon the palato-quadrate arches and upon a cartilaginous plate which corresponds in position with the vomer. Those of the lower series are set upon the inner piece of each dentary bone, and become firmly attached thereto by ankylosis.

The two most anterior, and by far the smallest of the upper pairs of teeth, form cutting plates which resemble somewhat the crown of a broad incisor with the posterior border well rounded off. They are arranged in the form of a V, with the point directed forward, having their greatest extent in an anterio-posterior direction. After a considerable interval the two large peculiarly constructed upper back teeth appear, similarly placed in the form of a V, and co-ossified with the bony arches. Their greatest length is quite equal to one-third the entire length of the skull, the breadth being much less. Each of these dental plates—for such they may be properly called—has a slightly curved internal border, with the convexity directed inward. The

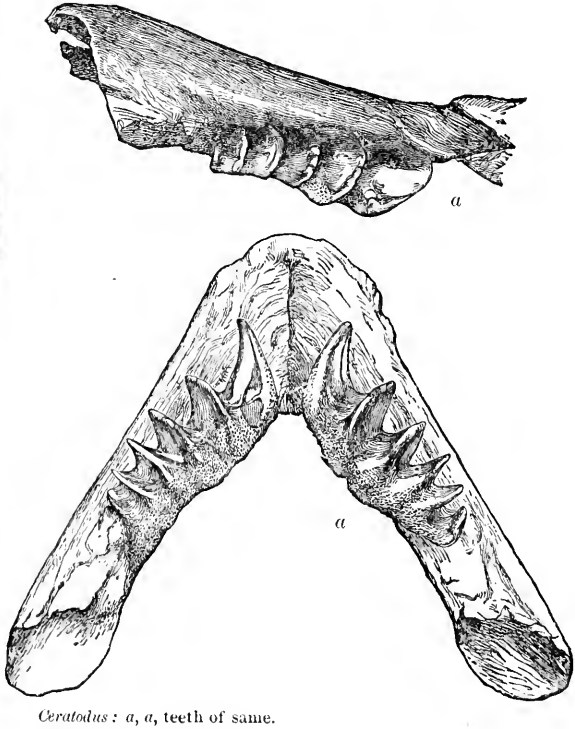

Ceratodus: *a*, *a*, teeth of same.

lower or working face presents internally a considerable flat pitted surface reaching the entire length of the tooth, whose plane is directed outward and a little upward. It is slightly broader in front than behind. The outer border is indented by five wide vertical grooves, forming six vertically convex lamelliform projections, which encroach somewhat upon the flat surface internal to them as well-defined parallel ridges; the anterior one passes entirely across the face of the tooth, or, rather, skirts its anterior margin, and becomes continuous with the slightly elevated internal border in this situation. The grooves are deeper in front than behind, leaving the anterior projections the most pronounced, while the last one is scarcely perceptible. The points of the projections describe a gentle curve from before backward, the convexity being outward.

The two teeth of the lower jaw are very similar to those of the upper, but are somewhat narrower, owing to a decrease in width of the flat pitted surface. As already stated, they are ankylosed to two plates of bone which cover the inner and half of the lower surface of Meckel's cartilage or the central axis of the lower jaw. It will thus be seen that each ramus of the mandible consists of an inner and an outer bony plate enclosing the central cartilaginous axis, which meet in the median line below. To these is added a third piece at the symphysis on its lower surface, so that the bony part of the jaw—which in all probability corresponds with the single dentary piece in other fishes—is made up of three, one of which bears teeth. This fact is of great morphological significance, and will be referred to again when we come to discuss the attachment of the teeth.

In the two allied genera *Protopterus* and *Lepidosiren* the teeth are very similar to those of *Ceratodus*, but in numerous extinct forms referred to the dipnoans a considerable amount of variety exists. As regards the development of the teeth in this group, very little is known, and until this has been studied it will be impossible to say whether the dental plates are moulded upon a single papilla or represent the combined calcification of several. Judging from their complexity, the latter would seem to be the case.

The teeth of the remaining ganoids are of the ordinary conical form which prevails to so great an extent in the *Teleostei*. In number, position, replacement, etc. they likewise agree so closely with the average teleost dentition that it is unnecessary to make any further mention of them.

Among teleosts, however, there are several well-marked modifications in the dental armature which deserve to be noticed. One of these is presented by the *Plectognathi* (plaited jaw), of which the "trigger-fish" (*Balistes vetulus*) and the "swell toad" (*Diodon geometricus*) represent the extremes in dentition. The teeth of the mouth of *Balistes* are twenty-two in number, of which fourteen belong to the upper and eight to the lower jaw. Those of the superior series are disposed in two rows, one placed immediately behind the other, and both are lodged in the premaxillary bones. The most anterior of these rows contains eight teeth, while in the posterior one there are only six. In the front row the mesial pair are the largest, of a subtrihedral form, tapering gradually to an obtuse point. Those upon either side decrease regu-

larly in size toward the back part of the jaw, and have notched cutting extremities.

The teeth of the posterior row are applied closely to those of the front row, and are completely concealed when the mouth is closed. They have a broader, more incisiform pattern. The teeth of the lower series are like the corresponding ones of the upper front row, and are lodged in the dentary bone. They are attached by slight ankyloses to the respective bones upon which they are supported by having their bases placed in a shallow alveolar depression, in the middle of which a conical process of bone rises up and is received into the hollow basal portion of the tooth. The successors of those in use are developed deep down in the substance of the jaws, in bony crypts which communicate with the exterior by means of foramina in the side of the jaws in the vicinity of the bases of those in use. All the teeth in this species are said by Owen to be covered with enamel. There are likewise small conical hooked teeth developed upon the pharyngeals.

While the teeth of *Balistes* are more nearly affiliated with the normal teleost condition, those of *Diodon*, on the other hand, show a much wider departure. When the mouth is closed the biting surface of the jaws seems to be invested with a continuous covering of tooth-substance; upon close inspection this is found to consist of a number of dentine plates closely incorporated with the bone of the jaws and more or less fused together at the base. Each one, however, develops separately, and takes its place when its predecessor has disappeared through wear. Just inside the margin of each jaw, in the middle line, is to be seen a broad rounded mass consisting of transverse plates of dentine intimately blended and ankylosed to the jaw bones. A faint median longitudinal suture divides each into two parts; when this becomes more distinct and extends to the edge of the jaw, as it does in some species, it constitutes the mark of generic distinction of the genus *Tetrodon*. The plates composing this mass, which is peculiar to these fishes, are developed in the same manner as the teeth, and are strictly homologous with them.

Many other examples quite as peculiar as the last one could be cited among the dental organs of fishes, but more time and space would be required than is afforded the present paper.

The mode of development is essentially the same as that described for the mammal, with the exception that the dental sacculus is generally simple; the dentine papilla arises from the corium, and the oral epithelium dips down to form a cap-like investment, in both of which calcification takes place in the manner already described. With regard to the succession and attachment of the teeth in this group, as well as in the Batrachia and Reptilia, some preliminary points in the development of the jaw bones must first be noticed.

In the early stages of embryonic development each jaw is primarily made up of two cartilaginous bars which meet in the median line in front. In the upper jaw these bars are known as the palato-pterygoid bars, and in the lower jaw as Meckel's cartilage. In the elasmobranchs these bars persist, and the teeth are supported by them. As a consequence of this condition, as we have already seen, succession in them

takes place by a movement of the fibrous gum, in which the bases of the teeth are imbedded, outward over the curved surface of the jaw. Coincidently, however, with the ossification of the skeletal axis the osseous bases of the dermal denticles coalesce to form the dentary bones, as has been shown by Hertwig. By reason of the development of this bony envelope of the primitive axis of the jaw, any further movement of these denticles is prohibited, being firmly co-ossified with it.

During the coalescence of the denticles a portion of the primitive tooth-bearing membrane is enclosed beneath the fused osseous plates, and retains its original formative energy, thereby furnishing a source of supply quite equal to that of the sharks. The denticles whose basal plates form the sides and under portions of the dentary bones disappear, while those on the summit of the jaw are retained as teeth. A conformation of this position by evidence other than that afforded by embryology is seen in the dentary bones of *Ceratodus*, in which each one is made up of three or four pieces which have failed to coalesce.

The attachment of the teeth, therefore, in this group, as we would be led to anticipate, is by ankylosis to the dentary and other bones which support them. Still, there are many brush-like structures which are identical with true teeth to be found in the mouths of many fishes, which remain imbedded in the lining membrane and do not develop any connection with the underlying bones. There are several ways by which the teeth become fixed to the jaw bones in ankylosis, but the most common is for the central axis of the tooth to be occupied by a cone of osteo-dentine, which blends with the bone of the jaw. Several families of fishes have some of the teeth attached by an elastic hinge, by which they can be bent down in one direction and resume an erect attitude.[1]

Teeth of Batrachia and Reptilia.

As we pass from the dental organs of the more typical fishes to those of frogs, salamanders, newts, etc., constituting the batrachian subdivision, a marked diminution in the number of individual teeth is to be observed. With the appearance of perfected air-breathing organs the complex hyo-branchial skeleton, typical of the fishes, becomes greatly reduced and simplified as the higher forms are approached; consequently, the branchial and pharyngeal teeth disappear in all the Vertebrata above fishes.

In all those Batrachia in which teeth exist they are usually disposed in a single row on the borders of the jaws, and are supported by the maxillary, premaxillary, and dentary bones respectively. In addition to these, each vomer (for there are two) bears a single row of teeth, between which and the maxillary row the lower jaw bites. As a rule, the Reptilia, on the other hand, lack the vomerine set, but in some of them (serpents, for example) teeth are developed upon the pterygoids and palatines, as well as upon the maxillary and dentary bones.

The teeth of the Batrachia present so limited a range of variation that the description of one will serve to give a general idea of the dentition of the whole group.

[1] This fact was first noticed by Prof. Gill.

It should be stated here that some of the tailless species (toads) are quite edentulous, while in others (the frogs) teeth are absent in the lower jaw. All the existing tailed batrachians, however, are provided with teeth which present practically the same pattern and disposition which obtains throughout the entire sub-class.

An excellent and easily-obtained example of this latter subdivision is found in the Alleghany *Menopoma*, popularly known as the "hell-bender." In this animal the skull is remarkable for its flatness and breadth, as well as the almost perfect semicircular outline which the dentigerous surface of the jaws presents. The mandible, as in the fishes, is composed of angular, articular, and dentary pieces, and is suspended to the cranium by means of two bones known as the squamosals through the intervention of the quadrates.

The palato-quadrate or palato-pterygoid arch is not so well defined, although the principal elements are present. The vomers are two in number, and occupy their usual position behind the maxillaries, sharing in the formation of the bony roof of the mouth. The maxillaries and premaxillaries also have the same position as in the fishes, but are less mobile, on account of sutural connections with the surrounding bones.

The biting surface of each jaw is produced into a sharp ridge by reason of the existence of a well-marked ledge extending the full length of its internal face. This ledge is converted into a groove in the recent state by a fold or flap of the gum, which forms its internal wall, and is in all probability homologous with a similar structure (the thecal fold) found in the sharks. At the bottom of this groove the tooth-germs of the successive sets of teeth are developed. It will be seen, therefore, that the general arrangement is not different from that of the sharks; but this important difference is to be observed: in the sharks the bases of the teeth are at first directed upward, and it is only when they are about ready to take position on the working surface of the jaw that they assume the erect attitude; this, as we have already seen, is due to the movement of the entire gum outward. This manner of replacement gives weight to the conclusion that the teeth in the sharks are invaginated dermal spines, the position of which we would expect to find reversed upon the inside of the jaws.

In the batrachians, on the contrary, the teeth are said to have an erect position from the earliest stages of development, and it is less easy to see how they represent dermal spines or how the position came to be reversed. Believing, however, that all the maxillary and mandibular teeth were originally of tegumentary origin, as is clearly demonstrable in the sharks, it is more than probable that the arrest of the outward movement of the gum in the batrachian by the appearance of ossifications around Meckel's cartilage to form the dentary bones is responsible for this change. It is quite possible that the tooth-germs of the batrachian do at first have the same position as those of sharks—that is to say, with the points directed downward—and that the formative energy of the tissues beneath causes them to become erect at a comparatively early period.

We have already stated, in connection with the account of the dental organs of the elasmobranchs, that tooth-succession is primarily due to

the evagination of the lining membrane of the oral cavity. Whether this is caused by unequal rate of growth of the surrounding parts, whereby this lining membrane is forcibly pulled outward and replaced from within, or whether the formative energy inherent in the membrane itself causes it, is difficult to determine. This primary cause of succession is profoundly affected by the development of an osseous sheath from this same membrane around the central cartilaginous axis of the jaws. It seems plausible that secondarily the cause of tooth-succession is to be sought for in the proliferation of the cellular elements beneath the young and growing germ.

To the inner side of the external osseous wall of this groove in *Menopoma* the functional teeth are attached; their bases are slightly enlarged and extend quite to the bottom of the groove, while the tapering crowns reach considerably above the level of the jaw. Attachment takes place by the ankylosis of that part of the base which is in contact with the outer wall to the bone of the jaw through the intermediation of osteodentine. This manner of implantation is known as "pleurodont," on account of the fancied resemblance of the teeth so attached to ribs.

The teeth in use at any given time are from thirty to forty in number upon either side in each jaw; they are subequal in size, and are placed with great regularity, being separated by spaces about equal to the width of a single tooth. Their crowns are sharp-pointed and slightly recurved; they are said in some species to be tipped with enamel, which is probably true of all. The vomerine teeth are fewer in number than the maxillary, there being not more than twelve or fifteen upon either side. Their line of direction and manner of implantation coincide with the maxillary row external to them, agreeing with those also as to size and form.

In some of the extinct batrachians, notably the labyrinthodonts, there were several teeth of the maxillary and premaxillary set considerably enlarged and of a caniniform pattern. The species of this section were mostly of large size and presented a formidable dental armature. They likewise differ from all other of the Batrachia in that the teeth were implanted in distinct sockets, and were rarely if ever attached to the body of the jaw by ankylosis. The structure of the teeth is a curiously complex one, and finds no parallel throughout the entire Vertebrata, save in one extinct saurian (*Ichthyosaurus*) and several fishes, which exhibit a similar condition in a less perfected degree.

The external surface of the crowns of the teeth in the labyrinthodonts is marked by a number of longitudinal ridges, separated by what at first sight would appear to be comparatively shallow grooves extending from the base to the apex of the crown. Upon cross-section, however, these fissures are seen to penetrate into the body of the tooth to a remarkable depth—to a point, in fact, quite near the pulp-cavity or central axis of the tooth, where they are separated from it by a thin wall of dentine. The entire outer surface is covered by a thin layer of cement, which is reflected inward to the bottoms or internal terminations of the fissures just mentioned. The cut edges of this reflected layer of cement, which is of uniform thickness throughout, are almost straight for a short distance beneath the surface, but soon become very

tortuous. The arrangement of the dentine is as follows: The axial portion of the tooth consists of a central cone of dentine hollowed out in the centre to receive the pulp. In cross-section this cone appears as a ring surrounding the pulp-cavity; from it plates of dentine, which are cleft by the fissures from without, radiate to the periphery, pursuing the same tortuous course as that of the fissures. These dentinal plates are separated from each other by fissures which radiate from the axial cavity, but do not reach the exterior of the crown. Some of the dentinal plates do not arise from the central ring, but appear on transverse section as processes from the periphery of the crown directed toward the central axis, thus causing the fissures which radiate from the pulp-cavity to become bifurcated at their outer or peripheral terminations. Some of these accessory processes reach but a short distance toward the interior, while others penetrate halfway or more to the centre.

This complexity in the arrangement of the tooth-substances has suggested the name of the typical genus, *Labyrinthodon*, which was originally described by the great anatomist Prof. Owen. Just how it has been produced is difficult to understand.

Teeth of the Reptilia.—This class of vertebrated animals includes snakes, lizards, crocodiles, turtles, etc., and, considering the extinct as well as the recent forms, is divisible into eleven distinct orders, according to Prof. Cope's classification. Of these, but five are represented in the existing fauna, the others having become extinct in the different epochs of the earth's history.

The batrachians make the nearest approach to the permanent gill-breathing vertebrates in all the essential features of their structure; the Reptilia, on the other hand, furnish us with the transitional forms leading to the avian and mammalian stems. It is a very significant fact—and one upon which the doctrine of evolution is primarily based, so far at least as the Vertebrata are concerned—that the lowest forms appeared first in the order of time, and were followed by those higher in the organic scale; thus we have the cartilaginous fishes as the earliest representatives of vertebrated animals; after them come the batrachians; next the reptiles and birds, and finally mammals. It must be borne in mind, however, that the highest of one group is not always most nearly related to the group next above it; for example, if we compare the structure of a bony fish with that of a salamander, a great interval will be found to exist, but if we institute a comparison between the latter and a dipnoan fish, which is comparatively little removed from the cartilaginous forms, this interval will be found to be materially diminished. Thus, the conclusion is obvious that the Batrachia sprang not from the higher bony fish, but from some generalized representative of the piscine type. The same reasoning can be applied to other divisions.

As regards the Reptilia, the chief distinction between them and the Batrachia consists in the circumstance that the latter during the larval stages of their existence breathe by means of gills like the fishes, whereas the Reptilia breathe by means of true lungs from the time of birth. Important osteological differences are found in the bones of the skull.

The earliest appearance of the Reptilia dates back to the Permian Epoch, where they are represented by a group of peculiar batrachian-

like reptiles which has been designated the *Theromorpha* by Prof. Cope. This group includes two important divisions, one of which, the *Anomodontia*, was first described by Prof. Owen from the Triassic (?) deposits of South Africa; the other is the *Pelycosauria*, which is so far known only from the American Permian.

The osteological structure of this order furnishes us many transitional characters between the Batrachia and more typical Reptilia, on the one hand, while on the other they seem to stand in ancestral relationship to the prototherian Mammalia. Their batrachian affinities are manifested in the structure of the pectoral and pelvic arches, in the structure of the limbs, and the possession of teeth on the vomer. In the absence of a parasphenoid bone in the base of the cranium and the unicondylian condition of the skull they are markedly reptilian. The structure of the pelvic and pectoral arches and limbs, together with the intercentral articulation of the ribs, allies them with the lower Mammalia.

Their dental organs present a considerable variety of structure—in some instances departing widely from the simple conical form usual among the other orders of this class of the Vertebrata. In one genus (*Dimetrodon*) there were two large caniniform teeth in each premaxillary, implanted in distinct sockets; these were followed by a single row of maxillary teeth, whose crowns resemble somewhat the premolars of the dog in general pattern. They were lodged in distinct alveoli, and exhibit the remarkable peculiarity of being implanted by double fangs, or rather single ones deeply grooved upon either side, otherwise unknown among the Reptilia. The first tooth behind the maxillo-premaxillary suture is enlarged into a canine, and the entire maxillary series does not exceed fifteen in number. The palato-pterygoid arch is present, and one of its elements, probably the pterygoid, is thickly studded with small conical teeth irregularly disposed. Another element which lies internal to this last-mentioned bone is described by Prof. Cope as bearing a single row of teeth. Other genera related to this one are *Theropleura*, *Clepsydrops*, etc. of Cope, which present minor differences in the form and size of the corresponding teeth.

A nearly-allied family of this group is the *Diadectidæ*, likewise described by Cope. A typical example of the dentition of this family is seen in *Empedocles molaris*, wherein the pattern of the crowns of the molars is thoroughly unique. The teeth are disposed on the borders of the premaxillary, maxillary, and dentary bones, as well as upon the vomer, which forms a median keel in the roof of the mouth. The maxillo-premaxillary set in the upper jaw describe a sigmoid curve in their line of implantation, and form an uninterrupted series from the front to the back of the mouth. There are fourteen teeth belonging to this series, of which the first two are larger than those immediately succeeding them. They have obtuse subconic crowns, and are lodged in distinct alveoli. From this point the teeth gradually decrease in size up to the sixth, when they again become larger and more complex in pattern. The crowns of the typical molars have a much greater transverse than longitudinal extent; the grinding surface is somewhat elliptical in outline, and is provided with a submedian cusp which stands nearer the outer than the inner border. The portion of the crown external and

internal to the median cusp is horizontal, and has its surface thrown into conspicuous folds or wrinkles. The teeth of the lower jaw are essentially like those of the upper. The vomerine teeth are small and conical, and are disposed in two longitudinal rows.

In the typical genus (*Diadectes*) there is a well-developed canine, while in another member of the family (*Helodectes*) there are canines and a double row of maxillary teeth upon either side in the dentigerous surface of these bones.

In the other subdivision of this order—viz. *Anomodontia*—the dentition is reduced to large pointed, recurved tusks, which are lodged by distinct sockets in the maxillary bones. The rest of the jaw is edentulous, and was in all probability ensheathed in a corneous substance, as in the existing turtles. Other extinct members of this subdivision, notably *Rhynchosaurus* and *Oudenodon*, were entirely edentulous, and in all probability were the ancestors of the turtles.

That division known as the *Crocodilia* includes the alligators, crocodiles, gavials, etc., which are separated from the other Reptilia by a number of important osteological characters, prominent among which is the complete development of the bony roof of the mouth. Teeth are supported by the premaxillary, maxillary, and dentary bones only, the palatines and pterygoids having approximately the same relations and edentulous condition as in the mammalian skull. In no crocodilian so far known are the teeth ever ankylosed to the body of the bones upon which they are borne, but, on the contrary, they are set in distinct sockets disposed in a single row along the margins of the tooth-bearing bones. In young specimens the alveoli are apt to be ill defined, more especially toward the back part of the jaws, but as age advances the bony partitions become more distinct. On account of each tooth having a distinct alveolus, this division of the Reptilia was formerly known as the thecodonts, in contradistinction to the pleurodonts—a condition already mentioned in connection with *Menopoma*—and acrodonts, presently to be described.

A good example of the dentition of a crocodilian reptile is afforded by the Mississippi alligator (*Alligator Mississippiensis*), which can be found in almost any osteological collection in this country. In the upper jaw there are from eighteen to twenty-two teeth upon either side, of which five are usually set in each premaxillary and the remainder in the maxillary bones. The most anterior of the premaxillary series is the smallest, from which they gradually increase in size to the fourth, which is nearly twice as large as any of the others; the fifth is about equal to the third. The first of the maxillary series is likewise the smallest; the three succeeding teeth gradually increase in size until the third is reached (the ninth counting from the first tooth in the premaxillary), which is known as the canine of the upper jaw. The eighth and tenth are frequently as large as the canine. Behind, the teeth become smaller, and are again enlarged in the vicinity of the sixteenth or seventeenth from the first premaxillary tooth; from this point they rapidly diminish toward the posterior end of the tooth-line.

In the lower jaw the teeth are likewise of unequal proportion, but those which are largest in the one series are opposed by the smallest of

the opposite set; thus that tooth which is caniniform in the lower jaw is the fourth, and bites in front of the corresponding tooth above. It is received into a deep fossa in the upper jaw just internal to the alveolar border at the point of junction of the maxillary with the premaxillary bone, or between the fifth and sixth teeth above. It not unfrequently happens in old specimens that this fossa is converted into a foramen leading to the external surface of the skull by the perforation of its base. In such cases the point of the lower canine passes through the upper jaw and appears upon the upper surface.

The only important distinction between the alligators and the crocodiles consists in the fact that in the latter this fossa is open externally, causing the tooth-line to be interrupted by a deep notch, whereas in the latter it is intact.

Both the alligators and the more typical crocodilians are remarkable for the breadth of the palate and the flatness of the muzzle, as well as the alternate increase and decrease in the size of the teeth from before backward; but in the gavials the snout is very long, narrow, and almost cylindrical; the teeth, too, are more nearly equal and of more regular proportions.

In the alligator the anterior teeth have conical crowns terminating in sharp points, which are slightly recurved. The posterior ones have more obtuse crowns, which terminate below by a moderately well-defined neck. In some species the anterior and posterior surfaces of the crowns are produced into trenchant edges, which may be more or less serrated; in the alligator this is but faintly marked.

The manner of succession is not different from that of the other lower vertebrates. If the root of a tooth in place be exposed, the successional sets in various stages of development will be seen below and to the inside of it, arranged in the form of a nest of crucibles. This arrangement results by reason of the absorption of the inner wall of the root of the tooth in place which the immediate successor causes. By this means the point of its crown comes to occupy the pulp-cavity of the functional tooth.

In the order *Lacertilia*, which includes the lizards proper, a more varied development of the dental organs is met with. As a general rule, teeth are borne upon the pterygoid and palatine as well as upon the maxillary, premaxillary, and mandibular bones. There are, however, some exceptions, one of which is afforded by our little "horned toads" (*Phrynosoma*), in which the palatines and pterygoids are edentulous. The teeth may be either "pleurodont" or "acrodont" in their manner of implantation, but in certain extinct forms (*e. g. Mososaurus*) both conditions are to be observed. In the case of acrodontism the bases of the teeth are soldered to the summits of slight elevations which arise from the alveolar border of the jaws. Pleurodontism, as has already been mentioned, consists in the ankylosis of the base and outer sides of the teeth to the outer wall and bottom of the dental groove. Another variety of implantation, known as cœlodontism, has been described, in which the tooth has a permanent pulp-cavity, and is attached to the outer wall, leaving the base free; it should be mentioned that in pleurodonts the pulp-cavity is not permanent; it soon becomes obliterated, leaving the tooth solid.

A fair example of a pleurodont lacertilian is afforded by the majority of the numerous species of the *Iguanidæ*, although some of the members of the iguanian family, such as *Isturus*, *Lophyrus*, *Calotes*, and others, are acrodont. In the horned iguana (*Metopoceras cornutus*) the maxillary and premaxillary teeth are from twenty-two to twenty-three in number upon either side. The central ones of the premaxillary set, of which there are four, are smallest, the outer ones slightly enlarged. These, together with the first five or six maxillary teeth, have subconic recurved crowns, while the crowns of the posterior maxillary series are laterally compressed into anterior and posterior cutting edges and terminated by a principal cusp. Of the two edges, the anterior is the longer and is interrupted by three minor cusps, the posterior being shorter and bearing only a single accessory cusp. The presence of these cusps gives the crown a serrated appearance when viewed from the side.

The teeth of the lower jaw are from twenty to twenty-two in number upon either side, and are similar in form to those above, with the exception that there are generally two accessory cusps upon either trenchant edge of the crown. There is in addition to these a single row of small conical teeth supported by each pterygoid bone; the number of these varies from five to seven.

The only lacertilian which is known to be poisonous is the "Gila monster" (*Heloderma suspectum*) of our American fauna. Recent experiments of Drs. Mitchell and Reichart of Philadelphia have demonstrated beyond doubt the poisonous qualities of its salivary secretion. Considerable interest therefore attaches to its dental organs, as well as to the anatomy of the poison-glands; this latter subject I am, unfortunately, not in a position to describe, and will therefore limit what I have to say here to a consideration of the teeth only.

This animal, of which there are two species, is confined to the desert wastes of the South-western United States, where it is not of rare occurrence. In life it has a rather repugnant appearance, which is no doubt increased by our knowledge of its poisonous qualities. It attains a length of eighteen inches or two feet, and is covered with bright yellow spots, a circumstance which gives the name *Heloderma* to the genus, meaning "sun skin." Its venomous nature was not known until the experiments above mentioned were made, although Prof. Cope had reason to suspect as much, and gave the name "suspectum" to the species, which he described several years before.

The teeth are supported by the premaxillary, maxillary, and dentary bones, the palatine and pterygoids being edentulous. Those of the premaxillary, of which there are three upon each side, are the smallest of the upper teeth. They increase regularly in size from before backward, and form a continuous series, with the maxillary teeth behind, which continue to augment their dimensions up to the eighth tooth from the median premaxillary pair or the fifth of the maxillary set. From this point backward the two remaining teeth become slightly smaller. The teeth of the lower jaw are nine in number, and are disposed very much in the same manner as those above—the smallest in front and the largest toward the back part of the mouth. A considerable disparity

in size exists between the inferior series and the corresponding teeth above, those below being much the longer and more robust.

In their manner of implantation they cannot be said to be either acrodont or pleurodont, but rather intermediate between the two. The internal aspect of each jaw, which is remarkable for its breadth, is slightly bevelled internally, causing the outer edge to rise a little above the inner. Nearer the outer than the inner edge of this bevelled surface are a number of low bony elevations, corresponding to the number of the teeth in functional use, to the summits of which they are attached by ankylosis. In some instances these elevations are so faintly indicated that the teeth appear to be soldered to the bevelled surface of the jaw directly. Just internal to the basis of the functional teeth may be seen the successive sets in different stages of development. In the recent state they are covered by a fold of the gum, which likewise covers up the bases of the functional teeth.

The form of the crown is that of a long, slender, sharp-pointed cone curved inward and backward. The anterior surface of each tooth is marked by a well-defined groove extending from the base to the apex. It is somewhat deeper at the base than the summit, and is most distinct in the teeth of the lower jaw. The intervals between the bases of the teeth allow abundant room for the accommodation of poison-glands, the secretion of which is conveyed down these grooves and thus injected into the wound which the teeth inflict upon a prey.

Another group of curious and interesting reptiles is the *Dinosauria*, which became extinct at the close of the Cretaceous Epoch. They are of especial interest on account of their remarkable bird-like affinities, and, according to the views of many authors, were the direct progenitors of the struthious birds, or ostriches, emus, etc. They were mostly of gigantic size, and some of them are remarkable for the great number of teeth contained in the upper and lower jaws; others, again, were almost edentulous.

In the iguanodonts and hadrosaurs, which are typical representatives of the herbivorous division of this order, the crowns of the teeth are somewhat expanded and are marked externally by vertical ridges, while the internal portion is smooth and rounded. In *Iguanodon* the external surface, to which the enamel is confined, is traversed by three vertical ridges, separated by vertical grooves; the anterior and posterior edges were serrated, as in *Iguana*, before the crown was abraded by wear. In the hadrosaurs there is but one vertical ridge, which is external in the upper and internal in the lower teeth. The part which bears this ridge is known as the enamel or cementum plate. Prof. Cope has recently had the opportunity of satisfactorily determining the dental peculiarities of this group of gigantic saurians, as exemplified by the genus *Diclonius*, through the fortunate discovery of an almost complete skeleton by Dr. Russel Hill and the author in the Bad Lands of Dakota during the summer of 1882.

According to Prof. Cope's description, there are in all two thousand and seventy-two teeth. Of these, there were not more than two or three hundred in use at one time, the others being arranged in successive rows beneath, ready to take the place of the functional ones when they were

worn out. One striking peculiarity which this reptile presents is in the dentigerous character of the *splenial* and the edentulous condition of the dentary bones of the mandible. The teeth are relatively small, and are placed at some distance from the anterior part of the mouth. This part of the jaws is believed to have been occupied by a kind of horny sheath similar to that found in birds and turtles.

The proportions of the limbs were those of the kangaroo, the posterior greatly exceeding the anterior in size. The general shape of the skull is very much like that of a bird with a large spatulate beak; it was supported upon a long, flexible neck, which was doubtless useful to the animal in gathering the soft aquatic vegetation upon which, from the character of its teeth, it is supposed to have subsisted. It likewise had a powerful tail, much deeper than thick, which probably served not only as a fifth limb in balancing the weight of the animal, but could also have been useful as a swimming organ. The feet were provided with true hoofs.

The carnivorous dinosaurs were scarcely inferior in size to the herbivorous species, but were of a more slender and active build. Their jaws were provided with large, powerful conical teeth, better adapted for the capture of living animal prey. The terminal phalanges were ensheathed in distinct claws.

Another order of the Reptilia, and one which is probably best known, is the *Ophidia*, or snakes. Especial interest attaches itself to the dental organs of many of this group, inasmuch as their poisonous bite constitutes one of their most conspicuous features and renders them particularly obnoxious as well as dangerous to life.

According to most systematists, the order is divisible into five sub-orders, which have been defined as follows:

I. "The palatine bones widely separated, and their long axes longitudinal; a transverse (ecto-pterygoid) bone; the pterygoids unite with the quadrate bones."
  a. "None of the maxillary teeth grooved or canaliculated" . . . . . *Asinea.*
  b. "Some of the posterior maxillary teeth grooved" . . . . . *Tortricina.*
  c. "Grooved anterior maxillary teeth succeeded by solid teeth" . *Proteroglyphia.*
  d. "Maxillary teeth few, canaliculated, and fang-like" . . . . . *Solenoglyphia.*
II. "The palatine bones meet or nearly meet in the base of the skull, and their long axes are transverse. No ecto-pterygoid bone; the pterygoids are not connected with the quadrate bones" (Huxley) . . . . . *Scalecophidia.*

The first of these sub-orders includes nearly all of the harmless or non-venomous species, of which the black snake, garter snake, boa, etc. are familiar examples. The second includes a single family with few species, said to be harmless; they are confined to Africa. The third sub-order embraces such forms as the deadly cobra, the coral snake, harlequin snake, and others. The fourth includes the vipers, rattlesnakes, adders, etc. The last is represented by few species which are non-venomous.

In general, the dentigerous elements of the ophidian skull may be said to consist of maxillary, palatine, and pterygoid bones of the upper and the dentary bones of the lower jaw, although in the pythons and tortrices teeth exist upon the premaxillaries as well. In *Rachiodon*, a singular African species of the Asinea, the teeth of the jaws are extremely small and soon disappear. This loss is compensated for by an excessive development of the hypopophyses of several of the anterior

vertebræ, which pierce the superior wall of the œsophagus and are tipped with a layer of hard cementum. The food of this species consists of the eggs of small birds, which it swallows whole. During the act of deglutition the calcareous shell is brought into contact with and crushed by these œsophageal teeth, thus preventing the escape of any of the nutritious substances.

In the non-venomous species the maxillary bone is long, and bears a row of teeth which are of variable size in the different parts of the jaw in different genera. In some the teeth are largest in front and smallest behind; in others it is the reverse of this; while many have the teeth of equal size throughout; then, again, certain teeth of either jaw may be specially enlarged and separated from the others by a diastema. All these conditions have received distinct names.

All serpents are acrodont, and the crowns of the teeth consist of long, sharp-pointed, recurved cones which are designed more to prevent the escape of a struggling prey than as instruments of mastication. The two rami of the lower jaw are bound together at the symphysis by elastic ligaments, which, together with the great distensibility of the throat, due to the mobility of the suspensory bones, allows them to swallow objects many times larger than the usual diameter of the body. During the act of swallowing the recurved and pointed teeth act as so many hooks to prevent a backward movement of the object.

In the sub-order known as the *Proteroglyphia* the maxillary bone is shortened somewhat, and the anterior teeth are enlarged and grooved on their anterior faces. One of these teeth (the anterior) is the largest, and is denominated the fang. It is permanently erect in these serpents, being ankylosed to the maxillary bone, which is capable of comparatively little movement.

In the solenoglyphs, on the other hand, of which the rattlesnake is an excellent example, the maxillary bone attains its maximum of abbreviation and supports a single tooth, the fang.[1] It is movably articulated with the lachrymal above by means of a ginglymoid joint. The fang is canaliculated or perforated in the direction of its long axis by a canal which opens near its point. This canal results from the fusion of the free edges of the anterior groove, which remains open in the fangs of the proteroglyphs. When the mouth is closed, the maxillary bones are retracted and the fangs lie parallel with the roof of the mouth; when the animal "strikes," the maxillary bones are extended by special muscles and the fangs become erect.

The canal of the fang receives at its proximal termination the duct of the large poison-gland, which lies above it, so that when the punctured wound is inflicted the poisonous secretion is injected into it. This is facilitated by a coincident contraction of the muscles which surround the gland. It has been suggested by Owen that as the quantity of saliva and lachrymal secretion is increased during particular emotions, so the rage which stimulates the venom-serpent to use its deadly weapon must

[1] Usually, a number of teeth are found just behind the fang in this bone, some of which are nearly or quite as large as the fang itself. These are the teeth which are destined to succeed the functional fang whenever it shall have been shed or lost by accident.

be accompanied with an increased secretion and great distension of the poison-glands.

In reference to the poisonous character of this secretion, it is a well-known fact that the normal saliva of many animals is more or less dangerous when injected directly into the blood, and that in a state of rage it is rendered more so. Prof. Cope has recently called my attention to the possible explanation of the poisonous character of this analogous secretion of the venomous serpents: that since their peculiar method of locomotion would expose them most frequently to injuries and inconveniences calculated to excite this state, the normal salivary secretions have become accordingly modified.

The remaining orders of the Reptilia do not exhibit any important modifications of the dental system worthy of special notice.

THE TEETH OF THE MAMMALIA.

With a consideration of the teeth of the Mammalia we enter upon a study of a series of dental organs whose complexity, variety, and specialization surpass those of any other group of the Vertebrata. The wide diversity of conditions under which the different members of this great group exist would of itself lead one to anticipate a corresponding diversity in dietetic habits, as well as organs suitable for the prehension and assimilation of the substances by which they are nourished. The broad grinding surface afforded by the molar tooth of the elephant, the sharp, trenchant, sectorial dentition of the lion, the great scalpriform incisors of the beaver, the small cylindrical teeth of the armadillo, are a few examples of the great range of variety which mammals exhibit in the form of their dental organs.

As already remarked in the introductory pages, this study is greatly facilitated by considering it from the standpoint of evolution, or rather in the light of the palæontological history of the group. If we look upon the fossil remains of any given period of geologic time as the representatives in part of the animals which at that time inhabited the earth, it then becomes of the utmost importance to ascertain the exact relationship which the animals of each period bear to those which have preceded and succeeded them in time. It is needless to say that the conclusions which we are compelled to draw from studies of this character are important and significant, and serve to bring into the closest connection many isolated facts which if considered by themselves would be wholly unintelligible.

Some objection to this method of treatment will doubtless be raised by those who do not accept evolution as a demonstrated fact, or those, again, who consider our information concerning extinct forms too meagre for purposes of generalization. In answer to these objections it must be urged that palæontological law compels us to recognize the important fact that in every department of life the generalized has preceded the spe-

cialized in time; we pass from the simple to the complex, whether an individual organ or the entire organism be considered; and the teeth form no exception to this rule. So conclusive is the testimony which it is now possible to adduce in support of this general proposition, and so pregnant are the minds of modern biologists with this belief, that it seems utterly impossible to escape the conviction that life from its earliest inception has been continuously, and in many instances progressively, modified. As to the nature of the causes which have induced this modification, there is much less unanimity of opinion. It is a question regarding which the most exhaustive philosophic discussion is now in progress.

When we speak of the origin of mammalian teeth, it is necessary to have some definite knowledge of the origin of this class of animals before we can be absolutely certain of just what constitutes a primitive mammalian dentition. Unfortunately, the evidence which would enable us to determine the ancestry of the mammal beyond dispute has not as yet been found, but it appears sufficiently evident that we are limited in our choice to the Batrachia and Reptilia of the Permian Period. Huxley, who has devoted considerable attention to this subject, concludes that we must go backward past the Reptilia directly to the Batrachia. This conclusion is primarily based upon a comparison of the pelvic arch of the monotremes with that of the batrachians. In addition to the evidence drawn from this source, upon which his argument is principally founded, the following reasons are given for this view: "The Batrachia are the only air-breathing Vertebrata which, like the Mammalia, have a dicondylian skull. It is only in them that the articular elements of the mandibular arch remain cartilaginous, while the quadrate articulation remains small, and the squamosal extends down over the osseous elements of the mandible, thus affording an easy transition to the mammalian condition of those parts. The pectoral arch of the monotremes is as much batrachian as it is reptilian or avian. The carpus and tarsus of all Reptilia and Aves, except the turtles, are modified away from the batrachian type, while those of the mammal are directly reducible to it. Finally, the fact that in all Reptilia and Aves it is a right aortic arch which is the main conduit of arterial blood leaving the heart, while in the Mammalia it is the left which performs this office, is a great stumbling-block in the way of the derivation of the Mammalia from any of the Reptilia or Aves. But if we suppose the earliest forms of both Reptilia and Mammalia to have had a common batrachian origin, then there is no difficulty in the supposition that from the first it was the left aortic arch in the one series, and the right aortic arch in the other, which became the predominant feeder of the arterial system."

If we had only the recent forms to consider, the argument advanced by this learned anatomist would be specially potent; but when we study carefully the osteology of the Reptilia of the Permian Period, many of the arguments here advanced are invalidated. The structure of the pectoral and pelvic arches of the theromorph Reptilia, as has been ascertained by Cope, resembles that of the monotremes far more than does that of any known batrachian. The carpus and tarsus of these forms are almost identical with those of the monotremes, while comparatively

little importance can be attached to the dicondylian character of the skull, from the fact that there is in certain members of this group a double articular surface on the occipital bone for the atlas vertebra. The only osteological character left in which the Batrachia resemble the Mammalia most is that of the quadrate articulation; which resemblance is somewhat counterbalanced by the approaches to the distinctive peculiarities of the mammalian dentition found only in the *Theromorpha*. The condition of the arterial system must remain inferential for this group, since it became extinct, so far as we now know, at the close of the Permian Period. Upon the whole, I am disposed to think that there are quite as many reasons to regard the theromorph Reptilia as the ancestors of the mammal as there are to regard in the same light any of the Batrachia so far discovered.

Accepting the "placoid scale" or the "dermal denticle" as the structure from which all teeth were primarily derived, we have, as characters of a primitive dentition, the following: (1) the conical form; (2) increased number; (3) frequent and almost endless succession. These conditions we have fulfilled in many of the sharks. The next step in specialization consists in the fusion of the basal osseous plates of the "dermal denticles" to form the maxillary and dentary bones, to which the teeth become attached by ankylosis. This, we have already seen, obtains in a majority of the fishes, and is associated largely with the simple conical form. In the Batrachia the conical form, this mode of attachment, as well as the succession, are closely adhered to, but the individual teeth are reduced in number. In certain of the Reptilia—*e. g. Theromorpha*—another advance is made in the implantation of the teeth in distinct sockets, with a disposition to form more than one root or fang. There are still, however, many successive sets of teeth developed. Lastly, in the Mammalia the teeth are generally greatly reduced in number; they are always implanted by one or more roots in a distinct socket, and there are never more than two sets developed, the second of which is only partially complete; they are also, as a general rule, of a complex nature and show a wide departure from the primitive cone.

In searching, therefore, for a primitive or generalized mammalian dentition, the most important point to be taken into consideration is the following: numerous single-rooted teeth, confined to the maxillary and mandibular bones, implanted in distinct sockets, with a complete development of one or more successive sets. It is possible, even probable, that this stage in tooth-development was reached in the ancestors of the Mammalia before they assumed their distinctive characteristics as such; but the nearer any approach is made to this condition on the part of the mammal, in that proportion it may be regarded as primitive in its dental organization.

Having already spoken of the probable origin of the Mammalia, it now remains to give a brief synopsis of their classification before proceeding to a detailed description of their teeth. The arrangement here adopted is, with some modification, the one which has been proposed by Prof. E. D. Cope, and is based upon a study of both fossil and recent forms:

TABLE OF CLASSIFICATION OF MAMMALIA.

- MAMMALIA.
  - PROTOTHERIA.
    - Monotremata (duckbill).
  - EUTHERIA.
    - Didelphia.
      - Polyprotodontia (opossum).
      - Diprodontia (kangaroo).
      - Plagiaulacidæ (extinct).
    - Monodelphia
      - Mutilate Series.
        - Sirenia (sea-cow)
        - Cetacea
          - Zeuglodontia (extinct).
          - Denticete (toothed whales).
          - Mysticete (whalebone whales).
      - Unguiculate Series.
        - Bunotheria
          - Insectivora (shrew, etc.).
          - Tillodonta (extinct).
          - Toxodontia (extinct).
          - Prosimia (lemurs).
        - Rodentia
          - Sciuromorpha (squirrels).
          - Myomorpha (rats).
          - Hystricomorpha (porcupines).
          - Lagomorpha (rabbits).
        - Cheiroptera (bats).
        - Carnivora
          - Fissipedia (dogs, cats, etc.).
          - Pinnipedia (seals).
        - Primates (monkeys, man, etc.).
      - Ungulate Series.
        - Taxeopoda
          - Condylarthra (extinct).
          - Hyracoidea (hyrax).
        - Amblypoda (extinct).
        - Proboscidea (elephants).
        - Diplarthra
          - Artiodactyla (hog, cow, deer, etc.).
          - Perissodactyla (horse, tapir, etc.).

It will be seen, from the foregoing table, that the Mammalia are divisible into two primary groups, which hold the rank of sub-classes. The first of these, *Prototheria*,[1] has but two living representatives, both of which are confined to the continent of Australia. These are the *Echidna*, or spiny ant-eater, and the duck-billed platypus. The principal characters by which they are separated from all other Mammalia may be conveniently contrasted with those of the second sub-class, *Eutheria*, as follows: in the former there are (1) "large and distinct coracoid bones, which articulate with the sternum. (2) The ureters and the genital ducts open into a cloaca into which the urinary bladder has a separate opening. (3) The penis is traversed by a urethral canal which opens into the cloaca posteriorly, and is not continuous with the cystic urethra. (4) There is no vagina. (5) The mammary glands have no teats." In the *Eutheria*, on the other hand, (1) "the coracoid bones are mere processes on the scapula in the adult, and do not articulate with the sternum. (2) The ureters open into the bladder, the genital ducts into a urethra or vagina. (3) The cystic urethra is continuous with the urethral canal of the penis. (4) There is a single or double vagina. (5) The mammary glands have teats" (Huxley).

In their anatomical structure the *Prototheria* resemble the reptiles and birds more than does any other mammal. This is particularly conspicuous in the pectoral arch and the reproductive system. On this account, De Blainville applied the name *Ornithodelphia* (bird womb) to them, by which they are sometimes known. Strange as it may seem, no fossil remains of great antiquity of this most primitive group of all Mammalia are with certainty known to exist, but it may yet be found that the earliest mammalian representatives, which date as far back as the Triassic Period, and which are known from teeth and jaw bones only, really belong to the *Prototheria* rather than to the *Didelphia* or pouched series of the *Eutheria*, as is frequently maintained. Both the living forms are devoid of true teeth.

The second sub-class, *Eutheria*, has two principal divisions: *Didelphia* (double womb), including those animals popularly known as the "pouched quadrupeds," of which the opossum, kangaroo, wombat, etc. are familiar examples; and the *Monodelphia* (single womb), which embraces all the remaining mammals. The name of the first subdivision, *Didelphia*, was applied by its author, De Blainville, with reference to the peculiar habit which these animals possess of sheltering their helpless young in an abdominal integumentary fold. This is correlated with the only important character in which they differ from the monodelph division—viz. the complete absence of an allantoic placenta or any uterine connection between mother and fœtus. In consequence of this peculiarity of gestation the young are born in an exceedingly helpless and imperfect condition, and are nourished for a considerable period in the marsupium or pouch of the mother. This character is

[1] The classification of the Mammalia proposed recently by Prof. Huxley includes three principal subdivisions—viz.: *Prototheria*, *Metatheria*, and *Eutheria*. The terms *Prototheria* and *Eutheria* were employed by Prof. Gill a number of years previously to designate the two principal groups of this class, and appear to have been appropriated by Huxley without credit.

considered of sufficient value by some to give the *Didelphia* a rank equal to that of the *Prototheria*, and they consequently make three primary divisions of the class—*Ornithodelphia*, *Didelphia*, and *Monodelphia*, after De Blainville. If this were associated with any other characters of structural importance it would be quite sufficient, but since it is not, and in view of its unreliability and inconstancy in the lower Vertebrata, I am not disposed to regard it as equal in value to the strong structural characters by which the *Prototheria* are defined.

The subdivision of the Monodelphia is not an easy matter, if indeed any important divisions further than the separation of the mutilate series can be made. It is convenient, however, to adopt the classification of Lamarck, and divide them into three series, as follows: the mutilate series, the ungulate series, and the unguiculate series. The first of these includes the *Cetacea*, or whales, and the *Sirenia*, or sea-cows. The only character by means of which they are associated is the absence of hind limbs and the loss of the articular processes of the bones of the manus. The *Cetacea* form a perfectly natural and homogeneous group, and are entitled to a wide separation from all other Mammalia. We at present know very little concerning their development or ancestry, further than that their Eocene representative, *Zeuglodon*, resembled the ordinary monodelphous type more than does any other member of the order. They are undoubtedly a very old and distinct group, and it would not be at all surprising if they are ultimately found to have descended directly and independently from the *Prototheria*.

The *Sirenia*, or sea-cows, on the other hand, appear to be simply modified ungulates that have gradually assumed their present structure in accordance with their aquatic environment. The Miocene genus (*Halitherium*) of this order had distinct hind limbs, and in many ways resembled the primitive hoofed Mammalia. For this reason it is probably best to associate them with the ungulate rather than with the mutilate series, since they differ in almost every essential feature from the *Cetacea*, except in the loss of the posterior members.

The separation of the two remaining series, ungulate and unguiculate, depends entirely upon the distinctions to be drawn between "hoof" and "claw." If we contrast, for example, two such structures as the claw of the lion and the hoof of the horse, the distinctions are perfectly obvious, and we will experience no difficulty in recognizing the differences; but if we carefully trace the respective lines of ancestry of these two forms backward to the Eocene Period, we will find them converging to such an extent as to involve the hoof-and-claw question in almost hopeless confusion.

There are, however, two principal lines or stems which have terminated in the distinctly hoof-bearing mammals on the one hand and the claw- and nail-bearing on the other. The exact point at which these two lines converge has not as yet been satisfactorily determined, but it is undoubtedly true that they approached one another to a remarkable extent in the early Eocene. The ancestry of the entire ungulate series is indicated by the *Taxeopoda* of Cope, to whose persistent efforts and scholarly researches we are alone indebted for their discovery and description.

The primitive or central stem of this order is the *Condylarthra*, from

which we pass by easy stages through the extinct genus *Meniscotherium* to the little hyrax or "coney," whose classification has long remained a puzzle to zoologists. From this group the extinct amblypods and elephantoid animals likewise came, while the *Perissodactyla* and the *Artiodactyla* are traceable directly to it.

The unguiculate series also has a generalized order, from which all the others radiate in different directions. This order has been called the *Bunotheria* by Cope, and exhibits a central axis in the sub-order *Insectivora*, the representatives of which are among the oldest of monodelph mammals. From the *Insectivora* we derive the *Creodonta*, a group of extinct insectivoro-carnivorous animals which terminates in the *Carnivora*. In another line come the lemuroids, monkeys, and man, while in still another are the *Cheiroptera* or bats, which are simply insectivores modified for flight.

One other order, the *Edentata*, or sloths, armadillos, ant-eaters, etc., remains to be accounted for. Some authors believe them to be affiliated with the unguiculate series, and to have sprung from the central insectivorous group. Palæontology has so far given us very few if any hints concerning the origin of this order, and it is probable that it will not be until the Eocene and Miocene Tertiaries of South America are more fully explored that any important information will be had upon this subject. At present I consider the evidence too meagre to hazard an opinion.

Divisions of the Mammalian Dentition.—Many years ago Prof. Owen called attention to the fact that in many of the *Eutheria* there are two sets of teeth developed during the life of the individual—a deciduous or milk set and a permanent set—while in others but a single set appears. The former of these two conditions he designated by the term *diphyodont*, and to the latter he gave the name *monophyodont* dentition. It likewise so happens that generally, in those that have two sets (diphyodonts), the teeth in the various parts of the mouth are different in form and complexity, while in those that have but a single set (monophyodonts) the teeth are alike throughout. The diphyodont dentition is therefore, as a general rule, *heterodont*, that is, there are many kinds of teeth, and the monophyodont dentition is *homodont*, or all the teeth are alike. It was therefore originally supposed by Owen that diphyodont and heterodont and monophyodont and homodont were correlative and interchangeable terms, but it has since been discovered that there are many exceptions to this rule.

It must be borne in mind that the terms diphyodont and monophyodont are simply conveniences by which we are enabled to express briefly the conditions of replacement, and are not in any way to be looked upon as definitive of a natural group. The degree to which the second dentition is developed in the various sections of the Mammalia is subject to extreme variation, and it is not always an easy matter, if not frequently an utter impossibility, to determine whether certain teeth belong to the deciduous or permanent set, or in the monophyodonts to say whether it is the permanent or deciduous set which has been lost. There are, however, as will appear later, several important series in which the replacement and position are sufficiently constant to enable us to divide

the teeth into several categories, the convenience of which, to say the least, if not the real importance, is undeniable. The question of the nature and relationship of the milk dentition to the permanent one will be discussed after the teeth of the several groups have been considered.

THE TEETH AND THEIR ACCESSORY ORGANS IN THE DOG.—I have thought best to next present a detailed description of the adult structure of an average diphyodont dentition, together with the accessory organs, in order that the student may become familiar with the technicalities before proceeding to consider the teeth of the various sections of the Mammalia The dog has been selected as an example of this kind, partially on account of the generalized condition of the teeth, but principally on account of the readiness with which the student will be enabled to provide himself with the necessary material.

The teeth of the dog (Figs. 195 and 196) are forty-two in number, of which twenty belong to the upper and twenty-two to the lower jaw. The most anterior teeth of the upper series are relatively small, and are implanted in the free edge of the premaxillary bones in such a manner as to describe the arc of a circle. These are known as the *incisors* (*ic*, Figs. 195, 196). Behind these, after a slight interval, are

FIG. 195.

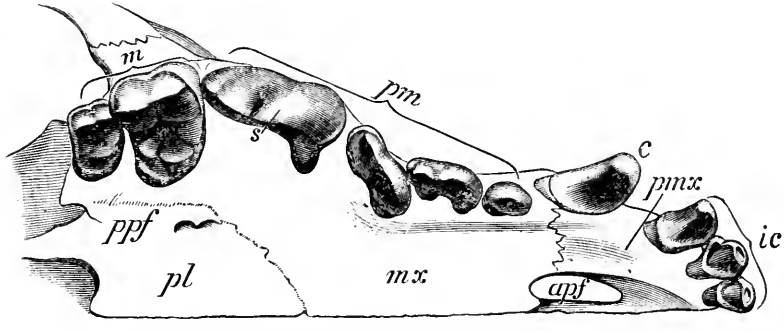

Vertical View of the Upper Jaw of a Dog (*Canis familiaris*): *ic*, incisors; *c*, canine; *pm*, premolars; *m*, molars; *s*, sectorial; *pmx*, premaxillary bone; *mx*, maxillary bone; *pl*, palatine; *apf*, anterior palatine foramen; *ppf*, posterior palatine foramen. The position of the third premolar is slightly abnormal.

a pair of strong, laterally compressed curved teeth, the *canines*, which are lodged deeply in the substance of the maxillary bone, immediately behind the maxillo-premaxillary suture. Behind the canines, again, are six teeth on each side, which progressively increase in size and complexity as we proceed backward until the penultimate tooth is reached, the last one being somewhat smaller. These are termed *molars* and *premolars*. The tooth-line of each moiety of the upper jaw presents three curves, the most anterior of which is formed by the three incisors and canine, with a strong convexity outward; the line of the next four describes a gentle curve whose convex surface is inward; while that of the last two curves boldly inward toward the median line.

The number of teeth in the lower jaw is one in excess of that of the upper, which is caused by the addition of a small single-rooted tooth at

the posterior end of the series. They describe the same curves, so as to oppose those of the upper series. The incisors of the upper jaw, as has already been stated, are lodged in the pre- or intermaxillary bones, which limit the anterior part of the oral cavity above. The definition, therefore, of an incisor tooth of this series is *one which has a pre- or intermaxillary implantation irrespective of its size or form.* The incisor teeth of the lower jaw are *the corresponding ones which are brought into opposition with those of the upper jaw when the mouth is closed.* The teeth thus defined are three in number upon each side above and below in this animal, and are implanted by single slightly recurved fangs in distinct sockets or alveoli. In the upper series the median pair is the smallest, the outer ones gradually increasing in size. The base of the crowns of the four middle teeth is somewhat trihedral in form, with the apex flattened from before backward and produced into three cusps, of which the central one is the largest. The entire apex of the crown is slightly recurved. Upon its inner aspect the crown presents a basal ledge or cingulum, which sends out a low ridge to each of the lateral cusps. The lateral incisors are the largest and are somewhat caniniform. Like the median ones, their crowns have a strong basal cingulum posteriorly, but the lateral cusps are absent; the apex terminates in a strong hooked point.

The incisors of the lower jaw are similar to those of the upper, with the exception of the median pair, which is much the smallest and occupies a more anterior position than the others. The internal lateral cusps of these teeth are very faintly indicated, if indeed they can be at all made out, while the external lateral cusp is present and situated high up in the two median pairs. In the lateral ones it has a position nearer the base of the crown, and is separated from the median cusp by a deep fissure.

Between the lateral incisors and canines of the upper series there is a space or *diastema* about equal to the width of the lateral incisor. This space serves to receive the lower canine when the mouth is closed. At the back part of it upon the outside may be seen the suture by which

FIG. 196.

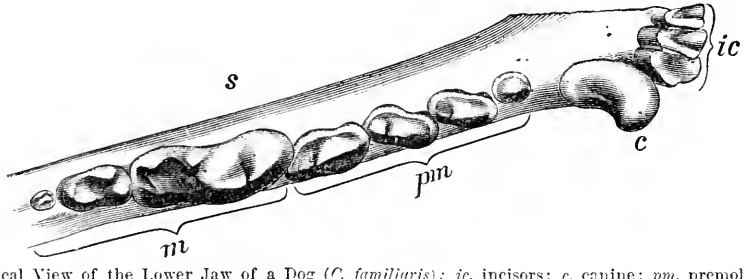

Vertical View of the Lower Jaw of a Dog (*C. familiaris*): *ic*, incisors; *c*, canine; *pm*, premolars; *m*, molars; *s*, sectorial.

the premaxillary bone joins the maxillary in the dentigerous border of the jaw. Just behind this suture the superior canine is lodged.

The definition, then, of a superior canine tooth is *one which is situated in the maxillary bone immediately behind the maxillo-premaxillary suture, provided it be not too far back, whatever may be its form, size, or func-*

tion, while the canine of the lower jaw is the tooth which closes just in front of it.

The canines of the dog are large, recurved, pointed teeth, projecting far above the level of the others, with slightly trenchant anterior and posterior edges. They are almost equal in size and very similar in shape. A very useful means by which they can be distinguished from each other, if at all worn and isolated from the rest of the teeth, is to note the point at which the worn surface exhibits itself. It must be remembered that the lower canine closes in front of the upper, in consequence of which the *posterior* face of the lower impinges against and abrades the *anterior* face of the upper; the anterior face of the lower canine also comes in contact with the lateral incisor, and an abrasion takes place at this point; but the posterior face of the upper canine is seldom worn except by long-continued use, so that ordinarily these points of wear serve as a useful guide in distinguishing between them. There is a slight difference in form, which can be ascertained only by close and careful comparison.

Behind the canines are four teeth which have been designated *premolars*. The reason for this distinction is founded upon the circumstance that these are the teeth situated behind the canine which vertically succeed the corresponding ones of the deciduous or milk set. The definition, therefore, of a premolar tooth is *one which, being situated behind the canine, displaces in a vertical direction a deciduous or milk tooth; all others behind these are true molars.* This is the definition which was originally proposed by Owen, to whom we are greatly indebted for this nomenclature: it would appear to be entirely satisfactory and sufficient, were it not for the fact that the first tooth counting from before backward, which is generally enumerated in the premolar series, *does not have any deciduous predecessor.* If we adhere strictly to this definition, it cannot be justly considered a premolar, but common usage has so long given it a place in this category that it appears advisable to still call it such. It should be remembered, however, that this is by no means an isolated case, but that other animals exhibit similar peculiarities.

The first premolar, so called, of the superior series is the smallest of the four, and is implanted rather obliquely in the maxillary bone; its single fang is slightly compressed laterally, and joins the crown at a moderately well-defined neck. The crown has an elongated oval form, terminated by a prominent obtuse cusp and surrounded by a well-marked ledge or cingulum, which is most conspicuous upon its inner face. From the summit of the main cusp two well-defined ridges descend to the cingulum, one on the posterior and the other upon the anterior border, giving to the tooth a slightly trenchant appearance. The hindmost of these two ridges divides the posterior half of the crown into two equal parts, and terminates with a very slight enlargement in the cingulum, while the anterior one has a more internal direction, and terminates in a distinct tubercle which occupies a position at the base of the antero-internal portion of the crown. The two ridges and the cingulum below enclose a shallow triangular depression internally, the outer face being convex.

The second and third premolars are considerably larger than the first, and are implanted by two roots, of which the posterior is the larger. These two teeth resemble one another very closely, the only appreciable difference being their slight disparity in size. Their crowns, like that of the first, are of greater longitudinal than transverse extent, and are produced into a prominent cusp situated a little anterior to the centre. The posterior ridge is interrupted shortly before it joins the cingulum by a deep transverse notch which gives rise to a distinct cusp, the *posterior basal tubercle*, situated over the hinder root. A faint indication of a second cusp is seen just behind this as an elevation of the cingulum. The antero-internal tubercle is present, and occupies relatively the same position as it does in the first premolar. The cingulum is more prominent on the inner than on the outer side of the crown, and with the two ridges encloses a triangular space.

The fourth premolar is by far the largest and strongest tooth of the premolar series. It is commonly known as the "flesh tooth," or *superior sectorial*, for reasons presently to be given. It is implanted by three roots, two external and one internal. The crown is composed of two principal lobes supported by the two external roots, and a small antero-internal one supported by the internal fang The two principal lobes have an antero-posterior position, and are separated from each other by a deep, narrow fissure. Of these, the anterior is the larger and higher of the two; when viewed externally it resembles a cone with the anterior contour produced. Internally it is flattened somewhat, so as to correspond with the flattened inner surface of the posterior lobe. Posteriorly it is produced into a strong blade-like ridge, which is terminated by the vertical fissure, while its anterior surface is marked by a moderate vertical ridge. The posterior lobe is essentially chisel-shaped in form, with the bevelled edge external; its apex forms a blade-like crest which extends the entire length of the lobe. The internal lobe is small, and occupies a position at the antero-internal angle of the crown, being connected with a faintly-marked cingulum which surrounds the base of the crown. When we attempt to homologize the component lobes of this tooth with those of the premolars in advance of it, it is not difficult to see that the anterior lobe is the principal cone, that the posterior one is merely an exaggerated posterior basal tubercle, while the internal lobe is strictly homologous with the structure which has a similar position in the others. The three anterior premolars are not in as close contact as the teeth in the back part of the jaw, but are separated from each other by slight intervals, which are most conspicuous between the first and second.

The premolars of the lower jaw are similar in form to those of the upper, with the important exception of the fourth or last, wherein there is to be found a wide difference both in size and structure. The first of the lower series is smaller than the corresponding tooth above, and has a simpler, more conical crown. It is separated by a considerable diastema from the canine in front of it, but is almost in contact with the second behind. The second and third resemble those which are in a like position in the upper jaw, while the fourth is also similar to the corresponding tooth above, with the exception of a

slightly increased size and the possession of a well-defined second posterior basal lobe. It slightly overlaps the great first true molar behind it.

The true molars of the superior series are two in number upon each side, and are placed directly behind the premolars. The definition of a true molar tooth is *one which, being situated behind the premolars, does not displace a deciduous or milk predecessor.* The two molars above are three-rooted, with broad tuberculated crowns imperfectly quadrangular in outline. The first, which is more than twice the size of the second, has two strong obtuse conical tubercles on the external portion of the crown, situated directly over the anterior and posterior external roots; they are subequal and separated from each other by a transverse notch. Internal to these there is a broad ledge, well rounded off internally, bearing three cusps. The one most internal is lunate in form, and is closely connected with the cingulum, which surrounds the base of the tooth. The cusp situated near the antero-internal angle is the largest, and has a subtrihedral form. A distinct ridge passes outward and forward from it to join the cingulum. Posterior to this last-mentioned cusp, and separated from it by a wide open notch, is the third tubercle, less distinctly marked than either of the others. An analysis of the various cusps of which the crown is composed leaves little room to doubt that the two external cusps are strictly homologous with the two external ones of the sectorial in advance of it—that the internal ledge which bears the three tubercles represents the greatly enlarged internal lobe of the sectorial, which has been removed to a more posterior position, and has acquired an important addition from the cingulum. That part of it which is exactly homologous with the internal lobe is the principal cusp at the antero-internal angle, which in some carnivorous animals is continued outward and backward as a prominent ridge, and does not develop the third tubercle. If the lunate cingular cusp be subtracted, the crown will be seen to resemble that of the sectorial in its general features.

The second true molar is like the first, except that the internal ledge exhibits, instead of three tubercles, two crescentiform ridges.

The first true molar of the lower jaw is the largest tooth in the entire dentition of the dog, and is the *sectorial* of the inferior series. It is implanted by two powerful roots at a point about midway between the anterior extremity and the condyle of the lower jaw, and occupies a position near the canthus or angle of the month. Its crown may be described as composed of two anterior blade-like cusps, a small internal tubercle, and a low tubercular heel. Of the two anterior cusps, the posterior is the larger, and rises gradually above the level of the one anterior to it; both are convex internally, but somewhat flattened externally to correspond with the internal flattened surface of the two blades of the superior sectorial. They are separated from each other by a deep, narrow fissure. The heel is low, and occupied by two cusps disposed transversely, of which the outer one is the larger. A faint ridge connects them, enclosing a shallow basin in front; on this account the heel is said to be basin-shaped. The internal tubercle is small, and is placed at the inner posterior part of the median lobe. In many carnivores it

completely disappears, as does also the heel, as we shall presently see. The fourth superior premolar and the first inferior true molar are called *sectorial*, on account of their scissor-blade structure and the manner in which they oppose each other. If the macerated skull of a dog be carefully examined, it will be seen that the incisors of each series oppose each other almost exactly, while the lower canines close in front of the upper. As a consequence of this, the first premolar below closes in advance of the first premolar above; the second below in the interval between the first and second above, etc., but always upon the inside, on account of the unequal width of the two jaws. Now, the inferior sectorial bites against the superior in such a manner that its blades exactly oppose those of the tooth above after the manner of a pair of shears, so that when the mouth is closed the inferior sectorial is completely hidden from view; the heel opposes the first true molar above. Those who have ever studied the habits of dogs or wolves must have noticed that when they wish to divide a tough animal membrane or ligament they pass it back to the canthus of the mouth on one side and make several short quick strokes of the jaw; this is the shearing movement of the sectorials.

The remaining two true molars are much smaller, the last being one of the smallest of all the teeth, and is implanted by a single root. It is said to be permanently absent in some races of the domestic dog, especially the "pugs" and "Japanese sleeve dogs." The second molar is two-rooted, with a tuberculate crown of a more or less quadrate form. Two transverse cusps occupy the anterior part, while a third is placed at the postero-external angle of the crown on the edge of a broad flat heel. A basal cingulum is also present. The last tooth has an obtusely

FIG. 197.

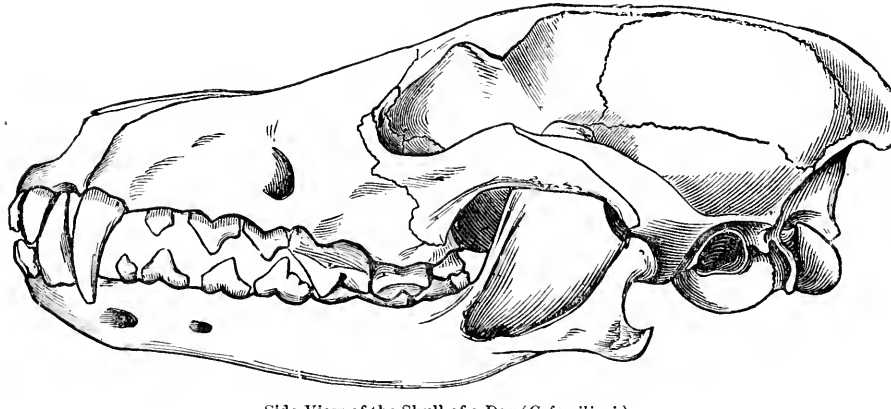

Side View of the Skull of a Dog (*C. familiaris*).

conical crown. The homologies of the cusps of the inferior true molars are not evident in the dog, but when we come to examine allied forms it will be found that the two blades of the sectorial represent the primitive cone, and the anterior basal lobe of the ordinary premolar greatly enlarged and specialized, while the heel represents the two posterior

basal tubercles arranged transversely; the internal tubercle is an extra outgrowth from the cingulum.

In the case of many extinct animals the succession, and consequently the discrimination, of the molars and premolars would be attended with considerable difficulty were it not for the fact that in a majority of the Mammalia the first true molar is the first of the permanent set of the molar and premolar series which comes into place. By the time the last or fourth premolar is cut, which is usually one of the last, the first true molar immediately behind it is considerably worn down by use, so that this disparity of wear will of itself frequently serve to locate the exact limits of each series. It is a rule which is often employed by palæontologists to determine the dental formula of an animal the succession of whose teeth is unknown. When the anatomist wishes to indicate briefly the number of the various teeth of any particular animal, he employs what is called a dental formula. By this method the permanent dentition of the dog would be expressed as follows: I. $\frac{3}{3}$, C. $\frac{1}{1}$, Pm. $\frac{4}{4}$, M. $\frac{2}{3}$; which means that there are three incisors upon each side above and below, that there is one canine upon each side above and below, that there are four premolars, and that there are two true molars above and three below. This manner of abbreviation is convenient and easily understood, and saves both time and space in descriptions.

The division of the teeth into incisors, canines, premolars, and molars, although open to some objection, is nevertheless useful, since it serves to locate, in the case of addition or subtraction of a tooth to or from the normal diphyodont number, the exact position in which the change has taken place. In the marmoset monkeys of South America, for example, the total number of teeth is thirty-two, the same as in man. An inspection of their formula, however, which is I. $\frac{2}{2}$, C. $\frac{1}{1}$, Pm. $\frac{3}{3}$, M. $\frac{2}{2}$ = 32, will show that there is an important difference between the number of molars and premolars, the formula in man being I. $\frac{2}{2}$, C. $\frac{1}{1}$, Pm. $\frac{2}{2}$, M. $\frac{3}{3}$. In the former it is a molar which is lost; in the latter it is a premolar. Another example of this kind is seen in the upper and lower teeth of the otter, in which they are equal in total number, but unequal as far as the respective kinds are concerned. The dental formula in this animal is I. $\frac{3}{3}$, C. $\frac{1}{1}$, Pm. $\frac{4}{3}$, M. $\frac{1}{2}$ = 36.

The Accessory Organs.—This subject properly embraces a consideration of the bones by which the teeth are supported, the muscles concerned in their movement, the blood-vessels by which they are supplied with nutriment, and the nerves distributed to them. The bones in which the upper teeth are implanted are the *maxillæ* and *premaxillæ*, which are usually enumerated as bones of the face. The maxillary bone (Fig. 195, *mx*) is by far the largest one belonging to this category, and forms the greater part of each moiety of the upper jaw. It likewise contributes to the formation of the cheek, orbit, and palate, and also takes the principal share in forming the boundary of the nasal chamber. The maxillary bones do not meet in the median line above, on account of the interposition of the nasals and premaxillaries, but below they send inward two thin horizontal plates which meet in the middle of the roof of the mouth.

For descriptive purposes it is convenient to divide each bone into

three external surfaces, the facial, palatine, and orbital. The facial surface, which is the largest of the three, is directed outward, and is irregularly triangular in form, with the apex directed forward. The superior border of this surface is considerably curved, and joins the premaxillary in front and the nasal behind. The posterior border is irregular, and is in contact from within outward with the frontal, lachrymal, and malar bones respectively, being excluded by these bones from the rim of the orbit. The inferior border is known as the dental or alveolar border, on account of its affording support to the canine, premolar, and molar teeth of the upper jaw. It is in contact with the premaxillary in front, and terminates behind in a free extremity beneath the orbital fossa.

The surface thus bounded is uneven, being interrupted by elevations and depressions. At the anterior angle the superior canine is implanted, and the course of its powerful curved root is indicated by a well-marked ridge or swelling of the external surface. Behind and above the posterior termination of this is a broad, shallow depression, while behind and below is another depression, the *canine fossa*, ending posteriorly in a large foramen, the *infraorbital foramen*, situated above the interval between the third and fourth premolars. Behind the infraorbital foramen a strong process is thrown up to meet the malar; this is known as the *malar process* of the maxillary. The posterior superior angle is produced into a considerable rounded process, which passes as far backward as the centre of the orbit to articulate with the frontal. This is the *nasal process* of the maxillary, and is the homologue of a corresponding process in the human skull bearing this name.

The posterior or orbital surface is relatively small, convex from before backward, and concave from side to side. It is somewhat triangular in shape, and forms the greater part of the floor of the orbit, being directed upward and backward. It is bounded above and externally by the malar, directly above by the lachrymal, and internally by the palatine bones respectively, terminating in a free rounded border behind. The internal portion of this last-mentioned border is separated from the palatine by a notch, and forms a conspicuous eminence known as the *maxillary tuberosity*. At the anterior extremity of this surface is seen the posterior opening of the infraorbital canal, which traverses the maxillary bone and serves for the transmission of the second division of the trigeminal or fifth nerve, as well as a part of the external carotid artery, which terminates in this situation as the infraorbital. This surface is perforated by small foramina for the entrance of the superior dental nerves and arteries.

The inferior or palatal surface forms a considerable part of the bony roof of the mouth as well as the floor of the nasal chamber. It is limited in front by the premaxillary bone, externally by the free alveolar border, posteriorly in part by the palatine and in part by a free edge, and internally by the suture with which it joins its fellow of the opposite side. It is slightly concave from side to side, the alveolar border being considerably elevated. Posteriorly it sends backward a narrow strip which terminates in a free edge behind; anterior to this, at a point opposite to the anterior part of the sectorial, it widens rapidly. From this point to its anterior termination it gradually narrows again. Just internal

to the sectorial is seen a deep depression, the *sectorial fossa*, which serves to accommodate the blades of the inferior sectorial when the mouth is closed. Internal to this, again, are usually two, sometimes three, foramina, the *posterior palatine foramina*, which transmit the posterior palatine vessels and nerve. From the largest, most anterior of these a shallow groove is continued forward in which the palatine artery is lodged. This is the *palatine groove*.

The line of junction of the two palatal plates of the maxillaries is marked by a longitudinal ridge, the *sutural ridge*, which gives support to the vomer above. The maxilla articulates with the premaxilla and nasal in front, with the frontal above, and with the lachrymal, malar, and palatine behind.

The premaxillæ are small bones placed in front of the maxillæ, the two together forming the anterior termination of the upper jaw. Each consists of a thickened anterior portion meeting in the median line, together with an ascending or vertical process and a horizontal process. The thickened body forms the lower boundary of the anterior nares, and by its free alveolar border lodges the incisor teeth. The ascending or vertical process is a long, sharp spicule of bone which springs from the outer side of the body and furnishes the external wall for the narial opening. It is directed upward and backward, and insinuates itself between the nasal above and the maxilla below. This is known as the *nasal process* of the premaxilla. Upon either side of the median line the horizontal or *palatine processes* pass backward to the maxillæ, forming the anterior portion of the bony palate. These processes are in contact with each other in the middle line, but each is separated from its body by a wide hiatus, which is converted into a foramen by the interposition of the palatal plate of the maxillary behind. These large oval foramina are conspicuous features in the macerated skull, and are known as the *incisive* or *anterior palatine foramina*. They transmit the anterior palatine vessels and nerve.

The next and last bony structure to be noticed in connection with the teeth is the *mandible* or lower jaw. This part of the skeleton in human anatomy is known as the *inferior maxilla*, and consists, in the adult state at least, of a single bone (the two halves co-ossified), as is also the case in the monkeys and several other mammals. In the majority of them, however, it is made up of two more or less persistent pieces, which may unite in extreme old age to form a single bone. The mandible of the dog consists of two symmetrical elongated halves, *the rami*, diverging behind and coming in contact in front in the median line by two roughened surfaces, the *symphysis*. They are bound together by the interposition of fibro-cartilage at this point, and are movably articulated to the skull behind by two transversely elongated processes, the *mandibular condyles*, placed near the middle of the posterior border. Each ramus is laterally flattened, with the inferior border considerably curved in an antero-posterior direction. In front this border slopes gradually upward to meet the alveolar or dentary border, while behind it is terminated by a prominent, slightly-inflected process, the *angle*. The dentary border is nearly straight, and is prevented from reaching the posterior border by the intervention of a broad flat recurved plate of bone, the *coronoid pro-*

cess, which rises high above the level of the surrounding parts. The posterior border is interrupted by two notches, between which is situated the condyle. Immediately in front of the condyle is a wide and deep depression, the *masseteric fossa*, for the insertion of the powerful masseter muscle. In front of and below the condyle, on the inner side, is a conspicuous opening, the *inferior dental canal*, which gives passage to the inferior dental artery and nerve. On the external surface, behind and below the root of the canine, is another opening, the *mental foramen*, through which a part of the nerve makes its exit to be distributed to the lower lip.

The Muscles.—The principal muscles concerned in the movement of the lower jaw are the temporal, masseter, external, and internal pterygoids, the digastric, genio-hyoid, and mylo-hyoid.

The *Temporal* is a broad, thick, fleshy muscle which covers the side wall of the brain-case from the post-orbital process in front to the lambdoidal or occipital crest behind, reaching as high up as the sagittal crest above, and completely filling up the temporal fossa, to which it gives its name. Its fibres converge fan-wise to be inserted into the summit of the coronoid process of the ramus of the mandible. Its principal action is to elevate the lower jaw. By its leverage and great strength the animal is enabled to take a firm grip upon its prey.

The *Masseter* is a short, thick muscle arising from the under and a part of the outer surface of the malar bone, as well as the posterior part of the maxillary, and, passing downward and backward, is inserted into the masseteric fossa of the ramus. Its action is similar to that of the preceding muscle.

The *Internal Pterygoid* muscle consists of a strong bundle of muscular fibres which takes its origin from the pterygoid fossa in the base of the skull, and passes downward and outward to its insertion in the lower part of the angular process. By its contraction the lower jaw is drawn upward and inward, but owing to the manner in which the teeth interlock no extensive lateral movement is possible. The most reasonable view of the action of this muscle, as well as the succeeding one, is, that by the contraction of those of one side the sectorial apparatus of the side opposite is enabled to perform a more perfect shearing movement, just as the blades of a pair of scissors must be pressed closely together in order to make them cut. From the direction of its fibres it likewise assists in elevating the jaw.

The *External Pterygoid* arises from the pterygoid plate of the sphenoid bone, and is inserted into the base of the condyle, and as far forward as the inferior dental canal. Its action has already been alluded to.

The *Digastric* is a large muscle which arises from the skull behind the auditory bulla in a strong bony prominence, the paramastoid process, and passes forward to its attachment on the inferior margin of the ramus in front of the angular process. Its action is to depress the jaw and open the mouth.

The *Genio-* and *Mylo-hyoid* muscles are broad muscular sheets which lie between the rami forming the floor of the mouth in the recent state, being attached to the hyoid bones and the "fork" of the jaw. They

assist in depressing the mandible, and consequently in opening the mouth.

Vessels and Nerves.—The blood-vessels by which the teeth and the muscles described above are supplied are derived from the external carotid artery, which passes forward along the side of the neck, giving off branches to the various structures in this situation. This artery does not terminate, as in man, in the temporal and internal maxillary arteries —at least it is so generally considered by anatomists. Both the right and left common carotids spring from the innominate, as in the *Carnivora* generally. After giving off the thyro-laryngeal branch, remarkable for its large size, to the thyroid gland and larynx, it passes forward in front of the transverse process of the atlas vertebra, where it gives off the occipital artery, which goes to the back of the head and the deep muscles of the neck. Upon the base of the skull in the vicinity of the carotid canal it bifurcates into two principal branches, the external and internal carotids, the latter entering the skull through this canal to be distributed to the brain, the latter continuing forward through the alisphenoid canal, giving off in its course the laryngeal, lingual, facial, posterior auricular, and superficial temporal branches. Near the condyle of the lower jaw it describes a remarkable sigmoid curvature between this structure and the internal pterygoid muscle, thence passing forward to the infraorbital canal, where it receives the name of the infraorbital artery. Between the condyle and the infraorbital canal the following principal branches are emitted by this arterial trunk: the inferior dental artery, which enters the inferior dental canal and supplies the teeth of the lower jaw; the deep posterior temporal, which furnishes a masseteric branch passing through the sigmoid notch, or that between the condyle and coronoid process of the ramus, to enter the masseter muscle; several pterygoid arteries, which go to the pterygoid muscles; the ophthalmic artery, distributed to the eye; the deep anterior temporal; the palatine, buccal, and alveolar arteries; lastly, the superior dental artery, which supplies the teeth of the upper jaw.

The nerves supplying the teeth and accessory organs are derived principally from the trigeminal or fifth pair of cranial nerves. This is essentially a mixed nerve in function, arising by two roots, a large sensory and a small motor root. At a short distance from its origin the sensory root swells out into ganglionic enlargement, the Gasserian ganglion, after which it divides into three branches—the *ophthalmic* or *first division*, the *superior maxillary* or *second division*, and the *inferior maxillary* or *third division*.

The first of these makes its exit from the cranial cavity through the sphenoidal fissure, and supplies by its subdivisions the eyeball, mucous membrane of the eyelids, the skin of the nose and forehead, dividing into frontal, lachrymal, and nasal branches.

The second of these branches, the superior maxillary, issues from the skull through the foramen rotundum, and supplies the side of the nose, upper teeth, and the upper part of the mouth and pharynx. It crosses from the foramen rotundum directly to the infraorbital canal, in the vicinity of which it gives off the anterior and posterior dental nerves which supply the teeth.

The third division, inferior maxillary, passes out of the skull through the foramen ovale, just outside of which it is joined by the motor root. It then divides into two branches, a small anterior one distributed to the muscles of mastication, and a large posterior branch, which supplies the ear, side of the head, lower lips, gums, teeth, salivary glands, and inside of the mouth. The posterior branch divides into the *auriculo-temporal*, which passes backward to the temporal region; the *inferior dental*, which supplies the teeth of the lower jaw; and the *gustatory*, or the nerve of taste, which goes to the mucous membrane of the tongue.

The lips, tongue, and salivary glands should also be mentioned in connection with the accessory organs, since they serve an important purpose in preventing small particles of the food from escaping during mastication, as well as supply the requisite moistening fluid whereby comminution is more readily accomplished and the food rendered more digestible.

Teeth of the Edentata, or Bruta.

Although this group is by no means the most primitive of the Mammalia, as will be seen by reference to the table of classification, yet the characters which we have assigned to the ideal primitive mammalian dentition are most nearly approached in certain members of this order. Whether the comparatively simple form and absence of enamel in the adult tooth, which is characteristic of all the animals of this order, pertain to a primitive state, or whether this condition has been reached by a process of retrogression or degradation, as many believe, we are not at present prepared to say, in the absence of any knowledge of their palæontological history beyond the latest Tertiary epoch. There is one character, however, in which one at least is more decidedly primitive than any other known Eutherian mammal, and that is *the succession of all the teeth but one (the last) by a second set.* I refer to the nine-banded armadillo (*Tatusia peba*). It is not certainly known whether this condition exists in any other of the edentates or not, with the exception of the sloths, which are truly monophyodont.

The term *Edentata* is inappropriate, inasmuch as one would be led to suppose from the name that they have no teeth. The original term, *Bruta*, was applied to this order by Linnæus, which he defined by the absence of incisor teeth. It was afterward changed to *Edentata* by Cuvier—a name which has been extensively adopted by subsequent authors. It was formerly supposed that no incisor teeth are ever present in this group, but the discovery of new forms proved this to be erroneous. The median incisors, however, are wanting in all cases so far known. The definition of the order now most commonly given is "absence of enamel on the teeth." This peculiarity appears at first sight striking and quite sufficient to separate them from all other monodelphous mammals, but C. S. Tomes has shown[1] that the tooth-germs of the nine-banded armadillo have distinct enamel organs, which are subsequently aborted as the tooth comes to maturity. This discovery is important, since it indicates pretty clearly that the loss of enamel is a

[1] *Philos. Trans.*, 1876.

mark of degeneracy, and leads indirectly to the conclusion that the armadillos at least are descended from ancestors with enamel-covered teeth, who in all probability were the possessors of a completely developed second set.

The only assignable cause for this degenerate condition of the dental organs is the peculiarity of their food-getting habits. Many of them feed upon insects, which they capture by means of a long whip-like tongue covered with the viscid secretion of the submaxillary glands, and swallow whole. This manner of feeding would occasion little demand for masticatory organs, which from disuse would gradually fall into a rudimentary condition and eventually disappear. Those in which the entomophagous habit is exhibited in its greatest perfection are edentulous, and have small mouths with extremely long tongues. All the Edentata in which this structure exists at all show a tendency toward such a habit—even the arboreal sloths, which are said to be exclusively vegetable feeders.

Flower has recently shown that the sloths are intimately connected with the ant-eaters and armadillos of South America through the extinct megatheroids, and that all the American forms have probably descended from a common ancestor, while the Old World forms are likewise closely related and descended in another line. It is probably true that the armadillos are most nearly related to the ancestral form, and that the sloths represent an offshoot which was derived from them after they had lost the enamel of the teeth in the manner indicated.

The teeth of the armadillos are, with one exception, relatively small cylindrical bodies implanted in the dentigerous borders of the lower jaw, maxillary, and sometimes premaxillary bones. They are entirely devoid of enamel, and grow continuously throughout the life of the animal, in consequence of which no roots are formed.

FIG. 198.

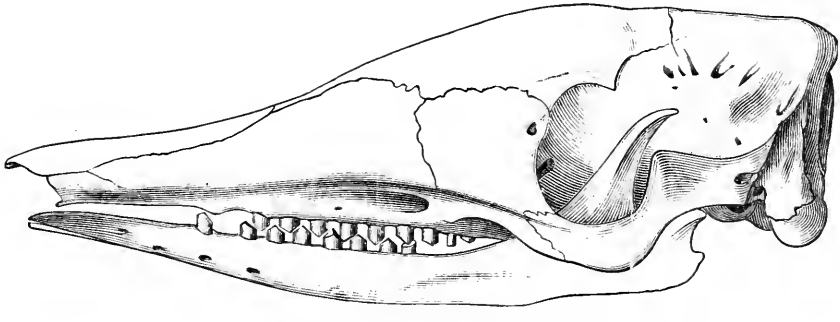

Side View of the Skull of a Seven-banded Armadillo (*Tatusia hybridus?*)

In the seven-banded armadillo (*Tatusia hybridus*, Fig. 198[1]) there are seven teeth above and eight below upon each side. So little is known

[1] The specimen here figured is in the U. S. Army Medical Museum, and is labelled *Tatusia septemcinctus*. It exhibits the peculiarity of having eight teeth upon one side and seven upon the other in the upper jaw. There is, however, a considerable space between the first and second tooth of the right side which would indicate that a tooth is missing. The number ascribed to this species by Owen is seven above and eight below upon each side. Its exact identification is therefore difficult.

about their succession that it is impossible to say whether there are molars and premolars represented or not. The teeth of the upper series are lodged in the maxillary bones, and begin at a considerable distance behind the maxillo-premaxillary suture. They progressively increase in size up to the fifth or sixth tooth, the last being quite small. They are not in contact with each other, but are separated by slight spaces about equal to the width of a tooth. The teeth of the lower jaw are similar to those of the upper jaw in size and shape, with the exception of the last, which is much larger than the corresponding tooth above. The teeth of the inferior series close in the intervals between those of the upper and conversely, causing the summits of the crowns to wear, as Prof. Owen puts it, "into two facets divided by a median transverse ridge." The form of the working surface of the tooth is therefore wedge-shaped. The first two teeth of the lower jaw shut in front of the first tooth above, and the last three teeth above behind the last one of the lower series, leaving them with little or no opposition. Each tooth continues its cylindriform shape to the bottom of the alveolus in which it is implanted, having its base excavated into a large pulp-cavity. It consists of dentine and cementum only.

In another species, the nine-banded armadillo, the number and form of the teeth are the same. The teeth of this animal, as has already been stated, have a successional set. According to the definition laid down for premolar and molar teeth in the diphyodont Mammalia generally, there would be one molar and six premolars in the dentition of this animal. The rooted appearance of the deciduous teeth, according to Tomes, is not due to the possession of true roots, but to the absorption set up by the approach of the successors.

The genus *Priodon* of this group has as many as one hundred teeth, the greatest number exhibited by any land mammal. They are relatively small and simple in form, and are confined to the maxillary and mandibular bones. They vary in number from twenty-four to twenty-six upon each side in the upper, and from twenty-two to twenty-four upon each side in the lower jaw. In the living genus *Dasypus* there is one tooth upon each side implanted in the premaxillary bone, which, according to the definition, becomes an incisor, while in still another extinct genus, *Chlamydotherium*, almost equalling in size the rhinoceros, there were two incisors above and three which opposed them below. In *Glyptodon* the teeth are more complex in pattern, being laterally compressed and divided by two vertical grooves upon each side, which are opposite to each other. The resulting structure from this arrangement is three transverse vertical plates connected in the centre by an isthmus. There were teeth in the premaxillaries in this genus.

The megatheroids afford another example of moderate complexity in the enamelless teeth of the *Bruta*. In the gigantic extinct *Megatherium* there are five molars above and four below upon each side. They are very deeply implanted in the substance of the jaw bones, and have remarkably elongated pulp-cavities, which communicate with the grinding surface by means of a narrow fissure. The pulp-cavity is immediately surrounded by soft, more or less vascular dentine—the vaso-dentine of Owen—which is covered by a thin layer of unvascular, much

harder dentine. Upon the outside of this comes the cementum, which has a great thickness upon the anterior and posterior face of the tooth. Owing to the unequal powers of resistance which these substances offer, the teeth wear in such a manner as to present two transverse crests each, and are therefore spoken of as *lophodont*. They are confined to the maxillary and mandibular bones and grow from persistent pulps.

In another extinct allied genus, *Megalonyx*, the teeth are oval in section, and did not wear into transverse crests as in *Megatherium*, but have slightly concave grinding faces. The first tooth of the upper series also is considerably enlarged and caniniform in shape, as in one of the living sloths. Another nearly-related form is *Mylodon*, likewise extinct, which exceeded the rhinoceros in size. The first tooth above, instead of being enlarged and caniniform, is smaller than the succeeding ones, and otherwise like them in pattern.

The dental formula of the three-toed sloth (*Bradypus tridactylus*) is I. $\frac{0}{0}$, C. $\frac{0}{0}$, M. $\frac{5}{4}-\frac{5}{4}=18$. It has been observed, however, that there is in some young examples of this species a small extra tooth in the lower jaw just in front of the first permanent one, which is shed before the animal attains to the adult state. The teeth are relatively small, of a columnar form, and implanted to a moderate depth in the substance of the jaws by a deeply-excavated base for the accommodation of the persistent pulp. The grinding surface presents a central depression in the vaso-dentine, surrounded by a raised rim on its outer margin composed of the harder dentine, which usually wears unequally into one or two prominent points. The teeth of the upper and lower jaws do not oppose each other exactly, but alternate when the mouth is closed.

In the two-toed sloth (*Cholœpus didactylus*) the dental formula is the same. The first tooth in each series, which in the edentates generally is the smallest, is here greatly increased in size, of a subtrihedral form, and of a caniniform pattern. They are separated by a considerable diastema from the rest of the teeth, and are implanted above in the maxillary bones a short distance behind the maxillo-premaxillary suture. It will be seen, therefore, that as far as the definition of a canine tooth is concerned, all the conditions are fulfilled; but the tooth in the lower series, which has undergone a similar modification, violates the definition of a canine, inasmuch as it closes behind the upper caniniform tooth instead of in front of it. It is therefore a matter of uncertainty whether these teeth are strictly homologous with the canines of the diphyodont Mammalia or not. From the manner in which they oppose each other the posterior surface of the upper and the anterior surface of the lower are extensively abraded, and their summits worn into sharp points, which would render them efficient weapons of offence or defence should the animal choose to use them as such.

The next tooth of the upper series is relatively small, and is implanted rather obliquely, with the summit inclined backward and inward. The two following teeth are larger, with a central depression upon the grinding face, and having the external and internal portions of the rim produced into sharp points. The last tooth is about equal to the second in size, which it also resembles in form.

The teeth of the lower series resemble those of the upper, with the

exception that the three posterior ones are more robust and gradually decrease in size from the second to the last. Viewing the teeth and accessory bony structures of this animal as a whole, the premaxillæ are remarkable for their small size, little extension anteriorly beyond the maxillæ, and the complete absence of the ascending or nasal process, as well as their edentulous condition. The palatal plates of the maxillæ are widest in front and gradually narrow posteriorly, causing the dental series of opposite sides to converge behind. In the lower jaw the two halves are completely co-ossified, as in monkeys and man; the anterior part of the symphysis is produced into a peculiar spout-like termination, at the base of which the jaw widens rapidly; and the rami are little divaricated posteriorly. The posterior teeth are implanted in a strong inwardly projecting ledge, in consequence of which the dentigerous border gradually approaches the median line as it proceeds backward. The mental foramen is placed below the interval between the third and fourth teeth near the middle of the ramus.

With respect to the teeth themselves, Owen gives the following common and constant characters of both recent and extinct sloth-like animals, which would include the megatheroids: "Teeth implanted in the maxillary, never in the intermaxillary bones; few in number, not exceeding $\frac{5}{4}-\frac{5}{4}$; composed of a large central axis of vascular dentine, with a thin investment of hard or unvascular dentine, and a thick outer coating of cement. To these, of course, may be added the dental characters common to the order *Bruta*—viz. uninterrupted growth of the teeth, and their concomitant implantation by a simple deeply-seated excavated base, not separated by a cervix from the exposed summit or crown."

Of the two Old World genera now living, but one has teeth. This is the aard-vark (*Orycteropus*), or, as it is sometimes called, the Cape ant-eater. Its dental formula is M. $\frac{7}{6}-\frac{7}{6}=26$, of which the anterior ones of each series are not unfrequently wanting or concealed by the gum. The teeth of the superior set progressively increase in size from before backward up to the last tooth, which is smaller. They are oval in section, with the exception of the fourth and fifth, and have wedge-shaped triturating surfaces, like the armadillos. The fourth and fifth above and the last two below have two vertical grooves, one upon each side, which give to them an hour-glass shape upon section.

The teeth of this animal do not exhibit the customary excavated base of the Edentata generally, but are continued solid to the bottom of the sockets. Their minute structure is peculiar, and resembles that found in *Myliobates* among the elasmobranch fishes; the dentine is of the variety known as plici-dentine. This consists of a series of small vertical parallel tubuli which pass up from, and are virtually prolongations of the pulp-cavity. From these the dentinal tubuli radiate toward the periphery, just as they do from the single pulp-cavity of the human tooth already described. Owing to this peculiarity, Prof. Owen regarded the tooth of *Orycteropus* as an aggregate of many denticles, each with its proper pulp-cavity and dentinal tubes.

In Europe fossil remains of edentates are known from the Middle Miocene of Sansan in France and the upper Miocene deposits of Pikermi in Greece. Two genera, *Macrotherium* and *Ancylotherium*, have been

described by Lartet and Gaudry, from feet and limb bones principally, nothing being known of the skull or teeth. In South America fossil remains of this order are very abundant in the Pampean or Pliocene deposits. Older deposits on the Parana River have furnished M. Ameghino with numerous forms which stand in ancestral relation to those of the Pampean beds, and which, it is interesting to observe, have more or less enamel on the teeth. In North America, Prof. Marsh has described a genus under the name of *Morotherium*, from the Loup Fork or Upper Miocene strata, from feet bones only. The teeth are not known.

Teeth of the Cetacea.

According to Dr. Theo. Gill's arrangement, the cetaceans are divisible into three groups or sub-orders, as follows: *Mysticete*, including the "whalebone whales;" *Denticete*, or the "toothed whales," and *Zeuglodontia*, a division which includes *Zeuglodon* and several other extinct genera. In the *Mysticete*, teeth are present in a fœtal state only, being absorbed before birth. This loss of the teeth is compensated for by the development of large corneous plates, the "baleen plates," which depend from the roof of the mouth. The more important of these are of a triangular form, and are arranged along each side of the palate in such a manner as to be transverse to the axis of the skull, the centre being occupied by smaller ones, also placed transversely. Altogether, they form by their extremities a vaulted surface into which the large tongue fits accurately, their edges being broken up into numerous stiff hairs which project into the mouth. The animal feeds by taking large quantities of water into the mouth and expelling it again through the nostrils ("spouting"); any small aquatic animals which may have been contained in it are entangled in the fringes of the baleen plates, and subsequently collected by the tongue and swallowed. It will thus be seen that the baleen acts as a sort of sieve or strainer, and is pre-eminently adapted to the capture of the small aquatic forms with which the sea in certain places literally swarms. Each baleen plate possesses a pulp situated in a cavity at its base, from which it is developed, and through which it is regenerated as fast as worn away. According to Tomes, each hair-like fibre has within its base a vascular filament or papilla; "in fact, each fibre is nothing more than an accumulation of epidermic cells concentrically arranged around a vascular papilla, the latter being enormously elongated. The baleen plate is composed mainly of these fibres, which constitute its frayed-out edges; and in addition to this there are layers of flat cells binding the whole together and constituting the outer or lamellar portion."

All the whalebone whales possess rudimentary teeth, or rather dentine and enamel organs, which undergo very little calcification before absorption sets in. In the fin-backs (*Balænoptera*) these dentine organs are simple in the front part of the mouth, bifid in the middle, and trifid in the back part of the jaw. They are placed in an open groove along the jaw, as in all other Mammalia at this stage of embryonic growth, and do not differ from them in any important particular.

In the second sub-order (*Denticete*) no baleen plates are developed; teeth are always present, and are more or less persistent. They are implanted by single roots, and are in some instances very numerous. No second dentition has ever been observed in any member of this group, and they are, so far as known, truly monophyodont. In the common porpoise of our coast (*Delphinus chymene*), which is an average example of this sub-order, the teeth are about ninety-four in number, and are lodged in the premaxillary, maxillary, and mandibular bones. They are implanted by single slightly enlarged fangs in ill-defined sockets incompletely partitioned off from each other, and in what at first sight seems to be a wide-open groove. Their crowns taper gradually to a sharp point, which is strongly incurved. The first two teeth in the upper jaw are small and implanted in the premaxillary bone, which furnishes a very small part of the dentigerous border of the upper jaw. Behind these the maxillary teeth rapidly increase in size up to the seventh or eighth tooth, after which they continue to the fifteenth or sixteenth almost equal in size, and then gradually diminish in size toward the posterior part of the jaw. The teeth of the inferior series are like those of the upper, except that the posterior ones are more robust. The jaws are remarkable for their great length and narrowness, and the arrangement of the bones of the face when compared with other mammals is also peculiar. The coronoid process of the lower jaw is obsolete.

In other members of the *Delphinida*—the dolphin, for example—the teeth are often as many two hundred, the greatest number exhibited by any mammal, or they may be reduced to a single functional tooth, as in the narwhal (*Monodon*). In this latter species four teeth are found in a fetal state, but the two lateral ones are lost or absorbed before birth. In the male narwhal the left of the two anterior ones, which is placed in the premaxillary bone, grows from a persistent pulp and attains a length of ten or twelve feet. This formidable tusk is almost straight, and is marked by spiral ridges which wind forward from left to right. The corresponding tooth of the opposite side sometimes reaches a development equal to that of the left, but more frequently its growth is arrested and it remains buried beneath the gum, as do both in the female. Owing to this circumstance, it has been thought that it serves as a sexual weapon similar to the antlers of the deer, but until the habits of the animal are better known this explanation of its use must remain conjectural.

The great bottle-nosed whale (*Hyperoödon bidens*) is, to all outward appearances, edentulous, but careful examination reveals the presence of two, sometimes four, well-calcified conical teeth in the front part of the jaw, which remain more or less completely hidden by the gum. In addition to these, there are usually twelve or thirteen small rudimentary teeth imbedded in the gums of both jaws, which soon disappear.

In the sperm whale (*Physeter macrocephalus*) the exposed and functional teeth are confined to the lower jaw. These are about twenty-seven in number in each ramus, loosely implanted in a wide-open gutter, with the alveoli or sockets scarcely perceptible. They are at first sharply conical, but by attrition wear down into obtuse cones, biting into pits or cavities in the gums of the upper jaw. In this jaw there

are a number of persistent rudimentary teeth concealed in the thick gums, one pair of which is exposed in the small pug-nosed sperm whale (*P. simus*).

In the dolphin of the Ganges (*Platynista gangetica*) the total number of teeth is one hundred and twenty-four, of which there are thirty upon each side above and thirty-two upon each side below. In the young animal their crowns are produced into sharp cones, but by attrition the posterior teeth are worn down to such an extent as to become molariform in shape. The last tooth in this species not unfrequently develops a double root or fang, and is the only example of the kind to be met with in living cetaceans.

The teeth of the dolphins of the Amazon are surrounded at the bases of their crowns by a well-marked ledge or cingulum, which throws up a strong internal cusp. On this account Dr. Gill elevates the genus *Inia* to the rank of a family.

The sub-order *Zeuglodontia* is extinct, and includes a number of fossil cetaceans, some of which are estimated to have attained a length of seventy feet. They differ from living representatives of the order in many important osteological characters, but not more prominently than in their dental organization. Besides being heterodont and having the posterior teeth implanted by two or three roots, *some, if not all, were diphyodont as well.* The exact extent of the replacement, however, is not fully known, but it is certainly true that two sets of teeth were developed. In *Zeuglodon cetoides* (Fig. 199), from the Claiborne

FIG. 199.

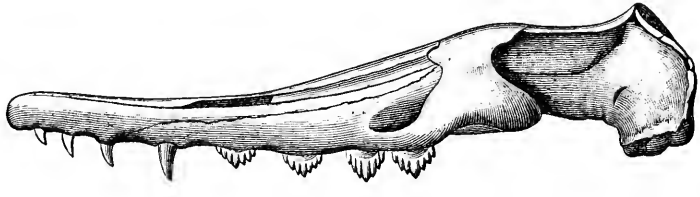

Side View of the Skull of *Zeuglodon cetoides* (after Gaudry).

Eocene deposits of Louisiana, Alabama, and Mississippi, the teeth are divisible by their form and position into incisors, canines, and molars. Three teeth with conical recurved crowns are implanted by single roots in each premaxillary bone, which in this animal contributes a considerable part of the tooth-bearing border of the upper jaw. Of these the anterior is the smallest and placed at some distance behind the extreme anterior border, the posterior ones gradually increasing in size. Behind these, near the maxillo-premaxillary suture, is a strong recurved single-fanged tooth of a caniniform pattern, and one which both by position and form becomes the homologue of the canine in the ordinary heterodont dentition. The rest of the alveolar border is occupied by four rather large more or less trenchant teeth, referable to the molar and premolar series. Each of these is implanted by two roots, and has a laterally compressed crown of a triangular form with the apex of the triangle at the summit. Each of the anterior and posterior edges are

interrupted by three well-marked cusps, which give to the tooth a strongly-serrated appearance.

The heterodont and diphyodont character of the teeth of this cetacean serves to bring the anomalous, and in many respects degenerate, dental organs of this order into the closest relationship with the teeth of the ordinary diphyodont Mammalia, and, being the oldest member of the group so far known, goes far toward filling the wide gap between these aquatic and the terrestrial mammals.

Teeth of the Unguiculate Series.

In considering the dental organization of this vast assemblage of mammiferous animals it is necessary to have at the very outset a correct conception of the primitive or ancestral stock from which all of them have been derived, if such can be found to exist. This can be learned only by a careful study of the successional history of the various orders composing it. In searching, then, for this original stem we can by this method exclude many of the groups from this position by fixing the date of their appearance, and thereby establishing their exact limit in time. We know, for example, that the *Primates* could not be the ancestral group, for the obvious reason that they do not extend beyond Miocene time; nor the Carnivora, which appeared about the same time; nor the Rodentia, which date from the Middle Eocene; nor the *Cheiroptera*, which can be traced back no further than the Upper Eocene. We are therefore restricted in our choice to the insectivores, lemuroids, creodonts, or tillodonts, which alone of the entire series continue backward to the base of the Eocene Period. With reference to the creodonts, I do not believe that any important distinctions exist between them and the insectivores, while the line between this latter group and the lemuroids and tillodonts becomes extremely shadowy at this point.

Prof. Cope unites the insectivores, lemuroids, tillodonts, creodonts, and tæniodonts into one order, which he calls *Bunotheria*, and defines the several sub-orders as follows:[1]

I. Incisor teeth growing from persistent pulps:
  (*a*) Canines also growing from less persistent pulps, agreeing with external incisors in having molariform crowns . . . . . *Tæniodonta.*
  (*b*) Canines rudimental or wanting; hallux not opposable . . . . *Tillodonta.*
  (*c*) Canines none; hallux opposable . . . . . *Daubentonioidea.*

II. Incisor teeth not growing from persistent pulps:
  (*a*) Superior true molars quadritubercular; hallux opposable . . *Prosimiæ.*
  (*b*) Superior true molars quadritubercular; hallux not opposable. *Insectivora.*
  (*c*) Superior true molars tritubercular or bitubercular; hallux not opposable. *Creodonta.*

I believe, with this author, in classifying those forms in which the incisors grow from persistent pulps as a distinct group from those in which the incisors are normal, as far at least as their growth is concerned. In the first division there are three well-defined sub-orders. In the second division it is extremely questionable whether more than two sub-orders should be made. If we use the opposable and non-opposable condition of the hallux as a character, we will have two perfectly natural

[1] *Proceedings Academy Natural Sciences Philada.*, 1883.

series—the prosimian or lemuroid and the insectivorous; but if we go further, and establish another sub-order upon the tritubercular or quadritubercular character of the superior molar teeth, it will necessitate the wide separation of forms closely related to each other by every important feature of their anatomical structure—a course which I do not deem advisable nor in keeping with our present knowledge of the subject.

According to Prof. Cope's definition, the only character in which the Creodonta differ from the Insectivora is the tritubercular superior molars as distinguished from the quadritubercular; and in order to make the Creodonta homogeneous he is compelled to take out of the old group Insectivora the *Tupaiadæ*, *Centetidæ*, *Chrysiochloridæ*, and *Talpidæ*, and place them in the Creodonta. Aside from the inadvisability of such a course, these teeth in many of the above-named families are altogether intermediate between the tritubercular and quadritubercular pattern, the postero-internal tubercle being represented often by a rudimentary cingulum, which may be entirely absent or produced into a strong cusp. Then, again, the superior molar teeth of the prosimian division are indifferently tritubercular or quadritubercular; and if we adhere to this practice in the one, why not in the other? In consequence of these facts, I propose to unite the Creodonta with the Insectivora into a single division, for which the old name Insectivora may be retained.

Thus constituted, palæontological history, in my judgment, points strongly to the fact that this group stands in the important relationship of ancestors to a large part, if not the whole, of the unguiculate Mammalia. Working upon this hypothesis, it will be desirable to describe the more important types of dental structure to be met with in this sub-order, after which they can be followed out to their respective terminations in the various orders and sub-orders which make up the series.

Insectivora.—The simplest form of dental structure in this sub-order is exhibited by the extinct genera *Mesonyx* and *Dissacus* of Cope, from the American Eocene strata. The teeth of *Mesonyx* (Figs. 200, 201) are forty-four in number, disposed as follows: I. $\frac{3}{2}$, C. $\frac{1}{1}$, Pm. $\frac{4}{4}$, M. $\frac{3}{3}$ = 42. The incisors are relatively small, with subconic crowns, which are closely approximated. The superior canines are large, recurved, and pointed, being placed at a considerable distance from the incisors to accommodate the crown of the inferior canine. The three anterior premolars of the upper jaw are two-rooted, with the exception of the first, which is probably single-rooted. They have comparatively simple compressed crowns, with a principal cusp and a posterior basal lobe, surrounded by a basal cingulum. The fourth is more complex, and resembles the true molars posterior to it. Like them, it has three principal cusps, of which two are external and one internal, giving to the crown a triangular shape. In the first true molar the postero-external angle of the crown is produced into a strong blade-like process, a development of the cingulum which is conspicuous in all. The last molar of this series is bicuspid, the posterior of the two external cusps being absent.

In the lower jaw both the premolars and molars are remarkable for their simplicity. The first premolar is single-rooted, and has a subconic crown, as in the dog. The teeth behind it are two-rooted, and

have a general premolariform appearance, the true molars exhibiting but little departure from the conical pattern of the lower Vertebrata. As in the premolars of the dog, their crowns are laterally compressed, of a

FIG. 200.

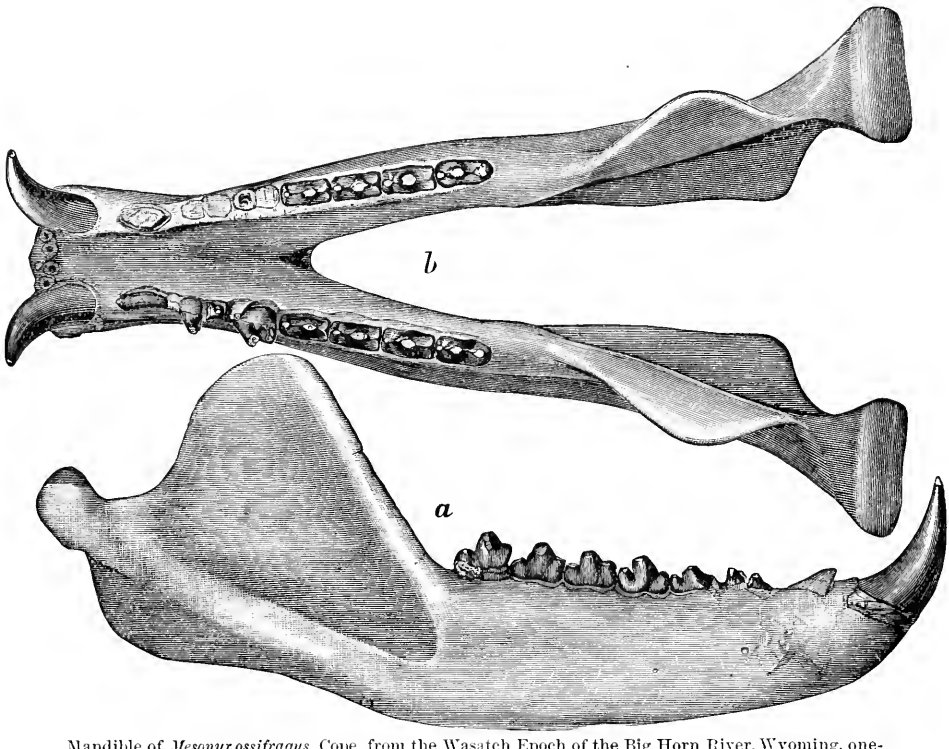

Mandible of *Mesonyx ossifragus*, Cope, from the Wasatch Epoch of the Big Horn River, Wyoming, one-third natural size (after Cope).

triangular form when viewed from the side, having a principal median cusp, to which are added an anterior and posterior smaller one from the cingulum.

It is a matter of considerable interest to find in this ancient representative of the unguiculate series so simple and generalized a dentition, inasmuch as it furnishes a key to an interpretation of the lobes and cusps of the teeth of many of the succeeding forms. It is more than probable that this particular species is not the original ancestral form from which the others have been derived, on account of certain characters presented by the skeleton, but, as far as the teeth of the lower jaw are concerned, they exhibit just such a transitional condition between the primitive cone of the theromorph Reptilia and the lowest forms of mammalian teeth as we would most reasonably expect to find in the primitive ancestor.

The various steps in this process of dental evolution I conceive to have been as follows: (1) additions to the anterior and posterior edges of the cone and the formation of a cingulum; (2) division of the single

root into two; (3) addition of basal cusps from the cingulum. It is a fact worthy of notice that in the conical dentition the teeth of one series do not exactly oppose those of the other, but close in the intervals between them. This in animals that attempted to crush a morsel of food would cause stimulation of the anterior and posterior edges of the tooth, thereby determining the point of the greatest nutritive activity and consequent growth. Long-continued vertical pressure I believe to be an adequate cause for the appearance of the wrinkle or fold of the enamel covering at the base of the tooth which is designated as the cingulum.

FIG. 201.

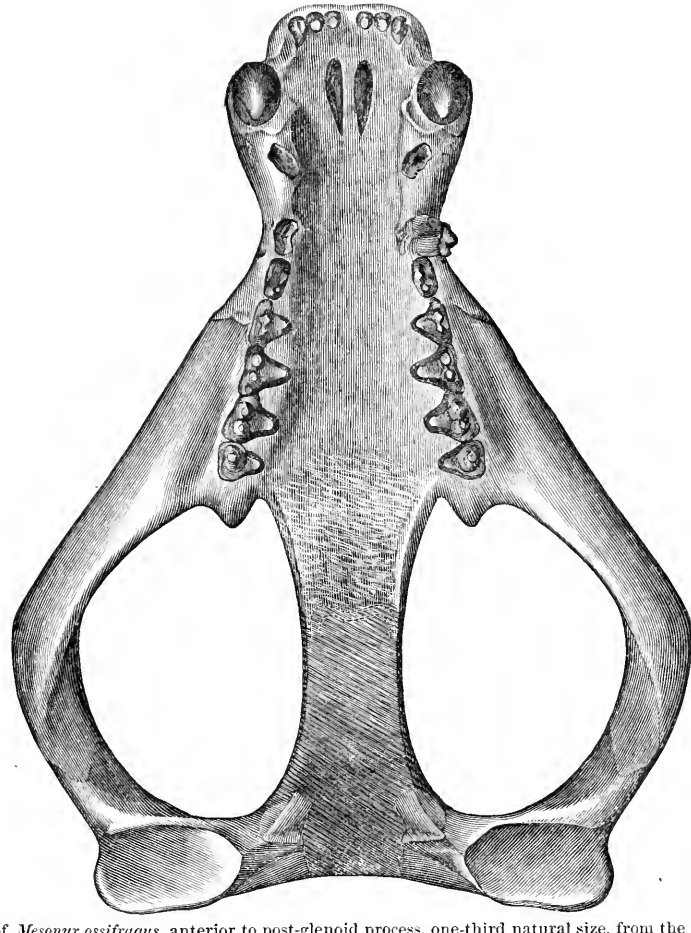

Skull of *Mesonyx ossifragus*, anterior to post-glenoid process, one-third natural size, from the Wasatch beds of Wyoming (after Cope).

The formation of two roots I believe to have been the result of the inequality of pressure exerted upon each tooth during the act of mastication, whereby there was an effort to displace the tooth in an antero-posterior direction, or, in other words, to give it a forward and backward rocking

movement, as the greatest pressure was in front of or behind it. This would cause the stimulation of the anterior and posterior faces of the root, and as a consequence of this a vertical groove was first formed upon each side, which eventually coalesced, dividing the root into two. As we have already seen, this condition is found in a theromorph reptile, and is likewise to be found in the premolars of many existing animals. The development of basal cusps would naturally follow at those points where the crown sustained the greatest amount of resistance, which would be at the base of the triangle.

It is a rule of pretty general application in heterodont teeth that the molars are more modified than the premolars. This, in all probability, results from the greater mechanical advantage which is gained by bringing the morsel to be crushed or divided to the posterior part of the mouth; that is to say, the resistance as near to the power as possible. The power in this case is the muscles which close the mouth, which, being attached to the posterior part of the jaw, exert the greatest influence upon those teeth in the vicinity of their attachment.

The next step in dental complication is seen in the genus *Dissacus*, from the lowest Eocene, the lower teeth of which are represented in Fig. 202. They are very similar in general appearance to those of

FIG. 202.

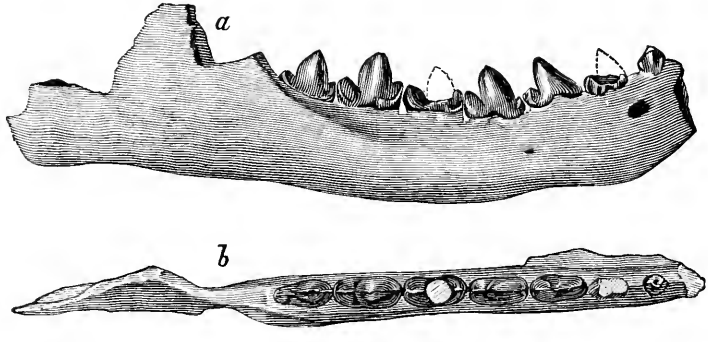

Dissacus navajovius, Cope. Right Mandibular Ramus, three-fourths natural size: *a*, external; *b*, superior view, from the Puerco Beds of New Mexico (after Cope).

Mesonyx, with which they also agree in number. There is, however, an additional cusp developed upon the inner side of the median cone near its summit, which is the homologue of the internal tubercle of the inferior sectorial of the dog, as well as that of many other animals of the unguiculate series. The upper teeth are not known. The genera in which the mandibular teeth present this premolariform structure are associated by Cope into a family which he calls the *Mesonychidæ*.

As a probable derivative of this family we have the extinct family *Hyænodontidæ*, of which the teeth of the single genus *Hyænodon* are represented in Fig. 203. This animal is known, so far, from the Miocene deposits of this country and Europe only, and has been shown by Prof. W. B. Scott of Princeton College to be a near relative of *Mesonyx*. The dental formula is, according to Gaudry, I. $\frac{3}{3}$, C. $\frac{1}{1}$, Pm. $\frac{4}{4}$, M. $\frac{2}{3}$ = 42. The incisors resemble those of the dog, the median pair being

the smallest, the outer pair the largest. The canines are large, pointed, and recurved. The anterior premolars above are two-rooted and have premolariform crowns. The third and fourth are three-rooted, with

FIG. 203.

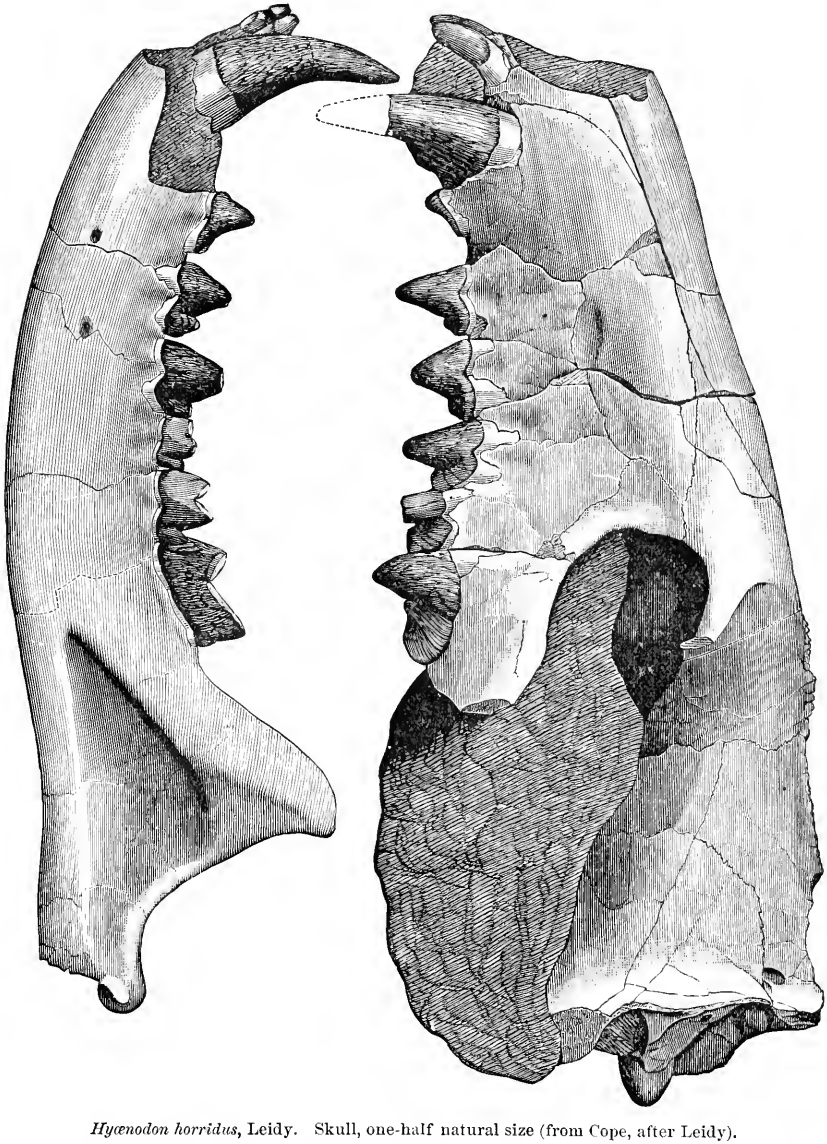

Hyænodon horridus, Leidy. Skull, one-half natural size (from Cope, after Leidy).

three external and one internal cusp, which in the third premolar is small and placed far back; in the fourth it is large and has a position nearer the middle of the tooth; while in the first and second molars it is anterior and more or less rudimental. The anterior cusp and median

cone in these latter teeth form cutting blades and are truly sectorial in their nature.

In the lower jaw the first premolar is two-rooted, with a compressed crown without basal lobes. The second, third, and fourth have well-developed posterior basal lobes, with the anterior absent. The first true molar has three lobes, which form an imperfect trilobed sectorial blade. The second is also trilobed, having the anterior cusp and median cone developed into a true sectorial, while the posterior lobe forms a cutting heel. In the third the heel is rudimental or absent, and the anterior lobe and median cone are modified into a perfect trenchant blade.

From the *Mesonychidæ* we pass, through *Dissacus* and *Triisodon*, to another extinct family, which Prof. Cope calls the *Leptictidæ*. In an

FIG. 204.

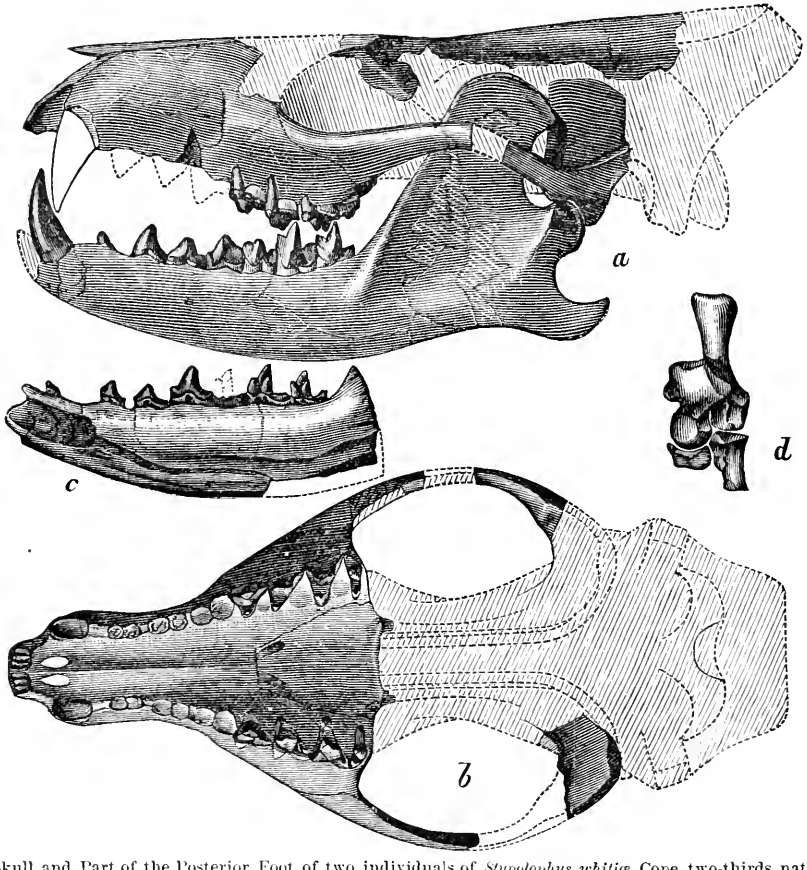

Skull and Part of the Posterior Foot of two individuals of *Stypolophus whitiæ*, Cope, two-thirds natural size: *a*, *b*, side and under views of the skull; *c*, portion of lower jaw; *d*, ankle-joint (after Cope).

Eocene genus of this family, *Stypolophus*, Cope (Fig. 204), the dental formula is I. $\frac{3}{3}$, C. $\frac{1}{1}$, Pm. $\frac{4}{4}$, M. $\frac{3}{3} = 44$. The incisors, canines, and premolars are very like the corresponding teeth in *Mesonyx*. The last superior premolar is, like the true molars, tritubercular, with the pos-

terior external angle produced into a prominent process, which is connected with the postero-external cusp by a sharp cutting ridge. The cingulum also furnishes a broad ledge upon the outside of the two external cusps.

In the three inferior true molars the median cone, the anterior basal lobe, and the internal tubercle are all well developed, and are disposed in such a manner as to form an equilateral triangle, with the apex directed forward and the base backward. Of these, the anterior basal lobe occupies a position at the apex of the triangle, the median cone and internal lobe being placed at the external and internal angles of the base respectively. The posterior basal lobe is also present in the form of a low heel, which may in some genera retain a simple cutting form or may be broken up into several and become "basin-shaped." This form of tooth Prof. Cope proposed some years ago to designate by the name of "*tuberculo-sectorial*." There can be little doubt that it furnishes the point of departure for the sectorial teeth of the lower jaw

FIG. 205.

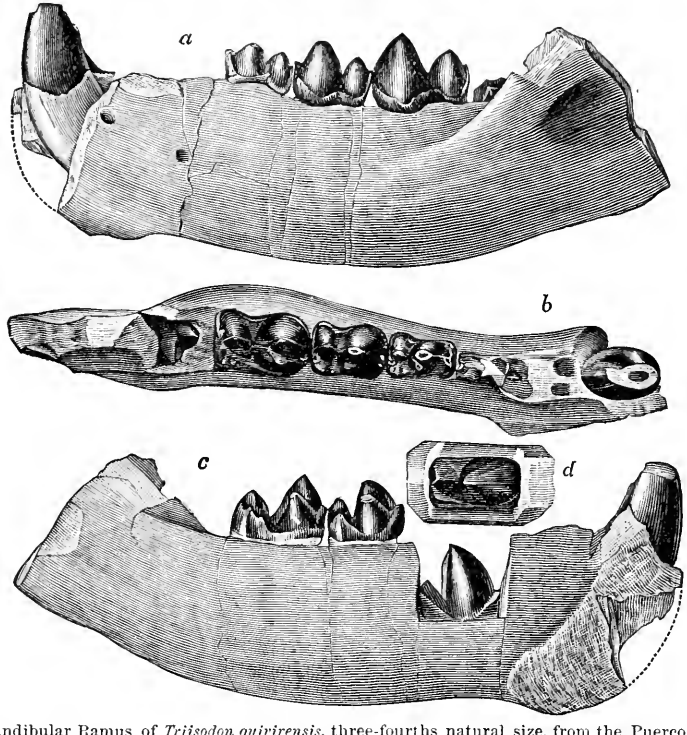

Left Mandibular Ramus of *Triisodon quivirensis*, three-fourths natural size, from the Puerco of New Mexico; *a*, external view, displaying last temporary molar in place; *b*, the same from above; *c*, the same, internal side, the temporary molar removed and the permanent fourth premolar displayed in the jaw; *d*, the fourth premolar seen from above (after Cope).

of the modern *Carnivora* on the one hand, and the quadritubercular lower molar of the entire unguiculate series on the other.

As will be seen, it displays the same elements that are found in the inferior sectorial of the dog, the only difference being in the relatively

smaller size of the internal tubercle and the modification of the primitive cone and anterior basal lobe into a more perfect sectorial form in the dog. The quadritubercular tooth has been derived from this by the suppression of the anterior basal lobe, the reduction in size of the median cone and internal tubercle, and the division of the heel into two cusps, whereby the median cone becomes the antero-external tubercle, the internal tubercle the antero-internal, and the heel the two posterior ones.

The genus *Triisodon* of Cope (Fig. 205) affords a perfect transition between *Stypolophus* and *Dissacus*, as far as the pattern of the inferior teeth is concerned. In another genus, *Chriacus*, Cope, from the Lower Eocene, which is provisionally referred to this family, the upper molars are tritubercular with a strong internal cingulum, which develops a rudimental fourth cusp behind. This forms one of the examples referred to in which it is difficult to say whether the teeth in question are tritubercular or quadritubercular, and goes far toward invalidating the definition of the *Creodonta* as given by Cope. This author says in reference to this family, and more especially to this genus: "Two groups are easily recognized among the *Leptictidæ*. In the first of these the last or fourth inferior premolar is a simple premolariform tooth, different from the inferior true molars and without any internal cusp. In the second division the fourth inferior premolar is either like the first true molars or approximates their form by the presence of an internal tubercle. To the latter group belongs the genus *Chriacus*, which, from the slight development of the fourth inferior premolar, approximates the first division. This genus may, however, be improperly referred to the Creodonta." [1]

FIG. 206.

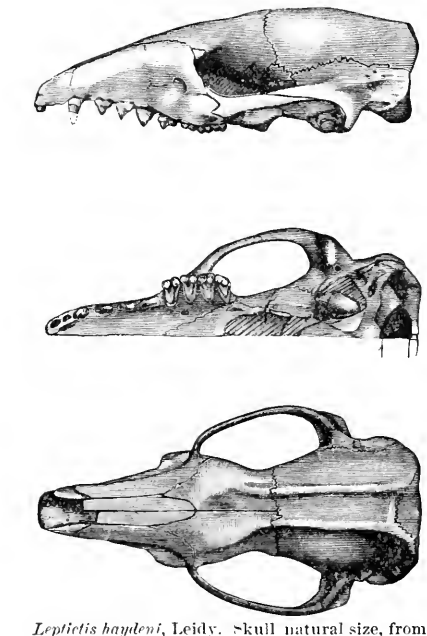

Leptictis haydeni, Leidy. Skull natural size, from the White River beds of Nebraska (from Cope, after Leidy).

Still another genus of this family, *Mioclænus*, also from the Eocene, presents truly quadritubercular lower molars. The premolars are simple and conical, and differ widely in their structure from the molars. The superior true molars are similar to those of the preceding genus, with the exception that the fourth tubercle is better defined and furnishes another example of the transition between the tritubercular and quadritubercular condition.

In the typical genus *Leptictis* of Leidy (Fig. 206) the dental formula is probably the same as that of *Stypolophus*, the lower jaw being imperfectly known. The upper teeth

[1] "The Creodonta," *American Naturalist*, April, 1884, p. 348.

are like those of *Stypolophus* in having the fourth premolar and all the true molars tritubercular. There is no broad ledge external to the outer cusps, however, as in that genus, and the posterior external angle of the crown is not produced. It is from the White River Miocene of this country, as is also a nearly-related genus, *Ictops* of Cope. The only difference between these two genera is the more complex form of the fourth superior premolar in the latter.

The living genus *Centetes*, or tenrec of Madagascar, is closely related to this family, and differs only in the incomplete condition of the zygomatic arch. The number and form of the teeth are very like those of *Leptictis*, and it is highly probable, as Cope suggests, that *Centetes* is the living descendant of this genus.

Another quite remarkable genus which Cope places in this family is from the Eocene, and was described by him under the name of *Esthonyx*. Its dental formula (Fig. 207) is I. $\frac{1}{2}$, C. $\frac{1}{1}$, Pm. $\frac{3}{3}$, M. $\frac{3}{3}$ = 34. The single superior incisor of each side is greatly enlarged, and exceeds the canine in size. The first premolar is small and has a simple crown. The next is larger, and is tritubercular. The third is like the true molars, with the exception that it lacks the internal cingulum. The true molars have two external cusps, bordered upon the outside by a broad ledge which is produced anteriorly into a marginal cusp. There is a large internal cusp, from which is developed at its inner posterior extremity a strong cingulum, the representative of the fourth cusp, which is continued thence around the base of the crown behind to join its broad external portion. This is another case wherein the tritubercular and quadritubercular question is involved in uncertainty.

FIG. 207.

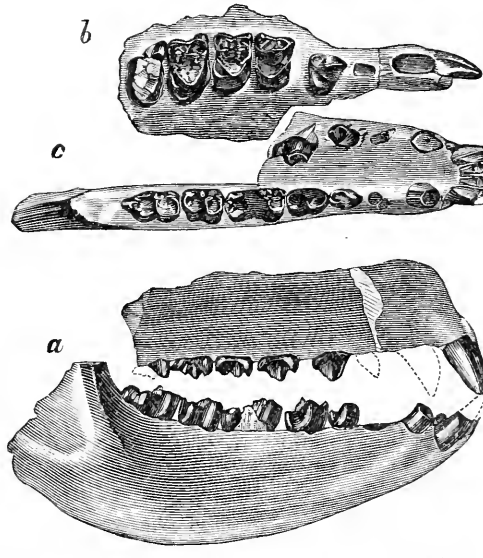

Esthonyx burmeisteri, Cope: *a*, *b*, *c*, parts of upper and lower jaws, two-thirds natural size (after Cope).

In the lower jaw the median incisors are small, the outer pair enlarged, almost equalling the canines. The first two premolars are small, the third larger, resembling the true molars somewhat in form. The molars support two Vs, of which the anterior is most elevated. An analysis of the crown shows it to be of a modified tuberculo-sectorial nature, wherein the three anterior cusps are connected by ridges that extend quite to their summit and form the anterior V. The broad heel displays two cusps connected by a strong ridge; from the outer of these, again, another ridge passes obliquely forward to join the internal

cusp, thereby completing the second V. The last molar has a fifth cusp behind, in this respect resembling many of the lemuroids.

The family most nearly approximated to this genus is that including the shrews (*Soricidæ*), which always have two incisors both above and below, greatly enlarged. In *Blarina talpoides*, a living species of this country, the teeth (Figs. 208, 209) are thirty-two in number, of which

FIG. 208.

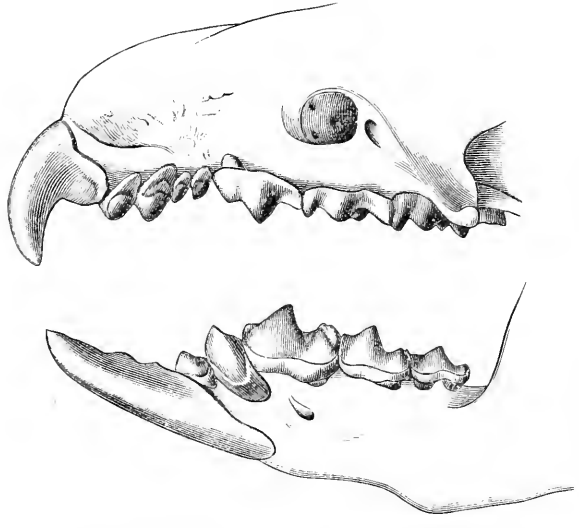

Side View of a Portion of a Skull of *Blarina talpoides* (much enlarged). The sixth tooth of the upper series is placed somewhat internal to the others, and is not represented in the drawing.

FIG. 209.

Vertical View of Grinding Surface of *a*, a lower molar, and *b*, an upper molar (enlarged.)

twenty belong to the upper and twelve to the lower jaw. Owing to the very early co-ossification of the premaxillæ with the maxillæ and the paucity of suitable material, I am at present unable to give the proper dental formula of this animal. Neither can I find any statement upon the subject further than that of Owen, in which he refers to the European species, *Sorex araneus*, with only eight teeth upon each side in the upper jaw, and says:[1] "The determination of the small teeth between the large anterior incisors and the multicuspid molars depends upon the extent of the early ankylosed intermaxillaries; the incisors being defined by their implantation in these bones, the succeeding small and simple crowned molars must be regarded as premolars, not any of them having the development or office of a canine tooth: their analogues in the lower jaw are implanted by two roots." If he confines his statement to this species, it is probably correct to refer all those teeth between the large incisors and the anterior one of the last three to the premolar series; but in *Blarina* there are six teeth to be disposed of. Allowing the normal number of premolars (four), we have either three incisors and no canine, or, as is most probable, two incisors and a canine, which would give the following formula: I. $\frac{2}{1}$, C. $\frac{1}{0}$, Pm. $\frac{4}{2}$, M. $\frac{3}{3}$. This determination of course may prove to be incorrect.

[1] *Odontographie*, p. 418.

The two large incisors above are hook-shaped, with a prominent posterior ledge at the base, which in some species of this family is produced into a strong basal cusp. The next two teeth are much smaller and subequal, while the three following, rapidly decrease in size, the last becoming very small. Exclusive of the large hook-shaped incisor, the abovementioned teeth display a principal cone with an internal lobe and an external cingulum, which is most distinct in the fourth, fifth, and sixth. The next tooth, which I take to be the last premolar, marks an abrupt change both in the character and size of the teeth of the upper series. It is almost equal in size to the first true molar, which it resembles very closely in structure.

The crowns of the molars may be described as consisting of four principal cusps or tubercles, of which two are external and two internal, and are therefore quadritubercular. The two external cusps stand at the apex of two Vs, which open externally, giving to this part of the tooth a distinct W pattern. At the extreme antero-external angle of the crown there is a considerable cingular cusp, which is connected with the main antero-external tubercle by a prominent ridge, thereby forming the first downward stroke of the W. From this main tubercle another well-marked ridge passes outward and backward to another small cusp of the cingulum, situated at a point midway between the two main external tubercles on the outer edge of the crown, forming the first upward stroke of the W and completing the first V. The second downward stroke of the W is furnished by a ridge connecting the small median marginal cusp with the postero-external tubercle, while the second upward stroke of the W is formed by a ridge continued outward and backward to the postero-external angle of the crown, where it terminates in as light enlargement.

From the apex of each of the Vs a high ridge passes inward, meeting at the antero-internal angle of the crown, forming a distinct U. The inner part of this crest is the antero-internal tubercle. The postero-internal tubercle stands just behind it, and exhibits a somewhat crescentiform pattern. It will be seen that the tooth just described does not differ materially from those of some other insectivores already noticed, especially *Esthonyx*. The principal differences are to be found in the greater development of the marginal cingular cusps and connecting ridges upon the external part of the crown, which we have, in a measure, foreshadowed in *Esthonyx* and others.

In the lower jaw the single pair of incisors are large, scalpriform, and procumbent. The two succeeding premolars are small, single-fanged, and have simple crowns. The first two true molars are the largest of the molar and premolar series, and exhibit a structure identical with that of *Esthonyx*. The last is very small, and corresponds with the last tooth of the upper jaw, which frequently disappears. The crowns of all the teeth are stained a deep wine-color by a pigment which penetrates the substance of the enamel, this tissue being remarkable for its thickness in all the Insectivores.

Considerable discussion has taken place in regard to the nature of the external Vs and the exact homology of the two external tubercles. Since this W-structure is common to the superior true molars of all the moles,

shrews, and insectivorous bats, as well as some others of the unguiculate series, it is desirable to have a thorough understanding of it. Cope maintains[1] that the median and anterior marginal cusps are the homologues of the two external tubercles of the teeth of such a form as *Stypolophus* (Fig. 204), and that the two cusps, which are here homologized as the representatives of the two external tubercles of this genus, he proposes to call intermediate tubercles. Mivart, on the other hand, holds[2] that all the marginal cusps are developed from the cingulum, and that the true external tubercles have come to occupy a more and more internal position on the crown—a view which I believe to be correct.

The evidence upon which I base my opinion is to be found by examining the teeth of such genera as *Stypolophus*, *Esthonyx*, and *Scapanus* of the unguiculate series, and *Thylacinus*, *Didelphys*, *Phascogale*, and *Dasyurus* among the marsupials. In the genera *Stypolophus* and *Esthonyx*, as we have already seen, the way is paved, so to speak, for the formation of the two Vs by the appearance of a broad ledge external to the two main outer cusps and the elevation of the cingulum into a small cusp at the antero-external angle of the crown, as well as the backward prolongation of the postero-external angle and its connection with the postero-external tubercle by a strong ridge. This latter ridge I regard as the strict homologue of the last upward stroke of the W. In these two genera the only modifications necessary to produce the W would be greater separation of the two external tubercles and the presence of a median marginal cusp connected with them by ridges.

In the genus *Scapanus*, or hairy-tailed moles, of this country the fourth superior premolar does not exhibit the W-shaped arrangement in the same perfection that the true molars do, the anterior V being rudimental or absent. The cusp at the antero-external angle, however, is present, and can be clearly shown to be of a cingular origin. It cannot therefore, as Cope supposes, represent the true antero-external tubercle, in this tooth at least. In the second unworn true molar of *Dasyurus* (Fig. 210) all the marginal cusps are present, but the median one is not connected with the two main external tubercles by ridges, leaving the W imperfect. In this tooth nothing is more apparent than the cingular origin of *all* the marginal cusps; and no one can doubt, it appears to me, that they are strictly homologous with the cusps in a like position in the molars of those animals in which the W is perfectly formed. A careful consideration of the teeth of the genera above mentioned in my judgment effectually disposes of the whole question, and demonstrates beyond doubt the correctness of the position here maintained, notwithstanding the conclusions of so high an authority as Prof. Cope to the contrary.

FIG. 210.

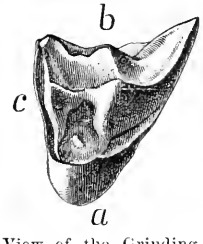

View of the Grinding Surface of an Unworn Molar Tooth of *Dasyurus* (enlarged): *a*, internal; *b*, external; *c*, anterior aspect of the crown.

Galeopithecus, or the so-called flying lemur, constituting another

[1] "Mutual Relations of the Bunotherian Mammalia," *Proceed. Acad. Nat. Sciences Philadelphia*, 1883. pp. 81–83.

[2] *Journal of Anatomy and Physiology*, ii. 138, figures, 1868.

family (*Galeopithecidæ*), is quite aberrant in the form of its incisors and some of the premolars. The incisors are two in number upon each side in the upper jaw, and those of the opposite sides are separated by a wide edentulous space; the first is minute and comparatively simple; the second is relatively large, two-rooted, and in every way similar to the tooth behind it, which is lodged in the maxillary bone. The form of the crown is that of a greatly flattened cone with anterior and posterior cutting edges. The anterior edge is interrupted by one minor denticle, the posterior by four, making it distinctly serrated. The next tooth behind this one is sometimes called a canine, but it is more probably a premolar; if this be the case the premolars are three in the upper jaw. The last premolar is like the molars, with three principal cusps and two small intermediate ones.

Fig. 211.

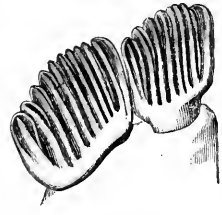

Two Incisors of the Lower Jaw of *Galeopithecus*, external view (enlarged).

In the lower jaw the incisors (Fig. 211) form a continuous arch around the alveolar margin, and are of a most remarkable pattern. They are four in all, of which the outer pair is somewhat the larger; they have broad incisive crowns, which are cleft to the base by deep vertical fissures like the teeth of a comb. In the middle pair there are seven such fissures, dividing off eight slender columns, whereas in the lateral pair there are ten.

The next tooth has a somewhat similar shape, but there are only four fissures, which do not penetrate so deeply; its crown cannot therefore be said to be more than serrate. The true molars are quintitubercular, with very elevated cusps.

In the European mole (*Talpa europea*), which may be taken as a fair representative of the family *Talpidæ*, the dental formula is I. $\frac{3}{3}$, C. $\frac{1}{1}$, Pm. $\frac{4}{4}$, M. $\frac{3}{3} = 44$. The incisors of the upper series are normal both in size and structure. The upper canine is large, recurved, and pointed, and exhibits the remarkable peculiarity of being implanted by two fangs. The premolars are simple compressed teeth, increasing progressively in size from the first to the fourth. The true molars are tritubercular, with the W-shaped structure externally.

Fig. 212.

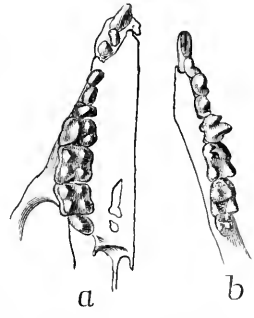

Vertical View of *a*, the upper jaw, and *b*, the lower jaw, of European hedge-hog (*Erinaceus*).

In the lower jaw the first four teeth are small and incisiform; the next is large, two-rooted, and caniniform, performing the function of the inferior canine. It is, however, really a premolar, since it closes behind the superior canine, and not in front of it. The tooth immediately in front of it is the true canine, notwithstanding its small size and incisive office. The three succeeding premolars are similar to the corresponding teeth above. The true molars are quadritubercular, or rather intermediate between the tuberculo-sectorial and the quadritubercular patterns.

In the hedge-hogs (*Erinacidæ*) (Fig. 212) and the elephant shrews

(*Macroscelidæ*) the molars are quadritubercular both above and below, and exhibit no traces whatever of the complex W-structure. If it is imperative to make any division of the Insectivora upon the characters of the teeth, I would suggest that the W-arrangement of the cusps of the superior true molars be considered as available for the purpose, although I would be seriously disposed to question this character alone as indicative of community of descent.

Another family of the *Insectivora* which in all probability stands in ancestral relationship to the *Carnivora* is the one which Cope calls the *Miacidæ*. It is represented by two genera, *Didymictis* and *Miacis*, both from the Eocene of North America. In this family we have, as Cope remarks,[1] "the point of nearest approximation of the Creodonta and Carnivora. This is indicated by the fact that the sectorials are sectorials both by position and form, such as are not elsewhere met with in the Creodonta. The genera might readily be taken for members of the Canidæ and Viverridæ (dogs and civets) but for the structure of the astragalus, which is thoroughly creodont."

Fig. 213.

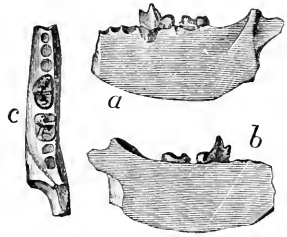

Fragment of the Lower Jaw of a species of *Miacis*: *a*, external, *b*, internal, and *c*, vertical views.

The genus *Didymictis* may be certainly regarded as the ancestor of the civets, while it is more than probable that *Miacis* (Fig. 213) was the immediate progenitor of the dogs. In the teeth of *Didymictis* (Fig. 214) the dental formula is not completely

Fig. 214.

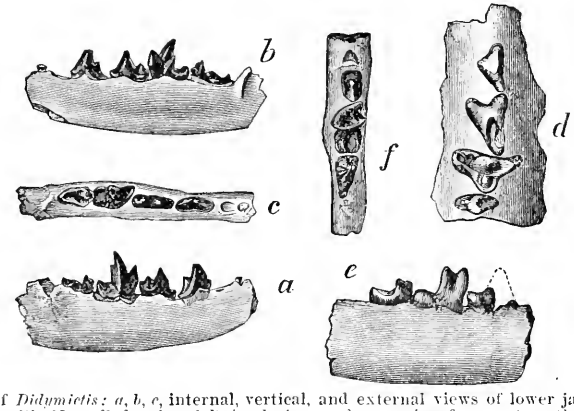

Two Species of *Didymictis*: *a*, *b*, *c*, internal, vertical, and external views of lower jaw of *D. dawkinsianus*, from Fig Horn Beds; *d*, *e*, *f*, *D. haydenianus*; *d*, upper-jaw fragment, vertical view; *e*, fragment of left ramus, inner side; *f*, vertical view of same,—all natural size (after Cope).

known, but most probably it is I. $\frac{3}{3}$, C. $\frac{1}{1}$, Pm. $\frac{4}{4}$, M. $\frac{2}{2} = 40$. The fourth premolar above is sectorial in form, the two true molars tubercular.

In the lower jaw the first true molar has lost much of its typical tuberculo-sectorial structure, which is best seen in the decreased size of the internal tubercle and the tendency of the anterior basal lobe and the

[1] "The Creodonta," *American Naturalist*, May, 1884, p. 483.

primitive cone to fuse into a cutting blade. A single tubercular molar follows the sectorial, which exhibits, as does the second lower true molar in the dog, a reduced or degraded condition of the tuberculo-sectorial pattern.

Miacis has three true molars in the lower jaw, of which the first is sectorial, in this respect resembling very closely the lower jaw of the dog; its complete dental formula is not known.

Teeth of the Prosimiæ.—With this group we enter that division of the *Bunotheria* which leads out to the monkeys and man. Its palæontological history reveals an antiquity quite equal to that of any other of the Monodelphia, continuing backward to the lowest Eocene. It is customary with most naturalists to regard the *Prosimiæ* as widely separated from the *Insectivora* on account of the higher order of brain-structure which the living representatives of the lemurs display, and they are accordingly placed near the Primates. Owing to the perishable condition and non-preservation of the soft parts in the extinct forms generally, we will never be able to know the exact structure of their brains, but must be content to judge of its generalized or specialized character by the mould of the cranial cavity, which in many respects is unsatisfactory.

It can be shown in the ungulate series that the lowest Eocene representatives possessed brains, judging from the cranial casts, almost as low in the scale of organization as that of the lowest known mammals, and it is likewise true that the brains of the Eocene prosimians were more generalized than those now living. I do not think there can be any radical differences shown to exist between the structure of the brain of such forms as the squirrel shrews (*Tupaiadæ*), the elephant shrews (*Macroscelidæ*), and the *Galeopithecidæ* of the insectivores, and the true lemurs (*Lemuridæ*), the fossil *Adapis*, and others of the *Prosimiæ*. The very fact of their remote antiquity and appearance in an age when the brain-development of all the Mammalia was small would of itself lead to the supposition that they too at first possessed brains of lowly organization. It should be here stated that very few skulls of the Eocene prosimians are known.

The dental formula of the spectrum lemur (*Tarsius spectrum*) is I. $\frac{2}{1}$, C. $\frac{1}{1}$, Pm. $\frac{3}{3}$, M. $\frac{3}{3}$. Of the two pairs of incisors in the upper jaw, the median is much the larger; they are closely approximated, long, pointed, and conical, and are surrounded at the base by a prominent cingulum, which is well defined upon the anterior face of the crown. The next pair are much smaller, and also have pointed crowns and basal cinguka. The upper canines are about equal in size to the median incisors, which they resemble both in the form of their crowns and the cingulum at the base.

The first premolar is the smallest of the three, and is placed just behind the canine; its crown is simple and pointed. The next two are larger and imperfectly two-lobed, the internal lobe being represented by a strongly-developed cingulum which continues around upon the outer face of the tooth. The true molars are subequal in size and tritubercular. The two external cusps are well developed, and placed at the external border of the crown. The internal lobe is relatively large,

and occupies a position opposite the interval of the two external. A moderate cingulum is developed on its internal aspect, and continues around to the outside of the tooth.

In the lower jaw the single pair of incisors come close together above the symphysis, and completely fill the space between canines; they have conic crowns and are smaller than the median pair above. The canines are larger than those above, and like them have pointed, slightly recurved apices. The premolars resemble those above, with the exception that the internal lobe is absent. The true molars are quadritubercular, with the two anterior slightly elevated. A trace of the anterior basal lobe is visible, and is best marked in the first, which brings the structure of the tooth into close correspondence with the tuberculo-sectorial of the Insectivores, and strongly suggests its derivation from it, as so many other examples of a similar kind do. The last molar displays a fifth lobe behind the two posterior ones, and is therefore quintitubercular. This species is the sole representative of the family *Tarsiidæ*.

In the typical lemurs of the family *Lemuridæ* the two pairs of upper incisors are separated from each other by a wide space in the centre, both being small and subequal. The superior canines are large; the premolars, with the exception of the first, have a small internal cusp. The molars are quadritubercular by reason of the internal cingulum rising up into a cusp at the postero-external angle of the crown. Various intermediate conditions between the perfect development of this cusp and its almost complete absence are to be seen. The fourth premolar, too, is in some genera like the true molars, in which case the last molar is small.

The incisors of the lower jaw are two in number upon each side, and are long, slender, laterally compressed teeth, having a procumbent implantation. The canines resemble them very much both in shape and position, being a little larger. The first premolar is large and caniniform, and would be readily taken for the canine at the first glance. The two following are smaller, and usually have simple crowns. The molars are truly quadritubercular, the anterior basal lobe being entirely absent. The last molar may or may not have a fifth posterior tubercle.

Teeth of the Tillodonta, Tæniodonta, and Daubentonioidea.—The aye-aye (*Chiromys*) of Madagascar is generally associated with the lemurs in the sub-order *Prosimiæ*, but naturalists—notably Profs. Cope and Gill—have seen fit to give it a rank equal to that of the lemuroids and place it in a distinct sub-order, *Daubentonioidea*, on account of the aberrant character of its teeth as compared with the lemurs. There are two other Eocene groups which go with it and constitute the first division of the order *Bunotheria*, according to Cope.

The dental formula of the adult aye-aye is, according to Owen, I. $\frac{1}{1}$, C. $\frac{0}{0}$, P. $\frac{1}{1}$, M. $\frac{3}{2} = 18$. The upper incisors are curved as in the *Rodentia*, and deeply implanted in the jaw. Their exposed portions are contiguous, their widely-excavated fangs diverging as they proceed backward. The incisors of the lower jaw are similar in shape to the upper ones, and are implanted as far back as the coronoid process. They are all covered with enamel, both in front and behind, and grow from

persistent pulps. In the entire investment of enamel they offer an important difference from the incisors of the rodents, which they otherwise closely resemble. The enamel being thicker upon the anterior than upon the posterior face of the tooth causes them to wear into chisel-shaped extremities, whereby the same effective gnawing instruments are produced as in the typical gnawing quadrupeds. The molar and premolar teeth are four in number upon each side in the upper, and three upon each side in the lower, jaw. They are implanted after a considerable interval behind the incisors, leaving a wide space or diastema, as in the *Rodentia*. The first and last molars of the upper series are the smallest, and have single roots; the second and third larger, and implanted by three fangs each. Their crowns have simple subelliptical grinding surfaces. The molars of the lower jaw are similar, the first being implanted by two roots, the second and third by one each.

The deciduous or milk dentition is I. $\frac{2}{1}$, C. $\frac{1}{0}$, Pm. $\frac{1}{1} = 12$. In the milk set a small incisor appears upon each side of the median pair, and is not replaced by a permanent one. Two teeth in this set occupy the spaces between the premolars and incisors above, and have been considered canines, they having no permanent successors. The single deciduous molar in each jaw is succeeded by the permanent premolar.

The *Tillodonta* is a group which was discovered and described by Prof. O. C. Marsh from the Upper Eocene deposits of Wyoming Territory. In the typical genus, *Tillotherium*, the dental formula, as given by this author is, I. $\frac{2}{2}$, C. $\frac{1}{1}$, Pm. $\frac{3}{2}$, M. $\frac{3}{3} = 34$. The median pair of incisors in each jaw are large and scalpriform, being faced with enamel, as in the rodents. They grew from persistent pulps, as is indicated by the large pulp-cavities at the base. The outer pair are small and did not grow persistently. The canines are much reduced, and placed well back in the alveolar border. The first of the three premolars of the upper jaw is small and simple, the other two being larger and of a more complex pattern.

The structure of the crowns of the superior molars is not very different from that of *Esthonyx*. Two external cusps are present, which are not well separated from each other; external to them is a broad cingular portion which is produced anteriorly into a process more marked than in *Esthonyx*. Internally two cusps are present, the posterior being lunate and consisting of a highly-developed cingulum. In the anterior, or that which corresponds with the antero-internal cusp of the quadritubercular molar, two well-developed ridges pass outward from its summit, one toward the anterior, and the other toward the posterior external angle of the crown, giving it a rounded U-shaped appearance. The pattern of the lower molars is identical with that of *Esthonyx*.[1]

In a general survey of the dentition of this genus I am compelled to dissent from the views expressed by Mr. Tomes, wherein he says that the molar teeth are of the ungulate type, and that the order combines characters of the Carnivora, Ungulata, and Rodentia. While it is true that the scalpriform incisors faced with enamel is a condition exhibited by the rodents, a condition also found in the *Toxodontia*, I fail to

[1] See Professor Marsh's monograph of this group, *American Journal of Science and Arts*, vol. xi., 1876, p. 249.

discover the faintest trace of either carnivorous or ungulate relationship. On the other hand, it seems to me that the evidence points strongly to the fact that this group is the direct descendant of *Esthonyx*, which preceded it in time. This is especially seen in the increased size of the mesial pair of incisors, the reduction of the canines, loss of one premolar in the upper jaw, and the remarkable similarity in the pattern of the molar teeth. That *Esthonyx* is an insectivore allied to the shrews there is scarcely any doubt. It is also probable that this group gave origin to the toxodonts, but the exact connections between them are not now apparent.

Another family, *Stylinodontidæ* of Prof. Marsh, makes approaches in this direction in the growth of the molars as well as the incisors from persistent pulps.

In the *Tæniodontia* the incisors are large and scalpriform, and were of persistent growth; the molar and premolar series are not separated from them by any diastema, in the lower jaw at least, and the canines, or those teeth regarded as such, in the inferior set also grew from persistent pulps, and have grinding crowns.[1]

Teeth of the Primates or Quadrumana.—The teeth of this order are closely affiliated with those of the typical lemuroids in the structure of the molars, and when compared with that of the other groups the amount of dental variation is comparatively insignificant. The order is naturally divisible into five families, of which the marmosets and platyrrhines of South America and the catarrhines and anthropoids of the Old World, as well as man, constitute the respective divisions. Of these families, the marmosets (*Hapalidæ*) are the most generalized and approach nearest to the lemurs in several important characters, prominent among which are the relatively smooth cerebral hemispheres, want of opposability of the thumb and its termination by a distinct claw instead of a nail,[2] and the possession of tritubercular instead of quadritubercular molars. Since they are found only in the New World, and as lemuroids were very abundant in this country in the Eocene Period, it seems probable that they are the derivatives of some member of this group. It is a fact worthy of notice that in the curious Eocene genus *Anaptomorphus* we have a near approach to the anthropoid condition of the teeth. In the shortness of the jaw and certain cranial peculiarities it also resembles the higher monkeys. For this reason Cope believes that the simians have descended directly from this lemur.

The dental formula of the genus *Midas* is I. $\frac{2}{2}$, C. $\frac{1}{1}$, Pm. $\frac{3}{3}$, M. $\frac{2}{2} = 32$, which obtains in the one other living genus. The upper incisors have longitudinally flattened incisive crowns, with a prominent internal ledge at the base. The median pair is the larger, as is gener-

[1] Prof. Cope has established this sub-order upon the peculiar condition of the canine teeth of the lower jaw, or at least those which he supposes to be such; the only knowledge we have of the teeth of the upper jaw is confined to the large scalpriform incisors. This sub-order must be regarded as provisional until we know more of the upper teeth, as well as the relationship of some genera apparently intermediate between it and the *Tillodonta*.

[2] Many of the lemurs are provided with an opposable thumb, which is terminated by a distinct nail. In this respect the marmosets are even below the lemurs.

ally the case in all the Primates, and are in contact in the median line. The smaller outer incisors follow closely in the dentigerous border of the premaxillaries, after which there is a wide space, almost equal to the width of the two incisors, for the passage of the lower canine. The canines of the upper jaw are comparatively strong for the monkeys, and have pointed, slightly recurved crowns which project far above the level of the other teeth; there is a deep groove upon their anterior faces.

The premolars or bicuspids are three in number, and completely fill the interval between the canines and molars. The first is the smallest, and has a prominent pointed external cusp on the grinding surface, to which the cingulum adds a low U-shaped internal portion; the second and third are similar, except that the internal lobe is no longer cingular, the cingulum furnishing a second internal ledge. The true molars are two in number upon each side, in this respect differing from all known Primates. The only approach to this condition to be met with elsewhere in the order is in the dentition of man, in whom it appears, as we will hereafter see, that the last molar, or the "wisdom tooth," is gradually becoming rudimentary or defective in the higher races. Various causes have been assigned in explanation of this fact, one of which is that the greater development of the brain necessitates the expenditure of smaller amount of growth-force upon the maxillary bones, whereby insufficient room is allowed and the tooth stunted. If this be the real cause, it is difficult to understand why in the lowest representatives of the order—and those, too, in which the cerebral hemispheres are proportionally the smallest—the complete suppression of the last molar should have occurred.

The two pairs of lower incisors are small and of the usual incisiform pattern, being considerably smaller than the canines. The lower incisors of the allied genus, *Hapale*, are proclivous, the canines being relatively small and approximated to them, as in the lemurs, although not to so great an extent. The canines are almost equal to the upper ones in size, and follow the outer incisors without interruption. The three lower premolars are subequal, the summit of the first being elevated above the level of the succeeding teeth. In the first the anterior basal lobe, the principal cone, and an imperfect heel can be indistinctly made out, while in the second and third the internal tubercle is present. In the true molars there are four indistinct cusps; the anterior basal lobe has almost completely disappeared, and all the cusps are of equal height. A careful study of unworn teeth will show them to be a still further modification of the tuberculo-sectorial type, whereby the perfect quadritubercular has been produced.

The next division, Platyrrhines, or flat-nosed monkeys, constitute the family *Cebidæ*, in which the dental formula is I. $\frac{2}{2}$, C. $\frac{1}{1}$, Pm. $\frac{3}{3}$, M. $\frac{3}{3}$ $=36$. They belong to the continent of South America, and have prehensile tails and generally rudimentary thumbs. The canines are usually strong and prominent, and the superior molars have a well-defined ridge connecting the antero-internal with the postero-external cusps, a remnant of the tritubercular condition. This ridge is found with varying constancy in the superior molars of all the Primates, and marks the

connection between the internal cusp and the postero-external tubercle, which generally exists in the tritubercular tooth. The postero-internal cusp, which lies inside and behind this ridge, is the last one which has been added to complete the quadritubercular tooth in the upper jaw. In the squirrel monkeys of this family the lower incisors have a tendency to be proclivous, as in *Hapale* of the marmosets, thus retaining the lemurine character of these parts. No fossil remains of this family are known except from very late geological time, and these do not differ materially from those now living.

The teeth of the Catarrhines (*Semnopithecidæ*) show a reduction in the number of premolars, whereby the formula I. $\frac{2}{2}$, C. $\frac{1}{1}$, Pm. $\frac{2}{2}$, M. $\frac{3}{3}$ = 32, the same as that of man, is reached. The incisors are of the same shape as in man, the central pair being considerably larger than the outer pair. The canines are always strong and powerful teeth, and their apices are always elevated above the other teeth. They reach their maximum of development in the baboons, more especially in the dog-headed baboon, *Cynocephalus*, in which they are deeply grooved anteriorly. In this group the first premolar below is implanted by a double fang, with its apex directed upward and backward. The anterior root is naked for some distance, and presents in front a blunt edge which bites against the posterior edge of the powerful superior canine, giving to this part of the jaw a peculiar and characteristic appearance. The second lower premolar of *Cynocephalus* is quadritubercular, with all the cusps well developed, but in the macaques the posterior tubercles are not well defined. Both the upper and lower true molars increase in size from the first to the last, the last lower one being distinctly five-lobed.

In the semnopithiques the incisors are more nearly equal in size; the canines are smaller and less deeply grooved than in the baboons; the first and second molars are subequal, while the last lower molar is proportionally narrower, but still retains the fifth lobe. The typical cercopithiques have the last lower molar quadritubercular and all the molars subequal. Fossil remains of this family are known from the Miocene and Pliocene deposits of Europe and Asia, but no characters of unusual importance occur in their dentition.

The next family of this order includes the anthropoid or tailless apes, which are also confined to the tropics of the Old World. They constitute the family *Simiidæ*, and are distinguished from the preceding family, *Cercopithecidæ*, principally by the absence of the tail; from the succeeding family, *Hominidæ*, by the circumstance that the hallux is opposable, whereas in the latter it is in a line with the other digits and is not opposable. Other characters of considerable anatomical importance are also found which distinguish them from man.

The teeth of this family are the same in number as those of man, but considerable differences are found in the relative size of the canines and the last molar when compared with that which obtains in the human subject. Although they are organized substantially upon the same plan, the teeth are larger and stronger than in man. The orang (*Simia satyrus*) is probably the most human-like in its dentition, although in other respects the gorilla and chimpanzee most resemble man. The molar teeth in this animal are remarkable for the straight line in which

they are implanted in both jaws, and contrast with the graceful curve they pursue in the normal human mouth.

The median pair of incisors are larger both above and below; in the upper jaw they are more than twice the size of the lateral pair, while in the lower jaw they are more nearly equal. Between the lateral pair and the canine above there is a considerable space, into which the lower canine bites. The canines are relatively large, and their apices rise far above the level of the surrounding teeth. They are imperfectly trihedral in form, with a trenchant edge behind. These teeth are larger in the male than in the female.

The premolars or bicuspids differ from those of man in the upper jaw in being implanted by three roots like the molars; their crowns are very similar to those of man, presenting essentially the same elements. The pattern of the crowns of the molars is like that of the human subject both above and below, but the last molar is as large as the others; it is implanted by three roots, and is always perfectly formed. In the lower jaw the two posterior molars slightly exceed the first in size, and the last is distinctly five-lobed. The first lower premolar is two-rooted, and has a faint resemblance to the corresponding tooth in the baboons. The second is also implanted by two roots, and its crown agrees with that of man.

In the other genera minor differences only are to be met with in the form, pattern, and arrangement of these organs.

The Human Dentition.

In this connection we come next to consider the teeth of man; and before so doing I am constrained to make some general remarks in regard to the position he occupies in the zoological scale. While it is undeniable that by virtue of his superior brain-capacity and intellectual development man is to be accorded a place at the head of the animal kingdom, it is nevertheless true that much of his anatomical structure has not been specialized beyond that of many of the lower forms. The fact that different members of the mammalian sub-class have been modified in different directions, some to fit one environment and some another, has led to the specialization of different sets of organs, and that, moreover, in different ways as the surrounding conditions and particular exigencies of the case have required.

It is these differences which enable the naturalist to construct zoological definitions of the major or minor groups, such as orders, sub-orders, families, genera, etc. The impracticability of determining which animal is highest or lowest in the scale of organization is thus rendered apparent from the fact that a comparison of different sets of organs is involved. Thus, in their dental, digestive, and limb structure the ungulates surpass all other Mammalia in complexity and specialization, and in these respects may be said to be highest, while in the matter of brain-development they are much inferior to others. The monkey line or Primates, on the other hand, of which man is at the head, retain a comparatively generalized structure of the limbs, teeth, and digestive

organs, but have outstripped all others in the development of the cerebral nervous system.

It is only upon an evolutionary basis that we are enabled to comprehend the significance and import of the manifold modifications with which the morphologist is called upon to deal, and it is not at all unnatural that in the consideration of the human or any other dentition the student should first of all bend his energies to the discovery of the relative position which his subject holds in the system. All the evidence which anatomical and palæontological science can now bring to bear on the question tends to show that man is the legitimate product and highest expression of the evolutionary forces in that line of development which began with the Eocene lemuroids, however objectionable this conclusion may be to many. No adequate conception of his place in nature or the structure of any set of his organs can be had without a comparison with the other members of the stem to which he naturally belongs. This reason alone has induced me, somewhat contrary to custom, to give an account of the human dentition in this situation, rather than at the latter part of the present article.

Looked at from the point of view of the comparative odontologist, these organs present little of general morphological interest beyond that displayed by other Primates; but from the practical standpoint of the operative dentist they are of the greatest importance. In the course of this account many questions in connection with this latter phase of the subject will doubtless suggest themselves to the reader which are not within the scope of the present part of the work to discuss, its object being merely to outline the anatomy.

The dental formula of the human subject is, normally, I. $\frac{2}{2}$, C. $\frac{1}{1}$, Pm. $\frac{2}{2}$, M. $\frac{3}{3} = \frac{16}{16} = 32$, the same as that found in the Old World monkeys. Much variation from this number exists, however, by reason of the failure of development of the superior lateral incisors and of the third molars, the wisdom teeth or *dentes sapientiæ;* these molars may be present in the upper or lower jaw only, or they may fail to develop on one side in one or both jaws, or, again, they may be completely aborted. These variations are most frequently met with in the higher races of mankind, and are said to be of rare occurrence in the inferior races. The teeth are implanted in the alveolar process in such a manner in both jaws as to describe a regular parabolic curve, being uninterrupted at any point by the intervention of diastemata or spaces. The summits of the crowns have, when normally developed, approximately the same level, the canines not excepted, thereby affording a marked contrast with the apes and monkeys, in which the crowns of the canines are always more elevated than the other teeth.

FIG. 215.

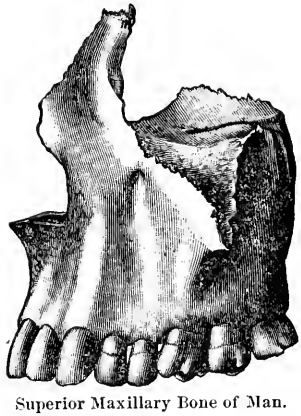

Superior Maxillary Bone of Man.

The incisors are four in number in each jaw, those of the upper being

implanted in the premaxillary bones, which at an early period coalesce with the maxillaries. Of these, the central pair is the larger and has a slightly more anterior position than the lateral ones, on account of the curve of the alveolar border. Their incisive nature is manifested by the possession of a crown, which is bevelled on its palatine or lingual surface[1] to a cutting edge, being broader at the extremity than at the

FIG. 216.

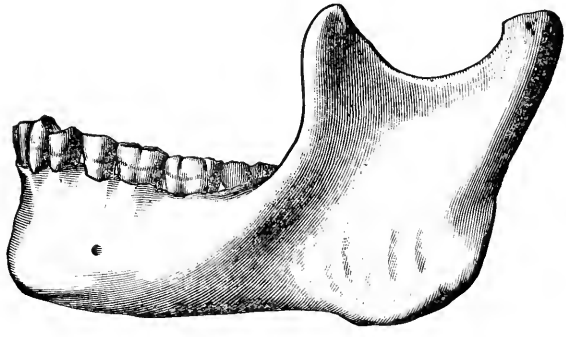

Inferior Maxillary Bone of Man.

base. The adjacent teeth are in contact at their coronal extremities, but on account of the narrower base a slight interval appears between them at the margin of the gum. The root joins the crown without any marked constriction, so that a neck can scarcely be said to exist; from this point it tapers gradually to an obtuse termination, being imperfectly trihedral in form and slightly recurved.

In newly-erupted teeth the cutting edge of the crown is divided into three inconspicuous cusps, which soon disappear through wear, leaving it smooth. The basal termination of the crown is indicated by the limit of the enamel covering, which is of greater vertical depth on the labial and palatine or lingual than on the lateral faces, so that if a line be drawn around the tooth at the most extreme basal portion of the enamel, it will touch only the labial and palatine prolongations, and not mark its exact limit on the mesial and distal surfaces. These

[1] The nomenclature of the various surfaces of a tooth as it stands in position in the jaw, it seems to me, is simplified by employing terms with the following signification: If the tooth-line were straightened out upon each side, the surface which looks away from the condyle would be *anterior*, and that which is directed toward it would be *posterior;* the surface directed toward the median line of the mouth would be *internal*, and that directed away from it *external*. In this system some confusion may arise with respect to the incisors and canines, in which the anterior surface is internal and conversely, owing to the curvature of the tooth-line; but while it has appeared to me best to speak of the surfaces as if the tooth-line were straight, I have in this paper adopted terms now most familiar to the dental profession, which are represented by the following: The surface looking toward the anterior part of the mouth and median line is called the *mesial surface;* its opposite, looking toward the condyle, the *distal surface*. In the superior row the surface which has been designated the internal I shall term the *palatal*, and in the inferior row the *lingual*, while the external surface is the buccal for the molars and bicuspids, and labial for the incisors and cuspids or canines. The triturating surfaces of the molars and bicuspids are termed *the masticating surfaces*, while the incisive surfaces of the incisors and cuspids or canines are denominated the *cutting edges*.

projections of the enamel present convex outlines basally, and are separated from each other by two wide V-shaped notches occupying the mesial and distal faces.

The labial aspect of the crown is convex from side to side, as well as from above downward, and is of greater vertical than transverse extent. Upon either side the crown is triangular in form, with the apex of the triangle terminating at each free angle of the cutting extremity, and the base directed toward the root; the basal part of the triangle is interrupted by the V-shaped notch already alluded to. That lateral surface which is directed toward the median line (mesial) is comparatively flat and most produced at the extremity, while the one which looks away from the median line (distal) is more rounded, having its terminal angle less produced. The interior or palatine surface is also triangular, but the base is formed by the free cutting edge and the apex turned toward the root. Usually, this surface is nearly flat, but in some examples it presents a broad central concavity whose depth may be considerably augmented by the presence of two marginal ridges meeting at the radicular extremity or apex of the triangle. These ridges, which are homologous with the cingulum of other teeth, sometimes develop a small cusp at their point of junction, in front of which there is usually a deep pit in the enamel—"a favorite site for caries." As a general rule, the cingulum is but faintly marked, and the posterior or palatine face is slightly concave.

FIG. 217.

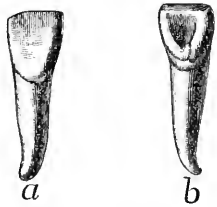

A Left Upper Central Incisor of Man: *a*, external or labial aspect; *b*, internal or lingual aspect.

The lateral incisors of the upper jaw are smaller than the median pair, but have approximately the same form. The labial face is more convex from side to side, and the outer or distal angle of the cutting edge is much more rounded off than in the median. The lingual surface may be slightly concave from above downward, and convex in the opposite direction, without any trace of the cingulum, or, as is most generally the case, it is concave, with the cingulum present, and elevated into a small cusp at the point of junction of the two lateral ridges. The basilar contour of the enamel covering is the same as in the preceding tooth. The root is more compressed laterally, of relatively greater length, and tapers more gradually to its termination, giving to the tooth a more slender and less robust appearance.

FIG. 218.

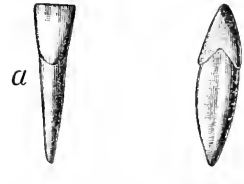

A Lower Incisor of Man: *a*, anterior, and *b*, lateral view.

The pulp-cavities of these two teeth have substantially the same shape, and the description of one will answer for that of both. Its form is that of an elongated tube, gradually increasing in diameter from the apical foramen in the apex of the root to a point which nearly coincides with the summit of the V-shaped notch in the enamel on the lateral surface of the crown, where it becomes contracted in an antero-posterior direction, but enlarged in its transverse diameter. It is prolonged upon either side into a slight cornua, which reaches but a short distance beyond the level of the general cavity; the one which cor-

responds to the internal or mesial angle of the cutting edge of the crown is a little the longer of the two.

The two pairs of lower incisors reverse the condition of the superior set, in that the central ones are the smallest. Their crowns have substantially the same pattern as those in the upper jaw, with the exception that an internal or lingual cingulum is never developed. They are readily distinguished from those above by their smaller size and greater lateral flattening of the roots. The pulp-cavity and basal enamel contour are like the corresponding teeth above.

The cuspids, canines, or "eye teeth," are the next in order behind the incisors; in both jaws they completely fill the gap between these latter teeth and the bicuspids, being in contact with them at the mesial and distal extremity of the crown. They are in every way stronger and more robust than the incisors, and are implanted by roots whose length, proportionate to that of the crown, is much greater. In the upper jaw these are indicated on the external surface of the maxillary bone by a vertical ridge or swelling which in many skulls extends quite as high as the lower border of the anterior nares.

FIG. 219.

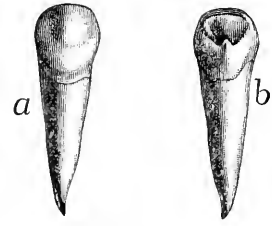

A Left Superior Human Canine: *a*, external, and *b*, internal view.

The crown is terminated by an obtuse point, which has a position in a line with the longitudinal axis of the root. Upon either side of this cusp the terminal extremity slopes away, but still retains a blunt cutting edge. When the median cusp is reduced by wear the crown does not look very much unlike that of an incisor; its labial or external face is broader above than below,[1] and convex in both a transverse and a longitudinal direction, as in the incisors; the palatal or internal surface is also bevelled, and the lateral surfaces (mesial and distal), or those which lie adjacent to the contiguous teeth, are likewise somewhat triangular in form, but more rounded. In the superior canines a slight ridge descends upon the external or labial face from the summit of the terminal cusp to the neck, but is absent in the corresponding teeth below.

The internal or palatine aspect is slightly convex from side to side, but concave from above downward. The palatine convexity is occasioned by a well-marked vertical ridge which extends from the summit of the terminal cusp to the cingulum below; this latter structure is usually well defined, being stronger in the upper than in the lower teeth. There is, as a general rule, a prominent basal cusp at the junction of the two lateral ridges which connects with the vertical ridge, leaving a deep pit upon either side—a spot where caries very frequently occurs.

As already stated, the extremity of the crown slopes away upon either

[1] When the terms *above*, *below*, *superior*, and *inferior* are used in connection with a single tooth, they refer to the free as opposed to the implanted extremities: in the upper jaw the part of the crown which is really above is that which joins the root, but in the lower jaw it is the reverse of this. It is convenient to use these terms for all teeth, as they correctly apply to the lower teeth, so that when we speak of the superior extremity of the crown, the free or terminal part is meant, whether it belong to the upper or lower jaw.

side of the median cusp; that side which lies next to the premolars or bicuspids is longer than that which is directed toward the incisors, so that the distal or posterior moiety is greater than the mesial or anterior. This inequality of the two sides exists in both pairs of the canines, being less marked in the lower than in the upper; it furnishes a very useful rule by which a canine can be referred without difficulty to its proper side of the mouth.

The inferior cuspids or canines differ principally from those above in the shorter root, blunter median cusp, and less-marked posterior or lingual cingulum and basal cusp. The roots of both are thicker labially than lingually, and are generally traversed by a vertical groove upon either side.

The bicuspids or premolars are four in number in each jaw, and afford a further complication of the pattern of the crown by reason of the elevation of the basal cingulum into a strong internal cusp. In proportion as this part of the crown is well marked and complicated, there is a corresponding disposition to increase in the number of roots or fangs. These teeth, as their name implies, are provided with two cusps to the crown; those of the superior set are of subequal dimensions and considerably exceed the lower ones in size. The crown of the bicuspid, when viewed vertically, presents an imperfectly quadrate outline, which is most distinct in the second, and are broader than long. Two strong cusps, of which one is external and the other internal, occupy the grinding face, and are separated by a deep notch or valley, deepest in the centre. The anterior and posterior margins of this valley are bordered by slight ridges which connect the anterior and posterior extremities of the cusps; the anterior of these is a little more elevated than the posterior, and forms a useful guide in determining the mesial and distal surfaces of the tooth, and consequently the side of the jaw to which it belongs. In some instances the enamel forming the floor of the valley and adjacent sides of the cusps and ridges is quite smooth, but most frequently it is considerably wrinkled and thrown into a number of minor cusps and ridges, with intermediate indentations which offer receptacles for the lodgment of food.

FIG. 220.

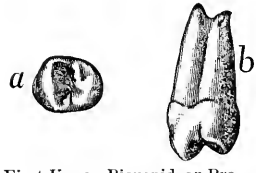

First Upper Bicuspid or Premolar of Man: *a*, vertical view of the crown; *b*, lateral view.

Of the two cusps, the external is slightly the larger and more elevated; it likewise has a greater antero-posterior extent. Its form is very much like the entire crown of the cuspid, terminating superiorly in a median cusp, from which the cutting edge gradually slopes away upon either side. The internal vertical rib is also present, but the external is absent. The internal or palatine cusp is thicker transversely than the buccal, and is more rounded. On account of the connecting ridges it has somewhat of a crescentic pattern.

Commonly, there is, to all appearance, but a single root, which is traversed upon the mesial and distal faces by vertical grooves which may unite near the apex, causing it to become divided. These vertical grooves are the external indication of two pulp-cavities in the implanted

extremity, which unite about midway of the root, and are thence continued upward into the crown as a common cavity. The cavity thus formed is of greater transverse than antero-posterior[1] extent; in the vicinity of the neck it is little more than a narrow transverse fissure, which widens somewhat above, and is prolonged into two cornua corresponding to the two cusps. The external of these is the larger and most elevated.

While this condition of the roots and pulp-cavity is the one usually to be met with, nevertheless two roots are frequently found in the first bicuspid, and three roots are occasionally developed, two of which support the outer cusp; the pulp-cavity has then, of course, three divisions.

FIG. 221.

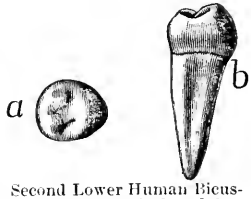

Second Lower Human Bicuspid: *a*, *b*, vertical and lateral views.

The principal differences between the upper and lower bicuspids or premolars are seen in the size of the internal cusp as compared with the external, the more cylindrical form of the root, and the almost complete absence of the vertical grooves, on account of which the pulp-cavity is, as a general rule, single. The crown consists of a large, somewhat conical external cusp, very convex without, to which is added a low lunate internal cingular ridge. The internal vertical ridge of the external cusp joins this cingulum near its central portion, leaving a deep pit upon either side where the destructive agencies of decay on the crowns of these teeth exhibit themselves most frequently. The degree to which this vertical rib is developed is subjected to great variation; it may be almost entirely absent in some individuals or strongly developed in others. The crown of the second or posterior bicuspid or premolar is more quadrate in outline than the anterior or first; the internal cusp is better developed, and frequently shows a tendency to form two.

The normal number of true molars is twelve, three on either side in each jaw, but, as already remarked, the last in both series may be absent. In a series of adult skulls of various civilized races which I have examined, twelve out of forty had one or both of these teeth wanting from the upper series, and in the lower jaw the proportion was ten to thirty. It is highly probable that in many of these cases these teeth had been present, but had disappeared early in life. Many examples could be cited in which the last or third molars wholly fail to be erupted, and it is established upon good authority that in many families one, two, or all of these teeth are habitually absent from generation to generation.

FIG. 222.

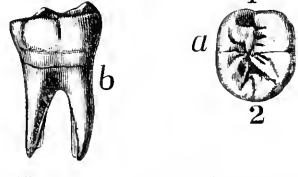

First Lower Human Molar: *a*, vertical view of the crown: 1, anterior; 2, posterior aspect; *b*, side view.

In the lower jaw the three molars in the more typical lower races are equal in size and substantially alike in pattern; their crowns are quadrangular in section, with the angles consider-

[1] By *antero-posterior* in this connection is meant the diameter which corresponds with the long axis of the jaw.

ably rounded off. They support four principal cusps, as in the quadritubercular molar generally, together with a fifth one behind, which is strictly homologous with the heel of these teeth in the more generalized members of the Primate section. These are separated by four distinct fissures arranged in the form of a cross; where the two limbs cross each other they widen out into a median valley deepest in the centre. The longitudinal of these, or the one which separates the external from the internal principal cusps, terminates in a posterior bifurcation which constricts off the fifth cusp or heel. The enamel lining this valley is, in perfectly unworn teeth, much corrugated, so that it is sometimes difficult to distinguish the principal cusps.

They are, with the exception of the last or third molar, implanted by two antero-posteriorly flattened roots, which join the crown at the moderately well-defined neck. These may be connate, having the two roots indicated only by a vertical groove upon either side. Each root is hollowed out in the centre to receive the radicular portion of the pulp, the cavity corresponding with the external form of the root. These unite into a common cavity above, which at about the time the tooth is erupted is relatively very large, but which becomes smaller with age, and is finally in old age obliterated through progressive calcification. The body of the cavity is terminated superiorly by cornua corresponding to the five cusps of the crown; of these the two anterior are most prolonged, and reach slightly above the inferior limit of the outer enamel covering.

In the higher races the last or third molar is usually smaller than the first and second, and does not have the cusp so well defined; but in many of the negro skulls I have examined it is nearly as large, and quite as well formed, as the two anterior to it. This tooth is more constant, both as regards presence and form, than the corresponding tooth above. It is, as a rule, two-rooted, but these roots may be confluent, in which case two vertical grooves mark a tendency in this direction.

The superior molars, like those in the lower jaw, are three in number, and have quadritubercular crowns normally, but many examples can be found in which the postero-internal cusp, the last one added in the quadritubercular molar, is little more than a cingulum,[1] and is scarcely entitled to the appellation of a cusp. In such cases it frequently has a position internal to the antero-internal cusp, and all stages between that and its normal position are to be met with.

The grinding face of the crown is of a squarish form, bearing a

[1] It is probable that this condition, of which I have seen a number of examples in the higher races, is a degenerate one, and is an effort to return to the tritubercular stage. Dr. Harrison Allen, in a communication to the Academy of Natural Sciences of Philadelphia, has recently called attention to the fact that in senile changes those structures which have been added last in the course of evolutionary growth are the first to disappear. Although this condition cannot be said to be in any way dependent upon individual senility, it is in all probability the result of senility of the race, wherein retrogressive modifications of any set of organs are first apparent in those parts which were the last to appear. It should be stated here that to Dr. Allen is due the credit of having prepared the way for all the more important generalizations that have been made in regard to the evolution of the quadritubercular tooth from the more primitive types. He demonstrated that the postero-internal cusp of the human molar is an outgrowth from the cingulum.

cusp at each angle. Of the two external, the anterior is slightly the larger, and is usually connected with the antero-internal by a strong ridge which skirts the anterior margins of the crown. The posterior is separated from it by a fissure which terminates internally in the median valley; it is also connected with the antero-internal cusp by a ridge, the oblique ridge. From its posterior margin a well-developed cingulum passes inward on the posterior border of the crown to join the postero-internal cusp, of which, as already remarked, this latter is a part.

Fig. 223.

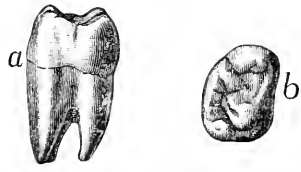

First Superior Human Molar: *a*, lateral, and *b*, vertical view.

The antero-internal cusp is the largest of the four, and by reason of its union with the cross-ridges above mentioned has a somewhat crescentic appearance. It is placed at the apex of a V which opens externally and encloses the median valley. The postero-internal cusp in the specimen figured stands a little posterior and internal to the last mentioned, being separated from it by a deep groove; it is little more than an enlargement of the strong posterior cingulum.

The roots are three in number, of which two are external or buccal, and support the two outer cusps, and one internal or lingual, supporting the two internal cusps. The two outer are not unfrequently connate, in which case the line of separation of the radicular portions of the pulp-cavities is indicated by a vertical groove. The palatine is the largest and longest root of the three.

While the structure here described usually obtains in the first and second molars, the last is more simple and variable. In the more civilized races it is exceptional for these teeth to be regular either in form or position, so great is their variability. The crown resembles in a general way those of the first and second molars, except that the oblique ridge is generally absent and the two internal cusps are blended together. The roots are connate and somewhat curved at their implanted extremity, and the pulp-cavity is single.

Occlusion of the Teeth.—The diagram (Fig. 224) on p. 446 represents the occlusion of the teeth. It has been previously stated that in a well-formed denture no one tooth rises higher than its fellows; that is, if the crowns of the teeth in position be turned, cusps and cutting edges, upon a plain or even surface, each tooth rests upon this surface. From this arrangement there is nothing to interfere with a perfect occlusion. Still, the fact must be recognized that while the above-described arrangement is true of a perfectly-developed jaw and teeth, yet so rarely is it found that it may be considered an *ideal denture.*

It has also been stated that the superior arch or row of teeth describes the segment of a larger circle than does the inferior row; this being the case, when the two are brought in contact, as in normally closing the mouth, the anterior superior teeth are thrown slightly over and anterior to the corresponding inferior teeth. Also with the bicuspids and molars, the external cusps of the superior ones are in closing slightly external to the corresponding cusps of the inferior. Another serviceable peculiarity is the noticeable absence of an exact opposition of tooth to tooth in clos-

ing, as will be seen by the diagram: the greater width of the superior central covers the width of the inferior central and a small portion of the inferior lateral; this brings the superior lateral over the remainder of the inferior one and the mesial fourth of the inferior cuspid, while the cusp of the superior cuspid fits into the concave space between the cusp of the inferior cuspid and the first bicuspid. In like manner, this

FIG. 224.

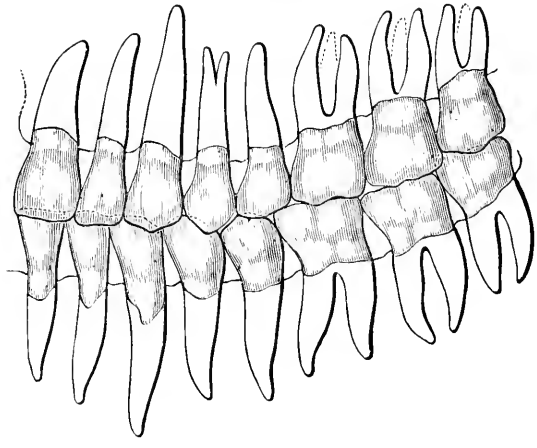

irregularity of opposition is maintained in all the teeth, so as to give each tooth a bearing on two teeth, except the superior third molar, which has but the corresponding tooth in the lower jaw for an antagonizer. This irregularity of opposition contributes to the efficiency of the teeth in mastication, and is a valuable feature when a tooth is lost from the arch in either jaw, for by this arrangement the tooth in partial antagonism with the one lost still maintains a portion of its usefulness by its occlusion with yet another tooth.

The Deciduous or Temporary Teeth (Fig. 225), twenty in number, are

FIG. 225.

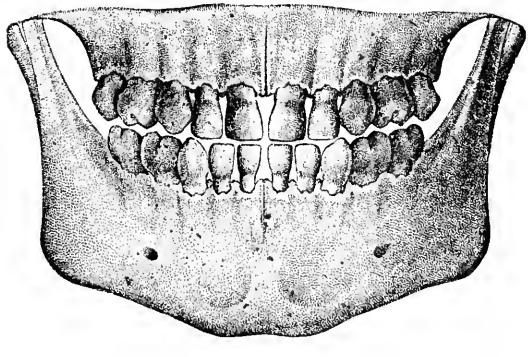

smaller than the permanent set, though they resemble them in their general conformation of crown and root, the bicuspids of the permanent set

not being represented in the deciduous dentine. The formula, when they are normally developed, is I. $\frac{2}{2}$, C. $\frac{1}{1}$, M. $\frac{2}{2} = \frac{1\,0}{1\,0} = 20$, the premolars or bicuspids being confined to the permanent set. A marked point of dissimilarity, as compared with their successors, is in the termination of the enamel on the neck of the tooth. In the permanent teeth the gradual completion of the enamel on the border of the cement marks but indistinctly the point of union of these two structures, while at the base of the deciduous crown the terminating enamel on the buccal and labial surfaces is recognized by a ridge or well-defined border which unmistakably marks its limitation and develops a well-constricted neck. This difference is often of importance in deciding as to whether a tooth in question belongs to the deciduous or permanent series. These teeth, from the fact that their crowns are largely calcified before birth, are much less liable to vices in conformation than their successors, but from deficient nutrition, want of use, and neglect not unfrequently become an easy prey to the ravages of dental caries. In common with a large class of the order to which man is closely allied, the difference in number between the deciduous and permanent set is twelve, the additional teeth being without predecessors.

The accompanying figure (226) represents the denture of a child about

Fig. 226.

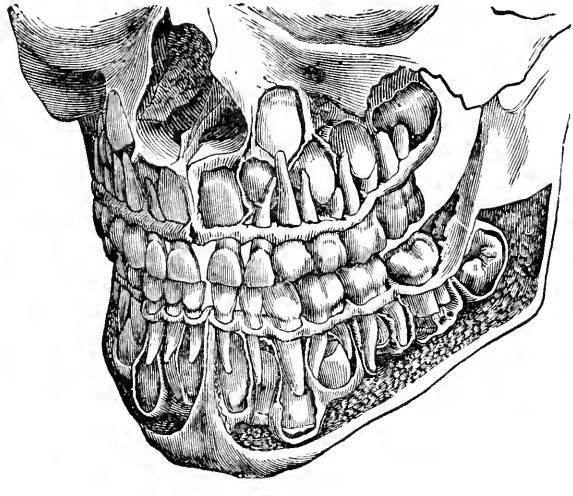

seven years of age. Twenty deciduous teeth, ten in each jaw, and the four first permanent molars, are erupted. The second permanent molar is seen in the crypt in the posterior part of each maxilla. Commencing with the median line, to the right of it and just above the erupted deciduous central incisor, we observe the permanent central with its crown fully calcified and the root partially so. In this case the crown of the permanent tooth stands in front of or on the labial side of the partially absorbed root of the deciduous central. This is not its constant relative position; not unfrequently the deciduous root is in front of the crown, as is seen in the adjoining lateral incisor. In this case the crown of

the permanent lateral has the position which it invariably maintains. The crown of the permanent cuspid is here normally located quite above the root of its predecessor, and at the side of and in close proximity to the wing of the external nares. Next in position, a little below and slightly posterior to this cuspid crown, is that of the first bicuspid, this and its fellow, the second bicuspid, are located between the roots of their respective predecessors, the first and second deciduous molars. The same is true of those on the other side of the jaw, and, with slight variation, the same relative positions of the deciduous roots and permanent crowns are observed in the inferior maxilla. It is above stated that the figure represents the teeth of a child about seven years of age. The first permanent molars, it should be noted, are at this age erupted and in position, though their roots are not quite completed. The permanent central incisors will be the next to take their position at about the age of eight, followed by the laterals at nine, the first bicuspids at ten, the second bicuspids at eleven, the cuspids from twelve to thirteen, and the second molars from twelve to fourteen, which completes the eruption of the permanent teeth, with the exception of the third molars or wisdom teeth, these may take their position at eighteen or some years later. The anatomy of human dentition is further illustrated in plates placed at the end of this paper (see p. 505).

Teeth of the Carnivora.

Our knowledge of the philogenetic history of the unguiculate series has so increased within the last few years that it is now a matter of great difficulty to say just what forms should be included in the order *Carnivora*, as at present defined. If we take into account the living forms only, no one will hesitate in fixing its limit and giving to it a moderately good definition; but when the fossil representatives are considered, the interval between it and some of the contiguous orders, especially the *Insectivora*, is brought down to extremely small limits. We have already seen that the *Miacidæ* approach the dogs and civets in the *Carnivora* on the one hand, and the *Leptictidæ* of the *Insectivora* on the other. If a dog, bear, cat, and seal, all of which are admitted to belong to the *Carnivora*, be selected, and a careful comparison of their anatomical structure instituted, the differences between them will be found to be much greater than between such forms as *Stypolophus*, *Centetes*, *Miacis*, and the dogs and civets.

Every increment to our knowledge of the more exact relationship of the various groups seems to bring us nearer to the conclusion that our present classification is largely a matter of convenience, and often fails utterly to express the deeper and more important facts of origin and ancestry. Such reflections bring us abreast of the question, What is an order, a family, or a genus, etc.? And just here we approach a problem as to the solution of which no two naturalists agree.

It appears to me that the only way out of these difficulties is to consider the test of ancestry the only true basis of affinity. If it can be shown, for example, that any given assemblage of organic forms have descended from a common ancestor, however much they may differ

among themselves, such a line or branch constitutes a natural division. Viewed from this standpoint, there can be little doubt that the order *Carnivora* represents the terminal extremities of several distinct branches, which arose not from one, but from two or perhaps three points in the *Insectivora*. The same reasoning holds good for many other orders.

The order *Carnivora*, as at present understood, is divisible into two sub-orders—*Fissipedia*, or the land carnivores, and the *Pinnipedia*, or aquatic flesh-eaters. The latter division includes the seals, sea-lions, and walruses, and is distinguished by the flipper-like modification of the feet for progression in the water, as well as by several important cranial characters. They are all known to be diphyodont, but the milk teeth disappear early; in some cases this occurs before birth, and in others a few weeks after. The teeth always possess comparatively simple crowns, which are either simple cones, as in the majority of the *Cetacea*, or laterally compressed, like the premolars of the dog, with smaller cusps along the edge, giving a well-defined serrated structure.

There are three families of this group, viz. the *Phocidæ* or seals, the *Otaridæ* or sea-lions and sea-bears, and the *Trichecidæ*, or walruses. In the common seal (*Phoca vitulina*), which is a good example of the first, the dental formula is I. $\frac{3}{2}$, C. $\frac{1}{1}$, Pm. $\frac{4}{4}$, M. $\frac{1}{1} = 34$. The central pair of incisors above (Fig. 227) are the smallest, with sharp-pointed,

Fig. 227.

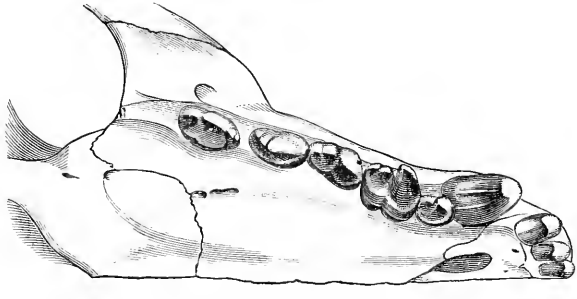

Vertical View of the Upper Jaw of a Harbor Seal (*Phoca vitulina*).

slightly hooked crowns; the next are similar in shape, but a little larger, while the outer pair are abruptly increased in size. These are separated from the canine by a diastema to admit the lower canine. The canine is a powerful tooth, with a conical recurved crown, and is deeply implanted in the maxillary bone. In the specimen figured, which is a young individual, it is remarkable for the very large size of the pulp-cavity, which extends nearly to the apex of the crown. The first premolar follows just inside and behind the canine, giving a crowded appearance to the first two premolars, the longitudinal axes of which are directed very obliquely to that of the succeeding teeth: it has no deciduous predecessor, as the corresponding tooth in the dog, and is one of the many examples in which it is difficult to say whether it should be relegated to the milk dentition as a persistent milk molar or whether it should be referred to the permanent set. It is implanted by a single root, also remarkable for the size of the pulp-cavity, and has a crown

with a principal hook-shaped cusp, a small posterior basal cusp, and a strong internal cingulum.

The next three premolars are similar, except that they are larger, implanted by two roots, and have two posterior accessory cusps, the hindermost of which is very small. The single molar differs from the rest of the teeth in advance of it in having an anterior basal cusp, being relatively thicker at the base of the crown, and with a moderately well-defined internal cingulum, which displays a tendency to develop internal cusps.

The incisors and canines of the lower jaw are like those above, but the two incisors of each side are separated at the median line. The first premolar is single-rooted and somewhat larger than its fellow above. The crown displays a median cone with three posterior accessory cusps, and one very minute anterior one. The following teeth, including the molar, are all similarly constructed, but have the anterior basal cusp better defined.

FIG. 228.

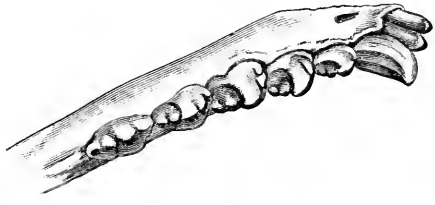

Vertical View of the Lower Jaw of a Harbor Seal.

In the hooded seals (*Cystophora*) the incisors are two upon each side above, and one upon each side below. The canines are comparatively large and powerful, while the molars and premolars are small and reduced to simple conical bodies, similar to the teeth of the cetaceans. In another genus (*Stenorhynchus*) the teeth are remarkable for the great length of the cusps, and in one species, *Leptonyx*, for the curvature of the accessory cusps toward the principal one, thereby resembling the trident of a fishing-spear.

A good example of the dentition of the *Otaridæ* is furnished by the fur seal (*Callorhynus ursinus*), which can usually be found in museums. The dental formula is I. $\frac{3}{2}$, C. $\frac{1}{1}$, Pm. $\frac{4}{4}$, M. $\frac{2}{1} = 36$. The two median pairs of incisors above are subequal and laterally compressed. They each present a deep transverse notch in the summit of the crown, into which the incisiform extremities of the lower incisors bite; the outer pair are larger and sharp-pointed. The canines are relatively longer and more slender than in the seals, and have a well-defined posterior trenchant edge. The succeeding teeth are all alike in form and size, being implanted by single fangs. Their crowns are of a triangular shape when viewed from the side, and present a single cusp. It frequently happens that the bases of these teeth just where they emerge from the gums are very much eroded, the cause of which is not at present well understood.

Both the *Phocidæ* and *Otaridæ* are remarkable for their comparatively weak and slender jaws, the backward direction of the coronoid process, and the great distance intervening between its base and the last tooth. In the seals the palate is very broad posteriorly, and the last tooth does not extend behind the anterior root of the zygoma, whereas in the sea-lions the palate is long and narrow, and the last tooth is placed considerably behind the anterior termination of the zygomatic arch.

The *Trichechidæ* or walruses exhibit the most anomalous condition of the dental organs of any pinniped carnivore so far known, in that two enormous tusks are developed in the upper jaw, which occupy the position and fulfil the functions of canines. Owing to the transitory character of some of the other teeth, it is difficult to assign a definite dental formula to this animal. Prof. Flower makes it out to be I. $\frac{1}{0}$, C. $\frac{1}{1}$, Pm. $\frac{3}{3}$, M. $\frac{0}{0}$. Besides these there are, according to Tomes, several other small teeth to be found frequently in the position of the incisors, and he is disposed to regard them as the rudimentary representatives of the permanent normal ones in other animals; there can be little doubt that he is correct. Rudiments of true molars are also not unfrequently present in the back part of the jaws. The incisors and molars are small and simple, and are soon worn down even with the gums into obtuse oval grinding surfaces. The canines of the upper jaw protrude far below the level of the symphysis, and grow from persistent pulps. They are composed of dentine with a thin investment of cementum. Tomes says of them: "These great tusks are employed to tear up marine plants and turn over obstacles, the walrus feeding upon crustacea and also upon seaweed, etc.; they are also used to assist the animal in clambering over the ice; as they are of almost equal size in the female, they cannot be regarded as weapons of sexual offence, but they are undoubtedly used in the combats of the males."

The walruses and sea-lions agree with respect to the use of the hind limbs for progression on land, being able to walk on all fours fairly well; in the seals, on the other hand, the posterior members are rotated backward, and permanently fixed in this position, so as to be of little or no use in walking. In this respect they approach nearer to the cetacean condition.

Viewing the *Pinnipedia* as a whole, I am inclined to think that the relationship existing between them and the *Fissipedia* is more apparent than real; and although palæontology does not at present permit us to judge, I am of the opinion that they will ultimately be found to have been derived from an entirely different ancestry. Fossil remains are known as far back as the Miocene, but all that have so far been found are typically pinniped. The simple structure of the teeth finds a parallel in the *Insectivora* in the teeth of the lower jaw of the genus *Mesonyx*, already described, which Cope believes to have been more or less aquatic from the evidence afforded by some of the limb bones. This genus or an allied one may have been the progenitor of the pinnipeds, but too little is known of the skull-structure to say anything about the affinities between them.

The fissiped *Carnivora* are more extensive, both in number and variety, than the pinnipeds, and enjoy a wider range of distribution. Some of them are almost exclusively aquatic in habit, while others are arboreal, fossorial, or terrestrial. It is in this group that we meet with the highest specialization of the dental organs for the purpose of seizing, lacerating, and devouring living prey. In many the claws are extremely sharp and hook-shaped, and are provided with a special apparatus by which they are made retractile, thereby rendering them efficient organs of destruction and prehension as well. The feet are

not modified into flippers, as in the pinnipeds, but constitute distinct "paws," which in the aquatic forms have webbed toes. The canines are always present and generally of formidable proportions, while the sectorial or shearing apparatus is present only in those that subsist exclusively on an animal diet.

They have been divided by Prof. Flower into three groups, which he has called the *Cynoidea*, *Ailuroidea*, and *Arctoidea*, defining them by the characters of the otic bullæ and the base of the skull. The first of these includes the dogs, wolves, and jackals, etc., and in all probability represents the central group. From it the civets, cats, etc., constituting the *Ailuroidea*, branch off on the one hand, while the bears, weasels, raccoons, etc. are closely connected on the other. The *Cynoidea* comprises two families—according to most authors only one; these are the *Canidæ*, or dogs, wolves, foxes, etc., and the *Megalotidæ*, including the single genius *Megalotis*, or the fennec of Africa, which, for reasons which will appear hereafter, I am strongly disposed to regard as an entirely distinct family.

A typical dentition of the *Canidæ* has already been described in that of the dog. About the only dental variations of importance to be seen in this family consists in the reduction of the number of premolars, addition or subtraction to the number of upper true molars to or from that of the dog, subtraction from the lower molar series, and slight modification in form of the sectorials. Upon these variations principally some thirteen or fifteen genera have been defined. The dental formula for many of the genera is the same as that of the dog, I. $\frac{3}{3}$, C. $\frac{1}{1}$, Pm. $\frac{4}{4}$, M. $\frac{2}{3} =$ 42, but the extinct Miocene genus *Amphicyon* (Fig. 229), found both in this country and Europe, had three true molars in the upper jaw. In another extinct genus (*Enhydrocyon*), described by Cope from the Miocene of the John Day beds of Oregon, the premolars are reduced to three in each jaw. *Oligobunus* is the name given by this author to another extinct genus from the same locality, in which the molar formula is Pm. $\frac{4}{4}$, M. $\frac{1}{2}$. The principal part of the skull is represented in Fig. 230. Still another genus of this family has been described by the same author from the rich fossiliferous deposits of that region under the name of *Hyænocyon*, which has three premolars above and below, with only a single true molar above.

Fig. 229.

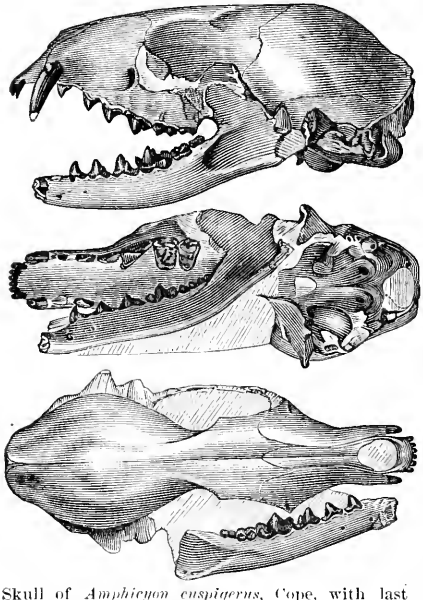

Skull of *Amphicyon cuspigerus*, Cope, with last superior molar lost, one-half natural size, from the John Day beds of Oregon (after Cope).

The sectorials of the more typical *Canidæ* are like those described in

the dog, but in some genera—notably *Temnocyon* of Cope—the heel of the lower sectorial, instead of being basin-shaped, retains the more primitive structure, and consists of a single trenchant cusp (see Fig. 231).

In the extinct genus *Ailurodon* of Leidy the dental formula is the same as in the dog, but it approaches the cats, and especially the hyænas,

Fig. 230.

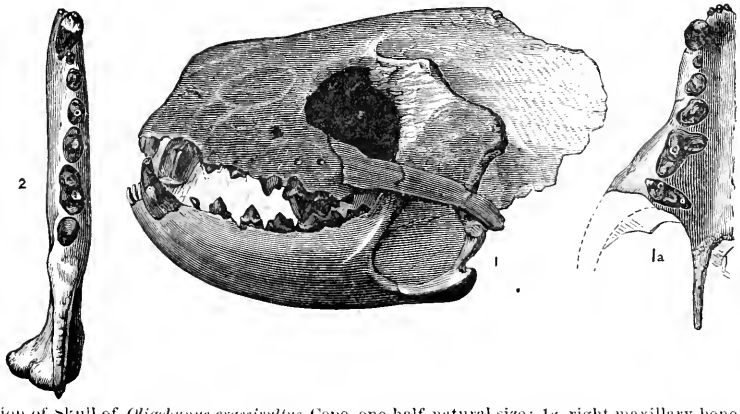

Portion of Skull of *Oligobunus crassirultus*, Cope, one-half natural size: 1*a*, right maxillary bone from below; 2, right mandibular ramus from above (after Cope).

in having three cusps to the blade of the superior sectorial, whereas the dog has only two. The premolars too are more robust than in the dog, constituting another approach to the condition of the *Hyænidæ*. The skull is represented in Fig. 232. The genus *Ictitherium* of Gaudry (Fig. 233), from the Miocene of Pikermi, Greece, is an allied genus, but the third molar of the lower jaw is absent, leaving a formula, I. $\frac{3}{3}$, C. $\frac{1}{1}$, Pm. $\frac{4}{4}$, M. $\frac{2}{2}=40$. In one species (*I. robustum*) the last superior molars have nearly the same proportions as in the dog, while in another (*I. hipparionum*) the last molar is considerably reduced in size. It will thus be seen that these two genera depart from the central or typical *Canidæ*, and establish close connections with the *Hyænidæ*, which are closely affiliated with the cats and belong to the *Ailuroidea*. Cope has suggested that *Ailurodon* is the ancestor of the hyænas; and there is undoubtedly much evidence to support this opinion.

Fig. 231.

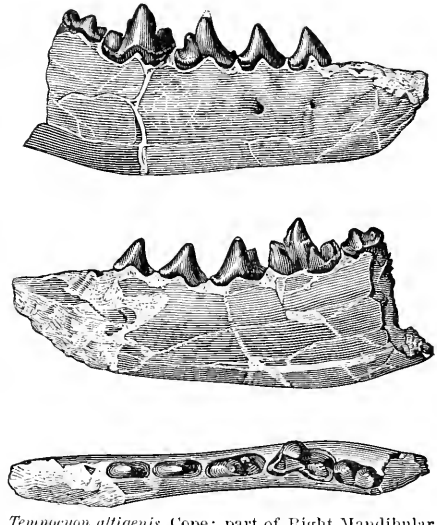

Temnocyon altigenis, Cope: part of Right Mandibular Ramus, one-half natural size, viewed from without, within, and above (after Cope).

The second family of the *Cynoidea* is the *Megalotidæ*, which is dis-

tinguished from the *Canidæ*—and, for that matter, from all other diphyodont monodelphous mammals—by the possession of *four* true molars in the lower jaw, thereby giving the formula I. $\frac{3}{3}$, C. $\frac{1}{1}$, Pm. $\frac{4}{4}$, M. $\frac{3}{4} = 46$. The only other cases in which there are more than three true molars normally are found in the marsupials, edentates, and cetaceans; and in these two latter orders we have already seen that the teeth are not generally divisible into incisors, canines, premolars, and molars, on account of the development of only a single set. In the marsupials, however, as we shall presently see, the normal number of

FIG. 232.

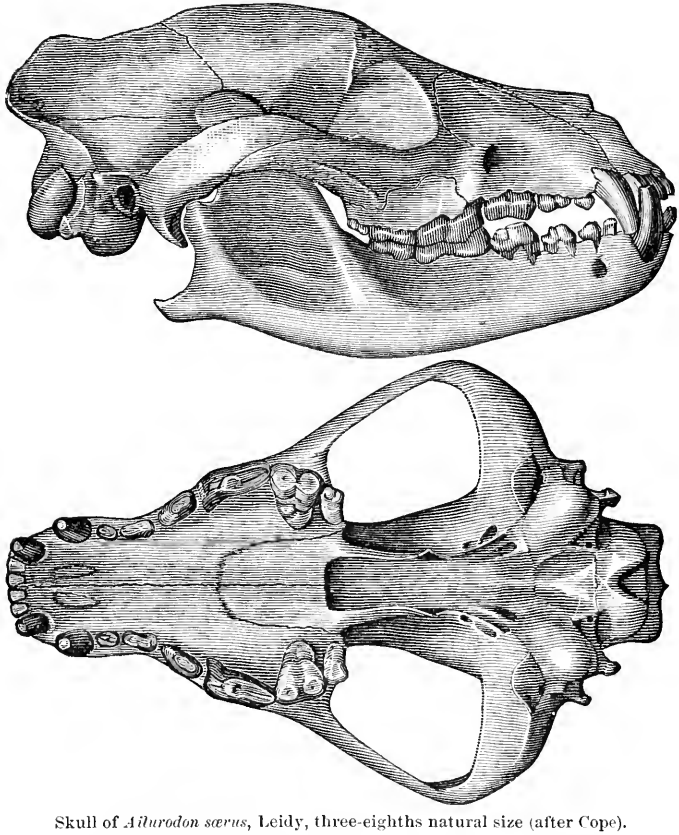

Skull of *Ailurodon sævus*, Leidy, three-eighths natural size (after Cope).

true molars is four, just as the number three is most common to diphyodont monodelphs. Reduction of the normal number is to be frequently observed in the monodelphs, and, as we have just seen in the *Canidæ*, occurs in genera otherwise nearly related; it cannot therefore be regarded as of more than generic importance, but there are no cases known to me in which teeth have been added. On the contrary, I am firmly of the opinion that not so much as a single tooth has ever been added to the diphyodont mammalian dentition in the course of development, but that specialization has invariably gone in the opposite direc-

tion, as almost all evidence of palæontology goes to show. The teeth are not otherwise remarkable, resembling distantly those of the dog in general pattern. The sectorials are not well defined, and the crowns generally have a tendency to the tubercular structure.

The second division of the Fissipedia (*Ailuroidea*) includes five families, the exact definitions of which the increasing knowledge of the extinct forms is tending every day to break down into hopeless confusion. The definitions are already very unsatisfactory and in many cases fail to define.

Fig. 233.

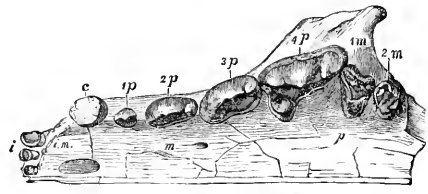

Superior Dental Series of *Ictitherium robustum*, two-thirds natural size (from Cope, after Gaudry).

The families which approach nearest to the *Canidæ* are the *Hyænidæ* or hyænas, and the *Viverridæ* or civets. The evidence already cited brings the former of these families into the closest relationship with the central cynoid group. The dental formula of the existing hyænas (Fig. 234) is, I. $\frac{3}{3}$, C. $\frac{1}{1}$, Pm. $\frac{4}{3}$, M. $\frac{1}{1} = 34$. The incisors and canines have very much the same pattern as the corresponding teeth in the dog, as do also the premolars, with the exception of their more robust proportions

Fig. 234.

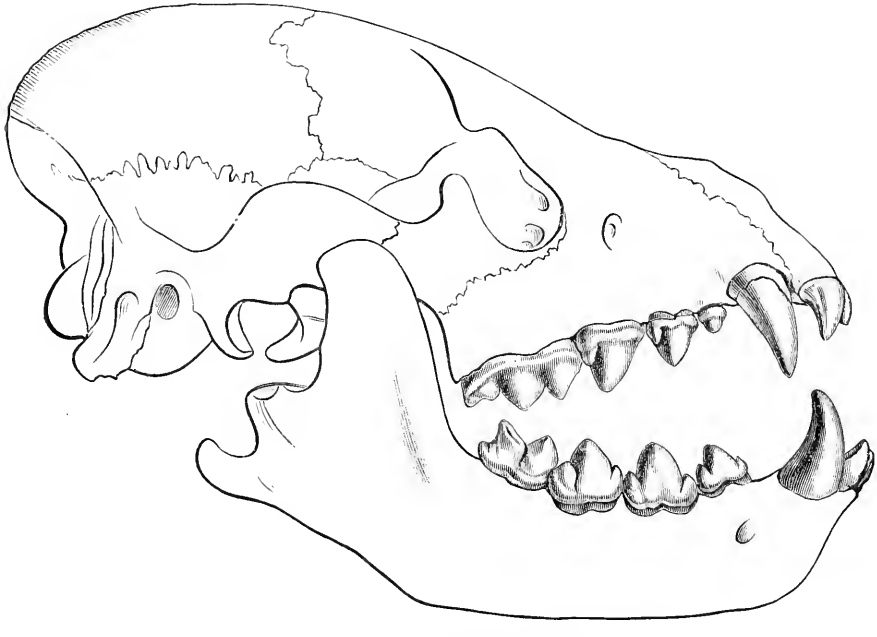

Skull of Striped Hyæna, *Hyæna striata*.

and the addition of an anterior cutting lobe to the superior sectorial. In the lower sectorial the heel is very rudimental and the internal tubercle is wanting. The single superior true molar is small and

situated just internal to the posterior part of the great superior sectorial, so as to be completely hidden in an external view of the jaw.

In an extinct species (*Hyæna eximia*) there were four premolars in the lower jaw, giving the formula I. $\frac{3}{3}$, C. $\frac{1}{1}$, Pm. $\frac{4}{4}$, M. $\frac{1}{1} = 36$. The inferior sectorial also has a well-defined heel. In the more ancient or Miocene representative of this family (*Hyænictis græca*, Fig. 235) the superior molar is much larger and has a more posterior position; the inferior sectorial (Fig. 236) has a relatively large basin-shaped heel, and there is a small second true molar behind it. It is through this genus that the transition is effected from the *Hyænidæ* to the *Canidæ* by way of *Ictitherium* and *Ailurodon*.

Fig. 235.

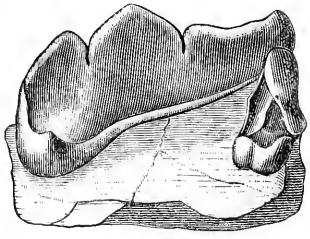

Superior Sectorial and First Molar of *Hyænictis græca* (after Gaudry).

The dental formula of the *Viverridæ* varies somewhat by reason of decrease in number of the premolars and molars. The more important of these will be noticed after we have first described the dentition of a typical example of the family, which is found in the genus *Herpestes*, or the mongoose. The dental formula is I. $\frac{3}{3}$, C. $\frac{1}{1}$, Pm. $\frac{4}{4}$, M. $\frac{2}{2} = 40$. The incisors of the upper series have flattened oval crowns without lateral lobes, increasing in size from first to third; the canines are long, pointed, and recurved; the first three premolars have the usual pattern, but are devoid of accessory cusps. In the fourth premolar or superior sectorial the blade is composed of the usual two posterior cusps, separated by a fissure remarkable for its depth. There is also a rudimental anterior basal lobe, which arises from the cingulum. The internal lobe is unusually strong, and sends a trenchant ridge backward and outward to join the principal cone. The next tooth, or first true molar, is tritubercular, with two external and one internal cusp; the crown is remarkable for its transverse extent. The last molar is relatively small, and has a more internal position, possessing a bicuspid crown. The decrease in size of the true molars from that of the great sectorial, and the strongly inward curvature of the tooth-line behind, are more pronounced than in the dog, and altogether intermediate between that of the latter animal and the cats.

Fig. 236.

Fragment of Lower Jaw of *H. græca*, showing sectorial and second molar (after Gaudry).

The incisors of the lower jaw are smaller than the corresponding teeth above, and the summits of their crowns are distinctly notched; the canines are like those of the upper jaw, while the premolars have basal cusps which are largest behind. The first true molar or inferior sectorial furnishes a pattern intermediate between the tuberculo-sectorial and the well-defined sectorial. The primitive cone and anterior basal lobes are connected into a blade, the internal tubercle being large and furnishing the characteristic triangular appearance of this portion of the

crown. The heel consists of a raised margin bearing several small tubercles. The last molar is quadritubercular, and seems to have retained the anterior triangle of the preceding tooth, together with one cusp of the heel. If this be so, it is an exception to the general rule, according to which the anterior cusp becomes obsolete.

In the two-spotted paradoxure (*Nandinia*) of West Africa the molar series is frequently reduced to M. $\frac{1}{2}$, while in the bintourong (*Arctictis*) the last molar above and the first premolar below are often absent. The premolar formula of the genus *Galidea* is normally $\frac{3}{3}$, which likewise obtains in the kusimanse (*Crossarchus*) from the West Coast of Africa. The form of the inferior sectorial of the genus *Cynogale*, a Bornean representative of this family, is nearer that of a tubercular than a sectorial tooth. The three anterior cusps which go to make up the triangular portion are very much reduced, and have altogether lost their sectorial character; the superior sectorial, however, is much better defined as such. In another genus (*Eupleres*) the teeth are very small and the incisors stand far apart, on account of which, together with several cranial peculiarities, Dr. Gill gives it a distinct family rank.

It will thus be seen in a survey of the dental organs of this family that they are almost identical with the genus *Didymictis* of our American Eocene, which has already been described, and I think there can be little doubt that they are the derivatives of this or some nearly related genus.

Another family, which stands intermediate between the civets and cats, is represented by the single living genus *Cryptoprocta*, which is limited in its distribution to the island of Madagascar. Some authors classify it as a sub-family of the cats, others as a sub-family of the civets, while others again make it a distinct family. No better argument, it seems to me, could be advanced in support of its intermediate nature. It undoubtedly has strong affinities with both families, and goes far toward bridging over the interval between them. The recent discoveries of Cope and Filhol have shown it to be the surviving remnant of an extensive group which lived in this country and Europe, and which were the ancestors of the cats, and in all probability the derivatives of the more generalized civets. In distinguishing between the *Felidæ*, *Viverridæ*, and *Cryptoproctidæ* the foramina at the base of the cranium afford the best, if not the only, grounds for separation. Previous to our knowledge of the extinct forms the number of the molar teeth was also used for this purpose, but owing to the intermediate condition of this latter character in many of the fossils it must be abandoned as altogether worthless. In the *Cryptoproctidæ* the alisphenoid bone is perforated by a canal—the alisphenoid canal—for the passage of the external carotid artery in its course forward. The foramen for the entrance of the internal carotid in its passage to the brain is also well defined, and of a considerable size. In the *Felidæ* there is no alisphenoid canal, and the carotid canal is minute or absent. In the *Viverridæ* the alisphenoid canal is generally present, but not invariably so; the foramen for the entrance of the internal carotid is of moderate proportions, as in the *Cryptoproctidæ*, from which I can see no very good reasons for distinguishing them as a family. Cope associates a number of extinct genera together under the name of *Nimravidæ*, and defines them from the *Felidæ*

by a number of characters in which they agree with the *Cryptoproctidæ;* the distinctions between them and this latter family are not so apparent.

The dental formula of *Cryptoprocta* is I. $\frac{3}{3}$, C. $\frac{1}{1}$, Pm. $\frac{4}{3}$, M. $\frac{1}{1} = 34$. The incisors and canines resemble those of the cats generally; the first premolar in the upper jaw is caducous, and does not usually appear in the adult skull. The superior sectorial has a rudimental anterior basal lobe, an internal tubercle, and a well-defined blade. The molar is a much smaller tooth, and has an internal position, as in the hyænas. In the lower jaw the sectorial has a faint heel and lacks the internal tubercle, and is altogether feline in its appearance.

The following extinct genera are enumerated and defined by Cope as belonging to the family *Nimravidæ*:[1]

I. Lateral and anterior faces of mandible continuous; no inferior flange.
  a. No anterior lobe of superior sectorial; inferior sectorial with a heel; canines smooth.
    Pm. $\frac{4}{4}$, M. $\frac{1}{2}$; inferior sectorial with internal tubercle . . . . . *Proælurus.*
    Pm. $\frac{3}{3}$, M. $\frac{1}{1}$; inferior sectorial without internal tubercle . . . . *Pseudælurus.*
    Pm. $\frac{4}{3}$, M. $\frac{1}{1}$; inferior sectorial without internal tubercle . . . *Cryptoprocta.*[2]
II. Lateral and anterior faces of mandible separated by a vertical angle; no inferior flange; incisors obspatulate.
  a. No anterior lobe of superior sectorial; inferior sectorial with a heel (and no internal tubercle); incisiors truncate.
    Pm. $\frac{4}{3}$, M. $\frac{1}{2}$; canine smooth . . . . . *Archælurus.*
    Pm. $\frac{3}{3}$, M. $\frac{1}{2}$; canines denticulate . . . . . *Ælurogale.*
    Pm. $\frac{3}{2}$, M. $\frac{1}{2}$; canines denticulate . . . . . *Nimravus.*
III. Lateral and anterior faces of mandible separated by vertical angle; an inferior flange; canines denticulate.
  a. No or a small anterior basal lobe of superior sectorial; inferior sectorial with a heel. No posterior lobes on crown of premolars.
    Pm. $\frac{3}{3}$, M. $\frac{1}{2}$ . . . . . *Dinictis.*
    Pm. $\frac{3}{3}$, M. $\frac{1}{1}$ . . . . . *Pogonodon.*
    Pm. $\frac{2 \text{ or } 3}{2}$ M. $\frac{1}{1}$ . . . . . *Hoplophoneus.*
    Pm. $\frac{?}{1}$, M. $\frac{?}{1}$ . . . . . *Eusmilus.*

Proælurus, is known to have possessed five digits in each foot, as *Cryptoprocta*, and it is probable that two sub-families should be made, since others had only four in the pes. The dentition of *Proælurus* (Fig. 237) is more primitive than *Cryptoprocta* in the following characters: there are four premolars in the lower jaw; the superior sectorial has no anterior basal lobe; the inferior sectorial has a strong heel and an internal tubercle; and there are *two* true molars below.

FIG. 237.

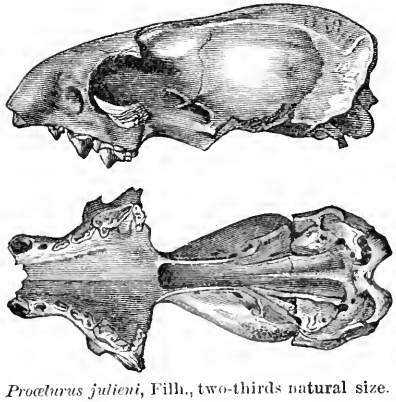

Proælurus julieni, Filh., two-thirds natural size.

Pseudælurus agrees more nearly with *Cryptoprocta*, but lacks one premolar in the upper series. As already observed, the first premolar is caducous in this latter genus, and they may be the same. In the sec-

[1] "On the Extinct Cats of America," *American Naturalist*, Dec., 1880.

[2] I have combined the *Nimravidæ* and the *Cryptoproctidæ*, and have inserted this genus where it seems to most appropriately belong.

ond section the anterior and lateral faces of the mandible are separated by an angle or vertical ridge, which gives to the jaw the appearance of having a square chin.

The genera of this section, with the exception of *Ælurogale*, are from the Miocene beds of the John Day Valley, Oregon, and were described by Cope; the premolar series shows a gradual reduction in number, but they all retain the heel to the inferior sectorial and the generalized character of two true molars in the lower jaw. *Archælurus* and *Nimravus* are represented in the accompanying figures, 239 and 240.

FIG. 238.

Proælurus julieni, Filh., two-thirds natural size: *a*, inner view of mandible; *b*, superior view of inferior teeth; *c*, inferior sectorial, natural size (from Cope after Filhol).

FIG. 239.

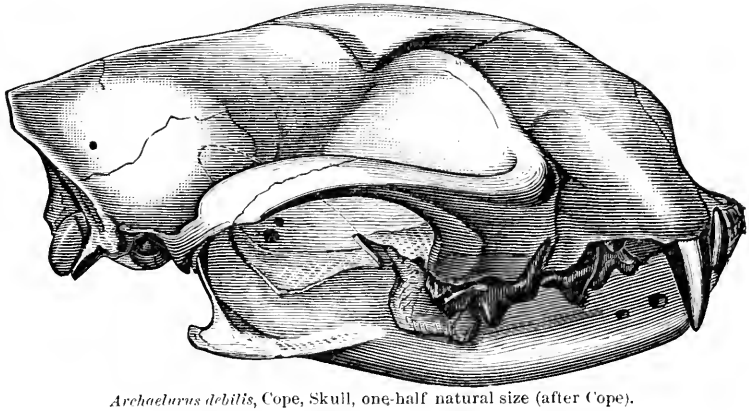

Archælurus debilis, Cope, Skull, one-half natural size (after Cope).

FIG. 240.

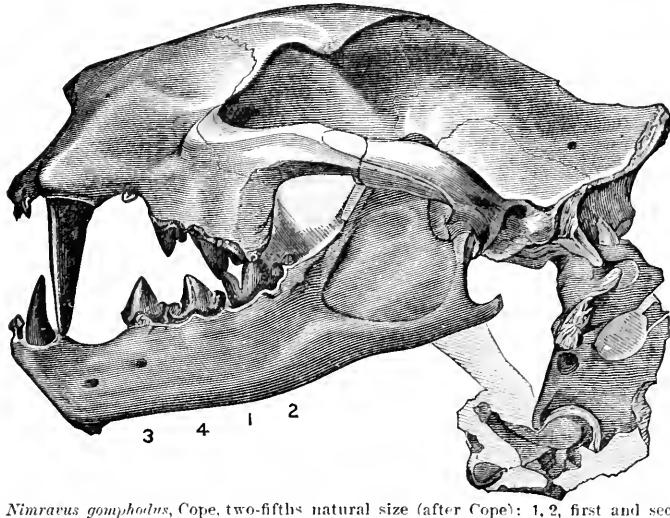

Skull of *Nimravus gomphodus*, Cope, two-fifths natural size (after Cope): 1, 2, first and second true molars; 3, 4, third and fourth premolars of lower jaw.

In the third section the mandible possesses a strong inferior flange upon each side to protect the powerful canines of the upper jaw, which in some forms project far below the level of the symphysis. They are therefore known as the "sabre-tooth division." In the first of these genera, *Dinictis* (Fig. 241), the true molars are $\frac{1}{2}$, the inferior sectorial

FIG. 241.

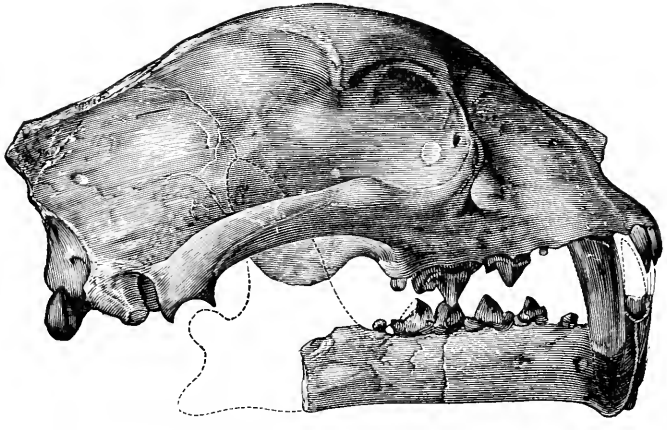

Skull of *Dinictis cyclops*, one-half natural size (after Cope).

has a heel, and the true molar above is a moderately well-developed tooth, as in the preceding genera. The genera *Hoplophoneus* and *Pogonodon* carry dental specialization several steps further, while in *Eusmilus* we have the highest point reached by any of this group, which is in many respects superior to the living cats.

Cope, in commenting upon the dentition of this group, says: "It is readily perceived that the genera above enumerated form an unusually simple series, representing stages in the following modifications of parts: (1) In the reduced number of molar teeth; (2) in the enlarged size of the superior canine teeth; (3) in the diminished size of the inferior canine teeth; (4) in the conic form of the crowns of the incisors; (5) in the addition of a cutting lobe to the anterior base of the superior sectorial tooth; (6) in the obliteration of the inner tubercle of the lower sectorial, and (7) in the extinction of the heel of the same; (8) in the development of an inferior flange at the latero-anterior angle of the front of the ramus of the lower jaw; (9) in the development of cutting lobes upon the posterior border of the large premolar teeth. . . . . The succession of the genera above pointed out coincides with the order of geologic time very nearly. . . . . The relations of these genera are very close, as they differ in many cases by the addition or subtraction of a single tooth from each dental series. These characters are not even always constant in the same species, so that the evidence of descent, so far as the genera are concerned, is conclusive. No fuller genealogical series exists than that which I have discovered among the extinct cats."

The last family of the *Ailuroidea* is the *Felidæ*, in which we meet with the highest point in specialization that has been reached in the flesh-

eating Mammalia. It includes two divisions—one in which the superior canines are normal and without the vertical angles and inferior flanges to the mandible; and another, "sabre-tooth division," wherein the superior canines are enormously enlarged, denticulate, and protected by inferior flanges of the rami.

The first of these groups or sub-families is the more generalized, and embraces all the existing cats or those animals popularly known as lions,

FIG. 242.

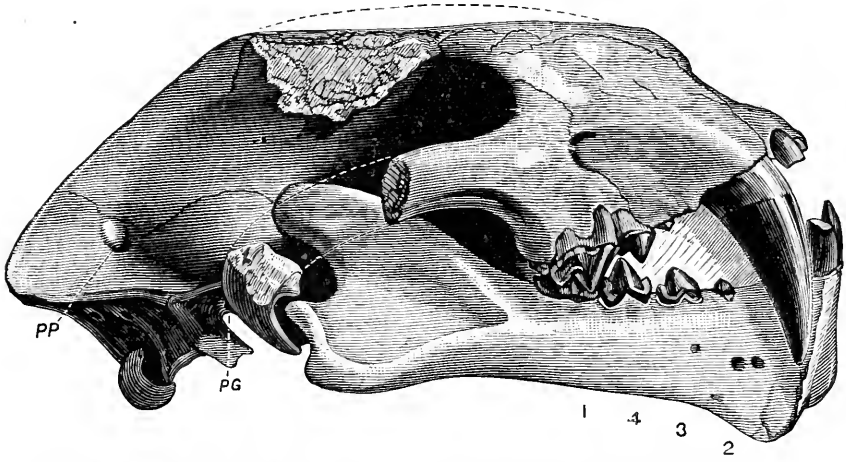

Pogonodon platycopis, Skull, less than two-fifths natural size (after Cope): 2, 3, 4, second, third, and fourth premolars, and 1, first molar of lower jaw; *P G*, post-glenoid foramen; *P P*, post-parietal foramen.

tigers, leopards, panthers, etc. Five genera have been established in this division on characters of the teeth and orbit. It is here that the domestic cat belongs, and its dentition may be taken as a good average representation of that of the sub-family.

The dental formula in this animal is I. $\frac{3}{3}$, C. $\frac{1}{1}$, Pm. $\frac{3}{2}$, M. $\frac{1}{1} = 30$. The incisors are relatively small, and are disposed almost transversely across the front of the jaw. The first premolar above is a small, single-rooted tooth, and is situated at a considerable distance from the canine, which has the usual form and proportions of that tooth in the *Carnivora* generally. The second is larger and two-rooted, while the fourth or upper sectorial is decidedly the largest tooth of the superior series; it has three external cusps united into a blade, and a small internal tubercle. The single molar is very small and functionless, being placed internal to the posterior part of the large sectorial. In the lower jaw the premolars are proportionately large, having two fangs and posterior accessory cusps. The sectorial is specialized, and consists simply of two cusps forming a trenchant blade; both the heel and internal tubercle are absent.

The lynxes have one less premolar upon each side above than the cat, and for this reason are placed in a distinct genus. In the flat-headed cat and the fishing cat the orbit is completely encircled by bone—an unusual occurrence in this family. In both, the number of teeth is the

same as in the domestic cat, but in the former the first premolar in the upper jaw has a single fang, whereas in the latter this tooth is two-rooted. Upon these characters two genera have been established. The clouded tiger of India has a dental formula like that of the lynxes, and approaches the "sabre-tooth division" in the enlargement of the superior canines, by reason of which it has also been given a generic rank. The hunting leopard, or cheetah, forms another genus, and is distin-

FIG. 243.

Cranium of *Smilodon necator*, Gervais, one-third natural size (after Cope).

guished by the absence of the internal tubercle of the superior sectorial. All the other cats are very much alike, and can be distinguished from one another only specifically, being classified, therefore, under the genus Felis.

The second division is extinct, despite the fact that they reveal to us the most perfect laniary dental apparatus yet known within the limits of the Carnivora, and were of the most formidable size. Two genera are known, of which the cranium of one (*Smilodon*) is represented in Fig. 243. In this animal the dental formula is I. $\frac{3}{2}$, C. $\frac{1}{1}$, Pm. $\frac{2}{2 \text{ or } 1}$, M. $\frac{0}{1} = 24$ or 26, and marks the extreme point in dental specialization in this order, as far as reduction is concerned. The canines of the upper jaw are of prodigious size in comparison with those of the lower series, having compressed crowns with serrulate edges. The superior molar has disappeared, and the first premolar in the lower jaw in some species is wanting. The exact use of the great superior canines is not very clearly understood. The possession of retractile claws, the reduction of the molar and premolar series, together with the general perfection of the sectorial apparatus, are strictly in keeping with a most carnivorous habit; but with all this it must have been impossible for the animal to open its mouth wide enough to take a firm grip upon a living prey, on account of the great length of the upper canines.

Seeing that in the existing cats their chief destructive powers reside in their biting qualifications, it is difficult to understand how these animals inflicted wounds sufficient to destroy their prey, unless they did so with that part of the tusk which projected below the level of the symphysis when the mouth was closed, just as the walrus uses his tusks to clamber over the ice. They may also have been used to assist the animal in climbing, and in this way attained their great size.

The animals composing the last group, *Arctoidea*, are the least carnivorous, and do not as a general rule display as trenchant and sectorial dental organs as the two preceding; in two families the almost exclusively carnivorous habits are manifested by sectorials of moderate perfection; this condition is associated with a reduction of molars and premolars from the number possessed by the dog. In the others the molars are more or less tubercular—a structure better fitted for the mastication of the mixed diet upon which they subsist—and usually exceed the premolars in size and strength. The extremes of dental variation in this group are exhibited by the bears and weasels, of which the former are the farthest and the latter the least removed from the more typical carnivores in the structure of the teeth.

In the bears the dental formula is the same as in the dog, but in most of the living species the three anterior premolars are very small, and frequently disappear in old age, leaving a wide space between the fourth and the canine. In the upper jaw the teeth progressively increase in size from the fourth premolar to the last molar, which, besides being quadritubercular, is provided with a large posterior heel rounded off behind; by the addition of this heel the crown is rendered elliptical in transverse section, the antero-posterior diameter being twice that of the transverse. The first true molar has four cusps on its triturating face, and is subquadrate in outline; the fourth premolar is tricuspid, as in the dog, but the two outer cusps are not united into a perfect blade, and the internal lobe is large and has a median position. This tooth is relatively small, and is situated considerably in advance of the canthus or angle of the mouth; it is doubtful

whether its possessor ever makes use of it as a sectorial organ, but rather prefers to tear the tough animal membranes than to divide them with the sectorials, as the dogs and cats do.

In the lower jaw the first true molar betrays the same lack of carnivorous specialization as the upper teeth, being essentially tubercular in structure, although the proper elements of the sectorial of the dog can be easily made out; the crown is much elongated, and is narrower in front than behind, the heel composing at least half of the crown. The next tooth behind it is the largest of this series, and is perfectly quadritubercular; the last molar is smaller, with a subcircular grinding face, upon which the tubercles are poorly defined.

While the structure here described is found in all the northern more carnivorous bears, the tropical frugivorous species retain to a greater extent the integrity and more normal condition of the anterior premolars. This is especially apparent in a genus recently discovered in the mountains of oriental Thibet and described under the name of *Ailuropus*. In this animal the first premolar only is small, while the others gradually increase in size to the last molar, which has a comparatively small heel.

The palæontological evidence is as yet too meagre to demonstrate with any considerable degree of certainty the evolution of this group of the *Carnivora*, but some suggestive hints of their former connection with the *Cynoidea* are afforded by the extinct genus *Hyænarctos*, which was originally described by Dr. Falconer from the Sewalik Hills in India. This genus displays three premolars of normal proportions and a large sectorial, together with a last superior molar in which the heel is absent. In one species in particular, *H. hemicyon*, from the Miocene of Sansan in France, which is provisionally referred to this genus, the two true molars in the upper jaw have about the same proportions as in the dog, and otherwise resemble them very much. The sectorial, as is indicated by the roots, was large, with the internal tubercle placed opposite the middle part of the crown. If it were not for this latter fact, the fragment of the upper jaw upon which the species was established would readily pass for that of a member of the *Canidæ*.

In the weasels, which constitute the family *Mustelidæ*, the sectorials are well defined as such, and some of them, notably the typical weasels, possess retractile claws. In none does the molar formula exceed $\frac{1}{2}$, except a fossil genus, *Lutrictis*, a near ally of the otters, in which the molars are two in the upper jaw; it may, however, be reduced to $\frac{1}{1}$, as in the case of the Cape ratel (*Mellivora capensis*). The premolars vary in number, as do also the sectorial in structure.

The dentition of the American pine marten (Fig. 244) will serve as an illustration of this family, although it is somewhat more specialized in a carnivorous direction than most of them. Its dental formula is I. $\frac{3}{3}$, C. $\frac{1}{1}$, Pm. $\frac{4}{4}$, M. $\frac{1}{2} = 38$. The incisors, canines, and premolars have approximately the same structure as those of the dog, except that the fourth premolar or superior sectorial has the two outer cusps blended together, with the vertical notch absent. The true molar is tubercular, and has a greater transverse than longitudinal extent. In the lower jaw the sectorial is very much like that of the dog,

while the second molar is small, single-rooted, having a crown with one cusp.

The teeth of the raccoons and allied forms are intermediate between those of the bears and weasels in many respects, with a stronger tendency to the tubercular than to the sectorial pattern.

TEETH OF THE CHEIROPTERA.—The modification of the anterior members for flight distinguishes this order from all other unguiculates at once. Excluding this peculiarity, which is universal among them, they are closely related to the *Insectivora*, and without doubt have been derived from some arboreal representative of this order. It is conceivable that in jumping from branch to branch they have first developed a lateral fold of integument, similar to that seen in the flying squirrels, which later involved the fore limbs and extended to the neck. The flying lemur (*Galeopithecus*) furnishes such a transitional condition, both in the possession of the membrane and the elongated and slender fore limbs, although it is highly improbable that the bats have descended through this genus.

FIG. 244.

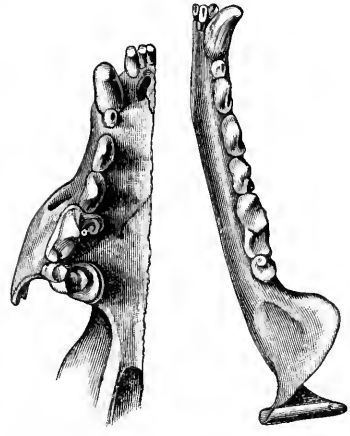

Vertical View of the Upper and Lower Jaw of American Pine Marten (*Mustela americana*).

The incisors are never more than two upon each side above, while the lower jaw is usually provided with the same number, but may be increased to three. Canines are always present in both jaws, but are of variable proportions. In the insect-eating forms (*Animalivora*), which includes the great bulk of the species, the upper molar teeth invariably display the peculiar W-pattern of the moles, shrews, etc. of the *Insectivora*, already noticed. The premaxillary bones are always small, and seldom meet in the median line so as to leave the tooth-border interrupted in front. In the W-pattern of the superior molars, the absence of the median pair of upper incisors, and the small premaxillaries it is interesting to note the resemblances they bear to the squirrel shrews (*Tupaiadæ*), the only other insectivores besides the flying lemur which are known to be arboreal in habit. Ignorance of the rest of the anatomy of this genus does not permit me to state whether it strengthens this resemblance or otherwise, but upon the whole I am inclined to believe that some such arboreal insectivore was the ancestor of the bats.

The dentition of the blood-sucking vampires is modified in accordance with their habits, as is also the entire alimentary canal, and deviates quite extensively from the normal condition of that of the insect-eaters. The alimentary tract consists of little more than a straight tube from mouth to anus, and is thus adapted to the assimilation of the blood of living animals, upon which it feeds.

The large incisors of the upper jaw are two in number, one upon each side, whose roots extend into the maxillary bone, and whose compressed, sharp-pointed, hook-shaped crowns are specially fitted to puncture the

skin of an animal sufficiently to cause the blood to flow freely. The canines are almost equal in size and similar in shape, while the lower incisors and canines are small. The molars are reduced to two in the upper and three upon each side in the lower jaw; the upper molars are implanted by single fangs and have simple conical crowns; in the lower jaw the first two are like those above, but the third has two fangs and a bilobed crown, and is considered by Owen to be homologous with the last premolars of insectivorous bats. The dental formula is thus reduced to I. $\frac{1}{2}$, C. $\frac{1}{1}$, Pm. $\frac{2}{3} = 20$.

The frugivorous bats, which are popularly known as "flying foxes," offer another deviation from the usual structure in the pattern of the molar teeth; those in the upper jaw have crowns of a subcircular form in outline with a central longitudinal depression, upon each side of which the edge is elevated into a cusp. Those of the lower series are similar but smaller, with the cusps more pronounced and the median groove narrower.

Teeth of the Rodentia.—The amount of minor variation in the dental organs of this order is so extensive that their complete elucidation is hardly within the scope of the present work; a description of the leading types must suffice. That which most conspicuously distinguishes the rodents from all other mammals is the possession of two powerful curved incisors in each jaw, which grow from persistent pulps and are faced with enamel. The roots are implanted deeply in the substance of the jaw bones in the lower jaw, often reaching as far back as the coronoid process. In consequence of the distribution of the enamel upon the front face of the tooth, leaving the dentine naked behind, the inequality of wear between the two surfaces is always marked, and constantly preserves a chisel point to the crown—a structure pre-eminently adapted to the gnawing habits of its possessor. Concomitant with this modification the canines are always absent, the premaxillary bones are large to support the roots of the incisors, and there is a wide space between the first molar or premolar and the incisor, in which no teeth appear. The mandibular condyle, moreover, is globular in form and never transverse, thereby allowing excursion only in an antero-posterior direction.

The order thus distinguished is divisble into four sub-orders, of which the rat, squirrel, porcupine, and rabbit are typical representatives of each.

The dental formula of the common rat (Fig. 245) is I. $\frac{1}{1}$, C. $\frac{0}{0}$, Pm. $\frac{0}{0}$, M. $\frac{3}{3} = 16$. Deciduous teeth are entirely wanting, and it is therefore monophyodont—a condition which we would be led to anticipate, as far as the molar and premolar series is concerned, in view of the subtraction of the latter. The absence of any deciduous predecessors of the two pairs of incisors is said to be a constant feature of all rodents except the hares, so that monophyodontism of this highly heterodont animal need not occasion surprise.

Fig. 245.

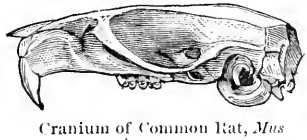

Cranium of Common Rat, *Mus decumanus*.

The incisors are of the usual pattern displayed by the order—large,

curved, compressed teeth, with chisel-shaped crowns, which are stained a deep orange color on the anterior face; the pigment which produces this color is intimately incorporated with the enamel itself, as in the shrews, and serves to sharply define the limits of the enamel covering.

In both the upper and lower jaws the first molar is the largest and the third the smallest. They are implanted by distinct roots, the opposite rows of teeth being nearly parallel. The crowns are made up of three curved transverse ridges, with the convexity in front and the concavity behind; the two anterior of these, in the upper teeth, are terminated internally by well-marked cusps, which rise above the summits of the ridges. In the last tooth the anterior and posterior of these ridges are less distinctly marked, and are reduced to little more than internal tubercles. The second molar of the lower jaw has the last crest rudimental, and in the third it is entirely wanting.

While this structure prevails in the teeth of the more typical murines, others possess molars with crowns of much greater complexity and without roots. Such is exemplified by the arvicoline section of the *Muridæ*, in which the crown is cleft to the median line by vertical fissures upon each side placed alternately. The structure of the grinding surface which results from this arrangement is a system of alternate triangular prisms connected in the middle of the crown by a narrow band of dentine. This is well shown in the accompanying figure.

FIG. 246.

Vertical View of the Grinding Surface of the First Lower Molar of a Muskrat (*Fiber zibethicus*).

In the squirrel division premolars are always present, in consequence of which there are deciduous teeth. With the exception of the beaver family, the teeth are very similar in the different species, the only important variation occurring in the number of premolars. In the common fox squirrel the dental formula is I. $\frac{1}{1}$, C. $\frac{0}{0}$, Pm. $\frac{1}{1}$, M. $\frac{3}{3} = 20$. The incisors (Fig. 247) are not so robust as in the rat, and, like them, are colored upon the anterior face.

FIG. 247.

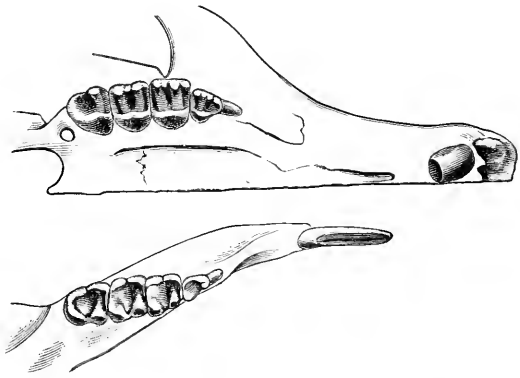

Vertical View of the Teeth of Fox Squirrel (*Sciurus carolinensis*).

The first and only premolar is smaller, implanted by three roots, and has a triangular tricuspid crown. The three true molars in the upper

jaw are larger and subequal in size. Their crowns are imperfectly quadrate in outline, and provided with two transverse crests which join a large marginal cusp on the internal border. There is in addition an anterior and posterior cingulum, which becomes continuous with the large marginal cusp. The inferior molars have the same quadrate outline as those above, but the crowns present a central depression surrounded by a slightly elevated margin bearing a cusp at each angle.

In this sub-order is to be found the nearest approach to the quadritubercular condition of the molar teeth in any of the *Rodentia*, in consequence of which there is little difficulty in comprehending their organization; but when we come to analyze the highly complex form of molar which some of the porcupines exhibit, we naturally seek for a key to a solution of their structure on the basis of the quadritubercular; this is all the more natural when we remember that the squirrels present the oldest known representatives of the order in the genus *Plesiarctomys* of Middle Eocene Age, which scarcely differs generically from the living forms. The teeth of the American porcupine (*Erethizon*), while possessing in general the molar pattern of the squirrel, nevertheless differs from it sufficiently in the direction of the more specialized hystricine teeth to let us into the secret of how these complex forms have arisen from that of the squirrel.

In the description of the molars of the squirrel we have already seen that the face of the crown is marked by three transverse ridges, enclosing two valleys, which open externally and are bounded internally by a thick marginal cusp. Now, in the first premolar of the porcupine (Fig. 248) which is unusually instructive, the three transverse ridges are present, but considerably augmented in height, together with a fourth ridge behind added from the cingulum. The valleys separating the three anterior crests open externally, while the fourth coalesces externally with the third, so as to enclose a deep pit or fossette; the strong internal marginal cusp is likewise present, but is interrupted on its inner side by a deep wide valley which opens internally. The succeeding molars are like it in structure, except that the first and second transverse ridges unite at their extremities to form a second fossette in front.

FIG. 248.

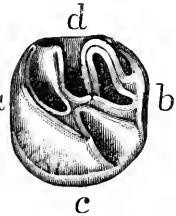

First Lower Premolar of Porcupine (*Erethizon dorsalis*), vertical view: *a*, anterior; *b*, posterior; *c*, internal; and *d*, external surfaces of the crown.

In other genera of this group the valleys are still further deepened by the elevation of the ridges, and other indentations are added from within. As a protection against fracture of the now laminar crests, cementum is added, which completely fills up the valleys, leaving the grinding surface approximately smooth. This is the condition attained by the beaver among the sciuromorph or squirrel sub-order, as well as a majority of the hystricomorphs or porcupines. As a further complication in this series, the external and internal valleys unite across the face of the crown, leaving transverse laminæ connected only at the base and bound together above by cementum; of which the guinea-pig is an example. Finally, the extreme of specialization is reached in the capybara, wherein these transverse laminæ are as many as thirteen or fourteen in a single tooth.

This point of perfection rivals that of the elephant, and is undoubtedly a long way removed from the quadritubercular structure. On account of this highly complex molar dentition and certain cranial peculiarities Dr. Gill has proposed to give this genus a distinct family rank.

The last sub-order of the *Rodentia* is the *Lagomorpha*, which includes the hares and rabbits. The dental formula in this group is constantly I. $\frac{2}{1}$, C. $\frac{0}{0}$, Pm. $\frac{3}{2}$, M. $\frac{3}{3} = 28$, in addition to which in very young specimens there is another or third pair of incisors in the upper jaw to be added to the permanent set. Huxley has recently shown that the deciduous dentition is D. I. $\frac{3}{2}$, D. M. $\frac{3}{2}$, which brings this group of the *Rodentia* into strict accord with other Mammalia in the replacement of the teeth.

Fig. 249.

Last Molar of Capybara (*Hydrochœrus capybara*), vertical view.

The median pair of superior incisors depart from the usual pattern, inasmuch as they are indented upon their anterior faces by a vertical groove near the middle of the tooth; they are otherwise as in the genera already noticed, except that they lack the orange color of the enamel. Immediately behind each of these incisors, and applied closely to them, is to be seen a small cylindrical tooth, the second pair of incisors. In the very young state a third pair can usually be found imbedded in the gum external to the two median ones, which fall out soon after birth. The single pair of the lower jaw are not grooved and have the usual form common to the order.

The molars are remarkable for their great length in a vertical direction, as well as their antero-posterior compression; they grow continuously and do not form roots. With the exception of the first premolar and the last molar, the molars and premolars of the upper jaw are alike, and consist of two vertical transverse laminæ closely united in the middle line, the division of which is indicated both on the inner and outer sides of the tooth by a vertical groove. The first premolar and last molar are made up of a single lamina, the enamel being thrown into two vertical folds upon the anterior part of the first premolar. In other respects the rabbits are remarkable for the entire absence of the coronoid process and the very small bony palate, which forms little more than a bridge across the roof of the mouth.

Teeth of the Ungulate Series.

So far, excluding the rodents, our attention has been confined to those dental organs in which the molars have not, with few exceptions, passed beyond the quadritubercular stage of development; this condition, we have the best of reasons to conclude, was preceded by the tritubercular in the upper and the tuberculo-sectorial, or at least a tooth possessing its elements, in the lower jaw. When one compares these short-crowned rooted tubercular molars with the complex rootless molars of a horse, cow, or elephant, he might spend hours and days in thoughtful contemplation without discovering the faintest relationship existing between their respective patterns; nor would we be any nearer a solution of the difficulty had not the researches of palæontologists brought to our

understanding a knowledge of these organs before they had assumed those distinctive characteristics and specialized patterns which they now display.

There are few students of odontography who are acquainted with the facts of mammalian palæontology as they now stand who have not had repeatedly forced upon their attention the gradual decrease in complexity of the molar teeth of the ungulates as we go backward in time. Cope has recently shown that the earliest ungulates had, as a general rule, tritubercular molars—a condition which is as primitive as that of many insectivores; and in no instance do we meet with highly specialized teeth until the latest geological periods are reached.

The ungulate series is divisible into four orders, which have been characterized and defined by Cope upon the structure of the limbs. The oldest of these orders, *Taxeopoda*, is remarkable for the generalized character of the limbs as compared with the later ungulates; they possess five toes upon each foot, and in one family, the *Periptychidæ*, the superior true molars are *tritubercular*—a fact which brings the ungulate stem to a point not far removed from the Insectivora of the unguiculates. This order includes three sub-orders, two of which are extinct, and one, the *Hyracoidea*, being represented by two living genera, popularly known as the coneys. The most ancient of these three sub-orders is the *Condylarthra*, a group thus far known only from the American Eocene. A careful study of their osteology leads to the conclusion that they are the ancestors of all succeeding ungulates, furnishing just such a generalized type in the proper geological position as is necessary to satisfy the demands of the development hypothesis; they likewise enable us to comprehend more clearly the mutual relationship and evolution of the entire series.

Teeth of the Taxeopoda.—As the *Condylarthra* are the oldest of this order and the most primitive in their organization, it will be best

Fig. 250.

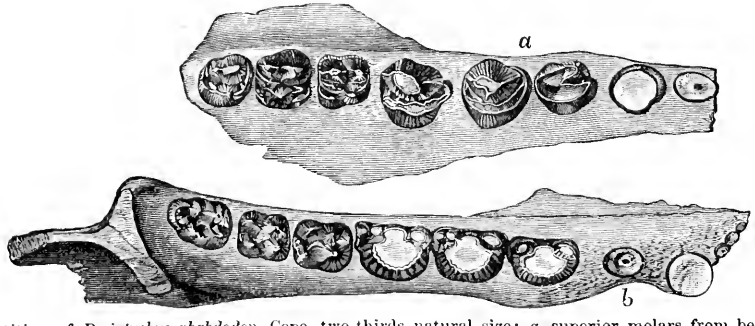

Dentition of *Periptychus rhabdodon*, Cope, two-thirds natural size: *a*, superior molars from below; *b*, inferior molars from above—from the New Mexican Puerco (after Cope).

to commence with a consideration of their teeth. Three families are referred to it, one of which, the *Periptychidæ*, is confined to the lowest Eocene deposits.[1] In the typical genus, *Periptychus* (Fig. 250), the

[1] When the lowest Eocene is mentioned, reference is made to the Puerco beds, which were formerly considered to belong to the Tertiary; Prof. Cope now considers that they are of Cretaceous age.

dental formula is I. $\frac{3}{3}$, C. $\frac{1}{1}$, Pm. $\frac{4}{4}$, M. $\frac{3}{3} = 44$, the normal diphyodont number. The incisors are relatively small and of the usual pattern; the canines are large, powerful teeth, and resemble those of many carnivorous and insectivorous animals. The premolars gradually increase in size from the first to the fourth, which considerably exceeds the true molars in size; the crowns of the last three premolars in the upper jaw have a large external conical cusp and a strong internal ledge; those of the lower jaw have a strong outer cusp, with a small accessory one at the antero-internal, and two at the postero-internal, angle of the crown.

The true molars of the upper series appear at first sight to be complex and multicuspid, but upon analysis it is found that they are essentially tritubercular, with minor cusps added. The two usual external cusps are present, together with one large internal tubercle somewhat crescentic in horizontal transverse section. The three principal cusps are homologous with the three cusps of the molar teeth of many of the Insectivora already mentioned, and like them are placed in the form of a triangle, but the two horns of the crescent are interrupted by the development of two intermediate cusps; to these are added two small interior cingular marginal cusps, making seven in all. The lower molars are quadritubercular, with a faint representation of the anterior basal cusp of the tuberculo-sectorial still remaining. The postero-external cusp is connected with the antero-internal by a ridge which crosses the face of the crown obliquely; this ridge is found in some of the insectivores, notably *Esthonyx*, and is what remains of the former connection of the heel with the anterior or triangular part of the tuberculo-sectorial. The enamel of both the molars and premolars of this genus is curiously sculptured, owing to the presence of a number of

FIG. 251.

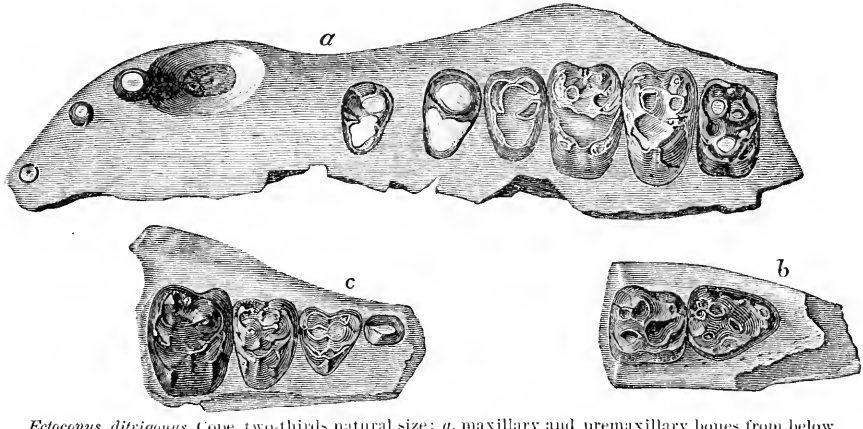

Ectocœnus ditrigonus, Cope, two-thirds natural size: *a*, maxillary and premaxillary bones from below, retaining a good deal of the matrix; *b*, last two inferior molars, worn by use; *c*, three deciduous with first permanent molar of a young animal (after Cope).

vertical grooves and ridges, it being the only case of the kind known in the Mammalia. In an allied genus, *Ectoganus* (Fig. 251), the molars are larger than the premolars, and their crowns are further complicated by the addition of an outer cingular cusp, giving a total of eight of the

most complex tritubercular teeth yet known. This figure displays more clearly than that of *Periptychus* the relationship of the component cusps.

Other genera of this family, of which there are seven in all, display simple tritubercular molars, which resemble the corresponding teeth of the insectivores to a remarkable extent.

The second family of this sub-order is the *Phenacodontidæ*, which continues to the Upper Eocene Period. Fragmentary remains of the typical genus *Phenacodus* were known as long ago as 1873, but very little was known of its true nature until, some nine years later, the writer was fortunate enough to discover two almost complete skeletons, representing two distinct species, in a fine state of preservation while exploring the Wasatch deposits of the Big Horn Basin, Wyoming Territory. This material has afforded Prof. Cope, at whose instance the exploration was undertaken, the opportunity of not only determining the position and affinities of this remarkable genus, but a key to a correct interpretation of many of his later discoveries, as well as a basis for one of the most important generalizations yet introduced in relation to the hoofed Mammalia.[1]

The dentition of this genus (Fig. 252) approaches nearer to that of the higher ungulates than the preceding family, although the interval between them is comparatively small. Its formula is I. $\frac{3}{3}$, C. $\frac{1}{1}$, Pm. $\frac{4}{4}$, M. $\frac{3}{3} = 44$. The premolars are of a simpler pattern than the molars, the posterior ones becoming tritubercular. The superior molars have quadrate crowns bearing four principal cusps, placed at each angle, to which are added several minor cusps, the rudiments of structures which assume considerable importance in the later and more specialized genera. The four principal cusps are the usual ones of the quadritubercular molar, two external and two internal, and are low, more or less conic, obtuse structures. Between the outer and inner ones are two isolated tubercles, which are later developed into cross-ridges connecting the outer and inner cusps, thereby producing the lophodont molar which is so characteristic of some groups of the ungulates. At a point midway between the two outer cusps, on the external margin of the crown, the cingulum is produced into a small tubercle, which in most of the specialized ungulates becomes connected with and unites the two Vs formed by the crescentic structure of the two external cusps, just as in some of the insectivorous genera already described.

In the lower molars four tubercles are present, of which the postero-external is connected with the antero-internal by a well-marked ridge. The anterior basal lobe is reduced, but still present in the form of a low cingular ridge.

The molar teeth of this animal display a typical bunodont dentition, and upon a correct understanding of their organization depends a proper comprehension of all the succeeding specialized molars of this series. It is by simple additions to, and modifications of, the component lobes and crests of this pattern that all the complex ungulate molars have been produced; if the advocate of the evolution hypothesis had no other evi-

[1] See Prof. Cope's valuable memoir of this group, *American Naturalist* for August and September, 1884.

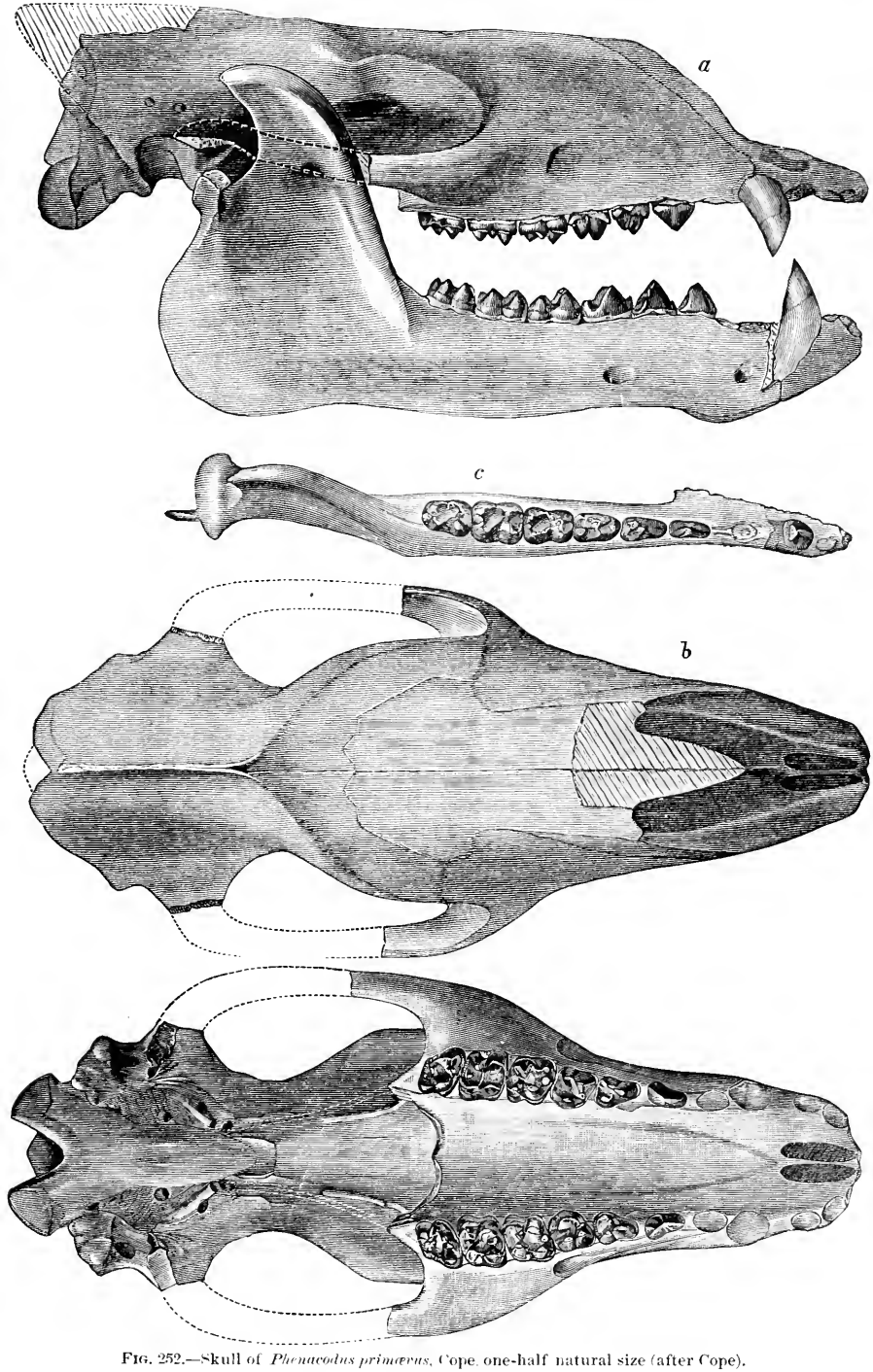

FIG. 252.—Skull of *Phenacodus primævus*, Cope, one-half natural size (after Cope).

dence upon which to base his belief than that afforded by the gradual complication of the molar teeth from this point upward in the hoofed

FIG. 253.

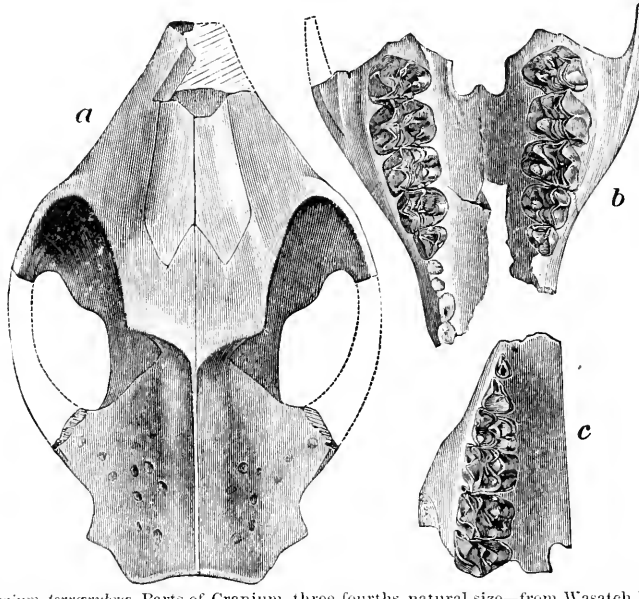

Meniscotherium terrærubræ, Parts of Cranium, three-fourths natural size—from Wasatch Beds of New Mexico: *a*, cranium from above; *b*, from below; *c*, portion of upper jaw, displaying deciduous molars (after Cope).

Mammalia, this alone, it appears to me, would be sufficient to gain for it a respectful consideration at the hands of its opponents.

FIG. 254.

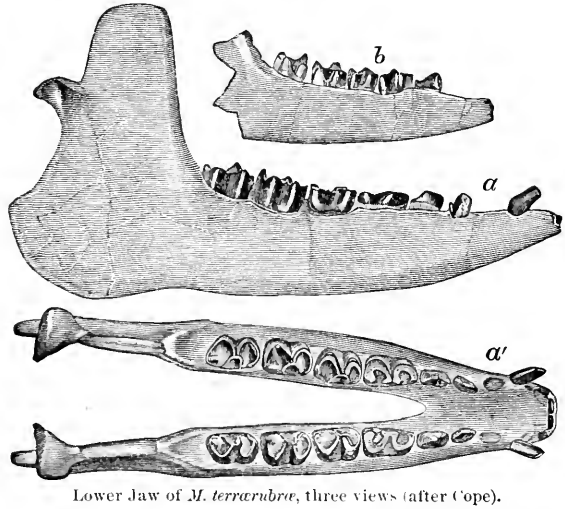

Lower Jaw of *M. terrærubræ*, three views (after Cope).

The last family of this sub-order is the *Meniscotheriidæ*, whose dentition is represented in Figs. 253, 254. The dental formula of the

single genus *Meniscotherium* is given by Cope as follows: I. $\frac{3}{3}$, C. $\frac{1}{1}$, Pm. $\frac{4}{4}$, M. $\frac{3}{3}=44$. As compared with *Phenacodus*, the canines are relatively smaller and the molars more complex; the same elements are readily recognized as in the molars of that genus, but the two external cusps are crescentic and elevated, the two contiguous horns being connected with the median external cusp, which now forms a vertical ridge or rib on the external part of the crown. The intermediate tubercles are also present, and are greatly enlarged; the anterior is crescentic and the posterior oblique and elongate. Of the two internal cusps, the anterior is conic, while the posterior is crescentic.

The lower molars exhibit two Vs, by reason of the development of cross-ridges connecting the external with the internal cusps and the increase in height of the oblique ridge. The tooth-line is uninterrupted by a diastema, and the incisors did not grow from persistent pulps.

The second sub-order, *Hyracoidea*, has long remained a puzzle to zoologists, and has been associated at different times near the rodents, at others with the perissodactyle ungulates, and latterly has been made the type of a distinct order. The discovery of the *Condylarthra* leaves no doubt of its relationship with these forms, and the propriety of making it a sub-order of the *Taxeopoda* is at once apparent. The dental formula of the two living genera, *Hyrax* and *Dendrohyrax*, is given, I. $\frac{2}{2}$, C. $\frac{0}{0}$, Pm. $\frac{4}{4}$, M. $\frac{3}{3}=36$, although DeBlainville in his figures of the different species represents some of them with only two incisors in the upper jaw instead of four.

The incisors grow from persistent pulps and have large pointed crowns; the canines are entirely absent from both jaws; the molars and premolars have complex crowns—in one genus, *Hyrax*, being almost identical with those of the rhinoceros; on account of this complexity Cuvier placed it in the same group with that animal. In the other genus, *Dendrohyrax*, the molar teeth are quite different, and upon careful comparison with those of *Meniscotherium* betray unmistakable evidence of near relationship. This resemblance is not confined to the molar teeth alone, but is strikingly shown in the general form of the skull, and especially in the great enlargement of the angular portion of the mandible. The upper molars of this genus (Fig. 255),[1] like *Meniscotherium*, have two crescentic external cusps connected by a vertical rib, and two intermediate tubercles, which are more or less blended with the two internal cusps, while the lower molars have essentially the same pattern as those of this genus. The whole structure of the molars represents just such an advance over that of the extinct Eocene genus as we should be led to anticipate on *a priori* grounds.

FIG. 255.

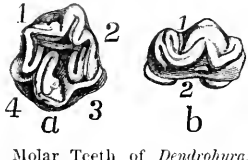

Molar Teeth of *Dendrohyrax arboreus*, vertical view: *a*, superior molar; 1, external, 2, anterior, 3, internal, and 4, posterior surfaces of crown; *b*, inferior molar; 1, external, 2, internal surfaces (after De Blainville).

It is true that the canines are absent in *Dendrohyrax*, and incisors grow from persistent pulps; but this is not at all remarkable when we consider the great interval of time between them and an approach to this condition, as far as the canines are concerned, in their reduced size,

[1] This figure does not represent the structure of the grinding face very clearly.

in the extinct genus. Altogether, I am disposed to regard *Meniscotherium* as the direct ancestor of the *Hyracoidea*, notwithstanding their wide separation in both time and space.

As a further complication in the molar pattern of this line, we have the complete fusion of the intermediate tubercles with the internal cusps in *Hyrax*, which, as already stated, gives the pattern of the molars of the rhinoceros.

It is believed by Cope, from evidence afforded by the structure of the limbs, that the *Toxodontia*, a group of curious extinct ungulate forms found in the later geological horizons of South America, belong to this order. I am unable to find any confirmation of this position from a study of the teeth, but it may be that they have been derived from a condylarthrous source.[1]

The dentition of the typical genus *Toxodon* contains incisors, premolars, and molars only, the canines being absent, and all were of persistent growth. The two pairs of incisors above are large and scalpriform, as in the rodents, of which the outer greatly exceed the mesial pair in size. In the lower jaw these teeth are three in number upon each side, and were also of persistent growth. They are subequal in size, and have imperfectly prismatic crowns similar in shape to the tusks of the boar in transverse section, being covered with enamel only upon the anterior convex surface.

The molars, of which there are seven upon each side above, gradually increase in size from the first to the last. It is highly probable that the first four of these teeth are premolars, but in the absence of any knowledge of the milk dentition and the manner of its replacement, this, of course, is inferential. They have remarkably long crowns, with an altogether unique pattern, and did not develop roots. In section they are triangular, with the apex of the triangle directed forward and outward. Upon the inner side there is a deep indentation or fold reaching to a point near the centre of the crown, which may be the valley separating the two internal cusps. The only arrangement similar to this is seen in the last upper molars of many of the Ungulata, of which *Meniscotherium* furnishes an average example. Here the postero-internal cusp is absent, and the two outer cusps are intimately blended. In the rhinoceros (Fig. 257) the last molar goes even further in this direction by reason of the fusion of the elements and the obliteration of the external rib. It is conceivable that some such structure as this preceded the present one in *Toxodon*, but until the palæontological evidence of the philogeny of this group is more fully known this is the only explanation which can now be offered to account for their aberrant pattern. The pattern of the lower molars is very like that of *Meniscotherium*—a fact which lends countenance to the above hypothesis.

Teeth of the True Ungulata.—This order includes nearly all the modern and many extinct ungulate animals, and is conspicuously distinguished from all other hoofed forms by the interlocking character of the proximal and distal rows of the carpal and tarsal bones. Cope has called it the *Diplarthra*, in allusion to the double articular surface afforded by the ankle-bone (astragalus) to the cuboid and navicular below,

[1] I have elsewhere spoken of their relationship to the *Tillodontia*.

whereas in the *Condylarthra* the astragalus articulates distally with the navicular or scaphoid only—a condition which obtains in nearly all Mammalia. Two prominent divisions of this order can be recognized —the *Artiodactyla*, or "split hoofs," of which the hog, cow, and deer, etc. are familiar examples, and the *Perissodactyla*, whose only living representatives are the horse, tapir, and rhinoceros.

The latter sub-order is divisible into a number of sections, which, when we consider the extinct forms constituting at least nine-tenths of the species, we are not able to separate by any characters of very great anatomical importance, notwithstanding the fact that the extremes of the several stems are different enough. That family which stands nearest to the *Condylarthra* is the *Lophiodontidæ*, a group of extinct generalized perissodactyls from the Middle and Lower Eocene beds. The digital formula is not so great as in the *Condylarthra*, being only 4—3, and in one instance 3—3; that is to say, four toes on the anterior and three on the posterior limbs.[1]

Hyracotherium (Fig. 256) is a typical example of this family, or at

Fig. 256.

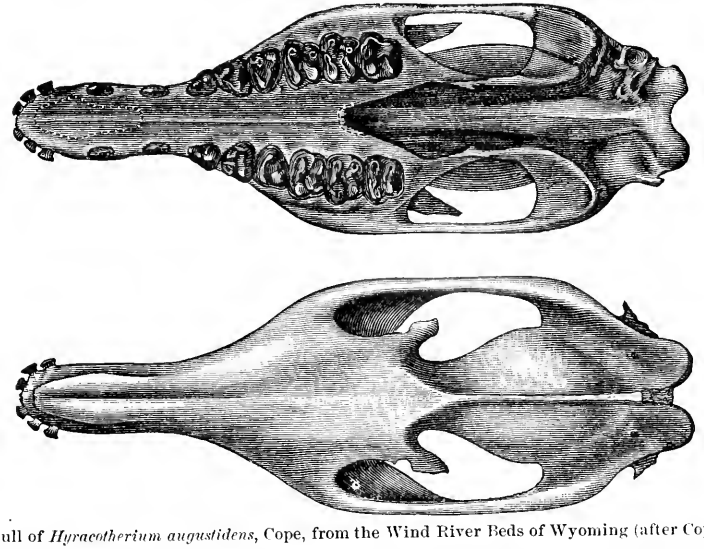

Skull of *Hyracotherium augustidens*, Cope, from the Wind River Beds of Wyoming (after Cope).

least that section of it whose dentition approaches nearest to *Phenacodus;* and if it were not known that the carpal and tarsal articulations were different, they might easily be mistaken for the same family, so great is the resemblance of their teeth. The dental formula of this animal is I. $\frac{3}{3}$, C. $\frac{1}{1}$, Pm. $\frac{4}{4}$, M. $\frac{3}{3} = 44$, the same as *Phenacodus*. The premolars are different from the molars, being simpler in form, and the first in both jaws is separated from the others by a diastema. The molar pat-

[1] Prof. Marsh has described several genera of this group, which he has called *Eohippus*, *Orohippus*, etc., but the descriptions are so brief that it is impossible to form any correct estimate of their true relationship. *Eohippus*, he says, has five toes, but further than this its osteology has not been described. It would be interesting to know in what respects it differs from the phenacodonts, *Hyracotherium*, *Pliolophus*, etc.

tern is substantially the same as in *Phenacodus*, with the slight exception that the cusps are more elevated and laterally flattened, and the external rib is very small or absent in *Hyracotherium*. In the nearly allied genus *Pliolophus*, which I suspect to be the same as *Orohippus* of Marsh, the last or fourth premolar below is like the true molars in form, and is quadritubercular, while the genus *Lophiotherium* has the third and fourth premolars below, like the true molars.

In the second section of this family the external lobes of the superior molars are laterally flattened and intimately blended together, so as not to be well distinguished. Of these the anterior is much the smaller, and is convex externally, whereas the posterior is large and concave without. The intermediate tubercles no longer exist as such, but form prominent crests which connect the external with the internal cusps, crossing the crown somewhat obliquely. In the lower molars the external and internal cusps are also connected by crests, giving the typical lophodont pattern. As a rule, the premolars are trilobed, and the molar formula is Pm. $\frac{4}{4}$, M. $\frac{3}{3}$, but in one genus (*Dilophodon*), recently described by Prof. Scott, there are only three premolars in the lower jaw. In another genus, lately described by the same author under the name of *Desmatotherium*, the third and fourth upper premolars are like the molars, and are four-lobed.

The tapirs form another nearly related family (*Tapiridæ*), which no doubt sprang from some member of the preceding group. The incisors and canines are like those of the *Lophiodontidæ*, but the canines in the lower jaw of the living forms are somewhat procumbent. The third and fourth premolars in the upper jaw are like the true molars, which display the four cusps connected by cross-ridges remarkable for their transverse direction in contrast with the oblique crests of some of the preceding family. The two external lobes are likewise different in their subequal proportions, both being convex externally and well separated from each other.

The lower premolars except the first are like the molars. The external and internal lobes are connected by strong cross-crests, which are as much elevated as the cusps themselves, and there is no ridge crossing from the postero-external to the antero-internal lobe, as in *Hyracotherium* and *Phenacodus*.

From this family we pass to the rhinoceros section of the sub-order. In accordance with what the philosophic student of the living forms would be led to anticipate, this section pertains to a later geologic period than the preceding, and not unnaturally would he seek for the connecting links between them and that section of the *Lophiodontidæ*, in which the external lobes are flattened. Through the researches of American palæontologists we are now in a position to fully comprehend all the more important steps in the evolution of this group, and I fail to recall in the whole range of vertebrate palæontology an instance in which the demands of the evolution hypothesis are more completely satisfied than in the present one.

The molar formula of the rhinoceros is Pm. $\frac{4}{4}$, M. $\frac{3}{3}$, the usual number in perissodactyles; but, as regards the incisors and canines, the greatest variability is to be observed. In the two-horned African species

neither canines nor incisors exist in the adult animal, they having completely disappeared in the course of development. On the other hand, in the remarkable and interesting Eocene genus *Orthocynodon* of Scott and Osborn,[1] the canines are of normal size and erect in position, as the name implies. The number of incisors has not been definitely determined, owing to the imperfect condition of the single specimen

FIG. 257.

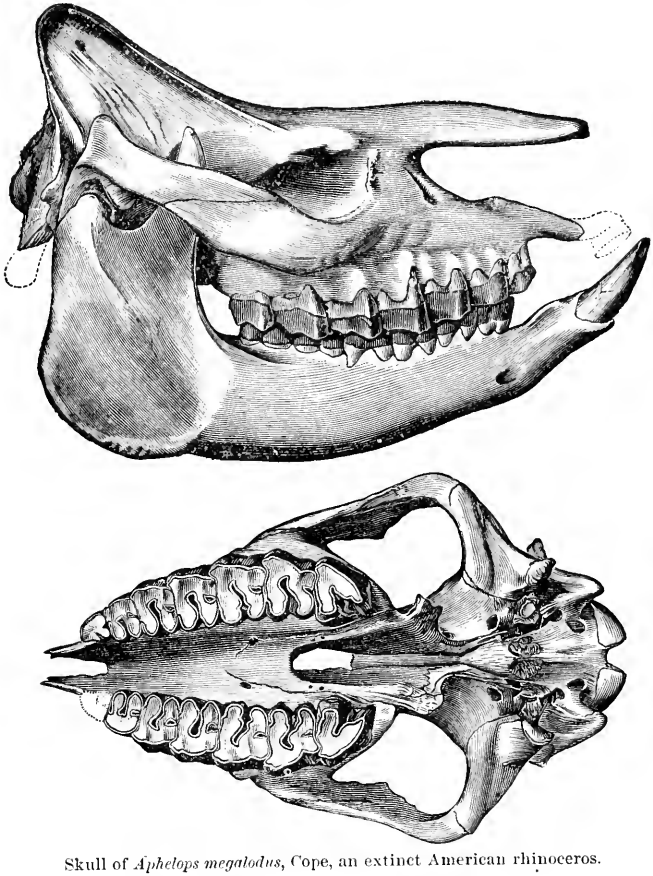

Skull of *Aphelops megalodus*, Cope, an extinct American rhinoceros.

known, but it certainly had two, and probably three, in the lower jaw, as there is abundance of room between the canine and the second incisor for another tooth. If the number is three in the lower jaw, it would imply a like number in the upper, which would bring it very near to the *Lophiodontidæ*. From this condition of the dentition, which is very nearly that of the *Lophiodontidæ*, we pass to the genus *Amynodon* of Prof. Marsh, in which the lower canine is much smaller and procumbent, with the incisors reduced to two pairs in each jaw. Following this

[1] See *Bulletin No. 3 Contributions* from E. M. Museum of Geology and Archæology of Princeton College, May, 1883.

genus in time comes the Lower Miocene representative *Aceratherium*, in which the incisors are two upon each side in the upper and one in the lower jaw, with the upper canine absent. The Middle Miocene furnishes a genus, *Ceratorhinus*, in which the incisors are one upon each side above and below, and a canine in the lower jaw only. Finally, we have a complete disappearance of both incisors and canines in some species now living. The reduction of the incisors and canines from *Orthocynodon* to *Cœlodonta*, a living species, can be summarized as follows: I. $\frac{3}{3}$, C. $\frac{1}{1}$, *Orthocynodon*; I. $\frac{2}{2}$, C. $\frac{1}{1}$, *Amynodon*; I. $\frac{2}{1}$, C. $\frac{0}{1}$, *Aceratherium*; I. $\frac{1}{1}$, C. $\frac{0}{1}$, *Ceratorhinus*; I. $\frac{0}{0}$, C. $\frac{0}{0}$, *Cœlodonta*.

FIG. 258.

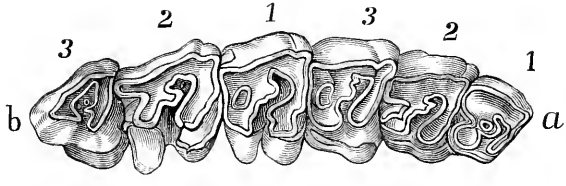

Superior Molar Dentition of Rhinoceros: *a*, anterior; *b*, posterior end of series. The figures 1, 2, 3 indicate molars and premolars.

In the earliest forms the molars are more complex than the premolars, but in the later and living species the premolars are as highly organized as the molars, and like them in form; this is well shown in the accompanying figure.

About twelve genera have been described, seven of which come from the fossil beds of North America. Through *Orthocynodon*, as was pointed out by Profs. Scott and Osborn, they inosculate with the *Lophiodontidæ*, after which they branch into several distinct lines. While the rhinoceroses have perpetuated the type of molar which began with the last section of the lophiodonts, other forms inherited the pattern of the hyracotheroids, and from this point the dentition was gradually specialized, not so much through subtraction of the number of teeth as addition and complication of the different lobes and crests of the crowns of both molars and premolars. The culminating point of this line is found in the living horses.

The first step beyond *Hyracotherium* in this series is seen in the Eocene genus *Ectocion* of Cope, in which the external rib is better defined, the external cusps more crescentic, and the cusps and oblique ridge of the lower molars are more prominent. In the next geological stage (Upper Eocene) we meet with the family *Chalicotheriidæ*, abundantly represented in the Wind River deposits by the genus *Lambdotherium*, likewise described by Cope. In this form (Fig. 259) the external cusps of the upper molars are considerably elevated, of a crescentic form, and connected with an external median rib. The anterior cross-crest still has a tubercular form, while the posterior is crest-like and blended with the postero-internal lobe. The four cusps of the inferior molars are connected by cross-ridges and the oblique crest, so as to form two Vs, opening internally. The tooth here represented is the last one, which in many of the perissodactyls has a prominent heel (*h*). In this animal

the antero-internal cusp (*ai*) becomes bifid at its summit, and the anterior basal lobe (*k*) again assumes considerable importance.

Following the chalicotherioids, and as a probable derivative of them, we meet with the palæotherioids, in which the molar pattern makes a considerable advance in complexity over that of the preceding family, and the premolars are now like the molars. *Anchitherium* is a good representative of this group, and is here taken for illustration. This genus is of especial interest, in view of its ancestral relation with the horses; it is here that we get the first distinctive traces of equine peculiarities, although several genera intervene between it and the modern Equidæ or horses. The species were numerous, most of them equalling the sheep in size, and had three subequal toes on each foot. The incisors, as in all the preceding genera, are plain incisiform teeth, without the pits or "mark" found in the corresponding teeth of the horses. Well-developed canines are likewise present.

Fig. 259.

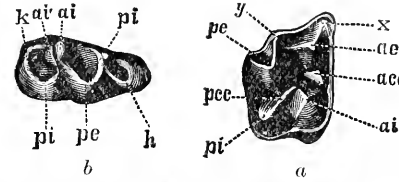

Upper and Lower Molar Teeth of *Lambdotherium*, vertical view, natural size: *a*, superior; *b*, last inferior molar. In the upper molar, *ae*, antero-external; *pe*, postero-external; *ai*, antero-internal; *pi*, postero-internal or principal cusps respectively; *y*, external vertical rib; *x*, an anterior cingular cusp; *acc–pcc*, anterior and posterior cross-crests. In the lower molar the principal cusps are lettered the same: *k*, anterior basal lobe; *ai'*, accessory cusp; *h*, heel.

The superior molars (Fig. 260) display the same elements as those of *Lambdotherium;* the external cusps are very much flattened and crescentic, having their vertical dimensions considerably augmented. The cross-crests form laminar ridges connected with the two internal cusps at the base, and separated from them above by open notches; they reach quite across the face of the crown. The two internal cusps almost equal the external ones in height, but have a more conical form; they are separated from each other by a deep fissure or valley opening internally. On the posterior border of the crown the cingulum develops an accessory cusp, which has a tendency to form a cross-crest in this situation and enclose a valley between it and the posterior cross-crest.

Fig. 260.

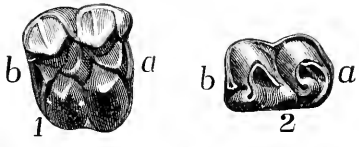

Upper and Lower Molars of Right Side of a species of *Anchitherium*: 1, upper; 2, lower tooth; *a*, anterior; *b*, posterior border.

In the molars of the lower jaw the same elevation of the lobes and crests is to be observed; their pattern is substantially that of *Lambdotherium.*

In a later geological epoch the genus *Hippotherium* carries dental modification a step farther toward that of the existing horses. The outer toes are much reduced, the incisors possess the peculiar pits of the horse, the molars are more complicated, and the entire appearance is decidedly equine. A strict comparison of the elements of the molars with those of *Anchitherium* is generally difficult, on account of the thick deposit of cement which fills up the valleys and spaces between them. To obviate this difficulty and bring out more clearly the relationship between them, I have represented in Fig. 261 an unworn molar in

which the cementum has been removed. Although the respective patterns are very much alike in their general structure, the differences consist in this: the external cusps of the superior molars are relatively larger, more perfectly crescentic, and strongly inclined inward in *Hippotherium*. The anterior cross-crest is better developed and joins the posterior cross-crest, so as to enclose a deep pit or valley between it and the antero-external cusp, which is filled with cement in the natural

FIG. 261.

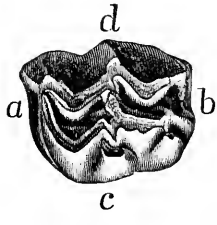

A Superior Molar Tooth of a species of *Hippotherium*, with cementum removed: *a*, anterior; *b*, posterior; *c*, internal; *d*, external borders. Vertical view, natural size.

FIG. 262.

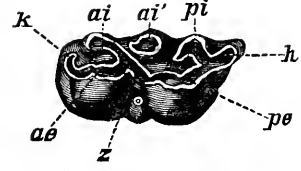

Lower Molar of same. Letters as in Fig. 259.

state; this is called the anterior lake in the worn tooth. The posterior cross-crest bends around to join the posterior cingular cusp, which, with the postero-external cusp, furnishes the boundary of the posterior lake. To these cross-crests are added a greater or lesser number of vertical folds, which give the borders of the lakes a crenate appearance when the crown is much worn. The internal cusps are relatively small, the posterior being connected with the corresponding cross-crest, the anterior isolated. To all these must be added the increased height and the presence of cementum.

The lower molars (Fig. 262) do not exhibit such marked difference from the *Anchitherium* type as do those above, but they are nevertheless more complex in their increased depth, complete isolation of the accessory antero-internal cusp, and the addition of cementum. The grinding surface of the teeth resulting from this arrangement of the enamel, dentine, and cement is kept constantly rough by reason of the inequalities in the rate of wear which these substances sustain during mastication. Coincident with this structure of the crown the roots disappear and the tooth grows continuously—a condition necessary to compensate for the great waste of the tooth-substance.

Lastly, we come to the modern horse, in which digital reduction has reached the extreme point in this series, or that furthest removed from the pentedactyle *Condylarthra*. As is well known, the digital formula in this family is $1-1$ in functional use, with the second and fourth represented by the rudimentary metapodials commonly known as the "splint bones."

The incisors are peculiar and characteristic, inasmuch as the working face is interrupted by a deep pit caused by the upward growth of the posterior cingulum. Previous to extrusion, the posterior wall of this cavity is incomplete and does not rise so high as the anterior.[1] After

[1] Ryder, "On the Origin and Homologies of the Incisors of the Horse," *Proc. Acad. Nat. Sci.*, Philada., 1877.

the tooth has been in use for a little while, however, the face is worn down smooth, and the central depression appears bounded by a layer of enamel, between which and the enamel covering the outer surface of

FIG. 263.

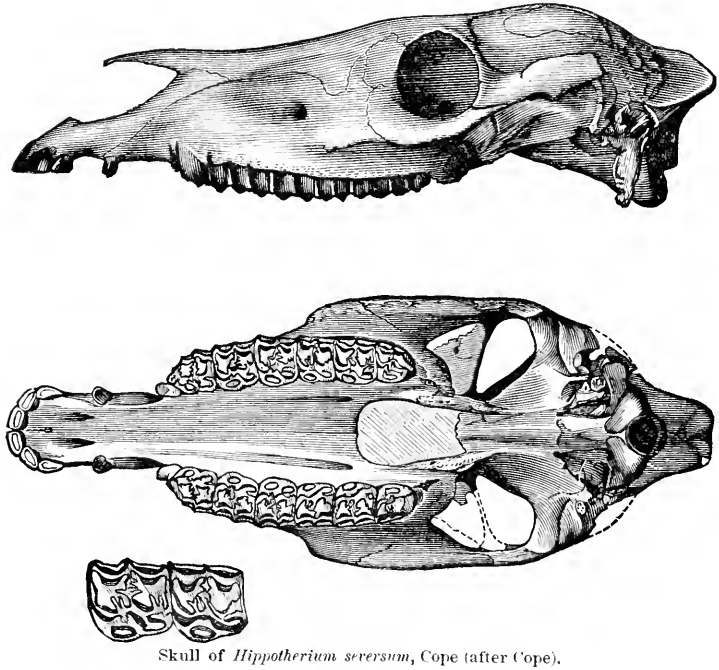

Skull of *Hippotherium seversum*, Cope (after Cope).

the tooth, may be seen the dentine. The incisors are not all cut at the same time, the last appearing at the age of five years, on account of which the central pit disappears through wear sooner in those teeth which are first extruded than those which are cut last. By observing carefully the date of appearance of the various incisors, and the consequent difference in time at which the pits are obliterated in the different teeth, veterinarians have established some very useful rules by which the age of a horse can be approximately told with considerable certainty up to ten or twelve years.

FIG. 264.

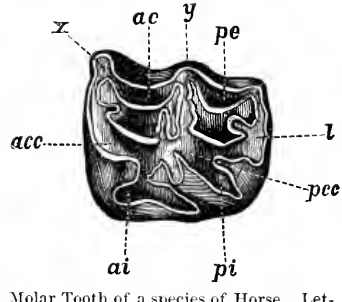

Molar Tooth of a species of Horse. Letters as in the preceding figures.

Canines, or the "bridle teeth," are present, but they are of smaller size, and sometimes disappear in the female. The first premolars in both jaws are normally absent, but there are many cases on record in which they are present. In *Hippotherium* they are normally present and functional.

The molars present essentially the same pattern as those of the preceding genus, the only difference of importance being found in the

enlargement of the antero-internal lobe and its connection by a ridge with its corresponding cross-crest. Some species of *Hippotherium* show a gradual advance from the conic isolated condition of this element to its enlarged and sub-connected form.

Thus it is that palæontology has enabled us to fully comprehend the different steps in the production of these complex and specialized organs from the simple bunodont pattern. To say that such evidence is without its special bearing on the great problem of biology, or that evolution or development has not taken place, is to deny the truth of the assertions herein made. Many intermediate steps between those given could be cited, but time and space have compelled me to limit the examples to the most salient.

The remaining perissodactyles exhibit different degrees of modification of the bunodont type, none having reached the same stage of perfection as the horse.

The second sub-order of the ungulates, *Artiodactyla*, attained its greatest development at a later geological period, and it is probably in the present epoch that the genera and species are the most numerous. A few genera are found in the Lower Eocene, but they are of rare occurrence as compared with the perissodactyles. It is probable that they two came off the condylarthrous stem, but the direct evidence to substantiate this supposition is wanting. They are primarily divisible into two groups, *Bunodontia* and *Selenodontia*, characterized by the pattern of the molar teeth and the consequent condition of the posterior termination of the maxillary bones. In the former division, of which the hog is an excellent example, the molars have approximately the same pattern as *Phenacodus;* the tooth-line is little curved, and the posterior extremity of the maxillary is applied closely to the palatine and pterygoid bones, whereas in the *Selenodontia* the molar teeth have crescentic cusps, and the posterior borders of the maxillaries are separated by a wide sinus from the palatines and pterygoids. These characters at first appear insignificant and inadequate to establish and define two such great groups as the foregoing; but when we remember that they express a very important structural modification, and that the two are correlated, we cease to express surprise.

Of these two divisions, the *Bunodontia* is the older, and as a consequence the more generalized. Their generalized characters are most conspicuously displayed in the increased number of digits, bunodont teeth, absence of horns, non-complexity of the stomach, and separate condition of all the limb bones. In fact, the suilline artiodactyles are as primitive in many respects as the *Condylarthra*, but in the arrangement of the carpal and tarsal elements they are specialized and far removed from their primitive ancestry.

In the hog the dental formula is I. $\frac{3}{3}$, C. $\frac{1}{1}$, Pm. $\frac{4}{4}$, M. $\frac{3}{3} = 44$. The outer pair of incisors are small, and sometimes fall out in old age. The canines are relatively large—disproportionally so in the male—and in the upper jaw curve round in such a manner that the point of the crown is directed upward. The enamel of these teeth does not uniformly invest the crown, but is disposed in three bands corresponding with its trihedral form. The canines of the lower jaw are more slender and

have a normal direction. It is said that castration arrests the excessive development of the tusks of the boar, just as this operation profoundly affects the growth of the antlers of the deer—a circumstance which at once relegates the cause of this condition to sexual influences.

The first premolar has no deciduous predecessor, and disappears soon after the adult stage is reached. The rest of the premolars increase in complexity and size from front to rear, but none of them are quadritubercular. The first and second molars are quadrate in section, with four-lobed crowns. The last molar is greatly elongated in an antero-posterior direction, which is occasioned by the possession of an enormous heel, much as in the bears, and its crown, as in the others, besides presenting the normal four cusps, has an immense number of subsidiary tubercles, giving to it a decidedly wrinkled appearance.

In the wart-hogs (*Phacochœrus*) a very peculiar modification of the molar pattern is to be seen in the last tooth. In the unworn state the crown of this tooth presents about thirty small tubercles, arranged in three rows in a direction longitudinal to the axis of the body, the intermediate spaces between them being occupied by cementum. When wear takes place, the summits of these cusps are abraded, leaving as many little dentine islands bordered by enamel; they are strengthened by the addition of cement.

The canines are of enormous size, devoid of enamel, and grow from persistent pulps; the superior ones are directed upward at first, piercing the upper lip, and then curve backward toward the eye; their length is sometimes as much as eight or ten inches. All the molar teeth are generally shed in old age, with the exception of the fourth premolar and the last true molar, so that the molar dentition is practically reduced at this time to four upon each side in both jaws, and is the only case of the kind known in the Mammalia.

The peccaries constitute another family of this division, and are known from the lowest Miocene, if not from the Upper Eocene deposits. Their molar dentition is more nearly like that of the *Condylarthra* and primitive perissodactyles than other suillines, lacking, as a rule, the great development of the minor tubercles of the molars of the hog as well as the elongated heel of the tooth. The canines, moreover, are normal in direction, and the great disparity in size between these teeth does not exist in the sexes. The incisors are of the usual pattern, although the outer pair is absent from both jaws in some genera.

From this family the transition is easy to the earlier forms of the selenodonts, in which the feet were multidactyle; in one genus, *Oreodon*, as has been recently shown by Prof. W. B. Scott, the anterior limb was provided with the normal number of toes, five. That family, which almost completely bridges the chasm between these divisions, is the extinct *Anthracotheridæ*, whose remains are abundant in the Miocene strata of Europe, but less so in this country.

It is somewhat uncertain how many genera should be referred to this family, and by what character or characters it should be defined. *Palæochœrus*, which by common consent is a suilline, has four lobes upon the crowns of the superior molars, which are conic and not connected with an external rib, together with two small intermediate cusps, repre-

senting the cross-crests very much as in *Phenacodus*. *Chœropotamus*, another genus from the Eocene of France, is altogether intermediate between *Palæochœrus* and *Anthracotherium*, the typical representative of this family, in the pattern of the superior molars; the external cusps are somewhat crescentic, but the external rib is rudimentary or absent. In the first molar the anterior of the two intermediate tubercles only is present, while in the other two molars it is very small and insignificant; the two internal lobes are conic.

Following this genus in time come *Anthracotherium*, *Hyopotamus*,[1] *Ancodus*, and others in which the anterior of the two intermediate tubercles is the only one which is present in the upper molars. This character, I am therefore disposed to believe, defines a natural group, and should, in connection with the external rib and crescentic form of the external cusps, be the test of limitation of this family.

Two derivatives of the Eocene *Hyopotami*, *Xiphodon*, and *Anoplotherium* soon became specialized in their limb structure, but, strangely enough, disappeared in the Early Miocene. Another line was commenced contemporaneously with that of the anthracotheroid in the genus *Dichobune*, wherein the *posterior* intermediate tubercle only was retained. It continues forward through the genus *Cainotherium* into the Upper Miocene deposits of Sansan, where it gradually faded from existence, leaving no modified descendants. This, it appears to me, constitutes another family, definable by the above character.

From the *Anthracotheridæ* have sprung all the modern artiodactyles, with the possible exception of the cameloids and the existing suillines, together with other stems which are extinct. Many extinct genera complete the connections with the living forms in all the osteological and dental details, which it is scarcely within the scope of the present article to discuss.

In the production of a perfected double crescentic pattern of the superior molars in this sub-order from the short-crowned semi-bunodont anthracotheroids, the anterior intermediate tubercle has gradually usurped the function of the true antero-internal cusp, it having been reduced to a small cusp situated internal to the mesial horns of the inner crescents on the inner basal portion of the crown (see Fig. 265).[2]

Specialization of the dental organs of the *Selenodontia* is seen in the following characters: (1) Formation of double crescents in the superior and inferior molars; (2) great elevation of the cusps and deposit of a thick layer of cementum, filling up the valleys; (3) loss of the roots of the molars and premolars, and their growth from persistent pulps; (4) reduction of the premolars to three in each jaw; (5) subtraction of the canines and incisors from the upper jaw; (6) the reduction in size and approximation of the lower canine to the incisors; and finally (7), the

[1] Gaudry places the appearance of this genus in the sands of Beauchamp, which probably corresponds with our Bridger Beds or Upper Eocene. He also fixes the date of appearance of *Palæochœrus* in Europe in the deposits of Saint-Geraud-le-Puy, Middle Miocene. In this country *Hyopotamus* does not appear until the Lower Miocene, whereas *Palæochœrus* probably extends into the Bridger epoch.

[2] For a further knowledge of the fossil forms of these families the reader is referred to the important work of Prof. Albert Gaudry, "Les Enchainements du Monde animal dans les Temps géologiques," in which the more important genera are figured.

FIG. 265.

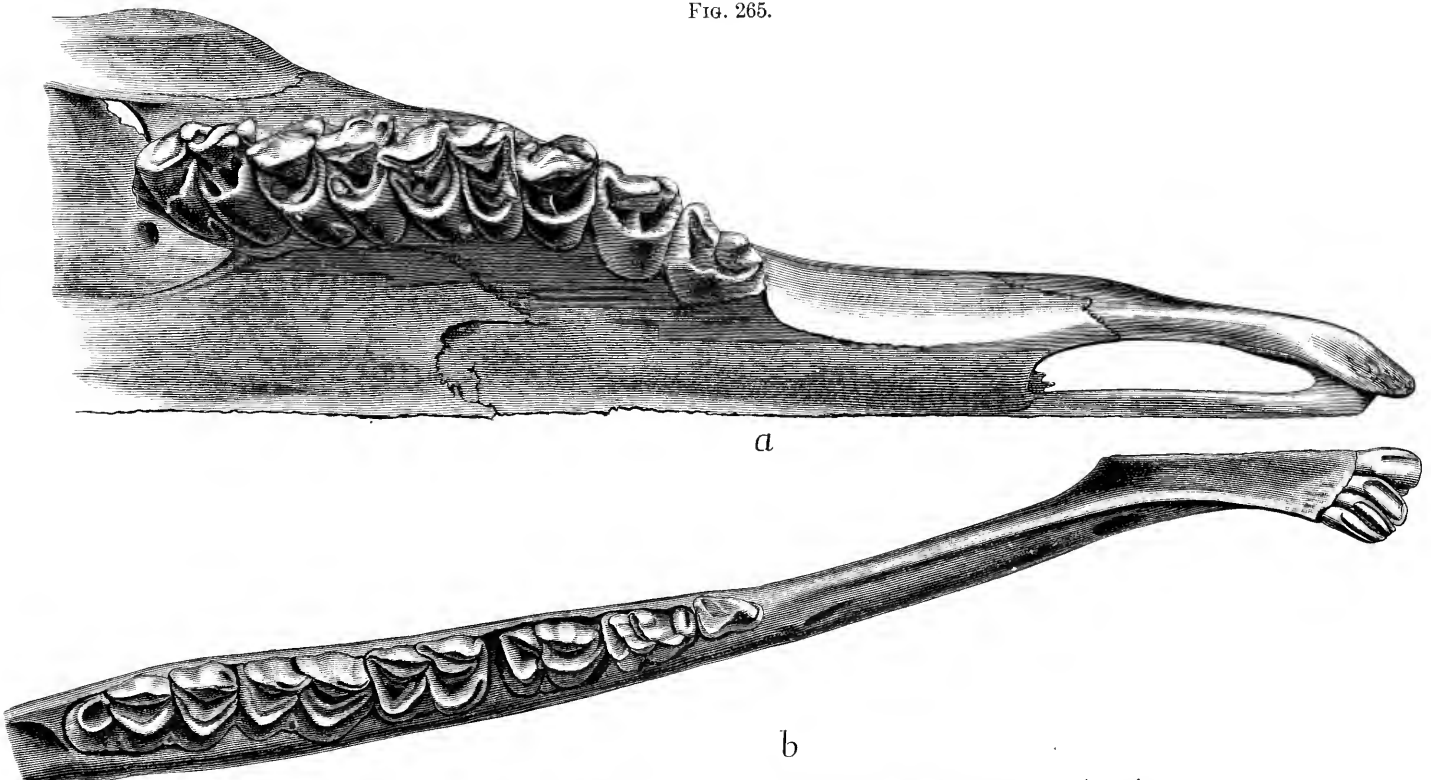

Vertical View of an Upper and a Lower Jaw of Virginia Deer (*Cariacus virginianus*): *a* upper, *b*, lower jaw.

development of a long diastema in front of the premolars. While the complete assumption of these characters is reached only in the bovine ruminants, others exhibit all the intermediate stages of modification tending in that direction.

The common Virginia deer (*Cariacus virginianus*) has been selected as an average example of the higher selenodont dentition; although in its family (Cervidæ) canines are sometimes found in the upper jaw, there is little or no cementum on the crowns of the molars, and they have well-defined roots. It will therefore be observed that it does not fulfil all the requirements of the most highly specialized selenodonts in its dental organization. The dental formula of this species (Fig. 265) is I. $\frac{0}{3}$, C. $\frac{0}{1}$, Pm. $\frac{3}{3}$, M. $\frac{3}{3} = 32$. The incisors have long spatulate crowns, the median pair being the larger, the outer ones decreasing gradually in size. The canines are smaller than the outer pair of incisors, which they resemble very much in shape, being applied closely to them. After an immense interval follow the premolars, the first two in the lower jaw being comparatively simple, the third four-lobed like the succeeding molars. The molars display two perfect double crescents, of which the outer are convex externally. The last molar has a fifth lobe. In the upper jaw the premolars are bilobed, the internal being convex internally and enclosing a deep valley between it and the external cusp. The true molars have double crescents enclosing two valleys. The antero-internal of these crescents is made up of the anterior intermediate tubercle, which has become greatly enlarged and developed into a crescentic form, the true antero-internal cusp being situated internal to and behind it. The proper evidence to support this determination is to be found by examining the superior molars of *Hyopotamus*, *Anoplotherium*, and *Xiphodon*, in which it will be seen that the antero-internal cusp becomes gradually smaller.

Teeth of the Proboscidea.

The last order of the ungulate series whose dental organs remain to be noticed is that including the elephants, mastodons, etc. The animals composing this group are the largest of terrestrial mammals, and display many curious modifications of the primitive ungulate type. Probably no part of their organization has been more profoundly affected in their gradual evolutionary growth than the teeth, and were it not for the fact that abundant evidence is at hand to demonstrate the successive steps in the progressive modification from a more simple type, we would be at a loss to comprehend the manner of production of these most complex of all teeth.

Two genera of proboscideans are found in the existing faunæ of Asia and Africa, but these are only the inconsiderable remnant of a once greater and much more widely distributed representation, as is indicated by their fossil remains. During the later Tertiaries proboscideans were not unknown in both the northern and southern hemispheres in all the extensive land-areas; in some parts of the northern hemisphere, where they are now extinct, judging from their fossil remains immense herds and droves must have at one time existed.

In the African elephant (*Loxodon africanus*) the dental formula is I. $\frac{1}{0}$, C. $\frac{0}{0}$, Pm. and M. $\frac{6}{6}$. The two incisors are greatly enlarged, implanted in deep sockets, and grow from persistent pulps. They are preceded by small deciduous teeth, and when first protruded are tipped with enamel, which soon wears off. The tooth then consists mainly of dentine covered by a thin layer of cement, the dentine presenting a slightly modified form known as "ivory." This substance, as is well known, is extensively used in the arts and has a fixed commercial value. Although not exclusively confined to the tusks of the elephant, nevertheless the chief source of supply of this material is derived from them. Tomes cites an example in which a pair of tusks of this species were exhibited in England that weighed three hundred and twenty-five pounds and measured eight feet six inches in length and twenty-two inches in circumference; the average weight, however, does not exceed from twenty to fifty pounds. The female of this species has tusks quite as large as the male, but in the Indian species the tusks of the male exceed those of the female in size.

The molar teeth of the living elephants are very much alike in general pattern and mode of replacement, which is unique; the description of one will therefore suffice to convey an intelligent understanding of the entire subject.

Both existing species have a molar formula of $\frac{6}{6}$, which are divided into milk molars $\frac{3}{3}$, true molars $\frac{3}{3}$. There is sometimes, in addition to these, a small rudimentary milk molar in front, which increases the total number to seven upon either side in each jaw.

Although the total number of molars is normal or nearly so, they are not all in place nor in existence at the same time. Barring the occasional rudimentary one, the first molar in the Indian species cuts the gum at a considerable distance from the front of the jaw about the second week after birth. It is implanted by two fangs, and displays a subcompressed crown bearing four cross-ridges, and is therefore lophodont in pattern. The upper tooth corresponding to this one cuts the gum a little earlier, and possesses five cross-crests. These teeth are shed at about the age of two years.

Before the disappearance of the first two teeth the second molars come into place from behind. They are considerably larger than the first, being on an average two and a half inches in length by one inch in breadth. Their crowns are of similar form, but have the number of cross-ridges increased to eight or nine. They are implanted by two fangs, and are shed before the beginning of the sixth year.

By the time the second molar has been worn out the third molar, averaging four inches in length by two in breadth, makes its appearance. Its crown has from eleven to thirteen cross-plates on its working face, and is also supported by two fangs, of which the posterior is much the larger. It is said to be worn out and shed about the ninth year.

The teeth so far enumerated are taken to be homologous with the second, third, and fourth milk molars of the ordinary diphyodont dentition, which have in this case failed to develop permanent successors. This conclusion is rendered reasonably certain, as we shall presently see, by the fact that their ancestors had a more or less complete permanent

premolar system, which underwent progressive subtraction as they approached the modern proboscideans.

Three teeth which are homologous with the permanent true molars are developed behind these in a similar manner. They increase in size and complexity from before backward: the first, or fourth of the entire series, bears fifteen or sixteen plates; the second has from seventeen to twenty plates; while the last supports from twenty to twenty-five. The first true molar disappears between the twentieth and twenty-fifth years of the animal's life, the second somewhere about the sixtieth, while the last is retained until the termination of the animal's natural existence, which is said to be more than one hundred years.

The structure of these teeth is complex, and, as we have said on a former page, resembles that of some of the hystricine rodents, such as the capybara, for example. The cross-ridges near their summits are broken up into a number of conical projections, which, when abrasion first takes place, present so many dentine islands surrounded by a rim of enamel: these are arranged in rows across the face of the crown in the position of the future plate (see Fig. 266). As wear goes on these islands unite

FIG. 266.

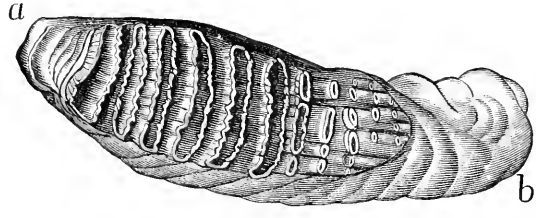

Molar Teeth of Indian Elephant (*Elephas indicus*), after Tomes: *a*, anterior; *b*, posterior border.

below, and form transverse lamellæ composed of a narrow strip of dentine surrounded by enamel. Between these much-elongated lamellæ, which are all blended together at the base of the crown, a thick deposit of cementum is found; it also invests the lateral surfaces of the crown and prevents fracture of the cross-plates.

In the growth of the tooth the anterior plates or crests are first formed, and come into position and use long before the posterior. As a consequence of this, the most anterior plates wear out and disappear while the posterior ones are still being formed. This is well shown in the accompanying figure. As new plates are added from behind, the whole tooth moves forward, which probably exerts some influence in the removal of the tooth in front of it. Finally, before the tooth disappears altogether, it presents an oval area of smooth dentine surrounded by enamel and cementum. It is then no longer efficient as a grinding organ, and is consequently discarded.

It will be seen by this arrangement of the three tooth-substances on the working surface of the crown, and by reason of the varying rate of their wear, the teeth of the two jaws when brought into opposition afford most perfect machinery for the grinding up of the coarse herbaceous substances upon which the elephant feeds.

The two genera of existing proboscideans may be readily distinguished

by the character of the plates of the molar teeth. In the African species they are fewer in number on the corresponding teeth than in the Indian, and they have a distinct lozenge-shaped pattern upon cross-section, whereas in the Indian species they present an oval outline upon cross-section and the enamel border is crenate. In the number and succession of the teeth the two genera are alike.

The genus *Deinotherium* includes a few species whose remains have been found in the Miocene deposits of Europe, and which were but little if any inferior to the living proboscideans in bodily proportions. They are the oldest representatives of this order so far discovered, and especial interest attaches to their teeth, inasmuch as their structure furnishes a clue to a more perfect understanding of the later and more complex types.

The premaxillary bones were edentulous, but the front part of the lower jaw was provided with two large decurved tusks. What particular use the animal made of these teeth is difficult to imagine. The molar formula is Pm. $\frac{2}{2}$, M. $\frac{3}{3}$. The structure of these teeth is not very different from that of the tapir, consisting of a moderately short crown bearing two or three cross-crests. Both the premolars had deciduous predecessors, just as in the diphyodonts generally. These animals, however, were very elephantine in every other feature of their anatomy, and were in all probability provided with a trunk.

From this condition of the dental organs we pass to the mastodons, in which there is a marked approach to the elephants. In some species there were two tusks in each jaw, but the lower ones were small, and in many cases disappeared early in life. The molars increase in complexity and size from before backward, the posterior ones bearing in some species as many as ten cross-crests, which were unsupported by a cementum deposit; in others the cross-ridges are much fewer in number. Many species are known, and when all are considered a complete transition between the comparatively simple lophodont and the extreme lamellate patterns is afforded. Many of them had deciduous teeth, which were vertically succeeded by two, and probably three, permanent premolars. As the elephantine molar pattern was acquired, however, these were gradually lost.

Altogether, it is impossible for a student of odontography to study carefully the teeth of this order, and not be thoroughly convinced in the end that the complex pattern has gradually, but none the less certainly, arisen from the simpler one. If this, therefore, is true of one series, it must be of all.

The Amblypoda.

Another order of hoofed mammals which became extinct at the close of the Eocene Period has been described from the fossil-bearing deposits of this country. They were mostly of gigantic proportions, and exhibit affinities with both the proboscideans and the Perissodactyla. They are most nearly related, however, to the Toxeopoda, with which they were contemporary in the Eocene.

Nearly all of them have the full complement of incisors, canines, pre-

FIG. 267.

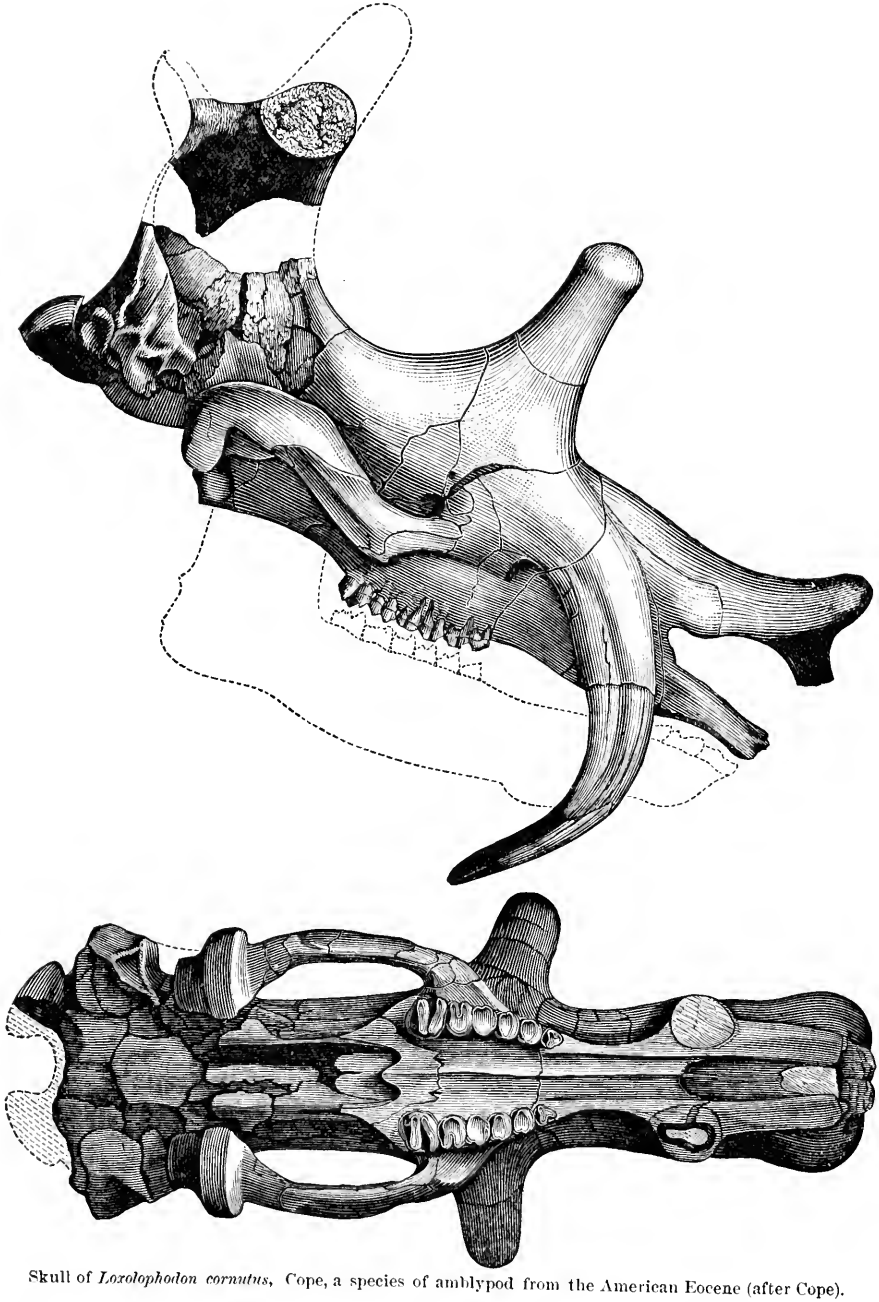

Skull of *Loxolophodon cornutus*, Cope, a species of amblypod from the American Eocene (after Cope).

molars, and molars, and in some the canines were greatly enlarged. The molar pattern is of moderate complexity, and shows a considerable

departure from the primitive tritubercular ancestry. In the lower jaw the molars are lophodont, while in the upper they have a single crescent of moderate perfection. Owing to their near relationship with the Toxcopoda, it is highly probable that their teeth represent an extreme modification of the tritubercular pattern, but of the different steps in their production lack of space prevents me from speaking here. I must refer the reader to the papers of Profs. Cope and Marsh for a more complete description of the dentition of this order.

Teeth of the Marsupials.

I have indicated on a preceding page that this division of the Mammalia is sharply defined from the monodelphs by the circumstance that no connections are formed between the fœtal envelopes and the walls of the uterine cavity during gestation, so that no placenta is developed. They are therefore known as the implacental division of the *Eutheria;* they are likewise known as the *Didelphia* and *Marsupialia*. The young are born in an exceedingly helpless and imperfect condition, and are transferred to the pouch or marsupium of the mother, where, by a special arrangement, the nourishment is forced into their months until such time as they are enabled to help themselves.

In the majority of the lower Vertebrata very little development of the young takes place in the body-cavity of the mother; the ovum is relatively large, by reason of the addition of an abundant supply of pabulum sufficient to nourish the embryo until the later stages of development are reached. It has been recently ascertained that the monotremes reproduce in the same way; that is, they lay eggs like birds and reptiles, which are hatched in a similar manner. The whole plan of development moreover, is like that of the bird (mesoblastic)—a condition which would be reasonably suggested by a study of their reproductive system.

As the monotremes furnish the connecting link between the higher mammal and the reptile, so do the marsupials, as far as reproduction is concerned, afford a transitional stage between the monotremes and the monodelphs. For this reason we would naturally be led to look for primitive and transitional characters in their teeth. Unfortunately, these organs do not in many particulars go beyond the lowest forms of the monodelphs sufficiently to give us any clear insight into the intermediate structures and patterns which must have preceded the diphyodont monodelph dentition; still, some of the earliest representatives of mammalian existence which have been referred to in this group possess a greater number of heterodont molar and premolar teeth than any known mammal.

In the small living marsupial genus *Myrmecobius* the dental formula is I. $\frac{4}{3}$, C. $\frac{1}{1}$, Pm. $\frac{3}{3}$, M. $\frac{6}{6} = 54$. The incisors are small, subconic teeth, implanted in the premaxillary bones above, and followed by the canines, which have the usual laniary form. The premolars have laterally-compressed, unicuspid crowns, and are implanted by two roots. The molars exceed in number those of any other marsupial, reaching the unusual number of six in each jaw. Owing to the imperfect descriptions of

the crowns of these teeth, and never having seen a specimen myself, I am at present unable to say just what the pattern of the crown is. From the best information at my command I suppose it to be somewhat after the style of a modified tuberculo-sectorial. I further do not know whether the succession has been observed, and whether a proper distribution of the molars and premolars expressed in the above formula has been made; but, judging from the condition in marsupials generally, I am induced to believe it to be correct. It is so given by Owen and Waterhouse.

Some fragmentary remains, consisting principally of jaws and isolated teeth, of a number of small mammals have been discovered from time to time in the Jurassic and Triassic deposits of this country, Europe, and South Africa, in which the teeth behind the canines reach as high a number as twelve in each lower jaw in some species. These are somewhat arbitrarily divided into an equal number of molars and premolars, but whether any or all of them had deciduous predecessors is not known. The reason for this division is that the first six behind the canine are premolariform in shape, while the others possess a number of sharp cusps. They have been referred to the marsupials and assigned a position near to *Myrmecobius*, but until their osteology is better known this is doubtful. Inasmuch as they are the oldest known mammals, we should anticipate on *a priori* grounds that they really belong to the monotremes instead of the marsupials. The great number of teeth certainly constitutes an approach to the Reptilia, and if they possessed a complete development of a second set, which is not at all improbable, the transition between reptile and mammal would be in a measure complete as regards the teeth.

Another strange and remarkable genus, *Plagiaulax*, together with a number of allies, comes from these ancient horizons. In this animal the molar pattern is complex for so early a representative of the Mammalia, and is difficult to understand. In the lower jaw of *Plagiaulax* there are seven teeth, of which the first is large, curved, and pointed, and is probably an incisor. This is followed after a considerable space by four teeth, all of which, except the first, are implanted by two roots and increase gradually in size. Their crowns are terminated superiorly by a wedge-shaped crest directed antero-posteriorly, which is rendered subserrate by the presence of a number of oblique vertical grooves. Behind these are two smaller teeth with tubercular crowns, which have been supposed to represent true molars.

The remaining marsupials which are really known to be such are divisible into the *Polyprotodontia*, or those of predaceous habits, having many incisors, and the *Diprotodontia*, vegetable feeders, having only two incisors, in the lower jaw. As far as dental characters go, they all agree in the possession of four true molars; there are never more than three premolars, and the deciduous molars, which are succeeded at a comparatively late period by the last premolars, are reduced to one in each jaw. This, therefore, furnishes another example wherein the definition of a premolar is violated.

Three families are included in the polyprotodont division, one of which, the opossums, is confined to North and South America, and the

other two to the continent of Australia. As the common Virginia opossum is a good representative of this division, it is here taken for illustration and description. The dental formula is I. $\frac{5}{4}$, C. $\frac{1}{1}$, Pm. $\frac{3}{3}$, M. $\frac{4}{4} = 50$. The incisors (Fig. 268) have a truncate cylindroid pattern,

FIG. 268.

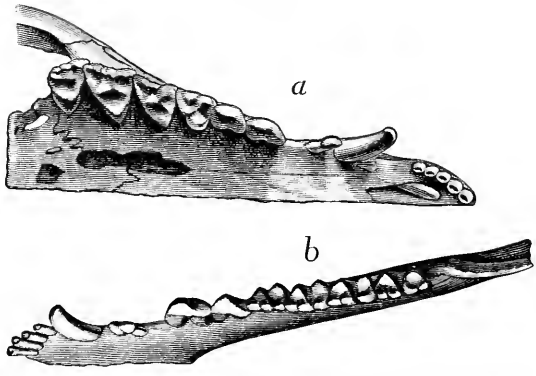

Dentition of Virginia Opossum (*Didelphis virginianus*): *a*, upper; *b*, lower jaw.

implated by single fangs, and differ considerably from the corresponding teeth of the carnivores, which they exceed in number by two upon each side in the upper, and by one upon each side in the lower, jaw. The canines have relatively the same size and form as in the dog, and indicate clearly the carnivorous habits of their possessor. The premolars are simple premolariform teeth implanted by two roots, the first being smallest and separated from the other two by a diastema.

The molars of the lower jaw are essentially tuberculo-sectorial in pattern, with the external cusp of the anterior triangle largest. The heel is tritubercular and of large size. The molars of the upper jaw are interesting, inasmuch as they furnish a transitional stage in the formation of the W pattern described in the moles, shrews, etc. The first molar has the following structure: The crown is triangular in transverse section, with the apex directed inward, at which is situated the antero-internal cusp or the one corresponding with the single internal tubercle of the tritubercular molar. At the antero-external angle is situated a cusp of moderate dimensions, which in perfectly unworn specimens is more or less blended with the cingulum; just internal to this, upon close inspection, can usually be seen the rudiment of another cusp, which becomes better defined in the second molar. The exact homologies of these two cusps are not clear, but it seems very probable that the external is of cingular origin, and that the one internal to it is the true homologue of the antero-external cusp of the tritubercular tooth. On the outer edge of the crown, posterior to the two just described, is another cusp, which disappears in the last two molars, but which is well defined in the first and second. This cusp is homologous with the one which terminates the median external part of the W in the molars of the shrew and mole. A little posterior to a line drawn between this last-mentioned cusp and the one most internal is another large well-defined tubercle, from which

a conspicuous ridge passes outward and backward to the produced postero-external angle of the crown.

It will thus be seen that all the requisite cusps are present in the first and second molars for the production of the W-structure, and that it would only require the presence of connecting ridges to complete it.

A distinctive characteristic of this, as well as most other marsupials, is seen in the strong inflection of the angle of the jaw and the vacuities caused by failure of ossification in the posterior part of the palatine bones.

Another family of this group includes the Phascogales, Tasmanian devil, the dog-headed opossum, etc. of the Australian continent and neighboring islands. This family is known to naturalists as the *Dasyuridæ*, and is distinguished from the opossums proper (*Didelphidæ*) by having the incisor formula $\frac{4}{3}$. In the genus *Phascogale* there are three premolars in the upper jaw and two in the lower; in *Dasyurus*, or the Tasmanian devil, there are only two premolars in each jaw, which number also obtains in the dog-headed opossum (*Thylacinus*).

The pattern of the molar teeth of this latter animal is very much like that of *Mesonyx*, consisting in the lower series of a principal cone, to which are added anterior and posterior basal cusps. The upper molars are tritubercular, as in that genus, but there is a considerable cingular ledge external to the two outer cusps.

The lower molars of the other two genera are very similar to those of the opossum, already described. The pattern of the upper molars of *Dasyurus* have been alluded to in connection with those of the shrew, and need no further description; those of *Phascogale* are essentially the same.

The bandicoots, constituting the family *Peramelidæ*, are distinguished by an incisor formula $\frac{5}{3}$. The canines are reduced, and placed relatively far back in the dentigerous border of the jaws. The molar and premolar formula is the same as in the opossum, and there is a similarity of pattern in the corresponding teeth of the two families.

In the second division, *Diprotodontia*, the incisors are reduced to two in the lower jaw; the canines are always small, and in many cases altogether wanting, while the molars are more complex, being better adapted to the mastication of a vegetable diet, upon which they principally feed.

The kangaroo furnishes a typical example of this group, and is here described. The dental formula of Bennett's wallaby (*Halmaturus bennetti*) is I. $\frac{3}{1}$, C. $\frac{0}{0}$, Pm. $\frac{1}{1}$, M. $\frac{4}{4} = 28$. The three pairs of incisors in the upper jaw (Fig. 269) are subequal and closely approximated, except in the middle line, where those of the opposite side are separated from each other by a considerable space. They have incisiform crowns, and are implanted by enlarged roots caused by an unusually thick coat of cement. These are opposed by a single tooth on each side below, whose direction is almost a continuation of the long axis of the jaw, so procumbent is its implantation. They are long teeth with enamel-covered crowns, slightly compressed from side to side, so as to present cutting edges on the surfaces which would correspond to the anterior and posterior faces if the tooth were erect, but which in its present position are superior and inferior. The superior edge bites against the three upper incisors, opposing them exactly.

After a long interval come the premolars, which have approximately the same structure in the two jaws as do the molars behind them. The premolars are implanted by two roots, and have crowns whose longitudinal diameter greatly exceeds the transverse. The summit of the crown terminates in an antero-posterior ridge, which is bordered at the base

FIG. 269.

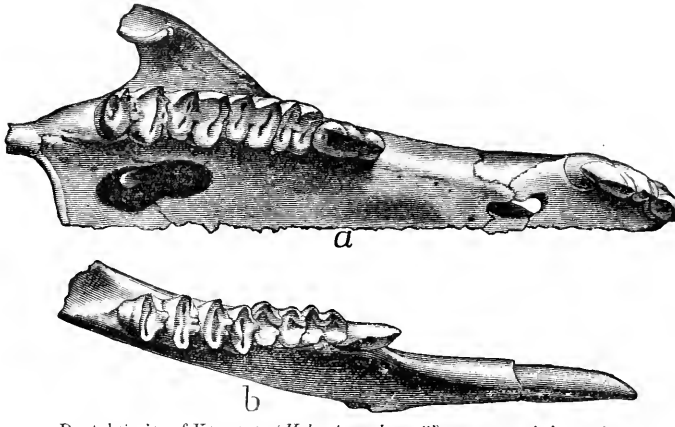

Dental Series of Kangaroo (*Halmaturus bennetti*): *a*, upper, *b*, lower jaw.

internally in the upper ones by a well-marked cingulum bearing several small cusps; this cingulum is absent from the inferior teeth.

The crowns of the molars are highly lophodont, consisting of two strong transverse crests connected in the median line by an antero-posterior ridge. They are all nearly equal in size and alike in both jaws.

In the phalangers, which constitute another family of this division, the incisors are the same as in the kangaroo. Small canines are usually present, and the premolars may be increased to three in the upper jaw. The third premolar has substantially the same structure as that of the kangaroos, but the molar pattern is selenodont, resembling in this respect the artiodactyle ungulates. They are quadritubercular, the four cusps being crescentic in section, with the crescents reversed in the lower jaw, just as in the artiodactyles.

Still another family is represented by the wombat, whose dentition exhibits a modification in the same direction as the rodent monodelphs in the reduction of the incisors to a single pair in each jaw and their growth from persistent pulps. The canines are absent, the premolars are $\frac{1}{1}$, and the molars, as well as incisors and premolars, grow continuously during the life of the animal. The molar pattern consists of transverse laminæ, greatly elongated and united by cement, much as in capybara, one of the rodents.

A gigantic extinct marsupial animal (*Thylocoleo*) has been described from the late Tertiary deposits of Australia, whose affinities and probable habits have provoked a good deal of discussion among English palæontologists. In each jaw there is a pair of enlarged, hooked, and pointed teeth in the position of the median incisors; these are followed in the upper jaw by three small teeth, the posterior of which probably

represents a canine; in the lower jaw but a single tooth of this kind exists. Next follows a relatively enormous tooth, corresponding in pattern with the single premolar of the kangaroo, and is therefore trenchant. Behind these are one small tooth in the upper and two of like nature in the lower jaw.

From the trenchant nature of the large premolariform teeth, Prof. Owen, its describer, has considered it to have been carnivorous in habit, while Prof. Flower concludes, from the enlarged incisors and general resemblance of the enlarged teeth to that of the premolars of the kangaroos, that it is really affiliated with this group and was a vegetable feeder.

Other marsupials might be mentioned, but the principal modifications of the dental organs of this group have already been set forth in the types selected.

The Milk Dentition.

In the preceding pages we have spoken of the deciduous or milk dentition of the diphyodont Mammalia so far only as they relate to the permanent set in matters of definition. It now remains to discuss the more important question of their true nature and relationship to the permanent teeth in a philosophic sense. Are they superadded embryonic structures similar to the amnion and allantois, which subserve a temporary purpose and disappear with approaching maturity, or are they to be homologized with the first set of teeth of the lower Vertebrata?

Before proceeding to a discussion of these questions, it will first be necessary to give a general statement of the more important features of their anatomy, as well as the principal characters in which they differ from the permanent teeth.

As regards their development, it must be borne in mind that their enamel organs are originally derived from the lining membrane of the oral cavity, or at least that part of it which immediately covers the axes of the jaws, by a dipping down of the epithelium, while the dentine organ is developed from the underlying embryonic tissue. The enamel organs in this case are said therefore to arise *de novo*. After a time the enamel organs of the permanent incisors, canines, and premolars appear by a process of budding from the necks of the enamel organs of the deciduous teeth, but that of the first molar in the human subject arises *de novo*, just as those of the temporary teeth do from the primitive epithelial layer of the mouth.

From the neck of the enamel organ of this tooth the enamel organ of the second true molar buds out, while the third is derived from the second in a like manner. Whether this order of development is true of all diphyodont mammals is not known, and is a subject which very much needs further investigation.

The form of the milk teeth resembles that of the permanent ones which succeed them, as a general rule; an important exception to this, however, is to be observed in the last milk molar, which in the majority of cases is more complex than the permanent tooth which succeeds it. In the ungulates the last milk molar in the lower jaw resembles the last

true molar in having three lobes, while in the upper jaw the last two milk molars have the complex pattern of the permanent molars. It is a rule of pretty general application that the last milk molar, and in many instances the last two, are succeeded by teeth of a simpler pattern. They may be well developed and retained in the jaw for a considerable period, as in the dog, or they may be extremely small, and shed, or rather absorbed, before birth, as in some of the seals. There may be as many as six in each jaw, as in the case of the nine-banded armadillo, or they may be reduced to a single one in each jaw, as in the marsupials. The usual number of milk molars is four in what may be called the typical diphyodont dentition, in which there are forty-four permanent teeth in all. Subtractions from this number are of common occurrence by reason of the first milk molar failing to develop a permanent successor or its complete disappearance. This, as we have seen, occurs in the dog and many other animals in which the number of premolars is normal. That this tooth is a persistent milk tooth is suggested by the fact that its enamel organ arises *de novo*, like those of the milk teeth generally.

In the monophyodonts one set has been lost, and the question naturally suggests itself, Which one is it? The very rudimentary condition of the milk teeth in the seals, which reaches an extreme point in the elephant seal, has led Prof. Flower to conclude that the single set of the monophyodonts is homologous with the permanent set of the diphyodonts, the first set having become rudimental and finally disappeared. He further concludes that the milk dentition generally is something superadded, and cannot therefore be homologized with the first set of the lower vertebrates. These conclusions are adopted by many authors.

In the first place, as regards the homology of the single set of teeth of the monophyodonts, there is much plausibility in Prof. Flower's position; but, upon the whole, our information respecting the exact limits of monophyodontism is too meagre to reach any satisfactory results in a solution of this question. It may yet turn out that many of the Cetacea, in which it is thought to be universal, really have rudimentary deciduous teeth in the early stages of growth, as has been suggested by Tomes. Among the edentates the nine-banded armadillo has already been cited as having two sets of teeth, and it does not seem at all improbable that all armadillos will ultimately be found to be diphyodont.

It should also be remembered that an approach to monophyodontism is made in many diphyodonts; and in all cases in which there is a partial loss of one set there can be little doubt that it is the *second* which has been subtracted. An example of this is afforded by the proboscidean series. In *Deinotherium* there were two and probably three permanent premolars; in some species of mastodons they are reduced in number to two or three; while in the existing elephants they have completely disappeared. The teeth which remain in the position of the premolars in these animals are certainly *persistent milk molars*. The first premolar of the dog, hippopotamus, and others is a case of the same kind. If monophyodontism has been produced in this way, then the single set which remains is not homologous with the permanent set of the diphyodonts, but combines the two, the molar dentition being made

up of the true molars and persistent milk molars, with the permanent premolars subtracted.

With reference to the second conclusion, that the milk dentition is something superadded, Dr. Tomes very justly raises objection on the ground that the history of the development of the permanent teeth interposes a difficulty. He says:[1] "The tooth-germ of the milk tooth is first formed, and the tooth-germ of the permanent is derived from a portion (the neck of the enamel germ) of the formative organ of the milk tooth. Again, in most of those animals in which there is an endless succession of teeth, such as the snake, the newt, or the shark, each successive tooth-germ is derived from a similar part of its predecessor; the natural inference from which would be that the permanent set, being derived from the other, was the thing added in the diphyodonts."

Aside from the inherent improbability of this hypothesis of superaddition of the milk teeth, if the mammal has been derived from the reptile or batrachian—which is true if evolution is true—it is not at all remarkable, but, on the contrary, quite in keeping with the nature of the case, that the descendants should have retained some of their ancestral features. In the Batrachia and Reptilia there are many sets of teeth developed during the life of the individual, of which the first arises *de novo*, and all the succeeding ones are derived from that which precedes it. Altogether, I am disposed to regard the diphyodont mammalian dentition in the same light: those teeth which take their origin primarily from the epithelial lining of the mouth are strictly homologous with the first set of the lower vertebrates. This would include in the first set the deciduous incisors, canines, molars, and the first true or permanent molars. The second set of the batrachian and reptile would be represented by the permanent incisors, canines, premolars, and second true molar. The third succession would be represented by the last molar of the diphyodont dentition.

This view, of course, is based upon the presumption that the development of the true molars is the same in all diphyodonts as it is in the human subject—viz. that the enamel germ of the first is derived from the epithelial lining of the mouth; that that of the second is derived from the neck of the first; and that of the third from the second.

If it shall be found, however, on further investigation, that in any diphyodont the enamel germs of all the molars arise *de novo*, then they must in all such cases be added to the first set. This objection may be urged against the view that there are three, or even two, successions represented in the molars of the diphyodont—viz. that they do not succeed each other vertically, as in the case of the reptile and batrachian; but this I do not consider of vital importance. There is one thing upon which I would strongly insist, and that is that the first true molar in the human dentition is a persistent milk tooth.

[1] *Manual of Dental Anatomy*, p. 302.

CONCLUSIONS, ACKNOWLEDGMENTS, ETC.

THROUGHOUT the foregoing pages I have endeavored not only to give the leading characteristics of the principal modifications of the dental organs of the Vertebrata, but have in many cases, so far as our knowledge of the extinct forms would permit, endeavored to trace the leading steps in the production of the complex from the simple form. In so doing I have been made aware of the difficulties which beset such an undertaking: the principal burden of these difficulties lies in the comparatively imperfect knowledge we possess of the palæontological history of certain groups. In others the ancestry is more clearly indicated, and in my judgment the evidence is sufficient to demonstrate with a reasonable degree of certainty the more important steps in their dental evolution.

The modification of an organ from a simple to a complex structure necessarily implies a cause or force adequate to the production of such result. What, then, is the nature of the force or forces involved, and what is their method of operation? To simply say that this or that is so, that this tooth is simple and that is complex, without giving any reason why it is so, conveys little information. If one tooth is simple and another complex, there are reasons for it, and it is not only within the province, but is clearly the duty, of the odontologist to discover and point out these reasons if they can be found to exist.

Two explanations for all such phenomena have been offered. One of these presumes that they were created so by supernatural forces, but as to the nature of these forces we are not informed; much less do we know about the manner in which it was done. The other assumes that the natural or physical forces, operating through distinct and well-known physiological laws, are alone responsible for the resulting modifications.

Between these two explanations the naturalist experiences little difficulty in deciding which is most in accordance with the observed facts at his command. While the one rests solely upon the vaguest assumption, unsupported by so much as a single fact, the other rests upon observed scientific truth, which any one can verify who will take the pains to investigate. When we ascribe these modifications to the physical forces, the conclusion seems inevitable that those of a mechanical nature have been most largely concerned in the modification of form.

The change in form or size of any organ is principally due to addition, subtraction, or transposition of the histological elements of which it is composed; these, as is well known, are directly dependent on the amount of physiological waste and repair which the organ sustains, or, in other words, the extent of use and disuse. In proportion as an organ or a part of an organ is used, in that proportion will there be increased destruction of its substance and a corresponding determination of the nutritive fluids to supply the loss. The reverse is true of disuse.

In the harder tissues of the animal body strain and pressure have likewise been potent factors in the determination of form. Recognizing the importance of these influences, Mr. J. A. Ryder has constructed a most ingenious and far-reaching hypothesis in regard to the teeth, which he terms "the mechanical genesis of tooth-forms."[1] In this he satis-

[1] *Proceedings Acad. Nat. Sciences*, Philada., 1878.

factorily accounts for the forms and patterns of the molar teeth of the ungulates by the manner in which they have used their jaws. He has shown that in the bunodonts the mouth is simply opened and closed during mastication—a movement which is associated with a short-crowned tubercular molar—while in the selenodonts the lower jaw makes an extensive lateral sweep, and is associated with long-crowned crescentic molars. The conclusion is therefore obvious that as the bunodonts were compelled, through force of circumstances, to live upon a diet which required more extensive comminution before it could be properly assimilated, they gradualy develop greater mobility of the lower jaw; as a consequence of this, the patterns of the molar teeth were modified through pressure in accordance with this movement. If this proposition be true of the teeth of the ungulates, it must likewise be true of all other animals.[1]

Dr. Tomes in his *Manual of Dental Anatomy* criticises Mr. Ryder's conclusions, as follows: "The simple mechanical explanation that the teeth are drawn out into these forms hardly conveys much information, seeing that the tooth, before it is subjected to these influences, is quite finished, and its form, such as it is, is unalterable; while to effect an alteration in the form of a masticating surface an influence must be brought to bear upon the tooth-germs at an exceedingly early period. It might with equal justice be said that the crown of the tooth, being formed thus, had influenced the excursions of the jaw, and so modified the condyle."

It is evident that Dr. Tomes has either failed to grasp the meaning of Ryder's reasoning, or else denies one of the most important principles of the evolution doctrine. I am not aware that Ryder has anywhere asserted that the production of the selenodont pattern of the ungulate molar took place in a single generation, as Dr. Tomes's criticism would seem to imply. As a matter of course, the tooth of a modern ungulate when it comes into position is "quite finished," but were the teeth of the ancestors of the modern ungulates quite finished when they came into position? Ryder has attempted to show that this finishing process was a gradual one, which took many generations to accomplish, and the facts of palæontology bear out this view. The bold assertion of Dr. Tomes, to the effect that the masticating surface of a tooth when it comes into position is unalterable, is open to very grave and serious doubts. If the form of a bone or any other organ of the animal body can be influenced by impact and strain, as all evolutionists believe, then I can see no reason why a tooth is not amenable to the same influences.

The suggestion which Dr. Tomes offers, to the effect that the crowns of the teeth have determined the direction of the jaw movements, and so modified the condyle, is somewhat absurd. It is equal to assuming that structure has determined habit—a most remarkable conclusion for an evolutionist of the pronounced type of Dr. Tomes. The fact of the matter is, the evolution hypothesis assumes the very opposite of this. I have always believed it to be one of the cardinal

[1] Dr. C. N. Pierce has elaborated the views of Ryder and made important additions to this mechanical hypothesis.

principles of that great doctrine to consider that structure is largely the result of habit. Upon the whole, I find it quite impossible to harmonize such a suggestion with what this author holds on page 268 of the same work, in which he says: "It would be impossible in these pages to go through the arguments by which Mr. Darwin has established his main propositions; it must suffice to say here that he has fully convinced all those who are not in the habit, from the fixity of early impressions, of putting many matters upon another footing than that established by the exercise of reason, that any modification in the structure of a plant or animal which is of benefit to its possessor is capable—nay, is sure—of being transmitted and intensified in successive generations until great and material differences have more or less masked the resemblances to the parent form."

As a result of palæontological investigation we know that the form of the mandibular condyles has been very little, if any, modified, while the teeth have. We know, moreover, that it was a gradual process, and that all complex patterns had their origin in simple ones.

I feel well satisfied that there is not a single dentition of a complex nature that has not been profoundly modified by these same mechanical influences. If evolution has taken place as a result of the physical forces, it is impossible to discover any forces sufficient to produce such results other than those of strain, impact, and pressure. These have in some instances probably been exerted upon the young and growing tooth-germs; in others they have operated upon the adult tooth, thereby furnishing the causes for individual variation and determining the direction of the hereditary energies.

In the preparation of the present article my grateful acknowledgments are due to the following gentlemen: to Prof. E. D. Cope of Philadelphia, who has kindly accorded me free access to his large and valuable collection of fossil vertebrates, without which it would have been impossible to include the extinct forms. He has likewise placed at my disposal all the illustrations in his possession which relate to his labors in this field. To Mr. J. A. Ryder for many wise and valuable suggestions in the developmental history of the teeth and other kindred subjects. To Dr. Theo. Gill for the loan of illustrations and much important information; and, finally, to Prof. C. N. Pierce, at whose instance I was led to undertake the present work. I also wish to express my obligations to this gentleman for much kindly advice and assistance.

Of the works consulted I have made free use of C. S. Tomes's *Manual of Dental Anatomy*, a most useful and important work; also, of the published writings of Profs. Owen, Huxley, Gegenbaur, Flower, Cope, Leidy, Allen, Ryder, Marsh, and others.

Descriptions of Plates.[1]

Plate I.—Figs. 1 and 2 represent the deciduous incisors and cuspids, with their labial surfaces, and the molars with their buccal surfaces facing. Also the normal number of roots for these teeth in situ.

Figs. 3 and 4 represent the superior incisors, cuspids, and molars with their palatine surfaces, and the full inferior set with their lingual surfaces facing.

Figs. 5 and 6 represent the mesial surfaces of the full deciduous set, and both mesial and distal surfaces of the molars.

Plate II.—Figs. 1 and 3 represent the full permanent set of thirty-two teeth, sixteen in each jaw, with the labial surfaces of the incisors and buccal surfaces of bicuspids and molars exposed: *a a*, the central incisors, right and left; *b b*, the laterals; *c c*, the cuspids or canines; *d d*, the first bicuspids; *e e*, the second bicuspids; *f f*, the first molars; *g g*, the second molars; *h h*, the third molars.

Figs. 2 and 4 represent the anterior teeth, incisors, and cuspids, with their cutting edges notched, as they are usually seen in the newly-erupted teeth, this uneven or notched appearance usually disappearing in a few months, or at most in a year, after eruption.

Plate III.—Figs. 1 and 2 represent the deciduous or temporary teeth divided longitudinally through their lateral diameter.

Figs. 3 and 4 represent the same teeth divided through their antero-posterior diameters. These cuts give a very accurate idea of the relative size of the crown and roots, and of the position occupied by the pulp-chamber in the same.

Plate IV.—Fig. 3 gives in contrast a sectional view of deciduous and permanent upper teeth divided through their lateral diameters.

Fig. 4, a sectional view of the corresponding lower teeth divided through their antero-posterior diameters. *a*, *b*, *c*, represent, respectively, the deciduous and permanent front incisors in contrast; *d*, *e*, *f*, the lateral incisors; *g*, *h*, *i*, the cuspids; *k*, deciduous molars, upper and lower; and *l*, *m*, the successors to the deciduous molars, the bicuspids; *n*, *o* represent permanent molars. *c*, *f*, *i*, *m*, *o* have dotted lines, indicating the thickness of enamel removed by wear, atrophy of the cementum, and reduction in the size of the pulp due to progressive calcification, these changes being incident to old age.

Plate V. represents in Fig. 1, letters *a* to *h* and *a* to *h*, the longitudinal or vertical sections of the sixteen superior teeth, showing the labio-palatine diameter of the pulp-chamber and canal in crown and roots, the section of the molars being through the anterior buccal and palatine roots, while the bicuspids *d e* and *d e* illustrate the result of such a compression of the fang or root as to divide the pulp-chamber into two canals—a condition which so frequently exists in these flattened roots. The double-lettered series, *d d* to *h h* and *d d* to *h h*, represent in the molars a section through the posterior buccal and the palatine roots, from which is quite readily recognized the slightly greater lateral diameter of the pulp-chamber in the crown and the larger canal in the posterior buccal root over that in the anterior buccal root, while the bicuspids lettered *e e d d* and *d d e e* illustrate a modified pulp-chamber and canal, with bifurcation of the root in one, these being cut through a different axis or plane from the single-lettered series.

Fig. 2, letters *a* to *h* and *a* to *h*, represents the sixteen inferior teeth with the section through their long diameters, as in the superior series. These incisors illustrate the compressed or flattened condition of their roots in contrast with the cylindrical character of the roots of the superior incisors, while the bicuspids *d e* and *d e* illustrate the singleness of their pulp-chamber and the cylindrical condition of their roots as in contrast with the flattened or compressed condition of the roots of the superior bicuspids. The molars *f*, *g*, *h*, and *f*, *g*, *h* represent sections through the anterior root, illustrating its compressed condition and divided pulp-chamber in the first and second molar, and a somewhat flattened one in the anterior root of the third molar; *f f*, *g g*, *h h*, and *f f*, *g g*, *h h* represent the single and cylindrical pulp-chamber in the posterior root of the inferior molars, while *b b*, *c c* and *a a*, *b b* represent the incisors and cuspids of the same series, with modified pulp-chambers arising from modified development.

Plate VI.—Fig. 1, from *a* to *h* and *a* to *h*, represents the superior teeth, with transverse or horizontal section through the base of the pulp-chamber in the crown, viewing the entrance to the canals of the several roots, while the same letters in Fig. 2 represent the inferior series in the same manner.

Fig. 3 represents the superior teeth, with the transverse or horizontal section made below the largest diameter of the pulp-chamber and through the canals after they have diverged from the central chamber, but before the roots into which they run have in the molars bifurcated.

Fig. 4 in like manner represents the inferior series, well illustrating the flattened or compressed condition of the canal in anterior roots of the molars and the division of the chamber, as is frequently found in the roots of the inferior incisors.

The letters *a a*, *b b*, *c c*, *d d*, *f f*, *d d* and *e e* (Fig. 3) represent the relative shapes, whether circular, oval, or flattened, of the pulp-canal in the roots of the superior central and lateral incisors, the cuspids, the first and second bicuspids, and the first, second, and third molars, while the same letters in Fig. 4 represent the relative shapes of the pulp-canal in similar teeth in the inferior series.

[1] These plates are taken from v. Carabelli's *Anatomie des Mundes*.

PLATE I.

For description, see page 504.

Fig. 1.

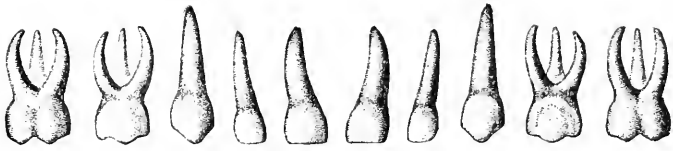

Fig. 2.

Fig. 3.

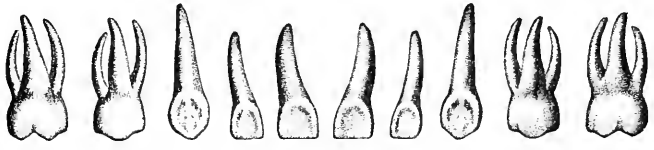

Fig. 4.

Fig. 5.

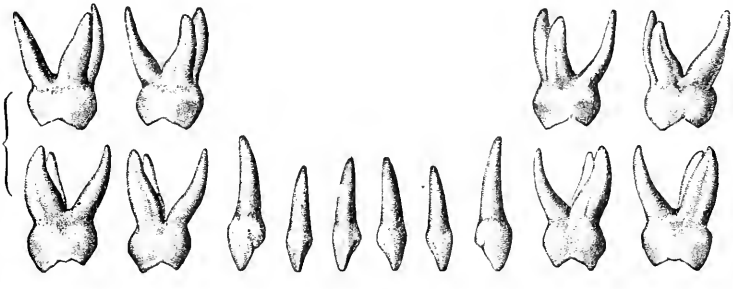

Fig. 6.

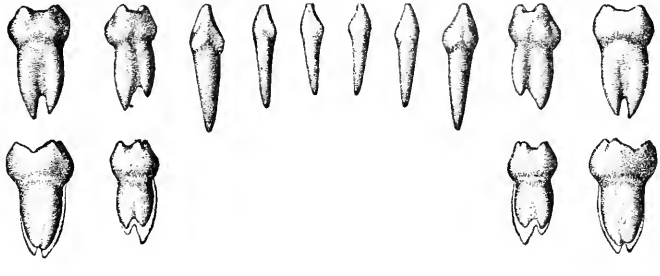

PLATE II.

For description, see page 504.

Fig. 1.

Fig. 2.

Fig. 4.

Fig. 3.

PLATE III.

For description, see page 504.

Fig. 1.

Fig. 2.

Fig. 3.

Fig. 4.

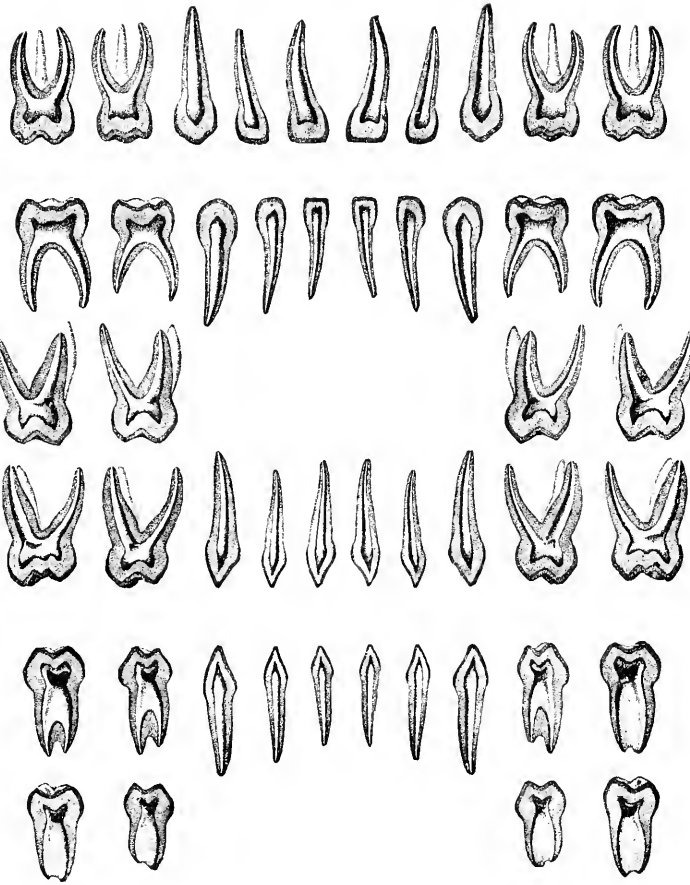

PLATE IV.

For description, see page 504.

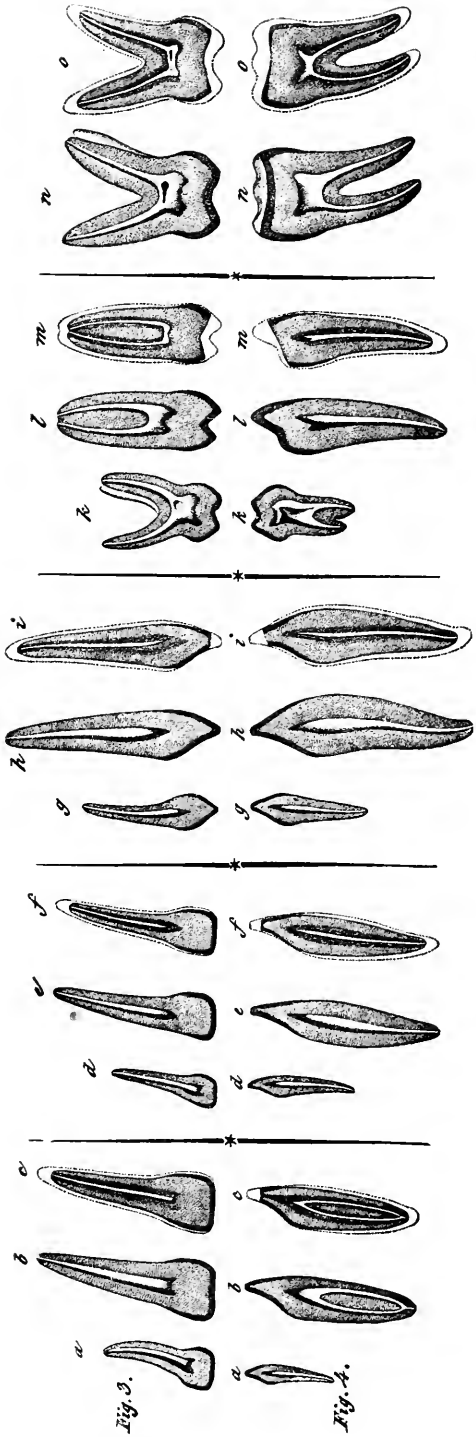

Fig. 3. Fig. 4.

PLATE V.

For description, see page 504.



PLATE VI.

For description, see page 504.

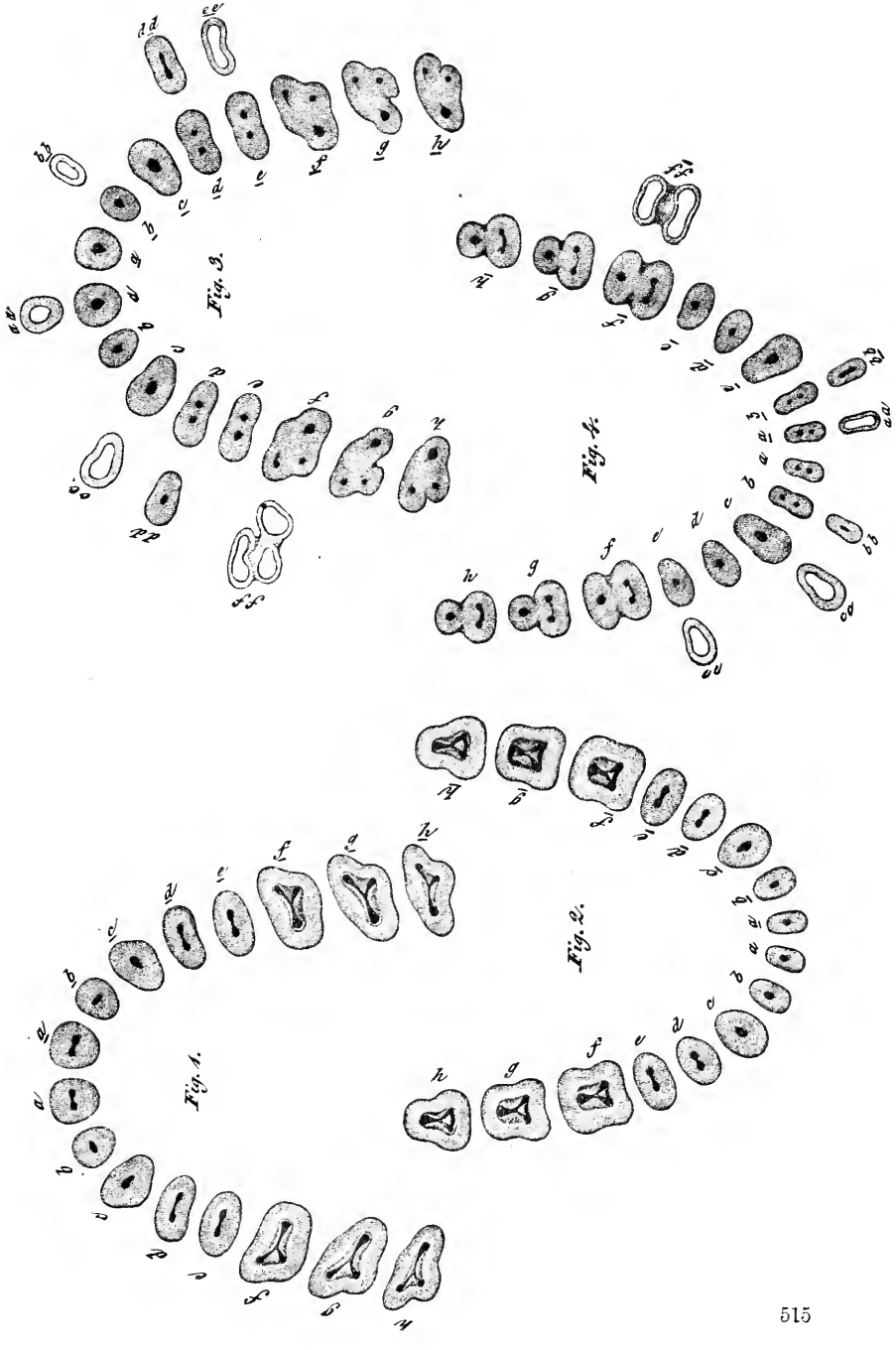

PART III.

EMBRYOLOGY AND DENTAL HISTOLOGY.

DENTAL EMBRYOLOGY AND HISTOLOGY.

By W. XAVIER SUDDUTH, M. D., D. D. S.

Physiological Consideration of Life-Force.

What is the nature of life? is a question which man is ever asking of the universe of which he is so wondrous yet so infinitely small a part. From the earliest times the ultimate purpose of all scientific research has been to elicit a sufficing reply to this inquiry. The deepest thinkers and most devoted searchers after truth have speculated and investigated in the hope of making up something like a satisfactory answer. But, though knowledge has been augmented and phenomena explained, the great life-mystery remains unrevealed. The question still is asked, What is that vital or living principle which we call life?

Scientists and philosophers have ventured various and widely divergent theories in explanation of the nature and powers of vital phenomena. Setting aside opinions that are so manifestly based upon fallacies as to carry with them no inkling even of definite signification, the great variety of theories advanced in our own day may be for the most part reduced to two or three classes.

In the early part of the present century Lorenz Oken, a devotee of the physical school, proclaimed "primordial slime" to be the original source of life and the material basis of all living bodies. This "primordial slime" possessed in all essentials the same qualities and the same importance now ascribed to the substance known as *protoplasm*. The protoplasm theory—varied in many ways as to the first vitality on earth—has occupied the attention of the most earnest scientists and profoundest thinkers of the age.

It is not my intention to notice to any extent the different phases which this theory has assumed, but I wish to be understood as antagonizing that interpretation of it which aims to make the beginning of life in the individual solve the great mystery of the beginning of life in the world. I desire, at the outset, to forestall any misapprehension of facts I may state hereafter, and to impress upon my readers the wide difference between accepting protoplasm as the *first formative substance* and ascribing to it the power of spontaneous generation, since it by no means follows that because it is the essential and active agent in the formation of every tissue, in the construction of every organ and of every form of mechanism existing in a living being, it is in any sense self-originating.

Perhaps the most plausible theory advanced by speculators concerning

life-formation is that of evolution, but evolutionists themselves assign several meanings to the term. One class maintains that the development hypothesis is restricted to the living world—that it simply teaches that all grades of life have arisen from the simplest beginnings, the higher being derived from the lower by a long course of organic development solely through the operation of such forces and laws as belong to matter. Another class holds that the hypothesis includes not only the evolution of living forms from pre-existing living forms, but the spontaneous production of living from non-living material. A vast majority of the practical, working scientists in Europe and America—those who report not what they wish nor hope nor imagine, but only what they see, who are seeking, not the mere support of cherished hypotheses, but the uncolored truth from Nature,—refuse to accept the doctrine of evolution, while at the same time they fully allow the value of many of the facts gathered by its followers.

In regard to the "transmutation of species," that part of the theory of evolution which undertakes to show how the higher grades of life came by a series of natural changes from the lower, Agassiz has written thus:

"I wish to enter my earnest protest against the transmutation theory. It is my belief that naturalists are chasing a phantom in their search after some material gradation among created beings by which the whole animal kingdom may have been derived by successive development from a single germ or from a few germs. I confess that there seems to me a repulsive poverty in this material explanation that is contradicted by the intellectual grandeur of the universe. I insist that this theory is opposed to the processes of Nature as we have been able to apprehend them; that it is contradicted by the facts of embryology and palæontology, the former showing us forms of development as distinct and persistent for each group as are the fossil types of each period revealed to us by the latter; and that the experiments on domesticated animals and cultivated plants, on which its adherents base their views, are entirely foreign to the matter in hand."

From the side of geology—on which evolutionists very largely depend for the support of their scheme—we have many an earnest protest, of which the following may serve as an illustration:

"Were all the anatomists of the earth against us, we should not one jot abate our confidence. For we have examined the old records, but not in cabinets, where things of a different age are put side by side, and so viewed might suggest some glimmering notions of a false historical connection. We have seen them in spots where Nature placed them, and we know their true historical meaning. We have visited in succession the tombs and charnel-houses of these old times, and we took with us the clue spun in the fabric of development; but we found this clue no guide through these ancient labyrinths, and, sorely against our will, we were compelled to snap its thread, and now dare to affirm, with all the confidence of assured truth, that geology—not seen through the mists of any theory, but taken as a plain succession of monuments and facts—offers one firm cumulative argument against the hypothesis of development" (Sedgwick).

Still stronger words than these have been spoken against the doctrine of spontaneous generation. It is even admitted by nearly all the foremost evolutionists themselves that as yet not an instance of life-formation without seed has been made out. "It is true," say they, "that the knowledge of man has not *yet* enabled him to make a vegetable or animal germ, but the time may come when it will be done."

"'To-morrow, and to-morrow, and to-morrow,'" says Dr. Beale, "has always been the refuge of the philosophers who have faith in the dogma that matter alone is competent to develop every form of life. But the 'to-morrow' of Lucretius has not yet dawned; and how many thousand years, I would ask, may be expected to pass away before the prophecies of those who would now go along with Lucretius shall be fulfilled?" Again, speaking directly of the theory of spontaneous generation, he says: "I cannot but remark that the more minutely investigation is carried out, the more thoroughly and intently facts bearing upon the matter are examined, the more improbable, in my judgment, does it appear that any living form should be derived directly from the non-living. Notwithstanding all that has been recently written upon this subject, I cannot but feel surprised that at this time many good reasoners should decide in favor of the *de-novo* origin even of bacteria. Whether we consider the matter from the experimental side only, or study the evidence obtained in a general survey of Nature, or carefully reflect upon the facts learned from investigations concerning the properties of living and non-living matter with the aid of the most perfect instruments of minute research now at command or from other standpoints, the conclusion seems to me irresistible that the verdict of a jury of well-educated men would be against the direct origin of any form of living from any form of non-living."[1]

Pasteur asserts decisively, "There is no circumstance now known that permits us to affirm that microscopic beings have come into the world without germs, without parents like themselves. Those who affirm it have been victims of illusions, of experiments badly made, and infected with errors which they have not been able to perceive or avoid. Spontaneous generation is a chimera."

Did our limits allow we might multiply quotations almost indefinitely to show that the most thoughtful among working scientists, both at home and abroad, deny that there have been proved cases either of transmuted species or of spontaneous generation. On the contrary, experimental investigation is constantly furnishing positive proof of the permanence of species, and so intensifying the vast dissimilarities between the living and the non-living as to preclude the possibility of drawing even an analogy between the properties peculiar to living matter and any properties known in connection with the non-living.

The distinctive characteristic of non-living matter is *rest;* the distinctive trait of living matter is *motion*, life. The non-living, once formed, never changes from internal causes; its parts invariably preserve the position which they have once taken in respect to each other, unless endowed with the properties of life by the aid of organisms already living. Living bodies, on the contrary, from the very lowest in

[1] *On Life and on Vital Action in Health and Disease.*

the vegetable kingdom to those concerned in the development of man, are continually in action. This capacity of movement is the broad essential character which distinguishes living matter absolutely from all other matter, and makes a clear-cut boundary between it and the non-living. It has been claimed that the phenomena of the minute organisms which lie on the very verge of the vast area of what we know as the living are not essentially different from those of the highest points in the area of the non-living which they touch. The wonderful revelations of the lowest forms of life made by the modern microscope have shown that not only is the assertion entirely groundless, but the highest form of living matter is not more unlike non-living than is the lowest—that "one is, in fact, just as near and just as far from inorganic matter as the other."

With all our study, we must admit that at best we have only been able to demonstrate life in its concrete form. It is a correlation of forces that our present knowledge does not enable us to separate into ultimate principles. We know the elements that compose the vital stuff; we know their physical properties. But *how* these elements can be so combined as to acquire the wonderful properties of life is as great a mystery now as when God first "breathed into man the breath of life, and he became a living soul." Humanity stands to-day, as in the remotest past, with the same question on its lips: What is life? What is it to *be?*

But whatever may be the *essential* nature of the central force which determines the form and action of living bodies, it cannot be denied that some power does exist and act in every organism independent of the physical and chemical forces of Nature. "Besides the material substance of which a living body is constructed, there is also an immaterial principle, which, though it eludes detection, is none the less real, and to which we are constantly obliged to recur in considering the phenomena of life. It originates with the body, and is developed with it, while yet it is totally apart from it." We are as certain that this *inscrutable principle* does exist as we are of the *constancy of species*—a phenomenon depending on its operation. Every living thing tells of some wonderful power which is capable of controlling matter and its forces—"a power which we cannot isolate and physically examine, but the effects of the actions of which we may study."

Let us use a familiar illustration: If one grain of copper be dissolved in three pints of water, a distinctly blue tint is imparted to the volume of water. We cannot see the finely-triturated particles which by their minute subdivisions have given the blue tint to the water—they do not reveal themselves even to the microscope—but we *know* that they exist, and that by the process of evaporation we may receive back our one grain of copper. But you ask, How can this illustration be applied to the question of ultimate life-force? We answer: In all our study of life we see the "blue tint," as it were. Especially is this the case in the microscopic study of the *formative material* which we designate protoplasm. Beyond the protoplasm we see the manifestations of a universal power by virtue of which all formation, whether vegetable or animal, takes place. We see how protoplasmic atoms act under the

direction of this indwelling principle just as plainly as we see the blue tint of the water; and we feel as sure that there is a force outside the properties of matter, which pervades and vivifies every living particle, as we do of the grain of copper left after the evaporation of its menstruum. It is only as man contemplates, at the same time, matter and mind that he is able to master the first data of life-science or form even a dim conception of that Infinite Spirit "whom none by searching can find out."

But we must now leave the question of how life begins, and consider life as it presents itself to our eyes when seen in its minutest forms and at its earliest known stage of existence—*i. e.* as an aggregation of transparent cells.

The unit of life, as we are able to demonstrate, is expressed in small bodies denominated *cells*, and "*the life-history of the individual cell* is the first important and indispensable basis whereon to found the true physiology of the life-history of all the orders of creation." We shall therefore take our starting-point from the simple cell, which is the same, in respect to its chief characters, in animal and vegetable life.

Structure of Cells.

A mature *cell* is composed of a nucleus, a cell-body, and a cell-limit, or wall. The *nucleus* is that part of the cell which is first formed from the germinal matter, and is the first to be affected when a change in form occurs. The nucleus may assume various shapes, as round, oval, rod-like, or irregular. It generally encloses central dots, termed *nucleoli*, which are thought by some histologists to be the enlargements of portions of an irregular network of fibres which can be seen inside the nucleus. The *cell-body* is the formed material which surrounds the nucleus. The *cell-wall* is the limit of this formed material. When we speak of a cell-wall, we do not mean that there is any abrupt demarcation between the cell-body and its outer edge; the one passes gradually into the other. Cells draw their nourishment from a protoplasmic substance which circulates in the intercellular spaces. This supply of cell-pabulum is inert until acted upon by the living principle resident in the cell. Such are the *visible* parts of a cell when seen in its early stage of existence.

Ziegler, speaking of the youngest embryonal cells, says: "The cell by itself appears originally as a microscopic mass of pale, slimy, finely-granular matter—the so-called protoplasm. It usually contains within it a nucleus—that is to say, a structure like a tiny vesicle, whose form may be round, oval, rod-like, or irregular, and in whose interior we can make out, by proper handling—1, small definite bodies, the nucleus-corpuscles; 2, a net-like framework of nucleus substance; and, 3, a clear fluid, the nucleus juice. The young cell is at first naked. Only in its maturer stages does it develop on its surface an optically distinct membrane or other structure according to the special tissue of which it forms a part." This accords with my own observation. For example, in studying sections from the mucous membrane of the mouth it is found that the deepest part of the epithelial layer of the

mucous membrane of the mouth in the embryo is formed of a layer of protoplasm, which is conspicuous in preparations stained with hæmatoxylon and eosin in that it stains more darkly than the surrounding tissue. In this protoplasmic basis-substance are found small spheroidal cells (nuclei), sometimes arranged in regular layers; in other cases the dark-stained layer of protoplasm is wider, and several layers of spheroidal cells exist—not arranged in strata, but presenting an irregular appearance, and in some instances being four or five cells deep. These spheroidal cells have no distinct cell-body or membrane, and the surrounding protoplasm presents no characteristic feature. The youngest cells of the Malpighian layer take the stains similarly to the embryonal connective-tissue cells lying immediately beneath in the submucous layer, and at this stage present the same shape, and can be seen in the pig embryo 1— centimeter in length, and in the human embryo at the thirty-fifth day.

As the nuclei are crowded up from this bed of protoplasm, they carry with them a certain portion of protoplasm which surrounds the nucleus as a cell-body, and as they approach the surface of the epithelium they apparently develop a cell-wall; in this state they present an imbricated border which unites them to their fellows. (For further description and figures see section on Mucous Membrane of the Mouth, p. 611.)

The shape of cells depends to a great extent upon the reciprocal pressure of fellow-cells. This is specially noticeable in cells developed from the epiblast and hypoblast: these may be round, oval, cylindrical, columnar, prismatic, hexagonal, or tessellated in form. The cells developed from the mesoblast—viz. the connective-tissue group—vary from round or oval to fusiform with numerous fibrillæ. The size of a cell may be $\frac{1}{300}$th part of an inch in diameter; some are larger, some smaller; the nucleus may be $\frac{1}{3000}$th of an inch in diameter; the nucleolus $\frac{1}{10000}$th of an inch in diameter, more or less.

Physiological Consideration of Cells.

Dependent upon an inherent principle, the nature of which we have never been able to divine, cells have a threefold character: the power of self-preservation, of multiplication, and of functional activity.

In the first place, out of the common stock of cell-pabulum each cell has the power to assimilate such constituents as are needed to prolong its existence. That different cells require different kinds of food, and are able to convert the same into matter like themselves, is evidenced by the fact that chemical reagents give manifestly different results on the various cells. A simple demonstration is found in the action of staining agents upon different tissues. Cells have, within a certain limit, the power of overcoming deleterious agents or conditions. This limit is not great as regards the cell itself, but for the tissue of which it is a component part the range is much more extended.

Recovery after the loss of a portion of the cellular elements that compose a tissue is generally very rapid, and depends upon that attribute of cells we term *multiplication*. Increase of cells is accomplished by segmentation, which, beginning in the nucleus, results in the division

of the parent into two equal parts, each of which when detached absorbs nutrient matter, and, soon attaining the same size as the mother-cell, multiplies in turn. The principle enunciated by Virchow twenty years ago, *Omnis cellula e cellulâ*, is as much in force now as then. Discoveries regarding the methods of cell-multiplication have been made, but no instance of metaplasia between members of different groups or families has been demonstrated. That the repair of tissues depends upon the multiplication of cells of *like families* is the accepted belief of histologists to-day. A surface denuded of its epithelium does not recover itself from the connective tissue beneath, but from the edges of the wound by the extension of the borders toward the centre, thus gradually forming a complete skin. It is true that the regeneration of connective tissue is through granulation-tissue, but granulation-tissue is developed from the escaped white blood-cells; and I think we can place white blood-cells in the list of connective tissues developed from the mesoblast. The change from white blood-cells to plasma-cells and fixed connective-tissue cells is simply a matter of adaptation to environment.

We come now to the consideration of the third attribute of cells—that of *functional activity*. The life of the individual rests in the life of the individual elements that compose it. The human body is made up of millions of individualities which are dependent upon a special localized principle for their functional activity. These units of life not only have the power of individual cellular activity, but, united, they form organs which are but the expressions of their aggregation. A tissue is what it is by reason of the elements that constitute it, and the function it performs is only the united expression of its component parts. Cellular activity, then, is the basal principle that underlies all visible life-functions.

The limit of duration as regards the life of an organism is in adverse ratio to the scale it occupies in the order of being. A perversion of physiological action in the individual organism gives rise to a pathological condition known as disease. Total and permanent cessation of functional activity is that state of being which we recognize as death. Death may result from outside influences or by reason of the cells having performed their life-office.

Cells are developed to perform well-known physiological actions, and when a pathological result is produced it has its origin in some outside influence. Cells have not the power to produce pathological results unless stimulated by some agent which lies without the bounds of physiological action; and when so stimulated they act through their original channels. Thus, we see that pathological conditions are only perverted physiological conditions. Many physiological processes present pathological appearances, but when we study their deeper expressions we find that they are purely physiological. For instance: in the development of bone, giant-cells or osteoclasts are always present taking down the first-formed bone from the inner side, while the osteoblasts are adding to its circumference. In the resorption of the roots of temporary teeth we find another excellent example of physiological action which bears upon its face the stamp of a pathological process. In this

case giant-cells are Nature's physiological agents, by whose aid she removes tissues that have performed their life-office.

There can be no doubt that cellular activity can be induced by different agents, but the action of a given tissue is always the same—provided the other conditions remain unchanged—whatever may be the nature of the outside irritant. Too little stress is laid upon the *character* of the irritant, and too much on the visible expression of Nature's effort to remove it.

The close intimacy existing between physiological and pathological processes is very clearly seen in the action of giant-cells. In one instance they are the expressions of normal action; in another they are actively engaged in producing pathological results. Let us study them in their several conditions.

Giant-cells are found in connection with a perversion of the equilibrium of the circulation which results in increased nutrition. In most instances where such disturbance is found it can be directly traced to some local irritant. We see a hyperæmic condition of some organ or part of the body, which state is quickly followed by congestion and the exudation of white blood-corpuscles. These tend to form granulation-tissue. The increased nutrition does not sufficiently account for increased cellular activity, either as regards multiplication or function—congestion not always resulting in cell-multiplication. There is back of all that can be observed some force inherent in the cell itself that leads to these special attributes—an *ego* which has the power to turn the local irritant into a cellular stimulant.

Ziegler, writing on this subject, says: "The proposition, often enunciated as if it were self-evident, 'the stronger the external stimulus the greater the proliferation,' cannot be accepted as true. We can, *at most*, admit that slight stimuli, sufficient merely to excite the cell without injuring it, may perhaps call into play its powers of multiplication; but nothing has been experimentally established concerning the nature, the action, or the mode of application of such stimuli. If, then, it be true that external injurious agencies are not competent to induce multiplication of cells, we must have recourse to the normal vital stimuli if we are to explain the process of pathological cell-growth. For the due growth and multiplication of a cell certain external conditions must be fulfilled. Above all, it is necessary to provide for a certain degree of warmth and a certain modicum of proper nutritive material. In addition to this there must be no obstacle in the way of multiplication. These are the external requirements. The internal condition is the inherent faculty of the cell to assimilate the nutriment offered to it. In a tissue not undergoing transformation the factors favoring proliferation and those which inhibit it must be in a state of balance. If this balance be disturbed toward the side of the proliferous forces, the cells proceed to grow and to multiply. The factors in question resolve themselves on analysis into three. In the first place, it is conceivable that the capacity of the cell to assimilate nutriment may be increased. Such increase can only be conditioned by an increase in the normal stimuli required for the preservation of the cell. Such stimuli are warmth; for many cells, light; for the muscles, motor impulses; for glands,

special excitations from the nervous system, etc. Increased stimulation of this kind may, as a fact, lead not only to intensified functional metabolism in the tissue concerned, but even to hypertrophy of its elements. Such hypertrophies, which we may call functional hypertrophies or hypertrophies of action, are specially common and remarkable in muscles and glands (heart-muscles, bladder-muscles, kidneys, etc.). As we have said, they are referable, in part at least, to increased vital activity in the cells, consequently upon increased physiological stimulation. A second possible factor is increase in the supply of nutriment. This plays a chief part in hyperplastic processes, at any rate. A third is the removal of the normal checks to growth. Its effect is most evident in the processes described as regenerative. If we attempt in particular cases to make out to which of these factors cell-multiplication is due, we are led to see that it is rare for any one factor alone to be the efficient cause.

"The remarkable regulating mechanism of the vessels is so adjusted that when the function of a tissue is increased, its blood-supply is increased to correspond. In like manner, when the smallest fragment of tissue is removed, the slight loosening of the surrounding texture is enough to augment the stream of transudation from the vessels. In consequence of these adjustments increased supply of nutriment plays a great part in all the formative disturbances of nutrition.

"Cohnheim, in his *Allgemeine Pathologie*, has insisted on the importance of increased supply of nutriment even more strongly than we have done. According to his view, it is the sole influential factor, compared with which the intrinsic activity of the cell is quite secondary. We are unwilling to condemn the cell to play so passive a part, but rather agree with Virchow,[1] who affirms that 'the cell is not nourished, but nourishes itself.' Functional hypertrophy is therefore not to be looked upon as the mere consequence of the increased blood-supply to the active organ.

"If the assimilative activity of the cells were not augmented, the mere presence of a greater supply of nutriment would be valueless.[2]

"We shall more readily comprehend the activity of the tissue-cells—*i. e.* their behavior under various conditions and the changes they pass through, now at rest and now manifesting intense formative energy—if we consider first the vital manifestation of an organism that is unicellular, micro-organisms of bacteria and yeast-plants, and their mode of life. If we reflect on the conditions essential for the multiplication of such organisms, we note that the nature of the nutrient fluid is (next after the adjustment of the temperature) the factor of higher importance. In suitably composed fluids the fungi develop much more luxuriantly than in those that are ill-suited. But we are not thereby justified in assuming that the cell plays a merely passive part—that all it has to do is to take up the nutriment offered to it. The cell is, on the contrary, active, and its activity has a special influence on the liquid itself. It has the power to induce certain chemical changes in the liquid, to decompose certain substances contained in it, and to change

[1] *Cellular Pathology.*

[2] See Samuel's *Allg. Path.*, 1879; Paget's *Surgical Pathology*, Lect. 3.

this condition so as to adapt them for assimilation by itself. The cell does not merely take in and give out material; it acts 'catalytically' on its environment. This is proof at least that the cell possesses a high degree of spontaneity—that it has the power of making more available for its own sustenance the various forms of nutriment that come in its way.

"It is also of great interest to note that the cell is ultimately limited in its formative activity by its own products. When the amount of nutriment present is abundant, the activity of the cell comes to an end, not through the exhaustion of the supply, but through its contamination with certain products of cell-metabolism.

"Many of the substances engendered in fermenting liquids by the action of fungi tend to check the growth and multiplication of the fungi themselves; when present in quantity they may put a stop to multiplication altogether.

"The alcoholic fermentation, and the multiplication of the yeast-plant which produces it, come to an end when a certain proportion of alcohol has been generated in the fermenting liquid. In septic putrefaction the bacteria generate compounds, such as carbolic acid, which are destructive to themselves. If we may apply these facts of fungus physiology to the cell physiology of higher organisms, we find that they illustrate, first of all, this principle: that the quantity and quality of the nutritive material at the disposal of the cell have a profound influence upon its behavior; and, secondly, this other: that the cell has nevertheless an intrinsic power of utilizing this material, and of appropriating what is suitable to itself out of various combinations. Lastly, the limits imposed on the multiplication of fungi by the products of their own activity may help us to understand how the formative activity of the cells of complex organism may be temporarily checked.

"We cannot, indeed, regard the intercellular substance of the connective tissues as equivalent in significance to the products of the chemical changes induced by the bacteria. Yet the comparison may at least enable us to conceive how cell-growth may tend to limit and to check itself without the interposition of extensive resistance. In the connective tissues the formation of the intercellular substance is the limiting factor; in the epithelia it is the cohesion or cementation of the individual cells into a firm and single whole, just as in yeast fermentation it is the formation of alcohol. When the alcohol is withdrawn in the latter case, the multiplication of the yeast-fungus goes on again. So, likewise, if the intercellular substance be dissolved away from a connective tissue, or if the continuity of the epithelial mosaic be loosened or interrupted, the faculty of multiplication is again awakened in the constituent cells; or if (as in the epithelia) it has never been dormant, it is at once intensified."

Cellular activity, as found in normal development, depends upon some force which cannot be explained by chemistry and physics or without calling in the aid of the hypothesis of *vital functions*. Cells stimulated by the indwelling vital power proliferate until the typal demands of the tissues are reached. In many tissues this growth is so adjusted as to be self-limiting, as in the Haversian system of bones, in which the development is centripetally arranged, thus lessening the calibre of the enclosed

capillary vessels, and so diminishing the supply of cell-food. The innate governing principle in normal development decides that cellular activity shall set in at one point and not at another. This is beautifully illustrated in the development of the hair, glands, and the enamel organ of the teeth. These organs are formed by an infolding of the superimposed epithelium. This process begins in localized cellular activity; rapid cell-multiplication follows, and the new-formed cells sink into the subepithelial tissue. The point of greatest activity is always found in the deepest portions of the ingrowing tissue; and this activity continues until the typal demands of the special organ are met, when it ceases. No other satisfactory explanation of the action of cells can be given than that an independent life-principle resides in them which directs their growth and function. As we investigate more minutely we find that insuperable difficulties present themselves to any physical interpretation of the facts connected with living cells.

Fleming has established beyond dispute that cell division is dependent upon nucleus division. In some instances, however, the nucleus divides and a subsequent division of the cell does not follow. In this case multinuclear cells are formed. We do not know positively why cellular activity results, but it is probable that the cells are stimulated to an increased assimilation of cell-pabulum, as an increased supply of nutrition does not always produce giant-cells. Some authors hold that giant-cells or osteoclasts found in connection with resorption of bone are produced by the liberated bone-cells; but the fact that giant-cells appear in connection with the resorption of other hard tissues which do not contain bone-cells seems to establish for them an independent identity. When speaking of erosion of bone, Ziegler uses the terms osteoclasts, giant-cells, and resorption-cells as synonymous, and asserts that they arise from multiplication of exuded white blood-cells. Resorptive-cells in some cases contain but one nucleus. They are, however, considerably larger than ordinary cells, so we will use the term giant-cells in the sense of larger cells having a specialized function, whether they be multinuclear or not.

Giant-cells are found in diseases where great cellular activity exists, as, for example, in miliary tuberculosis, syphilis, myeloid sarcoma, and hyperplastic granulation-tissue; they are also found in connection with the resorption of bone in normal development, and in the roots of temporary teeth and other bodies that Nature desires to remove. They are developed in all the above-named cases unless the exuded cells are destroyed and a purulent condition produced.

Ziegler, writing of the resorption of tissue, says:

"The first stage is the formation of a zone of inflammatory infiltration around the foreign body. This is followed by the development of granulation-tissue, and at length of fibrous tissue. If the foreign body is not meanwhile absorbed, it thus becomes encapsuled. Only insoluble and compact bodies can remain quite unaltered, for resorption is, as it were, attempted, even though it be in vain. Bodies which are at all assailable are sure sooner or later to undergo changes. These ensue as follows: The migratory leucocytes, transformed into uninuclear or multinuclear formative cells, attach themselves to the surface of the object.

If this be made up of smaller parts, or if particles of necrosed tissue be mingled with it (such as decomposed blood in hemorrhagic patches), these are taken up by the cells and carried off by the white blood-cells which migrate from the blood-vessels. These migratory cells appropriate the foreign substances lying in the tissue. They let their protoplasm flow round them, and so take them up into their interior. By frequent repetition of this process granule-carrying cells are produced. According to their contents these have been variously described as fat-granule carriers, blood-cell carriers, pigment-granule cells, cinnabar-carrying cells, etc. If the foreign body be compact and not to be broken up, the cells cling to its surface. If there be accessible cavities or clefts in it, they penetrate into these. If the cells be insufficiently nourished, they become fatty and die. If new vessels are formed to supply them, they develop as granulations. Very often, indeed, multinuclear or giant-cells are found in such circumstances."

"A dead piece of bone inserted under the skin of an animal and examined a few weeks after will be found interpenetrated with vascular granulations, and the trabeculæ will be beset in many places with giant-cells. The whole process is very similar to that of physiological bone resorption." . . . .

"This process is peculiarly modified when the foreign substance is firmly connected with the surrounding tissue—when it is, in fact, a necrosed fragment of the tissue itself, such as bone or kidney. In this case the first step is the separation of the living from the dead." . . . .

"Langhans was the first to describe minutely the process by which larger foreign bodies are absorbed. He pursued the subject experimentally by producing extravasations of blood in various animals. He thus discovered the giant-cells. Heidenhain also found them in pieces of elder-pith which he had inserted in the abdominal cavity of animals. Ziegler always met them in connection with his experiments in placing cover-glasses, slightly separated, under the skin of a dog. Later experiments with sponge-grafting have demonstrated their presence and active agency in the absorption of the pieces of sponge."

Resorption of tissues or foreign substances is a purely physiological process. The pathological phase is found, not in the removal of the offending substance, but in the irritant which brought about the resorptive process. Hitherto, too much stress has been laid upon the visible expression of Nature's effort to remove the irritant, and too little on the character of the irritant itself. Pathological results may attain to the resorptive process through the action of giant-cells by reason of the juxtaposition of healthy tissue, but such conditions are incidental, and not the direct point of attack. Cells have not the power to produce pathological results, except they be pathologically stimulated, and when so stimulated they act through their own peculiar channels. I look upon giant- or resorption-cells as Nature's physiological agents, by whose aid she removes tissues which have performed their life-office, and substances which by their presence are hurtful to the animal economy. The action of giant-cells in this process belongs to the third attribute ascribed to cells—viz. that of function. They secrete a fluid which has the power of digesting the tissues in their immediate neighborhood. In

claiming this attribute for them we do not go beyond the physiological action of cells. The process of digestion is well known to every student of physiology. In the stomach glands secrete certain fluids, by whose action that which we call food is so changed that it can be taken into the blood and assimilated by different parts of the body. A failure on the part of these glands to produce their normal fluid results in what we term indigestion. Food-stuffs, unless prepared and dissolved by the fluid secreted by the glands of which we have been speaking, cannot be assimilated. We find that what is true of the digestion of food-stuffs is also true of the resorption of tissues. In order that a tissue may be removed it must first be digested by the cell-fluid, after which it can be taken up by the lymphatic system. It is true that very small particles, by reason of their minute subdivision, do enter the lymph-channels, but they are not assimilated into the general system; they are deposited in the first gland into which the lymphatic empties. Instances of this kind are found in cases of respired particles of coal- and stone-dust, and as a consequence we have the pathological condition known as the "coal-miner's" and the "stone-hewer's" lung.

As I have already said, in order that any tissue may be assimilated it must first be digested. In the cases above mentioned the soluble ferment is secreted by the giant-cells at the point of irritation. The juxtaposition of the secreting cells and the tissue to be resorbed is a matter of essential import. The ferment or fluid in question is not an exuded fluid of the blood; it is as truly a specialized fluid as are the secretions of the peptic glands of the stomach. The nature of the body to be resorbed has no more influence in the production of the secretions than have various food-stuffs which are taken into the stomach over the secretions of the stomachic glands. Then, again, resorbed and resorber must be in actual contact, as is seen in every instance where tissues are removed. The secretion acts upon the tissues found in its immediate neighborhood, whether they be living or dead. This fact is well illustrated in the resorption of the roots of temporary teeth. It matters not whether the pulp, the life of the root, be alive or dead, so long as the surrounding parts do not become purulent.

Resorption, then, is the result of the physiological action of cells stimulated by irritation to increased cellular activity; but in order that they may so act the irritation must not be too severe. If, when the pulp of a temporary tooth dies, a chronic abscess results, physiological resorption of the root cannot occur. Its removal is then accomplished by *necrosis*, and *giant-cells* are not found. Resorption by *giant-cells*, as we have seen, can only occur when the cells are stimulated to an increased assimilation of the over-supply of nutrition which is produced by the local irritant.

Morphological Appearance of Cells.

Under this head we will briefly consider *blood-corpuscles*, *epithelial* and *connective-tissue cells*.

The physical appearance of blood is that of a red fluid somewhat thicker than water. When examined under the microscope we find

suspended in the fluid (serum) of the blood small spheroidal and disc-shaped bodies known as blood-corpuscles. These blood-corpuscles or cells vary not only in form, but also in color and action. One of the disc-shaped corpuscles, seen by itself, looks slightly yellow in color, but when seen in a mass the mass is clearly red; and it is to the presence of these cells that the blood owes all its color, the other blood-cells and the serum being alike colorless. Upon the warm stage or when subjected to the action of a strong salt solution they become crenated in form (see Fig. 270, *c*, *c*); if the salt solution be displaced by distilled water, they assume their original shape for a short time, but soon become swollen and decolorized, the hæmoglobin which gives them their color being freely soluble in water.

In different animals the corpuscles vary both in size and form. In Mammalia they exist in general, like those of man, as circular discs, larger or smaller, but without nuclei. In birds and cold-blooded animals nuclei are found, but the cells, instead of being circular, are oval and larger. "The size of the corpuscles," says Foster, "seems to bear no relation to the size of the body, but, as has been pointed out by Milne-Edwards, there occasionally exists a relation between the size and the muscular activity of the animal. Thus it was found that in deer and other fleet-footed animals the corpuscles were relatively small; in Amphibia, which are comparatively sluggish, the corpuscles were relatively larger. The relation, then, that the diameter of the corpuscle would bear to the muscular activity would be in an inverse ratio. It has also been found that the higher the scale of life is advanced the smaller the diameter of these bodies becomes."

FIG. 270.

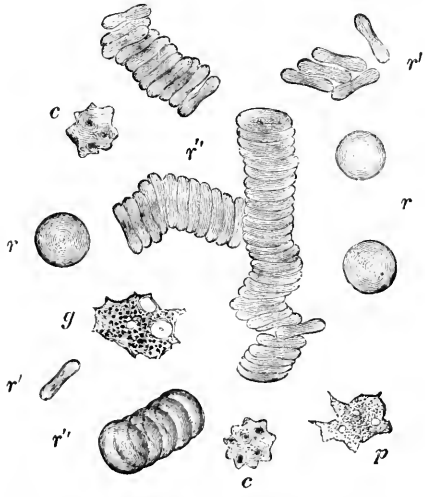

Human Blood as seen on the Warm Stage (magnified about 1200 diameters): *r*, *r*, single red corpuscles seen lying flat; *r'*, *r'*, red corpuscles on their edge and viewed in profile; *r''*, red corpuscles arranged in rouleaux; *c*, *c*, crenate red corpuscles; *p*, a finely granular pale corpuscle; *g*, a coarsely granular pale corpuscle. Both have two or three distinct vacuoles, and were undergoing changes of shape at the moment of observation; in *g* a nucleus also is visible.

Besides the red blood-cells, there are others slightly larger, not colored at all, and not circular and flat, like those above described, but round like a ball; these are termed colorless or white corpuscles. When watched under the microscope—care being taken to keep the temperature the same as that of the body—they are seen to have a peculiar amœboid movement, by means of which they are able to transport themselves from place to place; it is owing to this capacity of movement that they have received the name of wandering leucocytes. Their activity varies with the rise and fall of the temperature and the amount of oxygen present in the tissue. Under

favorable circumstances they may be seen migrating from the sides of blood-clots. When at rest the white corpuscles are spheroidal, but in a state of activity they are continually changing in shape. Sometimes they assume an irregular form, throwing out pseudopodia or prolongations (Fig. 270, *p*), such as are found in the amœba; in fact, so strong is their resemblance to that minute animal that they have been called the human amœbæ.

The white blood-cells are lighter than the red, and traverse the vascular channels upon the periphery of the vessels. They also pass through the walls of the capillaries, and are found normally in the various tissues of the body; in pathological conditions they migrate in vast numbers. Each pale corpuscle has one or more nuclei, which are surrounded by a mass of protoplasm unconfined by a cell-wall (*g*). By certain methods of staining, the nuclei are demonstrable.

In size the white corpuscles are somewhat larger than the red, averaging about $\frac{1}{3200}$ of an inch in diameter, and they always retain about the same measurement in different species of animals. They bear to the red the proportion of 1 to 500.

Besides these red and white cells or corpuscles there may also be seen in the blood free granules and fine filaments (Fig. 271). Some of the granules are round (B), others angular. In some instances the angular granules are connected with the fine filaments (A), as if they formed the nucleus from which the filaments radiate.

FIG. 271.

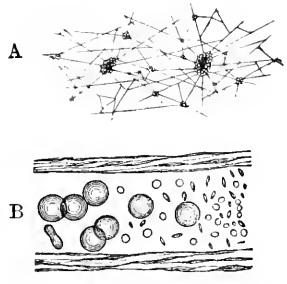

Fibrin-filaments and Blood-tablets: A, network of fibrin, shown after washing away the corpuscles from a preparation of blood that has been allowed to clot; many of the filaments radiate from small clumps of blood-tablets. B (from Osler), blood-corpuscles and elementary particles or blood-tablets within a small vein.

The blood-corpuscles and granules can be washed out from a small quantity of blood that has been allowed to clot upon a slide, and there will be nothing left but an opaque, stringy substance. This white stringy substance is fibrin, which may now be stained and examined.

The physiology of the blood is perhaps less understood than any other part of the animal organism. Many theories have been advanced as to its origin. It seems most rational to believe that one which teaches that the lymph-corpuscles become altered by contact with pre-existing white blood-corpuscles, and that these in turn are changed into red corpuscles, which in time disintegrate, their pigment being taken up by their successors.

Prudden, speaking of the origin of blood-cells, says: "Direct observation has shown that, in some animals at least, the white blood-cells can multiply by division. Whether the cells which supply the place of those which seem to be used up in the process of growth and reparation are produced in this way, and, if so, whether the division occurs in the blood- or lymph-vessels, or in the cell-spaces of the connective tissue, or in certain special organs, or whether they are produced in a manner entirely unknown to us,—these are questions not only of theoretical but of practical interest; but in spite of much research and the accumula-

tion of many observations bearing on the matter, we are still unable to give them a definite answer. Still more obscure, if possible, is the origin of the red blood-cells. Although in the adult man they seem to possess no nucleus, yet in embryonic life they certainly are furnished with that structure; we find nucleated red blood-cells. Now, it has been recently shown that in certain parts of the body in adult life cells occur which in many respects resemble the nucleated red blood-cells of the embryo; such cells are found, for example, in the spleen, in the red marrow of bones, etc. The most plausible theory in regard to the matter is that in certain parts of the body—spleen, marrow, lymph-glands, and liver—white blood-cells are produced, a part of which are changed into the red blood-cells. The so-called nucleated red blood-cells are supposed to be intermediate forms. It must be remembered, however, that this view is not established as yet, and many observers do not ascribe to the so-called nucleated red blood-cells the significance upon which the advocates of this theory insist."

Klein says that "at an early stage of embryonic life, when blood makes its appearance it is a colorless fluid, containing only white corpuscles (each with a nucleus), which are derived from certain cells of the mesoblast. These white corpuscles change into red ones, which become flattened, and their protoplasm becomes homogeneous and of a yellowish color. All through embryonic life new white corpuscles are transformed into red ones. In the embryos of man and mammals these red corpuscles retain their nuclei for some time, but ultimately lose them. New nucleated red blood-corpuscles are, however, formed by division of old red corpuscles. Such division has been observed even in the adult blood of certain lower vertebrates (Peremeschko), as well as in the red marrow of mammals (Bizzozero and Torre). An important source for the new formation of red corpuscles in the embryo and adult is the red marrow of bones (Neumann, Bizzozero, Rindfleisch), in which numerous nucleated protoplasmic cells (marrow-cells) are converted into nucleated red blood-corpuscles. The protoplasm of the corpuscles becomes homogeneous and tinged with yellow, the nucleus being ultimately lost. The spleen is also assumed to be a place for the formation of red blood-corpuscles.

"Again, it is assumed that ordinary white blood-corpuscles are transformed into red ones, but of this there is no conclusive evidence. In all these instances the protoplasm becomes homogeneous and filled with hæmoglobin, while the cell grows flattened, discoid, and the nucleus in the end disappears. Schäffer described intracellular (endogenous) formation of red blood-corpuscles at first as small hæmoglobin particles, but soon growing into red blood-corpuscles in certain cells of the subcutaneous tissue of young animals. Malassez describes the red blood-corpuscles originating by a process of continued budding from the marrow-cells. The white corpuscles appear to be derived from the lymphatic organs, whence they are carried by the lymph into the circulating blood."

Notwithstanding these differences of opinion regarding the origin of blood-cells, there is almost universal agreement as to the function performed by the blood; and it is to be hoped that with improved means

for observation we shall soon be able to solve the enigma of its derivation. That there must of necessity be some means for renewing aged cells or supplying lost ones is admitted by all, but as to the special mode of their origin there seems to be considerable doubt. The white blood-corpuscles are probably the main source of supply for the regeneration of lost tissues, osteoblasts, and the other members of the connective-tissue group. This part of the subject will be considered in detail later on.

Epithelial Cells.

A very delicate membrane forms the outer covering of the *derma* or true skin of animals, and enters also into the structure of glandular organs; to it the name *epithelium* is given.

The microscope has shown this tissue to be an aggregation of epithelial cells, differing in different situations in form and function.

Epithelial cells are derived from both *epiblast* and *hypoblast.* We will dismiss the consideration of those which have their origin in the hypoblast, and confine ourselves to the epithelium of the mucous membrane of the mouth, premising that it is derived from the same source as the skin. It is certainly analogous in form, being only slightly modified by constant immersion in the fluids of the mouth, which does not permit the oldest or outer layer to assume the corneous nature found in the most superficial layer of the skin.

The epithelium of the mouth belongs to the stratified epithelial group: it may be considered as transitional epithelium, and is composed of several layers of cells which are constantly undergoing the process of desquamation. These layers of cells are held together by an intercellular cement-substance, which exists in small quantities.

We divide the layers into three kinds: the *infant*, *older*, and *oldest*. The oldest layer can readily be studied by examining microscopically the saliva or scrapings from the tongue. Under examination this layer very plainly appears to be made up of flattened discs containing nuclei. The cells of the corneous layer of the skin, however, as a rule, do not contain nuclei. The cells vary so much in size that no definite measurement can be given.

Fig. 272.

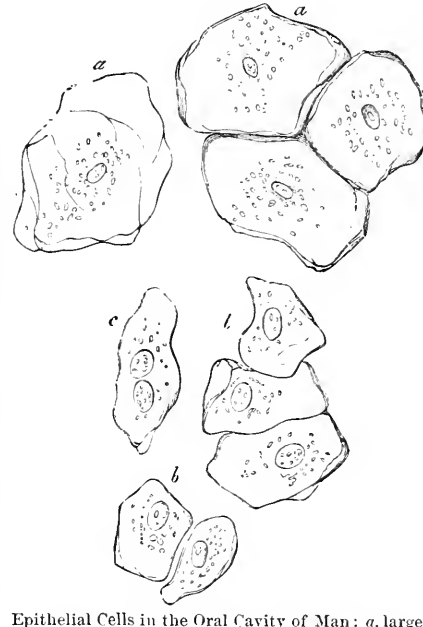

Epithelial Cells in the Oral Cavity of Man: *a*, large; *b*, middle-sized; *c*, the same with two nuclei (high power).

FIG. 273.

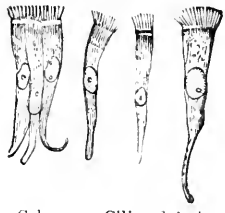

Columnar Ciliated Epithelium Cells.

In some of the cold-blooded animals the palate is covered with ciliated cells. These are for the most part spheroidal in form, and do not differ greatly from the cells above described. The most remarkable circumstance in connection with them is the movements of their cilia, which arise from the broad side of the cell. These hair-like appendages are supposed to be prolongations of the cell-protoplasm. They can be seen in the frog, and examined while yet in motion by scraping the surface

FIG. 274.

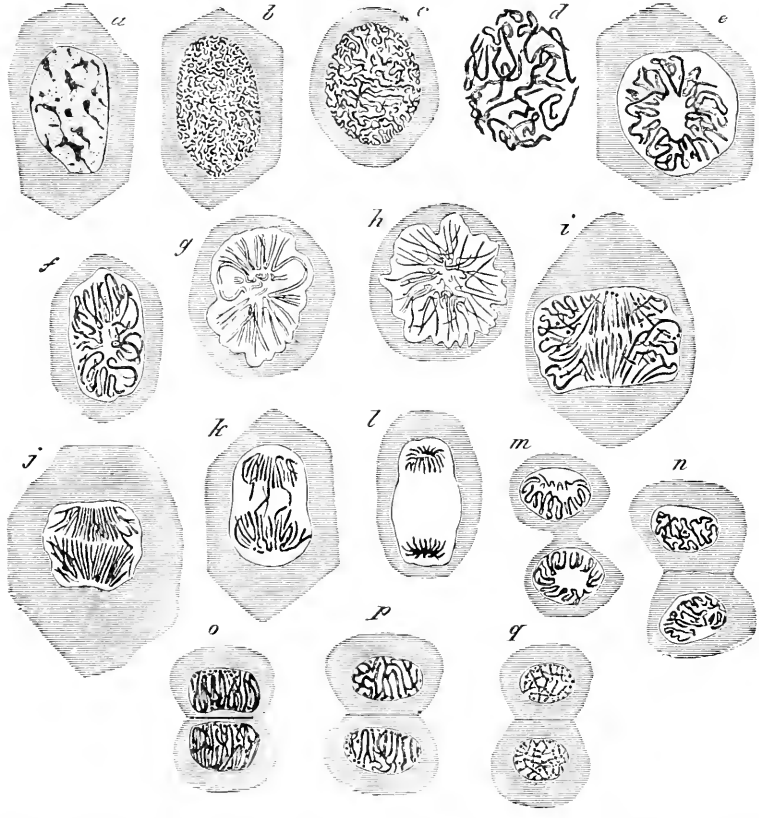

Epithelium-cells of Salamander Larva in Different Phases of Division: *a*, normal cell, by comparison with which the following changes may be noted: I. The network of filaments of the resting nucleus becomes formed into a sort of *skein*, formed apparently of one long convoluted filament; the nuclear membrane and the nucleoli disappear or are merged into the skein (*b*, *c*, *d*). II. The skein becomes arranged in the form of a *rosette*, the filaments looping in and out to and from the centre (*e*). III. The outer loops of the rosette separate so that the filament breaks into a number of V-shaped fibres arranged like a star (*aster*, *f*, *g*, *h*). IV. The V-shaped fibres separate into two groups, the ends of which are for a time interlocked (*i*, *j*, *k*). V. The two groups pass to the opposite poles of the now elongated nucleus and form a star-shaped figure (*l*) at each pole (*dyaster*). Each of the stars represents a daughter-nucleus. VI. Each star of the dyaster goes through the same changes as the original nucleus, but in the reverse order—viz. rosette (*m*) skein (*n*), and network (*o*, *p*, *q*)—passing finally into the condition of a typal resting nucleus. The protoplasm of the cell divides soon after the formation of the dyaster (*m*). Sometimes fine lines may be seen in the protoplasm, during the process of division, radiating from the poles of the nucleus, and others uniting the two daughter-nuclei.

FIG. 275.

Two Flattened and Branched Connective-tissue Corpuscles from the subcutaneous areolar tissue. Opposite *l* a secondary lamella, projecting toward the observer, is seen in optical section as a dark line.

FIG. 276.

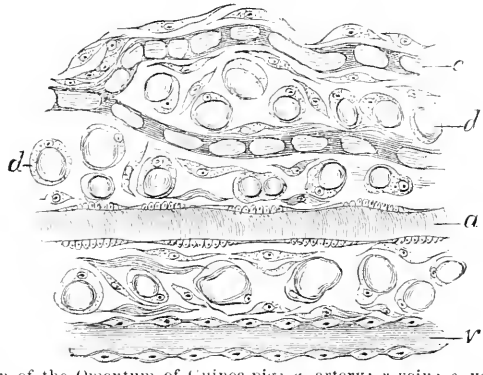

From a Preparation of the Omentum of Guinea-pig: *a*, artery; *v*, vein; *c*, young capillary blood-vessel; *d*, fat-cells formed by infiltration of ordinary connective cells with fat-globules.

FIG. 277.

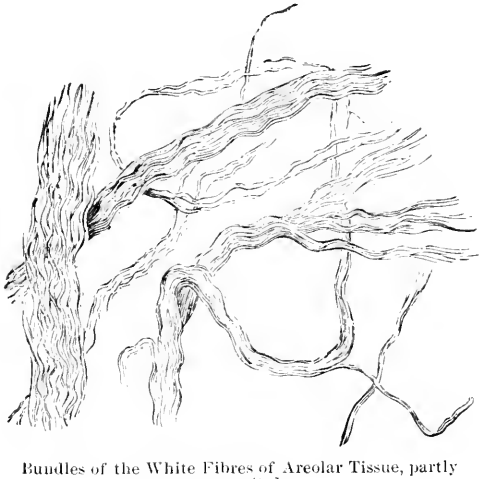

Bundles of the White Fibres of Areolar Tissue, partly unravelled.

FIG. 278.

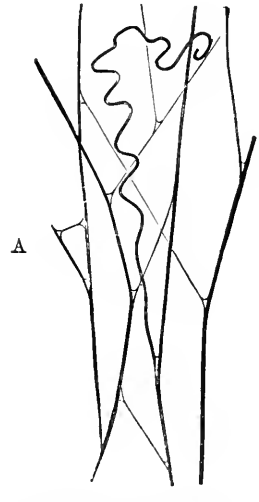

A, Elastic Fibres of Areolar Tissue, from the subcutaneous tissue of the rabbit.

of the mucous membrane and transferring the substance thus obtained to a slide, adding tepid water.

Ciliated cells are also found in the nasal passages of man, an illustration of which may be seen in Fig. 273.

The middle or older layer of cells of the buccal epithelia are more or less polyhedral in shape, and have an imbricated border: they are sometimes called "prickle cells," and generally extend beyond the oral cavity into the pharynx.

The deepest or infant layer of the epithelium of the mouth is composed of spheroidal or slightly cylindrical cells placed vertically upon the dividing-line between the epithelium and the dermal layers. It is in this layer of the rete Malpighii that cell-multiplication occurs; the

FIG. 279.

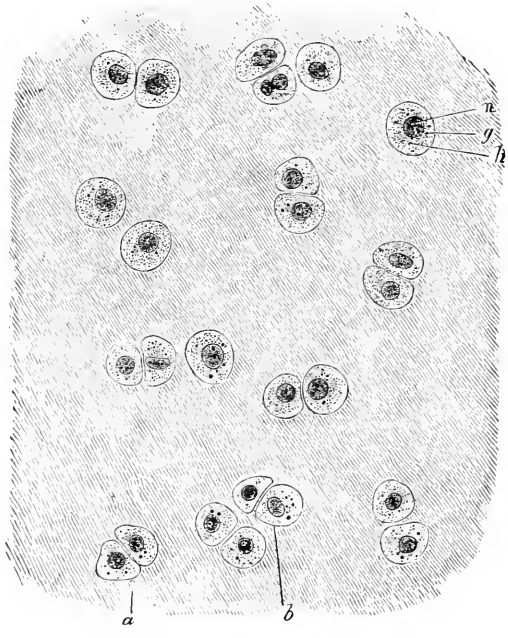

Articular Cartilage from Head of Metatarsal Bone of Man (osmic-acid preparation); the cell-bodies entirely fill the spaces in the matrix (310 diameters): *a*, group of two cells; *b*, group of four cells; *h*, protoplasm of cell, with *g*, fatty granules; *n*, nucleus.

changes whereby the cells undergo division appear first in the nucleus (see Fig. 274, after Fleming, from Schaefer's *Histology*), afterward extending to the cell-body in adult tissues.

The method of cell-growth in embryonal tissues will be considered later on, in the section on the development of the mucous membrane of the mouth.

Connective-tissue cells of the dermal layer of the mouth are of two kinds, *fixed* and *wandering* cells. The first are fibrillated, and have a definite relationship to the basement-substance, although varying in form and number in different positions. The second are spheroidal, and have been considered in our study of the white blood-corpuscles. The fixed cells may have one or more processes, and when infiltrated with fat, constitute fat-tissue.

The intercellular substance is broken up into fibres, both yellow and white. The yellow fibres are *elastic* (Fig. 278), and are more or less abundant in areolar tissue. The white fibres form the interlacing network which binds the tissues together throughout the body. They are joined in bundles, as may be seen by referring to Fig. 277.

There yet remains to be considered hyaline cartilage, which belongs to the connective-tissue group. In this tissue spheroidal flattened or angular cells, containing one or more nuclei, are seen lying in a homogeneous basement-substance (see Fig. 279), which is said to yield *chondrin* upon being boiled. The cells are sometimes finely, at other times coarsely, granular. Both the capsule which surrounds the cell and the hyaline intercellular substance possess higher refractive power than does the cell itself.

Having thus brought our brief examination of a few of the more important characteristics of cell-action and morphology to a close, it only remains to express the hope that it will stimulate the student to a better and more careful survey of the whole subject. The importance of such a survey cannot be too strongly urged upon his attention, for without definite knowledge of cellular structure it is impossible to prosecute histological inquiries with any degree of success.

We are now better able to enter upon the subject of Embryology, a subject in regard to which what we know at present is so little in comparison to what we do not know that there remains an illimitable field for our inquiries and discoveries.

Embryology.

Down to our own century, though many important truths bearing upon embryology were known to anatomists and physiologists, nothing could have been farther from their conception than the fact now universally admitted that all animals, without exception, arise from eggs.

Aristotle and his followers recognized three modes of generation—viz. oviparous, viviparous, and spontaneous generation. By the progress of investigation the last mode of generation was shown to be a thing unknown in Nature, and in 1651, Dr. William Harvey announced that there is no essential difference in the mode of generation between oviparous and viviparous animals, but that "all animals whatsoever, even the viviparous, and man himself not excepted, are produced from ova." A little later Linnæus expressed this great truth in the sentence so often quoted, "Omne vivum ex ovo;" but neither he nor Harvey appreciated the full significance of these statements, for the existence of the mammalian egg was not then dreamed of. Since then the discoveries of Von Baer, Négrier, Pouchet, and others have shown not only that "the egg is common to all living beings without exception, from the lowest radiate to the highest vertebrate, but that its structure is at first identical in all, composed of the same primitive elements and undergoing exactly the same process of growth up to the time when it assumes the special character peculiar to its kind;" and the only real difference between oviparous and viviparous animals is that in the *Oviparа* the fecundated egg is discharged from the body of the female and

deposited in some suitable receptacle, in which it is afterward hatched, while in the *Viripara* it is retained in the body of the female and there nourished till it develops into a perfect organism.

In common parlance, we understand by an egg a spheroidal body composed of a mass of yolk, surrounded by what is known as the *white of the egg*, and an outer covering or shell. But to the embryologist the envelopes of the egg are mere accessories, while the true egg—or, as it is called, the *ovarian egg*—with which the life of every organism begins, is a minute globule of protoplasm. The undeveloped ovarian egg immediately after its fertilization is uniform in appearance throughout the animal kingdom, the human ovum at this stage corresponding in structure to those which stand at the very foot of the zoological scale.

The ovarian egg is at first a mere speck of living protoplasm, but through the processes of nutrition development proceeds, and presently there appears a bright, transparent spot on the upper side of the egg near the wall or outer membrane—the nucleus, as it is called. When this albuminous spot becomes a little larger there arises in its centre a minute speck of matter slightly more opaque than the surrounding matter: this is called the *germinal spot*. At this stage of its existence, when the egg consists of a protoplasmic body containing in its interior a nucleus which in turn envelops a nucleolus, its resemblance to a cell is unmistakable; and, in fact, an egg when forming is a perfect cell-structure. But while closely resembling the cell in structure there is, nevertheless, in this ovarian mass of protoplasm a wonderful power which separates it from the cell by differences too great to be bridged over—an inherent force by which its destiny as a distinct individual is assured. Agassiz has described this difference better than most embryologists:

"While we recognize the identity of cell-structure and egg-structure at this point in the history of the egg, we must not forget the great distinction between them—namely, that while the cells remain component parts of the whole body, the egg separates itself and assumes a distinct individual existence. Even now, while still microscopically small, its individuality begins; other substances collect around it, are absorbed into it, nourish it, serve it. Every being is a centre about which many other things cluster and converge, and which has the power to assimilate to itself the necessary elements of its life. Every egg is already such a centre, differing from the cells around it but by the principle of life in which its individuality consists, which is to make it a new being, instead of a fellow-cell with those that build up the body of the parent animal and remain component parts of it. This intangible something is the subtle element that eludes our closest analysis; it is the germ of the immaterial principle according to which the new being is to develop. The physical germ we see; the spiritual germ we cannot see, though we may trace its action on the material elements through which it is expressed."

At this period of its growth the microscopic cell is as truly an independent organism as it ever becomes; it is itself the young animal, and the action of the vital principle is manifest in it from the earliest moment

of its career, *guiding* and *directing* a series of changes which result at last in the complete development of an individual perfect in its adaptations and wonderful in its mechanism. The physicist and chemist are utterly unable to explain the energy and power which throb with unceasing pulse in every atom of living matter which enters into the formation of the several parts that make up the complete organism, or tell us in what way the multitudes of cells which exist in connection with its various tissues live, grow, and form, so that at length are produced the many textures of the living thing, each perfectly fulfilling the object of its formation.

In all our study of the phenomena of embryonic development from the tiny cell we shall see how this vital power, "unlike any physical agency yet discovered, manifests a remarkable capacity, so to say, of prevision. The changes effected by *living matter* at one time are carried out, as it were, in anticipation of future change, as if the conception of what *was to be* had been acted upon even while the early changes were proceeding." We shall see how this vital force, though it imprints upon the protoplasmic germ no trace by which it can be distinguished from a fellow-germ, unfailingly clears the way for its onward development according to prearranged forms, controlling and directing its growth into the perfect structure having the capacities and powers of the parent germ. It is impossible to express in any force-terms the inherent principle by which one germ develops into an oak, and another into the bird which seeks shelter amid its foliage, or explain how typal forms and peculiarities are handed down from generation to generation, so that each plant and animal reproduces its own kind. Consider for a moment the immense number, the perfect separation, of the different kinds of animals and plants, their power of life and reproduction, and their wonderful fruitfulness.

Consider first their number. In the animal kingdom the number of living species which have been satisfactorily made out and described is more than one hundred thousand, and botanists reckon about as many different kinds of plants. Not one of this great multitude of plants and animals has ever produced a structure unlike its kind.[1] No seed of wheat has ever yielded barley, or seed of alder grown up into an oak. The egg of the hen has never been made to produce any other animal than the chick, and the egg of the frog produces only the frog. It is true that the young frog or tadpole when first hatched from the egg is unlike its parent in external appearance and habits of life. But in this and other instances the process of development goes on after the young embryo has left the egg, till at last the perfect likeness to the parent is established. Here, again, we see how the *vital power* transcends physical forces, for it controls the successive formation and disappearance of different organs adapted to the different modes of infant life, but which would be useless when the adult state is reached. For my own part, the more I look into the phenomena of embryonic development the more am I convinced that they determine "the unity of the authorship of a wonderfully complicated design, exe-

[1] It is true that *hybrids* have been produced from the mixture of two species, but they have never been known to perpetuate themselves.

cuted on a groundwork broad as time and whose scope and bearing are deep as eternity." In them we find, "not a material connection by which blind laws of matter have evolved the whole creation out of a single germ, but the clue to that intellectual conception which spans the whole series of the geological ages and is perfectly consistent in all its parts."

General Account of Embryonic Development.

In our investigations into the first stages of embryology we are of necessity confined to the lower animals. It is not possible to secure well-preserved human embryos in sufficient numbers to enable us to formulate even a theory of development, except as we arrive at our conclusions by reason of such knowledge of the processes of development as we are able to glean from the field of comparative embryology. I have found the rabbit and pig more easily obtainable than other animals, and have therefore devoted most of my time to the study of their embryos.

The human embryos of which I have had the fortune to become possessed have been two months or more old; a great many have not been in a good state of preservation; consequently, I have been obliged to seek other sources for my supply of microscopical material. Judging from the paucity of illustrations drawn from human embryos under two months, I conclude that other observers have found the same difficulty. Very valuable specimens are being constantly lost through neglect or lack of knowledge as to the methods necessary to preserve them. Noticeable as this is regarding embryos, it is much more so in the case of the *ova*. No studies—at least so far as I am conversant with the literature upon the subject—have been made upon the segmenting human ova or the first stages in the development of the blastoderm. There is a vast field yet open for study in this direction. The exact nature of impregnation has not been definitely settled, and even the processes of segmentation have not been sufficiently studied.

The most convenient and easily-obtained mammalian eggs are from the rabbit. The variations between them and human ova are no doubt considerable, but by reason of the impossibility of obtaining human ova, and the difficulty attending the study of those more closely allied to them, we are obliged to accept those of the rabbit as a compromise. Many observers have noted the changes occurring in the egg of the fowl in its early stages; these very closely resemble those which occur in the mammalian egg. The former eggs are *oviparous*—that is, the ova are produced and developed by incubation outside the body; while the latter are *viviparous*, brought forth alive, the period of incubation being within the body.

Mammalian eggs come from two ovaries, which are said to produce ova alternately. In the development of the ovaries the cylindrical epithelium which covers their surface is by a process of involution enclosed in the connective-tissue substance of the ovary at many points in the form of solid buds or cords. These soon become detached from the surface epithelium, and set up a rapid process of cell-proliferation, in a

short time breaking up into small oval or irregularly-formed masses of cuboidal or polyhedral-shaped cells. These are surrounded by the connective tissue of the ovary, which by condensation forms one of the coats of the *Graafian follicles*, as the points in which the ova are developed are called.

Rapid differentiation now occurs inside the connective-tissue envelope, until the ovum which occupies the central portion is surrounded by several distinct layers of cells. As development progresses the Graafian follicles approach the surface and rupture at regular periods. The ripe ovum, when set free by the rupture of the mature Graafian follicle, is taken up by the fimbricated ends of the Fallopian tube. Impregnation generally occurs in the upper third of the Fallopian tube: unimpregnated eggs soon perish.

Before proceeding to a study of the more complicated development of the embryo of the rabbit, human, and pig, we will consider that of the tadpole. The ovum—by a process of segmentation—consists of a vast number of cells which form a double membrane within the vitelline membrane. This is called the *blastoderm*. In the fresh-laid egg the blastoderm consists of two layers of cells, an internal and an external. Shortly after incubation in the region of the *primitive trace* there appears a thickening of the blastoderm, which results in the formation of a middle layer. The blastoderm now consists of three layers: the external, or *epiblast;* the internal, or *hypoblast;* and the middle, or *mesoblast.*

If at this stage of development we examine a longitudinal section of the egg of a frog, the blastoderm will be seen in profile (see Fig. 280). The anterior portion (2), which occupies the position of the head, is thicker than the posterior part, or tail (3). As development progresses the ovum more nearly approximates the shape of the tadpole, and the tail assumes the more prominent part (Figs. 281, 282, and 283). Concomitant with the changes seen in profile, other changes are occurring. These can be demonstrated by making cross-sections of the body (Fig. 284). Arising at A, A are two processes which extend longitudinally the entire length of the tadpole, occupying a dorsal position. Between these two plates or ridges (B) a groove is seen, which, as the plates develop, naturally deepens (Fig. 285, B). The plates grow rapidly, and, folding together, form a canal in which is developed the spinal cord and nerve-centres (Fig. 286, B). Around this canal are developed the vertebræ, which appear first as cartilaginous matrices, but which afterward become ossified (C, C).

About the time the dorsal plates are seen the abdominal plates arise from the under side of the blastoderm, and, growing rapidly, completely enclose the hypoblastic layer within the abdominal cavity (Fig. 287). Within the latter cavity the remains of the vitellus are enclosed.

The hypoblast gives rise to the lining membrane of the alimentary canal. At first this is a closed sac or pouch, without either anterior or posterior outlet. As development progresses, an involution of the epiblastic layer, which finally unites with the hypoblastic layer of the intestinal canal, gives rise to the mouth at the anterior part, while a similar indipping at the posterior end forms the rectum (Fig. 283).

Having thus briefly considered the stages of development in the tad-

FIG. 280.

Diagram of Frog's Egg, in an Early Stage of Development, longitudinal section: 1, thickened portion of external blastodermic layer; 2, anterior extremity of the embryo; 3, posterior extremity; 4, internal blastodermic layer; 5, cavity of vitellus.

FIG. 281.

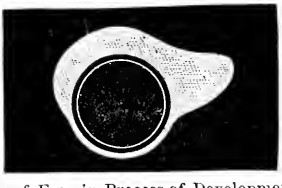

Egg of Frog in Process of Development.

FIG. 282.

Egg of Frog, farther advanced.

FIG. 283.

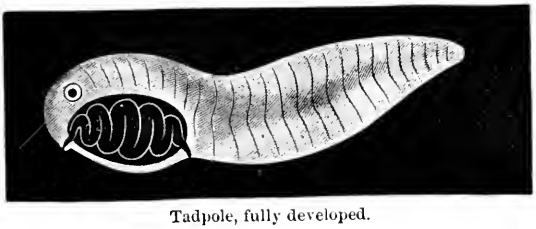

Tadpole, fully developed.

FIG. 284.



Cross-section of Frog's Egg, showing blastoderm same age as Fig. 280: A, A, lateral folds situated upon either side of groove B.

FIG. 285.



Cross-section of Frog's Egg, same stage of development as seen in Fig. 281: A, A, lateral processes; B, neural groove.

FIG. 286.

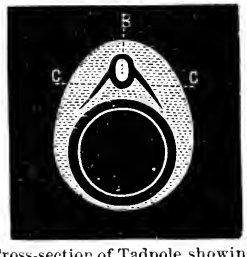

Cross-section of Tadpole, showing same stage of development as seen in Fig. 282: B, neural canal; C, C, lateral processes of spinal column.

FIG. 287.

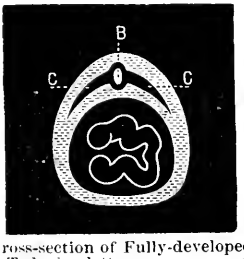

Cross-section of Fully-developed Tadpole: letters same as seen in Fig. 286.

pole, we are better prepared to take up the study of the more complicated processes as seen in the evolution of the ovum of the rabbit as it develops into the embryo.

After leaving the ovaries the ovum of the rabbit passes slowly down

FIG. 288.

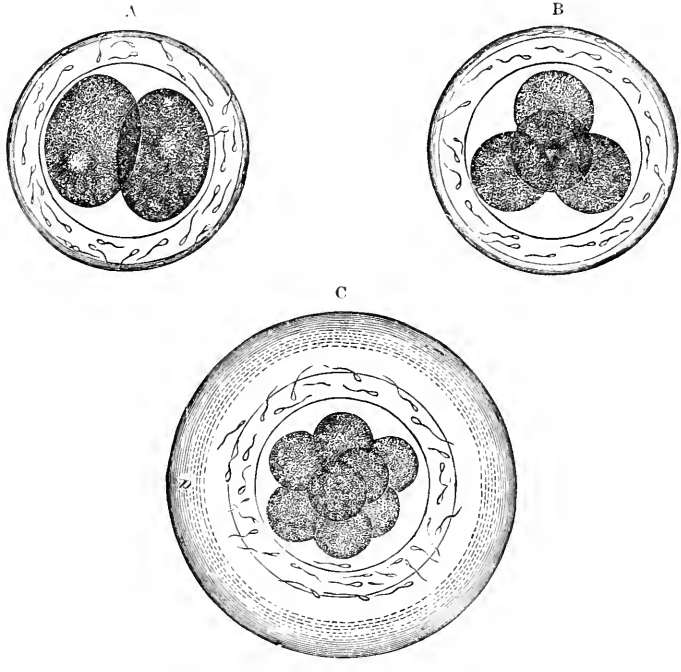

Three Stages in the Segmentation of the Rabbit's Ovum (from Quain's *Anatomy*, after Bischoff): A shows the division of the ovum into two nearly equal masses; B, the formation of four spheres by division of the two of the preceding stage; C, the stage with eight segmentation-spheres.

FIG. 289.

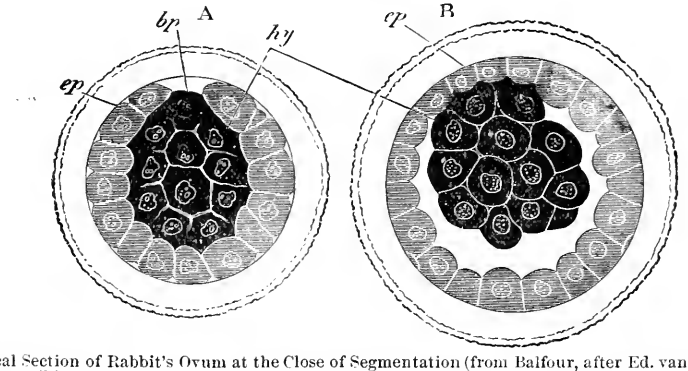

Optical Section of Rabbit's Ovum at the Close of Segmentation (from Balfour, after Ed. van Beneden): *ep*, epiblast; *hy*, primitive hypoblast; *hp*, spot where the epiblast has not yet grown over the hypoblast.

the Fallopian tube, where it meets the spermatozoa, impregnation taking place in the upper third of that tube, and the ovum reaching the uterus

about the fourth day. In their course through the Fallopian tube nearly all ova become coated with albumen, this covering attaining its greatest thickness in the egg of the fowl, where it is commonly known as the white of the egg.

Segmentation in the ovum of the rabbit occurs throughout the whole structure, but in the egg of the fowl it is less complete, being confined to one point on the surface. In the mammalian egg the process of segmentation is in all probability by segmentation of the nucleus first, division following in the cell-body, as in the division of cells in general. (See Fig. 274, p. 536.)

The ovum of the rabbit first divides into two parts, these again into four, then into eight, and so on until the ovum has become infinitely subdivided into hundreds of minute cells. These myriad cells are in fact the component parts of the young rabbit that is to be. They will undergo certain modifications to become muscle-cells, bone-cells, blood-cells, and so on, adapting themselves to the very different tissues and organs they are to build up. All these cells have descended from a common protoplasmic mass, yet they have as much "their definite and appointed share in the formation of the body now as at any later stage of its existence."

After segmentation the larger cells arrange themselves upon the periphery, enclosing the smaller ones in the central portion. The outer layer of cells is called the *epiblast*, and the inner the *hypoblast*.

The ovum has by this time reached the uterus, and consists of a spherical-shaped vesicle (Figs. 290, 291). Development now proceeds

FIG. 290.

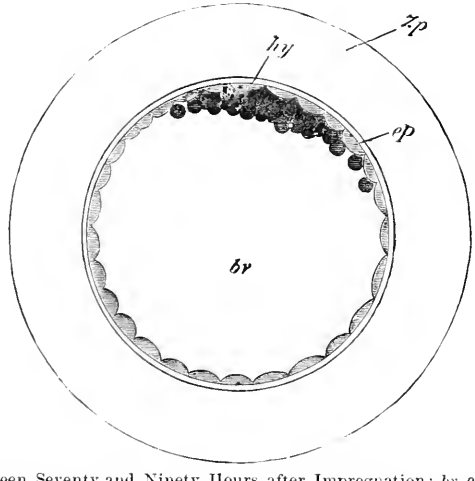

Rabbit's Ovum between Seventy and Ninety Hours after Impregnation: *br*, cavity of blastodermic vesicle; *ep*, epiblast; *hy*, primitive hypoblast; *zp*, zona pellucida.

very rapidly. The hypoblastic layer of cells, which occupied only a small spot upon the inner side of the epiblastic layer, gradually spreads in such a manner as to form an inner layer to the epiblast, which in turn encloses the former as a blind sac or pouch, within which is found the remains of the vitellus.

Outside these two layers the *zona pellucida* forms another coating. It, however, does not play any essential part in the further develop-

FIG. 291.

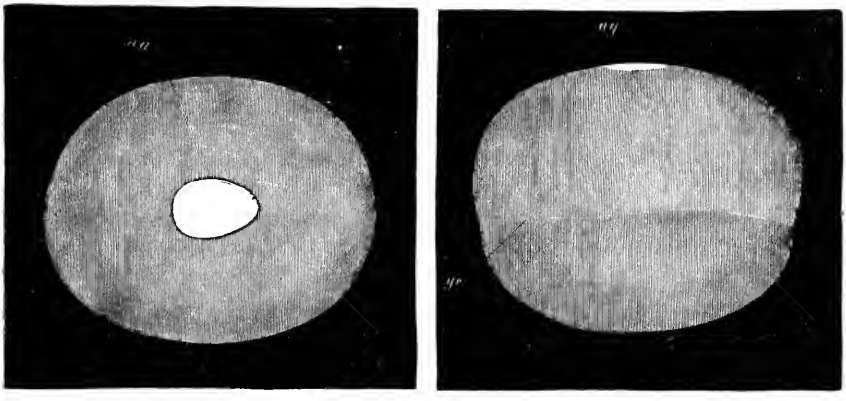

Diagrammatic views of the Blastodermic Vesicle of a Rabbit on the Seventh Day (from Balfour, after Ed. v. Beneden): In the left-hand figure the vesicle is seen from above; in the right-hand figure, from the side. The white patch (*ag*) is the germinal area; and the slight constriction (*ge*) marks the limit to which the hypoblast has extended.

ment of the embryo, at least in so far as we are to consider the subject; and henceforth we will not mention it.

This *embryonic area* is the result of the thickening of the hypoblast at the point where the development of the *primitive streak* will pres-

FIG. 292.

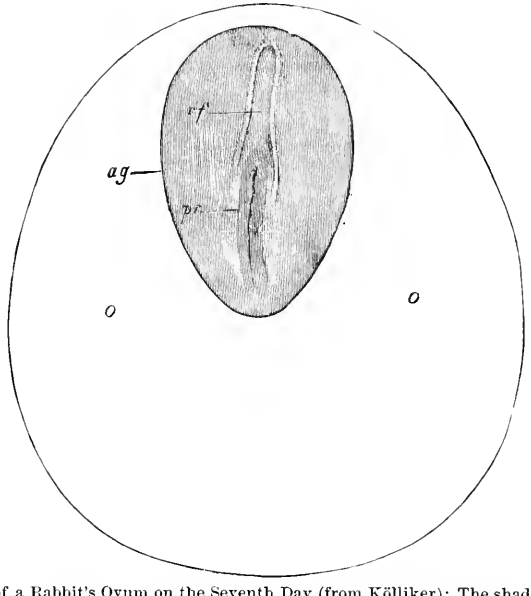

Embryonic area of a Rabbit's Ovum on the Seventh Day (from Kölliker): The shaded part (*ag*) is the embryonic area; *oo* is the region of the blastodermic vesicle immediately surrounding the embryonic area, into which the mesoblast has already spread, and in which blood-vessels will shortly appear; *pr*, primitive streak; *rf*, medullary groove.

ently appear. Previous to the formation of the latter, however, there is formed a third layer, which locates itself between those already developed, and is known as the *mesoblast*. It is mainly produced by the proliferation of the cells of the epiblast (Fig. 292).

The cellular activity of the epiblast proceeds rapidly, and results in the formation of two medullary plates which arise in parallel rows, between which lie the *medullary groove* or primitive streak. At the anterior portion, in the very first differentiation of the groove, a dark spot is seen, known as the "nodal point of Hensen," which subsequently marks the front part of the groove. Its signification is not exactly known.

The medullary plates develop rapidly, expanding at their anterior portion into a spatula-shaped crescent (Fig. 293). This gives rise to

FIG. 293.

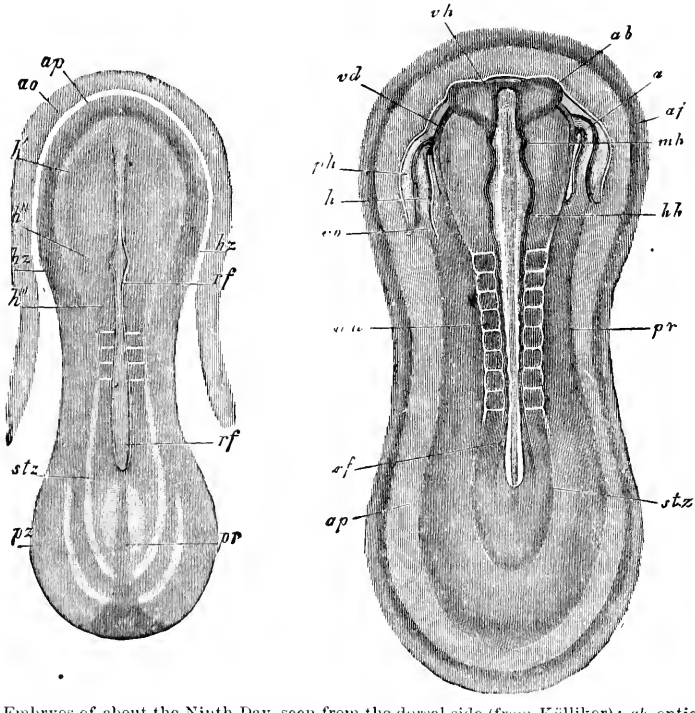

Rabbit Embryos of about the Ninth Day, seen from the dorsal side (from Kölliker): *ab*, optic vesicle; *af*, amnion; *ap*, area pellucida; *h* and *hz*, heart: *h'*, medullary plate in region of future fore-brain; *h''*, medullary plate in region of future mid-brain; *hh* and *h'''*, hind-brain; *mh*, mid-brain; *ph*, pericardial section of body-cavity; *pz*, lateral zone; *pr*, primitive streak; *rf*, medullary groove; *str*, vertebral zone; *uw*, protovertebræ; *vh*, fore-brain, *vo*, vitelline vein.

the cephalic end of the embryo. The first indication of the vertebral column is seen about the eighth day, in the formation of the first pair of somites. They are located in the region of the neck, and mark the line of union of head and trunk. The latter gradually elongates by the addition of other pairs of somites, the growth in length being from the first-formed somites caudal-ward. The medullary groove deepens as

the embryo grows older; the medullary folds become higher, and finally unite over the medullary groove, which they have made by their growth. The union of the sides begins at the anterior part. The canal thus formed is called the *neural* canal, and locates the spinal cord. The caudal end grows rapidly, pair after pair of somites being added, until at the twelfth day the embryo presents the appearance seen in Fig. 294.

FIG. 294.

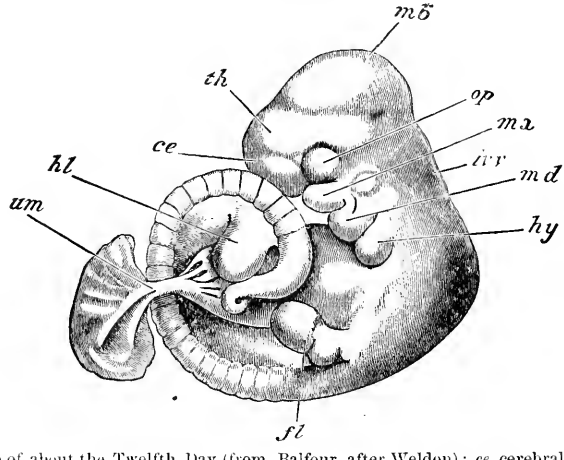

Rabbit Embryo of about the Twelfth Day (from Balfour, after Weldon); *ce*, cerebral hemisphere; *fl*, fore limb; *hl*, hind limb; *hy*, hyoid arch; *iv*, *v*, fourth ventricle; *mb*, mid-brain; *mx*, maxillary arch; *md*, mandibular arch; *op*, eye; *th*, thalamencephalon; *um*, umbilical stalk.

The embryo rabbit of twelve days has reached about the stage of the human embryo of four weeks and the pig 1 cm. in length.

In describing the rabbit embryo of twelve days Foster and Balfour say: "The latter stages in the development proceed, in the main, in the same manner as in the bird. The cranial flexure soon becomes very marked, the mid-brain forming the end of the long axis of the embryo (Fig. 294, *mb*). The sense-organs have the usual development. Under the fore-brain appears an epiblastic involution giving rise both to the mouth and to the pituitary body. Behind the mouth are three well-marked pairs of visceral arches. The first of these is the mandibular arch (Fig. 294, *md*), which meets its fellows in the middle line and forms the posterior boundary of the mouth. It sends forward on each side a superior maxillary process (*mx*), which partially forms the anterior margin of the mouth.

As the embryo increases in length, the convexity of the spine becomes greater, and the head and tail ends approximate each other. The chin rests hard upon the breast, and the caudal convexity comes in contact with the forehead. The limbs are seen as buds springing off from the sides of the body (*fl* and *hl*). The umbilical stalk (*um*) arises from the concave surface of the embryo and extends posteriorly.

As we have before said, a sufficient number of human embryos under four weeks of age have not been obtained to establish any definite description of development prior to that age. The earliest authenticated observations were made by Allen Thomson (see Fig. 297, human embryo

of four weeks, somewhat enlarged). The mandibular arch (*c*) and the maxillary arch (*d*) are quite plainly shown.

The proportion of the cephalic as compared with the caudal end of the human embryo is not as great as that seen in the rabbit. Our next illustrations (Fig. 295) show the human embryo in various stages of

FIG. 295.

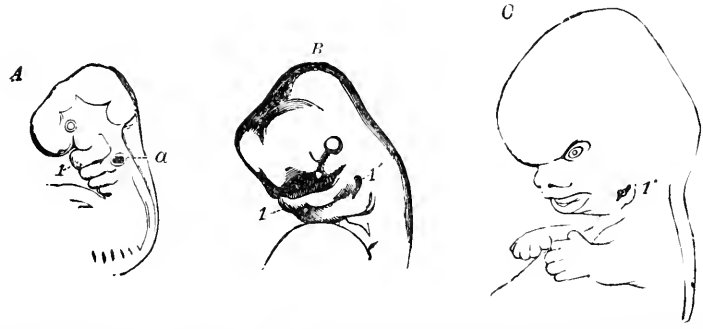

Figures illustrating the Formation of the Face in the Human Embryo (from Quain's *Anatomy*): *A*, head of an embryo of about four weeks (after Allen Thomson): 1, mandibular arch; *a*, ear. *B*, head of an embryo of about six weeks (after Ecker): 1, mandibular arch; 1', hyomandibular cleft. *C*, head of an embryo of about nine weeks (after Ecker).

development: *A*, four weeks, corresponding to pig embryo 1 centimeter in length; *B*, six weeks, shows the same progress in development as seen in fœtal pigs $1\frac{1}{2}$ centimeters; while the last, *C*, equals in length a pig embryo $2\frac{1}{2}$ centimeters.

Having thus shown the comparative ages and stages of development in fœtal life, we will confine ourselves in our further study largely to pig embryos, the supply of which in a good state of preservation is unlimited.

Development of the Jaws and Buccal Cavity.—The first indication of the formation of the oral cavity is seen very early in the life-history of the embryo. Considerable difference of opinion is recorded regarding the exact time of its formation in the human embryo. In Fig. 296, representing the twenty-fifth or twenty-eighth day of fœtal life, the wide cavity seen at (6) represents the posterior portion of the *buccal* cavity. The growth of the maxillary arches closes this cavity anteriorly. Its floor is formed by the inferior maxillary arches (4). These arise from the first pharyngeal arches. The superior maxilla arises from three separate points. On either side of the face a process springs off from the first pharyngeal arch (one side of which is shown at *d* in Fig. 297). The processes pass downward and forward, and unite with the sides of the nasal process.

From the frontal prominence (1) the third process, *the incisive*, grows downward, and fills in the space between the ends of the two preceding processes. By the union of these three processes the superior maxilla is completed. Failure of union between the middle and two lateral processes gives rise to the deformity known as *hare-lip*. This may be simple, and occur on either side at the juncture of the intermaxillary bones with the lateral processes, or in the median line at the point of

union of the two intermaxillary bones themselves; or it may be double, by reason of the non-union on *both* sides.

Development of the Palate.—The plates which form the hard palate arise from the lateral processes of the superior maxilla and grow toward each other, uniting in the median line. Previous to their development and union the buccal cavity and nose are as one cavity. The separation is usually completed by the end of the second month.

When for any reason union does not occur between the two plates, there results what is known as *cleft palate*. This is very apt to accompany *hare-lip*, the same causes which give rise to the latter operating to prevent the normal development of the palate bones, which, as we have seen, follow the development of the intermaxillary bones.

FIG. 296.

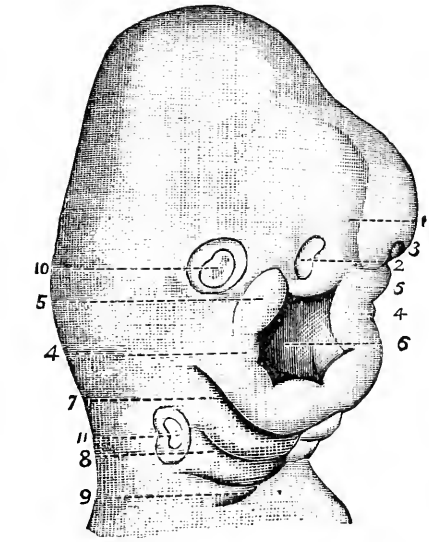

Face of an Embryo of Twenty-five to Twenty-eight Days (magnified fifteen times): 1, frontal prominence; 2, 3, right and left olfactory fossæ; 4, inferior maxillary tubercles, united in the middle line; 5, superior maxillary tubercles; 6, mouth or fauces: 7, second pharyngeal arch; 8, third; 9, fourth; 10, primitive ocular vesicle; 11, primitive auditory vesicle.

FIG. 297.

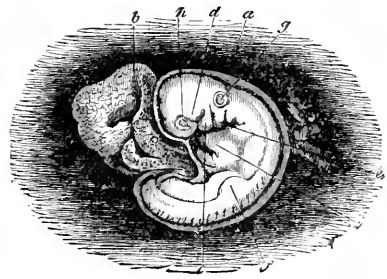

Embryo removed from the Ovum, and magnified: *a*, amnion; *b*, yolk-sac; *c*, mandibular arch; *d*, maxillary arch; *e*, hyoidean arch; behind this are the first and second branchial arches; *f*, rudiment of fore limb; *g*, auditory vesicle; *h*, eye; *i*, heart (× 5).

Turning our attention now to the inferior maxilla, we see, by referring to Fig. 294, that the inferior or mandibular arch also arises from the first pharyngeal arch (*md*). In the human embryo these processes are said to have been seen as early as the fifteenth to the eighteenth day of fœtal life. They arise in pairs, as do the lateral processes of the superior maxilla, and grow very rapidly, union occurring in the median line at about the twenty-eighth day. (See Fig. 296.)

The maxillæ arise as solid buds from the mesoblastic layer, and are covered externally by the epiblast. The maxillary bones belong to the class of *splint* bones, and are not preformed in cartilage, but ossify by what I term *interstitial ossification*.[1]

With the development of the maxillæ the anterior boundaries of the oral cavity are formed. Posteriorly, there is seen a "fœtal septum" between the forming cavity and the upper end of the intestinal canal; as the buccal cavity and the upper end of the intestinal canal near each other the septum diminishes in width, and finally disappears entirely.

[1] My own classification. See section on Calcification.

In the viviparous family the perforation of the fœtal septum occurs, in most cases, before birth; when, however, it does not occur, there arises a pathological condition known as impervious œsophagus.

Of necessity, the lining membrane of the mouth is formed from the involution of the epiblast. The point of union between the epiblastic and hypoblastic layers is located at variable distances from the upper end of the œsophagus, even to the union of the latter with the cardiac end of the stomach.

Meckel's Cartilage.—The central portion of the inferior maxilla, very soon after the union of the two lateral processes, becomes differentiated into a cartilaginous cord which serves to strengthen the jaw. To this band or cord the name of the discoverer, *Meckel*, has been given. It is formed in two parts arising from the mallei of either side, which unite, as do the lateral processes of the jaw, at the symphysis mentis. The cartilaginous matrices of the bones of the ear become directly ossified, as does the Meckelian cartilage of the jaw. The former undergo ossification about the third month.

FIG. 298.

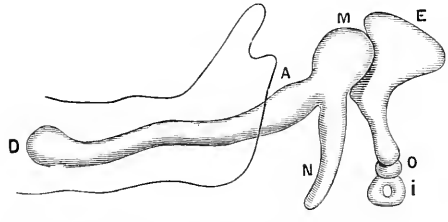

Meckel's Cartilage from Human Embryo of Forty to Forty-two days, and before the appearance of the maxilla y bone (magnified ten diameters): A, enlargement of cartilage near its union with the neck of ma leus; D, union with cartilage of opposite side; M, head of malleus; N, handle of malleus; E, cartilage of the incus; i, cartilage of the stapes; O, cartilage of the os lentieulare. The outlines of a jaw have been added to the figure to show the relative position occupied by the cartilag in the jaw. (After Magitot and Robin, Dean's translation.)

Regarding Meckel's cartilage very little has been written, and I deem the reason to lie in the fact that very little study has been given to the subject of maxillary ossification. Foster and Balfour, speaking of the development of the mandibular arch of the chick, say: "In the inferior maxillary process two developments of cartilage take place—a proximal and a distal. The proximal cartilage is situated at the side of the periotic capsule, but is not united with it. It is known as the *quadrate*, and in the early stage is merely a small knob of cartilage. The quadrate cartilage ossifies as the quadrate bone, and supplies the permanent articulation for the lower jaw. The distal rod is called Meckel's cartilage; it soon becomes covered by investing (membranes) bones, which form the mandible, and its proximal end ossifies as the *articulare*."

FIG. 299.

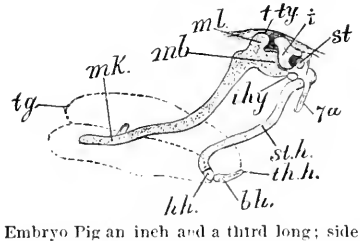

Embryo Pig an inch and a third long; side view of Mandibular and Hyoid Arches (Parker): *tg*, tongue; *mk*, Meckelian cartilage; *ml*, body of malleus; *mb*, manubrium or handle of the malleus; *tty*, tegmen tympani; *i*, incus; *st*, stapes. The rest of the letters refer to the hyoid arch.

Regarding its development, Foster and Balfour simply quote from Parker's account of the pig: "In a somewhat later stage (Fig. 299) the upper end of the mandibular bar, without becoming segmented from the ventral part, becomes distinctly swollen, and clearly corresponds to the quadrate region of other types. The ventral

part of the bar constitutes Meckel's cartilage (*mk*). In the course of further development the Meckelian part of the mandibular arch becomes enveloped in a superficial ossification forming the dentary. Its upper end, adjoining the quadrate region, becomes calcified, and then absorbed, and its lower, with the exception of the extreme, is ossified and subsequently incorporated in the dentary." Tomes says: "About the fortieth day a centre of ossification appears in the mandibular process, which, spreading rapidly, soon forms a slight osseous jaw outside Meckel's cartilage, which is not, however, in any way implicated in it, and very soon begins to waste away; so that by the end of the sixth month it has disappeared. That end of it alone which extends up to the tympanum does not waste away, but becomes ossified into the malleus. There are, however, observers who hold that in some animals, at all events, Meckel's cartilage plays a more active part in the ossification of the jaws." Dean agrees with the authors above quoted on all essential points.

The disappearance of Meckel's cartilage is accomplished by calcification, and afterward by ossification. The development of bone in the jaw begins in the embryonic connective tissue surrounding Meckel's cartilage; the latter, occupying the central portion of the jaw, is sur-

FIG. 300.

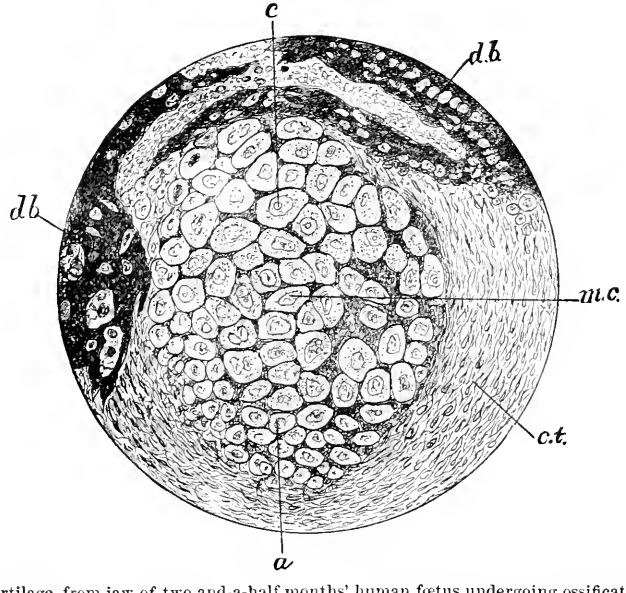

Meckel's Cartilage, from jaw of two-and-a-half months' human fœtus undergoing ossification: *a*, normal cartilage-cells; *c*, enlarged cells containing calcific material; *db*, *db*, developing bone; *ct*, connective tissue (× 250).

rounded by the connective tissue of the mesoblastic layer, which in turn is covered externally by that of the epiblast.

Development of bone in the inferior maxilla begins in the mesoblastic layer prior to the differentiation of the periosteum, about the fortieth day. As the forming bands of bone thicken they encroach upon Meckel's cartilage, which is also undergoing calcification. Under the

influence of the osteoblasts the cartilage is broken down and becomes ossified and incorporated into the substance of the maxilla. These changes are very plainly shown in the accompanying cut, from a photomicrograph (Fig. 300).

Ossification of Meckel's cartilage differs from that known as *intercartilaginous;* in the latter case there is rapid proliferation of the cartilage-cells, the cartilaginous head (femur) increasing in size in proportion to the encroachment of the ossification zone. This does not occur in ossification of Meckel's cartilage. There is no increase of cartilage-cells, except at the points of articulation, where true intercartilaginous ossification occurs. In the body of the jaw the cartilage simply becomes calcified, and afterward ossified and incorporated into the substance of the maxilla, as before stated. It entirely disappears before the fifth month—not by *wasting* away, but by ossification. This change begins, as we have seen, at two and a half months; at three months it is almost complete, and at four months, in nearly every case which I have examined, no trace of the cartilage remains. In the pig it persists much longer, and is unaffected by ossific processes in embryos ten centimeters in length.

Development of the Blastoderm.

In the unincubated chicken egg the blastoderm is composed of two layers—the epiblast and the hypoblast. There is little or no change observable until after the eighth hour of incubation, but between this and the twelfth hour marked changes occur. Cross-sections of the chick at this time will show a decided proliferation of the epiblastic

Fig. 301.

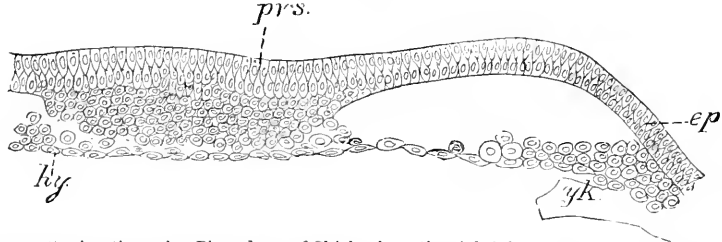

Transverse Section through a Blastoderm of Chick, about the eighth hour after incubation (after Balfour); the section passes through the middle of the primitive streak: *prs*, primitive streak; *ep*, epiblast; *hy*, hypoblast; *yk*, yolk of the germinal wall.

layer in the region of the primitive streak. The epiblast, previous to this time, is formed of a single layer of cells somewhat oval in shape, due to the lateral pressure of fellow-cells.

The hypoblast consists of a single layer of cells, which lie parallel with the surface of the blastoderm, while the epiblastic layer stands, palisade-like, upon the surface. Between the flat layer of the hypoblast and the proliferated cells of the epiblast, are seen a few scattering cells which appear to have arisen from the hypoblast, but the greater part of the thickening is from the epiblast.

There is little or no change appreciable in the histological appearance of the blastoderm until about the eighteenth or twentieth hour, when the

epiblast—now composed of one or more layers of cells—is seen to have separated from the mass of proliferated cells which lie beneath it. It is at this juncture that the *mesoblast* may be said to have assumed a separate entity.

The mesoblast is composed, as we have seen, of cells derived from both hypoblast and epiblast, but chiefly from the latter. About the twentieth hour, if the cells of the mesoblast are examined with a high power (Zeiss, $\frac{1}{12}$ oil im.), it will be seen that they are stellate in form. They take the stain similarly to the cells of the epiblast, and it is only in carefully-prepared specimens—studied with high powers—that we are able to detect any difference. They lie in a bed of protoplasm, and it is from this fluid—with which they are constantly bathed—that they derive their nourishment. They are simply nucleated structures, each containing numerous granular particles. They are the *bioplasts* of Beale, the nuclei of the future cells of the connective-tissue group. They have no cell-body, and consequently no cell-limit or wall. As they advance in age they gradually accumulate around themselves formed material, probably the undigested or unassimilated portion of the surrounding protoplasm. They thus assume distinctive and characteristic forms. Their processes gradually become thicker and more pronounced, so as to be visible even with low powers. The changes in the cells can now

FIG. 302.

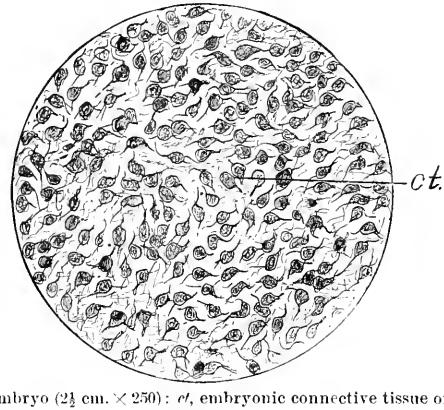

Porcine Embryo (2½ cm. × 250): *ct*, embryonic connective tissue of mesoblast.

be seen in the lower jaw of a fœtal pig two and a half centimeters in length (Fig. 302).

In the development of the oral cavity and associate parts we do not have to do with the hypoblastic layer of the blastoderm, so we will hereafter confine ourselves to the head of the embryo.

The epiblast in an embryo pig 1 cm. in length is composed of one or more layers of nuclei or bioplasts lying in a bed of protoplasm. With low powers they appear in no manner different from the underlying mesoblastic cells, except that the nuclei are closer together; and in sections stained with hæmotoxylon and eosin assume a darker hue than those of the mesoblast. The epiblast now constitutes the "infant" layer of the epithelium, being the deepest layer of the rete Malpighii.

It surrounds the lower jaw, forming a lining for the mouth and an outer coat for the jaw.

The jaw is a process which has budded off from the main body of the blastoderm, and is composed of a layer of mesodermic tissue sur-

FIG. 303.

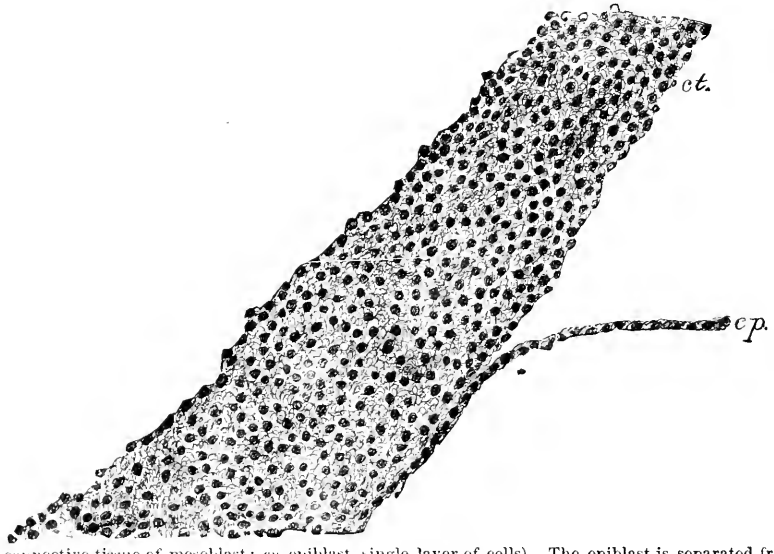

ct, connective tissue of mesoblast; *ep*, epiblast (single layer of cells). The epiblast is separated from the mesoblast mechanically.

rounded by a vesicle or sheath of the epiblast (Fig. 303). Here, then, we have an excellent opportunity to study the several tissues which arise from these two layers of the blastoderm, as far as the microscopical appearances are concerned. A 1 cm. pig embryo presents about the same stage of development macroscopically as found in a human embryo of four weeks. Histologically, it may be compared with a chick of from twenty-four to thirty-six hours or a rabbit embryo of twelve days.

PRODUCTS OF THE EPIBLAST AND MESOBLAST.

Let us first consider some of the products of the epiblastic layer, or, as we shall hereafter call it, the *epithelial* layer. These are *nails, hairs, glands*, and the *enamel organ*.

Development of Nails.—The nails are appendages of the epidermis, and are developed by an accretion and hornification of the cells which constitute the epithelial layer. Desquamation does not occur, but the cells coalesce, and, becoming glued together, form the nails. The nails can be resolved into their cellular elements by the use of dilute nitric acid.

In nails we distinguish three portions—the body, nail-groove, and nail-bed. The nail arises from the nail-bed by a hornification of the epithelium of that portion; it increases in thickness by the addition of cells from the under side, the nail being thickest at its free border. It

is attached along its lateral borders to the nail-grooves, which consist of folds in the skin. The nail merges by almost insensible gradations from the corneous layer of the skin in its posterior portion into the hornified nail. The sides of the nail are not soft, and do not pass gradually from the corneous layer of the skin, but are completely hornified down to their attachment to the skin in the lateral grooves.

The nail is developed in the *lunula*—as the nail-bed is sometimes called—from a matrix of the epithelial cells constituting the *rete Malpighii*, which, thickening, prevents the blood-vessels of the corium from showing so plainly as in the body, and accounts for the lighter color of that portion of the nail. Between the nail and the corium are seen the *infant* cells of the Malpighian layer, constituting only a single layer near the free margin, but gradually becoming thicker toward the posterior part of the nail-body. The corium, which underlies the nail, and is situated between it and the bone, does not differ essentially from the corium of other portions of the skin. The papillæ are somewhat longer, and are inclined slightly forward by the outward growth of the nail, which is firmly attached to the corium, and through it to the periosteum of the bone. The vascular system differs in no manner from that of the other parts of the corium; the capillary vessels end in capillary loops which supply nourishment to the Malpighian layer. This layer gradually becomes considerably thickened, and, folding upon itself, forms a shallow pocket or groove which will in time be occupied by the nail-root. This infolding is not unlike that formed for the glands, hair, and enamel organ.

The cells which have been pushed up from the nail-bed have assumed a peculiar translucent appearance, and do not take the stain freely. They are becoming hornified by desiccation and deposition into the cell-body of a greater proportion of carbon and sulphur, both of which are generally found in the epidermis. As a consequence of desiccation, the cells which constitute the body of the nail lose their nuclei and become condensed into a compact tissue or structure, for the examination of which it is necessary to resort to the use of strong alkalies, which resolve the nail into its cellular elements.

In the developing nail the line of division between the epiderm covering the end of the finger and the free border of the nail is plainly marked by a condensed layer of cells, which does not partake of the nature of either tissue, but which lies, as it were, on the borderland between the two. This layer will form the attachment of the nail at its free margin.

The lengthening of the nail corresponds with the growth of the finger, being from the posterior portion outward. The nail is somewhat thicker at the free border than it is nearer its origin.

No sweat or sebaceous glands are found underneath the nail, which perhaps accounts for the change of the epidermis at that point into the nail by the process of desiccation.

Hairs, glands, and the enamel organ are formed by an ingrowth of the Malpighian layer into the mesodermic portion underneath. Just why the rapid multiplication of epithelial cells should result in one place in the formation of nails or horns, while in another part their

increase results in an ingrowth which forms hairs, glands, etc., is a question which has puzzled the brains of thoughtful men since anything has been known of the histology of tissues. The only answer that can be made is that in so doing the cells are obeying a *vital power* which cannot be explained from a knowledge of their microscopical character or chemical composition, or from a knowledge of the ultimate substances into which they may be resolved, but which endows each cell with a distinct individuality. That such is the case no one can doubt who has for himself studied the development of tissues. If such is not the case, why is it that the cells of the mesoblast—which in the first instance arise almost altogether from the epiblast—form one line of tissues, while the parent epiblast forms another entirely different? So far as we can make out in the early stage of the differentiation of the mesoblast from the epiblast, there is no histological difference between the two; but they have each separate offices to perform, and unless interfered with by lack of material (cell-pabulum) they go on growing and forming until they have produced very different tissues. From the time of the separation of the mesoblast from the epiblast, histological differences are presented which become more and more marked at each succeeding stage, until at last the products of their life-work show the widest divergence.

Development of Hairs.—The process of the development of hairs is somewhat more complex than that of nails, but is of a similar nature.

FIG. 304.

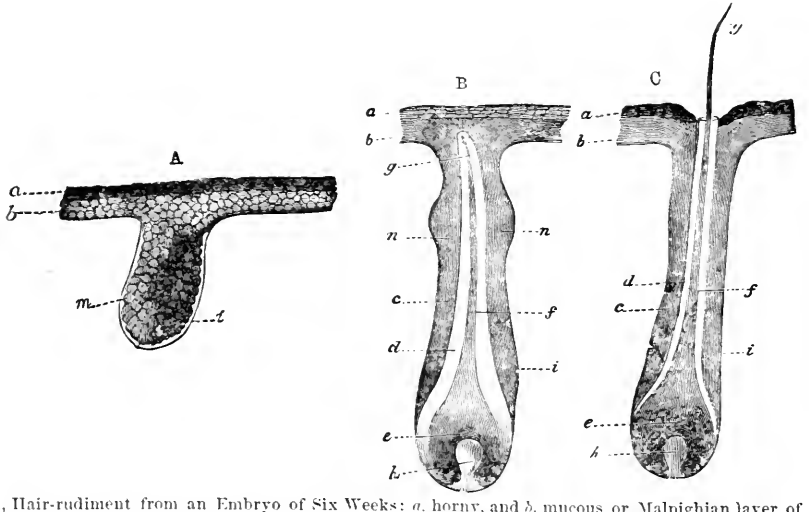

A, Hair-rudiment from an Embryo of Six Weeks: *a*, horny, and *b*, mucous or Malpighian layer of cuticle; *i*, basement-membrane; *m*, cells, some of which are assuming an oblong figure, which chiefly form the future hair.

B, Hair-rudiment, with the Young Hair formed, but not yet risen through the cuticle: *a*, horny, *b*, Malpighian, layer of epidermis; *c*, outer, *d*, inner, root sheath; *e*, hair-knob; *f*, stem, and *g*, point, of the hair; *k*, hair-papilla; *n*, *n*, commencing sebaceous follicles.

C, Hair-follicle, with hair just protruded.

Instead of being developed, like the nails, upon the surface, they are developed inside a pouch or sac, through the mouths of which they push their way to the surface. The first appearance of the development

of hairs is seen in the pig 3 cm. in length or in human fœtuses between the third and fourth months. The infant cells of the rete Malpighii

FIG. 305.

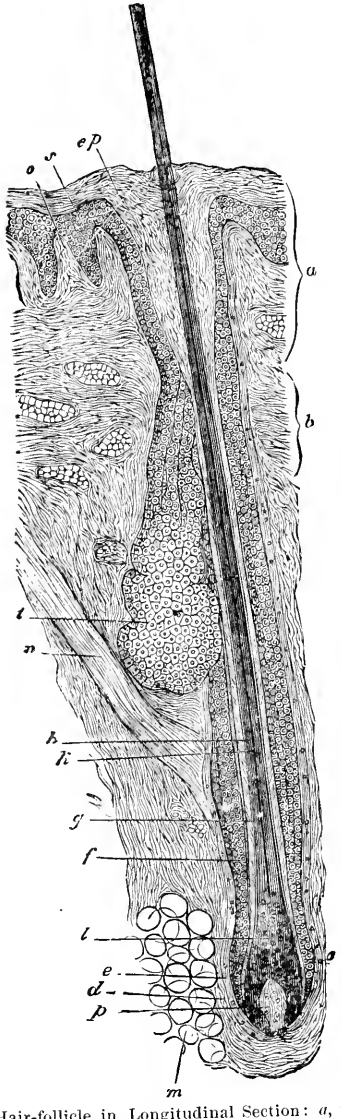

Hair-follicle in Longitudinal Section: *a*, mouth of follicle; *b*, neck; *c*, bulb; *d*, *e*, dermic coat; *f*, outer root-sheath: *g*, inner root-sheath; *h*, hair; *k*, its medulla; *l*, hair-knob; *m*, adipose tissue; *n*, hair-muscle; *o*, papilla of skin; *p*, papilla of hair; *s*, rete mucosum, continuous with outer root-sheath; *ep*, horny layer; *i*, sebaceous gland.

FIG. 306.

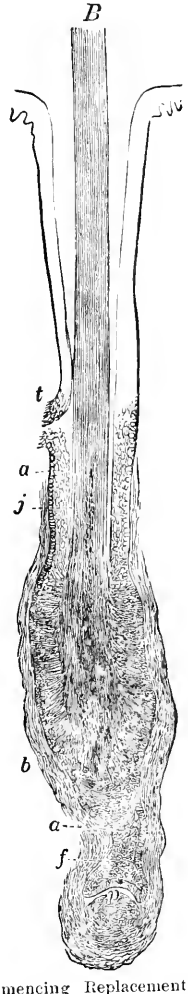

Commencing Replacement of Old by New Hair (Toldt): *a*, outer root-sheath; *b*, dermic coat of follicle; *f*, downgrowth of epithelium to form new hair-follicle; *p*, papilla of new hair commencing; *j*, root of old hair; *t*, duct of sebaceous gland.

appear to thicken at many points; this thickening proceeds until they dip into the underlying corium. The cellular activity does not lessen

until the sac has reached the typal limit of its growth. The sac is filled with cells which have been pushed off from the infant layer. The surrounding connective tissue has now become somewhat condensed, and constitutes the outer root-sheath. The continued development of the cells at the deepest portion of the sac causes it to expand and become bulbous; this appearance gives rise to the term *hair-bulb*.

From this time onward the effort of Nature, as expressed in ingrowth, ceases, and her energy is directed toward the surface. The cells which are pushed off from the *infant layer* become condensed in the central portion of the sac—not into a solid shaft, but into the cortical portion of the hair surrounding the *medullary cavity*. The hair-bulb rests upon a *papilla*, which is developed from the corium, and which invaginates the deepest portion of the hair-bulb, so that the latter covers the sides of the papilla in much the same manner as though a bell had been let down over it; this union serves to form the attachment of the base of the hair.

The connective-tissue papillæ have no special signification, but come and go as the hairs are destroyed and new hairs develop. They are not a special product of fœtal life, but are developed all through life as new hairs are formed, for hairs are short-lived, and are constantly being cast off, and new ones formed in their places. When the hair-bulb atrophies, a new bulb is sent down from the remaining portion of the hair-follicle (Fig. 306); this in turn becomes invaginated by a new papilla; a new hair is formed, which by its upward growth pushes the old hair out. When the entire epithelial portion of the follicle atrophies, there cannot arise a new bulb, and consequently the process of future development ceases. The hair papillæ contain loops of capillary vessels. The depth to which the follicle penetrates into the subcutaneous tissue is in proportion to the size and length of the hair, as is also the thickness of the root-sheath. Larger hairs are set more deeply and firmly in the underlying tissue than smaller ones. Whether the size of the hair governs the depth and firmness of its attachment, or the depth and firmness the size of the hair, I leave to the reader to settle for himself. Probably Nature knew from the beginning just how to build each part so as to have it best subserve the purpose for which she intended it. Questions of this kind are continually arising in the mind of the student in Embryology, and especially is this true in our study of the products of the epiblastic layer.

Development of Glands—Sebaceous Glands.—These are a differentiation from the same infolding of the epithelial layer as the hair-follicle, and develop simultaneously with it. In early fœtal life the sebaceous gland is much larger and more prominent than the hair-follicle—so much so that the hair-follicle is apparently situated in the mouth of the gland. Sebaceous glands belong to the racemous type (like a bunch of grapes). They are developed by an infolding of the epithelial layer, which becomes involuted, forming several pockets which open into one common duct. This duct finds outlet into the sheath of the hair-follicle or upon the surface of the skin. The outer wall of the gland is composed of a connective-tissue envelope formed from the slightly condensed surrounding connective tissue of the corium. Inside this is situated a layer

of small polyhedral granular cells containing oval nuclei; this is the continuation of the *infant* layer of rete Malpighii. Very frequently these cells are seen to contain droplets of oil. Their office is to secrete the oil which serves to lubricate the hair and skin. Inside this layer,

FIG. 307.

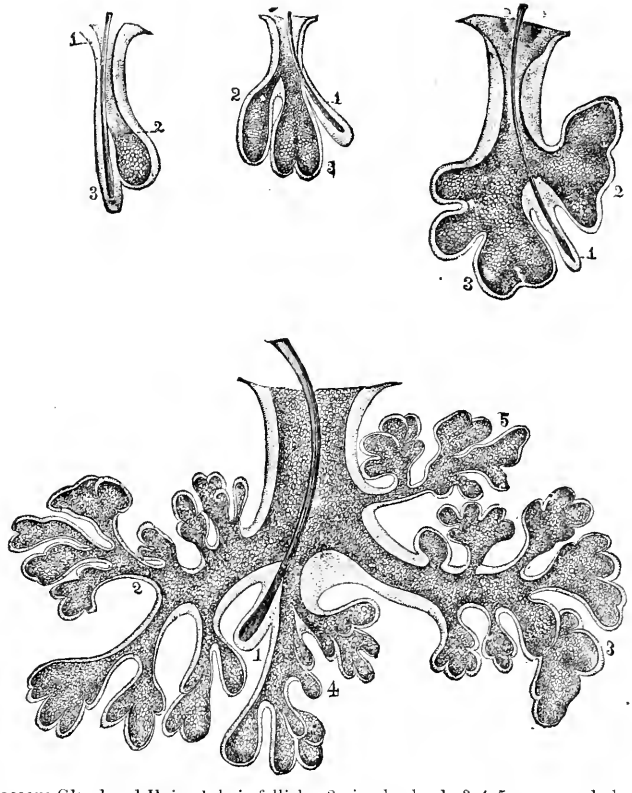

Sebaceous Gland and Hair: 1, hair-follicle; 2, simple gland; 3, 4, 5, compound glands.

and occupying the cavity of the gland, are seen cells which have been pushed off from the outer layer, and which become larger as they near the central portion of the gland. The older cells pass through varying stages of fatty degeneration until they are forced from the mouth of the gland as *sebum*, a substance holding in suspension minute oil-globules. The sebaceous glands rest upon the erector papillæ muscles, and are moved as the hairs move. No doubt the action of these muscles materially aids the ejection of the contents of the glands; vigorous brushing of the hair tends to increase the flow of this oily secretion.

Sweat-Glands.—The other glands developed from the epithelium are the tubular sweat-glands. Their development does not differ materially from that of the sebaceous glands, except that instead of assuming a racemous form they curl or coil upon themselves at their deepest extremity, in a very peculiar manner, presenting the appearance of a ball (Fig. 308).

The epithelial cells found in sweat-glands are polyhedral or cuboidal in form. Their office, implied in their name, is too well known to need further explanation.

FIG. 308.

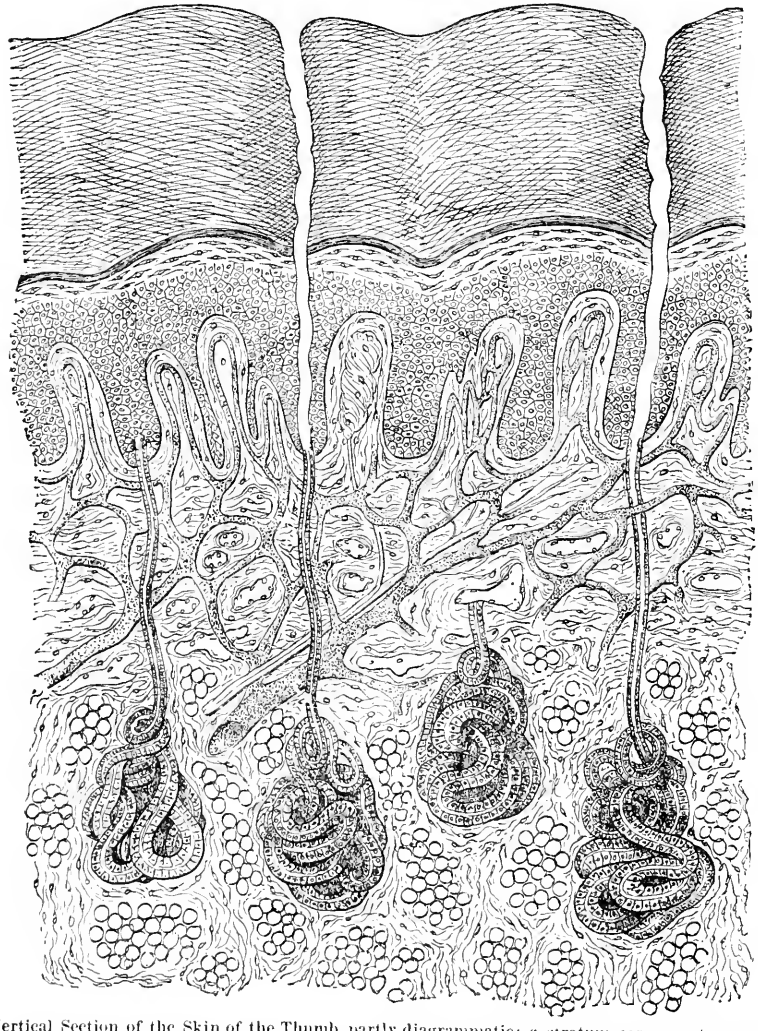

Vertical Section of the Skin of the Thumb, partly diagrammatic: *a*, stratum corneum, traversed by ducts of two glands; *b*, rete mucosum, with prolongations extending between papillæ beneath; between *a* and *b* is seen the stratum lucidum; *c*, papillary layer of corium. Near the centre of the figure is seen a tactile corpuscle; *d*, reticular layer of corium with vascular plexus nucleated connective tissue, and interspaces; *e*, coils of four sweat-glands; *f*, fat-globules in the meshes of the connective tissue.

Development of the Enamel Organ.—The development of this organ differs but very little from that of the hair-follicle. This is especially true of the enamel organ of the permanent molars, the cords for which arise directly from the epithelial layer of the mucous membrane of the

mouth. A detailed account of the development of the enamel organ does not fall within the province of this section; we will therefore confine ourselves to its simplest form of development as seen in the sixth-year molar. The cord for this molar is said by some to arise from the distal face of the second-year temporary molar, but I doubt the accuracy of the statement.

At the point where the cord for the tooth is to arise, be it from the *band* or directly from the surface epithelium, active cell-multiplication is seen. The layer of *infant* cells, by reason of this cellular activity, becomes depressed into the substance of the subepithelial tissue in the form of a blind pouch. Fig. 309—which has been so extensively copied from Frey's *Histology*—was evidently taken from the posterior portion of the jaw, and it shows quite correctly the changes in the form of the cord in the development of one of the permanent molars. I will use it here for the illustration of the point in hand.

The cells of the *infant* layer are not columnar, as shown in the cut, but oval or spheroidal (as I will take occasion to show when we come to the development of the teeth proper). This cut is introduced for the purpose of calling attention to the errors of many who have written upon this subject.

The ingrowing sac elongates into a cord, thus sinking more deeply into the submucosæ. (See Fig. 309, 1, *d*.) The greatest cellular activity is found in the deepest portion of the ingrowing sac, as we have seen in the development of hairs and glands. The cord under the pressure of rapid cell-multiplication becomes bulbous. In turn, this bulbous part becomes invaginated by the upward growth of the *dentinal papilla* (2, *f*)—at first slightly (Fig. 309, 2), afterward completely (Fig. 309, 3). Presently it is severed from the epithelium of the mouth by the breaking up of the neck of the cord: at the same time there springs up from around the sides of the enamel organ a connective-tissue envelope (3, *h*) which is connected at its base with the dentinal papilla. This grows up and around

Fig. 309.

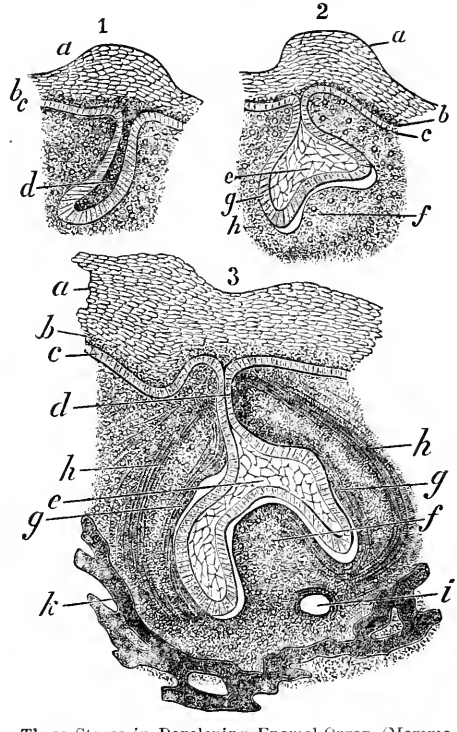

Three Stages in Developing Enamel-Organ (Mammalian).

1. *a*, dental ridge; *c*, infant layer of cells, here wrongly figured as columnar; *d*, cord for permanent molar (probably) as it arises directly from the epithelium of mouth.
2. *e*, stellate reticulum; *f*, dentinal papilla; *g*, inner tunic.
3. *h*, outer tunic; *i*, transverse section of vessel; *k*, forming bone.

the enamel organ, enveloping it in very much the same way as the hair-bulb enwraps the papillæ, by forming a bell-shaped cover. We have now a fully-developed dental follicle, the connective-tissue envelope corresponding to the outer root-sheath of the hair-follicle. The layer of epithelial cells which lies just inside the connective-tissue envelope is a continuation of the *infant* layer of the rete Malpighii, and the cells have not, as yet, changed their shape, being more or less oval, tending somewhat to a cylindrical form. They are most emphatically not columnar or prismatic, as has been so often stated and represented in cuts by previous authors. That they do become so later no one can doubt, but not until they are differentiated into a special cell for a special office; and that is the secretion of the enamel.

Between the walls of the invaginated enamel organ the older cells, which have been pushed up from the *infant* layer of the rete Malpighii, are assuming a stellate shape (Fig. 309, 2, *e*), and we find the spaces between the fibrils filled with a fluid which is probably rich in proteids.

Let us now turn our attention to the connective-tissue group, the product of the mesodermic layer of the blastoderm.

Development of the Connective-tissue Group.

As before stated, connective tissues arise from the mesoblastic layer of the blastoderm. For convenience of study we will consider—1, embryonic connective cells in their earliest stages of development; 2, fibrillar connective tissue; 3, plasma-cells; 4, areolar tissue; 5, mucous tissue; 6, blood-corpuscles and vessels; 7, dentinal papillæ and odontoblasts; 8, osteoblasts; 9, cement organ.

Embryonic Connective Tissue.—The mesoblastic layer of the blastoderm in a fœtal pig 1 cm. in length is composed of nucleated bioplasmic

Fig. 310.

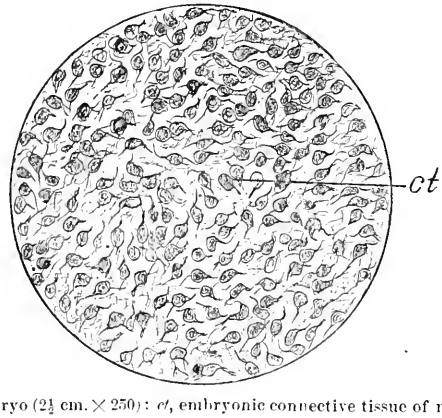

Porcine Embryo (2½ cm. × 250): *ct*, embryonic connective tissue of mesoblast.

bodies, oval or round in form. They soon begin to assume a fibrillated appearance, sending out short processes, which may be seen in the chick at thirty hours and in the pig 1½ cm. in length; in a pig 2½ cm. the fibrillated nature of the bioplasmic bodies is more marked (Fig. 310).

The processes are so fine that it requires very high amplification to demonstrate them. The intercellular spaces, filled with protoplasm, are large in proportion to the number and size of the cells. As development progresses this order is reversed, and the cells with their processes constitute an almost solid mass of tissue. The intercellular *fibrillar connective tissue* is formed by the separation of the protoplasm into very fine fibres. At first these fibrils are few in number, but gradually increase in thickness by becoming joined together into bundles, which anastomose with other similar bundles, thus forming a dense network of connecting fibres. The longitudinal striations seen upon the bundles of fibres are due to the fact before stated, that these bundles are made up of primary elementary fibrils, which by special methods of technique or staining may be demonstrated. Variations in the size of the bundles are dependent upon the number of fibrils contained in them. They are held together by a semifluid cement substance, which, according to Klein, partakes of the character of *globulin*.

Fibrous connective tissue forms the sheaths of muscles, which it binds into bands, and is continuous at their termini as tendons, by which they are attached to the osseous system. It also forms the tissue of the periosteum, pericementum, and the perichondrium; it spreads out into membranes and lines all the serous cavities; forms the tissue of the dermal and subdermal layers; and is, indeed, an important factor in the formation of nearly all the organs of the body. Very generally

FIG. 311.

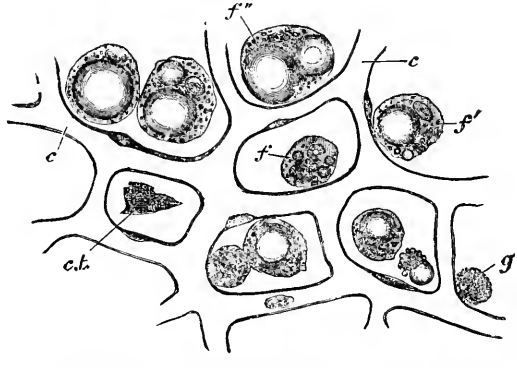

Deposition of Fat in Connective-tissue Cells: *f*, a cell with a few isolated fat-droplets in its protoplasm; *f'*, a cell with a single large and several minute drops; *f''*, fusion of two large drops; *a*, granular or plasma cell, not yet exhibiting any fat-deposition; *c t*, flat connective-tissue corpuscle; *c*, *c*, network of capillaries.

distributed through the connective tissue are round cells, called *plasma-cells*. These are, in all probability, migrated white blood-corpuscles, and have been previously considered.

Development of Fat or Areolar Tissue.—This is formed by a process of infiltration into the substance of the *plasma-cells*. At first these droplets are very small, but as they accumulate they gradually coalesce and unite to form larger drops. By the aggregation and fusion of the fat droplets the cell-body is entirely filled, and the nucleus is crowded to one side of the cell; a thin cell-wall encloses the cell-contents, and

thus we have ordinary connective tissue developed into areolar tissue. This, as we have seen in the article on Anatomy, forms the principal tissue of the derm and many other portions of the body.

Mucous tissue is most typically shown in the *jelly of Wharton*. It belongs normally to embryonal life, and when found in adult tissues is pathological in character, and is then called myxomatous tissue. It belongs to the connective-tissue group, and is composed of branching stellate cells lying in an undifferentiated protoplasmic basis-substance.

FIG. 312.

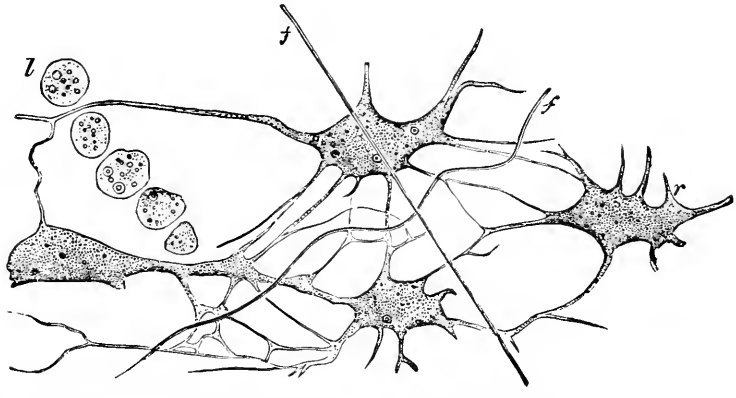

Jelly of Wharton: *r*, ramified cells intercommunicating by their branches; *l*, a row of lymph-cells; *f*, fibres developing in the ground-substance.

I introduce mucous tissue here in order to show the distinction between it and the stellate reticulum of the enamel organ, which we are soon to discuss. Some have called the latter myxomatous tissue.

Development of Blood-corpuscles and Vessels.—If we stain a section through the mesodermic layer of a fœtal pig 1 cm. in length very deeply with hæmotoxylon, and afterward with eosin, it will be seen that some of the cells are dark purple and others bright red. In form they are similar, and it is only by the differentiating action of the stain that we are able to demonstrate any difference between them. In parts of the section these red cells are indiscriminately distributed; in other portions, however, they will be seen to have arranged themselves in rouleaux; these are the newly-developed blood-corpuscles. The embryonic connective-tissue cells of the mesoblast arrange themselves around the rows of blood-corpuscles, and, becoming fibrillated, form the walls of the capillary vessels.

In an older embryo, 2½ cm. in length, the formation of capillary vessels by a process of budding may be distinctly seen (Fig. 313). These arise in solid bands of protoplasm which appear red in sections stained with hæmotoxylon and eosin. The bands extend and form a network of granular protoplasm. The same process of development of new vessels may be seen in granulation-tissue. The solid buds or processes become hollowed out by vacuolation, and into the tubes thus formed the circulation extends. The surrounding protoplasm becomes liquefied, and forms the *plasma* in which the corpuscles float. The walls are formed, as before described, by the embryonal connective-tissue cells.

At first they are quite thin, but as the tissues grow older muscular tissue is developed and the walls of the vessels are thickened.

From the above description it will be seen that I hold that the blood is developed in its first formation from the embryonic connective cells of the mesoderm. This theory is also advanced by Klein and many others who have written upon the subject; all very generally agree in classifying blood-corpuscles in the connective group. Balfour holds essentially the same views in regard to them, and locates their origin in the mesoblastic layer. He considers that the formation of the protoplasmic network or bands precedes the formation of true blood-corpuscles, and says: "In the pellucid area, where the formation of the blood-vessels may be most easily observed, a number of mesoblastic cells are seen to send out processes (Fig. 314). These processes unite, and by their union a protoplasmic network is formed containing nuclei at the points from which the processes started.

FIG. 313.

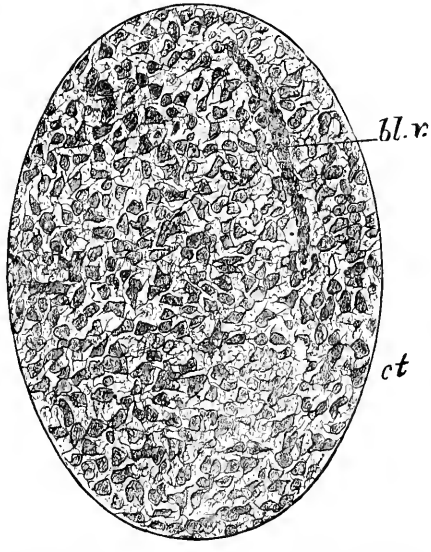

Porcine Embryo (2½ cm. × 250): *bl. v.*, developing blood-vessel, breaking up of solid band into blood-corpuscles; *ct*, embryonal connective tissue.

The nuclei—which, as a rule, are much elongated and contain large oval nucleoli—increase very rapidly by division, and thus form groups of nuclei at the, so to speak, nodal points of the network. Several nuclei may also be seen here and there in the processes themselves. The network being completed, these groups by continued division of the nuclei increase rapidly in size; the protoplasm around them acquires a red color, and the whole mass breaks up into blood-corpuscles (Fig. 314, *b. c.*). The protoplasm on the outside of each group, as well as that of the uniting processes, remains granular, and together with the nuclei in it forms the walls of the blood-vessels. A plasma is secreted by the walls, and in this the blood-corpuscles float freely. Each nodal point is thus transformed into a more or less rounded mass of blood-corpuscles floating in plasma, but enveloped by a layer of nucleated protoplasm, the several groups being united by strands of nucleated protoplasm. These uniting strands rapidly increase in thickness; new processes are also continually being formed; and thus the network is kept close and thickset, while the area is increasing in size. By changes similar to those which took place in the nodal points blood-corpuscles make their appearance in the processes also, the central portions of which become at the same time liquefied. By the continued widening of the connecting processes and solution of their central portions, accompanied by a corresponding increase in the enveloping nucleated cells, the original protoplasmic

network is converted into a system of communicating tubes, the canals of which contain blood-corpuscles and plasma, and the walls of which are formed of flattened nucleated cells.

"The blood-corpuscles pass freely from the nodal points into the hollow processes, and thus the network of protoplasm becomes a network of blood-vessels, the nuclei of the corpuscles and of the walls of which have been, by separate paths of development, derived from the nuclei of the original protoplasm. The formation of the corpuscles does not proceed with equal rapidity or to the same extent in all parts of the blastoderm. By far the greater part are formed in the vascular area, but some arise in the pellucid area, especially in the hinder part. In the front of the pellucid area the processes are longer and the network accordingly more open; the corpuscles also are both later in appearing and less numerous when formed."

Fig. 314.

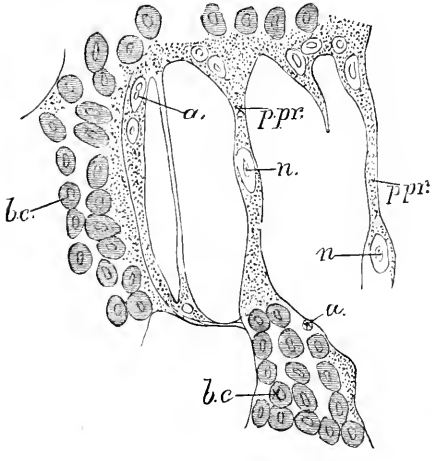

Surface View, from below, of a small portion of the posterior end of the pellucid area of a thirty-six hours' chick (to illustrate the formation of the blood-capillaries and blood-vessels, magnified 400 diameters): *b. c.*, blood-corpuscles at a nodal point, already beginning to acquire a red color: they are enclosed in a layer of protoplasm, in the outermost part of which are found nuclei, *a*. These nuclei subsequently become the nuclei of the cells forming the walls of the vessels. The nodal points are united by protoplasmic processes *p. pr.*, also containing nuclei with large nucleoli (*n*).

Assuming the truth of the above account, it is evident that the blood-vessels of the yolk-sac of the chick do not arise as spaces or channels between the adjacent cells of the mesoblast, but are hollowed out in the communicating protoplasmic substance of the cells themselves. The larger vessels of the trunk, however, are probably formed as spaces between the cells, much as in the case of the heart.

There yet remain to be considered in this connection the dentinal papillæ, cement organ, odontoblasts, osteoblasts, and cementoblasts.

Dentinal Papilla.—This important organ is developed from the embryonic connective tissue of the mesoblast under the influence of the ingrowing enamel organ. We have seen in our study of developing hair that papillæ are developed wherever and whenever a hair-bulb is found growing into the connective tissue, whether in embryonic or adult life, and that upon this process depends the reproduction of hair that has fallen out. Now, I consider the dentinal papillæ to be a similar differentiation of the ordinary connective tissue. They originate at any period in life, from the development of the first-formed temporary teeth to that of the wisdom tooth or third molar of the permanent set. In the light of our study of the analogous formation of the hair-papillæ, I do not think it rational to believe that there is a *papillary layer, sheet of dentinal tissue*, or *semilunar area*.

No difference can be demonstrated histologically between the cells of the papillæ and the surrounding embryonic connective-tissue cells of the jaw. Again, it is not to be presumed that this dentinal sheet persists until all the dentinal papillæ for the permanent teeth are formed; on the contrary, when the time for the development of such papillæ arrives, they are formed from the ordinary connective tissue found in contact with the cord of the enamel organ, and at any point or depth to which it reaches.

The cord does not penetrate the mesoblastic layer searching for a papilla already formed or for a dentinal sheet, but, like the solid ingrowth which forms the hair, it has the power to superintend the differentiation of a papilla for itself. The enamel organ is a specialized tissue which superintends the formation of the papilla and shapes the pulp, and consequently the tooth; in a word, it is the first essential element in tooth-formation, the papilla occupying a secondary position.

The first indication of the development of the papillæ varies so much in the several teeth, even in the same jaw, that no set rule can be laid down. It is safe to say, however, that when the ingrowing cords become bulbous the time is ripe for their appearance.

The papilla is first seen as a condensation of the connective tissue outside and in juxtaposition with the deepest point of the bulbous cord. By its growth in a direction opposite to the enamel organ of the tooth it causes this organ to invaginate itself, after which there is differentiated from the surrounding connective tissue, on all sides of the bell-shaped enamel organ, a follicular wall which is connected with the papilla at its base. This is the cement organ, in connection with which cementoblasts are found underlying this fibrous connective-tissue layer, the future *pericementum*.

Cementoblasts are analogous to osteoblasts; in fact, they are osteoblasts which have received the additional name of cementoblasts. Personally, I would prefer to call them by their original name but for the fact that we have adopted the name *cement* for the osseous covering of the roots of teeth.

Osteoblasts are specialized cells belonging to the connective-tissue group, and the probable nature of their origin will be discussed in the section on Ossification.

Upon the surface of the dentinal papilla, at a period which precedes the formation of dentine, a layer of cells may be seen; these are termed *odontoblasts*. They are developed from the ordinary connective-tissue cells of the papilla. Their differentiation can be studied by following the side of the papilla from its base to its apex in a specimen which shows the beginning of the process of dentinification.

At the base they are generally spheroidal or oval in form, but higher up on the sides of the papilla they are somewhat cylindrical, while at the apex they are columnar. They are sometimes connected with the tissue of the papilla by slender processes.

On the side of the forming dentine they have one or more processes called *dentinal fibrils*, which penetrate the forming dentine and superintend its arrangement into tubules, the centre of which they occupy as the organic part of the dentine. In some instances these fibrils pene-

trate the intercellular spaces of the cementoblastic layer, and dentine is formed around the terminal fibrils, causing an interdigitation of the dentinal tubules and the enamel-prisms. This interpenetration precedes the process of calcification of the enamel.

This now brings us to the consideration of the subject of calcification, which rightly precedes the study of both amelification and ossification.

Calcification.

"Calcification is the process of change into a stony substance containing much lime, as in the formation of the teeth" (R. Owen). In the light of the present status of scientific investigation I would change the above definition as follows: Calcification is that process by which (organic) tissues become hardened by deposition of salts of calcium in their intercellular substance, as exemplified in the formation of bones and teeth.

The intercellular substance found in organic tissues is fluid, and into this fluid minute particles of lime salts, in such fine subdivision as not to be demonstrated by even the highest powers of the microscope, are deposited in regular systems after the several forms of calcified tissues. This arrangement is superintended by specialized cells for each particular structure—*osteoblasts* for bone, *odontoblasts* for dentine, etc. These cells secrete lime salts and deposit them in the intercellular substance.

All cells lie embedded in, or are bathed by, a fluid which is more or less gelatinous in consistency. It is from this surrounding medium that the cells derive the supply of nourishment necessary for the performance of their functions. Cells are capable of cellular activity in proportion to the amount of cell-pabulum this fluid contains. I do not say that cells are *active* according to the amount of food-supply present, but that they are *capable* of putting on cellular activity just in proportion to the amount of cell-food at hand, and in this way are stimulated to increased functional activity. Bricks cannot be made without straw, neither can tissues present increased functional powers without plenty of food with which to nourish themselves. The presence of an intercellular substance is of essential importance in the development of tissues. In embryonic life the quantity of cell-pabulum is very marked. It is at this period that calcification begins in two forms—*ossification* and *amelification;* the first under the superintendency of the *connective-tissue* group of cells, and the second a product of the *epithelium*.

Connective tissue is developed from the mesoblast, while the epithelium is produced from the epiblast. In our former studies we found a wide difference between the tissues of the two layers, and we shall find a yet wider difference between their products.

Under the calcified products of the connective-tissue group we will consider bone, cement, and dentine; under the calcified products of epithelial tissues, enamel, shells, etc.

The essential difference between the two depends upon the matrix, and the manner in which the lime salts are deposited, rather than upon the character of the cells which govern the deposition. The general appearance of cells is dependent, to a very considerable extent, on the matrix in which they lie, yet an epithelial cell, while presenting varia-

tions, is nevertheless always epithelial in its nature, and so are its products. The same is true in regard to the connective-tissue group: an interchange between the two tissues is not known in all the domain of normal or pathological histology, neither can this interchange occur between the products of the two tissues. Those who hold that the enamel is a differentiation of a dentinal basis-substance have not comprehended the subject in all its bearings. Enamel is no more modified bone than is the shell of the mollusk.

Enamel and shells are analogous structures, and are secreted by the epithelium *upon*, and not *in*, the substance of tissues. The shell of the snail is secreted upon its surface, and the lime salts form a semi-crystallized mass. Enamel is secreted by the ameloblasts upon the already formed layer of dentine, there being no basis-substance between the layer of ameloblasts and the formed layer of dentine, and, as in the case of the shell, the lime salts crystallize—not, however, into true crystals. Shells and enamel are identical except in their mineral constituents. Enamel is nothing more or less than a coat of mail, and as such best serves the processes of nature.

As we have seen in our study of developing epithelium, there is little or no intercellular substance above the infant layer of cells. In the development of nails the hornification occurs, not in the *infant* layer, but in the *older* layer, or "stratum granulosum" of other writers. So in the deposit of enamel the lime salts are secreted (shed out) by the cells of the infant layer—not *in* the infant layer, where the greatest amount of intercellular substance is found, but *upon the under surface of the infant layer*—upon an already formed layer of dentine. These cells have become altered in form and specially endowed with functional power. This point will be considered in presenting the subject of the development of the ameloblasts.

We have seen, when treating of the development of connective tissue, that the proportion of intercellular substance largely preponderates over the cells themselves. Into this intercellular substance the calcified products of the connective-tissue group are deposited.

Connective tissues are divided into three great classes: (1) fibrous connective tissue; (2) cartilage; and (3) bone, in which class dentine is included. Each of these is subdivided into several varieties, as will appear farther on, but in all instances the *ground substance*, *matrix*, or *intercellular substance* is to be distinguished from the cells themselves.

In the fibrous connective tissue the matrix yields *gelatin*, and the cells are called connective-tissue corpuscles. In cartilage the ground substance yields *chondrin*, and the cells are called *cartilage-cells*. In the third group the ground substance contains inorganic lime salts, and the cells are termed *bone-cells*.

"The *matrix of osseous substance* is a dense fibrous connective tissue —*i. e.* a substance yielding gelatin on boiling. The cement substance *between the fibrils is petrified*, owing to a deposit of insoluble lime salts, chiefly carbonates and phosphates. These can be dissolved out by strong acids (as hydrochloric), and thereby converted into soluble salts. Thus the organic matrix (Fig. 315) of osseous substance, called *ossein*, may be obtained as a soft, flexible material easily cut" (Klein).

The *ossein* mentioned above is the calco-globulin of Mr. Rainey. It is evident that the basis-substance left after decalcifying bone has changed its nature, and no longer presents the characteristics of the intercellular substance in which the lime salts were deposited.

FIG. 315.

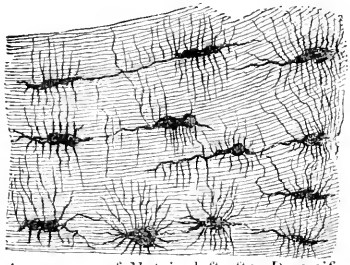

Appearance of Matrix left after Decalcification by HCl. Osseous Lamellæ, oblong-branched bone-lacunæ and canaliculi between them.

The intercellular substance is composed of *protoplasm*. In life this contains, besides the albuminoids, a living principle which permits it to modify its form and perform functions. Just what this principle is we have never, by chemistry, been able to determine, for by the use of the reagent which we employ to demonstrate its molecular constituency we destroy the living principle, and have left only the material substance which held the active principle in bounds. Chemical analysis shows protoplasm to be composed of proteids, in which are held in suspension carbohydrates and fats. These substances are undoubtedly formed from protoplasm by the action of the living matter of the cell. We also find in different parts of the body several varieties of substances derived from the above-mentioned constituents of protoplasm—gelatin, mucin, etc.

Under the direction of the vital principle found in living protoplasm —viz. cells—the lime salts are deposited in forms peculiar to each tissue. Lime salts, however, may crystallize *without* the body, but the form of the structure in the body depends upon the superintendency of specialized cells. Tubular bone or dentine is deposited by odontoblasts, and calcospherules of bone by osteoblasts. These cells do not exert any other influence upon the depositing structure than that of shaping it according to certain prescribed and prearranged forms. They are, in fact, but the moulds which shape the accumulating mass. Where lime salts are deposited in albumen or any other gelatinous material there appears no definite form other than that naturally assumed by the particular lime salt when undergoing crystallization.

Renal calculi are in all probability formed by the deposition of lime salt in a matrix of mucus, for similar calculi can be formed artificially outside the body. "The chemical substances to be employed in the production of the artificial calculi," says Mr. Rainey, "are a soluble compound of lime and carbonate of potash or soda dissolved in separate portions of water, and some viscid vegetable or animal substance, such as gum or albumen, mixed with each of these solutions. The mechanical conditions required to act in conjunction with the chemical means are the presence of such a quantity of the viscid material in each solution as will be sufficient to make two solutions, when mixed together, of about the same density as that of the nascent carbonate of lime, and a state of perfect rest in the fluid in which the decomposition is going on, so that the newly-formed compound may be interfered with as little as possible in its subsidence to the sides and bottom of the vessel. This will require two or three weeks or longer, according to the size and com-

pleteness of the calculi. But I have not found that they increase at all after six weeks."

Mr. Rainey has by many and thoroughly scientific tests proven the analogy between his artificial calculi and those formed in the body. The lime salts are deposited in both cases in a gelatinous matrix, but without the forming influence of the specialized cells which we find in true calcification. The difference between crystallization *outside* of the body and crystallization *within* it is due to the action of the specially-endowed cells which superintend the deposition of the lime salts.

The lime salts which are deposited in the intercellular substance enter into some chemical combination with the protoplasm which composes this intercellular substance, the nature of which is not known; but it is *not* due to any special action of the living protoplasm, as such, for we find the same apparent characteristics shown where lime salts are thrown down in albumen or mucilage. The product thus obtained is insoluble in acids: a portion or all of the lime salts will be given up, but the matrix will remain.

On this subject Mr. Tomes has written as follows: "The insoluble salts of lime are altered in their behavior by association with organic compounds—a fact which was first pointed out by Rainey and has been more recently worked out by Professor Hasting and Dr. Ord. If a soluble salt of lime be slowly mixed with another solution capable of precipitating the lime, the resultant lime salt will go down as an amorphous powder, or, under some circumstances, in minute crystals. But in the presence of gelatin, albumen, and many other organic compounds the form and physical character of the lime salts are materially altered, and in the place of an amorphous powder there are found various curious but definite forms quite unlike the character of crystals produced without the intervention of the organic substance. Mr. Rainey found that if calcium carbonate be slowly formed in a thick solution of mucilage of albumen, the resultant salt is in the form of globules, laminated in structure, so that the globules may be likened to tiny onions, these globules, when in contact, becoming agglomerated into a single laminated mass, it appearing as if the laminæ in immediate apposition blended with one another. Globular masses, at one time of mulberry-like form, lose the individuality of their constituent smaller globules, and become smoothed down into a single mass; and Mr. Rainey suggests as an explanation of the laminated structure that the smaller masses have accumulated in concentric layers which have subsequently coalesced; and in the substitution of the globular for the amorphous or crystalline form in the salt of lime when in contact with various organic substances Mr. Rainey claimed to find the clue for the explanation of the development of shells, teeth, and bone. At this point Professor Hasting took up the investigation, and found that other salts of lime would behave in a similar manner, and that by modifying the condition of the experiment very various forms might be produced. But the most important addition to our knowledge made by Professor Hasting lay in the very peculiar constitution of the 'calcospherites,' by which name he designated the globular forms seen and described by Rainey. That these are built up of concentric laminæ like an onion

has already been mentioned, and Mr. Rainey was aware that albumen actually entered into the composition of the globule, since it retained its form even after the application of acid. But Professor Hasting has shown that the albumen left behind after treatment of a calcospherite with acid is no longer ordinary albumen: it is profoundly modified, and has become exceedingly resistant to the action of acids, alkalies, and boiling water, and in fact resembles chitine, the substance of which the hard skin of insects consists, rather than any other body. For this modified albumen he proposes the name of 'calcoglobulin,' as it appears that the lime is held in some sort of chemical combination, for the last traces of lime are retained very obstinately when calcoglobulin is submitted to the action of acids. The 'calcospherite,' then, has a true matrix of calcoglobulin, which is capable of retaining its form and structure after the removal of the great bulk of the lime. Now, it is a very suggestive fact that in the investigation of calcification we constantly meet with structures remarkable for this indestructibility; for example, if we destroy the dentine by the action of very strong acids or by variously-contrived processes of decalcification, putrefaction, etc., there remains behind a tangled mass of tubes, the 'dentinal sheaths' of Neumann, which are really the immediate walls of the dentinal tubes. Or if bone be disintegrated by certain methods, there remain behind large tubes found to be the linings of the Haversian canals (Kölliker), and small rounded bodies recognizable as isolated lacunæ; and in the cuticula dentis we have another excellent example of this peculiarly indestructible tissue. In point of fact, as will be better seen after development of the dental tissue has been more fully described, on the borderland of calcification, between the completed, fully-calcified tissue and the formative matrix, as yet unimpregnated with lime, there very constantly exists a stratum of tissue which in its physical and chemical properties very much resembles calcoglobulin."

It should also be noted that globular, spherical forms are constantly to be seen at the edges of the thin cap of forming dentine, and may be also traced in and around the interglobular spaces. Moreover, isolated spherules of lime salt have been described by Messrs. Robin and Magitot as occurring abundantly in young pulps of human teeth, as well as those in Herbivora, where their presence was noted by Henle. This brings us to the consideration of the first division of calcified products—viz. bone.

Ossification.

By *ossification* we mean the deposition, under the superintendency of the osteoblasts, of the salts of calcium into the intercellular protoplasmic basis-substance.

Bone is simply an aggregation of calcospherules. These are at first thrown out or secreted as a thin covering around the osteoblasts. The specialized cell, at the time when it assumes the office of bone-builder, is at its highest state of development as regards functional activity, and has also attained its greatest magnitude. From the formation of the first layer of bone the cells begin to decrease in size, and they continue

to lessen until the typal demands of each spherule are reached, when the process ceases. The wall of the calcospherule is thickened at the expense of the size of the osteoblast itself; so that the bone-cell—which is really the encased osteoblast—is perceptibly smaller than the original osteoblast.

Osteoblasts are round or oval bodies varying considerably in diameter. They are not fibrillated, and in this respect correspond to plasma-cells. They lie in actual contact with one another, and as ossification proceeds the points of contact draw out into fine fibres. Salts of calcium are deposited in the protoplasm which bathes the osteoblasts and have their location in the meshes of these fibres.

In intermembranous ossification of the skull-cap and subperiosteal development of bone the osteoblasts are arranged in layers in the substance of the fibrous membranes or underneath them, and the deposit of lime is along the fibres, giving them an opaque, granular appearance. The deposition begins on one side of the line of osteoblasts, and presents as many indentations as there are osteoblasts in line.

The crescentic nature of the first part of the layer secreted by the osteoblasts is plainly shown when they (the osteoblasts) are displaced or where they are considerably shrunken. As the process of secretion proceeds the osteoblast becomes enclosed in a thin spherule of formed material, designated by Mr. Rainey as *calcoglobulin*. This shell of bone is pierced here and there by the fibres of the osteoblast which are left as the osteoblast shrinks. The deposition of bone is really in the meshes of these fibres.

The body of the cell is spheroidal, hence the deposition assumes a spheroidal form; accordingly, we denominate it a *calcospherule*.

As the process of secretion goes on depositing from the circumference toward the centre the fine processes before mentioned continue to be united with the osteoblasts. Their terminal fibrillæ anastomose with those of other osteoblasts, and these again with others; those which lie nearest the capillary vessels connect with them, thereby receiving nourishment, which they in turn give to the outer layer of bone-cells. The office of these processes, then, is to supply the nutrient matter needed to support life in the bone-cells.

Bone-cells are nothing more or less than encapsuled osteoblasts which are occupying the homes which they have builded themselves. The cavities which they occupy are the *lacunæ* of the old writers; the canals in which their processes lie are the *canaliculi*, and the capillary vessels the *Haversian system*. These lacunæ and their canaliculi, together with the Haversian canals, are occupied in living bone by the above-described organic element.

If we dry a portion of the shaft of a long bone—by which process we destroy the organic element—and afterward saw off small sections and grind them quite thin, then mount them in hard balsam so that the spaces will not become penetrated by the balsam, but remain filled with air, we may observe the following arrangement: larger or smaller canals (Haversian), around which are arranged, concentrically, oval spaces (lacunæ), from which radiate numerous fine canals (canaliculi), which connect with other similar canals, and these in turn with the Haversian canals.

Now, if we had taken a portion of the same bone, when fresh, and placed it in dilute picric acid and decalcified it, afterward cutting thin sections and staining them with picrocarmine, we should not have seen the cavities which we observed in the section of dried bone; for while by the process of drying we destroyed the contents of the cavities, by the use of the picric acid we preserved their contents.

In lacunæ we find bone-cells; in canaliculi, processes of bone-cells; in Haversian canals, capillary vessels.

By studying sections prepared according to the methods above described, we are able to understand the real formation of bone. It is needless to remark that our present knowledge of bone-formation is the result of the accumulated research and careful observation of scientists for many generations.

The general misuse of the terms *lacunæ*, *canaliculi*, and *Haversian canals* attests the need of a more thorough understanding of the process of bone-formation. A brief recapitulation of the more important points may make the subject clearer to the reader.

The osteoblasts do not become calcified, but remain as the life-occupants of the calcospherules, and by reason of such occupancy make it possible for us to produce, by drying, the cavities known as lacunæ. Calcification is a process of secretion *around*, and not *in*, the cell. The mollusk secretes *upon*, and not *in*, its body, and the secreted portion of its shell does not contain organic tissue. The only living matter found therein is the body of the mollusk, which we can extract and yet

FIG. 316.

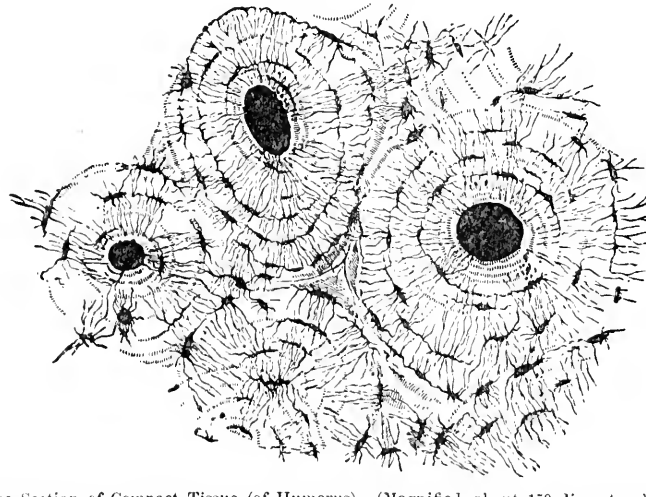

Transverse Section of Compact Tissue (of Humerus). (Magnified about 150 diameters.) Three of the Haversian canals are seen, with their concentric rings; also the lacunæ, with the canaliculi extending from them across the direction of the lamellæ. The Haversian apertures had become filled with air and débris in grinding down the section, and therefore appear black in the figure, which represents the object as viewed with transmitted light.

leave the shell as perfect a shell as before the death of its occupant. We do not think of attributing to the shell the possibility even of such a thing as an inflammatory process, for the reason that the shell is

composed of material unsusceptible of any change except that of disintegration. The mollusk may add to its shell internally, but it must necessarily be at the expense of the size of its own body. And so it is with the osteoblasts: they are arranged in close proximity—so close that the first secreted calcospherule joins that of a neighboring spherule, and by this juxtaposition and coalescence solid bone is formed.

Fracture of the shell may also be repaired by the same cells which in the first place secreted the shell.

The area of tissue supplied by a capillary vessel at the beginning of the process of calcification marks the limit of the Haversian system. The osteoblasts are arranged around the outer portion of this area, and the first-formed layer of calcospherules constitutes the periphery of the Haversian system; the next-formed layer of spherules lies inside the first-formed layer, thereby lessening the space occupied by the capillary vessels; the third layer is still inside the second; and so on centripetally, until the several layers almost entirely fill the space (Fig. 316). The remaining space is occupied by the vascular and lymphatic system, and no less an authority than Schaefer claims the presence of nerves (Fig. 317).

FIG. 317.

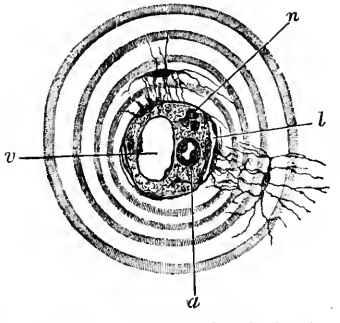

Section of a Haversian Canal, showing its contents (highly magnified): *a*, small arterial capillary vessel; *v*, large venous capillary; *n*, pale nerve-fibres cut across; *l*, cleft-like lymphatic vessel: one of the cells forming its wall communicates by fine branches with the branches of a bone-corpuscle. The substance in which the vessels run is connective tissue with ramified cells; its finely granular appearance is probably due to the cross-section of fine fibrils. The canal is surrounded by several concentric lamellæ.

In the centripetal manner of development I see a wise design on the part of Nature to limit the space occupied by the calcospherules and mark the outline of the Haversian system. This centripetal arrangement lessens the calibre of the vessels, but yet allows them abundant capacity to carry sufficient cell-pabulum to keep alive the enclosed organic tissue.

Thus is cellular activity made self-limiting and a beautiful and symmetrical object conformed to its purpose brought into being. Were the process of bone-formation centrifugal, we should be more likely to find abnormalities and distortions.

This brings us to the consideration of the several forms in which bone is developed. We have seen how the calcospherules are built and by their aggregation made into compact bony tissues, and it now remains to discuss the several different forms they assume under the government of pre-existing tissues which modify their arrangement.

Nearly every author gives a different interpretation of the existing classifications. Upon those known as intracartilaginous and subperiosteal they generally agree, but there seems to be considerable difficulty in harmonizing their views upon the third class—viz. intramembranous. This, as I shall try to show, grows out of the fact that this classification is made to cover too much ground.

Dr. T. Mitchel Prudden describes this form of ossification as occur-

ring "in the substance of pre-existing fibrillar connective-tissue membranes," and cites the skull-cap as a typical example. He classifies subperiosteal development separately.

Dr. Carpenter says: "The intermembranous form of ossification principally occurs in the flat bones of the head, and is also the mode by which long bones increase in girth." It will be seen from the above that Dr. Carpenter considers intermembranous and subperiosteal formations of bone under one head.

Klein recognizes two classes—enchondral and periosteal, or intermembranous—and says: "All the bones of the limbs and of the vertebral column, the sternum and the ribs, and the bones forming the base of the skull, are preformed in the early embryo as solid hyaline cartilage covered with a membrane identical in structure and function with the periosteum, which at a later period it becomes. The tegmental bones of the skull, the bones of the face, with the lower jaw, except the angle, are not preformed at all. Only a membrane identical with the future periosteum is present, and underneath and from this bone is gradually deposited." Under the division intermembranous he further says: "All bones not preformed in the embryo as cartilage are developed directly from the periosteum in the manner of periosteal bone just described."

FIG. 318.

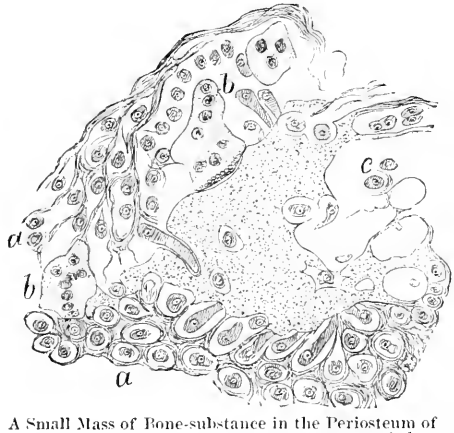

A Small Mass of Bone-substance in the Periosteum of Lower Jaw of a Human Fœtus: *a*, osteogenetic layer of periosteum; *b*, multinucleated giant-cells, myeloplexes. The one in the middle of the upper margin is an osteoclast, whereas the smaller one to the left upper corner appears concerned in the formation of bone. Above (*c*) the osteoblast-cells become surrounded by osseous substance, and thus become converted into bone cells.

The accompanying cut is here reproduced as the only one published—at least, so far as I am aware—that has any reference to maxillary ossification. It is evidently taken from a quite mature fœtus, as osteoclasts are figured, and they do not make their appearance in the jaws until very near birth, at which time a periosteum has been differentiated and subperiosteal bone-formation is in active progress; this is also the case in all the bones of the body, the maxillæ being no exception to the rule.

Dr. Shakespeare,[1] in speaking of intramembranous development of bone, says: "The intermembranous formation of bone is analogous to the development of bone from the periosteum. For instance, the bones of the cranium have their origin in a fibrous membrane which soon presents a division into two layers similar both in structure and function to the outer and inner layers of the periosteum."

Schaefer[2] makes only two divisions—intercartilaginous and intermembranous. He says: "Sometimes the bone is preceded by cartilage,

[1] Allen's *Anatomy*.

[2] See Schaefer's *Histology*.

which first of all becomes calcified, and this is invaded, and for the most part removed, by an embryonic tissue which deposits bony matter in the interior of the cartilage, whilst at the same time layers of bone are being formed outside, underneath the periosteum. This is *intercartilaginous* or *enchondral ossification*. Sometimes the bone is not preceded by cartilage, and then the only process which occurs is one corresponding to subperiosteal ossification of the former variety. The ossification is then known as *intramembranous*." From the above it is seen that this author makes intramembranous and subperiosteal bone-formation analogous except as regards position.

FIG. 319.

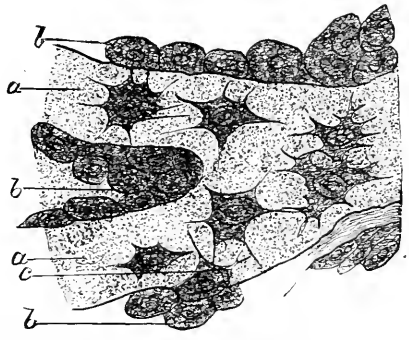

Osteoblasts from the Parietal Bone of a Human Embryo thirteen weeks old: *a*, bony septa, with the cells of the lacunæ, or bone-corpuscles; *b*, layers of osteoblasts; *c*, the latter in transition to bone-corpuscles (very high power).

Gray makes two main divisions—intracartilaginous and intramembranous—and places subperiosteal as a subdivision of the second. As an example of the first, he cites the "long bones;" of the second, the "cranial bones"—viz. the occipital as far as it enters into the formation of the vault of the skull, the parietal and frontal bones, the squamous portion of the temporal with the tympanic ring, the Wormian bones, the nasal, lachrymal, malar, palate, upper and lower maxillary, and vomer; also, apparently, the internal pterygoid and the sphenoidal turbinated bones. "The intramembranous ossification," he further says when discussing that division, "is that by which the bones of the vortex of the skull are entirely formed. In the bones which are so developed no cartilaginous mould precedes the appearance of the bone-tissue. The process, though pointed out originally by Dr. Nesbitt in the year 1736, was first accurately described by Dr. Sharpey, and it does not appear that subsequent observers have been able to add anything essential to his description. This is substantially as follows: In the membrane which occupies the place of the future bone a little network of bony spiculæ is at first noticed, radiating from the point of ossification. When these rays of growing bone are examined by the microscope, there is found a network of fine clean fibres (osteogenetic fibres), which become dark and granular from calcification, and as they calcify they are found to enclose in their interior large granular corpuscles, or osteoblasts. These corpuscles at first lie upon the osteogenetic fibres, so that the corpuscles must be removed by brushing the specimen with a hair pencil in order to render the fibres clear, but they gradually sink into the areolæ developed among the fibres. The areolæ appear to be the rudiments of the lacunæ, the passages between the fibres form the canaliculi, and the osteoblasts are the rudiments of the bone-cells." This, with slight modification, is a very good description of intramembranous ossification as seen in the parietal bones of the skull-cap, but does not answer for the maxillæ, as we will see later on.

From the above quotations I think I am justified in saying that all agree regarding the manner and method of intracartilaginous and subperiosteal bone-formation, and intramembranous also, in so far as it refers to the parietal bones; but, judging from the paucity of illustrations and literature treating directly upon the formation of the remainder of the group not preformed in cartilage, I conclude that there has been less investigation of this than of kindred subjects.

From my own studies in bone-formation, I am convinced that we need all the classifications made by previous writers, and that still another is essential to a clear understanding of ossified products. I shall therefore make a fourth class, which I term *interstitial*. In our future study of bone, then, we shall have to consider four ways in which it may be developed: I. In the substance of the embryonal connective tissue of such bones as are not preformed in cartilage; found in maxillary ossification: *interstitial* (my own classification). II. In pre-existing membranes, as in the skull-cap: *intramembranous*. III. Underneath the periosteum, as in the cortical portion of long bones: *subperiosteal*. IV. In pre-existing cartilage, as in the head of the femur: *intracartilaginous*.

I. *Interstitial Formation of Bone.*—I introduce this term for the earliest development of bone, believing that it is needed. The term intramembranous, while applying to the manner of development in the parietal and some others of the flat bones, does not apply to the maxillæ and bones of that class. I am more convinced of the necessity of such a division of the intramembranous group than of the need of making a distinction between the latter and subperiosteal bone-formation. At best, intramembranous ossification occupies only a transitory stage, and gradually passes into subperiosteal by the differentiation of the periosteum; and I think a careful consideration of the subject will so convince the reader.

FIG. 320.

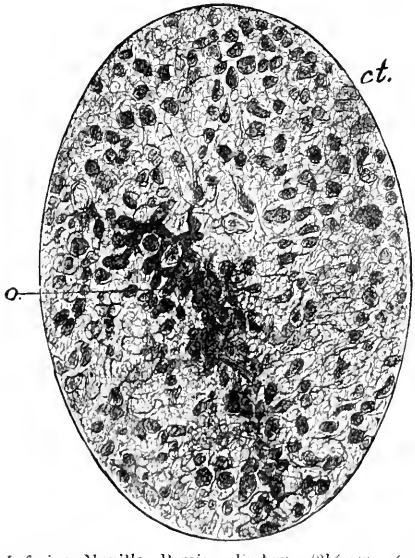

Inferior Maxilla Porcine Embryo ($2\frac{1}{2}$ cm. × 240): *o*, osteoblasts grouped together, surrounded by embryonal connective tissue, *ct*.

In the microscopic investigation of early embryonic life (pig $2\frac{1}{2}$ cm., and human 2 mo.; see cut) cells are seen grouped together here and there in the central portions of both the inferior and the superior maxillæ, which have taken the stain in such a manner as to call attention to their appearance; in other words, they have been differentiated by the staining process. Under low powers they do not differ in form from the surrounding cells, but under high amplification they show no processes as do the ordinary connective-tissue cells even at

this age. They differ in more than mere appearance, however, as is evidenced by their different chemical action when subjected to the staining process, when they take on a darker shade than other cells.

Staining is not *tingeing;* it is a chemical reaction exerted by the separate tissues upon certain dyes, by reason of which we obtain different colors in sections which contain one or more tissues or cells which have different chemical reactions, as in the case in hand. The darker-stained cells are osteoblasts (*bone-builders*) (Fig. 321). They are found

FIG. 321.

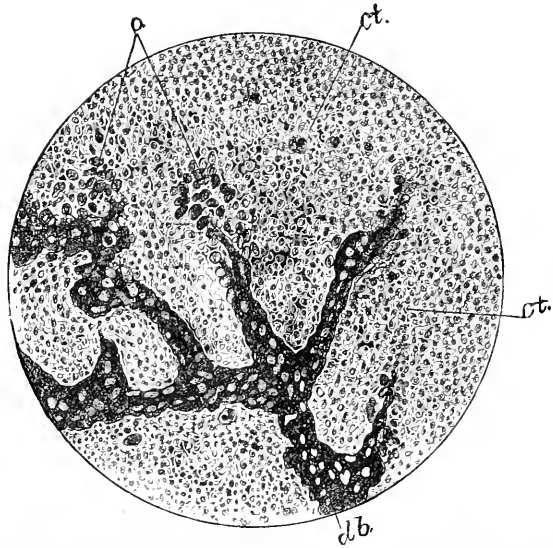

Porcine Embryo (5 cm. long × 250): *a*, osteoblasts situated at the ends of the lamellæ of bone; *db*, developing lamella of bone containing bone-cells; *ct*, *ct*, embryonal connective tissue.

near the central portion of the jaw, which, though composed of the mesoblast, is surrounded by the epiblastic layer. There is as yet no indication of a condensation of the connective tissue into a membrane such as we find when ossification first commences in the skull-cap. A few osteoblasts—independent of the influence of either membrane or periosteum—arrange themselves in groups here and there. These groups are the points of ossification (Fig. 320, *o*), and from them the process extends as the jaw develops.

At first these specialized cells are grouped together in a double layer, but later they may be seen at the termini of the trabeculæ—which are already in a somewhat advanced stage of calcification—where they appear to be a continuation of the process of bone-formation (Fig. 321, *o*); or, to use a simple illustration, they are the fully-equipped workmen (the osteoblasts) waiting for material (lime salts) with which to begin the work of bone-building.

Under the superintendency of the osteoblasts, a crescentic layer of true bone is deposited upon the side of the osteoblast in apposition with a similar crescentic layer formed by an osteoblast located on the opposite side of the line. The sides of each crescent join similar crescents

formed by fellow-workmen on either side. As deposition progresses the osteoblast becomes encircled by a shell of lime. As the trabecula widens by enclosing the osteoblasts which lie upon its sides new layers of osteoblasts are found arranging themselves on the walls, which in turn become enclosed in a layer of bone. Thus, by the accumulation of successive layers of calcospherules, the broadening of the bands of bone-tissue is accomplished. As the osteoblasts build themselves into the wall their places are taken by fresh recruits. When each osteoblast, by secreting its calcospherule, completes its life-work as a bone-builder, it becomes a *bone-cell*, and from that time on occupies the house it has builded. (See Fig. 322.)

The maxillary bones, including the alveolar processes, are thus preformed in *provisional* bone. The fœtal jaw is as truly the antetype of the mature jaw as the fœtal head of the femur, which is preformed in cartilage, is the pattern or matrix-former of the mature femur. This is so even in the very early stages of its development. The alveolar walls surround the microscopic follicle and present the same ragged appearance when the overlying mucous membrane is removed that we see later in mature tissue. The maxillary bones cannot be said to have any special *points* of ossification, as do other bones; development is general. The fact that the alveolar processes have not their analogue in form in any other portion of the body, strongly points to the correctness of my views regarding their special manner of development.

FIG. 322.

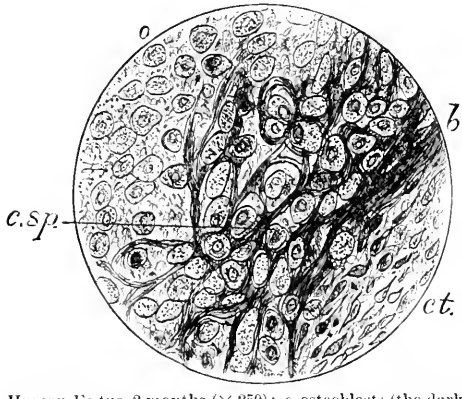

Human Fœtus, 2 months (× 250): *o*, osteoblasts (the dark lines which come to the edge of the figure at *b* represent bands of forming bone); *c. sp.*, calcospherule surrounding an osteoblast; *ct*, embryonal connective tissue.

The first-formed bone is removed by internal resorption, which is concomitant with the external growth by regular methods, which we shall now describe.

After the formation of the periosteum two other classes of bone-development occur—viz. *intramembranous* and *subperiosteal*. The essential point of difference between the two is found in the location of the embryonal plates of bone. *Intramembranous* development, as such *per se*, belongs entirely to fœtal life, and is found in its most typical form in the development of the skull-cap; here it has reference only to the first-formed bone, which we have before said is provisional in character, the growth which takes place after birth being subperiosteal in its nature. And so it is in regard to *interstitial* development: the cortical substance of the mature jaw is developed underneath the periosteum. Indeed, we may say that all bone-formation is provisional until such time as the bones have nearly reached the typal demands of nature, for of those

first developed not a trace will remain in the fully-formed bone. The space occupied by bone in the fœtal jaw will be nerve-canal in the mature jaw; of the later products of calcification—say after birth—at least some will be found in the fully-formed jaw.

In placing the division-line between provisional and permanent bone-formation *at birth* I do not wish to lay down any arbitrary rule. I simply desire to illustrate as clearly as I am able to do so my meaning, and impart to the mind of the reader some tangible point from which to reason. Regarding bone developed prior to birth, I think it is perfectly safe to say that not a trace will be found in mature bone. In making this statement I do not lose sight of the fact that adult tissues are continually being reproduced. I speak only of the form, not of the integral constituents of the formed material. Nevertheless, if there is any stability in tissues, it surely will be found in the inorganic formed material of bones.

II. *Intramembranous Formation of Bone.*—We will now consider the second division of our classification—viz. *intramembranous* development of bone. Prior to the appearance of the first layers of bone (pig 4 cm.) there is seen a condensation of the connective tissue immediately underneath the epithelial layer. There has not as yet been any attempt on the part of nature to differentiate what may properly be termed skin. The epiblast is composed of only one or two layers of epithelial cells. The condensed layer underneath is the first trace of the future peri-

FIG. 323.

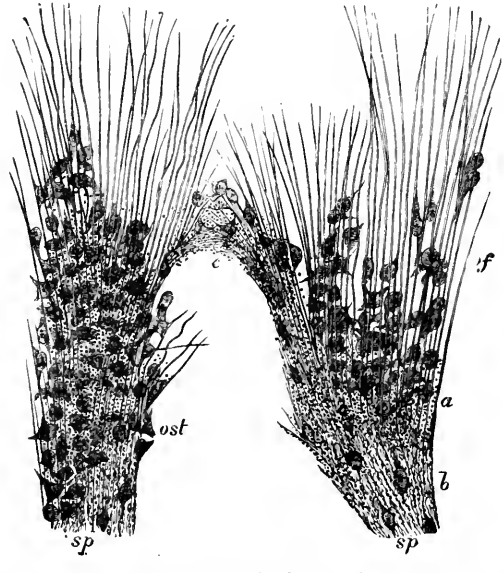

Part of the Growing Edge of the Developing Parietal Bone of a Fœtal Cat (1½ inch long): *sp*, bony spicules, with some of the osteoblasts embedded in them, producing the lacunæ; *of*, osteogenic fibres prolonging the spicules, with osteoblasts (*ost*) between them and applied to them.

osteum. There is as yet no indication of periosteum in the jaws. Nature hastens ossification in the skull-cap in order to protect the

delicate tissues of the brain-substance, which is being differentiated even at this early period.

If a piece of the skull-cap of a fœtal cat (Fig. 323), one and a half inches in length, which has been hardened, be cut out and divided into its several layers, and examined with the microscope, thin plates of bone will be seen; these can be rubbed with a stiff brush until they are thin enough to be examined by high powers. If the plates have been previously stained, a very nice specimen can thus be obtained. But for the best understanding of the manner of development we take the parietal bone—say of a five months old human fœtus—and decalcify it and cut sections; upon examination, lamellæ, or plates of bone, will appear in the now well-defined fibrous periosteum. These embryonal plates are situated in the substance of the periosteum in such a manner as to

FIG. 324.

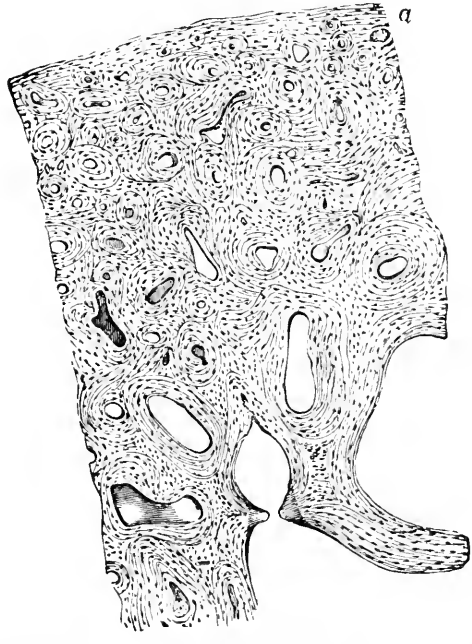

Transverse Section of a Bone (ulna). (Magnified 20 diameters.) The openings of the Haversian canals are seen encircled by concentric lamellæ. Other lamellæ run parallel with the surface, forming the cortical layer.

form connecting cavities which locate blood-vessels and marrow-tissue. The deposition of lime salts is controlled by the osteoblasts, as in interstitial bone-formation. These lamellæ of provisional bone are so located as to divide the fibrous layer into two separate layers: from the outer, *periosteum* is formed; and from the inner, the *dura mater* probably arises. That these plates of bone are only temporary is evidenced even at this time, for side by side with the osteoblasts are found osteoclasts (bone-destroyers), the two processes going hand in hand. The wall is being taken down as fast as it is built and carried farther out, so as to give more space for the rapidly-growing brain.

III. *Sub-periosteal Bone-formation.*—As the name implies, this form of development takes place underneath the periosteum, and is, of necessity, a later product than interstitial development. We have seen that repair of bone after caries is generally due to this mode of growth.

The vascular supply for the nourishment of bones is largely located in the periosteum. Small branches of the larger trunks of vessels, which are found in the periosteum, penetrate the cortical portion and form anastomosing loops with other branches which are found in the marrow-cavity. It is thus that Haversian canals are formed at right angles to the surface of the bone, and are seen to radiate toward the

FIG. 325.

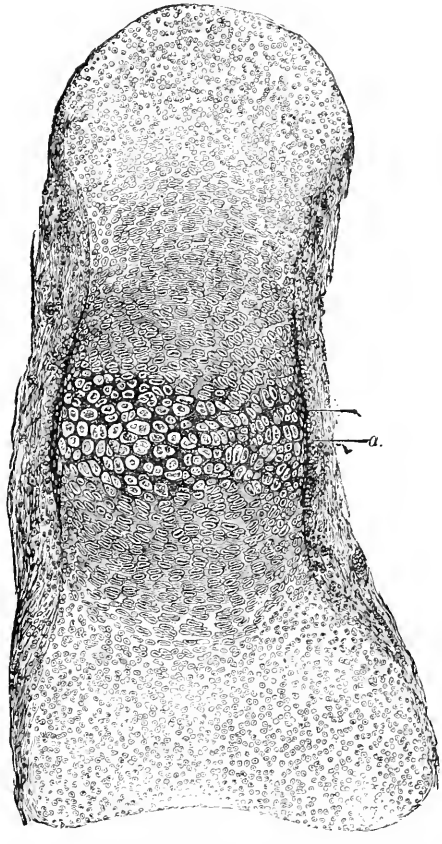

Section of Phalangeal Bone of Human Fœtus, 5 months (magnified about 75 diameters); *oz*, the cartilage-cells in the centre, midway between the epiphyses, are enlarged and separated from one another by a dark-looking calcified matrix; *im*, layer of bone deposited underneath the periosteum; *o*, layer of osteoblasts by which the layer has been formed. Some of the osteoblasts are already embedded in the new bone as bone-cells in the lacunæ. The cartilage-cells are becoming enlarged and flattened, and are arranged in rows above and below the calcified centre. At the ends of the cartilage the cells are small, and the groups are irregularly arranged; the cartilaginous heads are surrounded by perichondrium.

centre like the spokes of a wheel, following no regular course, but winding here and there, sometimes crossing and recrossing one another.

In the shaft of a long bone the Haversian systems follow the line of

the axis of the bone, the irregular arrangement being most generally found near the ends of the bone.

Subperiosteal bone-formation does not begin evenly along the surface

Fig. 326.

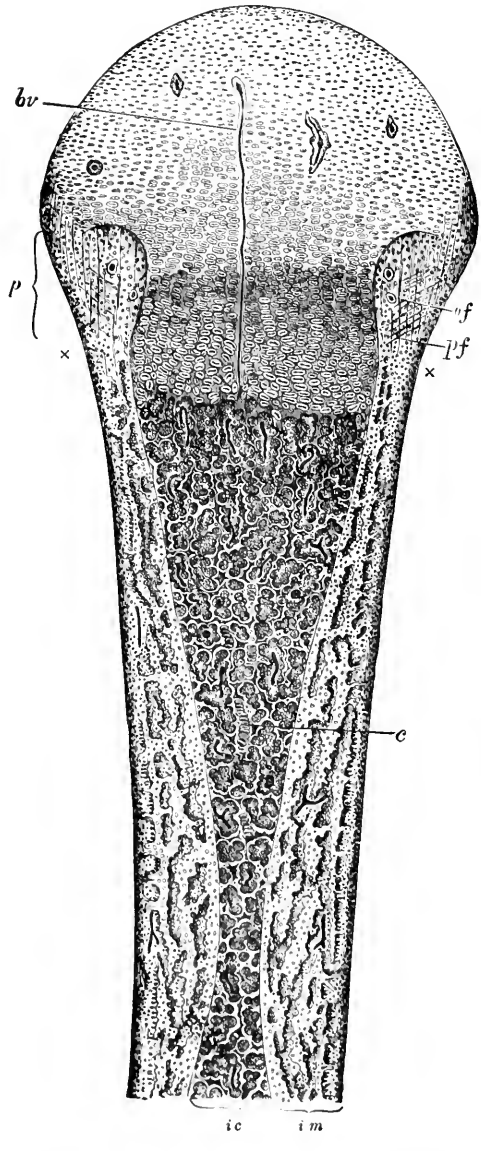

Longitudinal Section through the Upper Half of the Decalcified Humerus of a Fœtal Sheep, as seen under a magnifying power of about 30 diameters: *ic*, the part of the shaft which was primarily ossified in cartilage; what remains of the primary bone is represented as dark, enveloped by the clear secondary deposit. The areolæ of the bone are occupied by embryonic marrow with osteoblasts, and blood-vessels variously cut, represented as dark lines. One long straight vessel (*bv*) passes in advance of the line of ossification far into the cartilaginous head; most of the others loop round close to the cartilage. At one or two places in the older parts of the bone elongated groups of cartilage-cells (*c*) may still be seen, which have escaped absorption. *im*, the part of the bone that has been ossified in membrane—that is to say, in the osteoblastic tissue under the periosteum. It is well marked off from the central portion, and is bounded, peripherally, by a jagged edge, the projections of which are indistinctly seen to be prolonged by bunches of osteogenic fibres. A row of osteoblasts covers the superficial layer of the bone. The subperiosteal layer is prolonged above into the thickening (*p*), which encroaches upon the cartilage of the head of the bone, and in which are seen, amongst numerous osteoblasts and a few blood-vessels, the straight longitudinal osteogenic fibres (*of*), and some other fibres (*pf*) crossing them, and perhaps representing fibres of Sharpey. The calcareous salts having been removed by an acid, the granular ossific deposit passing up between the rows of cartilage-cells is not seen in this specimen; it would have extended as far as a line joining the marks × ×. Observe the general tendency of the osseous trabeculæ and the vascular channels between them to radiate from the original centre of ossification. This is found to prevail more or less in all bones when they are first formed, although the direction of the trabeculæ may afterward become modified in relation with varying physiological conditions, and especially as the result of pressure in different directions.

underneath the periosteum, but at certain points which are governed by the location of a capillary blood-vessel. At first lamellæ are developed at right angles to the periosteum; the first-formed layer is pitted and uneven, but as the process extends the bone becomes more compact,

until a smooth surface is formed. From this time on, even through the process of resorption and rebuilding, the surface is nearly always found to be smooth. The Haversian systems themselves almost entirely disappear in the cortical portion of long bones, the final deposition being from layers of osteoblasts which are found directly underneath the periosteum. Thus a dense cortical bone is formed which gives strength to the bony columns (Fig. 324, *a*).

In some instances the penetrating fibres of the periosteum are found in this cortical portion. These may persist for a longer or shorter time as such, and are known as Sharpey's fibres (Fig. 7, p. 41, Sec. on Anatomy). A similar arrangement is seen at the point of tendinous attachment for muscles.

IV. *Intercartilaginous Development of Bone.*—As early as the fifth day in the chick and in 1 cm. fetal pigs certain bones are found preformed in cartilage—viz. the bones of the skeleton, occipital, sphenoid, ethmoid, nasal, etc. It will be found that these cartilaginous formations bear a very close resemblance to the bones which will replace them; they are the matrix-formers which serve as the antetypes of the mature tissues. This is shown very nicely in Fig. 325; here the epiphyses are similar in form to the mature articulating heads of the phalangeal bone. The cartilaginous heads are only separated by the zone of ossification. If the section had been made through the same phalanx, before development had progressed quite so far, the heads would have been seen to be in apposition.

The increase in length of the bone is by the development of the shaft, the heads being pushed lengthwise in either direction. The first perceptible change is seen about the middle of the phalanx. The cartilage-cells are enlarged at the expense of the intercellular hyaline basement-substance, which latter is becoming finely granular in appearance, due to infiltration of minute granules of lime salts. This change in the character of the cartilage-cells can be seen extending a considerable distance from the borderland of calcification. The cells have arranged themselves into rows on a line with the axis of the shaft, gradually diminishing in size from the enlarged cells in the ossification zone, to their normal size as found in the unchanged heads. The capillary blood-vessels push their way into the calcifying cartilage, or, what is more probable, the penetration of the capillaries antedates the change in the cartilage. This arrangement is very nicely shown at *br* in Fig. 326, where a blood-vessel has burrowed its way into the very centre of the cartilaginous head.

The zone of calcification which has been figured so extensively as occurring in the central portion of the head, and which some authors claim is independent of the action of the blood-vessels, I have proven—to my satisfaction, at least—to be none other than a zone of calcification located around the terminal loop of one of these vessels.

Sometimes vessels may be seen to enter the head of the cartilage from the sides as well as from the marrow-cavity, and wherever they penetrate we find alterations in the character of the cartilage-cells. These changes are chiefly confined to the arrangement and deposition of lime salts in the basement substance.

Prudden says:[1] "If we examine the cartilage at a considerable distance from the line of ossification, we find the ordinary appearance of hyaline cartilage with more or less flattened cells. Approaching now the zone of ossification, we find that the cells are larger, are

FIG. 327.

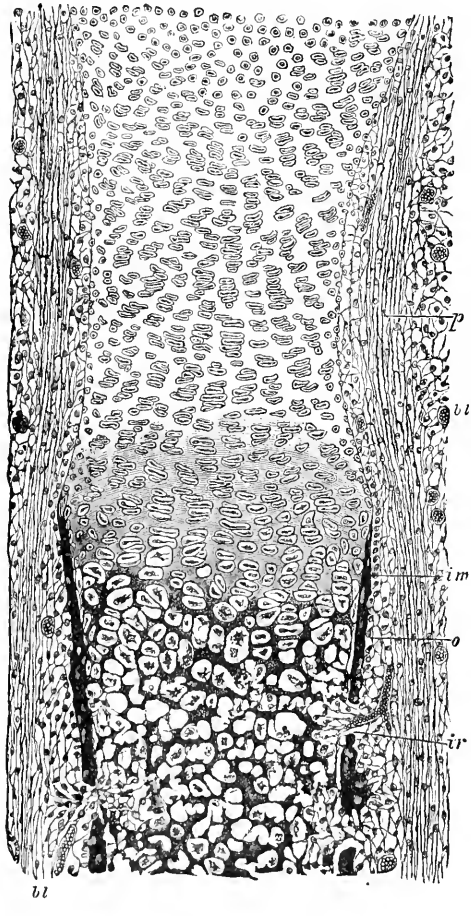

Section of Part of one of the Limb-bones of a Fœtal Cat, at a more advanced Stage of Ossification than is represented in Fig. 325, and somewhat more highly magnified. The calcification of the cartilage matrix has advanced from the centre, and is extending between the groups of cartilage-cells, which are arranged in characteristic rows. The subperiosteal bony deposit (*im*) has extended *part passu* with the calcification of the cartilage matrix. The cartilage-cells in the primary areolæ are mostly shrunken and stellate; in some cases they have dropped out of the space. At *ir* and in two other places an irruption of the subperiosteal tissue, composed of ramified cells with osteoblasts and growing blood-vessels, has penetrated the subperiosteal bony crust, and has begun to excavate the secondary areolæ or medullary spaces; *p*, fibrous layer of the periosteum; *o*, layer of osteoblasts: some of them are embedded in the osseous layer as bone-corpuscles in lacunæ; *bl*, blood-vessels occupied by blood-corpuscles. Beyond the line of ossific advance the periosteum may be noticed to be distinctly incurved. This incurvation is gradually moved on, the cartilage expanding behind it until the head of the bone is reached, when it forms the periosteal notch or groove represented in the preceding figure.

arranged in rows or groups of frequently four, eight, or sixteen, etc., the intercellular substance being less in amount, corresponding to the increase in size and number of the cells. Farther inward we find the cells still more plainly arranged in rows, very large, sometimes globular or flattened against one another, and the basement-substance reduced to quite thin septa, enclosing spaces in which the rows of large cartilage-cells lie. Then comes a narrow zone, in which the septa of the basement-substance are filled with fine granules of lime salts: calcification zone. Here the cartilage-cells have assumed a peculiar granular character. Finally, still nearer we find that the lime salts have disap-

[1] T. M. Prudden, *Normal Histology.*

peared from the septa, and that the spaces which contained the large granular cartilage-cells have become continuous with the advancing vascular, bone-walled marrow-cavities, above described. It is to be distinctly understood that the calcification zone is not bone, but only calcified cartilage, the true bone being first formed after this lime has disappeared, on the surface of the septa in which it was temporarily deposited—for what purpose we do not know." (See accompanying figure, 328.)

FIG. 328.

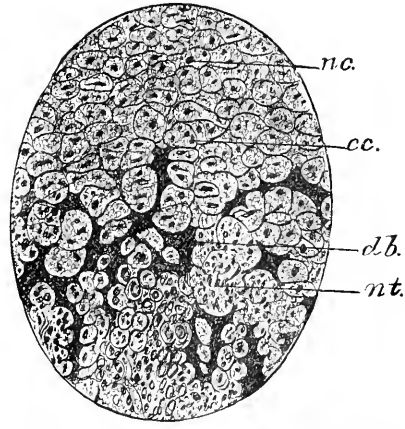

From Femur of Human Fœtus of 5 months (× 250): *nc*, normal cartilage; *cc*, calcified cartilage; *db*, the dark line representing developing bone; *mt*, marrow tissue.

The lengthening of the shaft proceeds until the cartilaginous head itself becomes ossified, when all further extension ceases and the bones are said to be fully developed. This time varies in different bones and also in the same class of bones.

As regards the origin of the osteoblasts in the first instance I am pretty fully convinced that they are the ordinary embryonic connective-tissue cells. That this is so in the very early stages such as we have described in interstitial development (p. 580) there seems to be no room for doubt. The close intimacy between the vascular supply and ossification tends to confirm the opinion held by some, that they are modified white blood-corpuscles. For my part, I see no antagonism between the two theories above mentioned. I think it can be quite clearly demonstrated that even fixed connective-tissue cells are only modified white blood-corpuscles which have passed through several gradations governed by location and environment, appearing (I.) as white blood-corpuscles in the vessels; (II.) as escaped white blood-corpuscles; (III.) plasma-cells; (IV.) fixed connective-tissue cells. Ziegler has made extensive studies in regard to the changes of the migrated white blood-corpuscles into fixed connective-tissue cells in pathological conditions where there is set up a process of progressive metamorphosis, and says that without doubt such is the process of change.

Osteoblasts are a constant concomitant of bone-formation. Ossification is a process which is under the superintendency of the osteoblasts. We have seen that there exists an intimate relationship between the vascular supply and calcification which precedes ossification. The breaking down of the cartilaginous matrix is, without doubt, due to the modifying influence of the capillary vessels. The hyaline basement-substance is dissolved and the cartilage-cells are liberated. These cartilage-cells pass into the form of fibrillated connective-tissue cells from which cartilage is originally developed.

The point I desire to make is this—that the white blood-cells are the common basis from which the several members of the connective-tissue

group spring. In some instances osteoblasts are produced from connective-tissue cells; sometimes they have their origin in cartilage-cells; but their most frequent and persistent source is found in the white blood-corpuscles.

Nature always uses the material at hand, in so far as it is available. If the bone is being deposited by intercartilaginous ossification, there is no necessity that the cartilage-cells should be destroyed or materially altered. They are, no doubt, modified and endowed with special functional powers; in a word, they become osteoblasts. And such use of pre-existing cells may occur in intramembranous and subperiosteal bone-formation. The fixed connective-tissue cells in all probability act as centres of calcification. In interstitial ossification true fibrous connective tissue has not as yet been found; it is embryonic connective tissue, and the cells are consequently embryonic connective-tissue cells.

There is very little difference, except as regards size, between the osteoblast and the surrounding connective-tissue cells. Thus we find that bone is developed in truly embryonic tissue as well as in older tissues; it is developed in cartilage and in membranes; it is developed in normal and in pathological conditions; and yet the process of ossification is ever the same, although the location or arrangement of the deposition may vary according to the essential differences in the tissues in which bone is formed. The only unvarying element that is found in intimate relation with all these tissues is the migrated white blood-corpuscle; and, by reason of its close relationship with the process of ossification, it seems to me to be more reasonable to infer that the white blood-corpuscle becomes modified in form and endowed with such specialized functional power as to be able to superintend the development of bone.

Cementification.

This is only a slightly-modified form of *subperiosteal* development of bone. In mature tissues the pulp, covered by a layer of dentine varying in thickness, acts as a large Haversian canal, around which the cement is deposited in concentric layers, the whole forming a large Haversian system. Sometimes this arrangement is modified, and Haversian canals are seen running at right angles to the surface. When this does occur, cementification differs in no respect from subperiosteal bone-formation.

I have cut sections from the roots of teeth in which well-defined Haversian canals were seen to enter the sides of the roots, and I have no doubt that if we were to search for them more carefully we could often find them. Quite a number are recorded in dental literature under the name of *multiple foramina*.

Cementification is the analogue of subperiosteal formation of the cortical substance of long bones. The first deposited layer of cement is permanent, there being no *provisional* cement to be afterward broken down. The circumference of the root at the beginning of the process of the deposition of cement is as great as it ever attains. The increase in thickness of the dentine is from the periphery toward the centre, at

the expense of the size of the pulp, just as the Haversian systems develop by successive layers of calcospherules which are situated inside the circumferential layer. The thickening of the cement is from the first layer deposited upon the dentine externally, thus enlarging the circumference of the root. The limit to this accretion is found in the fully-formed alveolar wall which surrounds the root.

When, at certain points, the process extends beyond typal limitations, we have a pathological condition, and malformation results; in later years the cement may become thickened (exostosis) as the result of constant irritation.

We find that the process differs in no degree from the first-formed cement. The pericementum is analogous and continuous with the periosteum. It is a *cement* organ only in the same degree that the periosteum is a *bone* organ. We know that both have the special function of superintending the deposition of their several products after injury or loss, and that, stimulated by irritation, they produce pathological conditions by secondary deposits. They are the persistent organs under the direction of which nature repairs injuries.

The individual elements which form cement are the osteoblasts, or—if it is desirable to increase the number of terms in connection with tooth-development—the *cementoblasts*. Calcospherules of lime are formed in a manner similar to those described in connection with our study of ossification.

FIG. 329.

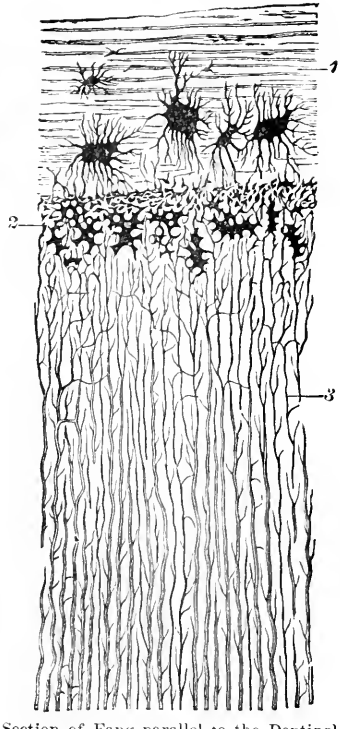

Section of Fang parallel to the Dentinal Tubules (magnified 300 diameters): 1, cement, with large bone-lacunæ and indications of lamellæ; 2, granular layer of Purkinje (interglobular spaces); 3, dentinal tubules.

A single layer of osteoblasts, or *cementoblasts*, is first formed around the periphery of the dentine of the root. By a process identical with that of subperiosteal bone-formation, the cementoblasts become enclosed in spherules of lime; successive layers appear, each in turn assuming the characteristics of the first-formed layer, till finally, by their aggregation, the cement is thickened to the typal point. A section of cement showing the similarity existing between it and bone is seen in the accompanying figure (329, 1). The union of the cement and the dentine is also shown very nicely, and will be referred to farther on, when treating of that subject.

DENTINIFICATION.

Dentine is a specialized product developed by specialized cells. In form dentine is very different from the several varieties of bone hereto-

fore considered. We have already studied—under the head of the connective-tissue group—the development of the special cells which superintend its formation—viz. odontoblasts.

Dentine is only a still more modified form of bone than cement. If we so desired, we could make a fifth class of ossified products and call it *tubular ossification;* but I prefer to hold to the existing nomenclature, and will speak of the process as *dentinification.*

Like cement, the first layer of dentine formed is a *permanent product.* I use the term in contradistinction to provisional deposition as found in the study of ossification.

Odontoblasts are a modified form of connective-tissue cells. They are situated upon the periphery of the pulp, and send out rod-like processes to the inner side of the enamel organ in the crown.

Under the superintendency of the odontoblasts lime salts are deposited around these rod-like fibrils, and thus form tubular dentine.

In our study of the development of bone we found that canaliculi were formed by the deposition of lime salts around the fibrils of the osteoblasts and within the calcospherules. Each calcospherule is a separate entity composed of an organic bone-cell with radiating processes around which inorganic lime salts have been deposited in such a manner as to form a perfect spherule. The dental pulp may be compared to a gigantic osteoblast, the fibrils of the odontoblasts representing the fibrils of the osteoblast. The dentine covering the pulp corresponds to the wall of the calcospherules, and the canals of the dentinal tubuli to the canaliculi.

The deposit of dentine is the work of mature cells which lie upon the surface of the dentinal pulp, being arranged in a single row. Dentine is a secretion of lime salts under the superintendency of the odontoblasts—not around themselves, as in the case of the encapsuled osteoblast, but around their fibrils. These being rod-shaped, the deposition naturally assumes a tubular form. The fibrils remain as the persistent organic contents of the dentinal tubuli, just as the fibres of the bone-cells are found to occupy the canaliculi. The thickening of the dentine is by accretion of lime salts in such a manner as to lengthen the tubuli. The fibrils lengthen as the dentine thickens, and the odontoblasts recede before the forming dentine, leaving a process behind.

FIG. 330.

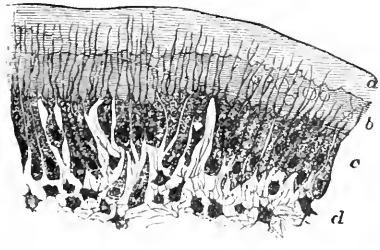

Part of Section of developing Tooth of young Rat, showing the Mode of Deposition of the Dentine (highly magnified): *a*, outer layer of fully-calcified dentine; *b*, uncalcified matrix with a few nodules of calcareous matter; *c*, odontoblasts with processes extending into the dentine; *d*, pulp. The section is stained with carmine, which colors the uncalcified matrix, but not the calcified part.

Each individual odontoblast does not become encapsuled, as do the osteoblasts, but remains free upon the surface of the pulp all through the life of that organ. They do, however, become encapsuled, in the aggregate, by the dentine of the entire tooth.

As we have before said, the pulp, with the odontoblasts, represents a

bone-cell; the pulp-cavity, a lacuna; while the dentinal fibrils are analogous to the processes of the bone-cells. The canals of the dentinal tubuli represent the canaliculi in which the processes or fibrils are situated.

We have seen that the thickening of the wall of the calcospherule is at the expense of the size of the osteoblast, and to a certain extent this is true of the tooth. But it must be remembered, however, that deposition of dentine is from one side of the odontoblast, and not circumferentially, as is the case in ossification (Fig. 330).

Additions to the thickness of bands of bone are produced by the addition of successive layers of osteoblasts, which one after another become enclosed by the deposition of lime salts. The thickening of the dentinal wall is accomplished by a single layer of odontoblasts which begin the process, and these cells persist throughout the life of the pulp, and when stimulated by the irritation of invading decay have the power to throw out a secondary layer of dentine, which acts as a barrier against the enemy. This thickening is at the expense of the cavity of the pulp, and consequently of that of the size of the organ itself.

The formation of the dentine of the root is also somewhat similar. The circumference of the outer layer of the dentine of the root is as great when first formed as it ever will be. The thickening of the wall is by a process similar to that seen in the Haversian systems, which, as we know, is at the expense of the contents of the Haversian canals.

The dentine of the root of a tooth is a hollow column which increases in length by extension and in thickness by internal deposition of lime salts. Under the superintendency of the odontoblasts new layers are being continually added to the end of the tube until the necessary length is completed. The apical foramen is the open end of the column. As the root reaches the required length this open end is constricted by internal deposition, and finally almost closes, until we see it as it appears in the ordinary apical foramen. The dentine reaches its required thickness in the crown first. Sometimes more than one apical foramen is found in a single root. This is due to a division of the pulp in this special case, and the phenomenon is governed by the same law that regulates the development of the separate roots of the molar teeth. The papilla divides into several parts, which indicate the position of the future roots, and dentine is developed around each part in a manner exactly similar to that which we have above described.

In the development of the dentine of the crown the process is somewhat modified. In shape the dentine of a tooth has the outward appearance of a double cone, the bases uniting at the cervical portion. The papilla, beginning as a microscopic object lying in what is afterward the very apex of the pulp at the cutting edge of the tooth, commences the deposition of the dentine directly under the enamel organ, and the tubules are developed in a line corresponding to the axis of the tooth. The papilla rapidly widens at its base, throwing out odontoblasts from its side, and as it does so the direction of the tubules gradually changes, tending more and more to a position at right angles to the axis; which position they assume at the neck of the tooth. The pulp has its great-

est diameter at the cervical portion at the time when the first developed layer of dentine is formed at that line. From this time forward the thickening of the wall of the dentine of the crown can be truly said to be at the expense of the size of the pulp.

Many persons have been deceived by mistaking the microscopic organ for the fully-developed, or macroscopic, tooth. At eight months the crown is not yet fully formed. The infolding of the lower portion of the enamel organ is due partly to the shrinkage of the very delicate pulp-tissue at its deepest extremity and partly to the fact that the deepest edge of the enamel organ always precedes the specialization and full development of the pulp. These contracted edges will in time be straightened by the expansion and growth of the pulp at that point. In order to become convinced that this appearance is not the extension of the enamel organ below the cervical portion of the tooth, as has been claimed by some (thus making the cement organ a continuation of the enamel organ), it is only necessary to measure the length of the enamel organ in its different stages of development and compare these with the length of a fully-developed enamel cap.

It is difficult for the mind to picture the whole of an object from a part, and it is still harder for it to grasp the wide distinction existing between microscopic and macroscopic objects. But the interpretation of the location of the cervical margin of a developing tooth, which at six or eight months has become a macroscopic object, is accomplished easily enough. This can be done with an ordinary pocket-rule, and does not require any of the refinements of microscopic measurement.

The deposition of dentine is around the fibrils of the odontoblasts, which latter stand nearly at right angles to the surface of the dentine.

Mature dentine is a solid mass of calcified tissue. It is held by some that it is composed of individual tubes; however true this may be of forming dentine, it cannot be said of mature dentine. In the process of development the salts of calcium are deposited around the fibrils of the odontoblasts, and in a certain sense dentinal tubuli may be said to exist at that time. We may say that dentine is an aggregation of tubes containing fibrils, but in the process of aggregation they lose their identity as such, becoming cemented together into a solid tissue.

I think, however, it is more in keeping with the facts in the case to say that dentine is a secretion thrown out by the odontoblasts in the meshes of the dentinal fibrils. The deposition is in the protoplasm which fills the interspaces between the fibres. By the deposition of lime salts into the protoplasmic basis-substance calcoglobulin is formed, and the dentine tissue becomes a homogeneous mass penetrated by many parallel canals filled with the persistent dentinal fibrils.

Besides the parallel canals filled with the dentinal processes, many lateral canals are seen branching off from the main tubes and forming anastomoses with neighboring canals. It must not be lost sight of for a moment that the appearances seen in ground sections of dentine are produced by the destruction of the contents of the dentinal canals. If we hold that distinct and separate dentinal tubes exist in mature dentine, then we must consider them as having many fine branches, increasing in numbers as we proceed toward the periphery of the dentine.

This is not consistent with our ideas of the character of a *tube*. No; the nature of dentine is very like that of mature bone: though it assumes a different form, yet it is developed in a similar manner, and by the aggregation and agglomeration of its individual elements a tissue is formed which we class among ossified products. Then, again, the occurrence of *interglobular spaces* in dentine militates against the tubular theory. These can only be explained by admitting that dentine is secreted into a protoplasmic basis-substance. "Interglobular spaces," so called, are composed of masses of calcoglobulin, which masses have not become fully calcified. The dentinal fibrils pierce them and are continuous upon either side (Fig. 331, *c*); while they make breaks in the continuity of the dentine tissue, yet they do not in any way interfere with the character or form of the dentinal processes. (For a discussion of the nature of calcoglobulin, see p. 574.)

FIG. 331.

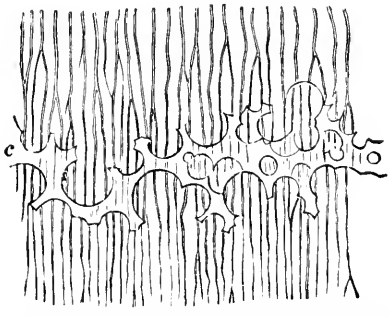

A small Portion of the Dentine with Interglobular Spaces (350 diameters): *c*, portion of incremental line formed by the interglobular spaces, which are here filled up by a transparent material.

In conclusion, the fact that dentine is not capable of being broken up into tubes is in my mind conclusive evidence against the theory of the existence of a *dentinal sheath per se* as the wall of a dentinal tube. Dentine is an osseous tissue permeated by numerous anastomosing canals which in life locate the fibrils of the odontoblasts.

AMELIFICATION.

The late Dr. Carpenter, who gave the greater part of his life to the study of conchology, and who has perhaps done more than any other man to lighten the dark places of this subject, says: "The structure of the *outer* layer of the common *Pinna* projects beyond the *inner*, and there often forms laminæ sufficiently thin and transparent to exhibit its general character without any artificial reduction. If a small portion of such a lamina be examined with a low magnifying-power by transmitted light, each of its surfaces will present very much the appearance of a honeycomb; whilst its broken edge exhibits an aspect which is evidently fibrous to the eye, but which, when examined under the microscope with reflected light, resembles that of an assemblage of segments of basaltic columns. This outer layer is thus seen to be composed of a vast number of *prisms* having a tolerably uniform size and usually presenting an approach to the hexagonal shape. These are arranged perpendicularly (or nearly so) to the surface of the lamina of the shell; so that its thickness is formed by their length and its two surfaces by their extremities. A more satisfactory view of these prisms is obtained by grinding down a lamina until it possesses a high degree of transparence, the prisms being then seen (Fig.

332) to be themselves composed of a very homogeneous substance, but to be separated by definite and strongly-marked lines of division. When such a lamina is submitted to the action of dilute acid, so as to dissolve away the carbonate of lime, a tolerably firm and consistent membrane

Fig. 332.

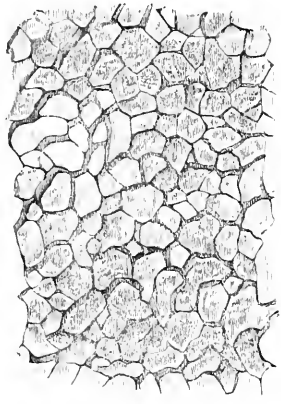

Section of Shell of *Pinna*, taken transversely to the direction of its prisms.

Fig. 333.

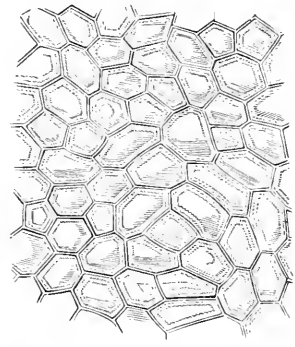

Membranous Basis of Shell of *Pinna*.

is left, which exhibits the prismatic structure just as perfectly as did the original shell (Fig. 333), its hexagonal division bearing a strong resemblance to the walls of the cells of the pith or bark of a plant." The shell of the *Pinna* and other species of the mollusk family is a structure analogous to enamel. Both are calcified products of the epiblast. We see variations in the form of the products of the connective-tissue group—as, for instance, in bone—and we also find variations in calcified epithelial structures. We have seen, in the calcification of bone, that cells do not *become* calcified, but simply *superintend* calcification; and I think we shall be able to show that the same rule holds good for the calcified products of the epiblast.

As we have already said, salts of calcium enter into chemical combination with proteids, and thus form a new group of products called by Mr. Rainey *calcoglobulin*. This modified form of albumen is insoluble in acids; therefore we have an organic matrix left behind after decalcifying the several varieties of bone. The form of the bone is seen in the decalcified material. This same matrix is found in the prismatic layers of shells, but not in enamel. There must, then, be some reason for its existence in the one case, and not in the other.

I hold, with Drs. Carpenter and Huxley, that all calcified products are excreted, and that there is not an actual conversion of living cells into calcified tissues. In some instances the cells become encapsuled, but lime salts are not deposited in the body of the cell; in other words, calcification by conversion cannot be demonstrated. In the formation of bone variations occur due to the position and matrix in which the deposition takes place; this is also the case with the products of the epiblast. The shell of the *Pinna* is excreted, or shed out, upon the sur-

face; the calcified product occupies the position of the *stratum granulosum*, or what I term the *older* layer of cells. Upon the surface of the prismatic layer we find a layer of hornified or corneous cells, and, underneath the calcified tissue, the formative layer—viz. the rete Malpighii, or *infant* layer of cells.

It is well known that this infant layer, or rete Malpighii, consists of nucleated structures which lie in a bed of protoplasm. This layer of protoplasm surrounds and bathes the cells of the older layer to a certain extent, growing less and less in quantity as we approach the surface. This protoplasmic substance does not differ in character from that which surrounds the cells of the connective-tissue group. So far as we know, the two fluids are identical: salts of calcium enter into chemical combination with protoplasm in the latter case, and why not in the former?

The first-formed layer of the shell of the mollusk lies in the protoplasm which bathes the formative, or infant, layer of cells of the rete Malpighii. These cells are the active agents in its deposit; they have become specialized and endowed with new functional power that they may superintend the deposition of the salts of calcium which enter into the composition of the shell. Their office is identical with that of the osteoblast.

The calcium salts are shed out from the ends of the cell as from the surface of a membrane—which, indeed, they form. They do not become individually encapsuled, as do the osteoblasts, but the body of the *Pinna*, covered externally with epithelium which remains as the lining membrane of the shell, becomes enclosed by the shell, and thus the infant layer may be said to be encapsuled.

The thickening of the shell is at the expense of the size of the body of the *Pinna*, just as the thickening of the wall of the calcospherule is at the expense of the size of the osteoblast. If we decalcify a shell and make sections, we find a matrix which differs only in form from that found in bone. The prismatic layer of the rete Malpighii has laid down the calcified products in the form of prisms, and cross-sections of the decalcified product will reveal their form just as well as ground-sections. Cross-sections will present the appearance of a honeycomb from which the honey has been extracted: the extracted honey compares to the salts of calcium, which before decalcification existed as prisms, and occupied, as did the fluid honey, the cells of the comb.

In the development of the shell the protoplasm shed out *between* the prismatic cells of the infant layer is limited in quantity. The secreted salts of calcium which are thrown out *by* the cells enter into chemical combination with the peripheral layer of protoplasm and form calcoglobulin, which, as we have before shown, is insoluble in acids. The sheath which surrounds the prism, as the protoplasm does the prismatic cell, may be compared to the wax in the cell of the honeycomb. Regarding the sheath, and the material which enters into its structure, Dr. Carpenter says:

"It sometimes happens in recent, but still more commonly in fossil, shells that the *decay of the animal membrane leaves the contained prisms without any connecting medium.* As they are then quite isolated, they

can be readily detached one from another, and each may be seen to be marked by striations. By making ground-sections of the shell perpendicularly to its surface we obtain a view of the prisms cut in the direction of their length (Fig. 334), and they are frequently seen to be marked by delicate transverse striæ closely resembling those observable on the prisms of the enamel of teeth, to which this kind of shell-structure may be considered as bearing a very close resemblance except as regards the mineralizing ingredients. If a similar section be decalcified by dilute acids, the membranous residuum" (the interprismatic cement-substance, which by its insolubility in acids shows it to be perhaps identical with Mr. Rainey's calcoglobulin) "will exhibit the same resemblance to the walls of the prismatic cells viewed longitudinally, and will be seen to be more or less regularly marked by the transverse striæ just alluded to." (See Fig. 335.)

FIG. 334.



Section of Shell of *Pinna* in the direction of its prisms.

FIG. 335.

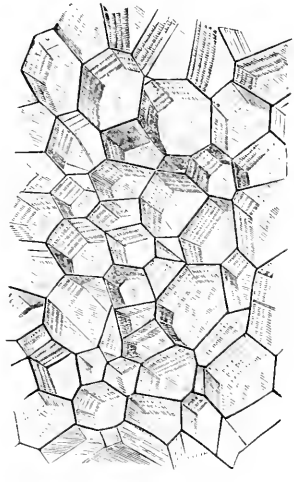

Oblique Section of Prismatic Shell-substance.

"These appearances seem best accounted for by supposing that each (prism) is lengthened by successive additions at its base.

"This 'prismatic' arrangement of the carbonate of lime in the shells of *Pinna* and its allies has been long familiar to conchologists and regarded by them as the result of crystallization. When it was first more minutely invested by Mr. Bowesbank and the author, and was shown to be connected with a similar arrangement in the membranous residuum left after the decalcification of the shell-substance by acid, microscopists generally agreed to regard it as a calcified epidermis, the long prismatic cells being supposed to be formed by the coalescence of the epidermic cells in files and giving their shape to the deposit of carbonate of lime formed within them. The progress of inquiry, however, has led to an important modification of this interpretation, the author being now disposed to agree with Prof. Huxley in the belief that the entire thickness of the shell is formed as an excretion from the surface

of the epidermis, and that the horny layer which in ordinary shells forms this external envelope, or 'periostracum,' being here thrown out at the same time with the calcifying material, is converted into the likeness of cellular membrane by the pressure of the prisms that are formed by crystallization at regular distances in the midst of it.

"The *internal* layer of the shells of the Margaritaceæ and some other families has a 'nacreous,' or iridescent, lustre which depends (as Sir D. Brewster has shown) upon the striation of its surface with a series of grooved lines, which usually run nearly parallel to each other.

"As these lines are not obliterated by any amount of polishing, it is obvious that their presence depends upon something peculiar in the texture of this substance, and not upon any mere superficial arrangement. But when the nacre is treated with dilute acid, so as to dissolve its calcareous portion, no such repetition of membranous layers is to be found; on the contrary, if the piece of nacre be the product of one act of shell-formation, there is but a single layer of membrane. This layer, however, is found to present a more or less folded or plaited arrangement, and the lineation of the nacreous surface may perhaps be thus accounted for. A similar arrangement is found in *pearls*, which are rounded concretions projecting from the inner surface of the shells of *Avicula* and possessing a nacreous structure corresponding to that of 'mother-of-pearl.' Such concretions are found in many other shells, especially the fresh-water mussels, *Unio* and *Anodon*, but these are usually less remarkable for their pearly lustre; and when formed at the edge of the valve, they may be partly, or even entirely, made up of the prismatic substance of the external layer, and may be, consequently, altogether destitute of the pearly character. In all the genera of the Margaritaceæ we find the external layer of the shell prismatic and of considerable thickness, the internal layer being nacreous. But it is only in the shells of a few families of bivalves that the combination of organic with mineral components is seen in the same distinct form, and these families are for the most part nearly allied to *Pinna*. In the Unionidæ (or fresh-water mussels) nearly the whole thickness of the shell is made up of the internal, or 'nacreous,' layer; but a uniform stratum of prismatic substance is always found between the nacre and the periostracum, really constituting the inner layer of the latter, the outer being simply horny."

The nacreous layer of the shell is found upon the inner side, next to the formative layer, and, being polished, protects the shell against the action of any pathological condition which may occur in the body of the mollusk. The cortical, or nacreous, layer of enamel is also found next to the formative layer. They are both the last-formed products of the formative organ. The polished surface of enamel also protects it against pathological conditions which may arise in the surroundings of the tooth.

As we have seen, the shell is secreted above the infant layer of the rete Malpighii. By referring to the section on the development of the ameloblasts it will be seen that the *bulbous* cord invaginates itself, and thus forms a double cap for the dentinal papilla. By this invagination the ends of the cells, which were external in the bulbous cord, come in

contact with the outer surface of the papilla.. Now, the enamel is deposited, or secreted, from these lower, or deeper, ends of the ameloblasts; the prismatic layer found in shells, on the other hand, is secreted from the upper ends of the cells. If enamel were secreted in a similar manner, the ameloblasts would be situated between the forming enamel and the dentine; which is not the case.

The mineralizing constituents of enamel vary considerably from those of shells. The amount of *organic material* found in shells is also far greater than that of enamel.

Whether there is less protoplasm shed out from the under side of the cells than from the upper, and whether the mineral ingredients which go to form enamel-prisms do not enter into combination with the protoplasm as readily as do those of shells and bone, are points which I am not able to prove. It is certain, however, that there is found in enamel only a very small per cent. of *fixed material*.

I use the term *fixed material* to designate protoplasm which has passed into a state where it requires to be *digested* by and through the action of the living principle which is found in the non-fixed material. It is the "formed material" of Beale, and in this particular instance it is also the "calcoglobulin" of Mr. Rainey.

According to different chemical analyses, the amount of fixed material found in enamel varies from 1 to 3 per cent.; it is only demonstrable by chemical analysis. There is not a sufficient quantity of this material to be demonstrated by the microscope, as no trace of a matrix can be seen after decalcification. I doubt if there enters into the formation of enamel, *as a necessary constituent part*, the least trace of protoplasm or organic material. It would be very difficult indeed to obtain a portion of enamel for chemical analysis which would not contain some "*organic* material," using the term as in contradistinction to inorganic. I much prefer the use of *fixed* or *formed material*, for I think it has been pretty conclusively shown that organic, or living, matter cannot enter into chemical combination with inorganic matter, as such, except the living lose its living principle and become non-living (fixed or formed material). When we consider the fact that enamel is developed *in* and surrounded by organic matter, that it frequently encapsules a greater or less amount, and that the fibres of the dentine interdigitate with the enamel-prisms, it does not seem at all strange that analysis should show from 1 to 3 per cent. of "organic" material which has passed into formed material: a contrary result would be the more surprising.

If dilute acids are allowed to act upon shells, the salts of calcium which form the prisms are dissolved, leaving a matrix of fixed material (calcoglobulin). The interprismatic or fixed material is insoluble in acids; the latter only serve to harden and preserve the former. This interprismatic cement-substance surrounds the prisms as a sheath, and cross-sections of decalcified shells plainly demonstrate its existence. (See Fig. 333.)

When enamel is acted upon by dilute chromic acid for a short time, the interprismatic cement-substance is dissolved out and the prisms fall apart and remain unchanged, thus demonstrating that the material

which holds the prisms together is more freely soluble in this acid than are the prisms themselves, being just the reverse of what we have seen in decalcification of shells by dilute acids. Then, again, when, through disintegration, the organic material of shells is destroyed, the prisms are released and fall apart. Such an occurrence in connection with enamel is not known.

Regarding the striations found upon the enamel-prisms, I am fully satisfied that they are caused by inequalities upon the surface of the prisms. I submitted this question to Mr. Christian Febiger of Wilmington, Delaware, who is perhaps the best authority in this country upon Diatomaceæ. It is well known that in the study of diatoms the very greatest nicety of judgment is necessary in order to differentiate between such points as the one in hand, and the opinion of an expert microscopist like Mr. Febiger should have a very considerable weight. He said, without hesitancy, after studying a ground-section of enamel in which the markings showed quite plainly, that they were *wave-lines*, due, not to striations or interlacing fibres, but to inequalities upon the surface of the section. The section examined had been placed for a very short time in a dilute solution of muriatic acid and then washed and mounted in glycerin. By this method the markings show better than by any other I have used. The accompanying figure shows this

FIG. 336.

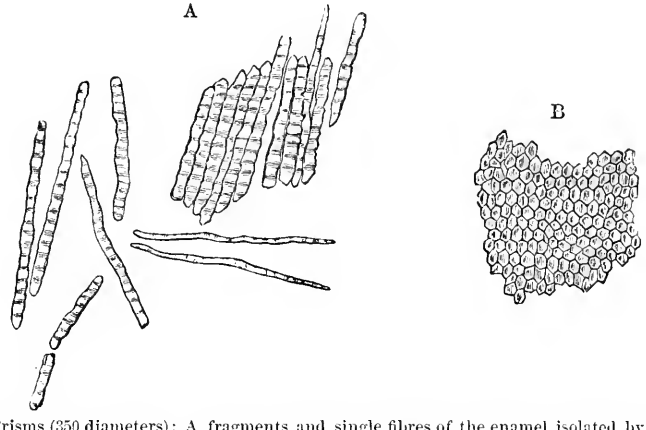

Enamel-Prisms (350 diameters): A, fragments and single fibres of the enamel isolated by the action of hydrochloric acid; B, surface of a small fragment of enamel, showing the hexagonal ends of the fibres.

appearance very accurately. Mr. Tomes has advanced substantially the same opinion; he says:

"In perfectly healthy human enamel the fibrillar arrangement is not so very strongly marked; the prisms are solid, are apparently in absolute contact with one another, without intervening substance.

"But Bödecker, basing his conclusions upon the examination of thin sections stained with chloride of gold, holds that enamel is built up of columns of calcified substance between which minute spaces exist. These are filled by a material which takes stain deeply and is probably analogous to the cement-substance of epithelial formations. As seen in

sections it gives off exceeding fine thorns, which apparently pierce the prisms at right angles to their length; so that it forms a close network very intimately mixed up with the calcified portion of the enamel.

"It is not of uniform thickness, but is beaded, and Bödecker attributes to it a rôle of far greater importance than that of a mere cementing substance, for he regards it as being an active protoplasmic network which renders the enamel much more 'alive' than it has hitherto been considered to be. He believes it to become continuous with the soft contents of the dentinal tubes through the medium of large masses of protoplasmic matter found at the margins of the enamel and dentine.

"But although there are various reasons for suspecting that enamel is not completely out of the pale of nutrition from the moment that a tooth is cut, yet further observations are needed before the activity and importance of the cement-substance demonstrated by Bödecker can be held to be fully established. Klein remarks that 'the enamel-cells, like all epithelial cells, being separated from one another by a homogeneous interstitial substance, it is clear that the remains of this substance must occur also between the enamel-prisms; in the enamel of a developing tooth the interstitial substance is larger in amount than in the fully-formed organ. It is improbable that nucleated protoplasmic masses are contained in the interstitial substance of the enamel of a fully-formed tooth, as is maintained quite recently by Bödecker.'"

The first-formed layer of enamel is deposited in more or less protoplasm. This is proven by the fact that we can decalcify immature or developing enamel up to a certain thickness, and yet have a matrix left. This layer becomes more fully impregnated with lime salts, and the later deposition, which adds to the length of the enamel-prisms, seems to be laid down without any matricial substance.

This first-formed layer constitutes the zone in which the dentinal fibres interdigitate with the enamel-prisms.

That points or spaces occur in enamel—the analogue of the interglobular spaces found in dentine—I fully believe; but such spaces are filled with calcoglobulin, and not with living protoplasm. Any such deviation is pathological, as it is in dentine.

Where these spaces occur upon the surface of the enamel, or so near the surface that the thin layer can be easily broken through, they give rise to the pitted or grooved points found in erupted teeth. The fixed material is dissolved out by soluble ferments produced by the organic tissue surrounding the erupting tooth. This fixed material is not soluble in the ordinary acids of the mouth, and only disintegrates through the action of soluble ferments and putrefactive processes. Regarding the character of these fluids I refer to Dr. Black's article upon the Pathology of Caries.

Variations in the hardness of enamel are due to several conditions, some normal, others pathological. Normal variations are found in different temperaments and in different species. The enamel on the teeth of rodents is much harder than that found upon the teeth of carnivorous animals. Such variations are illustrations of the law of "adaptation to environment," upon which so much stress is laid by some writers. This I admit, but claim that the adaptative power existed from *the beginning.*

These variations are seen in shells, and from the analogy found in their development I have no hesitancy in saying that variations in density of enamel are dependent upon the same conditions. Dr. Carpenter, speaking of the varying degrees of density found in shells, says:

"This [increased] hardness appears to depend upon the mineral arrangement of carbonate of lime; for, whilst in the prismatic and ordinary nacreous layers this has the crystalline condition of *calcite*, it can be shown in the hard shell of the *Pholas* to have the arrangement of arragonite, the difference between the two being evidenced by polarized light. A very curious appearance is presented by a section of a large hinge-tooth of *Myo-arenaria* (Fig. 337), on which the carbonate of lime seems to be deposited in nodules that possess a crystalline structure resembling that of the mineral termed *wavelight*. Approaches to this curious arrangement are seen in many other shells."

Fig. 337.



Section of Hinge-tooth of *Myo-arenaria*.

Variations in hardness of enamel may arise, as we have already indicated, by reason of pathological conditions resulting from interglobular spaces, which sometimes occur in enamel. The points are, without doubt, analogous to such spaces found in dentine. I am even willing to acknowledge that a condition corresponding to that found in shells may also be found in enamel—that is, an interprismatic matrix *can be formed;* but if it should occur, it would be pathological in character. I have ground many sections of teeth and examined many ground by others, but have yet to see the first specimen of an interprismatic matrix. That there is the least trace of organic interprismatic substance to be demonstrated in normal enamel I have very serious doubts, and think the action of dilute acids upon fully-calcified enamel substantiates the doubt.

Let us study such action.

A ground-section of mature enamel should be placed upon a slide and a cover-glass cemented on, leaving a small opening on two sides. If a $\frac{1}{5}$th of 1 per cent. solution of chromic acid be allowed to run under the cover by capillary attraction and then removed from the other side by blotting-paper, we can study the action of the acid upon the stage of the microscope with high powers.

But before we begin the study of the action of chromic acid on enamel let us see how it acts upon organic tissues. It is considered one of the best preservative fluids we have, and enters into the famous Müller's fluid, which is noted for its quality of preserving nerve-tissue. Now, if there is any organic substance in enamel, we shall be able to preserve it in good form and note the result. The interprismatic substance is first attacked by the acid and the prisms are liberated; chromate of calcium crystals are formed in great numbers. If there existed an organic interprismatic cement-substance, the action of this dilute solution of chromic acid

would tend to preserve it, and the prisms would be held together more firmly than before. After the acid has been allowed to act fifteen minutes it is displaced by distilled water and pressure made upon the cover-glass, when the prisms fall apart. They may now be easily examined even with very high powers.

If we substitute a solution of HCl (muriatic acid) for the chromic-acid solution, and of similar strength, we know that the organic tissues will be destroyed by its action. If there is any organic tissue cementing the prisms together, we should certainly be able to demonstrate it here; for the organic substance would be dissolved out and the prisms liberated. But is such the case? Far from it. The acid acts upon the enamel evenly as regards its penetration from the free margin; it dissolves the peripheral portion a little faster than it does the body of the prism, so that they present a somewhat dentated border along the external, or outer, surface of the enamel; but the whole mass gradually melts away before the action of the acid, not leaving the least trace of organic, or fixed, material behind, as in the decalcification of bone where the same acid is used. The fixed material, or calcoglobulin, as we have seen, is insoluble in acids; hence, if enamel were calcified—as is bone—by deposition in the albuminous intercellular substance, we should by both of the above methods have the matrix remaining after decalcification.

In my experiments I have taken every precaution against failure. I have embedded ground-sections of teeth fresh from the mouth in celloidin and fixed them upon a slide, taking care to cut the outlines of the teeth upon the reverse side of the slide with a diamond. After observing these precautions, I allowed a $\frac{1}{2}$ of 1 per cent. solution to flow under the cover-glass, and noted the result by placing the slide upon the stage of the microscope; but I have never been able to see any reticular substance after decalcification. I have also stained sections without being able to demonstrate any matrix. Such a basis-substance could not by any means have been lost or destroyed; the celloidin served as a perfect embedding mass, and was not acted upon by the acids in the least degree, neither did it hinder the process of staining; for it is well known to be more permeable to stains than tissue itself.

I took all these precautions because my observations regarding the action of acids upon enamel are not in accord with those held by C. Tomes and others, and I consider this a very essential point to establish accurately. Mr. Tomes does not state whether his experiments were made upon mature or developing enamel, but from the cuts he furnishes one would infer that his studies were made upon mature tissues, as it is not possible to demonstrate isolated prisms—especially striated prisms—until calcification is completed, or nearly so.

Then, again, Mr. Tomes speaks of the above-mentioned cut as follows:[1] "The accompanying figure, taken from enamel softened by prolonged maceration in a 1 per cent. solution of chromic acid, shows this well," etc. There is a mistake somewhere. Either Mr. Tomes's 1 per cent. solution of chromic acid is a great deal weaker than the one I use, or else English teeth decalcify more slowly than American teeth;

[1] Tomes's *Dental Anatomy*, p. 51.

for I have found that the action of a 1-per-cent. solution of chromic acid, even when not prolonged, results in complete decalcification and removal of the entire enamel-covering of a tooth. Again, Mr. Tomes says: "If dilute hydrochloric acid be applied to a section of enamel, the axial parts of the fibres (prisms) are first attacked, and are dissolved away; so that if the section be transverse a fenestrated mass remains." I think this phenomenon is capable of an opposite interpretation. If we carefully study sections of enamel ground in the direction of the axis of the prisms which have been exposed to the action of a very dilute solution (of HCl), we find that the edge is dentated, and that the light lines which mark the sides of the prisms end in the bottom of the indentations, thus clearly demonstrating that the action of the acid is slightly more rapid upon the *peripheral* than upon the axial portion of the prism.

The next statement made by Mr. Tomes I can fully substantiate. It is as follows: "During the formation of enamel the hardening salts are deposited first in (*around*) the periphery of the enamel-cells; so that the youngest layer of enamel is full of holes, each one of which corresponds to the centre of a fibre (prism)." This I have observed as a constantly-occurring phenomenon, and consider it as thoroughly substantiating my position that the enamel-cell, or ameloblast, superintends the deposition of the enamel-prism, and does not become directly calcified, as is held by Mr. Tomes.

I look upon enamel as nothing more or less than a coat of mail supplied by Nature to protect the dentine and subserve the processes of mastication. The presence of any considerable organic material in the enamel would be directly against the proper fulfilment of its office. Nature, when left to herself, develops a beautiful and symmetrical object perfectly capable of subserving its purpose, and any deviation from this standard is classed under the head of pathological conditions. The fluids of the mouth are *normally* alkaline or neutral, and against the action of such conditions of the saliva the constituent parts of enamel are proof. The enamel is not proof, however, against the action of acids; neither, indeed, was it intended to be.

The cross-striations found upon enamel-prisms as well as upon the prisms of shells indicate the manner of their development—*i. e.* by addition in length. This also accounts for the layers of pigment sometimes seen in these structures. They follow the course of the striated lines, and are undoubtedly laid down at varying times in the course of the formation of the prisms. The pigment seen in enamel is deposited by the ameloblasts. Experiments have been made of feeding young guinea-pigs upon madder, then allowing some time to elapse, after which the madder diet is resumed. When killed and the tissues studied, the madder dye was found to be deposited in bands or layers in the bone which was developed while the experiment was being carried on. The bands of unstained bone lying between the layers which had been colored by the dye represented the period which had elapsed between the different experiments. It was found that the width of the bands was entirely under the control of the experimenter, thus conclusively proving that the pigmentation was from within, and that it was secreted by the bone-

cells. I have no doubt that if the enamel had been examined it would have shown a similar arrangement.

The amount of pigment found in enamel varies very considerably in different animals, and generally bears a close relation to the density of the enamel; but whether it has any influence upon the hardness or not I am unable to say. Those teeth which have the greatest amount of pigment have the most compact formation, and *vice versâ*. Pigmentation after eruption comes from without and may be due to various causes: the use of tobacco is the most probable source of external pigmentation. The interprismatic cement-substance becomes dissolved by the acids of the mouth to a greater or less depth, and the pigment lodges in the spaces so formed, also coating the surface.

This pigmentation must not be confounded with the change in the color of the enamel which results from death of the pulp. In a vast majority of cases the enamel in human teeth, by reason of its translucency, transmits the varying changes in the color of the dentine. That there is no pigmentation of enamel itself in these cases may be proved by cutting out the underlying dentine and filling with chloride of zinc or some other white filling. Indeed, this mode of "mechanical bleaching" has come into almost general practice.

This naturally brings us to the consideration of the dense polished outer coat of enamel.

This layer shows a distinct characteristic variation from the prismatic layer underneath. It is the outer capping of the prisms, and furnishes a polished surface for the coat of mail which is best adapted for its office. Smooth, polished surfaces are known to resist the eroding action of acids longer than rough surfaces. The character and shape of the ameloblasts change before this layer is formed. From a membrane composed of prismatic cells, they now assume a horizontal direction. I have studied these changes in the form and direction of the axis of the ameloblasts in sections of incisor teeth of rodents, where it was very plainly shown. Enamel is here being continuously formed on the labial side, at the base of the tooth, to supply loss by attrition. All the stages of calcification, as well as the changes which occur in the ameloblasts, are plainly demonstrated in one tooth. Below a certain point the enamel-prisms are yet unfinished, and here the ameloblasts are seen to be prismatic in form; toward the surface they gradually shorten and widen until near the margin of the gum, when they change from a position at right angles with the axis of the tooth to a longitudinal direction. Mrs. Emily Whitman also noted these changes in studying the development of the teeth in the ray and rabbit. Mrs. Whitman says:

"The cuticula of the mammalian tooth has several times been found to have the same structure, and it has been possible, in transverse and longitudinal sections, to trace the gradual transition of the enamel-cells into a perfectly homogeneous membrane (Fig. 338), the cylindrical cells growing shorter as they approach the crown of the tooth, until, instead of being columnar, they are almost square, and finally flattened, and at last the outlines of the cells quite disappear, and there is left a perfectly homogeneous membrane.

"These changes are not easy to follow; in many preparations it is impossible to make anything out, and the drawings have been made from most fortunate preparations selected from some thousands of sections prepared in various ways.

"The cuticula dentis, then, is formed by the metamorphosis of more or less of the enamel-cells, and this metamorphosis may begin before

FIG. 338.

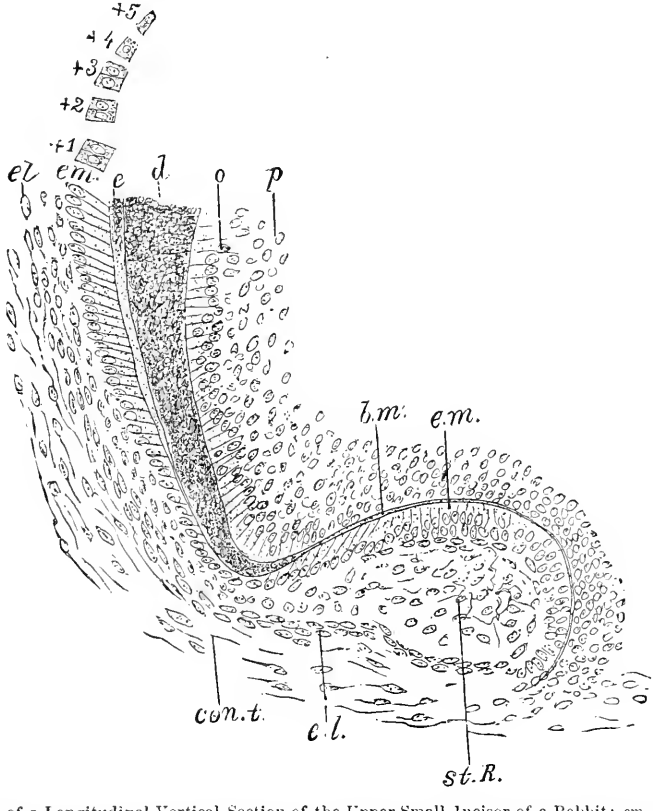

A portion of a Longitudinal Vertical Section of the Upper Small Incisor of a Rabbit: *em*, 1, 2, 3, 4, 5, are cells of the enamel-membrane drawn at intervals, showing their gradual change as they approach the crown of the tooth, until, on its exposed portion, they form a homogeneous membrane. Obj. F. Zeiss.

any calcification of the underlying dental tissues. In this stage it has been frequently taken for the 'newly-formed layer of enamel,' for the 'basement-membrane,' and for the 'first-formed layer of dentine.'"

It is evident that if the prisms depend upon the shape of the ameloblasts for their form the lime salts laid down from this altered membrane would differ materially from the secretion from the ends of the prismatic ameloblasts, and so we find it.

The analogy between the internal layer of the *Pinna*, which we have before studied, and the outer layer of enamel, is complete. Each individual prism of enamel is the work of a single ameloblast; the

outer layer of enamel, however, is secreted by the cuticula dentis before the tooth erupts.

The origin and office of Nasmyth's membrane, or cuticula dentis, has been a matter of very considerable speculation. I am fully convinced, from a study of the teeth of rodents, that this membrane arises by a metamorphosis of the ameloblastic layer as described by Mrs. Whitman, and I further believe that the change in the character of this membrane is of prime importance in the development of enamel. We have seen that the enamel-prisms derive their form from the prismatic ameloblasts. This being the case, the ameloblastic layer, as such, could not complete the calcification of the *cortical* layer of enamel. This layer is deposited underneath the cuticula dentis, and in its deposition the life-work of this membrane is completed; for it cannot be shown to have any other essential signification. In a newly-erupted tooth the enamel may be divided into three layers—the *internal*, or *prismatic;* the *cortical*, or *nacreous;* and the *organic layer*, or *cuticula dentis.*

FIG. 339.

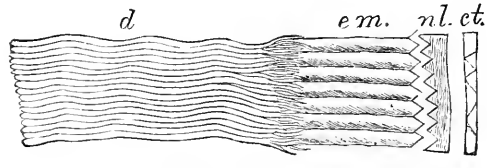

Diagrammatic Section of Enamel and Dentine: *d*, dentine; *em*, enamel prisms; *nl*, nacreous layer; *ct*, cuticula dentis.

In the nacreous, or cortical, layer we have a structure analogous in formation and character to the internal, or nacreous, layer found in shells. The latter has been conclusively demonstrated by Dr. Carpenter to be secreted by the altered layer of cells which produced the older prismatic layer. The cuticula dentis corresponds to the membrane described by Dr. Carpenter as found in connection with the nacreous layer of shells.

Variations in density in the enamel of the teeth of different individuals are due to several causes. The first essential difference lies in the proportionate amounts of phosphate and carbonate of calcium. Enamel in which there is more than a minimum amount of calcium carbonate will be softer than enamel which contains less—the deficiency being supplied by phosphate of calcium—and *vice versâ*, as will be seen from the following table, made by Von Bibra:

	Adult man.	Adult woman.
Calcium phosphate and fluoride	89.82	81.83
Calcium carbonate	4.37	8.88
Magnesium phosphate	1.34	2.55
Other salts	.88	.97
Cartilage	3.39	5.97
Fat	.20	a trace.
Organic	3.59	5.97
Inorganic	96.41	94.03

It will be seen by the above table that the essential point of difference between the enamel of man and woman lies in the contained amount

of carbonate and phosphate of calcium. It is a well-known fact that, as a rule, the teeth of women are softer than those of men; this, I think, is accounted for by the greater per cent. of carbonate salts of calcium, being 4.37 in man and 8.88 in woman. There is also found more "organic," or fixed, material in the teeth of woman than in man—5.97 in the former, as against 3.59 in the latter. We have already seen that in that degree in which enamel contains fixed, or organic, material is it incapable of performing its office and resisting the action of the fluids of the mouth.

Dr. Miller of Berlin has very conclusively shown that the products of fermentation have the power of digesting the fixed material found in dentine; they therefore would act upon any similar material found in enamel. But, as I have said before, any considerable amount of fixed, or organic, material in enamel is pathological, and enamel that contains such material will be found to decay very early in life.

The newly-erupted tooth hardens by desiccation after it makes its appearance. The saliva found in a child's mouth is neutral or, more generally, alkaline. The latter condition probably extracts water from the enamel. The teeth are constantly exposed to currents of air, which certainly extract water. This is fully demonstrated by the *checking* of the enamel in the mouths of persons who habitually breathe through the mouth. The fact that the enamel of teeth which have been extracted for some time becomes so hard that it will turn the edges of our best burrs proves the correctness of my assertion, that enamel hardens by desiccation.

A crystallized substance of the character which we are studying cannot become denser than it is except by giving up a portion of its water of crystallization. Crystallized bodies vary in density, but the variation is due to the different forms of crystallization of the several ingredients which go to make up the body. When crystals give up a part of their water of crystalization they become exceedingly brittle. Now, enamel is not a pure crystallized product, but, nevertheless, evinces this same property to a considerable extent; you can chip the thin edge of the enamel in the artificially dried tooth very easily by slight pressure of the thumb-nail. I know of no law by which a crystal once formed can become denser except by the one already named—viz. that of desiccation. I know it is a popular idea among dentists that enamel varies in hardness at different times, but I have never seen a case where I was fully convinced that enamel once softened by the acids of the mouth ever became harder, except, it might be, by desiccation. I have seen children's teeth which were quite soft when erupted become harder in *time*, and by the use of *tooth-powders;* but whether it was the powder or the *time*—which latter allowed of desiccation—is an open question. I am in favor of crediting the latter with accomplishing the benefit. I have been in the habit of using powder dry, and so advising my patients. I have no doubt that, so used, it will extract water from the enamel and hasten the hardening process.

The enamel of teeth which have given up a portion of their water of crystallization do not resorb it and return to their former condition.

When it has become *checked* by constant breathing through the mouth, it always remains checked. Then, again, I have no doubt that teeth the enamel of which has softened—during pregnancy, for instance—may appear to harden; but in such cases the softening has been superficial, and this thin layer, by the processes of attrition, becomes worn away, and the underlying layer of enamel, which has not been affected, becomes polished and cannot be told from the outer layer by ordinary observation.

Finally, then, enamel is the product of an organ which in the eruption of the tooth ceases to exist, and which, if it does remain, is lifted by the eruption beyond the source of nutrient supply and cannot thereafter exercise any influence over the physical condition of the enamel. The many varieties of calcified tissues are due to the variations in the form and nature of the matrices and the conditions and positions in which the lime salts are laid down. They are not dependent upon any variation or special *vital* function exerted upon the crystallizing products, but are due to the form of crystallization and the special salts of calcium which enter into their formation. I do not think that the theory advanced that secondary changes do occur in enamel by recrystallization can be demonstrated.

Development of the Teeth.

It is with the feeling that no easy task lies before me that I enter upon this section. Frey has well said that tooth-development is the most difficult subject that embryologists are called upon to demonstrate. The study of developing hair and glands is comparatively simple, and calcified products alone do not seem intricate; but when we approach the consideration of both these conditions in one structure, we seem to stand before an unfathomable mystery. It is only as we approach the problem from the standpoint of general histology that we get anything like a full and true interpretation of the phenomena of tooth-development. A microscopic examination of the intimate tissue concerned in tooth-development led to the discovery that the teeth are developed in the mucous membrane; that, instead of standing in close relation to the bony skeleton of the body, they are a part of its outer, or dermal, system; that they are developed in a similar manner to hair, nails, glands, etc., by a process of involution. Besides conducting us to new truths concerning the nature and constitution of the teeth, the microscope has shown us how to apply this knowledge in a better system of hygienic rules which aim at rendering their decay less rapid, their life more vigorous, and their loss less frequent.

All who wish successfully to prosecute pathological inquiries regarding decay of the teeth will do well to acquaint themselves not only with the histological character of the teeth of the human subject, but with that of some of the lower animals.

I have compared tooth-development in the human with that found in embryo pigs, calves, and lambs, and find that the porcine embryo varies very little from the human. Pig embryos are so easily obtained, and in any size desired, that I am confident that they will come to be

almost universally used to demonstrate the subject under consideration. I furnish them to my classes, and allow them to harden and cut them at will.

The very early stages of development have been the ones over which so much misunderstanding has arisen, and these differences of opinion have largely resulted from a study of poor specimens. By obtaining good specimens from porcine embryos these difficulties can be obviated.

The late advance in our knowledge of this subject is due to new technique in methods of staining and section-cutting, especially the introduction of celloidin, by means of which we have been able to obtain sections of human teeth that had progressed even as far as the eighth month, and teeth of other animals of corresponding age, without disturbing the relationship of the parts.

Before the introduction of celloidin into our technique it was not possible to obtain sections of jaws with teeth *in situ* without more or less mutilation, especially if calcification had proceeded to any considerable extent; by its aid I have been able to preserve a serial line of slides without break or tear in the sections employed. And, further, the illustrations made by the new process of photolithographing have enabled me to eliminate the much-tabooed "personal equation" which accompanies wood-cuts. Whatever may be said against photomicrography in its delineation of cell-structure, surely no exception can be taken to it as a delineator of the outlines of organs or structures like the developing tooth. It gives an accurate picture, upon whose exact amplification we can rely.

I have taken my illustrations from serial lines of porcine embryos, referring to the corresponding ages in the human fœtus as I proceed, believing that it is better to describe those specimens which are best preserved and of which I have been able to make good photomicrographs than to use human fœtuses less perfectly preserved.

The Embryonal Mucous Membrane of the Mouth.

There exists a great lack of agreement among writers on dental embryology regarding terms and descriptions of the mucous membrane of the mouth during the evolution of the teeth. It must be remembered at the outset that the membrane itself is in a formative state and presents different aspects in the several stages. The most marked changes are seen in the epithelial layer. This is analogous and continuous with the skin covering the body, as I have taken occasion to show in presenting the development of the oral cavity. There is, however, one point of difference between the two, due to the widely different conditions in which they are located. The external covering of the body is constantly subject to the drying action of the atmosphere, which produces the corneous layer. The sweat-glands, to a greater or less extent, keep the skin moist, but not sufficiently so to prevent desiccation. The oral mucous membrane is at all times bathed by the saliva, which prevents it from assuming the corneous appearance seen in the outer covering of the body. The same may be said of the rectum and vagina: were the conditions of the mem-

branes the same as those of the skin, we would find an analogous condition in the oldest layer of cells. As proof of the latter statement I cite the following case, to which my attention was called some time ago—a chronic case of procidentia of over two years' standing;

		Embryonal Mucous Membrane.	Mature Mucous Membrane.	Skin.	
Mucous membrane.	Epidermis.		Oldest layer.	Corneous layer.	Rete Malpighii.
		Older layer.	Older layer.	Older layer.	
		Infant layer.	Infant layer.	Infant layer.	
		Basement-membrane.			
	Dermis.	Embryonal connective tissue.	Papillary layer of membrana mucosæ.	Papillary layer of dermis.	
			Sub-mucosæ.	Subdermis.	

The above diagram shows a comparison between the developing mucous membrane, mature mucous membrane, and skin. Between the epidermis and dermis lies the division-line commonly called the "*basement-membrane.*"

the mucous membrane of the vagina was turned completely inside out, and for that length of time had been exposed to the external atmosphere. The most careful examination, except for the absence of hairs, could not elicit any difference between that which was formerly the lining

FIG. 340.

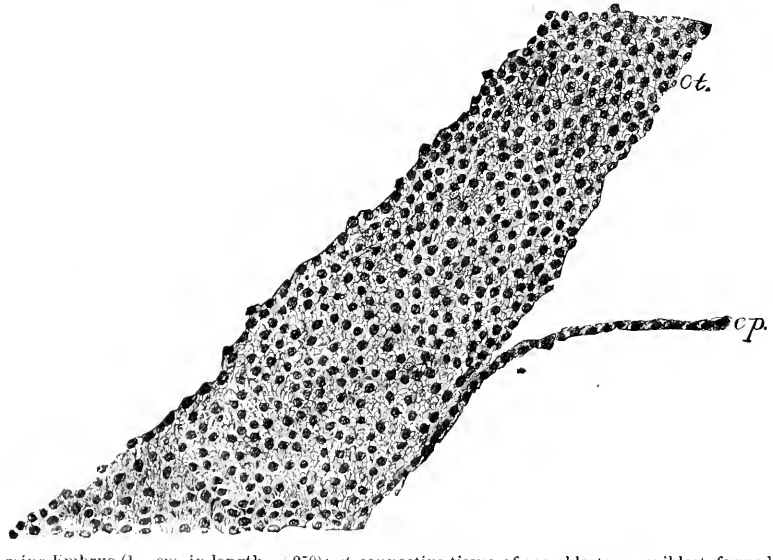

Porcine Embryo (1— cm. in length, · 250): *ct*, connective tissue of mesoblast; *ep*, epiblast, formed of one layer of cells.

membrane of the vagina and the skin covering any other portion of the body. Here we have a positive demonstration that the difference between the mucous membrane of the vagina and the skin is one of environment, and not a physiological difference, and does not necessitate a different classification. If the terms which appeared first in

Dean's translation of Legro's and Magitot's *Dental Follicle*—viz. *infant*, *older*, and *oldest* layers—come to be adopted, it will very considerably simplify our terminology and materially assist the student to a comprehension of the subject. The table on p. 612 will help to disabuse these terms of their intricacies, and to show a comparison between the developing mucous membrane as seen at the commencement of the formation of the band, the mature mucous membrane, and the skin.

The developing mucous membrane, as shown by the following serial studies from photomicrographs, will exhibit very plainly the changes which it undergoes. The first one (Fig. 340), taken from a porcine embryo 1—cm. in length, shows the epithelial layer to consist of a single layer of cells. Considerable space is seen between the cells, which consist simply of nuclei lying in a bed of protoplasm; they are oval, with their longest axis placed longitudinally and parallel with the basement-membrane.

The next one in the series (pig $1\frac{1}{2}$ cm.) indicates that rapid cell-multiplication is proceeding. The mucous membrane has thickened, and is now formed of several layers of spheroidal cells—not arranged in strata, but presenting an irregular adjustment, in some instances several cells deep. These cells have not differentiated any cell-body or wall, but, like those before seen, are still located in a bed of protoplasm. This constitutes the *infant*, or deepest, layer of the rete Malpighii.

FIG. 341.

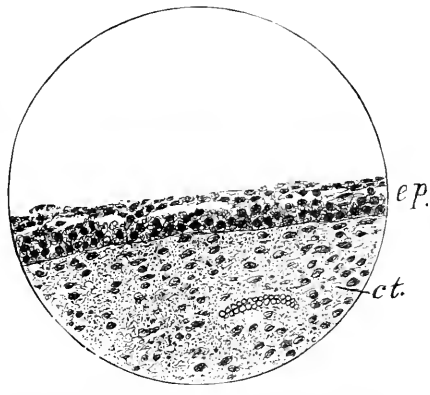

Porcine Embryo ($1\frac{1}{2}$ cm. × 250): *ep*, epithelium, infant layer; *ct*, embryonal connective tissue with large intercellular interspaces.

In the next specimen (porcine embryo $2\frac{1}{2}$ cm. in length) in the region of the band the epithelial layer is perceptibly thickened, and in such a manner as to depress the underlying tissue and fill the groove thus made. This figure is presented here to show that at the very inception of the formative process there is no appearance of columnar cells in the deepest layer of the rete Malpighii, as has been so extensively stated by other authors. The character of the cells of the *infant* layer has not changed; there has simply been an aggregation of nuclei along the line of the forming band, which is the result of such accumulation.

In the next of our series (pig 3 cm.) a noticeable change is seen: cell-multiplication is rapidly progressing and the mucous membrane is considerably thickened. The *infant* layer is as well marked as before; the cells are of a similar character, nuclei lying in a bed of protoplasm, perhaps a little more closely packed, thus giving the infant layer a darker appearance. This is now made more noticeable by the fact that above the *infant* layer a second layer of cells is seen, forming an *older* layer,

the cells of which, in being pushed up from the infant layer, have carried a certain amount of protoplasm with them, surrounding each cell. A marked difference is seen between this protoplasm, which surrounds the nuclei of the older layer, and that surrounding the nuclei of the infant layer. In the latter case, with hæmotoxylon and eosin, it stains very readily and darkly, while in the former it appears as an unstained mass surrounding the nucleus. The nucleus is the *germinal matter*, while the unstained mass surrounding it is the *formed material* (Beale). The nucleus and the formed material constitute what is commonly known as a *cell*.

These cells are surrounded by a certain quantity of protoplasm, which stains darkly, as does the intercellular protoplasm in the infant layer, and forms the lines which appear in the *older* layer in Fig. 343. The quantity of intercellular material decreases as we proceed toward the

FIG. 342.

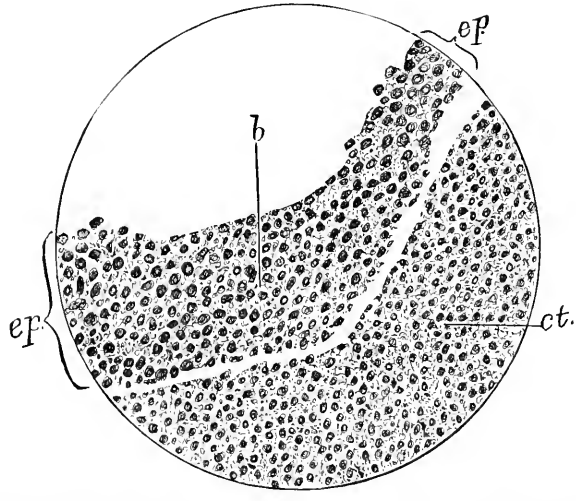

Porcine Embryo (2½ cm. × 250): *b*, region of band; *ep*, epithelium, infant layer; *ct*, embryonal connective tissue. The space between the two layers was produced by tearing the specimen intentionally.

surface, and the quantity of formed material increases; so that the cells grow larger. This surrounding formed material of the cell-body is, in all probability, the undigested or unassimilated protoplasm from which the *germinal* matter, or nucleus, draws its nourishment.

As we proceed in our examination of older embryos we find the cells losing their well-defined outlines, until they assume the appearance seen in Fig. 272, taken from a scraping of the tongue in an adult human mouth. They constitute the *oldest* layer, are farthest removed from the source of nutrition, and correspond to the corneous layer of the skin.

For a description of the epithelium of the skin I cannot do better than make several quotations:

"The epithelium constitutes the superficial layer of the skin. In the adult tissue the epithelium is composed of two layers of cells—a

younger, which lies at the deepest portion, and an older, at the surface —the 'outer or horny layer, consisting of very thin, transparent, tough, scale-like cells, which present, for the most part, no nuclei and are packed closely together; and the inner layer, the so-called mucous or Malpighian layer, consisting of larger and smaller nucleated cells of varying shape and character. In the deeper portion, adjoining the corium, the cells are more or less cylindrical; above this they are spheroidal or polyhedral or elongated; still nearer the surface they become flattened, and finally merge into the thin cells of the horny layer. In the middle zone the cells present a peculiar jagged outline, looking as if they were bordered by short, delicate spines, by which the cells appear dovetailed together. These spined cells—called prickle cells—are very characteristic of this part of the epidermis, and are also found

FIG. 343.

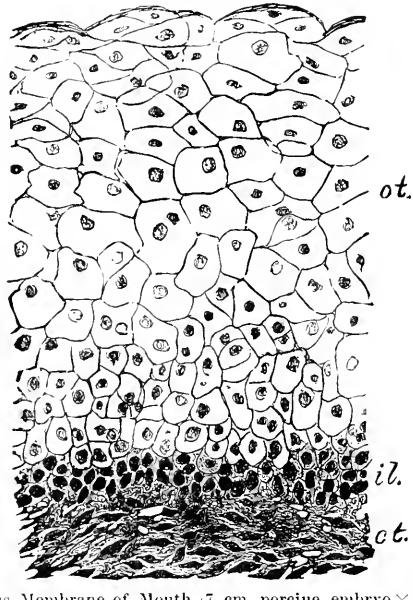

Vertical Section Mucous Membrane of Mouth (7 cm. porcine embryo × 250): *ol*, older layer of cells; *il*, infant layer of cells; *ct*, connective tissue of mesoblast.

in certain other parts of the body where stratified epithelium occurs, as in the vagina, mucous membrane of the mouth, etc.'" (Prudden).

Then again:

"The mucous membrane [of the mouth] and the skin are anatomically analogous and continuous structures. The first clothes the internal and the other the external surface, and the description of the one will, with slight modifications, apply to the other. In a general sense, they are composed of two strata, or layers—the dermis and the epidermis; yet, for convenience of description rather than for any other reason, they have been variously subdivided. The external stratum, the epidermis, composed entirely of epithelial cells, has been described as consisting of two layers, the external being termed the corneous and the

internal the Malpighian. The 'scarf-skin' raised on the external surface of the skin by a blister and the pellicle detached from the palate by hot drinks represent the corneous layer of the epidermis. By some authors this is called the 'true epidermis,' and by some the 'cuticle.' This layer is composed of the old epithelial cells which have ceased to perform any of the vital functions. The subjacent layer, formed of living epithelial cells which vary in form and size, is denominated (among many terms) the 'stratum Malpighii'" (Dean's *Dental Follicle*).

These descriptions apply to adult tissues. Let us turn now to the consideration of embryonal tissues, for it is with the latter that we have to deal in the study of the development of the teeth.

Dental Ridge.

I will first consider a section from the jaw of a porcine embryo $1\frac{1}{2}$ cm. (Fig. 341) in length; this compares in age with a human fœtus of four weeks. In the epiblastic layer which covers the gums is seen the first indication of that cellular activity which later will result in the evolution of the teeth. By comparing the epithelial covering of the gums we shall see that it is composed of two or more layers of oval cells which present evidences of active cell-multiplication, while the same membrane upon the outer portion of the body is yet composed of only one layer of cells. The thickening of the epithelial covering of the gums is at first general, and results in the formation of a thick layer. The next change is not so much evidenced upon the surface as it is in vertical sections of the jaws. The same cellular activity which resulted in a general thickening of the epithelial covering of the gums now becomes centred along a line which marks the crest of the gums and locates the line to be occupied by the future arch of teeth. The multiplication of cells is found to be in the *infant* layer of the rete Malpighii, or that layer which lies nearest the supply of cell-pabulum that is furnished by the vessels located in the subepithelial tissue. No vascular supply has ever been demonstrated in the epithelia proper.

Rapid cell-multiplication along the line just described results in a thickening of the *older* layer of cells, giving rise to a slight ridge higher in some embryos than in others. This ridge has been designated by Kölliker, Waldeyer, and Kallman as the *Kieferwall*, or *maxillary rampart*.

Concomitant with the formation of the ridge, the proliferation of the cells of the infant layer causes a depression of the subepithelial layer lying immediately underneath. Were we to lift up this thickened epithelial layer, it would leave behind a groove in the underlying tissue; but let it be remembered that in lifting the ridge or rampart of epithelial cells we have made the groove. It is never a ditch or groove *per se*, but, when found, is always an artificial product which can be made at will. As cell-multiplication advances this groove deepens, taking a direction toward the centre of the arch.

To this groove filled with epithelial cells[1] "Legro and Magitot have

[1] Dean's translation, Legro and Magitot.

given the name *bourrelet*, which means a rounded pad or cushion. This structure was for a long time supposed to be cartilaginous in its nature, and hence called *cartilago dentalis*, until Raschkow discovered its epithelial character. M. Guillot (1859) named it the *odontogenic part*, or the generating part, of the teeth."

The term band, which has been so universally adopted, while not expressing the exact nature of the thickened layer of cells, yet when modified by the adjective *epithelial* as nearly expresses the principal characteristics as any other; and for lack of a better term we will use it hereafter.

From the condition seen in a vertical section through the jaw of a $2\frac{1}{2}$ cm. porcine embryo, which compares with the human at from the forty-fifth to the sixtieth day, as seen in the accompanying photomicrograph (Fig. 344), the epithelial band rapidly deepens by cell-proliferation at the deepest point. The centre of the lower jaw is occupied by Meckel's cartilage, and the axis of the band assumes a direction which would cause it to pass between the cartilage and the inner side of the jaw. Were such lines continued in the same direction from several points of the band, they would converge to a given centre.

FIG. 344.

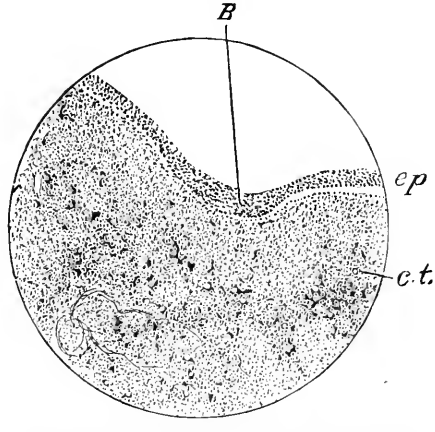

Porcine Embryo ($2\frac{1}{4}$ cm. × 60), inferior maxilla: *B*, first stage in the formation of band; *ep*, epithelium; *ct*, embryonal connective tissue.

In vertical transverse sections the band assumes a ploughshare shape with the mouldboard side directed toward the inner side of the jaw. This is shown very nicely in Fig. 345, taken from a porcine embryo $2\frac{1}{2}$ cm. in length, which compares with a human fœtus of two and one-half months. The convex surface of the band is toward the outer side of the jaw. This peculiar curve is almost universally seen, and constitutes one of the most characteristic and persistent features of the band. The walls of the band are composed of the *infant* layer of cells, while its centre is filled with the *older* cells, which have been pushed off from the sides as new cells have been developed in the infant layer. Note the fact—so plainly shown—that the deepest layer of the rete Malpighii (infant layer) is not composed of columnar cells, but of oval nuclei surrounded by a mass of protoplasm, which does not as yet present any indication of separating into cell-body for each individual cell. When the nuclei are pushed up from this bed of protoplasm, a certain amount of it accumulates around each nucleus and becomes the cell-body, on the surface of which a cell-membrane soon becomes visible. We have then a ditch or groove in the subepithelial tissue filled to overflowing with epithelial cells which by reason of their growth have formed the groove in which they lie.

The band as seen in its inception is broad (Fig. 344), but as development progresses and it sinks deeper into the jaw it becomes narrower, as seen in Fig. 345. The band is deepest at the anterior portion of the

FIG. 345.

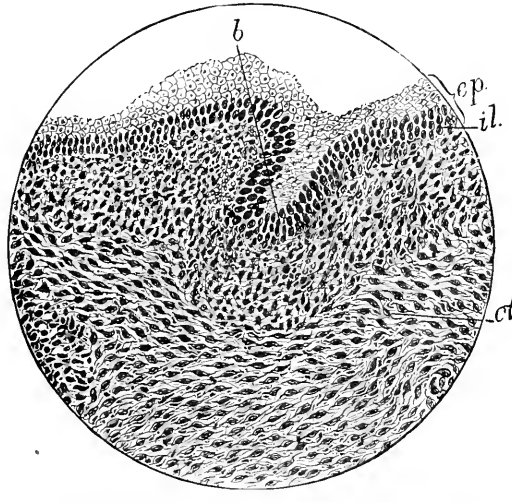

Vertical Section Band Porcine Embryo (2½ cm. × 250): *ep*, epithelium with infant layer (*il*); *b*, band; *ct*, connective tissue.

jaw, gradually growing shallower until it flattens out into the epithelial covering of the gums. The sections here shown are taken from the region of the premolars in the pig—first or second molars in the human embryo. The band in the region of the incisors is considerably deeper than at the point where the section from which this figure was made was cut. Posteriorly it grows shallower, until it finally disappears.

Cellular activity increases rather than diminishes as age advances; this activity evinces itself in that part of the band which is located deepest in the tissues. The rapid multiplication of cells at this point causes the deepest edge of the band to become expanded, and as this band sinks farther into the substance of the jaw this expanded portion becomes indented its entire length through the resistance offered by the underlying tissues. Thus a sheet, or *lamina*, is given off from the inner side of the band.

There are two ways of demonstrating the formation of the lamina—one by vertical transverse sections of the jaw, when at this age every section cut will show the band as a W-shaped infolding of the infant layer; whereas the previous figure (345), representing an earlier stage in development, will show it to be V-shaped. Imagine a V-shaped process by reason of multiplication of its contents becoming U-shaped, and afterward, by indentation of the base of the process, becoming W-shaped, and you have a fair illustration of the change which the infolding epithelium assumes. (See Fig. 346, showing the W-shaped band; *b* represents the outer base of the W, and is situated on the outer side of the jaw and corresponds to the original V-shaped band-process;

l is located on the inner side of the jaw, and is the internal sheet or lamina which has arisen from *b*, as if a second V had been added to the side of the first, thus forming the W-shaped process. These two processes are termed the band and lamina. The latter is only a process of the former.)

If we cut longitudinal transverse sections of both sides of the inferior maxilla, we first obtain sections of the mucous membrane; later we get sections horseshoe-shaped in form, the outer and inner edges of which will show a layer of epithelium, the bulk of the section being made up of embryonal connective tisue. Located equidistant from either side we will see a *band* of epithelial cells which extends entirely around the arch of the horseshoe-shaped section. Now, if such a sec-

FIG. 346.

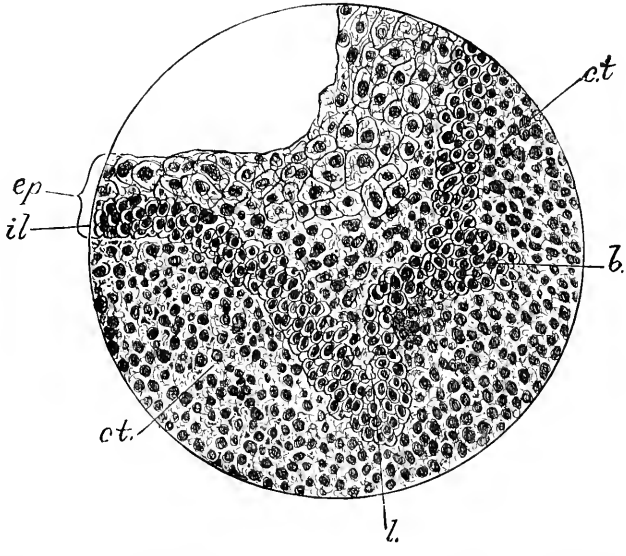

Porcine Embryo (3 cm. × 250): *ep*, epithelium with infant layer at *il*; *ct*, connective tissue; *b*, band; *l*, lamina.

tion be made of the jaw of a 3 cm. pig, we will find that for a certain distance from the surface our sections will appear as above described; but as soon as we reach the deepest part of the ingrowing epithelial processes we will find two (2) bands of epithelial cells instead of one, thus showing that we have cut across the W-shaped processes known as the *band* and *lamina*. Between the two bands the space is occupied by embryonal connective tissue similar to that formed upon either side of the bands, and forming the boundary of the section. We will find, as before, on both outer and inner side, epithelium. (See Fig. 347, representing a section from one-half of such a horseshoe-shaped section.)

As we have seen, cellular activity is evidenced in the deepest portion of the ingrowing processes. The lamina forms no exception. While cell-proliferation apparently seems to come to a stand in the band, rapid

cell-multiplication still proceeds in the lamina, which extends deeper into the substance of the jaw.

Fig. 347.

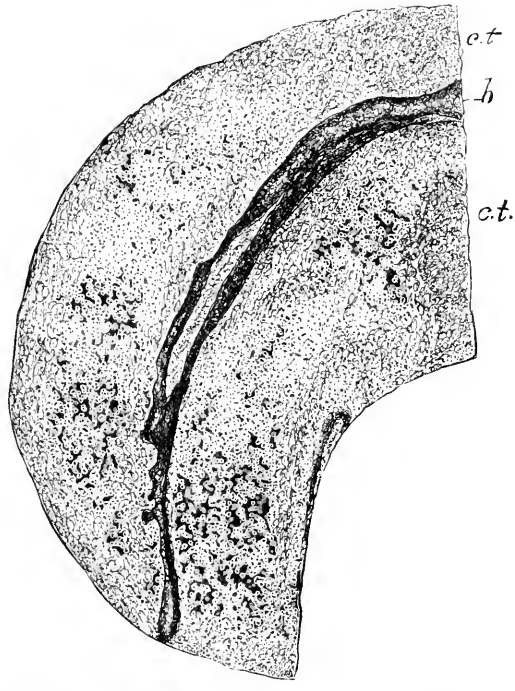

Longitudinal Transverse Section Inferior Maxilla (3 cm. porcine embryo × 40): *b*, band, solid at anterior portion, but divided posteriorly into band and lamina.

As this change is being accomplished the band becomes somewhat shallower and in some instances disappears, the more rapid growth of the lamina apparently causing the straightening of the outer base of the W, known as the band proper. When we consider that the lamina is only an offshoot from the side of the band, it is very easy to understand how the transferrence of development from one side of the band to the other would give rise to the disappearance of the original process.

Development so far has been general in character. The band and lamina have a common office, and that is to give origin and direction to the cords for the temporary teeth. Individualization now begins. The internal development of cells continues with unabated energy, expressing itself, not in the extension of the sheet, or lamina, but at regular intervals which correspond to the positions to be occupied by the temporary teeth. Here small buds make their appearance, and soon extend into slender *cords*, each *cord* developing in time into the enamel organ of a temporary tooth (Fig. 348).

The length of the cord varies in different mammals, those in human and porcine embryos being quite short, while in the fœtal calf and lamb it attains considerable length. The cords for the permanent teeth are of necessity longer than those for the temporary set,

having to descend beyond and beneath the latter. The *cord* is composed of a solid ingrowth of the cells which constitute the lamina from

FIG. 348.

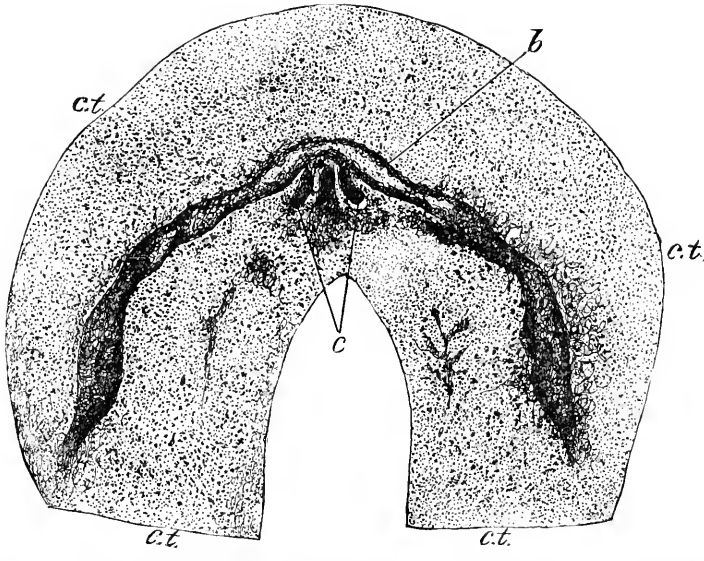

Longitudinal Transverse Section of both sides of the Inferior Maxilla (3 cm. porcine embryo × 25): *b*, band; *c*, cords for temporary central incisors; *ct*, connective tissue, surrounded on its outer circumference by a thick epiblastic layer.

which the cords arise. The lamina, as we have seen, arose from the band, and this in turn from the oral epithelium. The deepest layer of the latter, the infant layer, constitutes the outer layer of the cord. It is composed of oval or spherical cells similar to those described in studying the development of hair and glands. These cells have been very extensively spoken of as columnar. They sometimes assume a cylindrical shape when the layer is only one cell deep; but if more than one layer exist, then they are universally oval or spherical. The formation of the cord is very nicely shown in Fig. 349.

FIG. 349.

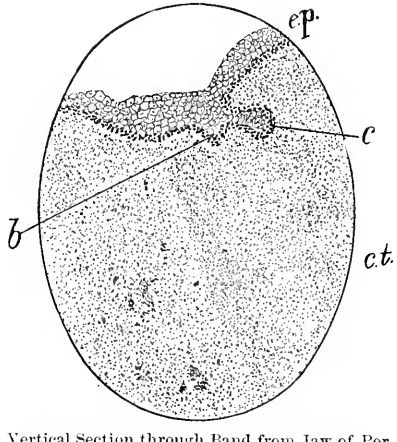

Vertical Section through Band from Jaw of Porcine Embryo (3¼ cm. × 60): *ep*, epithelium; *b*, band; *c*, cord; *ct*, connective tissue.

The cells seen at *c* are the older cells which have been pushed off from the infant layer (*d*), which forms the outer tunic of the *cord*. The cords at first stood at right angles to the inner side of the band, having an axis similar to the direction of the plane of the lamina of which

they are an extension. They radiate to a common centre, and lines drawn through their several axes would intersect each other in the centre of

FIG. 350.

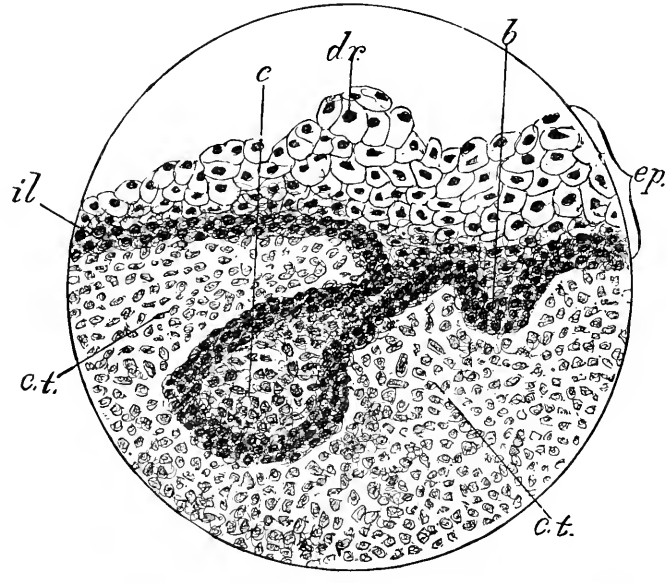

Same as 349, only more highly magnified: *b*, band; *c*, cord; *dr*, dental ridge; *ep*, epithelium: *ct*, connective tissue.

base of the tongue, and are the lines referred to when speaking of the direction assumed by the plane of the band in the first instance.

The cord soon turns sharply upon itself and dips more or less deeply downward into the substance of the jaw. Internal proliferation of cells results in the formation of a bulbous extremity, which I have designated the *bulbous cord*. With these changes the cord is seen to be becoming more deeply embedded in the substance of the jaw and curves in more and more toward the plane of the band, thus assuming a sickle shape. (See Fig. 351.) The cord now very much resembles a Mattson syringe with a short nozzle. The neck of the cord, which forms the connecting-link between the bulbous part and the band, does not keep pace with the deepest extremity in growth, assuming more and more the character of a neck, and is very rightly named the neck of the enamel organ.

A horizontal transverse section made of the jaw at this stage of development will show a vertical transverse section of the cord lying beside a longitudinal section of the band.

Studying sections from the jaw of a $3\frac{1}{2}$ cm. pig, we notice that the cord has become pear-shaped, and the section presents the appearance of a stirrup. The flattening at the deepest portion is caused by contact with a new element—viz. the *dentinal papilla*, which now presents a new feature for our consideration.

The papilla which will constitute the future pulp of the tooth is, as

FIG. 351.

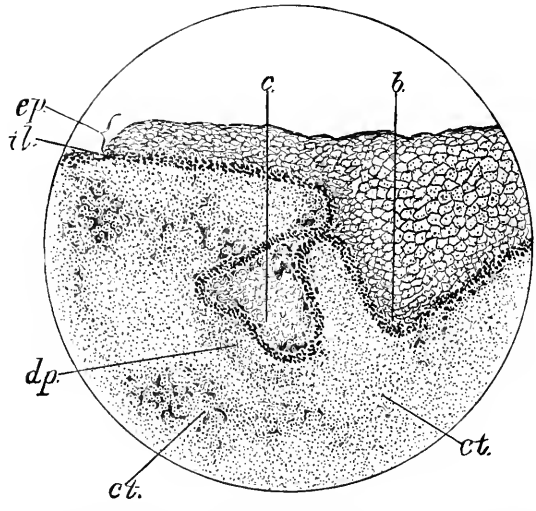

Vertical Section through Band and Cord of 3½ cm. Porcine Embryo × 60: *ep*, epithelium with infant layer (*il*); *b*, band; *c*, pear-shaped cord; *dp*, dental papilla; *ct*, connective tissue. In this cut the walls of the cord are shown very plainly to be a continuation of the infant layer of the epithelium.

FIG. 352.

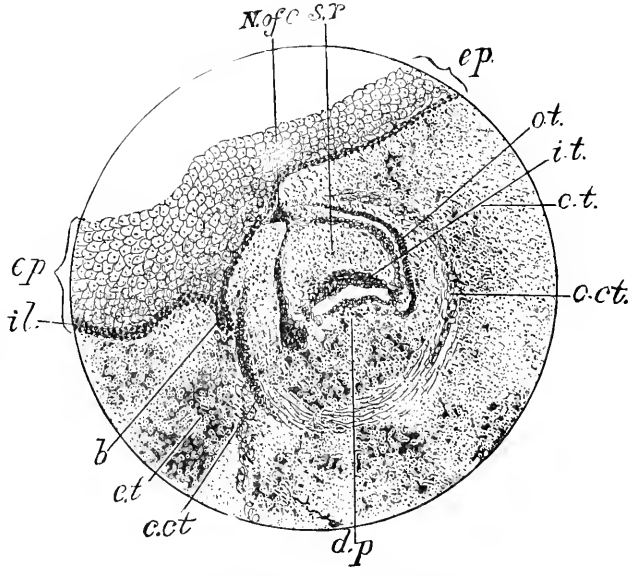

Vertical Transverse Section through Jaw of Porcine Embryo (5½ cm. × 60): *N. of c.*, neck of cord for enamel organ; *ep*, epithelium; *il*, infant layer; *b*, band; *ot*, outer tunic; *it*, inner tunic; *ct*, connective tissue; *dp*, dental papilla; *c. ct.*, condensed connective tissue forming follicular wall and continuous with the periosteum.

we have before said, developed from the subepithelial connective tissue of the jaw. Its growth is upward, or *gumward*, while the growth of the cord has been downward into the substance of the jaw. The com-

bination of these two elements into one organ seems to fulfil the same office as does fructification in the egg. New life is at once infused into the tissue, and very rapid and material changes now occur. The process of invagination sets in, by which the two tunics are formed.

A ready illustration of the process of invagination of the bulbous cord is made by taking in one hand a syringe with an egg-shaped bulb, the tube being attached to the small end. Hold the tube between the first and second fingers, the bulb lying in the hand; with the end of the thumb of the same hand press the large end of the bulb until it comes in contact with the small end. By this process the larger end of the bulb is invaginated in the upper, and that is what is meant when we speak of the invaginated cord. The cord invaginates itself in a manner similar to intestinal invagination. In this perfect illustration of the manner in which the two tunics are formed, your thumb represents the dentinal papilla filling the concave space in the enamel organ, and the tube represents the neck of the cord which still connects the enamel organ to the epithelial layer of the mouth.

FIG. 353.

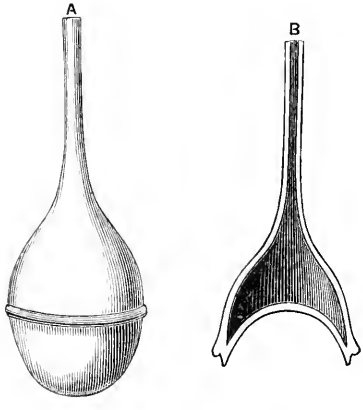

Similar invaginative processes occur in the formation of the hair-bulb and the glomeruli of the kidney.

As invagination progresses the older layer of cells, which occupy the interspace between the walls of the invaginating canal, are seen to be undergoing a marked change. The account given by Legro and Magitot is so complete, and so conforms to my views upon the subject, that I cannot do better than incorporate it into my manuscript. They say:

"If we now examine the composition of the enamel organ [at the period of development represented in Fig. 354], say about the fifteenth week of the human embryo, we find that the primitive elements (polygonal cells, which occupy its central portion, and the [prismatic?] cortical layer) have undergone notable modifications. We discover, in fact, that the middle region of this organ is occupied by some elements of a *new form* essentially differing in appearance from that of the original cells. *These are stellate bodies*, composed of a central nucleus surrounded by a transparent or finely-granulated mass, which ramifies and inosculates with the neighboring elements. These star-shaped bodies occupy at first only the centre of the enamel organ, those near the periphery preserving their original polygonal form, but becoming stellate in proportion as the dimensions of the organ increase. It will be noticed, however, that the anastomosing processes are always much longer and more ramified as the cells are situated nearer to the central portion, while in the vicinity of the periphery it is somewhat difficult to distinguish these processes, as they are here only rudimentary. The

elements thus described are immersed in a translucid amorphous mass coagulable in acids and having the consistence and appearance of the white of an egg. These starred bodies—or stellate cells, as they are usually termed—are formed directly at the expense of the polygonal elements composing the internal mass of the enamel organ. The process is as follows: The substance mentioned above interposes itself little by little between these originally small polyhedral cells, and thus their walls lose their mutual contact except at certain points where they still cohere. As a direct result of this phenomenon the primitive polygonal cells exhibit a number of depressions extending from their exterior surface toward the centre, giving them their stellate appearance. From this transformation the primitive cells would become entirely insulated by the intervention of this new mucous formation were it not for these connecting processes, which give to this organ, as a whole, its peculiar reticulated appearance and to each cell its stellate form. It is a remarkable fact that no line of juncture can be discovered where these cells are connected with each other, the various reagents failing to disclose the least trace of it, so effectually have these parts been cemented together. According to this theory, the stellate arrangement of the 'pulp' of the enamel organ (the intimate composition of which we do not propose to describe in this memoir) results from a *simple modification of the form* of the primitive polygonal cells—a change which they have undergone passively, as it were. These elements of the enamel organ, notwithstanding their stellate form, must be regarded, therefore, as *absolutely epithelial* in their nature. The mechanism of this transformation, however, differs materially from that given by Kölliker, and after him by several other anatomists, who contend that these primitive cells might take this stellate form spontaneously. Our opinion, however, is in conformity with that of Waldeyer, who was the first to properly examine and describe this phenomenon, though Huxley at a much earlier day had advanced the idea (hypothetically, it is true) that the enamel organ had an epithelial origin; but he did not indicate the mode whereby the transformation of its elements was affected."

The *stratum intermedium of Hanover* consists of those cells which lie nearest the infant layer of the inner tunic. They have not become stellate, as have the cells found nearer the central portion of the enamel organ. They are younger than are the stellate cells. They have no particular signification other than that which we assigned to them when discussing the formation of the cuticula dentis. Nearer the central portion of the enamel organ a more marked reticulation is seen in most specimens.

The vacuoled appearance of the interior of the enamel organs begins in the central portion in the oldest layer of cells; the cells which lie nearest the infant layer are the last to become affected. The change does not occur uniformly, but in places here and there. This is shown very nicely in the accompanying figure (354). The part from which the cut was taken comprises that portion, including the inner tunic and the overlying cells, situated immediately above the apex of the dentinal papilla. The *infant* cells of the inner tunic are of the character before described, no attempt having as yet been made upon the part of Nature

to differentiate the ameloblastic layer. Although these cells occupy the position where the first formation of enamel will make its appearance, the older layer (*ol*), in the central part of the figure, remains unchanged, the process of infiltration having not as yet begun. But on either side of these unaltered cells, at *sr*, *sr*, the stellate cells are very plainly shown. Between the stellate cells larger and smaller spaces occur. This stellate appearance is largely due to post-mortem changes. The actual spaces which occur between the stellate cells are chiefly the result of shrinkage. If an osmic-acid solution (1 per cent.) and alcohol, equal parts, be injected underneath the mucous membrane covering the jaws of an 8 or 10 cm. pig while the embryo is yet warm, and then immersed in a similar solution to harden, the post-mortem changes in the cells will be to a greater or less extent arrested. If we lift the mucous membrane from its bed after the tissue is sufficiently hardened, the enamel organs will adhere and bring up with them their papillæ. The

FIG. 354.

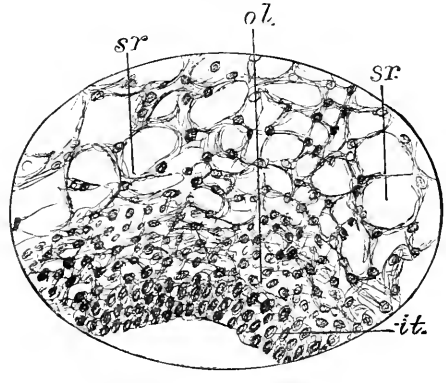

Inner Tunic Enamel Organ Porcine Embryo (6 cm. × 250): *it*, inner tunic; *ol*, older layer; *sr*, *sr*, stellate reticulum.

enamel organ is thus isolated from all surrounding calcified tissue, and we are able, after embedding, to make sections without waiting for the bone of the jaw to be decalcified, decalcification necessitating the use of acids which will cause more or less change in the soft cells in the interior of the enamel organ. The fibrillated condition of the stellate cells seen in specimens hardened in Müller's fluid, chromic acid, etc. is demonstrated, by the osmic-acid method, to be in reality a broad mesh. The reticular appearance seen in the chromic-acid preparations results from post-mortem shrinkage in the older cells which fill the interior of the enamel organ. I fully believe that if we could examine these cells at once, before any shrinkage occurs, we should be able to prove the fact that in life they are not stellate, but large polygonal cells. I am led to this inference by the above-noted experiments, the better methods of technique showing a less fibrillated appearance than do other methods which allow more shrinkage.

Sections of isolated enamel organs might be obtained by the freezing method were it not for their minute size; if this could be done without the use of any hardening fluids, better studies could be made. It is to

be remembered that the cells which occupy the central portion of the enamel organ are the *older* cells which have been pushed off from the sides by the development of the infant layer, which constitutes the walls of the organ. The central mass of cells are thus enclosed in a sac as are the cells of sebaceous glands. The latter, under this condition, pass through a retrograde process and become, through fatty degeneration, the oily material secreted by the glands. The cells of the enamel organ become infiltrated by fluid instead of fat; this fluid is freely soluble in the fluids which are used to harden the tissues. The cells undergo a sort of retrograde process due to the abnormal confinement between the tunics of the enamel organ, but not the same as that found in the glands above referred to. The shrinkage due to the giving up of this water results in the stellate form they assume after death. In the meshes of the stellate cells prepared by the osmic-acid method are seen numerous minute granular bodies which have a high refractive power; if a few drops of dilute nitric acid be put on the slide near the edge of the cover-glass and allowed to run under by capillary attraction, these granular bodies will disappear, and at the same time large numbers of bubbles will accumulate and force themselves out from under the cover-glass. In this experiment we have a positive demonstration of the presence of carbonate of lime in the meshes of the stellate cells of the fully-developed enamel organ previous to the beginning of the process of calcification of the enamel. These granules of lime do not appear in sufficient quantity to result in completely-calcified tissue, but are held in a state of suspension; as the meshes of the stellate reticulum shrink the granules of lime are brought nearer together, and by approximation stiffen the tissue. The presence of a non-shrinkable material in the meshes of the stellate cells of the enamel organ accounts for the different results, as regards shrinkage, in the preparation of tissues.

Previous to the beginning of development of the enamel we find little or no shrinkage of the enamel organ during the hardening and decalcifying processes, provided the hardening is accomplished first. It is only after the stellate cells have given up a portion of their lime salts, either by forming enamel or by being decalcified before hardening, that any considerable shrinkage occurs. The shrinkage in the first instance is localized in that portion nearest the forming enamel; in the latter it is general. The shrinkage on the part of the enamel organ, in any case, is more apparent than real, the space formed by the separation of the enamel from the ameloblasts being largely due to the greater shrinkage of the dental pulp, which draws the formed dentine and enamel down from the sides of the cone-shaped enamel organ. If the stellate reticulum is, as has been stated, very rich in albumen, and does not contain calcific material in large quantities, there would be a very great shrinkage in preparation, due to the rapid taking up of its water by the acids used in decalcifying, which is not the case previous to the commencement of the formation of the enamel. But after calcification has begun and the stellate reticulum has given up a portion of its lime salts, then more or less shrinkage is noticed; or if decalcification is first accomplished by hydrochloric acid, which has no hardening property, and the tissue is afterward hardened in alcohol, we notice the same phenomenon,

which is due to the same cause—viz. the giving up of its lime salts previous to the coagulation of the albumen in the substance of the tissue. Thus, I see in the stellate reticulum an essential agent in the process of the formation of the enamel, and not a mere occupier of the space to be taken by the formed enamel, as some would have us believe.

It is more. In the first place, it is the storehouse, so to speak, of the calcific material from which the first-formed layer of enamel is derived. Then, again, there is a very great difference in form between the enamel organs of the centrals, cuspids, and molars in the same mouth; and that this difference exists among the several classes of teeth, none will dispute. From this I hold that the enamel organ is the matrix-former: as the fœtal femur is to the mature femur, so is the enamel organ to the fully-developed tooth. They are the matrices that govern the form of the fully-developed tissue—at least, in a general way in each can be seen the type of the resulting product. The concave face of the enamel organ gives form to the future tooth in the Carnivora by the dentine forming against the inner ends of the ameloblasts. Sometimes the fibrils of the odontoblasts penetrate between the ameloblasts, and we have as a result an interlacing of the dentinal fibrils and the enamel-prisms. This interlacing of the fibrils of the odontoblasts with the ameloblasts militates against the theory of a limiting membrane existing between them. That this occurs before the process of calcification begins I have no doubt, although I have not been able to demonstrate it. The forcing of the soft fibrils of the odontoblasts between the calcified enamel-prisms is impossible. I have a pathological section from a human incisor, taken from the superior maxilla of a man who when he was four years of age was kicked in the mouth by a horse and seriously injured. When his permanent incisors erupted, they had furrows on their labial and lingual faces, showing faulty development; into these furrows horns of dentine projected fully one-half the thickness of the enamel. The fissure in the enamel probably resulted from a displacement of the ameloblasts at the time of the accident. Into the fissure thus formed the fibrils of the odontoblasts projected, thus showing the tendency of the odontoblasts to send out their fibrils until they meet an obstruction. In normal development this obstruction is formed by the inner layer of the enamel organ.

Much discussion has arisen regarding the nature of the union occurring between the papilla and the enamel organ; there exists no intimate connection between the two surfaces other than that of perfect adaptation to each other. Vessels or nerves have never been demonstrated to pass from one to the other. The relation is analogous to that sustained by the epithelium and dermal layers of the mucous membrane of the oral cavity, from which they have their origin. As there is no direct union between the two organs, enamel and dentine, so is there no such union between their products. The enamel cap can be very easily lifted from off the dentine cone, especially from an extracted tooth which has been allowed to dry. The enamel and dentine separate very readily at their line of union in teeth *in situ* when it becomes necessary to remove the enamel cap for the application of bands for crowning roots, thus demonstrating the lack of positive union between the two.

Sections from the jaw of a 6 cm. pig show the process of invagination farther advanced. The papilla, which originated as a microscopical point, rapidly increases in size. It is made up of embryonal connective-

FIG. 355.

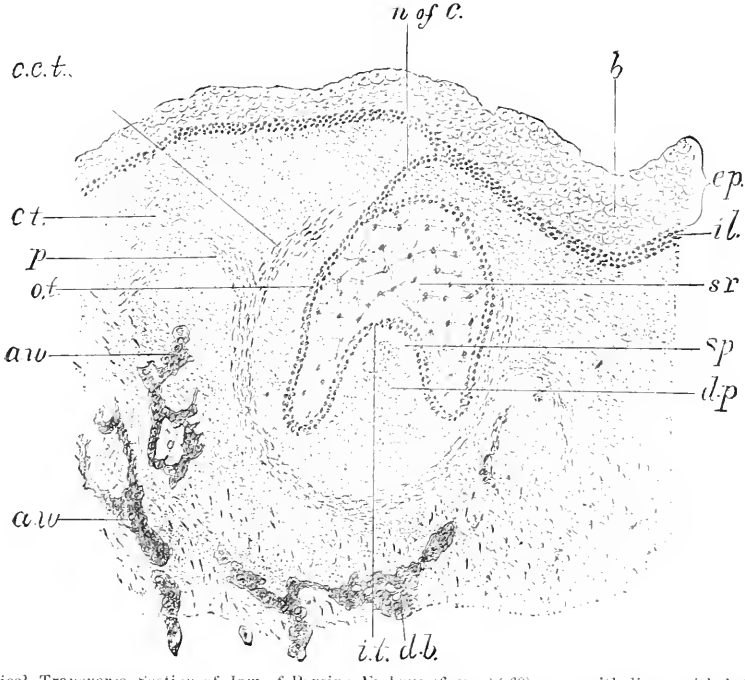

Vertical Transverse Section of Jaw of Porcine Embryo (6 cm. × 60): *ep*, epithelium, with infant layer (*il*); *b*, band; *n of c*, neck of cord; *ct*, connective tissue; *c. ct.*, follicular wall; *p*, periosteum; *alv*, alveolar wall; *ot*, outer tunic; *dp* dental papilla, with (*sp*) space between it and inner tunic (*it*); *db*, developing bone of jaw.

tissue cells similar to those found in other parts of the body. It is richly supplied with capillary vessels, but I have never been able to demonstrate any nerve fibres in the formative stages of the dentinal organ

Many changes are now seen to be occurring in the jaw; here appears the first attempt upon the part of Nature to differentiate a periosteum. The boundary of the jaws is very clearly marked by the condensation of the fibrous connective tissue at *pp* (Fig. 356). Outside of this membranous layer the muscular plates are seen in a formative state, and external to the muscular layer is seen the dermal tissue, covered by the epidermis. Inside the periosteum is seen the forming bone of the jaw (*dlb*, *db*). It is independent of the periosteum and Meckel's cartilage. It is Y-shaped, with the top of the Y toward the mucous membrane of the mouth. In the open, or upper, part of the forming bone the forming enamel organs are located at *eo*, *eo*. The position occupied by Meckel's cartilage is peculiar in the pig, and differs materially from that in the human embryo. This is owing to the different form of the two arches. The human is horseshoe in shape, and

the cartilage occupies the central portion of the arch; the arch in the porcine embryo is V-shaped, the base of the V corresponding to the anterior portion of the mouth. The two sides of the inferior maxilla come in contact at a considerable distance from the front of the mouth and at the point of union of the two sides of the jaw. Meckel's cartilage, which in the posterior portion occupies the central part of the jaw, as it does in the human throughout, is seen to converge toward the inner side of the jaw and locate in apposition with its fellow of the opposite side. At the anterior portion of the jaw this union is complete, but as we proceed posteriorly the sides gradually separate, until, in the region of the molars, they are entirely separated. Where a section is made across both sides of the inferior maxilla this divergence between the two sides of Meckel's cartilage forms an accurate guide to the location

FIG. 356.

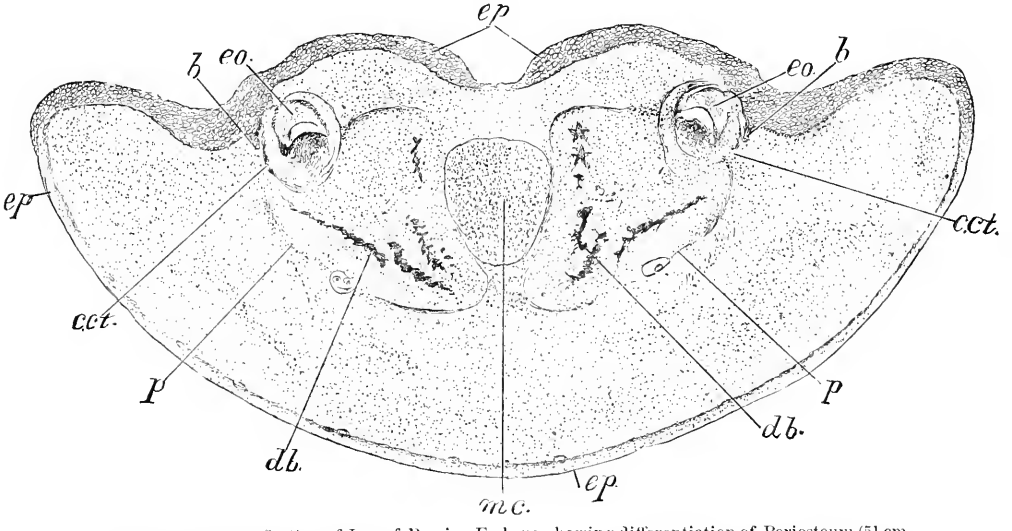

Vertical Transverse Section of Jaw of Porcine Embryo, showing differentiation of Periosteum (5½ cm. × 25): *pp*, periosteum of either jaw; *c. ct.*, follicular wall, appearing as a continuation of the periosteum; *b*, band; *eo*, enamel organs for premolars; *ep*, epithelium; *db*, developing bone; *mc*, Meckel's cartilage.

of the section, whether it is a central, cuspid, premolar, or molar. After the development of the papilla this determination can be made by the form of the papilla, whether it be uni- or multicuspid.

The direction assumed by the papilla is somewhat across the axis of the enamel organ; and if it be a cuspid, the form of the papilla is more conical than that of a central incisor, which is more or less wedge-shaped.

Springing from the base of the papilla is seen, in the section, two processes which are connected with the papilla. These are sections of a circular process which arises all around the base of the papilla, and, extending up and around the outer part of the enamel organ, envelops it as an outer tunic. This connective-tissue envelope does not in reality arise from the base of the pulp, but is formed by a condensation of the fibrous connective tissue in which the enamel organ lies. Its connec-

tion with the papilla is accounted for in that the papilla itself arises from the same connective tissue. This differentiation of the connective-tissue envelope is accomplished contemporaneously with the formation of the periosteum, and is seen at *c. ct.* (Fig. 357).

The exact office of this connective-tissue envelope is not known. I hold that it eventually forms the *pericementum*, and as such becomes the *cement organ*. *pp* marks the periosteum for the jaw; *c. ct.*, the pericementum for the root of the tooth, developed at the same time from the same embryoplastic elements, and later analogous and continuous structures. The products of the two membranes are very similar, cement being only a slightly modified form of cortical bone; which latter, as we have seen, is formed by subperiosteal development, and the former by subpericemental ossification. I consider the effort to differentiate between the two membranes as too fine a distinction to be substantiated. That some slight difference can be found no one doubts, but it arises from the fact that the pericementum lies between two bony walls, while the periosteum has bone only on one side and soft tissues on the other. I consider it a case of adaptation to environment.

Sections from jaw of a 7 cm. pig show the process of condensation of the follicular wall more markedly. The developing germ now has the appearance of being surrounded by an outer envelope, excepting at the upper portion, where it yet remains connected with the mucous membrane by the *neck* of the enamel organ. The stellate arrangement of the internal, or older, cells of the enamel organ is quite well marked. The alveolar wall is well developed and extends far up the sides of the follicle. The body of the bone of the jaw is becoming denser, and the developing enamel organ more nearly fills the temporary alveolus. The position occupied by the dentinal papilla is still markedly on one side of the axis of the enamel organ.

Sections from the jaw of an 8 cm. porcine embryo show the process of invagination almost complete. The concave surface of the cup-shaped enamel organ is filled with the dentinal papilla, or pulp. The development of the alveolar wall has progressed considerably. The size of the follicle has materially augmented. The mucous membrane of the mouth has increased in thickness. The neck of the enamel organ is shortened and evidences of cellular activity are seen in the inner tunic, over the apex of the papilla. The stellate reticulum is well developed all through the central portion of the enamel organ. The sides of the alveolus now come in close contact with the sides of the follicle, the fibrous connective tissue of the follicular wall uniting and blending with the periosteum of the alveolar wall. The cells of the inner tunic are oval, there having as yet been no attempt upon the part of Nature to differentiate ameloblasts. Between this and the next size (10 cm.) this change occurs, but, as their development can be demonstrated upon the sides of the specimen even after the process of amelification has progressed to a considerable extent, we will proceed at once to the study of a section from a 10 cm. porcine embryo which has been injected.

I think this is by far the finest specimen I have prepared; it shows the beginning of the process of calcification at the apex of the papilla.

But before proceeding to discuss that phase of tooth-development let us take into consideration the other changes which the follicle and surroundings have undergone. In the first place, note the very considerable increase in size. The lens with which the photomicrograph from

FIG. 357.

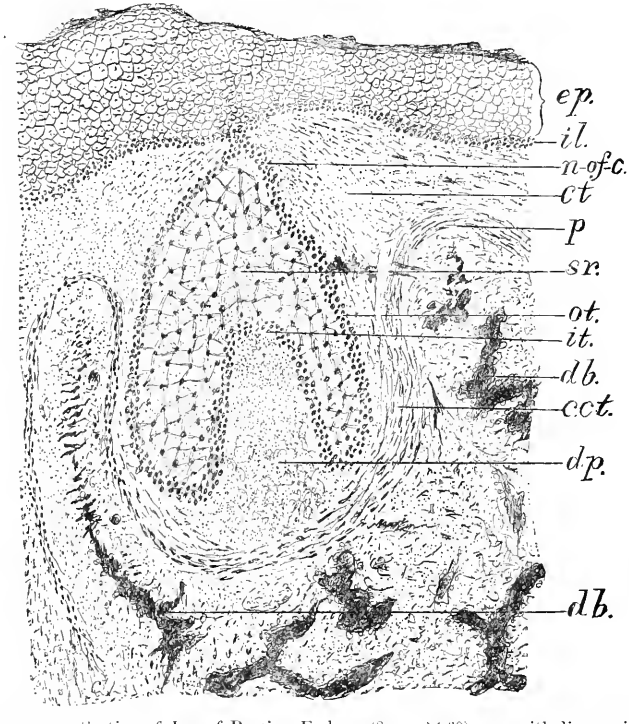

Vertical Transverse Section of Jaw of Porcine Embryo (8 cm. × 60): *ep*, epithelium, with (*il*) infant layer; *n of c*, neck of cord; *ct*, connective tissue; *c. ct.*, follicular wall; *p*, periosteum; *dp*, dental papilla; *ot*, outer tunic; *it*, inner tunic; *sr*, stellate reticulum; *db*, developing bone.

which this illustration was made was the same used for photographing all the others of the series; I purposely used the same amplification for this serial line, so as to show the comparative increase in size as well as the histological changes which occur.

It will be noticed that the alveolar wall has noticeably increased in height, presenting itself a little above the apex of the follicle. This appearance is, however, somewhat deceptive, for we must take into consideration another point, and that is the disappearance of the stellate reticulum over the apex of the developing tooth, which markedly decreases the height of the enamel organ at that point; it also gives the follicle the appearance of having settled deeper into the substance of the jaw. The breaking up of the enamel organ, as such, over the apex of the forming tooth is a constant accompaniment of the beginning of calcification. The enamel organ now presents, in section, the appearance of a pair of saddle-bags hanging over either side of the dental papilla, or pulp. The inner and outer tunics are separated by a

well-developed stellate reticulum. This specimen was well injected, and the vascular supply is nicely shown, both in the pulp and in the follicular wall. At the apex of the tooth the capillaries come in direct contact with the outer ends of the ameloblasts; this is made possible

FIG. 358.

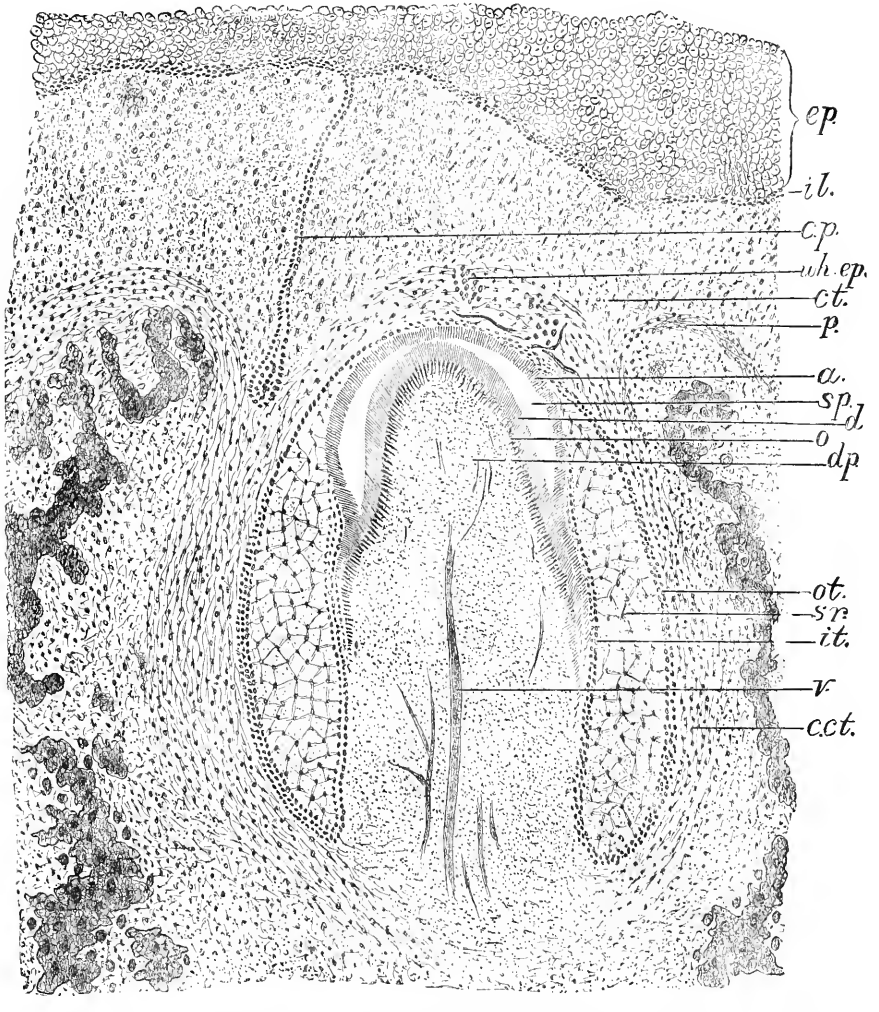

Vertical Transverse Section of Jaw of Porcine Embryo, injected (10 cm. × 60): *ep*, epithelium, with (*il*) infant layer; *a*, layer of ameloblasts; *o*, layer of odontoblasts; *cp*, cord for permanent tooth; *ot*, outer tunic; *it*, inner tunic; *sr*, stellate reticulum; *wh. ep.*, whorls of epithelium formed from outer tunic and stellate reticulum; *d*, dentine; *dp*, dentinal pulp; *v*, blood-vessels of pulp; *ct*, connective tissue; *c. ct.*, follicular wall; *p*, periosteum; *sp*, space.

by the breaking up of the outer tunic and the disappearance of the stellate reticulum. The entire thickness of the mucous membrane is not shown in this figure, the field of the lens not being large enough to include it all. Over the apex of the developing tooth masses of epithe-

lial cells—remnants of the outer tunic and the stellate reticulum—are seen, and are marked *wh. ep.* They have been called whorls of epithelium because of their tendency to gather into nests resembling somewhat the nests seen in epithelioma. The space between the apex of the developing tooth and the overlying epithelium is more or less filled with these whorls of epithelial cells and the buddings which have arisen from the sides of the temporary cord. The space (*sp*) seen between the layer of ameloblasts and the forming tooth-structure is the result of shrinkage, which occurred as a post-mortem change. The intimate relationship between the follicular wall and the periosteum is well exhibited in this figure.

We have now shown the three organs which will superintend the calcification of the tooth: the layer of ameloblasts—that is, a portion of the ameloblastic layer, as seen at *a*; the odontoblastic layer, situated over the apex of the pulp, at *o*; and the follicular wall, at *c. ct.*, which will form the osteogenetic layer for the development of the cement.

With this brief summary, we will now take up the consideration of the manner in which the cords for the permanent teeth arise, and afterward return to the study of the special manner in which calcification occurs.

Development of the Cord for the Permanent Teeth.

What I have thus far said has reference to the twenty temporary teeth. The permanent teeth which will displace these arise from an epithelial *cord* which has its origin from the cord of a corresponding temporary tooth. This statement holds good for the centrals, laterals, bicuspids, and—in some instances—for the sixth-year molars. When the sixth-year molar does not derive its cord directly from the mucous membrane of the mouth, it arises from the distal face of the second-year temporary molars. As a rule, however, the cords for the permanent molars arise directly from the epithelium of the mouth. It is held by some that the cords for the twelve permanent molars arise from the lamina at the same time as the cords for the temporary teeth, but lie dormant until the time comes for their special development; others hold that the cords spring from the débris of the temporary cords. I do not think that either position can be substantiated, for, as I have previously shown, the band flattens out posteriorly into the mucous membrane of the jaw at about the position to be occupied by the sixth-year molars. I do not look upon the band as an essential element in tooth-development except as it serves to direct the line of the dental arch. It is to be remembered that at the time when the formative process for the temporary teeth begins there has been no effort upon the part of Nature to establish the boundary of the jaws. The muscular plates have not as yet been differentiated, and the jaws are simply solid buds from the body of the mesoblast, and are surrounded by the epiblastic layer. Such being the case, the band acts as the guide to the proper location of the temporary teeth. But, the jaws having been formed, the twelve permanent teeth naturally take a proper location.

Concomitant with the origin of the cords for the permanent teeth,

the temporary cords present certain buddings which gather themselves into whorls of epithelial cells; to these have been attributed the origin of supernumerary teeth. I have no opinion to advance in the matter, never having seen any developing enamel organs in such position as to connect this supposed source with these abnormalities. The cord for the permanent teeth arises, as a rule, from the lingual aspect of the temporary follicle or the cord for the same. With the severance of the temporary enamel organ from its cord, the cord for the permanent enamel organ appears as a continuation of the former, and passes down upon the lingual aspect of the temporary tooth. This is shown in the preceding figure (358). The direct continuation of the temporary cord into

Fig. 359.

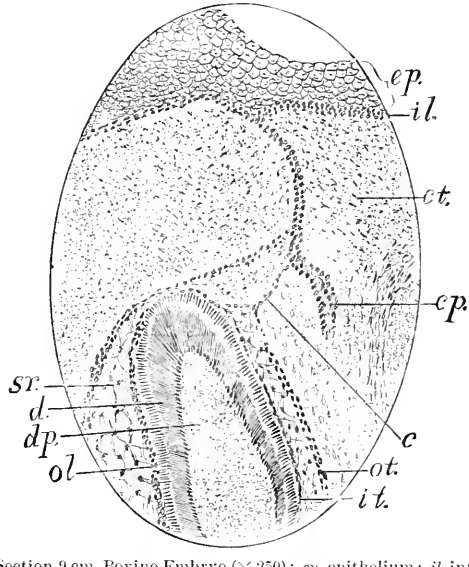

Vertical Transverse Section 9 cm. Bovine Embryo (× 250): *ep*, epithelium; *il*, infant layer; *cp*, cord of permanent tooth, still united at *c* with outer tunic (*ot*) of temporary tooth; *it*, inner tunic; *ol*, older layer of cells, known as stratum intermedium; *dp*, dental papilla; *d*, dentine; *sr*, stellate reticulum.

the permanent is nicely shown in the accompanying cut from a 9 cm. bovine embryo, where the connection is not yet entirely severed between the cord and the temporary tooth-follicle.

The time for the origin of the cord for the permanent teeth varies considerably. In the human embryo the cord for the permanent central incisor first makes its appearance about the fifth month. In the porcine and bovine embryos the cords for the permanent central incisors arise when the fœtus has attained about 8 cm. in length. Those of the premolars in porcine embryos arise as we have seen in the 10 cm. fœtus (Fig. 358). The length of the cords for the permanent teeth varies noticeably in different species and in different teeth of the same species. The course of the cords for the permanent teeth also assumes a more spiral direction than do the cords for the temporary teeth. I have never been able to satisfy myself as to the special signification, if any,

that these convolutions may have. They may arise from unequal cellular activity at different points; at any rate, they are well-known characteristics of the cords for the permanent which distinguish them from the cords for the temporary teeth. The cord passes down upon the lingual aspect of the temporary tooth and follows the same changes which

FIG. 360.

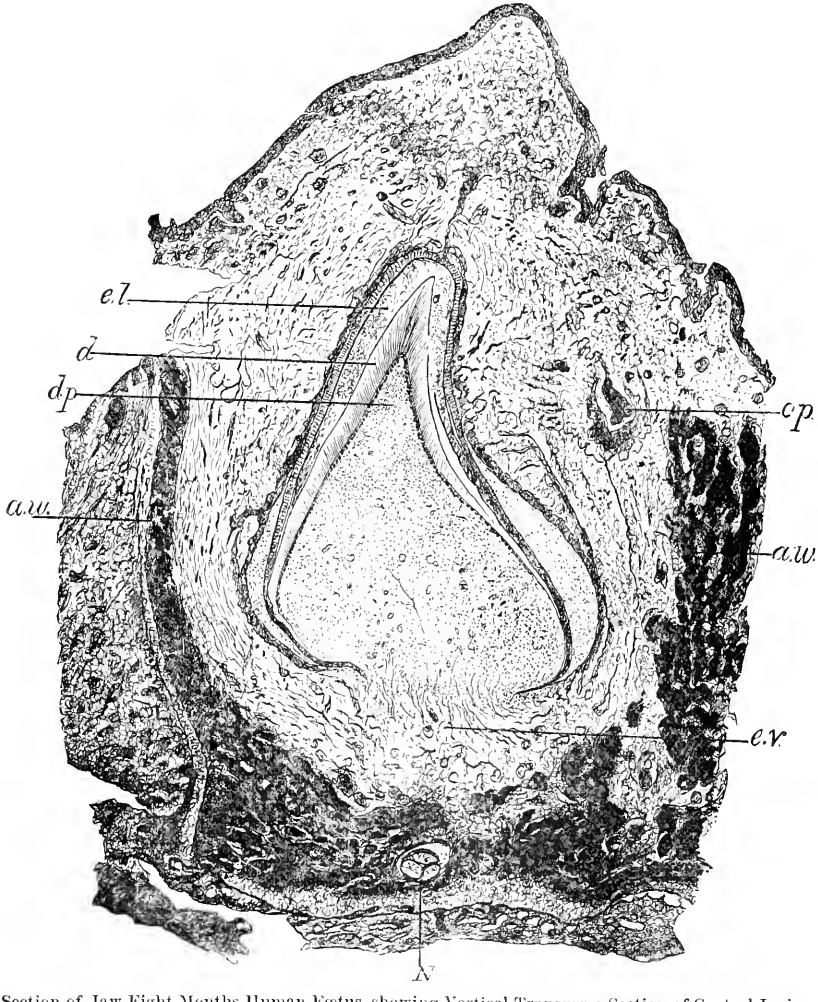

Section of Jaw Eight Months Human Fœtus, showing Vertical Transverse Section of Central Incisor, (injected; × 40): *el*, enamel; *d*, dentine; *dp*, dental papilla or pulp; *aw*, alveolar wall; *ep*, enamel organ permanent tooth; *ev*, entrance to vessels; *n*, nerve.

we have noted in the cord for the temporary tooth. It becomes bulbous at its deepest extremity; then it becomes invaginated by contact with the dental papilla, after which it settles deeper into the substance of the jaw, and is finally separated from the mucous membrane of the mouth. (See Fig. 360, *ep*.) It gradually becomes deeper seated, until it comes

to occupy a position directly underneath the temporary tooth, and is very nicely shown in Fig. 361, representing a temporary molar from jaw of rabbit. The multicuspid nature of the enamel organ for the molar teeth is here plainly shown.

FIG. 361.

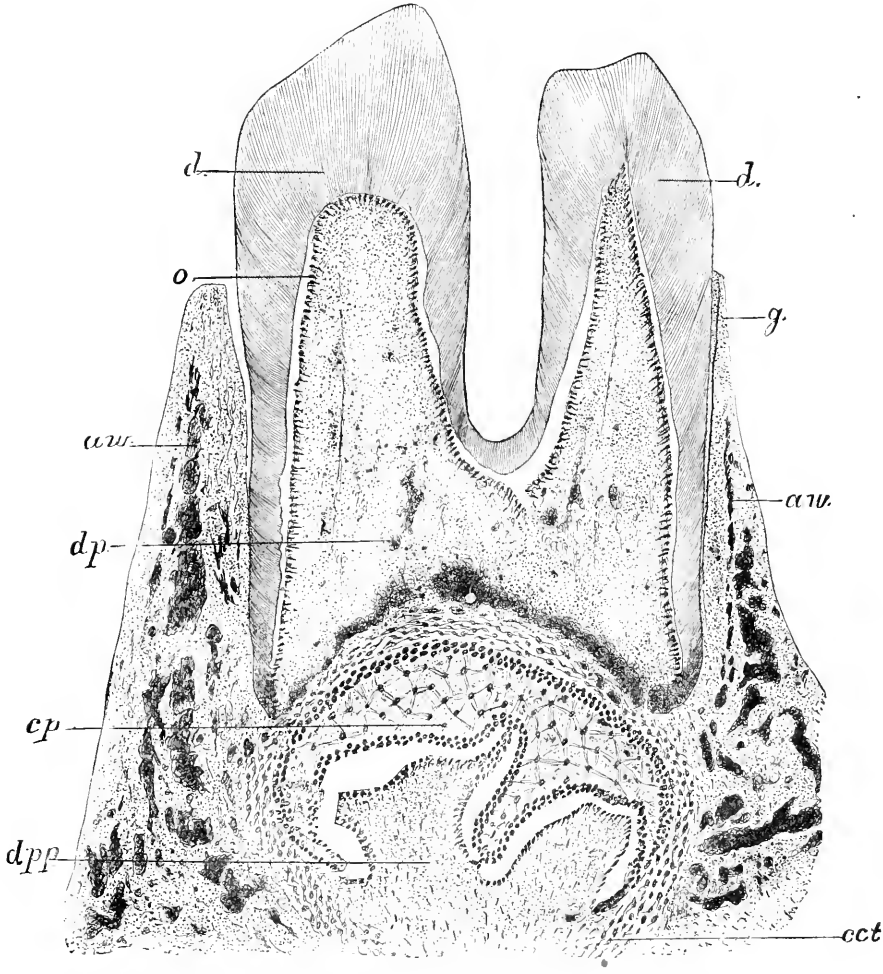

Temporary Molar (Rabbit), with permanent developing underneath; the enamel has been removed by acid in decalcifying process; *d*, dentine; *o*, odontoblasts; *aw*, alveolar wall; *dp*, dental pulp; *cp*, enamel organ for permanent molar; *dpp*, dental papilla from permanent molar; *g*, margin of gum (× 40).

The changes which occur in the enamel organ have been considered under the head of the formation of the stellate reticulum and development of the ameloblasts. The latter we noticed briefly under the products of the epiblastic layer. We will now enter into the study with more detail. The accompanying figure is the same as that presented

on p. 633, and is here introduced to serve as a guide to the higher-power studies which are to follow. The circles drawn at *a, b, c, d* rep-

Fig. 362.

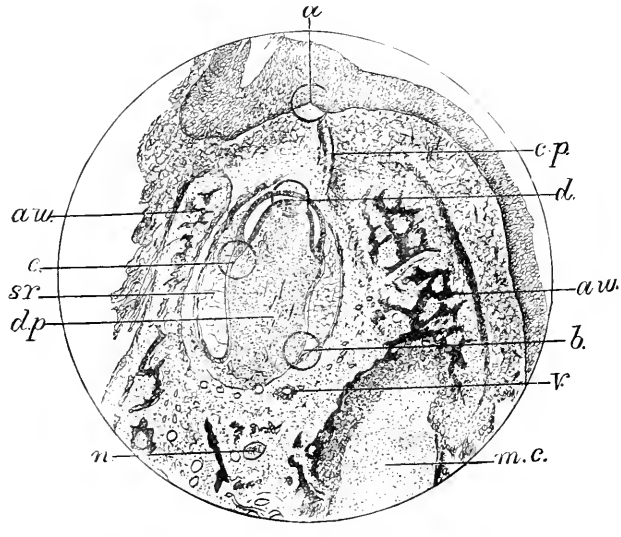

Vertical Section Jaw Porcine Embryo (10 cm. × 25): circles *a, b, c, d*, indicate positions from which figures are taken; *cp*, cord, permanent; *aw*, alveolar wall; *dp*, dental papilla, or stellate reticulum; *n*, nerve; *v*, vessels; *mc*, Meckel's cartilage.

resent the positions from which Figs. 343, 363, 365, 366, were taken. The first of these we presented when considering the development of the mucous membrane of the mouth, on p. 615.

The line *il* marks the infant layer of cells. This line also constitutes the outer and inner tunic of the enamel organ. The cells which fill the interspace correspond to those in this cut marked *ol*. Now, thoroughly to appreciate the relative positions of the two tunics it is necessary to remember that the enamel organ is formed by an infolding and involution of the infant layer of the epithelium, and as such it is composed up to a certain time of elements of a like nature with the infant layer of the mouth, from which it arises. After a time, however, the character of the cells undergoes certain changes, which we will describe later on.

We took occasion to say, when considering a section from a porcine embryo 8 cm. (see Fig. 357) in length, that the two tunics, both outer and inner, gave no indication of the appearance of the ameloblasts, but that they still presented the same features seen in the infant layer of the mucous membrane of the mouth. Up to this time the outer and inner tunics have presented the same features. They have both been composed of oval nuclei lying in beds or sheets of protoplasm which constituted the walls, inner and outer, of the enamel organ.

The first change noted is seen over the apex of the papilla. The protoplasm begins to break up into columns, which stand at right angles to the sides of the papilla; each column contains a nucleus. The

shapes of the cells are not unlike those previously described in studying the sweat-glands. They are columnar or basaltic in character, and are, as may be inferred, specialized cells for a special purpose.

The several stages through which the infant layer which composes the inner tunic passes may be studied in the one specimen in hand. We have seen the character of the cells which form the infant layer of the mucous membrane of the mouth, also the inner tunic of the enamel organ of the 8 cm. pig. By referring to Fig. 362, taken from the side of

FIG. 363.

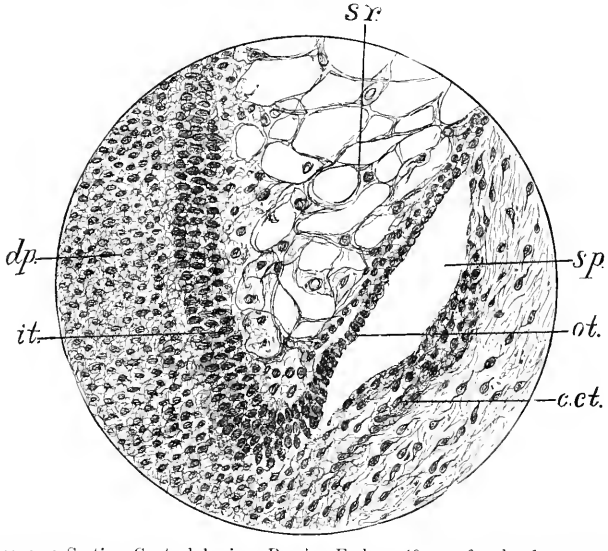

Vertical Transverse Section Central Incisor Porcine Embryo 10 cm.; free border enamel organ seen in circle *b*, Fig. 360 (× 250): *dp*, dental papilla; *sr*, stellate reticulum; *ot*, outer tunic; *it*, inner tunic; *sp*, space; *c. ct.*, condensed connective tissue of follicular wall.

the enamel organ (circle *b*), it will be seen that no change has occurred. There has been no effort upon the part of Nature to develop ameloblasts, but as we proceed higher up the sides of the papilla we see at circle *c* that the formation of columnar cells has begun; and when we reach the apex circle *d*, well-marked columnar cells are seen. Now, thoroughly to understand the reason why we do not find columnar cells at *b*, we must remember that calcification begins at the apex, and not upon the sides, of the papilla. The lower borders of the enamel organ are growing and extending deeper and deeper into the substance of the jaw. This rapid development of cells continues until the sides of the enamel organ have attained their typal length, when growth ceases and the cells of the inner tunic become converted into true columnar cells, the development of which has proceeded from the apex of the papilla along the sides toward the free border of the enamel organ. So, if we reverse the order of our study, we shall be able to follow the several stages of developing ameloblasts. But, as it will be more convenient to study the formation of ameloblasts and odontoblasts together, we will do so, first premising that the ameloblasts are a product of the epiblastic

layer and arise from the inner tunic, and that the odontoblasts belong to the connective-tissue group and are derived from the dentinal papilla, or pulp. By referring to Fig. 364, taken from the position marked

FIG. 364.

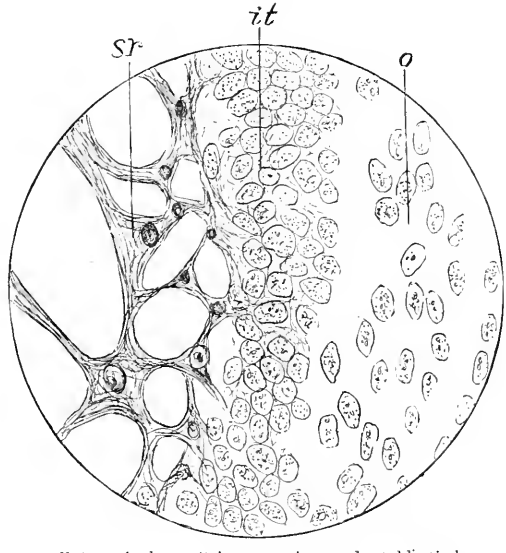

sr, stellate reticulum; *it*, inner tunic; *o*, odontoblastic layer.

by a point opposite the line *sr* (Fig. 362), and magnified 500 diameters, it will be seen that the ameloblasts and odontoblasts have not as yet made their appearance. This is below the point where calcification has reached. Proceeding up the sides to the lowest point where the formation of dentine appears—marked by circle *c*, and more highly magnified in Fig. 365—we see the first appearance of odontoblasts (*o*); they present themselves as elongated cells with fine processes extending into the homogeneous, calcareous mass. On the outer side of this line of forming dentine the layer of ameloblasts is plainly seen; the ameloblasts are columnar in form, with the nucleus of each situated at its outer end. Still outside of the ameloblastic layer is plainly seen the flattened layer of older cells which are always observed lying upon the layer of ameloblasts; they are the cells which have not become stellate —the stratum intermedium. Outside of these, and situated between the two tunics, is the stellate reticulum, which, with the outer tunic, is rapidly passing through a retrograde process by which it loses its identity.

The development of dentine always precedes the formation of enamel. The disappearance of the outer tunic occurs about the same time as the beginning of the calcification of the first layer of enamel, the salts of calcium which are stored up in the meshes of the stellate reticulum only sufficing to furnish material for the very first formed layer of enamel. With the disappearance of the outer tunic and the stellate reticulum, as such, the ameloblasts come in direct communication with

the rich plexus of capillary vessels, the latter furnishing the lime salts for the completion of the calcification of the enamel. By referring to Fig. 366, taken from circle *d*, it will be seen that a slight layer of enamel has been formed which has the appearance of a honeycombed layer. Between this layer of enamel and the layer of ameloblasts a space is noticed which was caused by shrinkage in the process of

FIG. 365.

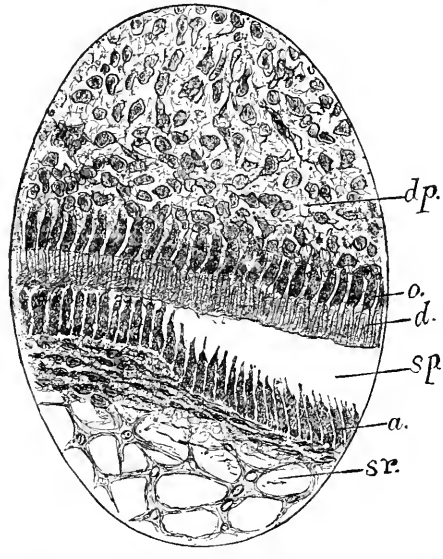

Circle *c*, Fig. 360 (× 250): *dp*, dental papilla; *o*, odontoblasts; *d*, dentine; *sp*, space; *a*, ameloblasts; *sr*, stellate reticulum.

hardening. Into this space projects a fibrillated margin of the ameloblastic layer known as Tomes's processes, of which we will speak later.

There exists considerable confusion regarding the outer tunic of the enamel organ. The most erroneous statement concerning it was published by Waldeyer, who says: "As far as the external epithelium reaches, the adjoining connective tissue exhibits its tolerably regularly-formed vascular papillæ, which project into the epithelium and correspond to the papillæ found in the remaining portion of the oral mucous membrane." He also presents a cut which does not represent the true condition of the enamel organ at this stage of development, either in the human or porcine fœtus. He neglects, however, to state the age or length of the fœtus—two essential points to be considered in presenting illustrations. This cut has been extensively copied, and those who have used it have also neglected to locate it. Now, the outer tunic does not present indentations in its surface until it begins to break up; it is smooth and even, like the inner tunic, until the time comes for its disappearance. The history of its retrogression can be followed as carefully as can the progression of the inner tunic. If we examine Fig. 363, taken from circle *b* of Fig. 362, we shall be able to

note the difference in the two tunics at the free margin of the enamel organ. In younger specimens there is no apparent difference between the two, but it must now be remembered that calcification has commenced at the apex of the tooth, and that material changes will now occur in the inner tunic; these have been noticed. The character of the enamel organ as such is rapidly changing; it has served its purpose, and from now on, upon the apex of the papillæ, it will disappear, and this change will gradually proceed down the sides of the papillæ until the typal demands of the enamel cap are reached.

There is, however, a marked difference between the inner and the outer tunic at this stage. The inner tunic gives evidences of rapid cell-proliferation and consists of many nuclei, forming a thick layer; on the other hand, the outer tunic consists of a single layer of cells. This is very happily shown in the figure by the shrinkage which has occurred just above the free margin, allowing the outer tunic to stand out in relief. This same character of the outer tunic, as compared with the inner tunic, is seen at circle *c*. At circle *d* (Fig. 366) the outer tunic and the cells of the stellate reticulum have settled down upon the layer of ameloblasts, sometimes arranging themselves in whorls, seen at *wh. ep.* (Fig. 358). Just what their signification is I am unable to state positively, but from my studies in comparative embryology I am led to believe that they supply the places made by the increase in the circumference of the enamel, and account for the short prisms seen in ground-sections of enamel.

FIG. 366.

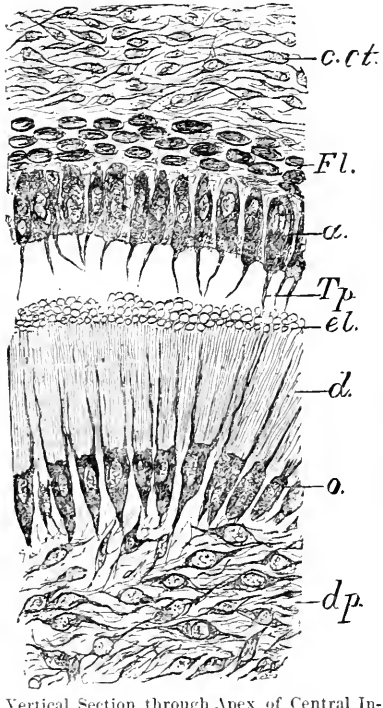

Vertical Section through Apex of Central Incisor 10 cm. Porcine Embryo (×500): *c. ct.*, connective tissue of follicular wall; *Fl*, flat layer of stratum intermedium; *a*, ameloblasts; *Tp*, Tomes processes into space; *el*, enamel; *d*, dentine; *o*, odontoblasts; *dp*, dental papilla.

In the development of teeth, where the enamel is to form a coat of mail on the crown of the tooth—viz. the Carnivora—the line of ameloblasts that is first formed does not represent the same number of ameloblasts that will finally complete the process of calcification. The outer circumference of the developed enamel is many times larger than that of the first calcified layer. If this represented a straight line, as the enamel on the rodent's tooth does, then the space would be made at one end of the line; but here it is in the form of the greater part of a circle. The expansion occurs at all parts, and the cell-supply from which the ameloblasts are developed is found lying in close proximity to the ameloblasts. Along the side of the enamel organ which forms the

straightest line fewer cells are found than on the upper arc of the circle, where the expansion is greatest.

In the rodents we do not see the same thickness of cells outside the ameloblastic layer as we find in the Carnivora. Previous to the formation of the ameloblasts in the rodent's tooth the inner tunic is made up of three or four cells, arranged as before described, on the outer boundary of which an equally thick layer of spheroidal cells appears, being also densely packed. Outside of these is the fibrous connective-tissue envelope.

This dense layer of spheroidal cells grows thinner toward the cutting edge, until at the point where the prismatic ameloblasts are fully formed it disappears, and we find the fibrous connective-tissue layer with its numerous capillaries in apposition with the ends of the ameloblasts. The office of the spheroidal cells in this instance is to develop ameloblasts to supply the places of those which were carried up with the growing tooth, enamel being developed only on the labial face, which represents almost a straight line. The extension of the line of ameloblasts is from the first-formed enamel-prism nearest the base of the tooth, and here we find located the supply which replaces such extension.

The persistence of the enamel organ at the base of the continuously-growing rodent's tooth has to my mind a peculiar signification: it is the forerunner of calcification. The same thing is seen upon the sides of the developing tooth in the Carnivora and Herbivora, after the commencement of the calcification of the enamel, but it disappears with the completion of the enamel cap in length. The final calcification in thickness is accomplished after the atrophy of the enamel organ has occurred. It is absolutely essential that the capillary vessels should come in contact with the enamel-cells before the process of calcification can be completed. In the human fetus this atrophy occurs at the apex about the fifth month, when only a very thin layer of enamel has been formed.

In the injected specimens which I have made and studied I have never been able to demonstrate any vessels in the internal portion of the enamel organ. I consider, from the experiments with the osmic-acid preparations of enamel organs, that the lime salts which go to form the first layer of enamel are supplied by the enamel organ itself.

The quantity, however, as I have before stated, is not sufficient to complete the process of calcification; but that a certain proportion is furnished by the enamel organ I have no doubt. I have never been able to demonstrate any capillary vessels in the stratum intermedium. The nourishment of the inner tunic comes from the vessels of the pulp until such time as it is cut off from them by the development of the layer of dentine which separates them most effectually from that source of supply.

The enamel organ is not a secreting organ except in so far as it furnishes the lime salts for the calcification of the first-formed layer of enamel, because its disappearance as an enamel organ quickly follows the formation of this first layer. This being the case, the supply of salts of calcium must of necessity be derived from another source.

As regards the development of the enamel, there are many theories.

Some hold that the enamel is a differentiation of a dentinal basis, but the fact that calcification of both dentine and enamel, beginning at the same line, progresses in opposite directions, makes that ground untenable. Others hold that the enamel results from the calcification of the enamel-cells themselves. From a casual examination this does appear to be so; but if such were the case, then at the beginning of calcification the enamel-cells would correspond in length to the length of the developed enamel-prisms, and the decrease in the length of the enamel-cells would be commensurate with the increase in the thickness of the enamel, or the enamel-cells would extend on themselves as calcifiation progresses; which phenomenon has not been established. It is asserted that the multiplication of the ameloblasts in the direction of their length is from the cells of the stratum intermedium as rapidly as calcification occurs at their free ends—that is, the calcification of the cell-body at one end and the building up at the other are made a consequent necessity. If the ameloblasts are directly calcified, it is the only place in normal development of tissue where calcification of cell-body does occur. In the development of bone the osteoblasts do not become calcified, but the lime salts are deposited around the spherical osteoblasts in the form of spherules, increasing in thickness from within outward; and, thus approaching one another, they coalesce. The osteoblasts persist as the organic contents of the lacunæ. The connection of one lacuna with neighboring lacunæ forms the canaliculi, and the capillary blood-vessels around which the osteoblasts are arranged become the Haversian canals.

In the calcification of dentine, as we have seen, the odontoblasts do not become directly calcified, but send out rod-shaped fibrils, around which tubular dentine is formed; so also in the enamel we have the prismatic ameloblasts superintending the deposit of prismatic enamel.

If a newly-formed layer of enamel which lies on the dentine in a thin plate be torn off from a thick section of tooth and mounted, the outer surface will be seen to be pitted—that is, provided you have succeeded in getting the enamel in just the right stage of calcification. The periphery of the pits corresponds to that of the ameloblasts. The ameloblasts, during the formation of enamel, seem to be impregnated with lime salts and break with a clean fracture at almost any point —sometimes near the newly-formed enamel, and sometimes at a point just inside the nucleus.

C. S. Tomes noticed the fact of the probable impregnation at the end nearest the forming enamel, and cited it as proof of the actual conversion of the ameloblasts into enamel-prisms. The impregnation of both ends of the cells is accounted for in the fact that they are carrying lime salts to the forming enamel. The pits in the newly-formed enamel are the central portion of the prisms, from which the still uncalcified exudation has been drawn by the ameloblasts when they were separated from it.

This semi-calcified material, which adheres to the ameloblasts, gives the appearance of a fibril or prolongation of the cells themselves. These fibrils—which have been called Tomes's processes—I consider as thus being mechanically made; for they do not always appear, but depend

upon a certain condition of the calcific material. They do not occur persistently, as do the fibrillæ of the odontoblasts. I have, under favorable circumstances, succeeded in demonstrating them in sections of pigs' teeth, where they showed very plainly indeed, being nearly or quite as long as the ameloblasts themselves and several times longer than the enamel was thick. As a rule, however, the ameloblasts separate from the forming enamel so as to leave a comparatively smooth line or plate —that is, provided the sections have been sufficiently thin, so as not to show a ragged edge from the overlapping of the cells themselves. I have never been able to demonstrate processes that would lead me to infer the least analogy between them and the fibrillæ of the odontoblasts. That the enamel organ exists in the commencement of the development of the teeth is now generally admitted. There are certain classes of teeth, however, that do not possess enamel, and in which, although there is an enamel organ developed, the stellate reticulum fails to appear. In all cases where there is to be a deposit of enamel we find a stellate reticulum fully developed, and my observation leads me to believe that the calcification of the *enamel-matrix* is due to the calcific material stored in the meshes of the stellate cells of the enamel organ.

The subject of calcification has already been considered, and will be referred to here only in a general manner. After the temporary teeth are developed and have served their purpose, they are then removed by resorption of their roots and their places taken by the permanent set. The process of resorption is physiological, and is accomplished through the agency of *giant-cells*. This part of the subject has been considered quite fully under the head of Physiological Action of Cells, in the opening chapter. The comparative stages of decalcification of the temporary and calcification of the permanent teeth have been so well delineated by Prof. Pierce in his chart in the *Dental Cosmos* (August, 1884) that I cannot do better than reproduce it here (see p. 647), together with the explanatory text accompanying the same:

"In the microscopical examination of dense animal tissues, or such tissues as are impregnated with the salts of lime, it becomes evident that they, like vegetable structures, have periods of growth and of rest, which are illustrated by concentric layers or zonal shades, and that, while these conditions are normal, they are both modified and intensified by the genius presiding over the function of nutrition. Unfortunately, however, in dating the progressive solidification of tissues, we can with a degree of certainty mark the beginning and the end only, the intermediate lines merely approximating the conditions which we attempt to illustrate; yet they are near enough to exactness to give a comprehensive idea of the condition of the average tooth at a certain age, and in so doing they serve as an important guide in the performance of many necessary dental operations (Fig. 1).

"From the tabular statement or chart to which we have alluded above we see that by the seventh week of intrauterine life, and when the embryo is less than one and a quarter inches in length, preparation is made for the development of the enamel-germ or matrix, followed in the ninth week by the dentine-germ, these germs continuing in or through their progressive stages until the seventeenth week, when we

find in the incisors and cuspids the border-line between the enamel- and dentine-germs receiving depositions of the salts of lime; or, to speak more correctly, we see the formation of the odontoblast-cells and their conversion into dentine and the ends of the enamel-cells into enamel by the formation and calcification of the ameloblasts. By the end of the nineteenth week the same developmental process has reached the molars, and from this period until the fortieth week, or time of birth, the growth of the tooth-germs and their calcification progress simultaneously. At birth the calcification of the crowns of the eight incisors is quite complete; the four cuspids and four first molars are fully two-thirds calcified, and the four temporary second molars have their crowns for half their length solidified by the same process. At the end of the following three months the infant enters into the critical period of its life, and from a glance at the condition of the twenty deciduous teeth and their progressive developmental changes it is fair to assume that this condition has not a little to do with the various abnormal systemic lesions or disturbances to which the child is liable at this age. In close proximity to the sharp and irregular edges of the calcifying extremity of each partial or complete tooth-crown lies the vascular papilla—the primitive tooth-pulp—and any want of correspondence between the absorption of the overlying gum at the coronal extremity and the deposition of solid matter at the calcifying or papillary extremity must produce, by this retarding influence, an irritation limited in its extent by the number of teeth advancing, the duration of the cause, and the ramifications of the trifacial or fifth pair of nerves and the extent of the sympathetic disturbances to which they are liable. The necessity for operation when the irritation becomes pathological is so unmistakable that it seems hardly necessary to remind you of the great advantage to be gained from the free use of the lance as soon as this condition becomes apparent.

"Another point worthy of recognition is the period at which the calcification of the apical ends of the roots of all the teeth is completed. Not infrequently these deciduous teeth, before eruption is complete, have become a prey to rapid molecular decomposition through the agency of dental caries. Pulps are sometimes exposed while yet the root is not completed in its growth. The impropriety of resorting to the ordinary method of pulp-devitalization is, under such circumstances, very apparent. When we consider the time of calcification, it is not a matter of surprise that the crowns of the deciduous teeth are much less frequently subject to malformations and defects arising from deficiency in the quantity and quality of enamel and dentine than those of the permanent set. The crowns of these teeth are largely provided for in embryonic life, and unless the mother during gestation is in markedly poor health, so that the function of nutrition is but imperfectly performed, the fœtus invariably escapes the necessary consequences of imperfect nutrition, which is so common after birth; yet if during this important period to the embryo there should be a prolonged attack of ill-health and systemic depression, the crowns of the deciduous teeth would give its history by deficiency in the quantity and quality of enamel and dentine.

Fig. 367.

CALCIFICATION AND DECALCIFICATION OF THE TEETH.

Fig. 1.

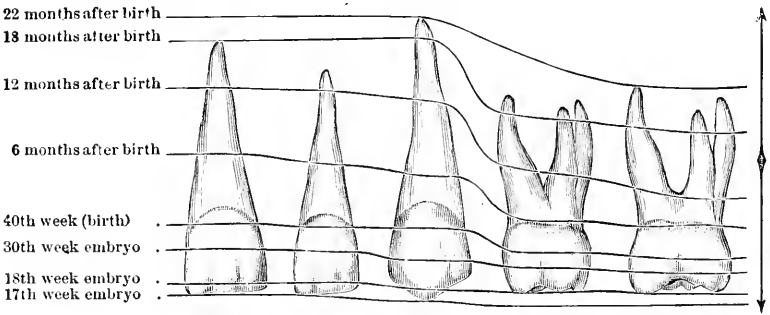

Calcification of the Deciduous Teeth.

Fig. 3.

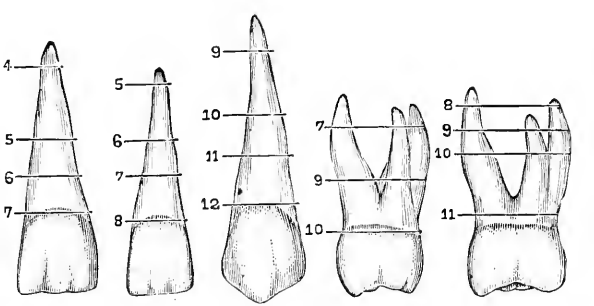

Decalcification of the Deciduous Teeth.
The numbers on Fig. 3 indicate years.

Fig. 2.

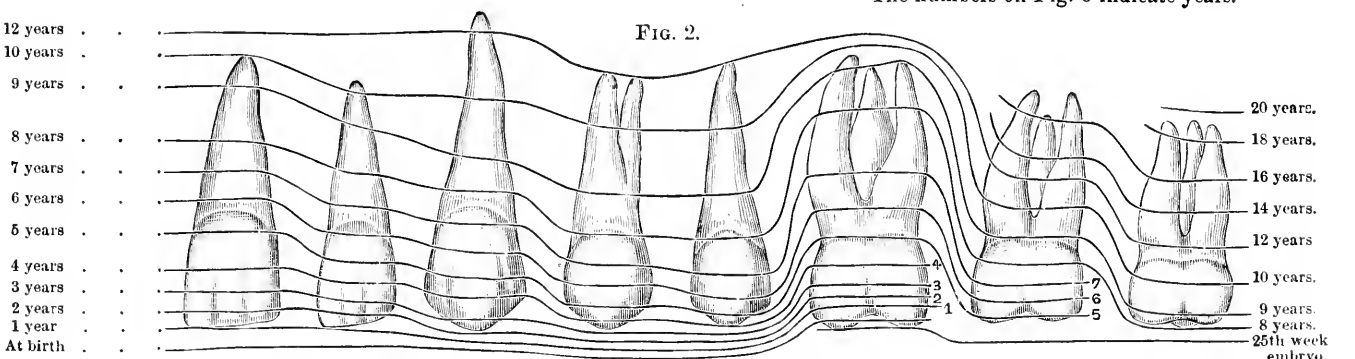

Calcification of the Permanent Teeth.

From a Paper by Dr. C. N. Peirce, in the Dental Cosmos for August, 1884.

"We come now to the permanent teeth, the calcification of which is illustrated by Fig. 2. By again referring to the tabular statement above mentioned we see that as early as the fifteenth week of embryonic life preparation is made for the development of the four first permanent molars, and following close upon these, in the sixteenth week, is the inflection giving rise to the enamel organ for the twenty anterior permanent—the successors to the twenty deciduous—teeth, and from this period until the birth of the infant the germs for twenty-four of the permanent teeth are passing through their several progressive stages preparatory to receiving the salts of lime. At birth, then, the child has not only the twenty deciduous teeth largely advanced toward calcification, but has germs of twenty-four permanent teeth, in twelve of which calcification commences the first year. The germ of the second permanent molar makes its appearance the third month, and that of the third molar the third year, after birth.

"The permanent teeth, unlike the deciduous, are during the periods of calcification constantly subjected to the influence of morbid systemic conditions, and any abnormal nutritional condition, of but a few days' duration, if occurring during the period of coronal calcification, is sure to make an impression upon the crowns of the teeth, which are at the time undergoing this process, markings or defects being located at the point of calcification and limited in extent or modified by the severity and duration of the abnormality or lesions. The principal object or advantage of Fig. 2 will be to determine the age of the child when the systemic conditions existed which caused the faults or imperfections in the development of the teeth. If serious nutritional disturbances have occurred prior to the termination of the tenth year, some one or more of the permanent teeth must in all probability have recorded it. Another service which this illustration will render will be in determining the condition of the apical end of the root or roots in any given tooth, when beginning treatment, from pulp-exposure arising either from caries or fracture, and also from partial or complete dislodgment by accident. This knowledge will in many instances aid the operator in forming his judgment as to the best methods to be pursued for the relief of his patient.

"As represented by the first and second lines in the diagram, we see that the four first permanent molars and the eight incisors have prior to the termination of the first year all received a portion of their lime salts, and before the termination of the third year twenty-four of the thirty-two teeth are in this process of development. The fifth year the second permanent molars and the eighth year the third molars or wisdom teeth commence calcification. With the permanent set it is rarely that the patient suffers from the effects of interrupted dentition, as is so frequently prominent in first dentition; yet at times both the cuspids and bicuspids are so retarded in their eruption by the persistence of their deciduous predecessors, or by a small and contracted condition of the maxillary bones, that serious trouble results; also, from induration of the gums or non-absorption of the anterior portion of the ramus or tuberosity, either the first, second, or third molar may be the cause of much local inflammation and a febrile systemic condition, and especially

is this invariably the result of an impacted third molar. The fact that the third molars are developed during the period of childhood and youth and while the system is liable to frequent conditions which impair nutrition is probably one potent reason for their frequent lack of usefulness and durability.

"The decalcification or absorption of the roots of the deciduous teeth is illustrated as far as practicable by Fig. 3, and in this effort your essayist has found it extremely difficult to do more than approximate the time at which this interesting and somewhat obscure physiological process is carried on. The average period at which it commences will be sufficient to indicate the time when much care will be necessary in the application of the arsenical paste for the devitalization of the pulp, and in the subsequent treatment of the pulp-chamber and root-canal. This process, usually commencing in the incisors before the close of the fourth year, progresses gradually, when normally accomplished, from the extreme end of the root toward the crown for about three years, and usually releases this deciduous crown between the seventh and eighth years, the central incisor being some months in advance of the lateral. The absorption of the roots of the first deciduous molars may be placed a year later than that of the lateral incisors, commencing about the middle or close of the sixth year and terminating with the removal of the first deciduous molars, about the tenth year, the second molars following usually some months or a year later. The cuspids—invariably the last of the deciduous teeth to be shed—have their period of absorption from the eighth to the twelfth year. While these periods would correspond with the absorption and removal of the teeth in the average mouth, so variable are they in different families that many would be widely different from the above figures.

"I have just spoken of this absorptive process as being physiological and somewhat obscure. It certainly is both, and, in contradistinction to the evolution of the tooth, may be termed its dissolution. . . . . What induces this molecular dissolution it is difficult to state, though the several conditions which are always present are readily recognized; but the part they play is so obscure that it is not readily ascertained. The manner of its commencement when successful—always at the end of the root—and the presence of a vascular papilla in close proximity to the absorbing surface are, with the retention of pulp-vitality, three essential accompaniments, and the absence of any one of them would militate against the completion of the process.

"The statement that the presence and pressure of the permanent tooth are essential cannot be sustained, for frequently the decalcification of the deciduous tooth is successfully accomplished in the absence of its successor; and again, how often do we find the permanent tooth impacted against or within the bifurcated roots of the deciduous molar, or pressing down by the side of its single-rooted predecessor, both being more or less displaced by the persistence of the deciduous tooth without absorption! That the organ has served its purpose, and that the nourishment which had previously been appropriated by it is diverted or relegated to its successor, is probably the most plausible explanation we can give of this interesting physiological process.

"This demonstration of dissolution and evolution is not alone confined to the teeth. The ramus of the inferior maxillary gives evidence of a similar phenomenon by absorption from its anterior border, with corresponding growth of its interstitial tissue, giving development and prominence to its posterior line. There are also bone-cased cavities and canals, increasing in diameter and capacity by absorption from within and addition to the surrounding walls. These, we conclude, are the results of similar physiological efforts. Roots which have long been bathed in pus from the establishment of chronic alveolar abscesses frequently display a worm-eaten appearance. This, though representing dissolution, is a chemical and pathological process depending, we surmise, entirely upon the acrid condition of the pus, and is not in any case to be mistaken for the physiological process which we have above described.

"In recording the periods of calcification of the deciduous and permanent teeth it should be noted that in many instances a want of correspondence between their calcification and eruption exists. By premature removal of the gum the crown is frequently exposed while yet there is no root-calcification, as instanced in deciduous incisors when erupted at birth, their crowns only being calcified, which is the normal condition of these teeth at this age. Again, not infrequently the persistence of the deciduous cuspids and molars as well as of the indurated gum over an advancing permanent molar causes delay in the eruption of the permanent teeth until after the calcification of their roots is completed. These instances illustrate that in one case eruption takes place without the development of the root, and in the other we have complete development of both crown and root without eruption.

"In presenting to you to-day the periods of calcification as represented by Fig. 2, I am not unmindful that Dr. G. V. Black, of Jacksonville, Ill., had previously published in the *Proceedings* of the Illinois State Dental Society a series of diagrams representing the same physiological process. The results of his researches so nearly correspond with those of mine that I have been encouraged to present them with others representing the calcification and decalcification of the deciduous teeth."

The comparative stages of calcification of the temporary and permanent teeth are also nicely shown in Fig. 368, taken from a jaw of child seven years of age. (This specimen is one of a series belonging to Prof. T. C. Stellwagen.) The eruption of the permanent incisors and sixth-year molars has been accomplished. The lateral incisor crown and a portion of the root are formed. The root of the temporary lateral is partially resorbed. The crowns of the cuspids, first and second bicuspids, and the twelve-year molars are well advanced in the process of calcification. The roots of the central incisors are not, however, fully formed, but the apical foramen still remain largely open. The roots are exposed by removing the bony covering; sufficient is left at *mf* to mark the mental foramen. The cancellated nature of the alveolar wall is such that the greatest mobility is afforded the erupting tooth. The pressure of the lips externally prevents the arch protruding; this is opposed by the outward pressure of the tongue, so that no uneasiness

should be felt by the practitioner, provided the teeth under his care were erupting the upper external to the lower.

FIG. 368.

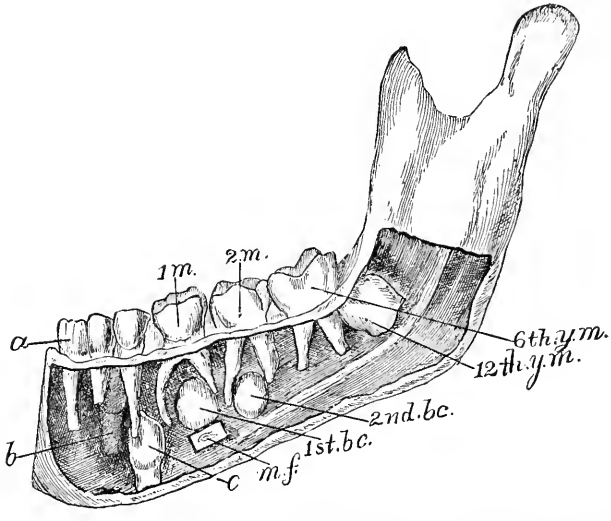

Drawing from Prepared Specimen from Prof. Stellwagen's Cabinet: *a*, permanent central incisor; *b*, erupting permanent lateral incisor; *c*, developing permanent cuspid; *1 m*, first temporary molar; *2 m*, second temporary molar; *mf*, mental foramen. The other letters plainly indicate their adaptation.

COMPARATIVE CHRONOLOGY OF THE DENTAL FOLLICLE.

In sections from the jaws of the common snake which are supplied with successional teeth, all the stages of tooth-development may be observed in the same section, from the first infolding of the mucous membrane through the invaginative process to complete calcification. The same may be seen in sections from the jaw of the dogfish. In the human fœtus the first indication of tooth-formation is seen about the forty-fifth day, and consists in the formation of the epithelial *band*. There is as yet no indication of points of ossification; Meckel's cartilage marks the central portion of the inferior maxilla. Between this age and two months the evolution of the *lamina* and *cords* for the temporary is accomplished. The cords for the central incisors are bulbous, while those for the other teeth show varying stages of development, those for the molars being less fully developed than are those for the incisors. Ossification is seen in both jaws alike. This is also true in regard to the development of the dental follicles for the temporary teeth, which occurs simultaneously in both jaws for the same teeth. At three months the enamel for the incisor teeth is nearly developed, the process of invagination having attained considerable progress. The central portion of the enamel organ gives indication of formation of the stellate reticulum. The forming bone has become a distinctive feature of the jaws and stands out in bold relief in sections stained with hæmo-

toxylon and eosin. There is no noticeable difference between the two tunics. The follicular wall is plainly seen.

At the fourth month the inner tunic at the apex of the papilla gives evidence of the development of the ameloblasts. The surface of the papilla at the apex also is covered by columnar cells, the odontoblastic layer. The central portion of the enamel organ is distinctly stellate. The stratum intermedium, lying upon the outer surface of the ameloblasts, is also well marked. The follicular wall is well developed and almost surrounds the enamel organ, which is still connected to the mucous membrane of the mouth by its neck. The cord for the permanent tooth may be seen in some instances coming off from the side of the enamel organ or from the neck of the enamel organ. In other cases the cords for the permanent do not make their appearance until a later period. I have not been able either by measurement or by other signs to establish any definite time for the origin of the cords of the permanent teeth.

Between the fourth and fifth month for the central incisors is accomplished the separation of the enamel organ from the mucous membrane of the mouth by the severance of the cord and the complete encapsulation of the enamel organ by the follicular wall.

At the fifth month the process of calcification of both enamel and dentine has considerably advanced for the incisors. The cuspids also show a thin enamel cap. The first and second molars give evidence of the multicuspid arrangement. The cord for the sixth-year molar is also seen. The bone of the jaw is largely developed, Meckel's cartilage has disappeared by ossification, and the alveolar walls are well formed and extend high up on the sides of the dental follicles.

At the eighth month, as seen in Fig. 360, calcification has progressed to a considerable extent. The enamel organ for the permanent central incisor is well developed and somewhat invaginated, and occupies a position upon the lingual face of the temporary tooth.

"On examining sections taken from the jaws of subjects two or three months after birth we discover in the region occupied by the follicle of the first permanent molar a process or prolongation, cylindrical in form, emanating from the epithelial cord of the latter follicle, and which takes a horizontal and backward direction, terminating in a bulbous extremity. This prolongation is the commencement of the follicle of the second permanent molar. Thus we fix the date of the origin of this follicle at the third month after birth. At about the third year of infancy the epithelial bourgeon that represents the enamel organ of the third molar originates from the cord of the preceding tooth—that is, the second permanent molar. According to the numerous observations we have made, this date may be regarded as very nearly accurate, though the difficulties of which we have already spoken have prevented us from following out the successive phases of evolution in a very rigid manner. Yet that a little cap of dentine is visible in this follicle about the twelfth year is true beyond a doubt." [1]

Bovine and porcine embryos show the same development for the same lengths, although there is a very considerable difference in the sizes of

[1] Dean's trans. Legro and Magitot.

the fœtuses at birth. Evolution of their dental follicles seems to begin about the same time.

At $1\frac{1}{2}$ cm. in the porcine embryo there is no indication of the formation of the band. The same holds good for the bovine embryos. The mucous membrane of the mouth of each is thicker than the external epithelium.

At $2\frac{1}{2}$ cm. the band is distinctly marked and the cells are heaped up over the line of the infolding epithelium.

At 3 cm. the lamina has made its appearance, and shortly afterward the buds for the cords of the temporary teeth are seen.

At 4 cm. the process of invagination begins, which marks the appearance of the dentinal papillæ; these arise from the embryonal connective-tissue elements into which the enamel organ by its growth is projected.

At 5 cm. the differentiation of the follicular wall has begun from the surrounding embryonal connective tissue. In its origin and character it is analogous with the tissue of the papilla, but seems to be condensed into a membrane, and in this differs from the pulp-tissue.

At 6, 7, and 8 cm. invagination is seen to be progressing, until at the last-named measurement it is complete. The formation of the stellate reticulum has also been accomplished. The bone of the jaw, which first made its appearance at 3 cm., has now well-defined alveoli, and the bodies of the maxillæ are well developed.

At 9 cm. the dentine cap is plainly visible, and the cords for the permanent teeth are seen springing off from the lingual face of either the enamel organ of the temporary tooth or from the cord of the same.

At 10 cm. the enamel organ over the apex of the papilla has disappeared. The enamel presents itself as a thin layer lying upon a cap of dentine of considerable thickness. The cord for the permanent tooth extends down upon the side of the follicle, having separated from the temporary follicle, which is now fully enclosed by the fibrous connective-tissue follicular wall, the future cement organ.

We might multiply words in further description; suffice it to say that at birth the crowns of the central incisors are fully formed, and very soon after erupt. My studies in ovine embryos have been confined to some half dozen at birth; the crowns in these cases were fully calcified and offered excellent examples for the study of Nasmyth's membrane, which has the character of a structureless membrane covering the enamel, and which is easily made discernible by the use of dilute acids.

Sections through the face of a fœtal puppy, the facial bones of which very nearly compare with those of the human fœtus, make good studies.

I have never had the pleasure of examining equine fœtuses, and shall take the liberty of quoting from Legro and Magitot, taken from Dean's translation:

"Our observations have been made upon equine embryos of different ages. From these we have determined certain facts in relation to the various phases of follicular evolution. For the first three embryos we are indebted to the courtesy of M. Raynal, of the veterinary school at Alfort. In the youngest of these (14 weeks) the enamel organs of the central *nippers* (incisors) are already formed and the bulb has made its

appearance. For the lateral nippers the enamel organ is just beginning to show itself. These facts indicate that the evolution of the follicles of these teeth in man and other mammals appears to be synchronous. For the molars it is found that at this same epoch the bulb has appeared for all the follicles of the first dentition, as have also the first traces of the follicular wall. In a second embryo (of 27 weeks) the follicles of the central incisors are closed, while those of the first lateral incisors are just beginning to exhibit the bulbs, and those of the second lateral incisors only the enamel organ. These facts, as we see, additionally confirm the unequal development of the different incisors in this animal. In the molars the facts are analogous; the follicle of the first temporary molar is closed at this date, while the enamel organ of the second has only just made its appearance, and no trace of that of the third molar is yet visible. It is at this period, also, that the first indication of the enamel organ appears for the first permanent molar. In a third embryo, measuring 255 millimeters [10 inches], corresponding to about 28½ weeks, the follicles of the permanent incisors are closed and complete; the enamel organ is well developed. The ameloblasts of the interior bed are very large, and the external epithelial layer has already disappeared, but no trace of dentine yet appears.

"The follicles of the permanent incisors have arrived at the period when the enamel organ already caps the bulb, which is just appearing, but is not yet constricted at its base. For the temporary molars the follicles are about equally developed. They are closed and well formed, but without any appearance of the dentine cap. The organ of coronal cement is already beginning to manifest itself. From the fragments of the ruptured epithelial cord numerous buddings have been produced.

"From the fourth (an equine fœtus of 31½ weeks), owing to a very prolonged maceration in alcohol, we were prevented from deriving much advantage. We were only able to determine that the temporary follicles were fully developed and provided with caps of dentine of considerable thickness. Some fragments of the epithelial cord (long since broken, without doubt) were still remaining. The organ of coronal cement was fully developed.

"We will conclude these chronological considerations with a few notes relative to the rodents. In an embryonal guinea-pig of 2 cm. [⅘ inch] in total length, which appeared to correspond to about the middle period of gestation, the follicle was at the stage when the enamel organ, in form of a hood, covers the bulb; there was no follicular wall or dentine cap apparent.

"In another embryo of the same species of 4 cm. [1½ inches] in length, the temporary follicles were formed, and their stages of development were nearly the same. They were provided with a dentine cap covered with a thin layer of enamel. In the rabbit we discover that at birth the incisors have effected their eruption, the molars still enclosed, but already capped with thick layers of dentine and enamel. Beneath the temporary molars we observe the presence of the permanent follicles, already provided with a thin but distinctly manifest layer of dentine."

The Dental Papilla, or Pulp.—The dental pulp first makes its appearance as a slightly condensed area of tissue in juxtaposition

to the lowest portion of the developing enamel organ. Its differentiation seems to be controlled by the enamel organ. It is composed at this early stage of embryoplastic connective-tissue cells, and differs in no manner, as regards its constituent elements, from the surrounding tissue. In stained specimens it presents a somewhat darker color, due to the condensation of the cells which compose it. As we consider it in the further stages of development there is presented no characteristic which may not be seen in the surrounding embryonal connective tissue. Blood-vessels early show themselves and form numerous anastomosing loops, which give the papilla a highly vascular nature. The first indication of the office of the papilla, or pulp, as the formative organ of the dentine of the tooth, is seen in the human fœtus of four months and the porcine embryo 8 or 9 cm. in length. There is developed a layer of cells upon the apical surface of the papilla; these cells are termed *odontoblasts*. At first they are oval in form and differ very little from the ordinary connective-tissue cells which make up the principal portion of the papilla. The cells of this outer layer—*membrana eboris*, as it has been termed—gradually become elongated and send out processes which connect them with each other and with the cells of the pulp, and also extend outward toward the inner tunic of the enamel organ. These latter processes are called the dentinal fibrils. The odontoblasts become columnar in shape as the time nears for the commencement of their work as dentine-builders. As calcification progresses from the apex of the papilla new odontoblasts are developed on the sides of the papilla, until the membrana eboris forms an outer covering to the papilla, and finally the fully-developed pulp. After the dentine is completely calcified the odontoblasts again change their form into oval cells, and continue to exist as such throughout the life of the pulp. When stimulated by irritation, whether from caries or by thermal changes brought about by loss of tooth-structure, by attrition, or abrasion, the odontoblasts again assume their old functional activity and develop secondary dentine.

While these changes have been going on in the formative outer layer of the pulp the embryonal connective-tissue cells are developed into ordinary connective-tissue cells.

Between these fixed connective-tissue cells may be seen the ordinary plasma-cells noticed throughout the connective-tissue system, the pulp being no exception to the rule.

Nerves of the Pulp.

The nerves of the pulp are many and consist of medullated and non-medullated fibres, which enter the pulp through the apical foramen in various-sized bundles. Passing forward, they break up into smaller branches and form a rich plexus underneath the odontoblastic layer. Regarding their termination many speculative theories have been advanced, but little or no definite knowledge has been presented. Some assert that the finer fibres pass between the odontoblasts and either unite with the dentinal fibrils or pass with them into the dentinal tubuli. Others assert that the non-medullated fibres become united with the

stellate layer of cells, which may be seen lying underneath and connected with the odontoblastic layers.

I am unable to make any statement regarding the termination of the nerves of the pulp. I am very skeptical regarding their having any direct connection with the fibrils of the odontoblasts, and have never been able to demonstrate any such relationship. Then, again, as no nerves can be demonstrated until after calcification has progressed to a very considerable extent, the proof is conclusive that they are not an essential element to the process. I am more inclined to the view held by Magitot—that the terminal fibrils unite with the odontoblasts, and that sensation is thus transmitted by the dentinal fibrils to the terminal branches of the nerves. As there exists a very considerable degree of ignorance regarding the termination of nerves in other parts of the body where the conditions are favorable for their demonstration, I do not think it strange that we should be unable to state authoritatively just how they terminate in the pulp, seeing that the technique for their demonstration in that organ is so difficult.

The calcification of the crown being completed and the time for eruption having arrived, the process of eruption begins as the tooth makes its appearance above the gum. The root is gradually developed; the jaw is also growing rapidly and gives a firmer setting for the erupting tooth. The attachment of the tooth to the jaw is fibrous in character and surrounds the root as a membrane, being united to the root on one side by many fine prolongations, which penetrate and anastomose with the processes of the bone-cells which occupy the lacunæ of the cementum. A similar attachment exists with the alveolar wall upon the outer periphery. The development of the cement, as we have seen when discussing that subject, is accomplished in a manner identical with subperiosteal formation of bone. The formative membrane remains as the pericementum and persistent cement organ. The deposits of secondary cement known as exostoses are due to this membrane. The process of calcification is not always a continuous, harmonious effort upon the part of Nature, but is subject to many interruptions; these leave their indications upon the cement, enamel, and dentine. Interglobular spaces are seen in both dentine and enamel. These we have discussed to a considerable extent. The pits seen upon the surface of the enamel are no doubt, in some instances, caused by these spaces. The serrations seen upon the edges of newly-erupted teeth—so long known as "Hutchinson teeth"—have now pretty generally come to be attributed not altogether to congenital syphilis, but to lack of nourishment or inherited conditions which may be other than syphilitic.

Besides the markings seen upon the individual prisms, there are other lines which run transversely across the prisms. These have been called the "broken striæ of Retzius." The lines of *stratification* have a more or less decided brownish tint, but just what gives rise to the appearance I am unable to conjecture. It is held by some to be the result of an arrest in the process of calcification, each line marking such a period; others hold that it is due to the varying character of food taken by the mother during gestation, some being rich in lime salts of one kind, while another salt predominates in another kind of food. If this is the

case, then the same statement will hold true regarding the action of food-stuffs upon the teeth of the second dentition. The lines of stratification that lie nearest the dentine are longest and form a complete arch. Those that lie nearer the surface do not form an arch, but "run out" on the sides of the tooth, growing shorter as the surface near the neck of the tooth is reached. Those nearest the dentine conform more

FIG. 369.

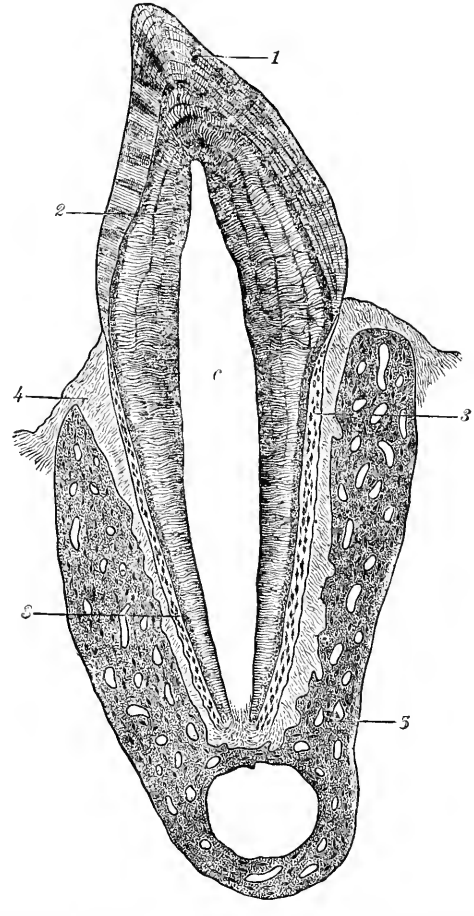

Vertical Section of a Tooth *in situ* (15 diameters): *c* is placed in the pulp-cavity, opposite the cervix or neck of the tooth; the part above is the crown, that below is the root (fang). 1, enamel with radial and concentric markings; 2, dentine with tubules and incremental lines; 3, cement or crusta petrosa, with bone-corpuscles; 4, dental periosteum; 5, bone of lower jaw.

or less in direction to the surface of the dentine, but the lines seen near the neck stand at an acute angle to the surface of the dentine.

These lines are also seen in the dentine and bear an almost parallel relation to the surface, although, as a rule, the brownish color is very generally absent.

The pigmentation of enamel of many of the rodent family, as we have

observed, is normally so, and may be said to bear a close relationship to the density of the teeth, those hardest being most deeply pigmented, and *vice versâ*. This rule holds good in human teeth as well. I am inclined to the opinion that chemical constituents of the enamel have much to do with its color. The darker teeth are much more resistive to caries than are the softer varieties.

In the accompanying figure we have combined in one section all the products of calcification we have been considering—viz. bone of jaw, cementum, dentine, and enamel.

PART IV.

GENERAL AND DENTAL PATHOLOGY.

GENERAL PATHOLOGY.

DENTAL CARIES.

PATHOLOGY OF THE DENTAL PULP.

DISEASES OF THE DENTAL PULP, AND THEIR TREATMENT.

DISEASES OF THE PERIDENTAL MEMBRANE.

ABRASION AND EROSION OF THE TEETH.

GENERAL PATHOLOGY.

By G. V. BLACK, M. D., D. D. S.

Introduction.

Health is a standard condition of the body in which all of its functions are regularly and normally performed. Any marked deviation from this is disease, no matter what the deviation may be. It is impossible to frame a strict definition of this standard of health, for the reason that it may vary within certain but rather wide limits. It is not the same in all individuals, nor always the same even in the same person. The various functions may, at different times or in different individuals, vary quite perceptibly in their degree of activity considered as a whole, so that some persons are habitually more robust than others. Again, among the individual functions some may be relatively less active than others without an impairment of health that can properly be considered a diseased condition. Some functions may be more active, others less so, and yet the departure from the normal equilibrium of functional activity may not be such as to impair so seriously the equable relation and mutual dependence of the various functions as to justify us in considering the individual unsound in health. A person may be fairly healthy and not be in the highest degree of health.

In disease there is a deviation in the performance of some one of the functions of the economy so marked that the individual is readily conscious of discomfort, or such morbid processes are in operation as will bring about a condition of disability by their continued action. In the great majority of diseased conditions the patient is at once made conscious by his sensations that something is wrong. He becomes aware of a departure from the normal state by a feeling of discomfort either general or local. There are, however, some forms of disease so insidious in their approach that the patient may not become conscious of their presence until very serious mischief has been done. Therefore the feelings of the person, while they are usually a safe guide as to the condition of the health, are not to be regarded as infallible.

A disease is an assemblage of morbid phenomena that have so often been noticed to occur contemporaneously or to follow each other in a certain order as to enable those skilled in their study to recognize them as marking a special form of deviation from health. In the study of these assemblages of symptoms, the groupings of which mark the different diseases known to us, it has long been noted that certain pathological states are common to various individual diseases. Of these the most constant are changes in the circulation of the blood and in the

blood itself, or in the relation of the blood to the tissues. Some of these changes may occur without other morbid symptoms preceding them—*i. e.* may be primary; or they may be dependent on changes that have preceded them—*i. e.* may be secondary; others are always secondary. In the study of individual diseases it is found to be cumbersome to enter into a detailed description of all these accompanying phenomena. A separate description of them is most convenient, and at the same time far more satisfactory, for in this manner we may save much repetition and avoid confusion. If the processes of inflammation be understood, it is much easier to describe the formation of an alveolar abscess, for in that case the description will not necessarily include a detailed account of the inflammatory process, but may be confined to the causes, peculiar characteristics, and results of the process in that particular situation. As this is true here, it is also true in the various other situations in which local inflammations may occur; and what is true of inflammation applies also to many other morbid phenomena. For these reasons I purpose describing under the above caption various morbid conditions that are common to many diseases, especially those of the blood and of its circulation.

The Pulse.

The pulse is produced by the action of the heart. This organ acts as a pump, taking the blood from the great veins and driving it into the arteries. With each contraction of the heart a considerable quantity of blood is projected forcibly into the aorta, and through this it is distributed to the entire arterial system. The arteries are so many elastic tubes, and the volume of blood in passing causes a sudden expansion of their walls at each impulse, which may be distinctly felt on placing the finger over any artery that lies near the surface. In the very superficial arteries the impulse may, in many instances, be seen. This movement is known as "the pulse." As the pulse is caused by the action of the heart, it becomes an index to the condition of that organ. If the heart be strong and vigorous, we will find a strong pulse; if weak, the pulse will be correspondingly so. This result is modified by the condition of the arteries. The arteries are not simply elastic tubes, but contain within their walls a circular coat of smooth muscular fibres by which their calibre may be diminished or increased, this action being governed by the vaso-motor system of nerves; which influence is continually modifying the pulse in various ways.

The importance of an accurate knowledge of the pulse becomes manifest when we consider that most diseases kill by arresting the action of the heart. In all cases of accident the condition of the pulse will give a more certain indication as to the immediate danger of the sufferer than an examination of the local injury sustained, for the reason that it affords an index to the condition of the nervous system, and tells the surgeon at once whether or not the patient has suffered any considerable depression of vital power in consequence of the injury. In disease the pulse is sure to give the signal of danger promptly and afford an early indication for treatment. It is true that in many instances the nervous

system gives way first, as is shown by muttering delirium and sleeplessness; but in these cases the anxiety of the physician arises more from the effect these conditions will ultimately have on the circulation than from danger as manifested directly through the nervous system. This delirium and inability to rest exhaust the patient, and at last the heart by its feeble pulsations signals the approach of fatal debility. In case of typhoid fever the delirium may be marked and long continued, yet so long as the action of the heart remains good, as indicated by the character of the pulse, fair hopes may be entertained that the patient will recover. It is the final effect of disease on the heart that destroys life; therefore it is hardly possible to overestimate the importance of an intimate knowledge of the varying qualities of the pulse and the indications they give of the effects of disease on the powers of life.

In the study of the varying phases of the pulse we should recognize three principal divisions of the subject—namely, 1st, frequency; 2d, quality; 3d, intermittence.

Frequency of the pulse relates solely to the succession of the pulsations. These may succeed each other with varying rapidity, giving a frequent or infrequent pulse.

Under the term *quality* we consider the character of the individual pulsations. This division of the subject is at once the most important and the most difficult. Quality is rarely dependent upon frequency or infrequency, but these conditions are usually dependent upon quality. We may express the principal qualities of the pulse as follows: The individual pulsations may be strong or weak, hard or soft, large or small, quick or slow (or short or long), compressible or incompressible, regular or irregular, dicrotous.

Intermittence is the failure of an occasional pulsation. This may occur very regularly, or it may be irregular in its occurrence. More frequently it is the failure of every third or fourth beat or pulsation.

EXAMINATION OF THE PULSE.—The pulse may be examined in any artery that lies near enough the surface to be easily felt by the finger. The radial artery at the wrist is, however, the one generally used, because it is the most convenient. Any other artery may be selected if from any cause the use of this one should be inconvenient. If the examination is only for the determination of the frequency of the pulse, any position in which the pulsations can be distinctly felt will answer the purpose; but for determining the qualities of the pulse much more care is required. In making this examination the wrist of the patient should usually be taken between the thumb and fingers in such a way that the ends of three fingers may be placed easily on the artery. The position should never be strained or uncomfortable either to the patient or the physician. The wrist of the patient should be straight or a little extended, but it should not be flexed, for in that case the artery is placed in a bad position for examination. In simply counting the pulse one finger is all that is required. In determining the qualities of the pulse one finger should first be pressed very lightly on the artery, and afterward more firmly, and the pressure varied from time to time until all of the finer qualities are ascertained. In determining the compressibility of the pulse all three fingers should be used, bringing

them to bear one after the other until the degree of compressibility is ascertained. Of this I will presently speak more definitely. The matter of the examination of the pulse demands much careful and patient study from those who would become proficient in the determination of its qualities and in the interpretation of its meanings. There are various circumstances that modify the normal pulse, some of which will be mentioned hereafter. It must always be remembered that the pulse at the wrist varies very much in volume in different individuals, on account of differences in the size of the artery, so that mere volume has not so much significance at a first examination. Also, the radial arteries of the two sides often differ in size very materially, so that one may serve to correct the other. In any case in which the examination of the radial pulse leaves the condition of the circulation in doubt, other arteries should be consulted for the more perfect correction of the readings. In the administration of anæsthetics it is very convenient to take the pulse from the temporal artery.

Frequency of the Pulse.—In health the frequency of the pulse presents wide variations. Some persons in seemingly good health have habitually a pulse of 100 beats in the minute, while in others it may fall as low as 50. These extremes of variation are, however, very rare. The greater number of persons will be found to have a pulse-rate of from 60 to 85 beats in the minute. Anything above 85 may be regarded as an abnormally frequent pulse in the adult. On the other hand, anything below 60 may be regarded as abnormally infrequent. In children the pulse is more frequent than in adults. The following statement will give a sufficiently clear idea of this:

The infant at birth	Pulse-rate 140
The child at five years	" 100
The child at ten years	" 90

The pulse of children is, of course, subject to variations similar to those of the adult. In women the pulse is a little more frequent than in men, the excess averaging about nine beats in the minute. Position also affects the pulse-rate; it is a little more frequent in the standing than in the recumbent posture. In sleep the pulse usually falls about ten beats in the minute.

There are many causes of frequency of the pulse, such as severe exercise, emotional or mental excitement, hysteria, diseases of the heart, debility, fever, reflex irritation, etc.

Usually, it is not difficult to determine the cause of frequency of the pulse. Frequency produced by violent exercise, emotion, or mental excitement passes away very soon after the cessation of the cause. Therefore, examinations made at intervals will, if the patient be kept under observation, soon clear up this point. Nervous patients usually present an acceleration of the pulse when first approached by the physician, especially if he be a stranger; and for this reason the pulse should be again taken after some time has elapsed.

In hysteria there is sometimes a pulse very frequent and continuous; the rate may be as high as 150 beats in the minute. In patients that present themselves for dental operations this cause of frequency will

sometimes give rise to some difficulty in diagnosis. A little observation of these cases will, however, almost always set the operator right. When grave illness occurs the hysteria usually disappears spontaneously.

In fevers the pulse is generally accelerated in proportion to the rise of the temperature. This is not uniform, however. In a few instances I have noted a very high temperature associated with an infrequent pulse, but this is evidently rare. From what has been said in regard to the variations of the pulse in health, it will be seen that there is no absolute pulse-temperature ratio. Any rule that may be given is subject to considerable variations. In general it may be stated that there will be an increased frequency of eight beats of the pulse to each degree of rise in the temperature. The same causes accelerate the pulse more in children than in adults, and the ratio also varies somewhat in different fevers. Thus, with a given temperature the pulse is more frequent in scarlet than in typhoid fever. A pulse which has a greater rapidity than the temperature explains indicates debility of the heart, unless it be dependent upon mental excitement, hysteria, or organic cardiac disease. It may be stated as a law of the action of the heart that what it lacks in power it endeavors to make up in frequency. A pulse that day by day becomes more frequent, the temperature remaining the same, shows progressive prostration. A pulse of 130 occurring in fever is serious, a pulse of 140 to 150 shows great danger, and a patient with a pulse-rate of 160 will almost certainly die.

Inflammations of the heart and its membranes are exceptions to this rule, for in these a very frequent pulse is of less serious import. In such cases we may find a pretty severe pericarditis with extensive effusion into the pericardial sac, with perhaps but little rise of the temperature, and a pulse of 140 to 150 per minute, and very bad in quality, without very great danger to life. Here the state of the pulse is the direct result of the condition of the heart itself, and does not reflect the condition of the vital powers, as it does when it is secondarily affected through the general prostration of the nervous system. In these forms of heart lesion, especially in endocarditis, the muscular substance of the organ is also inflamed, which disturbs its action, or its motions may be interfered with by the exuded fluid in the cavity of the pericardium. With this embarrassment the circulation becomes very poor, and from the want of oxygenation of the blood the patient may show considerable blueness of the skin; the breathing too may be proportionately hurried; yet clinical observation shows that very few die directly from this cause, it being rather a remote cause of death through injury to the valves of the heart or through a resultant fatty degeneration. Of valvular lesions I will speak again.

Qualities of the Pulse.—Under this head it is my purpose to inquire especially into the character of the individual pulsations. These depend upon the condition of the heart and arteries jointly. If the heart is weak, it cannot give strong pulsations, and, other things being equal, the pulsations will be lacking in volume and tone. The condition of the arteries, however, may modify this in several ways, so that various characters will be produced. As has been said, the calibres of the arte-

ries are directly affected by the vaso-motor system of nerves. This produces what is known as variations in "*arterial tension*." In the condition of health the blood may be said to be grasped by the muscular coats of the arteries with a certain degree of force. Therefore the blood is constantly subjected to a considerable degree of pressure, which is plainly indicated by the "spirting" when an artery is severed. Bleeding lessens the volume of the blood directly, yet it requires a considerable reduction in the volume to very materially reduce the arterial pressure. So too, conversely, the volume of the blood may be doubled by the process of transfusion before the arterial tension is materially increased. This equality of the arterial tension is maintained directly by the nervous system acting upon the muscular coats of the arteries, through which these vessels are contracted or expanded to accommodate the changing volume of the blood. This tension in disease is subject to very wide alterations, and, in the main, these alterations reflect the condition of the nervous system. It is this coincidence of conditions that gives to the qualities of the pulse their importance. In disease strength of the heart and tension of the arterial system do not always coincide. The source of their enervation is different. The heart receives its supply from the great sympathetic and from ganglia situated within itself, but principally from the pneumogastric, while the vaso-motor nerves seem to arise from the spinal cord. Hence, while in many respects the condition of the heart and arteries may coincide, they do not do so of necessity.

A *compressible pulse* is produced by relaxation of arterial tension. This condition permits the blood to flow through the arterial system and into the capillaries with less restraint, and, if the heart is strong, produces a large soft pulse that may be readily compressed. In this condition of the arteries a weak heart will produce a correspondingly small and quick pulse. The compressibility of the pulse is ascertained by placing two or more fingers on the artery and exerting more or less firm pressure until the pulsation is no longer felt under the finger nearest the distal (or terminal) end of the vessel. The degree of pressure required to do this determines the compressibility. If this is not accomplished with a reasonable pressure, the pulse is said to be incompressible and marks a strong heart with a fairly high arterial tension, and indicates a good condition of the system. If this incompressibility is extreme, as is often the case in the beginning of fevers, sedatives are called for, and especially so if the pulse is very frequent. In the reverse case, if the pulse be easily compressible, quick, and very frequent, it marks a condition of general prostration, and calls for stimulants, especially cardiac stimulants, such as digitalis. It will be noted here that these differences are based on the *qualities* of the pulse independent of its frequency. Yet it is a clinical fact that a full strong pulse never becomes so frequent as the small quick pulse, which is the indication of dangerous prostration.

A relaxed condition of the arterioles with a heart of only moderate strength will give a full round pulse that, if not closely observed, might readily be mistaken for a strong heart-beat. The ease with which it may be compressed will at once correct the error and set the physician

right as to the actual condition of his patient. In the relaxed condition of the arteries their walls present but little resistance to expansion by the blood-wave, and a very feeble contraction of the heart is sufficient to produce a tolerable dilatation of the artery, and the blood passes into the capillaries—which are probably also dilated—so easily that it produces very little resistance to compression. On the other hand, in high tension of the arterial system the artery is sometimes found to be so tense and hard that it is easily felt by the finger even in diastole of the heart, and may be traced for a considerable distance up the arm, feeling much like another tendon lying among the tendons of the wrist. In such cases, even though the heart may have a fair degree of strength, the pulse-beat is small, hard, and long—small, because the heart, though of good strength, is unable to produce much expansion of the tense, hard walls of the artery; it is hard for the same reason; and it is long because the blood cannot pass otherwise than slowly into the capillaries on account of the diminished calibre of the arterioles. This marks a condition of nervous irritation, and usually, when it is extreme, an exaltation of sensibility. When these conditions are present in connection with a weakened condition of the heart, we will find a small, frequent, and shot-like pulse, and as the decline of the patient progresses and the tension begins to give way the pulse becomes quick and thready.

The sphygmograph is an instrument for recording the pulse-waves, and much aid is obtained from it in the study of the varieties presented by them. This instrument will, however, only give us the form of the pulse-wave. It is not to be depended upon for information as to the strength of the pulsations, for this is not always shown by the height of the pulse-wave, as has already been sufficiently indicated; and even if this were not the case, it is so difficult to apply the instrument to the artery with equal regularity that there is much uncertainty in its use. The pictures of the pulse made by this instrument are, however, of the greatest benefit in gaining an accurate knowledge of the conditions of the circulation; they point out at once the differences between high and low arterial tension, and the study of them leads the observer to a better judgment of these conditions by the use of the finger. For this reason I introduce some tracings representing some of the principal varieties of pulsations. (See Fig. 370.)

In most diseases, both acute and chronic, failure of the circulation is very generally accompanied by evident signs of general prostration and failure of the powers of life. Yet by watchfulness this may be first discovered in the pulse; and it is not infrequently the case that this sign is present for some time before others manifest themselves. A patient with fever may not show any special evidences of weakness; the temperature may not be very high; he may take food fairly well; turn in bed with seeming ease, and the voice may be strong; but if the pulse is frequent and easily compressible, the patient is liable to sink at any time, and, in fact, is in a dangerous condition. It must always be remembered that there are occasional individual peculiarities which render the pulse especially sensitive, so that a little fever may accelerate it greatly without indicating danger. Such peculiarities can be learned only by acquaintance with the individual patients.

The following conditions usually give rise to high arterial tension: Affections of the nervous system; the rigor of fevers; Bright's disease of the kidneys; lead-poisoning; gout; degeneration of the vessels.

It may be useful to add here some account of the changes that may be expected in the pulse during the progress of an ordinary acute ill-

FIG. 370.

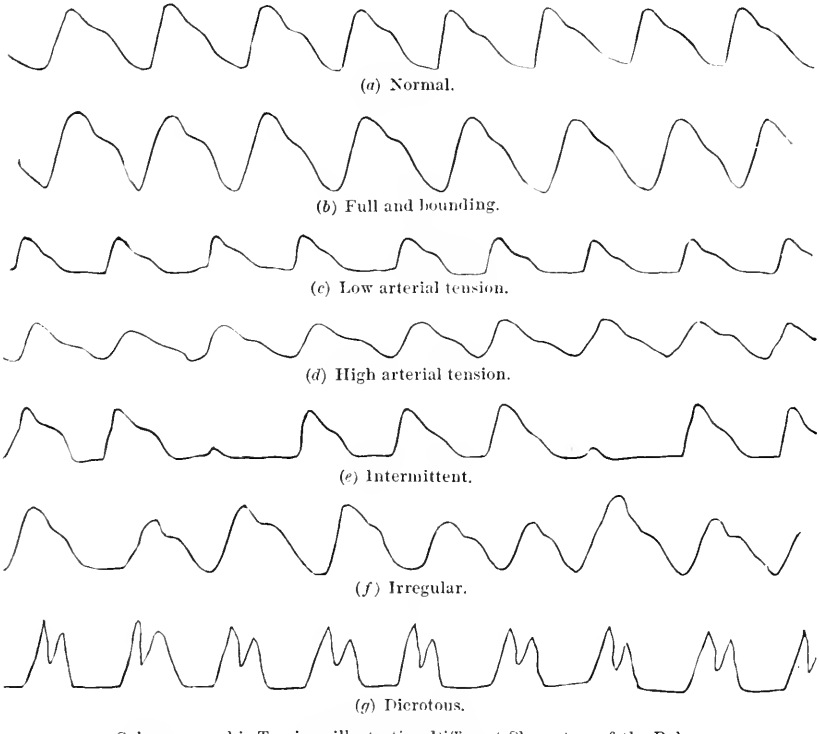

Sphygmographic Tracings illustrating Different Characters of the Pulse.

ness. These present, of course, great variations in different cases, yet there are certain changes that follow in succession so often that they may be said to form a sort of general rule. In case a person of robust constitution be attacked with acute fever, the pulse will differ in the separate stages of the progress of the affection. During the chill the arteries contract—*i. e.* high arterial tension occurs—and the pulse is frequent, small, hard, long, and incompressible (Fig. 370, *d*). During the continuance of this condition the temperature of the patient rises rapidly. With the disappearance of the chill it will be found that the pulse has changed in character in one particular: the arterial tension has relaxed. The pulse now becomes large, and is much softer, but it is still strong and incompressible, for the heart is yet vigorous, and is perhaps excited to unusual activity, giving a "full bounding pulse" (Fig. 370, *b*). This is a condition in which sedatives are of advantage, especially if this character of pulse be very marked. As the fever con-

tinues for days, and perhaps for weeks, oscillations will occur in the qualities of the pulse, especially if there is a disposition to recurring chill. But without this there will be oscillations both in the strength of the contractions of the heart and the tension of the arteries; but in the long run both these will be found to be gradually losing ground; the pulse becomes both smaller and softer, and the individual beats are comparatively short (Fig. 370, *c*). Gradually the pulse becomes very compressible, indicating extreme exhaustion of the nervous mechanism.

In case there is a disappearance of the fever, an enlargement of the pulse-beat indicates safety for the patient; provided always that this enlargement is from increased strength of the heart, and not from increased relaxation of the arteries. This is determined by the comparative compressibility of the pulse. Increased arterial relaxation is usual at the time of the subsidence of a protracted fever, but if the pulse shows a fair increase in volume at the same time, all is well. If, however, the volume of the pulse fails to increase with the arterial relaxation, fatal prostration is indicated and arterial stimulants are urgently called for. If the case approaches a fatal termination, the pulse becomes very small, quick, frequent, and generally thready. In case of recovery the pulse gradually reassumes its former vigor with the returning strength of the patient.

Irregularities of the Pulse.—The normal pulse is perfectly regular in its rhythm; that is to say, the contractions of the heart follow each other in very exact time, one beat occupying just as much time in its performance as another. In disease this regular rhythm is sometimes disturbed, in such a way that some contractions of the heart occupy more time in their performance than others, so that a long pulsation may be followed by a short one. In this way the normal rhythm is lost and the beating of the heart becomes irregular. In all such cases the force of the heart-beats is as irregular as the time. A strong pulsation will follow a weak one. These variations from the normal are known as the *irregular pulse* (Fig. 370, *f*). This must be sharply distinguished from the *intermittent* pulse. In this the regularity of the heart-beat is maintained, but occasionally a beat fails. The irregular pulse is of far more significance than the intermittent. It is most frequently seen associated with disease of the mitral valve, though it occurs sometimes in great prostration of the heart in the later stages of fevers that terminate fatally. This pulse is said to be diagnostic of mitral disease, but it must be remembered that it is not always present in this affection, there being many cases of extensive mitral lesion accompanied with a perfectly regular pulse; yet when irregularity occurs without other symptoms being present to account for it, this disorder is at least suggested. Irregularity is also frequently present in fatty degeneration of the heart. This pulse is occasionally seen, too, in connection with disorders of the nervous system, and is often a valuable diagnostic sign in meningitis, both in the acute and tubercular forms. Except in affections of the membranes of the brain, an irregular pulse is very rare in children, even in the same disorders in which it is seen in adults. Irregularity is usually cured, or at least greatly benefited, by the use of heart-stimulants.

Dicrotism.—Dicrotism results from diminished arterial tension, and is the exaggeration of the normal impulse or shock seemingly given to the blood-wave by the closure of the aortic valves. Viewing the heart as a pump, and following its motions, we will easily gain an understanding of this secondary wave which the sphygmograph shows us is present in all forms of the pulse, and which may be seen in all the charts on page 668. When the ventricle is filled the heart contracts forcibly and the blood is driven into the aorta. Then there comes the expansion of the ventricle from which the blood has just been expelled, and the tendency is for the blood to return into the heart. As a matter of fact, a portion of the blood now contained in the elastic artery does, with the cessation of the impulse, return toward the heart; and in this act the aortic valves are caught and forcibly closed, causing a sudden arrest of the returning volume of blood at a time when the artery is in active contraction upon it. These two forces, acting together at a time when there is a marked relaxation of the arterial system, cause a second expansion of the principal blood-wave, which necessarily occurs during its subsidence, as is seen in the charts. It is probably only in great arterial relaxation that marked dicrotism can occur, and it is usually associated with weakness of the heart as well. In some instances this second blood-wave is almost as high as that of the true pulsation, and may be plainly recognized with the finger, so that one not accustomed to pulse-examinations might mistake its significance and count the beats as double their real frequency. This form of pulse, however, is very rare, although it is occasionally met with in fevers.

Intermittent Pulse.—When the rhythm of the pulse is regular, with the exception that an occasional beat fails, it is said to be an *intermittent pulse*. The omissions of the beat may take place frequently or a considerable interval may occur between them (Fig. 370, *e*). They may happen regularly after every second or third beat, or even after longer periods; sometimes they are entirely irregular in their occurrence. Intermittence differs entirely from irregularity of pulse, and is of much less serious import. In some persons intermittence of the pulse is a constitutional peculiarity, lifelong in duration and unattended by evil consequences; more frequently it does not appear until middle life; in other cases its occurrence is only occasional, the attacks being induced by the use of certain articles of food or by certain extraneous conditions. Many persons who have a pulse occasionally intermittent are made very uncomfortable by it, but perhaps the greater number are unconscious of the condition. It seems in no way to endanger life, and the sphygmograph shows that in many cases the apparently omitted beat is really a very feeble pulsation not sufficiently pronounced to be felt by the finger.

The Pulse in Lesions of the Heart.—The importance which the subject of lesions of the heart has for the specialist, and particularly for those who administer anæsthetics, is such that I do not like to pass the subject without notice, although anything like a sufficient treatment of the variations of the pulse in these conditions would be beyond the scope of this article. There is not much doubt that the failure on the part of dentists to detect these conditions contributes to the number of fatalities that are continually occurring in that special field of practice. A close

study of the pulse is one of the best safeguards against these calamitous results. But a short time since a person presented herself to me asking that an anæsthetic be administered for the extraction of a tooth. Examination of the pulse at once revealed insufficiency of the aortic valves, and on inquiry it was learned that the patient had gone outside of her personal acquaintance for the express purpose of obtaining an anæsthetic which had been denied her at home. A few weeks later she suddenly died.

In aortic regurgitation from any considerable insufficiency of the valves the pulse is quite characteristic. The blood flows back into the heart during diastole, instead of being caught and held by the aortic valves, and the arteries become quickly collapsed or much more empty of blood than in other conditions. This gives a pulse of great arterial relaxation with a marked exaggeration in certain directions. The rise of the blood-wave may be the same as in the ordinary pulse, but when the height is reached it falls suddenly, almost as if the artery had collapsed. This characteristic presents various degrees as the aortic insufficiency is more or less extensive. In extreme cases the pulse seems to give the fingers a quick, sharp, shot-like blow, and disappears as suddenly as it came. These phenomena are intensified by raising the wrist high above the patient's head, so that gravitation will assist in emptying the artery.

In aortic regurgitation the pulse is often visible in certain of the superficial arteries, but this also occurs in arterial degeneration and in very high arterial tension, especially if persistent for some time. Markedly visible pulsations in the neck should always lead to further examination for the cause. In high tension the artery remains comparatively hard and firm during diastole of the heart, while in aortic regurgitation it collapses suddenly. In the former condition the pulse-beat is long, and in the latter it is short or quick. In degeneration of the arteries the vessels become tortuous, and remain distinctly hard after all the blood has been pressed out of them; and if degeneration is extensive, calcareous plates are frequently found in the arterial walls.

The pulse-beats in *aortic obstruction*, so long as the heart is otherwise perfect, are long, small, and infrequent. The reasons for this are explained by the fact of the increased difficulty of the transit of the blood through the narrowed orifice. This makes the rise of the blood-wave peculiarly slow. Hence the peculiar characters of the pulse. If this condition is accompanied by other lesions, the pulse will, of course, be modified.

Mitral disease has already been noticed.

Variations in the Blood, and in its Distribution.

Before entering upon the study of the variations that occur in the amount, quality, and distribution of the blood, it seems well to refresh the mind of the reader as to certain points in the physiology of the circulation. While studying the pulse we learned that the arterial system is under the control of the vaso-motor system of nerves in such a way as to give high and low arterial tension. This system of nerves is capa-

ble of changing the condition of the circulation of the blood in various other ways, and of accommodating a greater or less amount of blood in the vessels, either as a whole or in individual parts of the circulatory system; that is to say, the vaso-motor system does not necessarily act as a unit, operating at once on the whole vascular system, expanding or dilating it as a whole, but it may and does act locally as well, producing variations in the supply of blood to the different parts of the organism. Many of these local variations are of a purely physiological nature, such as occur in the glands during their quiescent and their active states. As an instance of this action I may refer to the well-demonstrated fact that the supply of blood to the salivary glands may be greatly increased, even by the sight of desirable food: the glands become turgid, and the outpouring of the saliva is at once begun or greatly increased. Every dentist is also well acquainted with the marked excitement of the salivary glands during the performance of painful operations within the mouth. These are examples of reflex actions of the nervous system by which impressions received by sensory nerves produce local variations in the circulation by being reflected through the vaso-motors, and may be regarded as the type of the reflex phenomena of the vaso-motor system wherever they occur. *Dilatations and contractions of the vascular system occur in response to irritation of, or impressions made upon, sensory nerves.* The impression received by the sensory nerve passes along the course of the afferent nerve to the central ganglion, and from thence is reflected back through the efferent nerve as a motor impulse. This statement holds good in both normal and abnormal conditions. In the mechanism of the nutritive functions impressions are probably received by nerves not sensory in the ordinary sense or in the sense that the impresssions they convey are perceived by the mind in any way. The result, however, is precisely the same in the one case as in the other. My meaning here may be illustrated by the results of the ligation of the arteries. When an artery conveying the blood to a certain part is ligated the immediate result is to lessen the blood-supply to that part, even though it is supplied by several other arteries. Within a very short time there is a dilatation of the other vessels leading to the part, so that the blood-supply becomes normal. This will always occur if the necessary quantity of blood can be supplied by a reasonable expansion of these vessels. How does this occur? It is not from the injury sustained and by reflection through the sensory nerves, for an injury otherwise similar, but not diminishing the blood-supply, would not produce a similar effect. Then the effect must be produced by other nerves that take cognizance of the nutritive processes and reflect the needs of the tissues for the nutritive fluid. In this manner the blood-supply to the several parts of the body is regulated in accordance with the needs of each, and is continually undergoing change, especially in the glandular organs that are periodical in their activity. These changes may be seen also in any of the tissues that may be subjected to microscopic examination in the living state. The small arteries do not remain uniformly of the same diameter, but are seen to contract and expand more or less continuously, now admitting more, now less, blood to the part. It would seem, then, that

the needs of each individual tissue are thus reflected through the vaso-motor nerves in such a manner that there is a corresponding movement of the muscular fibres of the arteries regulating the blood-supply in every part of the body, and that the nerves thus acting play the part of sensory nerves in the reflex phenomena in the fact that they convey afferent impulses that are in turn converted into efferent motor impulses. This is in accord with the general physiological law that sensory impressions or impulses travel from the distal to the central (afferent), and all motor impulses travel from the central to the distal (efferent). In the normal healthy organism the harmony of these relations is preserved. In disease this harmony is often seriously disturbed, and it is my purpose to notice some of these disturbances presently.

Pursuing the study of this system of nerves, it is definitely ascertained that paralysis of the vaso-motor nerves produces arterial relaxation. If the nerves distributed to any part are severed—as, for instance, those supplying the hinder leg of an animal—all of the arteries of that member dilate and the leg becomes surcharged with blood. This seems to show that it is the office of this system of nerves to hold, by means of the circular muscular fibres of the blood-vessels, a certain grasp or pressure on the blood they contain, and that the maintenance of this pressure—or tone, as it is sometimes called—is necessary to the proper performance of the functions of the circulation. The greatest proportionate amount of muscular fibre is in the smallest arteries, and it is these that undergo the greatest change in calibre. In this way the blood is not only more firmly grasped, but its outflow from the arteries into the capillaries is regulated.

Experiment shows that after the vaso-motor nerves of a part have been severed and the vessels have lost their tone, this will in time be recovered, the nerves in the mean time remaining asunder. From this experimental fact it is inferred that there are ganglia in the walls of the blood-vessels themselves that are capable of maintaining the tone of the circulation in the absence of the central force or influence, but that under all ordinary conditions these minor ganglia are dominated and controlled by the one central power which unifies the whole system and renders it complete. This is, in brief, a recital of the mechanism of the vaso-motor influence, and its office in the control of the circulation as at present understood. A more detailed discussion of it, while very desirable, is beyond the limit of this article.

PLETHORA.—The term *plethora* is used to designate a condition in which the total quantity of the blood is too great. The term *general hyperæmia* is also used in the same sense. This condition will occur when from any cause the blood-forming organs are unduly active, and is indicated by habitual over-fulness of the capillaries as shown in undue redness of the skin and turgescence of the venous circulation, especially that of the abdominal region known as the portal system. We may also have another condition closely akin to this, in which the bulk of the blood is not notably increased, but in which the proportion of the red corpuscles is greater than normal. The fluid portions of the blood are probably subject to greater fluctuations than are its solid constituents; and within reasonable bounds this is of compara-

tively little importance. The energies of the body, and especially its nutritive powers, upon which these energies depend, are closely connected with the corpuscular elements of the blood, especially the red corpuscles. Their importance is shown by the fact that animals bled nearly to death may be resuscitated by the injection of these corpuscles in serum. From what is known of their physiological relations, it might be inferred that the effect of an excessive quantity of blood with the full proportion of red corpuscles, or of a superabundance of the red corpuscles without an excess of fluid, would produce over-activity of the circulation and a disposition to undue excitation of the organs of the body. Such effects, in fact, constitute the phenomena of the condition of plethora. The power of the heart's action is increased; sensibility and muscular irritability are augmented; some rise in the temperature may be noted; the brain is more prone to excitement; and the whole body takes on a full and rotund outline. Pain in the head is liable to be produced by excitement or by stimulants, on account of the unusual power of the circulation; and this condition is thought to involve a liability to cerebral congestion. Febrile attacks are rendered more intense, and acute inflammations are more readily excited. It is important to discriminate between plethora and other morbid conditions. In pregnancy the fluid elements of the blood are often much increased without a true plethora. In this case there is not an abnormal increase of the red blood-globules, and other signs of the state of plethora are wanting. Abnormal fulness of the blood-vessels from some impediment to the returning veins might sometimes be mistaken for this condition.

A tendency to plethora may be inherited, or it may be acquired by over-feeding on rich foods, wines, etc., connected with diminished expenditure of blood-constituents in the nutrition of the body. This is directly favored by sedentary habits, the digestive and assimilative functions remaining active.

Experiments in the transfusion of blood in animals give us some idea of the extent to which the volume of the blood may be increased. Worm Mueller injected the defibrinated blood of dogs into other dogs, and by careful experiment found that the normal amount of blood might be increased one-half or three-fourths without materially endangering the health of the animal, and double the normal quantity would be borne without much apparent inconvenience. If, however, the quantity was increased much beyond this, perturbations of the circulation occurred, and the animal died within a day or two. It appears from these experiments that the excess of blood injected is quickly disposed of—that within three or four days there is only an excess of the globules, and at the end of two weeks these also have disappeared. From the results of these experiments it may be concluded that there is some mechanism in the body having the power of regulating the amount of the blood, but as to what this mechanism may be there is as yet no definite knowledge.

Local Hyperæmia, or Congestion.—Local hyperæmia consists in the presence of an undue amount of blood in a particular part. Two varieties, differing in mode of origin and in character, are recognized: these are

known as *active* and *passive*, or *arterial* and *venous* hyperæmia or congestion. It is essential that the distinction between these forms be well understood, for they arise under different circumstances and are of widely different significance. Local hyperæmia, when active, is dependent on the condition of the arteries, and when passive on the condition of the veins. In the active variety the arterioles of the affected region are actively dilated, admitting to the part an unusual amount of blood; this flows unobstructed through the capillaries to the veins, and there is, consequently, an increased amount of blood *passing through* the affected area, the blood being therefore more highly arterial than normal. In the passive or venous variety these conditions are exactly reversed. There is some obstruction to the passage of the blood by the *veins away* from the part; and the actual amount of blood *passing through* it is diminished, the blood itself being more highly venous than normal. In active hyperæmia there is not an unusual retention of the blood in the part, but rather the reverse; while in the passive variety there *is an unusual retention* of the blood in the part. These are the essential points of difference in the two forms of hyperæmia.

Active local hyperæmia is constantly occurring in the organism as a physiological process in all those glandular organs that have normal periods of activity and quiescence. This happens with most of the secretory organs. The salivary glands are hyperæmic while actively secreting during the process of eating. The glands of the stomach contain more blood, and much more is passing through their vessels, during the process of digestion than in the periods of rest. This is called for by the increased amount of work to be accomplished at these times, and serves as an illustration of the perfect and delicate working of the mechanism of the nutritive processes. This is not confined to the glandular structures, but extends to the other tissues as well. A muscle receives more blood in its periods of active work than in its periods of rest. Any perversion or undue and hurtful activity of any of these processes constitutes a pathological hyperæmia, and the natural inference would be that an organism so adjusted, and seemingly so liable to overstrain upon its individual parts, would be very prone to this kind of perversion of functional activity. Clinical experience shows, however, that this kind of difficulty is not so common as might be expected; yet its occurrence is of sufficient frequency to afford numerous examples. The pulp of a tooth in the normal condition transmits but one sensation, that of pain, excited by heat or cold; at each such excitation there is a transient dilatation of its arterioles. If this form of excitation be frequently repeated for a considerable period, a condition of pathological hyperæmia will be induced, during the continuance of which the least possible thermal change will produce excruciating pain. This may be considered an exaltation of a perfectly normal function to such a degree that it becomes a pathological condition. Something of the same nature is seen in the glandular system. The stomach is often teased into a state of physiological hyperæmia by the ingestion of improper food, and the brain may take on a similar condition from repeated mental excitement. These are types of hyperæmia that are liable to be followed by the inflammatory process, and

their further discussion will be taken up in connection with that subject.

It is to direct experimentation through vivisection that we are indebted for our knowledge of the phenomena of hyperæmia in its simple and uncomplicated forms, and indeed for what knowledge we possess of the vaso-motor system of nerves. There are no anatomical differences existing in the nervous system by which we can know a motor from a sensory nerve. By means of vivisection, then, the vaso-motor nerves are found to emanate from the spinal cord with the posterior or *sensory roots* of the spinal nerves, and pass to the sympathetic system by way of the *rami communicantes*. After passing some distance, up or down as the case may be, with this system, they again join the spinal nerves in communicating branches, and pass to the extremities in company with the motor and sensory nerves of these parts. When hyperæmia is produced directly by severing the vaso-motor nerves, it presents the following phenomena: The parts become somewhat swollen and reddened by the entrance of a greater amount of blood into them, and at the same time the temperature is markedly elevated. The elevation of temperature, however, in the most intense hyperæmia that can be produced never quite reaches that of the central portions of the body; indeed, it may be accounted for in all cases by the increased amount of warm blood passing through the circulatory apparatus. This process, when excited in this way—*i. e.* by interference with the vaso-motor nerves—never leads to inflammation. It seems to have relation solely to the state of the blood-vessels, which are simply widely dilated, admitting a larger quantity of blood. If the induced hyperæmia be of large extent the immediate effect is to reduce the general blood-pressure; but this is quickly regained, unless there are other reasons for depression. The blood-pressure seems to have little to do with the state of hyperæmia, for it is no greater in the hyperæmic part than elsewhere. Indeed, it may be actually less, for the reason that the blood is less hindered in its passage to the venous system, there seeming to be an expansion of the capillaries as well. Owing to the increased diffused redness this is well seen in any parts that are sufficiently transparent.

We can now understand why we have a collateral hyperæmia after the ligation of an artery. If the carotid artery be tied, the corresponding vessel of the opposite side becomes expanded. This is not to be explained by increase of the blood-pressure caused by the stoppage of the flow through the artery ligated, for such increase of pressure would be either general or in the arteries most directly connected with the ligated branch. This is not the case. The expanded artery is the one that can most directly supply the territory deprived of blood by the ligation. This is a reflex phenomenon, taking place through the action of the vaso-motor nerves in response to the needs of certain tissues for blood. This is the type of the reflex phenomena of the vaso-motor nerves in all cases of this character. Increased quantities of blood are, through these reflex actions, called to special parts or territories of the circulation under a great variety of circumstances of which some have already been indicated. If the hands are smartly struck together a few times, a reponse in the form of increased redness will be

received, a local hyperæmia having been called forth. This simple experiment will serve to illustrate a principle which seems of importance in the study of the subject, and constitutes the basis of a division of the local hyperæmias into two classes. It has already been sufficiently explained that simple hyperæmia, or local dilatation of the vascular system through reflex action, never gives rise to inflammation. It is evident, however, that in the experiment just related a continuance or increased severity of the cause might beget the inflammatory process. This is true of very many of the causes of local hyperæmia, and many of them are actually followed by inflammation; therefore they may be designated as *hyperæmias of irritation*. In this case the inflammation is not in consequence of the hyperæmia, for we have seen that inflammation does not necessarily follow the most extended dilatation of the vessels in complete paralysis of the vaso-motor nerves: the inflammation is the result of *tissue injury*.

Increase of blood-pressure is not often local, and even if it were it could not ordinarily produce hyperæmia. The vessels of the general system cannot be dilated to any considerable degree by this cause. In the lungs, however, the case is different. Here the object is the aëration of the blood, and the vessels are so arranged in the walls of the air-vesicles that the blood is spread out in very thin sheets. These capillary sheets are not composed of simple round anastomosing capillary twigs, as in the other parts of the body, but in the normal condition of expansion of the lung they are distinctly flattened. This renders them easily distensible by increase of pressure.[1] Therefore we are liable to active congestion of these organs in consequence of sudden increase of the blood-pressure from any cause.

Passive hyperæmia occurs whenever there is obstruction to the flow of blood away from the part by the veins. In this case the capillary system of the region becomes overfilled with blood, which, on account of retention or unusually slow movement, becomes highly venous in character. This is also called *passive congestion*, *venous hyperæmia*, or *congestion*. This state is seen in connection with debility or enfeeblement of the heart. In the normal state of the circulation the blood is urged forward with sufficient power to cause it to ascend from dependent parts against gravity without perceptible hindrance; but if the heart, which is the principal motive-power of the circulation, becomes weakened or disabled in its valves, the blood fails to return promptly by the veins, and stagnation is the result. The effect is the same if the veins be so obstructed that there is only a partial return of the blood from a part, the circulation being otherwise good. The congestion, except in the lungs, is probably in no case materially increased by arterial pressure, as was formerly supposed. *The dilatation of the capillaries is a reflex phenomenon occurring in response to the needs of the tissues for arterial blood.* Every individual living cell in the organism must have access to free oxygen, must absorb oxygen and exhale carbonic acid—*must breathe* in order to maintain its

[1] See monograph, "The Circulation of the Blood in the Air-vesicles of the Lungs," by G. V. Black, D. D. S., *St. Louis Med. and Surg. Journal*, and *Missouri Dental Journal*, 1878.

vitality. This is just as true of the individual elements of the organism as of the organism as a whole. We have already seen that it is the office of the vaso-motor system of nerves to regulate the supply of blood to the individual parts of the organism, and with this, of course, the supply of oxygen which the blood conveys. The dilatation of the vessels is, under these circumstances, a gasp for breath. In this thought we have the key to the otherwise singular phenomena of the so-called passive congestions. These congestions occur on interference with the circulation, whether the arterial pressure is high or low, whether the power that drives the blood be great or small. It occurs if the veins be obstructed before a powerful current of blood driven by a vigorous heart, or in the presence of a feeble current driven by a heart too weak to compel the return of the blood against the attraction of gravitation.

This kind of hyperæmia may occur under a great variety of circumstances, and is common to a great variety of diseases. It is seen first in the dependent portions of the body in all the forms of valvular disease of the heart when they have made such progress as to interfere materially with the propulsion of the blood. It is prone to occur in diseases of the kidneys, and is an element in all dropsical disorders. It is liable to occur in the later periods of any of the continued fevers that cause great enfeeblement. It is seen in anæmia and great nervous exhaustion; indeed, in any condition of great reduction of the vital powers. It occurs also from pressure on the veins preventing the return of the blood. This is often seen in the pregnant female from the pressure of the uterus on the veins. In persons not very strong it may occur in the feet from long standing, as is not unfrequently noted among dentists who stand much at the chair. It may be produced by tumors that compress or otherwise obstruct the veins—in short, by anything whatever that obstructs the free passage of the blood back to the heart.

The results of passive hyperæmia are somewhat complex. In case of the obstruction of a vein the amount of hyperæmia will obviously depend on the number of anastomosing branches in the neighborhood. If these be sufficient, the blood will be conveyed by these channels, and no hyperæmia will result. But in case these are not present in sufficient number to convey the blood, then the retained blood becomes more than usually venous in character; and in proportion as this takes place the vessels of the part are dilated, relaxed, admitting more and more blood to the part. The degree of this engorgement will depend directly on the amount of obstruction, and may vary from a slight fulness of the vessels to complete stagnation and the *complete filling of the tissue with blood*. In case there is only a moderate slowing of the blood-current, the tissue will contain more blood than the normal quantity, but the most obvious sign will be the escape of an undue proportion of the blood-serum from the vessels into the tissues, especially the cellular, areolar, or connective tissues of the part, forming what is known as *œdema*. When this escape of the fluid parts of the blood is not considerable, it is taken up by the lymphatic vessels of the part and conveyed back into the blood; but if there is more than these vessels can dispose of in this way, then the part becomes swollen and œdematous. This swelling is characteristic in that it has a doughy feel under the finger,

and remains deeply pitted for some time after the removal of the pressure. If now the obstruction is removed, the blood-current is soon re-established and the œdema disappears. The occurrence of these phenomena is the same when the obstruction is the result of any other cause, as great debility.

Diapedesis of the red blood-globules occurs when the stagnation is more considerable. This is the passage of the red blood-globules through the walls of the blood-vessels into the tissues. This occurs mainly, if not entirely, in the capillaries without the rupture of their walls. There seems to be some difference of opinion as to whether the blood-globules pass through the endothelial plates of which these walls are formed, or pass out between them at points, called stomata, where several of these plates join, as shown in the diagram (Fig. 372). The fact of the escape of the red globules is well shown in passive hyperæmia artificially produced by ligating the veins in the tongue of the frog. After a considerable amount of red blood has escaped into the tissues by this process, if the cause is removed complete recovery takes place and the arteries seem to have suffered no injury; the hemorrhage ceases at once. Arnold supposed that the so-called stomata at the corners of the endothelial plates were enlarged, as shown in the figure; but this idea seems now to have been given up in favor of the doctrine that the globules pass through the tissue without leaving any sign.

Fig. 371.

Normal Capillary, with endothelium mapped out by treatment with nitrate of silver.

Fig. 372.

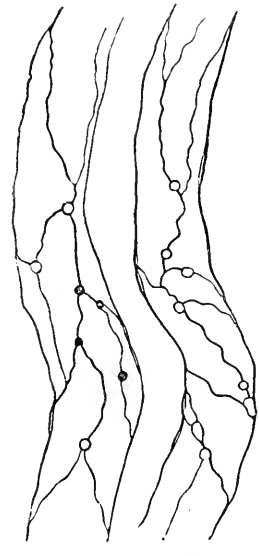

Capillaries after Passive Hyperæmia: apertures between the cells greatly enlarged—the so-called stomata (Arnold).

The nutritive power of the tissues becomes much weakened in passive hyperæmia if long continued. This gives rise to the sloughing of parts that bear the pressure of the body, and the formation of what are called bed-sores, these being prone to occur in great debility caused by long-continued fever or by other protracted illnesses that notably weaken the circulation.

Gangrene may occur in case of extreme passive hyperæmia with intense œdema. In this case the aëration of the tissues fails so completely that they die *en masse*. In this way in a case of Bright's disease of the kidneys I have seen a whole limb become gangrenous.

Thrombosis.—A thrombus is a blood-clot that forms, under a vari-

ety of circumstances, in the vessels while the blood is actively circulating. The clot which closes the divided end of an artery and that which forms after the ligation of an artery are also called thrombi. These varieties of thrombi differ quite remarkably in character. In order that we may appreciate these differences it is necessary that we study their mode of formation. The coagulation of the blood has been very closely studied (Zahn), both theoretically and in its clinical aspect. And the conditions under which the blood will coagulate seem to have been pretty clearly made out. In order that a clot may form three agents are essential—fibrin ferment, fibrinogen, and paraglobulin (Schmidt). In the presence of the fibrin ferment the two latter substances unite to form fibrin, which is the essential factor in the formation of the clot. The paraglobulin and the ferment substance are found to reside in the white blood-globules, and the fibrinogen exists in a state of solution in the blood-plasma. In order that a blood-clot may form, it is necessary that white blood-globules be disintegrated and the ferment substance and paraglobulin set free. Therefore as long as the white corpuscles are circulating and remain alive the blood will continue fluid. In order to maintain the life of the white blood-corpuscles it is necessary that they should not be exposed to contact with dead matter nor with inflamed or injured tissue. It has been demonstrated by experiment (Lister) that the blood may be kept fluid in the *still condition* for a long time if it is in contact with living tissue. If within the living body an artery is carefully ligated (so as not to injure its internal coat) at two points in such a manner as to include a portion filled with blood, this will remain fluid for twelve or fifteen days. If the section thus ligated be cut out, the blood will, under favorable circumstances, remain fluid for several days. These experiments show clearly that the coagulation of blood is not on account of the arrest of motion, as was once supposed. When we examine critically all the conditions under which the coagulation of the blood takes place, it will be found that the cardinal points are these: Contact with dead matter, such as the walls of the vessel in which it is drawn or any inanimate object—(the more rough and uneven the surface of contact the quicker will be the coagulation), contact with *changed living tissue*, whether this change be the result of inflammation or injury, such as cutting, bruising, or tearing the flesh. Under any of these circumstances some of the white globules of the blood become so far disintegrated as to give up the paraglobulin and fibrin ferment, and in the presence of the latter the former at once unites with the fibrinogen of the blood-plasma for the formation of the semi-solid fibres of fibrin by which the blood is held together in a gelatinous mass.

In hemorrhage occurring from the division of an artery the closure of the severed extremity by thrombus is favored by the flow of the blood over the injured tissue, and the greater the amount of injured tissue with which the blood may come in contact in proportion to the calibre of the vessel, the quicker it will be closed. Therefore, an artery severed by a blunt instrument that causes much bruising of the tissues is much more readily closed by the clotting of the blood than if severed by a very sharp instrument. Nature has also provided means of increas-

ing the contact of the escaping blood with the injured tissue. When an artery is severed, the inner coat contracts within the outer walls—*i. e.* becomes the shorter—and is pulled backward into the outer wall of the vessel, and at the same time the cut end is narrowed (Fig. 373). In this way the flowing blood is brought into contact with the greatest possible surface of injured tissue. The formation of the thrombus is begun by the adhesion of the white blood-globules to the injured surface. These adhere one after another, and are held fast by the formation of a little fibrin; others adhere, and more fibrin is formed until the end of the vessel is completely filled. In this process the red globules take no part, and if the thrombus is very slowly formed, very few of them will be included in the clot, and it will be white or gray in color. In this position, however, a thrombus is usually red from the entanglement of red globules. After the artery is closed the coagulation of the blood in the artery proceeds until the first lateral branch is reached. This in time becomes organized, or rather is absorbed, and its place filled with new tissue, and the vessel is permanently closed (Figs. 374 and 375).

FIG. 373.

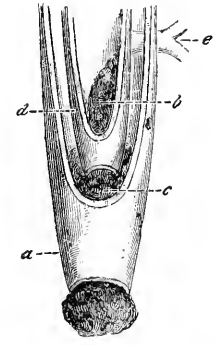

Natural Hæmostasis. The divided ends of the artery (*d*) retract within the sheath (*a*), and by contracting diminish the calibre of the canal. Blood coagulates in the sheath (*a*) around the orifice of the divided vessel, and in the artery itself (*b*) up to the first branch (*c*); and lastly, plastic lymph is poured out from the divided coats of the vessel, and by its organization the permanent closure takes place (Jones).

In the ligation of arteries the blood is caused to clot by *injury to the internal coat.* In this case the thrombus is always red, for it contains all the blood-constituents. If the clot should not, before the ligature comes away, become sufficiently firm to resist the blood-pressure, secondary hemorrhage will occur.

Thrombi form in the blood-vessels under various circumstances. This may be well studied in the mesentery of the frog. When this is exposed for microscopic study, a vessel of some size may be in some way injured—by pricking with a needle or placing some irritant in contact with it—and the progress of the building of the thrombus watched. As the blood passes over the injured point a few white globules adhere to it. Upon these others are slowly deposited in successive layers, and the little lump is seen to grow larger and larger as the successive layers are deposited. This may continue steadily until the vessel is completely occluded and the passage of the blood stopped; or after a little clump is formed it may be detached by some movement or by the force of the passing blood-current and float away. A second clump will then be deposited in the same manner as the first. During the growth of these the outline of the white blood-globules is usually lost. They seem, as the rule, to become fused with the forming fibrin into one mass, though sometimes a few continue to show their outlines. It does not seem that the destruction of very many white blood-globules is necessary to produce a considerable clot. The liberated material *acts as a ferment,* and according to the law of the action of ferments a very little may produce

a great result by causing changes in other substances without itself entering into the combination.

Thrombi formed in the manner just stated are always white or nearly so. This is always the case when they are formed slowly in the blood-stream, from the fact that very few red blood-globules or none become entangled in the forming mass. This circumstance enables the pathologist to determine whether or not a given blood-clot has been formed

FIG. 374.

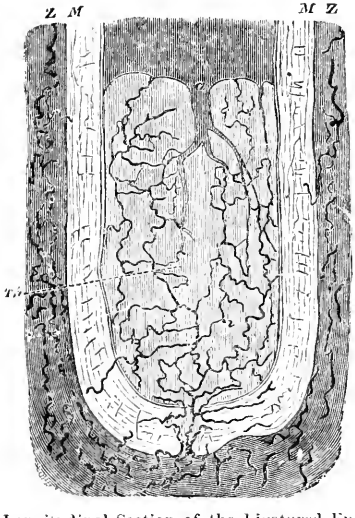

Longitudinal Section of the Ligatured End of the Crural Artery of a Dog, fifty days after the application of the ligature, showing the newly-formed vessels in the thrombus and their communications with the vasa vasorum: *Th*, thrombus; *M*, muscular coat; *Z*, external coat (× 20, O. Weber).

FIG. 375.

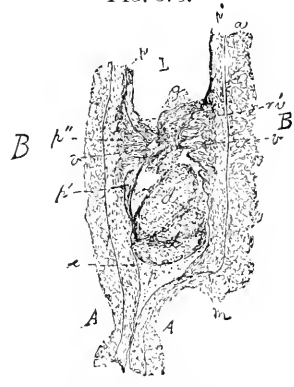

A Thrombus, ten days old, after modified ligation. Longitudinal cut. Low power. After ligature at *A*, the artery was seized and compressed at *B* between the arms of a pair of forceps. *a*, adventitia; *m*, media; *c*, cellular tissue; *p*, cellular formation at bottom of clot, non-organized, and apparently not larger than such an accumulation usually is at five days; it consists mainly of cells similar to white blood-corpuscles; only a few epithelioid cells are scattered through it, and no granulations springing from it penetrate the crevices of the laminated clot (*d*) immediately above; at *p'*, *p''* there is an ingrowth of the intima and inner layers of the media. At *L*, above the point of compression, a blood-clot like that at *d* rested, but handling caused its displacement.

by gradual growth on account of some injury, inflammatory or otherwise, to the vessels, or from stagnation of the blood. This character of clot can be closely imitated artificially by rapidly whipping freshly-drawn blood with a bundle of small twigs, to which the forming fibrin will adhere, leaving the red globules in the blood-serum. By working quickly and carefully the clot adhering to the twigs will be nearly white, and all the fibrin can in this way be taken from the blood. This is the mode of preparing defibrinated blood for transfusion.

But one cause is known for the formation of thrombi in the living vessels, and this is some actual injury to their walls. This injury may be effected in a multitude of ways. On account of pressure or extreme weakness of the heart the blood may stagnate in the vessels until the endothelium becomes seriously impaired. Arteritis may affect them, or,

in fact, any of the diseases to which the arteries are liable. It may result directly from injury in wounds, pricking with sharp instruments as the result of accident or in using the hypodermic needle, etc.

Thrombi often form in the debilitated heart. This is supposed to occur when the cavities of the heart are not completely emptied of blood at each contraction. Under such circumstances a portion of blood will remain in the apex of the ventricle and stagnate, or it may lodge behind the valves or in other nooks. The clotting, once begun, may continue until the motions of the heart are so interfered with as to cause death. A diseased and roughened condition of the valves of the heart is another cause of thrombus.

The organization of thrombi will be considered under the head of *Processes of Repair.*

Embolism.—Embolism is usually a result of thrombosis. A part or the whole of a thrombus becomes detached from its place of formation and floats away with the blood-stream. If this be in the arteries, it must pass into a smaller artery, and finally it will come to a point where the calibre of the vessel is too narrow to allow it to pass, and the plugging of the artery and the stoppage of the flow of blood through it are the result. An embolus is, however, not necessarily a detached thrombus. It may be any conceivable thing that can gain entrance to the vessels and travel with the blood, as detached bits of tumor, chalky deposits from the valves, oil-globules, or air that may have gained entrance to the vessels, or other foreign substance. If we know where an embolus starts, we can have some idea where it will lodge. If it be in an artery, it is likely to follow the most direct line until a point is found too small for it to pass; if it is in the portal system, it must lodge in the liver; if it is in the veins, it must lodge in the lungs after passing the heart; if it is in the heart, it may go to any part of the general system, but the manner in which the carotids are given off from the arch of the aorta frequently causes emboli to be sent to the brain.

The results of embolism vary greatly with the position of the lodgment of the embolus. In case there are many arteries with free anastomoses, the circulation is restored almost at once, and no harm results, for it is only the capillary circulation that is important to the tissues. The most that can occur in this case will be the formation of an abscess, and this is not likely to result unless the embolus contains septic material. Generally the embolic clot becomes organized, or, more strictly, is partially absorbed, and this part of the artery is reduced to a solid cord.

Hemorrhagic infarction results from embolism of arteries that have no anastomosing connections. These are sometimes called *end-arteries.* This arrangement of the arteries occurs in several of the organs of the body, as the brain, the kidneys, the lungs, the spleen, *the pulps of the single-rooted teeth,* and in various other positions. Infarction is very important on account of the serious, and often fatal, damage done to important organs. Such arteries supply blood to a definite piece of tissue, and when this supply is cut off by an embolus death of that tissue is the inevitable consequence. The lateral branches of the principal arteries of the tongue of the frog are without anastomosing branches,

and Cohnheim has employed them to study this subject experimentally (Fig. 376). He introduced little pellets of blackened wax into the

FIG. 376.

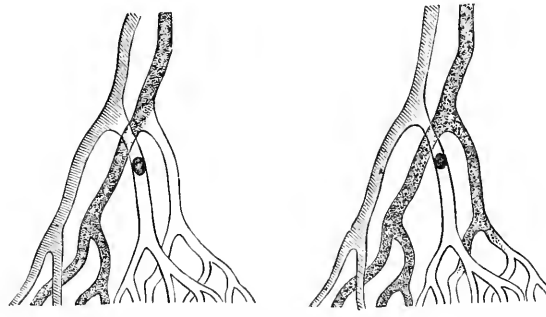

Diagram of the conditions following Embolism of an End-artery. In the figure to the left the state of anæmia after the embolism is shown; in the other figure the regurgitant current from the vein is indicated (after Cohnheim).

division of the aorta that communicates with the tongue, and succeeded in obstructing these particular arteries. When thus obstructed the effect was to stop the movement of the blood in the area supplied by the branch in arteries, capillaries, and veins. This state did not remain long, for soon there was observed a backward movement of the blood through the vein into the capillaries of the district, which went on slowly until these were distended with blood. But the movement did not cease with the wide distension of the vessels, for soon a remarkable phenomenon became apparent—the rapid diapedesis of the red globules of the blood into the tissues. This went on until the whole area was completely engorged with blood. How can this be explained? It is said that the diapedesis is occasioned by the impairment of the capillary walls from deprivation of arterial blood, but we have already seen, while studying active hyperæmia, that diapedesis also occurs from the obstruction of the veins, and that if the obstruction be removed within a reasonable time, the capillary walls prove not to be impaired. It seems to me clear that this is not the true explanation of this phenomenon. Neither are the vessels expanded by the pressure of the blood, for, as we have seen, the blood-pressure is reduced to the lowest possible standard by the closure of the artery. The expansion of the vessels in this, as in other instances that I have heretofore noticed, is to be explained from the standpoint of physiology rather than from that of dynamics. These tissues are deprived of aërated blood, and the expansion of the vessels is a reflex phenomenon denoting an effort to supply this need. The needs of the tissues are supplied, normally, by the absorption of certain constituents of the blood; and here we find this so exaggerated that the *whole blood is absorbed in the effort to obtain aëration*. Therefore, the tissues of the region become completely engorged with blood, which, as the impairment of tissue proceeds, coagulates, and the coagulum encloses the tissue in its meshes. That there occurs final deterioration of the endothelium of the vessels is a matter of course, but this is not the cause of the diapedesis, but a result of deprivation of aërated blood.

An infarct will have the form of the bit of tissue supplied by the artery plugged by the embolus, and is usually cone-shaped, with the apex at the point where the embolus has lodged and the base at the surface of the organ in which it has occurred (Fig. 377). In recent infarcts the appearance is that of a blood-clot in the tissues. In time this shrinks and the fluid portions disappear by absorption. Surrounding it there is a zone of hyperæmic tissue, and usually some projection of young granulation-cells into its mass. Under favorable circumstances the whole infarct will be absorbed and its place supplied by fibrous tissue, as is generally the case in the spleen. But very often the infarct becomes of a pale-yellow or whitish color, from the loss of the coloring matter of the blood, and finally undergoes fatty degeneration, and is absorbed or remains as a kind of cyst. The position of the infarction has to do with the evils connected with it. In the brain the infarct is more prone to softening than in other regions, apparently on account of the very small amount of the connective-tissue element, and its presence there is of much graver moment, owing to the importance of the tissue destroyed. In other positions the injury is less serious, the degree depending on the amount of tissue included. In the retina it may cause the loss of sight; in the kidney, the loss of the gland-tissue involved. If the embolus lodge in the artery of a tooth-pulp at the apical foramen, the pulp will be lost; and, as in this position the fluids are not readily absorbed, alveolar abscess is sooner or later likely to occur. It must be remembered that the plugging of such minute arteries as this may be by oil-globules.

FIG. 377.

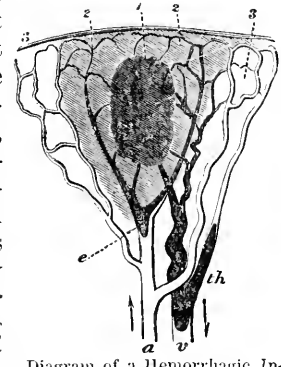

Diagram of a Hemorrhagic Infarct: *a*, artery obliterated by an embolus (*e*); *v*, vein filled with a secondary thrombus (*th*); 1, centre of infarct which is becoming disintegrated; 2, area of extravasation; 3, area of collateral hyperæmia (O. Weber).

HEMORRHAGE.—Hemorrhage may occur in two distinct forms—by rupture of the vessels and by diapedesis. The blood may pass outside of the body, may escape into the cavities of the body, or it may make place for itself in the tissues by forcing them asunder, or it may infiltrate the tissues. Hemorrhage by rupture may occur from any of the vessels, great or small; that by diapedesis occurs only in the capillaries. The latter has already been considered in some of its phases. Hemorrhage from rupture is generally traumatic in origin, as in wounds made by cutting or tearing the flesh. It may also occur from sloughing or by the perforation of the vessels by ulceration. Disease of the vessel may so weaken the walls that they give way to the blood-pressure, as in aneurism, atheroma, etc. There are some persons whose blood-vessels are so constituted that they are unusually easy of rupture. This is called the hemorrhagic diathesis. It is sometimes inherited. Aside from these causes there are some diseases, as scurvy, the anæmias, and the septic fevers, in which a disposition to hemorrhage is induced either by alterations of the constitution of the blood or of the tissues. In some of the diseases named, and also in purpura hæmorrhagica, blood is

extravasated in small spots of tissue-ecchymoses—often freely distributed over the body. It is probable that in some of these cases the bleeding is by diapedesis.

Hemorrhage is stopped naturally by the coagulation of the blood. This was described under the head of Thrombosis (p. 679). In some conditions of the blood there seems to be a partial failure of coagulation, and in this case the stoppage of the bleeding becomes more difficult. This is often noticed in the hemorrhagic diathesis, and occurs in persons who little by little have lost a large amount of blood, until they have become anæmic. It is also seen in the spontaneous anæmias and in exhaustion from fevers. Under ordinary circumstances the loss of blood, by reducing the power of the circulation, assists in the arrest of hemorrhage, but this occurs only before the blood has become changed by the loss of a large proportion of its red blood-globules; these are always lost in greater proportion than the other constituents of the blood, and are not replaced with the same facility. This accounts for the change in the constitution of the blood in repeated hemorrhages. In all of these cases the effort should be to restore the normal condition of the blood by appropriate treatment. This applies to bleeding by diapedesis as well.

The absorption of blood that has escaped into the tissues is a matter of much interest, and presents some singular phenomena. When the fluid portions of the blood alone escape, forming œdema, the serum is, if not in too great quantity, disposed of by the lymphatic vessels. Some of the corpuscular elements may also be carried off in the same way; but where a considerable number of the red globules are distributed in the tissues they cannot be so removed, and are disposed of, many of them at least, by the wandering cells. These cells accomplish this by taking them into themselves as the amœba takes its food. Once within the wandering cells, they soon disappear (Fig. 378). It is not

FIG. 378.

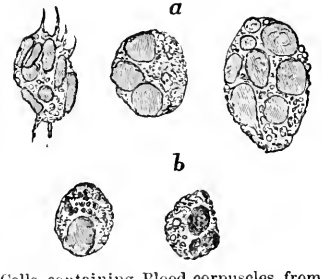

Cells containing Blood-corpuscles from the neighborhood of a Hemorrhage: *a*, with fresh corpuscles; *b*, with dark granules from disintegration of red corpuscles.

FIG. 379.

Crystals of Hæmatoidin from an Old Hemorrhage in the Brain: their color is reddish-brown (× 350).

unusual to see several red globules within one wandering cell, as shown in the figure. It is of course impossible that the multitude of red globules in large extravasations should be disposed of in this way. These lose their fluid portions by absorption, and the globules remain. Their coloring matter is slowly dissolved out, and often stains the tissues of the neigh-

borhood. This staining is of various colors, according to the concentration of the coloring matter, from a blue-black to a light-yellow tinge.

The dissolved coloring matter is finally all absorbed, and the tissues present their usual appearance. In case of considerable extravasations forming clots the coloring matter is often deposited in the crystalline form (Figs. 379 and 380). I have obtained some beautiful crystallizations by the section of clots occurring a short time before death, and also from uterine clots. (See Fig. 381.)

FIG. 380.

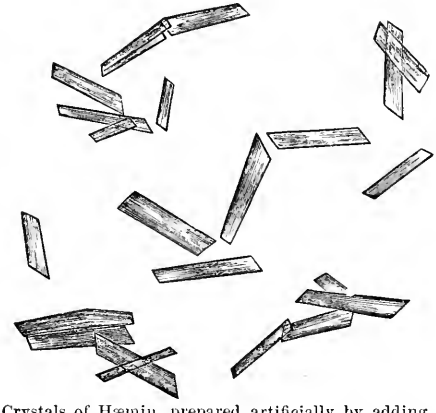

Crystals of Hæmin, prepared artificially by adding glacial acetic acid to a drop of blood, heating and evaporating to dryness (× 350).

ANÆMIA.—The term *anæmia* in its strict sense means *without blood*, but it is used to designate those conditions in which the blood is deficient in quantity or in quality. Deficiency in quantity may result directly from hemorrhage, and is then called acute traumatic anæmia. Otherwise than in this way a true deficiency in the quantity of the blood, without other deviations from the normal standard, is rarely seen. By active hemorrhage the arterial tension is rapidly reduced, and general debility is induced in proportion to the loss of blood. The bulk of the blood, however, is quickly made up by the absorption of the fluids from the alimentary

FIG. 381.

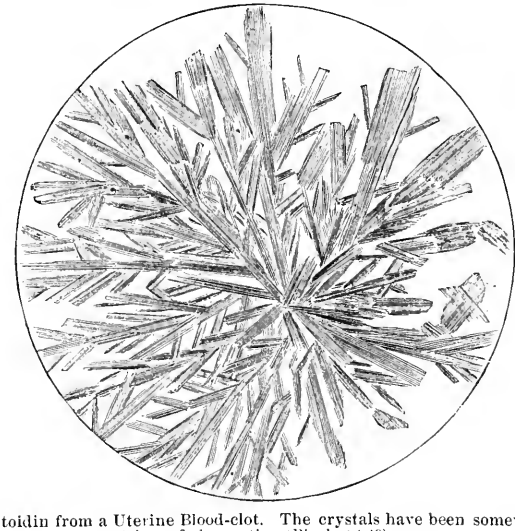

Crystals of Hæmatoidin from a Uterine Blood-clot. The crystals have been somewhat broken in the cutting of the section (Black, × 40).

canal and the tissues into the circulation, and the normal tension is thus restored. Besides this, a notable loss of blood may occur, and the tension be kept up by the contraction of the arterial walls under the influence of the vaso-motor nerves. In these two ways the arterial system accommodates itself to a considerable loss of blood without the occurrence of notable anæmia; and it is only by the loss of large quantities of blood that serious damage to the vital powers results. In case the loss of blood occurs repeatedly, a qualitative damage to that fluid results without notably diminishing its bulk, for the plasma is replaced much more readily than the corpuscular elements. The white blood-globules move slowly along the walls of the vessels, and are much inclined to cling to them, and are not lost in hemorrhage in the same proportion as the red globules, which usually occupy the central portion of the blood-stream. Now, the red globules when lost are regenerated very slowly; therefore, when hemorrhages occur frequently the effect on the quality of the blood, if the loss is considerable in the aggregate, may become serious. This constitutes what is known as *hydræmia*, or watery blood. The nutritive value of the blood depends on the proportion of its red globules, and if these are deficient a condition of debility results, no matter what the bulk of the circulating fluid.

Spontaneous anæmia is a term used to designate a condition of deficiency of the red corpuscles occurring without any direct loss of blood. The normal proportion of the red globules to the whole blood is estimated at about 13 per cent. In spontaneous anæmia it may sink as low as 6 or even 4 per cent. In this condition there is always a notable reduction of the vital powers, and such patients usually exhibit marked debility. This condition may be induced by a great variety of circumstances, such as exhaustion from overwork of any kind, and especially by continuous mental application. It is also induced by a variety of forms of chronic illness and by protracted fevers.

Essential or pernicious anæmia may come on without any perceivable connection with other ailment of any kind, and is prone to a fatal termination. Its characteristic is a marked reduction in the number of red corpuscles. Some authorities describe a red globule inferior in size to the normal red one as characteristic of this disease (Fig. 382). So far as I am able to determine, it seems probable that this is not an abnormal form of red globule, but a white globule that has become stained with the coloring matter of the red. Cornil and Ranvier state that they have not been able to find these abnormal corpuscles, but find that "many white corpuscles, especially the largest, contain very small amber-colored spherical granules grouped around the nuclei. This can be explained by the destruction of the red corpuscles, particles

FIG. 382.

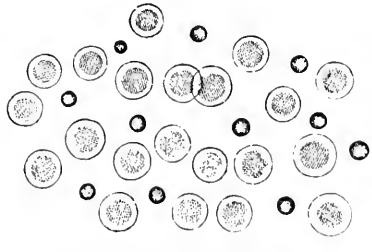

Blood in Pernicious Anæmia: the larger bodies are the normal red corpuscles; the smaller are the round, more deeply colored ones usually found—so-called microcytes (Eichhorst).

of which have been absorbed by the white corpuscles." It is known that in health there is a continuous consumption of the red corpuscles of the blood, and it is probable that the essential phenomenon of this disease is an exaggeration of this function, and that the consumption exceeds the powers of regeneration. This consumption is supposed to take place in the liver, but it is also known that under certain circumstances the red globules are destroyed by the white, and that these may become temporarily stained. This leads to the supposition that these corpuscles may be of that character. The place of the formation of the red blood-corpuscles is not certainly known. This function has been attributed to the spleen, to the lymphatic glands, and to the marrow of the bones. The bone-marrow seems to have been found in a diseased state in many cases of anæmia, and under these circumstances cells very like the red blood-globules have been discovered (Fig. 383).

FIG. 383.

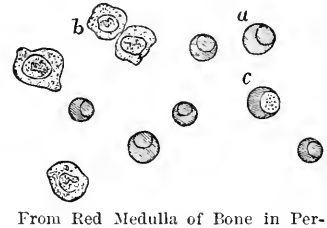

From Red Medulla of Bone in Pernicious Anæmia: *a*, nucleated red corpuscles; *c*, a red corpuscle with granular nucleus; *b*, large nucleated cells, forming the bulk of the altered marrow (× 350).

Chlorosis is a form of anæmia seen in females at or about the age of puberty. It is supposed to be due to a deficiency in the formation of the red blood-corpuscles, and is very amenable to treatment with the preparation of iron. With this condition there is often associated some deficiency in the vascular system, such as narrowness of the aorta or some of the important blood-vessels. Contrary to what is usually seen in the other forms of anæmia, the body seems well nourished in chlorosis, but there is the same defect in the proportion of the red blood-globules. The flesh, however, is usually soft and flabby, and a disposition to œdema is manifest in the extremities. Chlorotic patients are more than usually liable to nervous disorders.

In all these forms of anæmia the diminution of the coloring matter of the blood appears to be the prime factor, and cases of marked character now and then occur in which this deficiency is very marked, while the number of the corpuscles remains normal or nearly so. The bulk of the blood is not necessarily diminished, but may be more watery than normal, and may not clot so readily. This often gives rise to difficulty in controlling hemorrhage. Secondary changes in the tissues, especially in the form of fatty degenerations, may occur in any of the forms of anæmia from the imperfect nutrition of the tissues. Inflammatory processes are languidly performed, and are more prone to run a chronic course. The treatment of alveolar abscess, diseased pulps of teeth, or any of the inflammatory diseases of the mouth or other parts is rendered more uncertain and difficult.

Local anœmia is the diminution of the blood of a part. It is probable that this occurs in various organs as a feature of the neuroses or as perversions of innervation. There seems to be such a thing as a tonic spasm of the arteries of a part or organ, during the continuance of which the amount of blood admitted to it is materially lessened.

Some neuralgic affections are thought to be of this character. Anæmia in all of its forms is especially liable to give rise to, and, seemingly, not unfrequently constitutes the basis of, the more obstinate forms of neuralgic affections.

Inflammation.

The classic signs of inflammation are *redness, heat, pain,* and *swelling.* These describe with sufficient accuracy the more obvious superficial characteristics ordinarily presented by the inflammatory process, but convey very little idea of the changes that are in progress. These processes have for the most part been learned in comparatively recent times by direct microscopic observation of inflammations artificially produced for this special purpose. In the study of this process sharply divergent views have been developed by certain prominent pathologists, each of whom has his followers; so that the student in his first attempts to follow the explanations given in the different works that have recently appeared is very liable to find himself in a confused labyrinth of conflicting detail, from which he will emerge with anything but clearly-formed views of the phenomena. For this reason I think it best occasionally, in the course of my descriptions of these processes, to make brief citations of these differences as I understand them, with the view of assisting younger readers in clearing up this seeming confusion. Otherwise than this I shall adhere to the plan I have thus far followed of making but few references to the opinions of others.

For the microscopic study of the phenomena of inflammation any of the membranes that are sufficiently thin and transparent to be readily observed during the life of the animal may be employed, as the web of the frog's foot, the frog's tongue, the omentum, or the mesentery. When such a membrane is prepared for examination and placed on the stage of the microscope, an irritant is applied and the subsequent changes observed. The changes induced in this process may also be studied by the more ordinary plans of microscopic research.

When the tongue, mesentery, or web of the foot of the frog is brought under observation, the blood in the vessels is seen to be circulating in the normal manner. Upon the application of an irritant the first notable change is a contraction of the vessels. This is so slight, and endures for so short a time, that some observers have even denied its occurrence. Very soon the vessels begin to dilate, and the flow of the blood through the part is notably increased. The streams are larger and the blood flows more swiftly. This is now, to all appearance, a simple hyperæmia, the *hyperæmia of irritation,* that invariably precedes the appearance of inflammation. After this has persisted for a time it will be noticed that the blood-streams are slowing their movement. Where before the individual corpuscles could with difficulty be made out on account of their rapid movement, they are now readily distinguishable. The red globules for the most part occupy the centre of the current, while the white are seen to be creeping along the margins, stopping and clinging to the vessel's wall, then letting go and moving on, to stop and cling fast again. This is repeated continuously by the white globules

that are seen passing the field of view. Finally, some are seen to become more decidedly adherent to the wall, as if fused with it, and others to be likewise adherent in the neighborhood. As this progresses they begin to be piled the one on the other; and all this time the blood-current is becoming slower and slower. Some of the white globules that have seemed to hold fast are seen to loosen, and after swaying for a time float away with the current. In all this movement it will be noticed that the globules appear to be developing an adhesiveness that they did not manifest at the beginning of the observation. Those that gradually break away and move off from the focus of the irritation—which now can only be seen in this disposition to stickiness—seem to lose this property as they recede from the field. This will give the impression that it is the *vessel's wall* in which this stickiness is developed, and not in the blood-globule. In the focus of this action the adhesion of the white globules will go on until the entire inner wall of the vessel is completely covered as with a pavement, and they may be piled one upon the other. This adhesion of the globules is the first step in the process that can be considered as significant of inflammation. It may indeed be inferred that the hyperæmia is that of irritation, and will lead to inflammation; but there is nothing in the microscopic appearance of the tissues or of the blood in the vessels by which the difference can be noted until the adhesion of the white globules has become manifest. With the adhesion of the white globules, as it advances, there is also seen a disposition to the adhesion of the red. These at first occupied the centre of the blood-streams, but as the adhesion of the white globules progresses the channels become narrowed, the motion of the

FIG. 384.

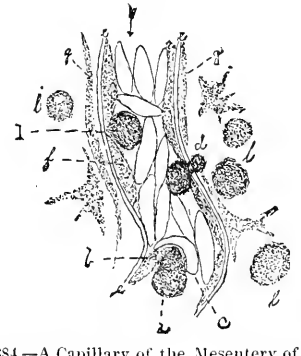

FIG. 385.

FIG. 384.—A Capillary of the Mesentery of a Frog nine hours inflamed, showing detachment of an endothelial cell, which is finally carried off by the blood-current (high-power): *e*, capillary walls; *l*, white blood-corpuscles or leucocytes external to the walls; *f*, capillary endothelia, granular and swollen with projecting bellies; *g*, cells of adventitia, also swollen and granular; *a*, *d*, *i*, colorless corpuscles adherent to the walls; *d* is rather firmly bound to the wall by means of a bud penetrating the latter; *i*, a corpuscle adherent to the point of union of two adjacent endothelial cells; *a*, a white corpuscle adhering tightly to the upper end of an endothelial cell, *b*, which is partly pried out from its bed by the action of the red discs. The arrow indicates the direction of the current (Shakespeare).

FIG. 385.—A White Blood-corpuscle, or Leucocyte, from human blood, showing amœboid movement (Klein).

blood is slow, and the red globules turn aside also and begin to adhere to the walls with the white. In this way the channels are progressively

filled up with the mass of globules, and the motion of the blood is finally stopped altogether. This is the condition of *stasis* (Fig. 384).

Before this point has been reached another phenomenon will have become manifest—*the diapedesis of the white blood-globules* from the vessels into the surrounding tissues. Under favorable circumstances some of the adherent globules will be seen to have sent a prolongation through the wall of the vessel (Fig. 384, *d*), and gradually the whole of the globule follows it, and is on the other side among the tissues. Here its amœboid movements become more apparent, and it is seen to move among the tissues surrounding it (Fig. 385).[1] This diapedesis now goes on rapidly, a few red globules mingling with the white, until the whole of the tissue is thickly studded with them, especially in the neighborhood of the vessels. In the mean time, the fluid constituents of the blood have also escaped from the vessels to so great an extent that the tissue has become swollen and clouded to such a degree that the further following of the phenomena is seriously interfered with, so that the changes that finally occur in the tissue itself cannot be followed

FIG. 386.

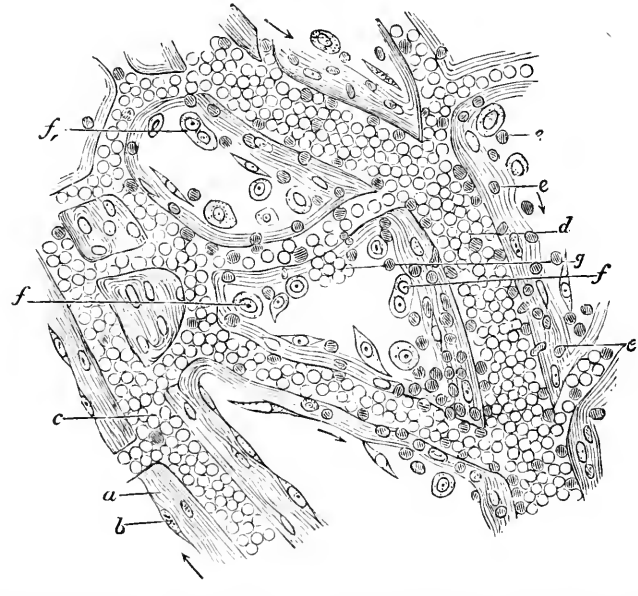

Inflamed Human Omentum. The phenomena of inflammation are seen in the veins and capillaries, the condition being normal at the artery (*c*), where *b* represents endothelium covering the trabecula (*a*). In the vein (*d*) there are many white corpuscles along the wall: some of these are emigrating (*e*); *f*, desquamated endothelium; *g*, extravasated red corpuscles (Ziegler).

with the accuracy that scientific precision demands. Fig. 386 gives an idea of the appearances presented in inflammation of the omentum.

We may now review the processes we have thus far observed, with

[1] On account of the variety of positions in which this cell is seen, and its peculiar changes of form, it has been designated by a variety of names. In the blood it is called the white blood-corpuscle or leucocyte; in the tissues outside of the blood-vessels it is variously designated as the leucocyte, amœboid cell, or wandering cell. These terms therefore apply to the same cell-forms.

the view of a better understanding of their meaning. The hyperæmia is undoubtedly of the same nature as hyperæmia in general, and in itself presents no phenomenon other than that of the most simple dilatation of the blood-vessels. As we have seen (p. 692), this process does not lead to inflammation, yet here we find it forming a part of the inflammatory condition. This happens from the fact that in this case there is an additional element not present in simple local hyperæmia. This additional element is *tissue injury*. The hyperæmia can be in no way the cause of the inflammation, but the same causes that produce inflammation induce hyperæmia as one of its phenomena. This hyperæmia may be induced by a tissue injury so slight that no characteristic inflammation results; for it must be understood that this process may begin to decline and go on to the resumption of the normal condition at any stage whatsoever. Therefore this is called the *hyperæmia of irritation*. In severe inflammation this hyperæmia is much diffused in the neighborhood, as seen in the diffusion of the redness and heat. It gives rise to œdema and swelling in the neighboring parts, without the accompanying inflammatory process, which in all of the phlegmonous varieties is confined to a certain area called the focus.

The elevation of the temperature, so far as this is capable of being determined by experiment, is due to the hyperæmia. The increase of heat is carried to the part by the greater influx of warm blood; therefore it never rises higher than that of the internal parts, no matter how intense the inflammation. Cohnheim caused an intense inflammation in one fore leg of a dog by scalding, and hyperæmia in the other by dividing the vaso-motor nerves, and examined the blood returning from each. That from the hyperæmic limb was found to be slightly the warmer. The mass of experimentation in this direction confirms this observation. This seems to completely refute the doctrine that the increase of heat in inflammation is caused by the more active metamorphosis of tissue through increased oxidation. It is now certain that if increased heat is thus developed, it is to so slight an extent as not to be appreciable by the ordinary means of experimentation.

The swelling is caused by three separate factors: the dilatation of the arteries, capillaries, and veins; the hyperæmic exudation; and the inflammatory exudation. The blood-vessels, especially the capillaries, become widely expanded; and in most of the tissues these are so numerous that this dilatation in itself must cause a considerable increase in the dimensions of the part. The swelling is, however, manifestly produced chiefly by the exudates, and will be great or small as these are abundant or scanty. If the hyperæmia is intense and widely diffused, it will produce a corresponding amount of œdema in the neighborhood. This, in many of the varieties of inflammation, is sharply differentiated from the inflammatory focus, showing itself in the readiness with which it is pitted by pressure of the finger. The swelling in the part inflamed, on the contrary, becomes hard and resistant. This difference is owing to the different character of the exudates in these localities. The qualities of these will be considered under the head of Exudates.

The pain in inflammation is supposed to be caused partly by the

injury to the tissues and nerves of the part which has produced the inflammation, and partly by the compression and stretching of the nerves by the swelling. The fact that inflammations occurring in the same parts under different circumstances differ very remarkably in this respect seems to show that the *cause* has much to do with the production of pain. This is illustrated by comparison of the pain produced by a plaster of mustard-seed with that caused by a plaster of cantharides. In many cases the amount of pain is not in proportion to the intensity of the inflammation; in others it is excessive. As a rule, inflammations occurring in the firmer tissues are more painful than those occurring in parts that are less dense. The individual tissues vary much as to the intensity of the pain induced. Our knowledge of the *modus operandi* of the production of pain is so limited that not much can be gained by the consideration of the subject.

The exudates are derived mostly from the blood. These are the serous, the fibrinous, and the corpuscular. The *serous* exudate is poured out from the dilated blood-vessels in the neighborhood of the inflammatory focus—in the region of hyperæmia. It is not peculiar to inflammation, but occurs in all the forms of hyperæmia. It is a thin, watery fluid, differing slightly from the plasma of the blood. It is but slightly coagulable, and does not coagulate in the tissues. It, however, seems always to contain some fibrinogenous matter in addition to dissolved albumen.

The fibrinous exudate is peculiar to inflammation. It contains in solution a large amount of fibrinogen. This amount seems not to be constant, but varies widely in different cases. It is always exuded from the blood-vessels in the fluid state and coagulates in the tissues. It is this that causes the first clinical differences between hyperæmia and inflammation; the exudate of hyperæmia remains fluid in the tissues, and is therefore easily displaced by pressure of the finger, while the exudate of inflammation coagulates in the tissues, and is not easily displaced by the finger, but forms a firm and resistant swelling. This exudate seems also to have more of the properties of glue than is found in the blood-clot, and it serves to bind the lips of a wound together with considerable firmness. Most pathologists seem to regard the coagulation of this exudate as taking place in the same manner as that I have described for coagulation of the blood (p. 680); but there is reason to suppose that the origin of the fibrin ferment is different. Instead of this being furnished entirely by the destruction of the white blood-globules, it may, and probably is, furnished principally by the inflamed tissue. It has been suggested by Denys de Commerey and Alexander Schmidt that this coagulation is effected by a substance furnished by the tissues in a state of inflammation, called by the latter *fibrino-plastin*. It is stated by Cornil and Ranvier that "under the influence of an intense inflammatory congestion the fibrinous matter escapes from the vessels and coagulates by uniting with the fibrino-plastic substance derived from the cells. The coagulation takes place suddenly and in successive layers, the exudate in contact with the tissues alone coagulating." The amount of this exudate is in many instances very large, and very thick layers are sometimes found lining the serous cavities when their walls

are inflamed (Fig. 387). Within the tissues this exudate has but a limited duration. It soon disintegrates and disappears. It first breaks up into fine granules, and finally becomes completely liquefied.

Fig. 387.

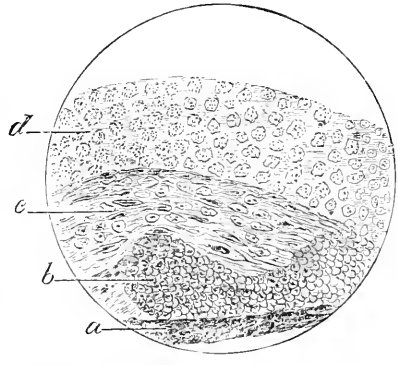

Iris inflamed after injury by a piece of iron thrust into the eyeball: *a*, pigment; *b*, circular fibres; *c*, radiating fibres; *d*, inflammatory exudate composed of coagulated lymph and leucocytes. Leucocytes are seen also in the tissue (× 350, Black).

The white blood-corpuscles are exuded (by diapedesis) with the fibrinous exudate, and they always accompany it in the tissues. Their motions are probably not interfered with to any considerable extent by the coagulation. I have remarked that the movements of the white blood-globules increased greatly after their exit from the vessels. This seems to be kept up so far as they have been traced. They are not always confined to the tissues that are living, but wander into almost anything that comes in their way. Blood-clot is invaded by them, and they become filled with the red globules. (See Fig. 387.) If milk is injected, they take up the milk-globules and become filled with them. If an insoluble coloring matter in fine powder be injected, the particles of this also are taken up; and much use has been made of this by pathologists in tracing the wanderings of these little bodies. If a frog be injected with finely granular vermilion, and then the cornea of another animal, as the rabbit, is removed and buried in the tissues of the frog, and left for two or three days, it will be found on examination that the leucocytes of the frog have wandered into the fragment of cornea in great numbers, carrying with them the vermilion as a mark of their identity. If the swimming-bladder of a fish be filled with water which has been so impregnated with common salt as to be of the same density as the blood, and then buried in the tissues of an animal until inflammation is established about it, these bodies will be found in the water, they having penetrated the bladder membrane. Nothing but actual solids seems to hinder their wanderings, and wherever they go they are continually picking up any little particles they may meet in their way which do not belong in the tissues or have become useless there.

Tissue-changes in inflammation have been the subject of the most persistent inquiry on the part of experimental pathologists within the last decade, and have given rise to much controversy. It will be remembered that when we terminated the study of inflammation by aid of the microscope (p. 692) the tissue had become so clouded by the inflammatory exudates that further observation of the changes going on was impracticable. This fact has confined this mode of the study of the subject to the onset of the inflammatory process. No plan has as yet been devised by which the further changes which may occur in the tissue-cells of the part can be accurately observed during the life of the animal; thus efforts for the further accurate following of these processes

are subject to the greatest disadvantage. There have been many and various attempts to overcome this difficulty, and after following out with some care all of the more feasible of these, success has been but partial. This is also illustrated by the differences of opinion that exist as to the actual occurrences. Difference of opinion as to the explanation of the *meaning of phenomena* does not argue faulty observation, but when our best observers differ diametrically in regard to what *actually occurs*, the morphological changes, we must suppose that the observations are either so difficult that they are liable to be inaccurate, or that the morphological changes are inconstant, or at least differ under circumstances so nearly the same that observers have failed to note the divergence. However this may be, the part the tissues play in the process of inflammation is not yet so accurately known that the best observers are able to harmonize their findings. In some cases the differences of opinion seem to result from modes of expression and in the explanation of phenomena rather than in differences of observed phenomena. Other disagreements occur from the use of different modes of observation. I will note the principal points of divergence as I proceed.

In the prosecution of this inquiry the effort has been to follow up the tissue-changes in those non-vascular structures deriving their nutriment from blood-vessels that lay at a considerable distance. This is done with the view of separating as perfectly as possible the phenomena due to tissue-change from those that are due to infiltration from the vascular system. For this purpose the cornea and the cartilages have usually been selected. The healthy eye of the frog or other animal may be used. A puncture is made, and the serum from the anterior chamber is collected in a suitable receptacle. A piece of the cornea is now excised and immersed in the liquid with the membrane of Descemet uppermost, and the little chamber so closed as to prevent evaporation, with the view of preventing changes in the density of the liquid. Prepared in this way, the tissue will retain its vitality for a considerable time, and give the best opportunity possible for the study of the normal structure. So long as the life of the tissue remains perfect, no structure whatever can be made out; every part is perfectly transparent; but as the tissue begins to die its form-elements come into view one after another—first, the epithelium, then usually some leucocytes just beneath, and finally the cornea-corpuscles with their branching processes. This observation is first made to familiarize the observer with the normal appearances. Then the observations on the inflamed cornea are made in precisely the same manner for the study of the changes that may have occurred. This is Professor von Recklinghausen's method, and with slight variations has been adopted by nearly all who have made this class of observations. Now the cornea of the living animal is irritated in some definite way, and after the lapse of a certain time, which varies in duration in different observations, it is treated in the same way and the tissue-changes studied. In these studies improvements have been made from time to time, the most notable of which is that by Prof. Stricker, of the continuous irrigation of the tissues under examination, with the serum of the animal

from which they were taken, this keeping them for a longer time alive.

For a description of the changes which occur in the tissues of the cornea when studied in this way I cannot do better than to make some quotations from the admirable article of J. Burdon Sanderson in *Holmes's System of Surgery:*

"If a cornea which has been irritated a quarter of an hour before by the application of a point of caustic to its surface is examined in the same way (as described above), the conjunctival epithelial layer can at once be distinguished, along with a few leucocytes, underneath and among the epithelial elements. If an hour or two has elapsed, the proper cornea-corpuscles are visible as dark stellate or spindle-shaped spots on a transparent ground. Of these, some are homogeneous, and can be distinguished from the surrounding substance by a slight difference of shade. In others, which are finely granular, the processes or rays are subject to slight variations of contour. These amœboid movements of the rays, although very sluggish as compared with young protoplasm in general, are rendered much more active by subjecting the preparation to a stream of blood-serum." . . . . "In the cornea excised three hours after irritation some of the corpuscles exhibit no change, excepting that their outlines are more strongly marked; in others there seem to be, in addition to the irregular nucleus above referred to, one or more spheroidal bodies which are imbedded in some other part of the corpuscle (Fig. 388). This appearance affords the earliest sign that the process which has hitherto been called 'proliferation' is beginning; that is to say, that the mode of life of the protoplasmic mass is changing from the normal quiescent state which fits it to take part in a permanent tissue to the state of reproductive or germinating activity —that new bodies are being formed in the body of the parent mass, to which such terms as 'germs' or 'offspring' are applicable. A part of the original living substance of the element begins a new life, much more active than it before possessed, and a new organic development. Since the introduction of the method of observing structural changes in living tissues, pathologists have learned that it is a constant characteristic of the change we are considering that the rejuvenescent part or substance acquires the property of contractility; in other words, that all protoplasm when assuming new life and beginning new organic development is endowed with the faculty of amœboid movement.

FIG. 388.

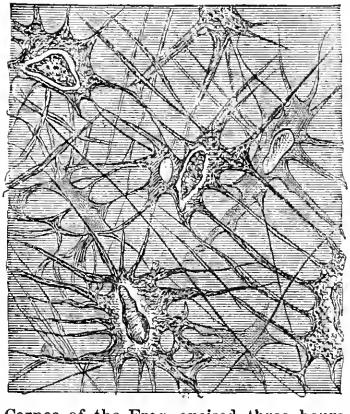

Cornea of the Frog, excised three hours after irritation (Sanderson).

"Between the fifth and twelfth hours after irritation the cornea-corpuscles become more distinct and granular, while their processes become thicker and shorter, until at length many of them lose altogether

their characteristic stellate or caudate outline and are converted into irregular clumps. If the cornea is examined in this stage after treatment with chloride of gold, it is seen that in those parts in which the structural changes are most advanced the normal character of the tissue is entirely lost (Fig. 389). The beautiful network produced by the interlacing of the normal corpuscles is no longer visible; in place of it the field is scattered over with clumps of irregular form, in some of which the caudæ are represented by rounded knobs, while in others the outlines are almost spheroidal. Most of these bodies are so granular that their contents cannot be distinguished, but in others the newly-formed germs are plainly visible. The number of these germs varies according to the stage of irritation, so that in the same cornea clumps containing a numerous offspring may be seen in one part, while in others the germination is only beginning (Figs. 390, 391).

FIG. 389.

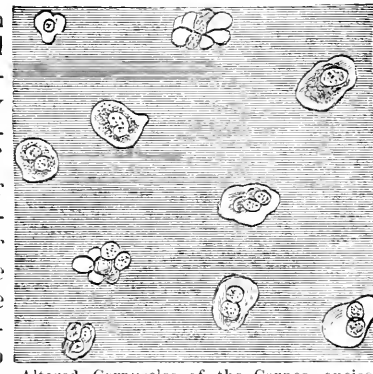

Altered Corpuscles of the Cornea, excised eight hours after irritation (Sanderson).

"That the interpretation suggested by these appearances is the true one, that the clumps containing numerous round corpuscles are nearly

FIG. 390.

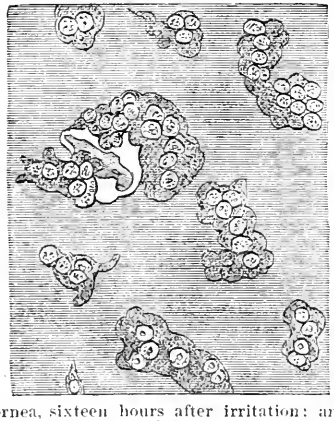

Cornea, sixteen hours after irritation: amœboid masses containing numerous newly-formed elements (Sanderson).

FIG. 391.

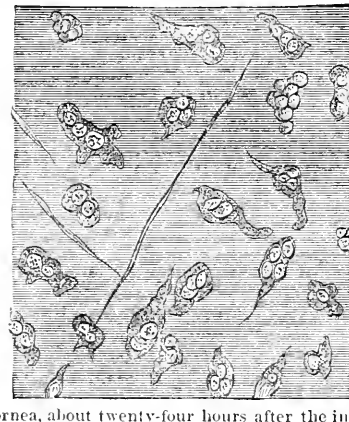

Cornea, about twenty-four hours after the insertion of a fine ligature: masses containing young elements in the neighborhood of the thread (Sanderson).

of the nature of mother-cells, the observer can best assure himself by returning to the method of examination first described; that is to say, by placing the inflamed tissue under the microscope alive, at the same time stimulating the elements in question to increased amœboid movement by irrigation with serum. It is then seen that the germs change their relative position with the movements of the mass of protoplasm in which they are enclosed, just in the same way as the granules and

ingesta do in the body of an amœba, rolling one over another in such a manner as would not be possible if they were not really contained in the mass."

It is on observations of the same nature as those so well described in these paragraphs that Prof. Stricker has founded his doctrine of inflammation, which he expresses in these words (I quote from his article in the *International Encyclopædia of Surgery*). He considers the essential phenomena to consist of "*metamorphosis of tissue; return to the embryonic condition; division into amœboid cells of the masses which have become movable; hence the destruction and the suppuration.*" This constitutes the basis of the doctrine of inflammation as taught by Stricker and others who have confirmed his observations. Cornil and Ranvier (*Manual of Pathological Histology*, 1880) express the same idea in the following words: "The process evolves in the following order: *hypertrophy of the nucleus; increase, then division, of the protoplasm; destruction of the enveloping membrane of the cell; destruction of the fibrous or of the fundamental substance; production of fundamental tissue; formation of new vessels.*" According to this doctrine, the tissues in inflammation are stimulated to greater activity in that amœboid cells are formed by the division of the original cells of the part, and the cells thus formed may, in the height of the inflammatory process, become pus-corpuscles through a lowering of their vitality, as in the formation of abscess on pus-yielding surfaces or mingled in the tissues (purulent infiltration); and in that when the height of the process has passed such cells as have not been too much reduced in vitality enter into the process of repair. The diapedesis and wandering of the leucocytes are noted, but they are assigned a subordinate place in the formation of pus and the building of tissue in the reparative process. The leucocytes are intermingled, but the principal part, both in the formation of pus and the rebuilding, is done by the *cells newly formed* by the breaking up of the old protoplasmic masses.

This doctrine is directly controverted by Cohnheim and his colaborers, who contend that all pus is formed directly from the diapedesis and collection of the leucocytes from the blood, and that all tissue repair is accomplished by the development of these cells. These pathologists regard the tissues as taking no part whatever in the process—that they are passive, or if they undergo any change it is always retrograde, which if continued results in the death of the cells; in which condition they mingle with the pus without forming a characteristic element, but in form of minute bits or shreds of dead tissue if not completely dissolved. Cohnheim particularly has repeated Stricker's observations in the most painstaking way without being able to discover the tissue-changes described, and upon this negative evidence reaffirms his doctrine that the tissues remain passive. On the contrary, it is claimed that Cohnheim has, in repeating Stricker's experiments, so varied them that they have been rendered ineffective. However this may be, there still remains a disagreement on this point, Stricker asserting the activity of the tissues in the inflammatory process, and Cohnheim as positively asserting that they are passive.

Touching the theory of inflammation held by Cohnheim, it seems

that his attention has been arrested principally by the changes that occur in the vessel's wall. These changes become obvious in various ways, and constitute, in the microscopic study of the subject, the most prominent factors. As we have seen in the microscopic study, the first sign which is characteristic is the development of an adhesive quality by the vessel's wall, which causes the passing blood-globules to linger, and finally to adhere. This change increases until the passage of the globules is arrested and stasis induced. Then we have an increased permeability of the wall of the vessel; its fluid contents pass through in greater quantity than normal, and in addition to this the white globules pass through the wall in abnormal numbers. These processes have been studied in the most painstaking way by the best experimental pathologists, and I think most observers will agree with Ziegler when he says that "the alterations in the vessel which take place in inflammation cannot be histologically demonstrated." These changes are not of a morphological character, at least until very great progress has been made, but relate solely to the physiological condition of the tissue composing the vessel's wall. This condition Cohnheim supposes to be that of paralysis produced directly or indirectly by the exciting cause of the inflammation. The vessels are widely expanded, and remain so during the continuance of the process. The adjacent tissues are also regarded as paralyzed; and in this condition take no part whatever in the processes that are going forward. This narrows the inflammatory process to a very few factors: injury to the tissues, and especially to the vessel's wall, by any form of irritation; paralysis of the tissues, and especially of the vessel's wall, as a result of this injury; increased permeability of the vessel's wall to both the fluid and the globular elements of the blood, which permits their escape into or among the elements of the tissue; the tissues while in the state of paralysis become crowded with these elements to an abnormal degree; under these adverse conditions the tissue-changes that occur are in the direction of their death and destruction; pus is formed by the aggregation of leucocytes, which come originally from the blood by diapedesis through the walls of the vessels, mingled with the results of the disintegration and liquefaction of tissue that may be destroyed. Briefly stated, these constitute the phenomena of inflammation, as held by Cohnheim and his followers. The changes in the tissue-cells, a description of which I have quoted from the admirable article of Burdon-Sanderson, are denied; and it is claimed that all pus-corpuscles originate from the white blood-corpuscles, and that all the tissue of repair is also derived from the same source through the development of these same white blood-cells.

The exciting cause of inflammation is tissue injury. It is obvious that this may occur in a multitude of forms. It may result directly from a wound, and this may vary from the slightest prick of a thorn to the crushing of a limb. It may occur from a chemical irritant, such as the caustics, or irritating medicaments, either animal or vegetable, as the Spanish fly or mustard. It may occur from the action of irritants that are carried to the spot by the blood itself, as is seen in inflammation of the gingivæ by mercury or the inflammation of the neck of the bladder by cantharides. It may also be caused by the

presence of micro-organisms that may gain access to, and are able to develop in, the tissues, as in the case of the *Bacillus anthracis* and many other microscopic forms that have been made known by recent experimental study. These varying causes of inflammation give rise to various outward expressions of the phenomena. Some inflammations are concentrated within a very small area, while others are diffuse or are spread over a comparatively large area. Some affect a certain tissue only, while others may affect several varieties of tissue at the same time. Some inflammations are prone to pass on to the production of pus, as is the apical pericementitis,[1] while others are prone to terminate in resolution without the formation of pus, as in erysipelas. If the cause acts continuously the inflammation will become chronic; in case the action of the cause is but momentary, the induced inflammation will generally terminate after an acute stage of short duration. These variations as to cause, coupled with individual idiosyncrasies and various conditions of body, give rise to the different forms of the affection.

Abscess is the result of a severe but circumscribed inflammation which causes the destruction of a certain area of tissue; or leucocytes may collect in large numbers at the centre of the focus of the inflammatory process, and, being reduced to a very low state of vitality, become aggregated together and cause a separation of the tissues, thus forming a *pus-cavity*. The differences of opinion as to the origin of these cells has been mentioned, and need not be further discussed at present; for, whether they arise in the one way or the other, they become pus-corpuscles when reduced to a certain state of vitality or when they commingle with the contents of a pus-chamber (Figs. 392, 393). Tissue is

FIG. 392.

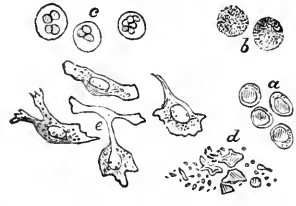

Pus-cells: *a*, from a granulating wound; *b*, from an abscess of cellular tissue; *c*, the same treated with dilute acetic acid; *d*, from a bone fistula (necrosis); *e*, migrating cells (Rindfleisch).

FIG. 393.

Pus corpuscles: 1, *a*, *b*, in water; *c*, *d*, *e*, after the action of acetic acid; 2, division of nuclei (Virchow).

usually destroyed in the focus of an intense inflammation, and, becoming dissolved or forming small gangrenous masses, mingles with the fluid and corpuscular exudates to swell the volume of pus. While this is in progress in the focus of the inflammation the exudation of coagulable lymph is filling the surrounding tissues, and in this way the abscess is, as it were, walled in. The abscess may continue to enlarge by a continuous destruction of its immediate walls. This destruction is, however, usually greatest in the direction of the least resistance, which brings the pus nearer the surface, favoring its discharge. In this event, if there is no continuous cause of tissue injury keeping up the

[1] Inflammation at the apex of the root of a tooth after the death of the pulp.

inflammatory process, the walls of the abscess-cavity begin to be built up by granulations, and healing is accomplished in the same manner as in any other breach of continuity.

An ulcer[1] is a condition attended by a progressive destruction of tissue, accompanied with the formation of pus or ichor in some of its forms, and which is confined to the surface of the body or to natural cavities, as the mucous surfaces. In this condition there is often a cause that continues to act and keeps up the discharge indefinitely; otherwise the ulcer heals after the first destruction of tissue and the formation of pus. The process is in no wise different in its *modus operandi* from that taking place in abscess, except that of location, the one being within the tissues, the other on the surface. The word *ulcer* carries with it, however, the idea of chronicity connected with progressive waste or destruction of tissue.

In case of abscess or ulceration Stricker accounts for the destruction of tissue at the focus of the inflammation on the theory of the conversion of the fixed cells into amœboid cells, which finally are converted into pus-cells. Hence the disappearance of tissue and the formation of the cavity. After the intensity of the inflammatory process has passed the same amœboid cells which have been converted into pus-cells begin to develop, and finally form the tissue of repair. According to Cohnheim, all this is the work of the exuded white blood-corpuscles.

An inflammation may begin to abate at any stage of the process. "The repair of the damaged vessel-wall is brought about by the *vis medicatrix* of the blood itself" (Ziegler). If, when the injurious influence has ceased, the blood brings to the injured vessel the material required for restoring it to its normal state, the inflammatory disturbance comes to an end, the exudation ceases, and the process of healing is begun. In the earlier stages of the process this consists in the restoration of the walls of the vessels to their normal state of comparative impenetrability, and the removal of the exudates by the lymphatics and blood-vessels. If a small amount of tissue has been injured, it is reproduced, the muscle-cell producing new muscle, periosteum producing new bone, and so on (Ziegler).

This manner of reproduction is, however, confined to very small

[1] There seems to be considerable confusion in the use of this word. Many make no difference between the processes of ulceration and suppuration, while others distinguish sharply between them. Loomis (*Principles and Practice of Medicine*) regards suppuration and ulceration as the same processes, except that that which forms a cavity, a pocket within the tissues, is an abscess, and that which is limited to the surface is an ulcer.

Sir James Paget says: "Ulceration is that part or effect of an inflammatory process in which the materials or inflamed tissues, liquefied or degenerate, are cast off in solution or very minute particles from the free surfaces, or, more rarely, are absorbed from the surface of the body" (*Holmes's System of Surgery*). In this article he holds distinctly the doctrine (if I understand him aright) that laudable pus is not formed in ulceration. It must be ichor or something lower than laudable pus; and as "the ulcer tends to heal its discharge becomes more like laudable pus."

W. H. Van Buren (*International Encyclopædia of Surgery*) regards that process of destruction of tissue by which the contents of an abscess make their way to the surface as ulceration, and says: "Under all possible circumstances this molecular death is the essential feature of the process which we call ulceration."

Billroth (*Surgical Pathology*) says: "An ulcer is a wounded surface which shows no tendency to heal."

amounts of tissue. If any considerable masses are to be re-formed, it is accomplished by a process entirely different. In the explanation of this process there is again encountered a divergence of views among pathologists, which, however, has its foundation in the differences of opinion already explained. It amounts to simply this: Is the regeneration of the lost parts accomplished by the return of the normal fixed cells to the embryonal form, the amœboid state, and the redevelopment of these, or is it accomplished by the development of the leucocytes into connective-tissue cells? I need not again enter this field of controversy, as all agree that the new tissue formed in the healing of wounds is by the development of the amœboid cells, which according to the one theory are produced from the fixed cells, and according to the other from the leucocytes. The new tissue formed is called granulation-tissue, inflammatory new formation, scar-tissue, tissue of repair, etc.

The formation of this tissue takes place in this wise: If the surfaces of a wound be examined twenty-four hours after it is inflicted, they will be found intensely red and more or less swollen. The tissue-elements are still distinguishable, but have become somewhat blurred. On the second or third day the original tissue is hidden from view, being covered with a more or less copious secretion, which at first is inclined to dry, if not too abundant, into a semi-gelatinous film, which, as the secretion becomes better established, changes to a creamy consistence and assumes a yellowish hue. This is composed of coagulable albuminous matter mixed with numerous corpuscular elements. The latter are amœboid cells that have sunk so low in the scale of vitality as to be incapable of further development, and have become *pus-corpuscles*. Here and there over the surface of the wound, if it is doing well, will be seen little red prominences. These are granulations, which are composed almost entirely of the same amœboid cells, which have taken on a redevelopment and are destined to form the new tissue for the filling of the wound. Thus the pus and the newly-formed tissue are developed from the same class of cell-forms; the one sinks so low in the scale of life that it cannot recuperate, and the other, being more favorably placed, lives and grows. These cells result from the inflammation set in action by the injury to the tissues in the production of the wound, through which the adjacent tissue becomes infiltrated with leucocytes, and probably others are developed by changes in the fixed cells as well, and both go to the formation of either pus or granulations as they may be more or less favorably placed. It would seem that the so-called leucocyte is the proper reparative cell of the connective tissues belonging to them and having its home among them. The name of white blood-corpuscle is a misnomer. The wandering of the cell by way of the blood-streams is perfectly natural and normal. These cells wander through the tissues at will, and are found everywhere, in all of the tissues and in the blood. They are most probably a product of the connective-tissue group, and in their development always form connective tissue. I therefore regard each of the views, although they seem to stand over against each other, as substantially correct, but only representing a part of the phenomena of the inflammatory process. The combination of the two is necessary to the complete explanation of the cycle of events.

Wherever there is trouble in the tissue the leucocytes are congregated, they being attracted by the changes that take place in the fluids of the part. Thus the stickiness of the vessel's wall brought about by changes in the cells under the influence of an irritant arrests those that are in the circulation, and others are promptly formed by the changes in the cells of the injured tissue.

We may now pursue the development of these cells in the formation of the granulations and subsequently of the tissue of repair. The whole life-history of these cells has not yet been made out, but much in regard to their growth is known. The brilliant experiments of Ziegler will illustrate the subject best. This experimenter placed together bits of glass, one of which was a cover-glass used in microscopic observations, so as to leave a space of a very small fraction of a line between them, and these he buried in the flesh of a living animal. The presence of this, together with the injury caused in placing it, produced sufficient inflammatory action to bring a number of wandering cells to the spot. These crept in between the bits of glass, and developed there. And as these were so close together, the cells were necessarily in a single layer, which placed them well for microscopic study. These bits of glass were removed from day to day and the development of the cells studied. Fig. 394 is an illustration

FIG. 394.

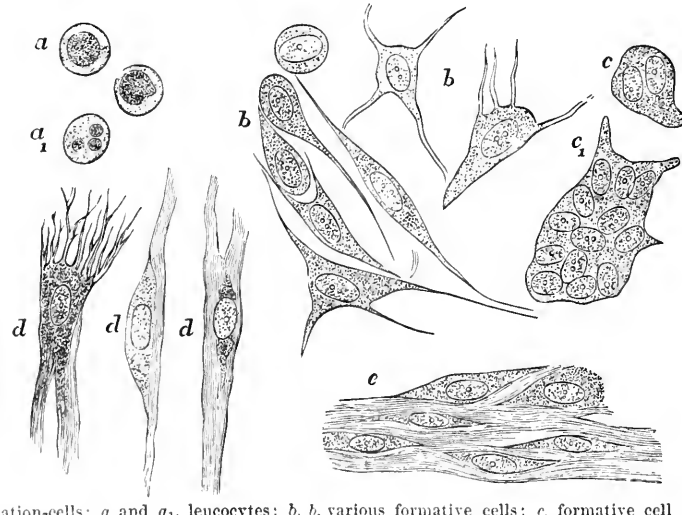

Granulation-cells: *a* and a_1, leucocytes; *b*, *b*, various formative cells; *c*, formative cell with two nuclei; c_1, with many nuclei; *d*, *d*, *d*, formative cells developing connective tissue; *e*, complete connective tissue (× 500, picrocarmine preparation, Ziegler).

of these, showing the progressive changes of form of the individual cells in the formation of tissue. *a* is the form of the cell when it first takes its place as a granulation-cell; a_1 shows the same cell as degenerated into a pus-cell; *b* shows various forms assumed by the cells in the course of their development into tissue. In watching these from day to day it is found that certain of the cells, presumably the weaker, disappear; and Ziegler supposes that they are devoured by the stronger or

that their substance goes to feed them. In other instances several cells seem to flow together and form one with many nuclei, as seen at c, c_1, the so-called giant-cells. Within my personal observation this form of cell has occurred mostly in connection with secondary neoplasms. They would probably occur in connection with Ziegler's glass slips, but I doubt their general presence in healthy granulations. It will be seen by studying the illustration how the cells increase in volume and put out long slender processes. By the interlacing of these with similar processes from the neighboring cells they become very firmly united into tissue. But this is not all. At d the cells are shown still further developed, and in the forms to the right in connection with this letter it will be noticed that the granular area of the cell has diminished and is connected with a finely fibrous substance, which is also seen at e, which represents the developed tissue. This fibrous material is a connecting substance which finally forms the bulk of the reparative tissue, the original cell remaining as a delicate spindle-cell.

If a wound be watched from day to day, it will be seen how it is pro-

FIG. 395.

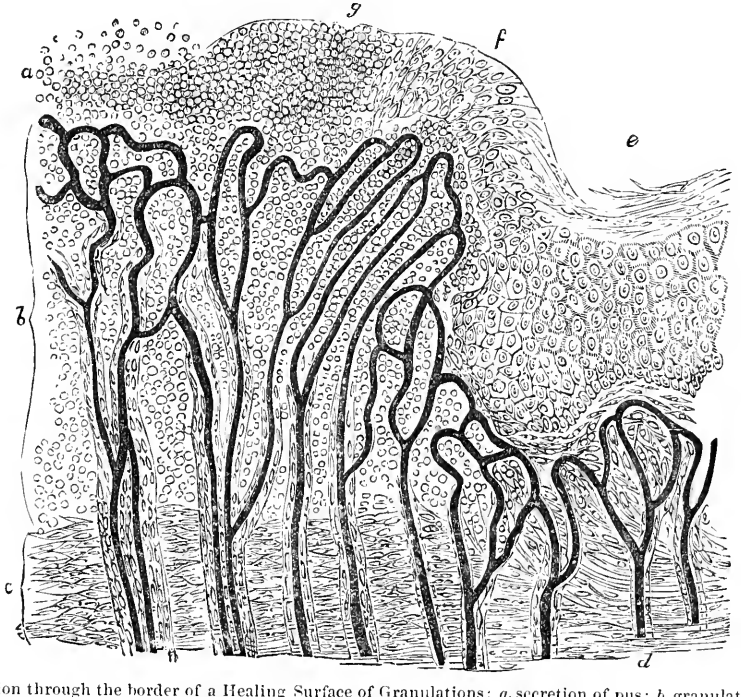

Section through the border of a Healing Surface of Granulations: a, secretion of pus; b, granulation-tissue, with capillary loops, whose walls consist of a longitudinal layer of cells decreasing in thickness from within outward; c, beginning of the cicatricial formation in the deep layers (spindle-cell tissue); d, cicatricial tissue; e, complete epithelial covering; the central layer of cells consists of serrated cells; f, young epithelial cells; g, zone of differentiation (× 300, Rindfleisch).

gressively filled up by the growth of the granulations. The cells are piled the one on the other in the form of little clumps which may be seen with the naked eye, and it is these that have given the name of

"granulations." This seems to require that new cells be continually approaching the surface and taking their place at the very outer surface of the granulations. In the microscopic study of granulation-tissue it is found that the cells actually do this; that is, the young cells are on the surface (Fig. 395); but what portion of them wander to this position from the tissues beneath or by way of the blood-vessels, and what portion are developed *in situ* by multiplication, is still an open question. Great multitudes of the cells are separated from the surface as pus-cells, and in this way are lost.

When, in the growth of the granulations, two opposite sides approximate, and finally touch each other, the cells coalesce in the same manner as the cells that are piled the one on the other, and thus union is established and the opposing walls of the wound are united. It therefore follows that if the opposing surfaces of a wound are placed in perfect approximation, the first cells that take their places at the surface unite the wound, and the time required and the expenditure of vital energy are reduced to the minimum. In what is known as *healing by first intention* the wound is sealed by the plastic exudate which I have described as first covering the surface of the open wound as a semi-gelatinous film. This holds the adjacent walls together, and the cells that perform the true reparative process find within this gelatinous substance the best possible conditions for their development, so that in this position none are lost in the form of pus-cells.

The development of blood-vessels keeps even pace with the formation of the granulations, so that every little granule or clump of cells has its vascular loop which carries the nutritive fluid directly to it. The vascular network of vessels that forms in granulation-tissue is exceedingly rich and intricate. Some idea of this is shown in Fig. 396. The man-

FIG. 396.

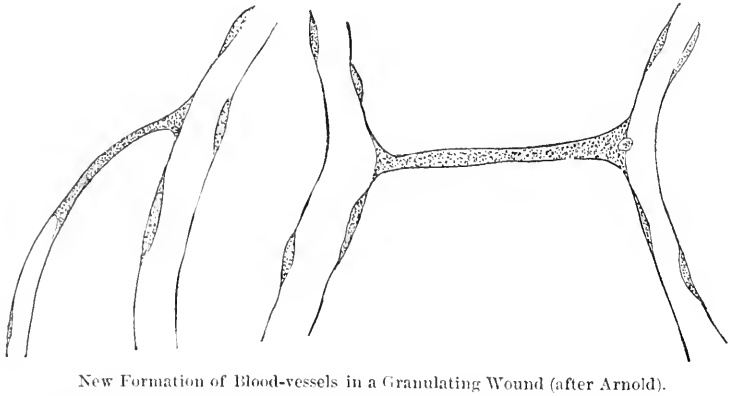

New Formation of Blood-vessels in a Granulating Wound (after Arnold).

ner of the formation of these vessels is probably the same in all tissue that is in the process of development, whether it be in the original growth or in the tissue of repair. This is by a process of budding from the blood-vessels already formed. It always takes its rise from the capillary loops, the bud from one always joining with one from a neigh-

boring loop, as shown in Fig. 395. These loops are formed as solid processes, and hollowed out afterward by the removal of the central substance of the cells. This process of the formation of ducts takes place in the same manner in the vegetable kingdom, and is easily observed, especially in the sprouting of seeds. If a number of grains of corn be planted in damp earth under suitable conditions for germination, and every twelve hours sections for microscopic examination be made of two of these (one cut lengthwise and the other crosswise of the germ), the process of the formation of the ducts, which are hollowed out in the same manner as the blood-vessels in animals, may be followed with the greatest accuracy. In Fig. 397, at *a*, I have represented a row of large cells as they appear in the germ of the grain twelve hours after planting, and at *b* the cross-section is shown. These grow in length, and their number is increased by fission. After a certain time their growth seems to cease; they begin to lose the central part of their substance and are rapidly converted into tubes, the walls of the cells alone remaining, which are joined together end to end. At *c* and *d* of the figure these are shown as they appear on the fifth day. This seems to conform very perfectly to the manner of formation of the first blood-vessels in the development of the fœtus, and is much easier of accurate study.

FIG. 397.

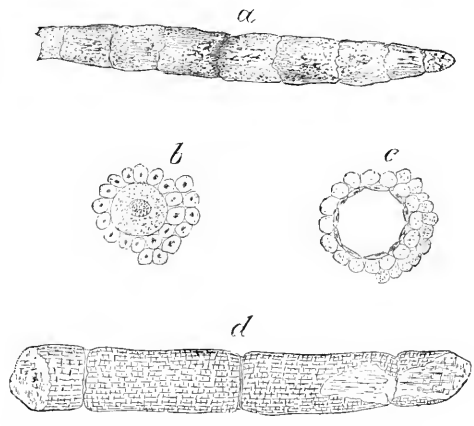

Formation of the Ducts in the Sprouting of a Grain of Corn, in sections cut twelve hours after planting. A series of large solid cells are seen placed end to end, as at *a*. *b* is a cross-section of the same, showing the cell to be finely granular, and staining brings the nucleus into view. It is shown surrounded by the neighboring cells. *c* shows the same cell converted into a tube by hollowing out. Fifth day: *d*, the duct on the fifth day, showing the elongated cells hollowed out, forming a tube, the walls of which show "duct-markings" (Black).

In the animal, after the formation of vessels is once begun, all new vessels are formed from buds given off from cells of the existing vessels. These, though they unite with similar buds, seem to be perfectly fused together as a single cell. After the hollowing out is accomplished, however, the formed vessel presents the usual appearance of epithelial plates joined together for the formation of its walls.

Granulation-tissue during its formation is very soft and friable. The capillary loops come so near the surface, and their walls are so thin, that the slightest touch is likely to cause hemorrhage, and the tissue contains much fluid. As it grows older and the cells begin to assume the spindle shape and form the fibrous connecting substance, it becomes much drier and firmer. Many of the capillary loops that were formed during the growth of the granulations are obliterated and the tissue shrinks, drawing the surfaces of the wounds together, usually in such a way as to diminish its surfaces and lessen the remaining scar. This

tendency to shrinkage, while in the main beneficial, sometimes produces disastrous results. This is seen most prominently in case of burns or other injuries involving a large extent of surface, in which the shrinkage of the cicatrix often produces distortion. This shrinkage continues for a considerable time after the complete cicatrization of the wound.

The reproduction of epithelium is always by proliferation from the existing epithelial cells at the margin of the wound or by division of young cells. In normal conditions the epithelial cells are continually being shed, and are as constantly being regenerated by the multiplication and growth of cells from beneath. These cells are never produced from connective-tissue cells, but always from the epithelial cell; hence in the healing of wounds the epidermis that finally covers in the granulations is projected from the margins. This is seen in the form of a very delicate film at first extending a little way inward all around the wound. Fig. 398 gives the microscopic characters of such a film from

FIG. 398.

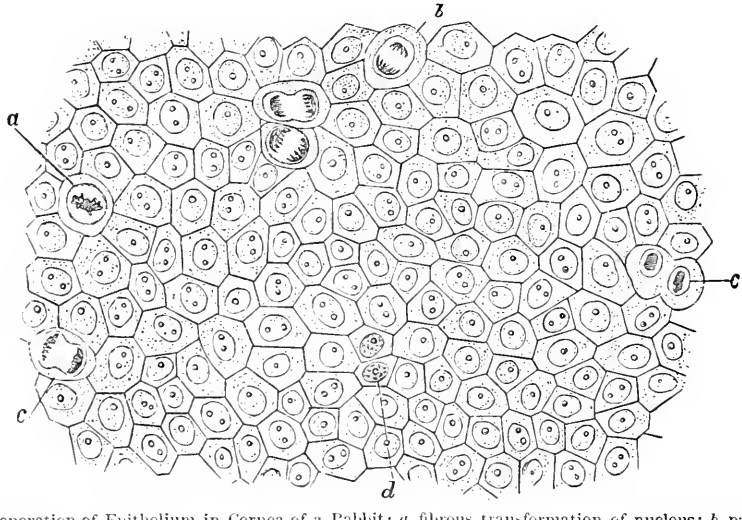

Regeneration of Epithelium in Cornea of a Rabbit: *a*, fibrous transformation of nucleus; *b*, partial separation of the fibres and hour-glass change of nucleus in the process of division; *c*, complete division of nucleus; *d*, complete division of cell (Eberth).

the cornea of the rabbit, and illustrates the process of division of the young cells. This increases from day to day in width until all of the granulations are covered in, the secretions cease, and the wound is healed. For some time, however, the layer of epithelium remains very thin and soft. By degrees this becomes thicker and denser, until in most small wounds it approaches closely the characters of the normal parts, but in large wounds it usually remains permanently much thinner than normal.

Transplantation of epithelium to the surface of granulations is practised for the purpose of bringing about a more speedy cicatrization of the wound. This little operation illustrates an important point in the physiology of these cells which determines their behavior in pathological conditions. When the epithelium is completely destroyed over a con-

siderable surface, as by a burn, no epithelium is produced on that surface except as it is projected from the margins where the epithelium is intact. Now, if the smallest bits of the epidermis from any portion of the body of the same individual or of another be clipped off and laid on the granulations, it will be observed that within a few days a film of epithelium will spread from this point. By placing many of these it is possible to cause a large wound to cicatrize much sooner than it would otherwise do. In this way the peculiar epidermis of the white man may be transplanted to the negro, producing a patch of white skin, or *vice versâ*. This shows that these cells have, independent of the organism to which they belong, a life and individuality of their own which they are capable of carrying into strange places and of asserting among strangers.

The organization of blood-clot, so called, is a process of great importance, not only as a matter of scientific inquiry, but also in its clinical bearings. The blood-clot meets the surgeon at every turn, and its clinical importance cannot well be over-estimated. If he ties an artery, he depends on the so-called organization of the blood-clot that forms in its interior to hold against the blood-pressure after the ligature has sloughed out or has been absorbed. If a blood-clot forms in a wound

FIG. 399.

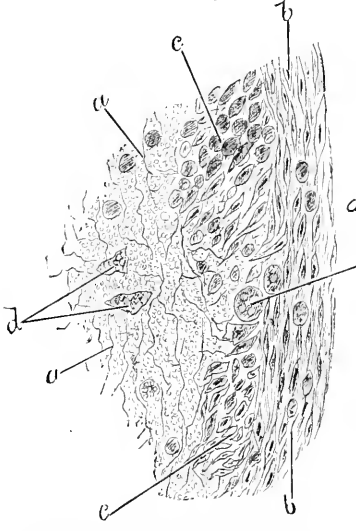

FIG. 400.

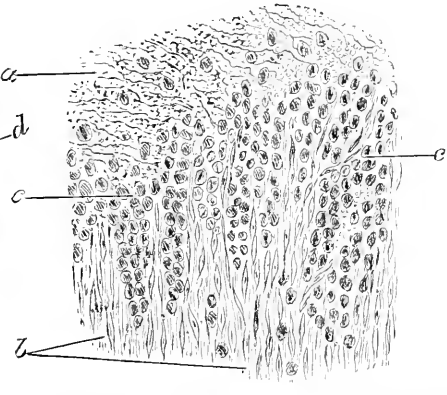

FIG. 399.—Absorption of Blood-clot. Section through the margin of a clot formed among the tissues by extravasation, showing the growth of granulations by which it is removed: *a*, *a*, portions of clot; *b*, *b*, original tissue; *c*, *c*, granulations springing from the original tissue and projecting into the clot; *d*, *d*, wandering cells or leucocytes that seem to have taken red blood-discs into their interior. (Section cut in gum arabic and stained with hæmatoxylin; × 350, Black.)

FIG. 400.—Absorption of Blood-clot. Section through the margin of a blood-clot formed by extravasation in the tissues, showing the growth of the granulations by which it is removed: *a*, portion of clot, showing fibrinous reticulum enclosing the blood-discs, which are much shrunken, and occasional wandering cells interspersed; *b*, newly-formed tissue projecting into the mass in the form of processes, which are covered with young granulation-cells, *c*, *c*. The granulations are in intimate relation with the clot. (Section cut in gum arabic and stained with hæmatoxylin; × 350, Black.)

after it has been closed, what is its significance? how is it disposed of? and what is its effect on the healing of the wound? These questions

will now admit of answer, thanks to the experimental study of recent years.

When a blood-clot has formed from any cause in the midst of tissues of fair functional activity, away from contact with the air, and therefore safe from contamination from without, it causes a slight inflammatory process to be developed in its immediate neighborhood. This brings to the spot numbers of the amœboid cells, which actively attack the clot in all its parts, but especially its margins. In addition to the cells that wander free into the clot, granulations spring out into it from all sides, and as they grow the clot disappears to give them room (Figs. 399 and 400). The clot is digested, dissolved, and removed. Thus the connective-tissue forming cells *grow into the substance of the clot* as they grow into the meshes of the sponge in the sponge graft, and the clot is removed by solution in the same manner as the sponge. In this manner very large clots are many times removed, leaving in their stead a quantity of newly-formed tissue that is of no value. In time this also shrinks away partly and is partly absorbed, so that in the end but little remains to show that there has been a clot in the locality. The clot itself has no power of organization any more than the sponge in the sponge graft, but as the sponge it acts as a stimulant to the growth of the granulations by which it is removed. It is possible also that in some positions the blood-clot may, as the sponge graft, *act as a ladder on which granulations may climb*, and in this manner assist in the formation of tissue for the filling out of lost parts; but in this respect it is much inferior even to the sponge in the character of the new tissue produced, which is usually of a very loose texture and shrinks together to an extreme degree (Fig. 401).

FIG. 401.

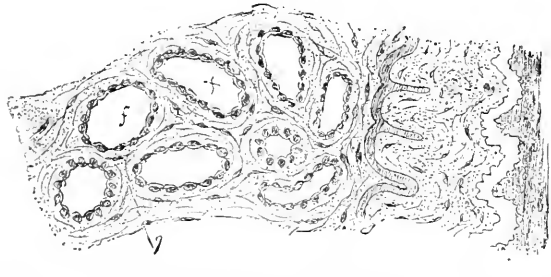

From the Cross-section of an Arterial Thrombus of Three Months: *f*, lumina of vessels in the thrombus, *x*, *x*, *x* (× 300, Rindfleisch).

In order that the granulations shall grow in blood-clot it must remain aseptic. Therefore it usually happens that clots which are exposed to the air are decomposed, and constitute a much greater hindrance to the healing process than in subcutaneous wounds. It has been shown by Lister that blood-clots do not decompose as readily as most other substances; yet clinical experience demonstrates that in very many cases their decomposition seriously interferes with the process of granulation by becoming the foci of septic processes. If the clot remains aseptic, it retards the process of healing by the time required to fill it with granulations. I think a close comparative study will show that granu-

lations form less rapidly in a blood-clot than in the filling of an open wound, and certainly the tissue formed is usually much less perfect.

Formerly it was held that the substance of the clot became itself tissue. This was the conclusion arrived at by O. Weber, Budnoff, and others, but recent studies have shown so plainly that the organization takes place in the manner I have just stated that it is accepted by pathologists generally.

Fever.

Fever is a condition of the general system characterized by elevation of the temperature and attended with increased frequency of the pulse. This condition has no known anatomical characters; at least, none that seem really essential to the condition of fever. It seems to consist of a disturbance of the function of heat-production, or of the relations that normally exist between the functions of heat-production and heat-dissipation. Fever occurs as an accompaniment of many and various lesions; and so common is this that it is expected to follow any lesion of considerable gravity, and in such cases may be considered as symptomatic. Fever occurs also as the forerunner and accompaniment of most of the grave inflammations, such as pneumonitis or lung fever, inflammation of Peyer's patches in typhoid fever, and various other forms of disease known as the essential fevers, so called from the fact that the condition of fever seems to be the prominent factor in the disease. It also precedes and accompanies the inflammation of the skin or eruption in the exanthems, as in smallpox, scarlet fever, measles, etc. Fever usually occurs after the infliction of wounds or surgical procedures which produce tissue injury of any conceivable kind in which much tissue is involved. This is the more certain of occurrence if the wound is open to the surface. This form of the disorder is known as wound fever or surgical fever. Fever is also liable to occur without any appreciable lesion of any known kind whatever that we are able to determine by our physical senses, either as a forerunner, accompaniment, or sequel. A person may be attacked with a feeling of languor, perhaps have some headache, abnormal dryness of the mucous membranes, some thirst, etc., and a thermometer placed under the tongue may show a rise in the bodily temperature of from three to five degrees. At the same time the pulse may rise in frequency from 75 beats in the minute to 100 or even 120. These symptoms may continue from six to twenty-four hours, and then subside with complete restoration to health, leaving no sign whatever of any disease connected with or explaining this disturbance of function.

From what has been said it would seem evident that fever does not arise from any one specific morbific cause: it may, and evidently does, arise from a variety of causes. As throwing light on this point, it might be useful to inquire into the particular tissue prominently affected, but as there are no anatomical lesions yet discovered that are essential to this condition, the inquiry must be directed by the disturbance of function. This leads to the questioning of the particular systems that make up the community of systems that combine to form

the sum of the functional activities. In this inquiry we will be more or less troubled by uncertainties. The older pathologists seem to have regarded the nervous system as the one specially affected, but recent investigations point to the blood as being primarily at fault, or at least indicate that fever results from some form of poison that has gained access to the blood and is circulating in it. Recent experiments demonstrate that the injection of pure healthy pus into the veins of the dog produces fever with certainty and promptness, and that the fever thus induced runs a very regular course, passing away in two days, more or less, according to the amount of pus injected (Senator). In this case it would seem that fever has a material cause, in that a substance is in the blood that in some way interferes with the proper and normal functions so as to increase its temperature. This increase in the temperature is the one essential factor. Increased frequency of the pulse is a usual accompaniment of fever, but is not invariably present, and may be induced by various causes independent of fever. We may and do have fever without increased frequency of the pulse, and we may reduce the frequency of the pulse during the existence of fever without materially altering the temperature. It is well known that during the existence of fever the pulse-rate may, by the administration of veratrum viride, be reduced without lowering the temperature as expressed by the thermometer. I recall a case of typhoid fever in a boy of twelve years, who when I first saw him had a pulse-rate of 70 to the minute, and at the same time a body-temperature of 107° F., as registered by a thermometer in the axilla. In this case veratrum viride had been given. Occasionally, even where no heart sedative has been administered, fever may be seen without a frequent pulse, though this is evidently rare. It is not very uncommon, however, to see the temperature out of proportion to the frequency of the pulse, or the reverse. A high pulse-rate, therefore, while an accompaniment that is almost universal, is not absolutely essential to the condition of fever. As it is with this, so it is with the other symptoms, as thirst, loss of appetite, the sensation of heat felt by the patient, etc. Any of these may be wanting, and in some rare cases all of them, and still the continued elevation of the temperature marks the condition of fever as being present notwithstanding. Fever, then, is shown to be present by the existence of this one fact of high temperature, and the other conditions that usually accompany it are due to this increase of the temperature—are caused by the fever—are products and not essential factors.

The increase of heat in fever is not in any sense local. Even though the febrile movement may have resulted from a purely local inflammation, the rise of temperature is always general and affects all parts of the body alike. Increased local heat accompanying local inflammations must not be confounded with fever. In fever the whole blood is warmer than normal, and this increase may stop at five or eight degrees above the normal, or in severe cases it may pass on to ten, but rarely above this limit. The organism in its normal condition possesses a self-regulating power as regards its temperature which under the varying circumstances of climate and seasons preserves the blood at about the same degree of heat—viz. 98° to 99° F. Therefore when it is observed

that this equable temperature is disturbed, and that an elevation is steadily progressing or is maintained above the normal, some factor has entered into the economy from without, or has been produced by faulty chemico-vital processes within, that has the effect of unbalancing the combined functions of heat-production and heat-dissipation. This may occur shortly after the receipt of an injury or the rise of an inflammation or of a complaint of languor, or seemingly as the result of the most varied physical disturbances.

All of the features of the affection are arranged around this one central phenomenon. The patient may or may not be conscious of the increased heat. At the beginning of the rise of his temperature he generally complains of chilly sensations. What is known as a chill or rigor is coincident with a rise of temperature that is more or less sudden or rapid, as is indicated by a thermometer under the tongue or in the axilla. The sensations of the patient are not to be trusted, for while he is shivering with cold his temperature may rise several degrees. Afterward flashes of heat begin to alternate with the sensation of cold, and as the case progresses the patient becomes unpleasantly conscious of the increased heat of his body. In the onset of certain forms of fever the occurrence of *chill* is a prominent manifestation. This is especially the case in what is known as chills and fever; and indeed in all of the types of malarial fever the duration and severity of the chill are especially marked, and the patient may be shivering with cold for an hour or more, during which time he is unable to recognize the fact that he is really unusually warm. The chill seems to mark a sudden rise of temperature, but the gravity of the chill is not always in proportion to the rapidity of the increase of heat. It has been suggested that the chill is an illusory sensation brought about by the change in the temperature relation of the body and the surrounding air; but there is evidently some other factor in the production of chill that is not yet certainly made out.

In other than the malarial fevers there is much difference as to the production of chill. Thus, in most of the grave inflammations of the internal organs, such as occur in pneumonitis and other of the continued fevers that are accompanied with distinct and severe inflammations, the occurrence of chill at the onset is the rule, and the severity of the chill usually bears some proportion to the severity of the attack. In inflammations not primarily accompanied with fever a chill is very likely to mark the beginning of the formation of pus or the development of an abscess. It is generally not very severe, and the fever which results usually passes away with the more complete formation of the abscess. This seems to have some relation to the particular conditions at the seat of the inflammatory process, in that the fever is called forth in the early period of the inflammation or of the formation of pus, and ceases after the effusion of plastic lymph has, so to speak, walled in the inflammatory products by the closure of the lymphatics, by which absorption into the general circulation is prevented or rendered less in amount. I will speak of this again.

In *surgical fever* (fever following shock or accompanying the development of inflammation in a wound) the chill is usually absent or but

slightly developed. The fever in this case comes on more gradually, and the temperature does not attain so high a degree. If, however, the chill should be pronounced, the fever which follows is likely to be accompanied with graver symptoms than the fever that is ushered in without marked chill.

In connection with the increase in the temperature of the blood in fever other evidences are presented, showing derangement of the functions of heat-production. Tissues are being destroyed by combustion or oxidation to an abnormal degree in consequence of the necessity for material sufficient to keep up the increased heat-production. It appears from the recent experimental studies of Senator, H. C. Wood, and others that the excretion of urea is doubled or tripled as a result of the increased destruction of albuminous material—blood-plasma, blood-corpuscles, the sarcose elements of muscular tissue, etc. Hence the increase in the salts of the urine and the increased excretion of carbonic acid which are also noted. At the same time, digestion and assimilation are disordered, appetite is wanting or is seriously impaired, and in this way the usual food-supply for renewing the waste of the tissues is greatly diminished or cut off entirely. Hence the absorption of adipose tissue, waste of the muscles, and impairment of the blood follow as results of, or it may be said form a part of the phenomena of, fever. It thus becomes evident that the abnormal production of heat during fever is maintained by the consumption of valuable material not used for this purpose in a state of health, or the regeneration of which is prevented by the accompanying conditions of impairment of the functions of digestion and assimilation. With this view fever might be said to consist of a disorder of nutrition made manifest in increased heat-production and increased tissue-waste.

It appears from the exhaustive experimental research of Prof. H. C. Wood that the temperature of the body is no certain guide to the extent of the abnormal heat-production that may be in progress in a given case of fever, for another factor enters into the disorder—namely, disordered heat-dissipation. It therefore follows that if the dissipation of heat be interfered with, a rise of the temperature of the body may occur without over-heat-production, and, *vice versâ*, over-heat-production may be present without rise of bodily temperature. It thus appears that the heat of the body is controlled in a large degree by the orderly play that normally exists between the combined functions of heat-production and heat-dissipation, and that the occurrence of a rise of temperature may be due to either increased heat-production or diminished heat-dissipation. Touching this point Prof. Wood formulates the following proposition: "Fever is a complex nutritive disturbance, in which there is excessive production of such portion of the bodily heat as is derived from chemical movements in the accumulated material of the organism, the overplus being sometimes less, sometimes more, than the loss of heat-production resulting from abstinence from food. The degree of bodily temperature in fever depends, in greater or less measure, upon a disturbance in the natural play between the functions of heat-production and heat-dissipation, and is not an accurate measure of the intensity of increased chemical movements of the tissues."

The cause of fever is in some degree elucidated by the experimental research of Senator, already alluded to. This experimenter injected fresh healthy pulse into the subcutaneous tissue of dogs, and found that it regularly produced a state of fever. Two or three hours after the pus was injected the temperature began to rise, and a state of fever was inaugurated that continued two or three days, and subsided unless the injection was repeated. This and similar experiments have established a connection between inflammation and fever that was inferred previous to the experimentation, but which is now placed on a more certain basis. The relation between these processes has been observed clinically since the inception of surgical knowledge. When a wound of considerable magnitude is inflicted, clinical experience has led men to expect the rise of fever to coincide very closely with the rise of inflammation in the wound; and it has been noticed especially that if the progress of the wound was favorable, this fever would begin to subside when the inflammatory process had reached a certain point—*i. e.* when the secretions were established, as the process has been denominated. This corresponds very closely with the time when the wound is, so to speak, walled in by the inflammatory exudates in such a manner as to prevent absorption of the materials elaborated by the inflammatory process.

If the fever recurs after this period or if it persists, the surgeon is led to seek some other cause for its recurrence or persistence. This is generally found to be some change in the condition of the wound or in the development of an abscess in connection with some foreign substance overlooked—a pocket in an unexplored nook in which retained pus has begun burrowing, or something of this general nature that has caused a fresh inflammatory movement; or it may be that the wound as a whole has taken on a septic condition. When no such causes as these can be found in connection with the case, the surgeon of to-day will regard the fever as arising from conditions foreign to the wound itself.

In this view of the matter we must suppose that some material has been elaborated in connection with the process of inflammation which, when taken into the blood, has the effect of disturbing the existing normal relations between heat-production and heat-dissipation in such a way as to give rise to fever, or which increases heat-production. This, as we have seen, has been the direct result of the injection of the fresh products of inflammation into healthy animals; therefore in the light of the clinical history of wound surgery, and the connection of fever therewith as related above, we cannot escape the conviction that the fever in each instance has a material cause in the absorption of the products of inflammation directly from the wound into the circulation.

In pursuing the clinical history of this subject farther we shall find that fever is also produced by inflammations independently of the formation of pus, though not so generally perhaps; yet the number of cases in which the fever is developed before the beginning of pus-formation is really very large. Then the cause of fever, in these cases at least, is not necessarily the absorption of the pus itself, but of the products of perverted cell-action which precede the development of pus. Some reference to these products have been made in the study of the process of inflammation as relating to the activity of the tissues. In this per-

version of cell-activity under the influence of, or as a result of, irritation or tissue injury, products of an abnormal character seem to be formed which, when carried into the circulation in sufficient quantity, serve to inaugurate the condition of fever. On the basis of observations similar to those cited above Dr. Sanderson speaks of the "infective" power of the products of ordinary inflammation, and arrives at the conclusion that "fever is the product of a fever-producing cause contained in the blood or tissue-juices, the morbific action of which on the organism is antecedent to all functional disturbance whatever;" and speaks of fever as "from first to last a disorder of protoplasm."

It is not necessary to suppose that all fevers result from the products of inflammation; indeed, such an hypothesis could not be maintained upon the facts at present in our possession, for many cases of fever occur which are in no way related to inflammation, so far as physical examination has thus far developed. This seems to be but one cause out of many. It seems probable that there are other forms of perverted cell-action, not yet known to us, which take place in the economy and are capable of giving rise to products which may act as a cause. Putridity is regarded as a cause, and the soluble sepsin of Bergman, which is undoubtedly the waste product of certain micro-organisms, and which holds a close relationship to the alkaloids of the higher plants, has been demonstrated experimentally to be capable of producing fever when introduced into the system. Besides this, a number of micro-organisms have been proved to stand in a causative relation to fever, and other causes will in all probability be identified in the near future.

The supposition so widely held that fever has its origin in irritation, which has given rise to the terms "irritative fever," "sympathetic fever," "fever from constitutional irritation," seems not to be maintained. The most persistent experimentation with that end in view has failed (in dogs) to produce fever by the irritation of peripheral nerves. Dr. Billroth has made these experiments in various ways, as by forcible injections of air into the subcutaneous tissue, by exposing nerve-trunks and irritating them with ammonia, by suspending weights to nerve-trunks, by tearing the inner coats of the vessels, by injecting powders into the blood so as to form emboli, by rubbing the ears with croton oil, etc., and in no case did he succeed in producing immediate fever. On this and similar experimentation he arrived at the conclusion that fever always has a material cause. Various other experiments have been made with this end in view, and after a close review of them it seems that the conclusions of Billroth are maintained. This idea of irritative fever has been so widely held, and has seemed so well sustained by clinical observation, that it is displaced with difficulty; but, as Prof. Wood so aptly says, "as our knowlege grows, fevers supposed to be due to peripheral irritations are shown, one by one, to have their origin in toxæmia."

Still, it seems hardly possible that all of the fugitive fevers that we see, many of them enduring only for a few hours and then passing away with complete restoration of health, or those mild febrile reactions of childhood that arise seemingly from slight intestinal irritations, the

fever so common during the cutting of the teeth of children, and the like, all come from an actual poisoning of the blood. However this may be, it is now very certain that all of the graver forms of fever which were formerly supposed to arise from irritation are due to a material cause circulating in the blood.

How the fever-producing poisons act in the production of fever, or upon what tissue, cannot now be certainly affirmed. It does not seem probable that their action is on the general protoplasm of the body. If this were the case, fever would often be expressed locally, for it is hardly conceivable that in all cases the poison could be so perfectly distributed that no local expressions of its action should be noticed. Then it must act on the blood directly or on the nervous system. These two form systems that are more general and widereaching in their bonds of union with the system at large than any other. The nervous phenomena of fever are so prominent that in the absence of exact experimental evidence we would naturally look to it as the system most prominently affected. It is well known that certain poisons affect certain portions of the brain or nervous system prominently when they gain access to the circulation and are carried to the particular part by the blood. This is seen in the action of alcohol, of opium, of strychnia, and many other drugs. All of these in a certain sense act as blood-poisons; that is to say, they reach the tissue upon which their impression is made through the medium of the blood. It seems most probable that the fever-producing poisons act in the same way. Of ordinary malarial fever Prof. Wood says: "The chill, the fever, and the sweating in their regular sequence and their periodical occurrences most plainly bear evidence to a neurotic origin." The same author calls attention also to the well-known fact that the paroxysm of fever may be replaced with a paroxysm of neuralgia "and various local vaso-motor and secretory disturbances" which can with difficulty be conceived as being induced otherwise than through the nervous system.

The discussion of our present knowledge of a probable heat-centre, or several centres acting in unison in a state of health for the control of the temperature of the body, in its relations to fever-production would lead me beyond the space alloted to this article. The experimentation that has been had, especially that by Prof. Wood, amounts almost to a demonstration, although the centre is not precisely located. The complete demonstration of such a centre, and of its powers and capabilities, will add greatly to our knowledge of this important subject. So far, it has been definitely determined that irritation of certain portions of the brain affect heat-production and heat-dissipation in a very marked degree; and this knowledge seems entirely sufficient to serve as the basis of the doctrine set forth above. On this basis Prof. Wood formulates the following: "Irritative fever, if it exist, is produced by an action on the nervous system. Fever occurring in case of blood-poisoning is often, and probably always, the result of a direct or indirect action of the poison on the central nervous system, and hence is a neurosis."

Results of Fever.—The usual tendency of fever is toward self-limitation. In other words, the tendency is toward a spontaneous

return to health after some days—more or less according to the nature of the cause. For instance, in the case of a common boil of moderate severity we should expect a rather mild form of fever, lasting one or two days and then passing away. In inflammations of greater extent a greater rise of temperature and continuing for a longer time would be expected. In cases of acute alveolar abscess there may be a temperature of 104° F., running for two or three days. This, however, may be regarded as rather unusual, and when it occurs marks the case as a somewhat grave one, with the probability that some necrosis of bone about the root of the affected tooth will occur. This necrosis is not caused by the fever, but results from the severity of the inflammation causing the fever. Therefore the severity of the fever is some indication as to the severity of inflammations. It may be stated that all of the symptomatic fevers which accompany the slighter forms of inflammation, such as I have mentioned, pass away spontaneously within a few days. In the continued fevers the cause is more persistent, and evidently remains in action for a much longer time, this differing much with the various forms of these affections.

If fever exceeds a certain degree, it becomes in itself dangerous to life. It rarely exceeds 107° or 108° F.; that is to say, this intensity of fever, or a rise of the temperature of the blood to this degree, is usually fatal if it continues many hours. Some time since there came under my observation the case of a young woman from whom the ovaries had been removed for the cure of violent and persistent hysteria: the temperature began to rise a short time after the operation, the increase continuing rapidly and steadily in spite of all efforts to counteract it. Within ten hours it had passed 108° F., and in another hour the patient died, with the thermometer indicating the extreme temperature of 110°. After death the temperature continued to rise until 112° was reached. It is usual for cases having a temperature of 108° or over to prove rapidly fatal, although some instances of recovery after a much higher temperature had occurred have been reported. Therefore, the upward limit of fever is controlled only by the endurance of the particular patient. There is usually no great danger from fever until 106° is passed, unless the high temperature be long maintained; but this temperature is not to be endured very long without remission. In the continued fevers, in which the temperature reaches this height, there are regular remissions, usually corresponding with the diurnal fall of temperature in health, which seem to relieve the patient and enable him to endure the very high temperature of the evening.

Persons sometimes succumb to a much lower temperature, though this is rather unusual unless there is some other cause of death co-operating. A few years ago I had under observation a case of seemingly mild type of typhoid fever in which the patient became comatose, and died on the tenth day, the fever not having risen above 103° at any time. Post-mortem examination revealed the usual lesion of this stage of the disease, but this was mild in degree. No cause of death was found other than the fever.

From the nature of fever there must be much injury to the tissues, especially if the febrile movement is intense and long continued. The

injury to the nervous structures is manifest in the delirium and other perturbations of the mental faculties that so generally accompany severe fevers. In severe and long-continued attacks the muscles are especially affected by the destruction of the sarcose element of the fibres. In this way portions of the fibres of certain muscles are occasionally injured to such an extent as to cause lameness for some time after recovery. The general emaciation has been spoken of: this is the usual result of fever; all of the tissues suffer waste, but the fatty tissues are perhaps destroyed to a greater extent than any others.

Shock.

Shock is a sudden and notable depression of the vital powers resulting from an injury more or less grave, or from an impression made on the nervous system through the medium of the sensorium, as by fright, sudden and overpowering mental emotion, etc. In its phenomena it seems to consist of a sudden check of the circulation brought about through the agency of the nervous system: this may be so grave as to cause instant death, or may result in prostration more or less prolonged, with or without a successful reaction following it. It was long ago noted that death sometimes resulted suddenly after injuries that left no trace of their destructive effects on the vital organs, and that many instances in which death was less immediate could not be explained by the visible effects of the injury sustained. It frequently occurs that persons who have sustained some injury sink into a state of prostration not to be accounted for by the severity of the hurt, such persons, even though apparently moribund, being sometimes within a day or two restored to their usual health and vigor. These cases can be explained in no way other than upon the supposition that the nervous system had been suddenly overpowered. Hence the term *shock*. *Collapse* is also used in the same sense.

It is not to be inferred that there is actually no tissue-change in these cases, but there certainly is none that can be recognized by our physical senses through either macroscopic or microscopic examination. It cannot be supposed, however, that such grave symptoms can occur without some molecular disturbance in the nerve-cells which for the time renders them incapable of the proper performance of their functions.

The cause of shock has been a subject of much inquiry, especially among surgeons, who are continually brought in contact with the graver forms of this condition. The general nature of shock remains the same, no matter whether it result from bodily injury or mental impressions. Diminished energy of the nervous system, resulting in enfeeblement of the circulation, is prominent in every symptom, and the general reduction of the vital powers seems to depend on this for its inauguration and continuance. The injury to the nervous system is especially manifest in the demeanor of the sufferer, and this is expressed in a variety of ways. In one case a person who has received a serious injury may for a time apparently disregard it; he seems not to suffer pain, and is possessed of a calmness that under the circumstances is entirely unnatural, while at the same moment the surgeon will perhaps

discover a marked pallor, soon followed by coldness of the skin. The pulse becomes weak, small in volume, and passes under the finger with a peculiarly short and quick stroke, denoting an extreme relaxation of the vascular system. The failure of the nervous system is seen in other directions as well. Questions are answered slowly and hesitatingly, as though not fairly understood; the tone of the voice is changed, and perhaps markedly enfeebled. The motions of the patient may show extreme weakness; sentences give place to monosyllables; and the patient may sink into a state bordering upon unconsciousness, in which he takes no notice of what is going on around him. He may recover from this condition speedily, with full restoration of the normal tone and vigor of the nervous system, or recovery may be delayed indefinitely. There is, however, generally a reaction within one or two days.

In other cases all of the more profound symptoms of shock may occur suddenly. Coma, or even death, may almost immediately follow the receipt of a comparatively trifling injury or from mental impressions that in other persons, and perhaps in the same person at another time, would scarcely be noticed.

Shock differs materially from syncope. Emotion, the sight of a wound, and various trifling circumstances may cause a momentary stoppage of the action of the heart, with a temporary loss of consciousness, and not be productive of shock. The production of shock evidently involves some other factor, for instead of a temporary arrest of function there appears to be a real injury to the structure upon which the functioning power depends that renders immediate recovery impossible. Time must be had for recovery from this tissue injury, and during this period these functions are imperfectly performed, apparently from lack of power. The symptoms seem to point to the failure of those nerve-centres that maintain the proper tension of the vascular system. Normally, the walls of the arteries are contracted upon the blood they contain, so as to keep up a certain degree of arterial pressure, this being to a lesser extent complemented by the veins. In shock there is a sudden letting go of this tension, of this grasp on the blood. The vascular system is relaxed abnormally, and in such a manner as to interfere with the circulation. At the same time there is a relaxation of the energies of the heart, but not a stoppage as in syncope, except it be in some of those grave forms that result in almost instant death, in which this point cannot well be studied and distinguished from other symptoms. The rule is that the heart maintains its action, but in a very feeble way; and it appears to have been shown by experiment on the frog that even when the heart is stopped it may be induced to resume its action by supplying it with blood. Prof. Goltz of Strasbourg performed the experiment in this way: A frog was suspended in a vertical position with the legs hanging down and the heart exposed. After a few moments' delay, to see that the circulation was going forward normally, the animal was struck a smart blow on the surface of the abdomen. The heart stopped its contractions at once, and after a few moments began again feebly, but it was clear that it was propelling no blood into the aorta, for the upper part of the vena cava was empty and no blood was supplied to

the heart. The effect of the blow seemed to have paralyzed those nerve-centres which control the tension of the vascular system, causing such a dilatation of the vessels of the abdomen particularly that the blood did not fill them, and the heart was unable to proceed normally for want of the usual stimulus of a proper blood-supply. When the animal was laid down, so that gravitation would bring the blood to the heart, the normal pulsations were resumed. It is clear that the animal could not have recovered had it remained suspended, for without the circulation, which under the circumstances could not be resumed, the nerve-centres could not recover their vigor. But with this the tension was soon restored. This experiment shows that an animal—and probably a man as well—may bleed to death without the loss of a drop of blood, simply by the dilatation of the vessels to such an extent that they shall not be filled with blood. It is probable that the great vessels of the abdomen when utterly relaxed will contain the whole blood of the vascular system, and in this condition it will for the time be as completely lost to the system as though it had been poured out. This seems to indicate the exact manner of death in some of the cases of shock already alluded to. Savory states that instant death may occur from a blow on the epigastrium which, though severe, leaves no detectable lesion; and Mansel-Moullin relates a case of sudden death from shock caused by the introduction of a trocar into a cyst of the liver, in which the tissue injury was so trifling that death could not be explained except on a supposition of a paralysis of the vaso-motor centres.

These facts seem to show plainly the nature of the condition which is known as shock or collapse. The vaso-motor nerves are for the time rendered inoperative, and in this way the circulation is so enfeebled, when not cut off entirely, that its functions are imperfectly performed, and the whole system suffers in consequence. There seems to be a positive enfeeblement of the heart as well, probably from the same cause, for in those cases of the lesser degrees of shock the effect on the heart seems to be the prominent factor, at least the most marked symptom. Yet in all cases the character of the pulse, which is very short and compressible, speaks plainly of lack of arterial tension. The heart is so far independent of other innervation than that contained within its own walls that it is capable of continuing its regular rhythmical actions when all other sources of nerve-supply are cut off. The great nerve-centres may be removed one after another until the last one is severed, and yet the nerves contained in its own walls will serve the purpose of continuing its motions. At the same time, it is so connected with these great nerve-centres that the irritation of one of its connecting branches may bring it to an immediate stop. Not only this, but irritation applied to a peripheral nerve may produce the same effect through reflex action. We have also learned through direct experiment, some of which was detailed while treating of hyperæmia, that the blood-vessels, veins as well as arteries, are under a control of the same nature and are affected in the same way by similar causes. While all of this is true, and the heart may be stopped by these reflex impulses, and the tone of the arteries may be relaxed, the local nerves of the heart will, after a time, set up these actions anew independently of other nerve-influence. It is

not shown that the blood-vessels will recover their tone so readily as the heart, but, on the contrary, experiment and clinical observation combine in the illustration of the fact that their enfeeblement is recovered from with much greater difficulty.

The molecular disturbances in shock should not be passed over without notice. All function is directly dependent upon remolecularizations of matter, or at least molecular motion or chemico-vital changes in some form. This is the opinion of the scientific world at the present time. In the performance of labor by the muscles the sarcose material of the fibres undergoes molecular changes with every contraction, and these changes result in the formation of waste products which are eliminated. Therefore if these changes occur with such rapidity that this cannot be resupplied by the nutrient functions in the necessary proportion, the muscle becomes exhausted; rest is then necessary that nutritive repair may bring the muscle up to the normal standard again. That which is true of the muscles is true also of other tissues. If in any case a functioning tissue is called upon for an extraordinary expenditure of energy, exhaustion occurs very quickly. In the case of shock the nervous system is overcome, and fails either partially or altogether in the performance of certain of its normal functions, such as that of maintaining the usual tension of the circulating system, and to a lesser degree, perhaps, that of cerebration and the voluntary motions. This, however, is not the only injury that occurs in shock. Under some circumstances the life-force as it exists in the individual cell is unable to carry forward in the normal manner its remolecularizations of matter in the processes of nutrition and denutrition, and the changes become abnormal, resulting in the formation of substances unhealthful in quality or quantity. This is seen in fatty degeneration. The tone of the life-force as it exists in the individual cells is lowered to such a degree that the matter of which the cell is composed, instead of passing regularly on to the formation of waste products in the normal manner, falls into the molecular groupings of oil. This oil gathers in the form of minute globules in the midst of the cell, instead of passing away with the normal waste products; which circumstance permits of its discovery by means of microscopic examination—a thing that would be impossible if the abnormal substance were more soluble. Changes of a similar nature undoubtedly occur in shock, though they differ in the character of the products. Just what these changes are is unknown, but the evidence that they occur is to my mind conclusive. It has long been known that fright, or any other form of mental impression productive of a slight degree of shock, is liable so to change the milk of the nursing woman that it will act as a poison to the child. This can be explained only on the supposition that the chemico-vital changes—the remolecularizations of matter—which take place in the formation of the waste products, and in the elaboration of the secretions as well, have been imperfectly, or at least improperly, carried on, and have resulted in the formation of abnormal molecular groupings, thus giving rise to chemical substances that prove injurious.

In the discussion of the subject of fever it was explained that it was always the effect of a material cause. One of the most common

of these is always produced in the peculiar tissue-changes that are taking place in the process of inflammation, and we find fever to result in case the inflammatory movement is considerable. All forms of shock are followed during the stage of reaction by fever. The regularity of the occurrence of this fever leaves us no room to doubt that it has resulted from some injury to the tissues which has rendered the performance of the chemico-vital remolecularizations both difficult and imperfect in their results, so that molecular groupings are formed that give a chemical substance capable of producing fever. There is, then, in addition to the paralysis of the vaso-motor nerve-centres, or as a result of this, an injury to some portion of the tissues; and this may be the nerve-tissue through which the chemico-vital changes are rendered imperfect or abnormal.

The symptoms of shock vary indefinitely in its different manifestations, but these differences are more of degree than of kind. In its extreme forms its features are plainly marked. The appearance of the patient is that of the most extreme prostration. There is pallor of the face and of the whole surface of the body; this is also very apparent in the mucous membranes where they are exposed to view, as in the lips and mouth. The surface is abnormally cold, and is covered with moisture, sometimes like great drops of sweat, cold and clammy in character. The features appear pinched and dull, the eyelids are drooped, and the eye itself seems to have lost its wonted expression. The debility of the muscular system is apparent in every motion if the patient attempts to move at all, and even in his position when he is motionless. The respiratory movements are usually feeble and short; they may be panting and irregular or gasping, and in the most grave conditions may be scarcely perceptible. The pulse is generally frequent, though it may be rather infrequent, and occasionally quite irregular. It is always very weak, and passes under the finger with a short quick stroke, leaving the artery soft and limp between the heart-beats, and is very compressible, indicating the extreme relaxation of the arteries. The temperature is always more or less reduced, and it seems that the amount of the reduction is some indication of the gravity of the case, though some of the cases with very low temperature recover even after a temperature of 93° F., and Wagstaffe reports a case that recovered after the extreme depression of 91.5° F. had been reached. The mind is generally clear, but the person may be drowsy and bewildered when aroused. In a minority of cases the senses are unusually acute—so much so that the patient seems continually on the alert and bordering on a condition of excitement. In this latter condition questions may be answered in a quick, jerky manner, but more generally they are answered hesitatingly, as though very slowly comprehended.

These symptoms may vary in degree from a condition in which death occurs within a few moments or a few hours to that of an impairment of the functions to so slight a degree as to amount to nothing more than an expression of weariness. Every conceivable condition between these extremes may be noticed. In the medium or lighter forms of shock there is often seen that which Travers has aptly termed "prostration with excitement." This may be present from the first, or it may

become apparent during the following reaction. The patient may seem perfectly frantic and tortured with the most terrible forebodings, in which condition no question will be answered or apparently noticed. I once witnessed a case of this kind in a man who had had both legs crushed under a railway-car, and who screamed the same words almost continuously until stopped by the administration of an anæsthetic preparatory to amputation. In this condition nothing in the way of encouragement is heeded, no form of advice or counsel is of any use, though there seems no lack of consciousness. The mind is too completely occupied with the terrors of the situation to admit any other mental impression. In all of this the condition of the circulation and of the skin, and all of the other symptoms except those relating to the condition of the mental faculties, are the same, only perhaps less in degree, as in cases of profound shock with stupor. This, like all of the other conditions of shock, may be manifested in all degrees from a mere watchfulness to the most complete delirium.

The liability of indirividuals to shock seems not to be regulated by any known laws. One person dies from shock under apparently the same circumstances under which another escapes it entirely. Nothing definite can be stated as to the liability of this or that individual to shock under given circumstances; yet it may be affirmed that as a general rule those whose constitutions have been broken down by debauchery are more liable to shock than others. Individual idiosyncrasy that cannot be determined in advance seems to have much to do with the difference of liability. Taken all in all, it may be said that the liability to shock is in proportion to the extent of the injury. Hence grave forms of shock are oftenest seen in connection with serious injuries and extensive surgical operations. Extensive burns, scalds, and contusions, crushing wounds and capital surgical operations, are most often attended with grave forms of shock. The danger seems to be greatest in case of wounds of the trunk, especially of the abdomen, and decreases as the seat of injury is extended along the extremities. A comparatively large proportion of cases of shock have been observed in connection with railway accidents, resulting in part, perhaps, from sudden suspension of motion or from being thrown violently against objects, and in part from fright. Mansel-Moullin states that "instances of severe and lasting shock, often assuming most insidious forms, are met with from time to time in cases of this kind, without there being any definite bodily lesion, and, indeed, are often the more severe when this is quite absent and there is no other explanation than the general mental cause." Some years ago I observed a case illustrative of this. A car, when at full speed, was thrown violently down an embankment, and fell on its side. One of the passengers fell with his hands through a window, where they were caught between the car and the ground in such a way as to hold him fast. The car immediately took fire and was burning rapidly when he was rescued. When I saw him, four hours after, he was in a state of profound shock, in which he took no notice whatever of what was going on around him. No bodily injury was found except a slight cut on one cheek made by glass. Reaction began in about twenty-four hours, and he made a good recovery.

Reaction from shock varies extremely in different cases. Sometimes it is prompt, and the usual health is resumed rapidly and perfectly. In other cases it is tardy, and the patient lingers along for days and weeks without marked improvement; and it is noteworthy that this is as apt to be the result in the lighter as in the graver forms of shock. As a rule, reaction may be expected to begin within one or two days. During the reaction the temperature, which is below the normal, usually rises several degrees; and the rule is that there is marked though not very intense fever. The occurrence of this in a mild degree is regarded as favorable, and when it occurs promptly the patient will usually go rapidly on to complete recovery. If it is delayed and not well marked, recovery is generally slow and often very imperfect. The principal thing to be done is to give the patient quiet and as perfect rest as possible. The large majority of surgeons recommend the judicious use of stimulants, especially brandy, for the purpose of favoring reaction; but a few—notably the late Dr. J. T. Hodgen of St. Louis—reject this treatment as bad practice, and prefer to depend on complete rest. The mental condition is of importance. The mind should be as much at rest as possible, and especially should sleep be had. Most surgeons agree in the use of opium, when necessary, to procure this. Among other stimulants, strychnia, belladonna, and digitalis have been used with advantage.

Shock resulting from dental operations seems not to have received due consideration in past years, for the reason, perhaps, that it is seldom seen in its graver forms. It should not be forgotten, however, that it is liable to occur at any time with all of its attendant dangers. But it is the lesser and more insidious forms of shock that are most to be feared as a result of dental operations. The following passage from Mr. Savory's article on this subject in Holmes's *System of Surgery* is applicable here:

"Hitherto, the influence of shock has been considered only in its extreme effects when directly producing a state of collapse, but it must be a very narrow view of the subject which would overlook its less severe though much more frequent results. It may operate in any degree, and produce in one case, as has already been seen, instant death, or a state not to be distinguished from it for a time even by the most anxious scrutiny; in another case effects so trivial that the symptoms pass unnoticed or unheeded by a superficial observer.

"There are many cases on record, and many more known to every surgeon, of death from this cause, less sudden, but in many instances scarcely less inevitable. In some cases injuries or operations comparatively trivial in their nature induce a condition of otherwise unaccountable debility, and terminate in death by asthenia. A careful inquiry into the history of such cases will often elicit facts which enable us to reconcile the apparent disproportion of cause and effect.

"After injuries or operations sufficiently severe to produce a serious impression on the system, yet by no means amounting to a condition of collapse, reaction is sometimes defective and unduly delayed. The patient remains depressed; there is no heat of surface; the pulse is weak and perhaps unsteady; he does not sleep soundly, though he may

be constantly dozing; and the stomach is often irritable. In a word, there is an absence of 'sympathetic fever.'"

In these paragraphs we find an expression of conditions that not unfrequently follow as a result of dental operations. They are closely akin to what is known as nervous exhaustion, but approach closer still to the condition of true shock in its lighter manifestations. These two conditions grade into each other in such a way that no exact line can be drawn. The major forms of shock occur suddenly from some impression that overpowers the nervous system at a single stroke, producing a marked dilatation of the whole vascular system, so as to leave the heart without a due supply of blood. Nervous exhaustion comes on very slowly from some cause that continues to act, and is often very insidious in its approach. It occurs oftenest, perhaps, from too continuous employment, mental strain, or any continuous condition that overtaxes the nervous energies for a considerable time. In many cases the minor forms of shock do not occur so suddenly as is usually the case in the major forms, nor so slowly as in nervous exhaustion, but are usually the result of more or less prolonged pain, nervous irritation, mental excitement, or some form of extraordinary effort. On this point Mr. Savory, after describing the more immediate results of shock, says: "But the effects of a shock to the system are not always thus limited in their nature and duration. Those which have been described may be termed primary or direct, but sometimes these are succeeded by those that are more remote and secondary, including perhaps, after a shorter or longer interval, grave mischief, or it may be even death. It is not uncommon to have various forms of local disease or disturbance of the general health referred to some previous shock which the system has sustained. 'He has never been the man he was since—' is a familiar allusion to a case of this kind; and after making every allowance for exaggeration and misinterpretation, the relation of cause and effect between some previous shock and present mischief may often be clearly and unequivocally established."

Such results as these are liable to happen occasionally in dental practice, and the lighter manifestations of shock are of frequent occurrence. A patient, perhaps a lady, presents herself at the time of her appointment to have several fillings inserted. There may be some special reason on her part or on the part of the operator for a long sitting. As the operations progress it is found that they are very painful, yet the patient is anxious to have them done with, and makes an heroic effort to bear the pain so that their accomplishment may not be delayed. Thus the operations go forward for one, two, three, and it may be four hours continuously. The operator may even be encouraged to persist by the not unusual fact that the patient flinches less in the third hour than in the first; but if he would follow up the pulse from hour to hour, he would find certain changes taking place. It will have lost markedly in tone and volume, and as it passes under the finger may perhaps present a peculiar thrill that was not present at the beginning of the operations. Sometimes it will be more frequent, sometimes less. There is also a perceptible change in the character of the motions of the patient. They may be quick, with a slight inclination to jerkiness, or

be languid and unusually slow. The face is pale, and the thermometer shows a slight reduction of the temperature. The patient is finally discharged, and goes her way without any very decisive sign that there is anything wrong; but she has a restless night, and the next day there is slight fever. This is of a mild type perhaps, and occasions no great uneasiness, or it may be more severe and accompanied with a feeling of great weariness. In the more ordinary cases this passes away in from three to five days with complete restoration to health, but occasionally the patient falls into a state of nervous exhaustion from which she rallies very slowly.

I might give a number of cases coming under my observation illustrative of this, but one or two must suffice. One of the most notable of these was observed some ten years ago. A young lady of eighteen came from a distance by appointment to have carious teeth filled. Upon examination it was found that there were two exposed pulps, besides other smaller cavities. Both the young lady and her parents insisted that all should be done that day if it was possible, it being necessary that they should return on account of important engagements: the lady said that she had no fears as to bearing any necessary operation, even the direct removal of the exposed pulps. The operations were proceeded with, and everything was borne without a murmur. My patient was a fine specimen of physical development, and I soon found that she prided herself on her powers of endurance. The pulps were, at her urgent request that there should be no delay, removed directly with the broach, and the filling proceeded with. After three hours of continuous operating the patient was discharged for two hours' rest. She returned promptly, but something in her appearance arrested my attention as not being just right, yet in answer to questions she said she felt perfectly well, only a little tired. The operations were resumed, and all went well at first, but after an hour, the latter part of which had been occupied in the excavation of a very sensitive cavity, I found that the pulse had become very easily compressible and other evidences of shock were becoming very apparent. Gutta-percha fillings were placed in the cavities excavated and operations suspended. I found it necessary to assist her to a couch, as it was evident that she was unable to walk steadily. After two hours in the recumbent posture she seemed better, and was taken to the train by her parents, and went home, some fifty miles by rail, and I saw her no more. I afterward learned from her mother that her condition became much worse *en route* home, and that for four or five days she was in "a stupid condition," and after this she passed into a nervous fever which continued for several months. Up to the time I last heard from her, four years after the incident, she had been more or less an invalid.

In dental practice the temptation to overtax patients who are so situated that it is very inconvenient for them to make frequent visits is very great, and great care should be exercised to avoid evil results. The case I have given is an extreme one, it is true, but many cases of a less grave character occur, and from much more trivial operations. Only a short time ago I placed fillings in two lower molars for a lady of about twenty-three, at the time in rather delicate health, though she

considered herself fairly well. The teeth were quite sensitive, but there was no unusual difficulty. The operation was followed by very decided shock, sufficient to confine her to the bed for several days. After six weeks the operations on other teeth were undertaken, special care being exercised; yet after an operation of an hour's duration there was decided prostration, followed the next day by fever and restlessness. This patient was evidently extraordinarily susceptible to shock, but the case serves to illustrate the necessity for due care in the performance of dental operations, and especially the necessity for a close study of this subject by dentists as well as by other specialists in medicine.

DENTAL CARIES.

By G. V. BLACK, M. D., D. D. S.

Introduction.

Caries of the Teeth consists of a chemical disintegration of the elements of the tooth, molecule by molecule. This disintegration always begins on the surface of the tooth, usually in some pit, groove, or other irregularity, at the point of contact of the proximal surfaces and about the necks of the teeth. Such places are protected from the friction of mastication and the movements of the lips and tongue, thus favoring the lodgment of particles of food until fermentation takes place, this resulting in the formation of products which decompose the constituents of the tooth. When a beginning has been made, the destructive process spreads toward the interior of the organ; and, as the dentine is more readily affected than the enamel, a cavity is formed whose interior is larger than its orifice. This cavity enlarges very gradually—so slowly, indeed, that usually, if examined at an interval of a week or a month, no progress is appreciable. But if the examination be instituted after an interval of two or three months, it will generally be found that progress is very decided. Thus, the area of the decay increases steadily until the crown of the affected tooth is destroyed. There are, however, in different cases great variations in the rapidity with which the disease advances. As caries progresses, the enamel, on account of its greater resistance to disintegration, is undermined by the solution of the dentine and is left unsupported; the enamel itself, however, also slowly disintegrates on its inner surface, and finally breaks away, leaving an irregular jagged opening. This effect is extremely variable. Sometimes the breaking away is such that the cavity is widely open before there is very much destruction of tooth-substance; in other cases a larger portion of the dentine may be destroyed, while the enamel remains almost perfect.

The color of caries varies from an ashy gray or white to a bluish or deep black. Every shade between these may be found. Many of the intermediate colors have something of a yellowish hue. It is common for the decayed mass to present different shades of color in different parts. The rule is that the outer parts are darkest, while the inner approach more nearly the color of the tooth, or may even be lighter in shade. Occasionally other colors may be seen, but I am persuaded that these are accidental and dependent on some unusual extraneous deposit. Those decays that present in the greater part of the mass the nearest approach to the color of the tooth, or are lighter in shade, rep-

resent those that are rapidly progressive; while, on the other hand, those that present a deep-black appearance throughout their mass are making very slow progress or have ceased to progress at all. These latter have been termed stationary decays.

It is not necessary that all the elements of the tooth-substance be disintegrated to constitute caries. In most cases of rapidly progressive caries there is remaining in the softened mass a sufficient amount of the original elements to preserve the histological forms of the dentine. This serves to separate caries sharply from certain other accidents and diseases to which the teeth are liable, among which I may mention mechanical abrasion, spontaneous or chemical abrasion, and the absorptive processes. In these the constituents of the dentine are removed entire, and in the first two the surface is left hard and firm, while in the latter the softening is very slight indeed. These must not be confounded with caries. They will not be considered in this article except as they stand related to true caries. In caries the elements of the dentine are always removed piecemeal, producing first a softened mass, which afterward suffers further disintegration, and finally falls to pieces, forming a cavity. Therefore, it is a constant condition of progressive caries that those portions of the decaying mass that are nearest the sound dentine are comparatively little softened, and upon microscopic section present the histological forms of the dentine with but little change. As we recede farther from the junction of the diseased part with that which remains normal, we find that the disintegration is progressive until all trace of the original form-elements are lost, and we have nothing remaining but débris or an open cavity.

Caries of the teeth has been known in all historic ages of the world, and wherever prehistoric human remains have been discovered traces of this disease have been found. It seems to be, and to have been, universal in the sense of affecting all nations and tribes of the human race. All have not been equally affected, but no race of men seems to have escaped its ravages. It has been thought that the savage races were not so much afflicted as the civilized, but my own study of the remains of ancient peoples will not bear out this opinion. This research has, however, been limited within comparatively narrow bounds—too narrow, perhaps, to serve as the basis of conclusions. Unfortunately, the literature of the subject furnishes no data that are of much value in this direction, but what there are strongly support the statements made above. Some hasty examinations recently made of the condition of prehistoric skulls found in a number of the principal museums show that those peoples were subject to decay of the teeth to as great an extent as the civilized races of to-day. It is possible that future research upon this point will show that certain races which have lived in a certain way or upon certain kinds of food may have suffered less than others which have lived differently. The studies I have been able to make in this direction indicate that the races of men who have eaten largely of acid fruits have had less decay of the teeth than those who have been debarred by their position or climate from the use of such articles of food. Generally, those tribes that have subsisted largely on flesh and grain have suffered more from caries than those that have had a

more exclusively vegetable and fruit diet. Our knowledge upon this point is, however, too meagre to warrant any lengthy discussion of it.

Among the individuals of the same tribe or nation there are observed the greatest differences in the liability to caries of the teeth. Some persons in almost every community escape it entirely, while others, their neighbors, subjected seemingly to the same influences, suffer from its ravages. The reasons for this are wholly unknown. The persons who escape this disease are, however, comparatively few. There is no disease that is so common or so widespread or that so generally afflicts the human family.

Etiology of Caries.

In the study of the causes of disease it is common to divide them into predisposing and exciting. The predisposing causes are such as render the individual more liable to attack, but are not in themselves sufficient to usher in the disease. The exciting causes are such as are actually responsible for its inauguration. It is the custom of writers on pathology to consider the predisposing causes of the particular disease under consideration first, and this is usually the most natural order of presentation; but in the present case there seems to be sufficient reason for reversing this order. It does not appear that the previous consideration of the predisposing causes will materially contribute to an understanding of the exciting causes, but these will be much easier understood after the exciting causes have been studied, and the presentation will thus be simplified.

It seems well, however, that in the beginning of this study we notice the views that within a century past have from time to time been presented, and which illustrate the growth of thought as observation and experience have added fact after fact to our knowledge of the subject. It has been treated of by very ancient writers, but the works of Boudett and Jourdain, which appeared within the interval from 1754 to 1766, seem to have been the foundation of the scientific investigations that were undertaken in after-years, and mark an era of awakening thought and of experimental study. Before this time many had written, and in a sense had written well, but they seem to have recorded such thoughts as came to them from what, as compared with the authors mentioned and those that came after them, may be considered casual observation. The common thought of the medical men of those days was that decay of the teeth resulted from inflammation, and the effort was to account for its phenomena on that hypothesis. John Hunter, who was a very close observer and a careful writer, while regarding caries of the teeth as resulting from inflammation, much in the same manner as necrosis of the bones or mortification of the soft parts, expresses dissatisfaction with this idea, deeming it insufficient for the explanation of the phenomena of gradual decomposition with the formation of the carious cavities. He does not, however, offer any theory on this point.[1]

[1] This is fairly shown in the following extract from the work of John Hunter (*Practical Treatise on the Diseases of the Teeth, and the Consequences of them*, 1778): "The most common disease to which the teeth are exposed is such a decay as would

Mr. Fox in 1806, and others of about this period, were much more exact in their descriptions of the processes of caries. It was regarded as resulting from inflammation of the lining membrane of the pulp-chamber (membrana eboris). This, in case it was severe, was regarded as depriving the dentine of its nutrition, and, it was supposed, would occur at isolated points within the pulp-chamber, as in inflammation of the periosteum of the bones, causing the death of certain portions of the dentine, which would then decompose with the formation of the carious cavities.

Mr. Bell as late as 1829 still regarded caries as a result of inflammation, but gives a different explanation of the process. He assumes as a cause an inflammation of the dentine beginning immediately beneath the enamel, or, in other words, in the superficial portions of the dentine, resulting in the death of the part inflamed. This dead part then acts as an irritant, causing the continuance of the inflammation, and thus the process is progressive until the destruction of the crown of the tooth is accomplished. He says:

"It (caries) may be defined, *mortification of any part of a tooth, producing gradual decomposition of its substance.* The latter clause of the definition is not, perhaps, essential, but it expresses the invariable condition of the disease.

"The true proximate cause of dental gangrene (caries) is inflammation, and the following appears to be the manner in which it takes place: When, from cold or any other cause, a tooth becomes inflamed, the part which suffers the most severely is unable, from its possessing comparatively but a small degree of vital power, to recover from the effects of inflammation, and mortification of the part is the consequence. . . . .

"The situation in which gangrene (caries) invariably makes its first appearance, immediately under the enamel, upon the surface of the bone, is, I think, explicable only with the view I have taken of the structure of the teeth and the nature of this disease. As the vessels and nerves which supply the bone of the teeth are principally derived from the internal membrane, it is natural to conclude that in so dense a structure the organization would be less perfect in those parts which are farthest removed from its source, and that, in the same proportion, they would be less capable of resisting the progress of mortification. . . . .

"The continued and invariable progress of dental gangrene is only to be accounted for by following up the same reasoning. When a portion of any of the other bones loses its vitality, it acts as an extraneous body, producing irritation in the surrounding parts, and a process of absorption is set up in a line of living bone in contact with it in order to effect its separation. A similar effort appears to me to be made in gangrene of the teeth, but with a very different result, in accordance with the difference in the

appear to deserve the name of mortification. But there is something more; for the simple death of the part would produce but little effect, as we find that teeth are not subject to putrefaction after death, and therefore I am apt to suspect that during life there is some operation going on that produces a change in the diseased part. It almost always begins externally in the small part of the body of the tooth, and commonly appears first as an opaque white spot. This is owing to the enamel losing its regular crystalline texture and being reduced to a state of powder, from the attraction of cohesion being destroyed, which produces similar effects to those of powdered crystal. When this has crumbled away, the bony part of the tooth is exposed (the dentine); and when the disease has attacked this part, it generally appears as a brown speck."

structure of the two seats of the disease. When a portion of the tooth is killed by inflammation, it excites, as in the other case, an increased action in the vessels of the surrounding portion of bone; but that very action, which in such bones as possess greater vital power becomes remedial by promoting the removal of the cause of irritation, produces in the present case the continued extension of the disease, for the irritation thus excited, instead of effecting the removal of the part by absorption, as in other necrosed bones, at once destroys its vitality and renders it only an additional portion of dead matter to that which had already existed. This, in its turn, becomes an extraneous and irritating body to the surrounding bone, in which the same action is set up and the same mortification produced; and thus portion after portion is successively irritated and killed, until the whole crown of the tooth is destroyed."

Dr. Fitch of Philadelphia, who wrote in 1829, also expresses very similar views, and in the second edition of his work, published in 1835, I find this view maintained and supported by citations of the works of Hunter, Fox, Koecker, and others.

Koecker, while holding opinions almost identical with those of Bell as to the part taken by inflammation in the initiation and progress of caries, adds a new thought. After a full and careful reading of his work, I should interpret his meaning to be about this: Decay is a two-fold process: the first of these is inflammation of the dentine, resulting in the death of a portion of the inflamed area; the second is the disintegration of this dead or mortified part by chemical agencies or putrefaction. While thus recognizing the agency of chemical processes in the production of the cavity, he supposes that they act only on parts which have been rendered inert by a preceding inflammatory process. He says:[1]

"One great cause of confusion and contradiction pre-eminently discoverable in every essay treating either theoretically or practically of this fatal malady (caries) of the teeth is the surprising manner in which the disease itself has been confounded with its effects, viz. putrefaction, or the living tooth under the influence of the disease, and the dead tooth which has been destroyed by it—an error by which authors have been led away from the subject in their inquiries and observations, and have been induced to adopt and to advance theories and practices false and unnatural in their facts and principles, as well as dangerous and destructive in their application.

"Caries of the teeth must be considered as similar to gangrene in other parts of the system. And where we speak of caries as a disease we mean that diseased action in the bony structure of the living tooth produced by the chemical irritation of its dead and rotten parts.

"Hence it is indispensable that we should make a due distinction between caries considered as a disease in the tooth and the effect of that disease—viz. mortification and putrefaction of its whole structure.

"Caries, in fact, is that state of the tooth in which mortification has taken place in one part and inflammation in the part contiguous to it, the former originally produced by the latter, and the latter continually kept up by the former."

Nevertheless, this author, in common with his contemporaries, describes two forms of caries—one beginning on the surface of the tooth,

[1] *Principles of Dental Surgery*, by Leonard Koecker, M. D., p. 111.

and the other beginning in the interior of the tooth-structure, internal caries. This latter he seems to have regarded as analogous to abscess occurring in the bone, and says:

"As the disease is more actively resisted by the greater vascularity, and consequent activity, of the internal structure than by the harder and less vital external parts of the tooth, it never proceeds so far toward the cavity containing the nerves as to render this membrane altogether unprotected by the bony structure, before it has penetrated through the external osseous parts, including the enamel, and has thus formed a natural outlet for the bony abscess."

It is curious how long and how continuously this old error of regarding caries as having its beginnings within the structure of the dentine was maintained—an error that, seemingly, should have been corrected by any reasonably close observer. Yet, with the then prevailing supposition that caries was the result of inflammation, there seemed to be no reason why it should not as readily have its beginning in the depths of the dentine as on its surface. Koecker makes a sharp advance, however, upon the observations of his predecessors, in that he affirms decisively that caries never extends inwardly so far as the pulp of the tooth without having first appeared on the surface of the organ.

It will be noticed that these views coincide with the theories of the causes of diseases of the bones in general, but especially those resulting in caries or necrosis. Decay of the teeth was regarded as a similar affection, but it was assumed, that, on account of their inability to repair the damages to their structure, the dead portion decomposed and a cavity was formed. The causes which were then generally regarded as leading to this inflammation were changes of temperature and other injurious impressions upon the surface of the teeth. It was, however, held by some that the causes might be wholly internal, and that decay might begin in the internal parts of the tooth (Fox) and work its way outward, not appearing on the surface until great damage had already been sustained. This opinion followed naturally from the supposition that decay resulted from inflammation beginning in the membrana eboris. In the bones inflammation of the periosteum may deprive the part beneath of nourishment and cause its necrosis; after this manner, inflammation of the membrana eboris was regarded as depriving the superimposed dentine of its nourishment, causing caries. But the supposition most generally advocated was that the inflammation began in the dentine, just beneath the enamel.

About 1830 the inflammatory theory was attacked by a very large number of intelligent dentists, and it was shown that, without great modification, it was untenable. Harris in America, Robertson in England, Regnard in France, and very many others, presented arguments against it. Among the most potent of these was that based on the fact that human teeth that had been removed, and afterward prepared and mounted as substitutes, artificial teeth made from ivory, etc., were as liable to decay as the natural organs. As such materials were then much used for these purposes, this fact was very generally noted. This decay, which was in all respects like that in the natural organs and ran

a similar course, could not have been caused by inflammation or by any vital process pertaining to the tooth itself. Hence the cause of decay must be regarded as extraneous to the teeth and acting upon them from without. Harris, especially, has given emphasis to another form of argument that deserves mention from its intrinsic importance in educating the mind to the appreciation of the fitness of any proposed remedy for a given disease. At the time the inflammatory theory was in vogue as explaining the nature of caries, the best authorities, although recommending the operation of filling the carious cavities, expected only temporary relief from it. But it was rapidly becoming the custom to fill the cavities for the purpose of *curing* the affection, also to remove superficial decay with the file for a similar purpose. In the hands of skilled persons these operations were becoming very effective. It is evident that if the decay of the tooth was the result of vital forces resident within its substance, these remedies would tend to increase the mischief they were designed to cure.

In 1835, Robertson of Birmingham, England, published his remarkable work,[1] in which he advanced the theory that caries resulted from chemical disintegration of the tooth-substance, and denied the agency of inflammation. This destruction was accomplished, he contended, by the action of an acid which was generated by decomposition of alimentary particles or of fluids of the mouth suffered to lodge about the teeth. These points of lodgment were shown to be the same as those in which caries made its beginnings, as in pits, grooves, and crevices, also between the teeth or about the margins of the gums.

Regnard of Paris also published a work in 1838 in which he defined caries as "*destruction of the teeth by decomposition.*" This, he contended, was accomplished by an acid generated by decompositions taking place in the very spot where its effects were shown.

As supporting this opinion, Regnard has formulated the following:[2]

"1st. Artificial teeth were fastened by threads of silk. These threads, which surrounded the neighboring teeth, became impregnated with saliva and covered with alimentary particles, and soon corrupted them; they became then a cause of caries to the teeth. This is so true that the limits of the caries proceeding from this cause are traced by the limits of the thread itself.

"2d. For sustaining the artificial teeth metallic caps are made to envelop one or more of the natural teeth. These constantly served to remove the pain produced by the wearing away of the teeth. These caps were not made with so much precision that there did not exist any space between them (and the teeth). The fluids of the mouth, the alimentary particles, soon lodged in these spaces; and if the persons who wore these caps were not very careful, these fluids of the mouth, these alimentary particles, decomposed and became the active cause of caries to the teeth. I have seen molars whose crowns were entirely destroyed by this cause in the space of six, five, and even four, months.

"3d. Human teeth and the teeth of the hippopotamus were used for artificial teeth. These teeth, being of an organic nature, are capable of

[1] *A Practical Treatise on the Human Teeth, showing the Causes of their Destruction and the Means of their Preservation*, by William Robertson, Old Square, Birmingham.

[2] Quoted from Desirabode, Part 1st, p. 169.

decomposing in the mouth. Then, if by a badly-arranged economy the persons who wore them still preserved them when they were in a state of decomposition, they decayed the neighboring teeth which are in immediate contact with them."

Regnard further enforces his doctrine by the following considerations:

"If, now, I devote my attention to the different parts of the teeth in which decay commences, I see that they are precisely those where the aliments and fluids of the mouth stop and remain sufficiently long to decompose themselves. It is in the necks of the teeth, in the interstices of these organs, in the anfractuosities of the large molars, in these pointed holes that we observe sometimes upon the external face of the first and second large inferior molars or upon atrophied teeth. If we reflect precisely upon the mode of action of caries, we see that they act in the same manner as an acid, that they deprive the tooth of its phosphate of lime, and upon the point where it exerts itself reduces it to a cartilaginous substance. Let us see if we can find in the decomposition of the alimentary particles or buccal humors an explanation of these phenomena. Now, chemistry teaches us that all vegetable or animal substances in a state of decomposition give birth to acidiferous products, to nitric acid, sulphuric acid, etc.—all acids which produce the same effect on the teeth."

Regnard advanced arguments that were, in effect, identical with those of Robertson. These views were immediately antagonized in France by M. Desirabode. While this author did not deny that the teeth might be injured by acids, he says: "To take the action of acids upon the teeth as the cause of decay in as absolute a sense as Regnard, is, according to our opinion, an error—a great error."

In opposition to the theory advanced by Regnard, M. Desirabode formulates the following propositions:[1]

"1st. A great number of caries commence in the ivory, which is often deeply affected, whilst the enamel is entire. . . . .

"2d. Many teeth, principally the last large molars, come from their alveoli deeply decayed, without, consequently, having been submitted to the action of any kind of an acid.

"3d. If it was always and solely an acid which affects the teeth, this action would be general; it would have *but one point* of decay; the *whole* of the dental system would certainly be decayed.

* * * * * *

"5th. Finally, the saliva and buccal humors are not as frequently acid as Regnard thought; we have often found alkalies among persons who had their teeth badly decayed. Our researches in this respect accord perfectly with the opinion of Dr. Donni, who expresses himself thus:

"'The alkalinity of the saliva has been avowed long since, but it has been proven only—in these latter years particularly—by the experiments of Tiedman and Gmelin.'"

In regard to the first of these propositions he says:

"Caries, according to our knowledge, as we have already said, proceeds frequently from the interior to the exterior. Smote in its vitality either by an act of nature which cannot be explained, and to which the pulp is

[1] *Complete Elements of the Science and Art of Dentistry*, by M. Desirabode, Surgeon Dentist to the King, Part 1st, p. 160.

not always a stranger, or because the delicateness of its tissue was not able to resist the agents with which teeth are constantly brought in contact, the ivory becomes the seat of a change which affects at the same time its color and the force of cohesion which unites its particles. A yellow or brown spot manifests itself near the enamel, which it invades by degrees until it extends upon the surface of the crown. This envelope loses in this respect its transparency, a natural consequence of the separation of the elements which constitute it. Whilst the interval layer of ivory which unites the enamel with the subjacent layers is not destroyed, the spot preserves the color, and even shining aspect, which belongs to the teeth; but it loses this brilliancy as soon as the connection is severed which binds the ivory and enamel together."

He then proceeds with the presentation of the usual arguments in favor of the old hypothesis, which are fairly represented in the above. It is easy for us of the present generation to see that these arguments were based upon erroneous observations, but we must remember that very many facts that are thoroughly established to-day were then either unknown or the observations leading to their establishment were accredited by comparatively few persons. And in this instance the great majority of dental operators asserted that decay did begin in the interior of the dentine. This illustrates some of the difficulties in the way of advance of thought.

It must be remembered that at the time these works were written the views expressed by Robertson and Regnard were in the most direct opposition to the theory generally held—namely, that caries resulted in some way from inflammation of the dentine; and, as might be expected, they were not very readily accepted. These authors denied *in toto* the influence of inflammation in the production of caries, and advanced what has since been known as the chemical theory—that all caries of the teeth is the result of chemical action or is caused by the operation of a corrosive agent acting from without. This entirely precluded the idea that decay ever, in any case, had its beginning in the internal parts of a tooth, and the accuracy of the observations that led to that belief was boldly questioned and denied. Further, the origin of the corrosive agent was accounted for on the hypothesis (for it could not at that time have been said to be proven) that it was produced at the very spot where decay began by the lodgment and fermentation of particles of food. Each of these authors proceeds to examine most attentively the particular spots at which each of the several teeth are most liable to the beginnings of decay, and finds that it never occurs on clean and smooth surfaces, but, on the contrary, the attack is in all instances made at such points as collect and retain alimentary particles, as in the interstices between the teeth, in pits and grooves in the enamel, or at such points as, from any cause whatever, retain particles until fermentation takes place; consequently, they claim that decay is caused by an acid produced by the fermentation of particles of food at the spot where the decay commences. So far as it is here expressed, I believe this view of the etiology of caries to be strictly correct, and that the facts developed during the succeeding years tend to confirm it.

When we consider the fact that at the time these authors wrote the

best of human thought and intelligence, and the deductions from all observations except their own, were diametrically opposed to their theory (a theory which all of the labor of the years intervening up to the present time has hardly been sufficient to demonstrate), that the laws of fermentation were very little understood, and that they had not the means of confirming their suppositions by direct experiments made either by themselves or by others, their writings seem very remarkable.

While their knowledge was limited within a comparatively narrow range, and their work as a whole exhibits less of learning than that of many of their contemporaries, yet they perfectly agree on this point, and evidently arrived at the true conclusions regarding it from a close analytical study of the phenomena of decay as they observed them.

The generally erroneous nature of the thought and observation of that period is well expressed in the arguments against these views by Desirabode.

The bold denial by these men that caries ever had its beginning within the dentine, as its truth was gradually established, had, however, great weight in confirming the chemical hypothesis.

It is exceedingly curious to note that in accepting the chemical theory a large part of the profession either misunderstood or lost sight of its main facts as related by the authors I have mentioned. Perhaps the most prevalent error, and one that has been most persistently prominent, is that contained in the objection that was immediately expressed by M. Desirabode—namely, that if acids caused decay, they would, from their necessary general distribution in the mouth, act upon all parts of the teeth, instead of spending their force on particular points. It will be seen at once that the idea of the localized development of an acid by fermentation is lost sight of in the expression of this objection. If the acid enters the mouth with the fluids as they are secreted by the glands, or with the food, or in any manner by which they would be generally distributed, there is no reason why they should act at particular points only.

On the other hand, much confusion has arisen through the supposition that caries might be caused by acids commingled with the fluids of the mouth or introduced from without. This is the form of error that has been most persistently present in the writings on this subject up to the present time. I may say that the acidity or alkalinity of the general fluids of the mouth or of the food plays but a small part in the case, provided these reactions be not in such degree as materially to modify the act of fermentation taking place in the out-of-the-way points about the teeth. The teeth may decay when the fluids of the mouth are habitually acid or when they are habitually alkaline. The condition governing the beginning and progress of caries is neither of these, but is dependent directly on the lodgment of substances at particular points and their fermentation with the production of an acid. It is in this manner that caries has its beginnings, and its progress is maintained by the continuance of this act of fermentation.

The failure to grasp this thought in its full meaning was perhaps quite natural. This subject of fermentation has been one of the most

difficult with which the intelligence of man has had to grapple, and was evidently not understood by those who conceived the fermentation hypothesis for the origin of caries. It was, indeed, known that many substances give rise to acids of various kinds during the process of decomposition by fermentation or putrefaction, but what was the *modus operandi* was an open question that was debated at that day only by the most astute chemists. The molecular-motion theory of fermentation and putrefaction cannot be said to have been fully developed until 1840, when Justus Liebig wrote his *Chemistry in its Application to Agriculture and Physiology* as a report to the British Association for the Advancement of Science. The subject had, indeed, been under discussion for several centuries without the development of any theory for the rational explanation of the observed phenomena upon which the learned men of the world could agree. This theory had been imperfectly shadowed forth for many years, but it seemed to require the genius of Liebig to systematize and place it before the world of thought in tangible form. Yet even before the work was completed an antagonist had arisen in the germ theory of these processes, growing out of the discovery of the yeast-plant by Schwann in 1838; and these two rival theories have struggled with each other for the mastery almost up to the present time, and there are perhaps many who will assume that the struggle is still going on. During this time it is but fair to say that there has been no theory of fermentation that has been fully accepted. The full explanation of caries of the teeth required an acceptable explanation of the processes of fermentation, and the learning of the period failed to afford this. For this reason the subject has always been enveloped in a degree of obscurity that has rendered all attempts at explanation unsatisfactory.

In this condition of the minds of men it is quite natural that other modes of explanation should be sought. And in the last half century almost every source of knowledge has been questioned with the hope of obtaining an answer, but none has been vouchsafed; for after threading the labyrinth of the theories propounded—and these have been many—the questioner has again turned back to the theory of fermentation with all its mystery and uncertainty. When we review the literature of the subject we find that since the time of Robertson and Regnard this explanation of the subject has never been entirely lost sight of. It must be confessed, however, that it has often been presented in so confused a manner, and so mixed with other theories, that its best friends could with difficulty recognize that a vestige of it remained.

Now, after the work of so many years has been added in the effort to explain the nature of fermentation, and when the labors of such men as Schwann, Schroeder, Lister, Koch, Klein, and Miller have made us acquainted with the agency of micro-organisms in the processes of fermentation and putrefaction, this seems to be regarded as another of the new theories which have sprung to the front demanding a hearing. If any have this thought, I wish to say that it is a misconception. It is but a further explanation of the old theory as propounded by Robertson and Regnard—an explanation of the processes of the fermentation by

which the acid spoken of by them is produced—and as such is not a theory that in any wise supplants or displaces that hypothesis.

Among the writings that have appeared since the works of Robertson and Regnard there are perhaps none that have deservedly attracted more attention than those of John Tomes. As a microscopist and histologist this author probably did more to give the profession correct views of the structure of the teeth and the phenomena presented by caries than any other writer.

As a contemporary of Robertson, Mr. Tomes was well acquainted with his views; but we do not find in his work any discussion of the theory of fermentation as applied to this subject. Mr. Tomes was a microscopist, and as such depended very largely on the teaching of that instrument for the views he entertained, and his writings seem to indicate that he began with a strong bias in favor of the theory of inflammation. Mr. Robertson, on the other hand, was not a microscopist, and seems not to have had any confidence that studies made by the aid of that instrument would be of any assistance in the explanation of the nature of caries. Under these circumstances it is not surprising that the views of the two men should be divergent.

In the earlier writings of Mr. Tomes we find views expressed that coincide in the main with those of Koecker, but with a more decided leaning to the theory of the action of acids as the active agents in the disintegration of parts rendered susceptible to their operation by a diseased action going on within the dentine. While this disease of the dentine was regarded as being of the nature of inflammation, Mr. Tomes finds by his microscopic inquiries that the phenomena of this process, as we understand them in its occurrence elsewhere in the tissues, cannot take place in the dentine. Yet he concludes by saying, in effect, that these phenomena are only the observed result of disturbance of the vital processes which are beyond the reach of investigation. The dentine is evidently endowed with vitality, though this vitality is invested in a different histological form from that of other tissues of the body, rendering it impossible that the same phenomena should appear on account of or in response to a given disturbance of this vitality. The dentine cannot become hyperæmic, because there is no provision for the circulation of the blood-globules within its structure; the entrance of leucocytes is prevented by the smallness of its tubules; and so on with all of the usual phenomena of the process known as inflammation; yet we cannot, on account of these differences in histological form, assert that the vitality existing in the dentine may not be disturbed in such a manner as to produce phenomena which will be peculiar to its histological forms. Mr. Tomes has critically examined the phenomena of caries, evidently with the intent to discover whether there were presented any conditions indicating a disturbance of the vitality of the dentine. In this search it must be admitted that he is in a degree successful, for he has shown what every experienced dental surgeon must recognize as true—namely, that in the beginnings of caries the dentine at the point of incipient disintegration becomes hypersensitive, and not a few patients complain when the parts are disturbed by the contact of foreign bodies. This phenomenon seems to be a sufficient evidence of a disturbance of

vitality, for how else can we account for the hyperæsthesia? As the caries advances and the point of exposure of the dentine is removed from the surface, this manifestation of pain is diminished or relieved, this agreeing precisely with similar phenomena manifested in injuries to the surface of the body; for it is well known that the skin is more sensitive to painful impressions than the parts beneath.

Again, Mr. Tomes describes what he terms "the transparent zone" as existing between the dentine affected by caries and that which has remained perfectly normal. In his earlier works this was regarded as being caused by the calcification of the dentinal fibrils, and as such was regarded as a vital act of resistance to the advance of the carious process—an act by which the fibrils shut themselves in from an external irritant, and attempted to build a barrier against further disintegration.

There is no doubt as to the microscopic appearances described, but in his earlier works, or those that were written soon after the discovery of the dental fibrils, this author seems to have been unfortunate in his interpretation of them; for it has been since determined that instead of being an act of vitality, by which a barrier is placed against the further progress of disintegration, it is, in fact, only the earliest stage of that process, and there is really no calcification of the fibrils. Mr. Tomes corrects this error in the recent editions of his work.

From these studies Mr. Tomes concluded that the life-force resident in the dentine possesses a certain power of resistance to injurious impressions, and that this resisting power must be overcome by some force or cause before disintegration can occur. In other words, the phenomena of caries must be preceded by something having the power of destroying the life of the part. This something may be a diseased state of the dentine similar in its nature to inflammation of the other tissues; but for this idea he does not strenuously contend, for he supposes that the life of the part may be destroyed by the same agent that effects the disintegration. Mr. Tomes says:[1]

"In speaking of the predisposing and exciting causes of caries, allusion has yet to be made to those agents which may be regarded as acting in the double capacity of depriving the dentine of its normal powers of resistance and of producing its immediate decomposition.

"In considering the subject from this point of view, we must be prepared to admit that the dentine is possessed of vitality, and that vitality must have been lost before the tissues undergo decomposition. If we take, for example, the effect produced on the skin by the application of caustic potash, the immediate result is the destruction of vitality in the part with which it comes in contact, and its secondary effect will be the disorganization of the part destroyed. But had the power exerted by the potash been incapable of depriving the skin of vitality, the secondary effect, that of producing decomposition, would have been successfully resisted. In the case of a tooth the application of potash would not produce conclusive results, but the use of a mineral acid would be followed by consequences similar to those mentioned with respect to the skin. The vitality of the part would be destroyed, and decomposition would succeed the loss of life.

"It may be said that agents of this character are not applied to the teeth, but such as have sufficient power to destroy are applied; and it is

[1] *System of Dental Surgery*, p. 372, 3d ed., 1859.

by taking an extreme case that we are best able to examine the mode of action and the ensuing results.

"Litmus-paper applied within the cavity of a carious tooth almost invariably gives strongly-marked acid reaction, and thus furnishes evidence of the existence of an agent capable, if unresisted by the vitality of the dentine, of depriving that tissue of its earthy constituents, leaving the gelatin to undergo gradual decomposition, favored by the heat and moisture of the mouth."

Mr. Tomes, therefore, while insisting on the presence of vital phenomena in the production of caries, finally admits a process that is almost purely chemical. From this point he proceeds to examine into the condition of the oral fluids with the view of finding the acids that do the mischief. He says:

"In examining the circumstances under which the decomposition of the dentine takes place and under which it is resisted, apart from the influence of vitality, any one must be struck with the power that is exerted by the mere form of the surface involved. Supposing the disease to be situated in a deep fissure or upon the side of a tooth against which another tooth is placed, the decomposition will go on with more or less rapidity, the rate being varied in accordance with the condition of the oral fluids. But if the cavity be superficial, and so placed that it is subject to friction during mastication, the progress is relatively slow; and if the low walls of such a cavity be removed, the part will become polished by the act of mastication and by the motions of the tongue, and decomposition will be completely arrested quite independently of any power of resistance exercised by vital action. Again, let a tooth be placed under circumstances the opposite of the preceding. For example, take a bicuspid of the upper jaw the distal surface of which is decayed, and remove the softened dentine; then let dry cotton wool be forced between the defective tooth and its neighbor, and renewed only once in three or four days; at the end of a fortnight or three weeks it will be found that the surface of the cavity, which was left hard and dense after the first operation, has become soft, and that the softening extends to a considerable depth. Had the cotton, prior to its introduction between the teeth, been dipped into a solution of resinous gum, such as mastic, the surface of the cavity would have remained unaltered, owing to the exclusion of moisture. But where the wool only is used, the secretions of the mouth are not only not excluded, but are held in constant apposition with the exposed dentine by the saturated wool.

"Experiments of this character lead to the conclusion that within the mouth are agents present which, under favoring circumstances, are capable of decomposing the dental tissues, and the source of these agents becomes the next question which naturally suggests itself."

This astute writer has left the subject of the influence of fermentation in the production of acids untouched. He attentively examined the fluids of the mouth in varying conditions of the system, and found in them acids, which he concluded must be sufficient to account for the phenomena of the disintegration of the dentine in the form of caries. That these acids are found there is no doubt. Under various circumstances the saliva itself becomes acid, and from my own examinations, which have been somewhat extended, it appears that it is usually acid (the mixed fluid) in the state of fasting; and the mucus is slightly acid in

the greater number of persons I have examined; especially is this so if the gums about the necks of the teeth are slightly irritated. Indeed, I may say that from my own observations I have conclusively confirmed Mr. Tomes's findings as to the frequency of acidity of the fluids of the mouth. But this does not constitute a satisfactory explanation of the occurrence of caries. Against such a supposition the argument of Desirabode, quoted in a note elsewhere, applies with its full force. If we succeed in accounting for the production of decay on the chemical hypothesis at all, we must account for the application of the acid to the particular point where that decay manifests itself, to the exclusion of other parts of the denture; otherwise we must fail. Therefore, acidity of the fluids of the mouth cannot be the active exciting cause of caries, though it is possible that this condition may be indirectly instrumental as a predisposing cause. This feature of the subject will be discussed on another page.

There is no doubt that the writings of Mr. Tomes had a powerful effect in drawing the thought of the profession away from the fermentation hypothesis as an explanation of the active cause of caries of the teeth. This, however, can hardly have delayed the full explanation of the phenomena, for before the processes of fermentation and putrefaction could become explainable a vast deal of labor in other directions was necessary; and this, from the very nature of the case, could best be done by others than those actively engaged in dental practice.

This search in the fluids of the mouth for the active factor in the production of caries did not begin, however, with Mr. Tomes. Amos Westcot, for the purpose of ascertaining what effect the acids supposed to be present in the oral fluids would exert on the teeth, had already made a series of experiments, in which he found that they were decalcified by very high dilutions.

These experiments were published in the third volume of the *American Journal of Dental Science*, and have been referred to by many writers since that time. They led to a vast number of analyses of the oral fluids in all conditions of health and disease, and almost unlimited experimentation in decalcification of the teeth in varied dilutions and compounds of the various known acids, an intimate acquaintance with the varying conditions of the oral secretions and the effects of acids on dentine being thus developed, but little or nothing being accomplished explaining the processes of caries of the teeth, except to demonstrate that in simple solution by acids certain of the phenomena of caries are absent.

In the progress of this study the most diverse views have from time to time appeared, and the formation in the fluids of the mouth of almost every known acid, by some possible changes of molecular groupings, has been assumed.

Some few have been satisfied with the theory of fermentation, as was Goddard, who supposed acetic fermentation to be the prime factor;[1] but the great majority of writers have invoked the aid of vital processes resident in the tooth itself for the production of caries or for limiting its effects, or for both; and, altogether, the agency of vitality in this process

[1] *Goddard on the Teeth*, 1854.

has been most thoroughly studied, seemingly in all possible aspects, but without results. At the present time the only influence that we can attribute to vitality is that it has some power to limit the rapidity of decay in the otherwise normal tooth. Teeth that have lost their pulps, and as a result the vitality of the dentine, decay more rapidly. The great number of pulpless teeth now retained in the mouth give abundant opportunity for observation upon this point; but it is uncertain whether this slower progress of caries in the living tooth is on account of its vitality or because the tubules are occupied with the dentinal fibrils in such a way as to prevent by their bulk that more rapid ingress of the agent of solution which would occur were the tubules laid open by the loss of the fibrils. This latter thought seems to be more in harmony with the phenomena, and yet it must be admitted that it is difficult to conceive that the living contents of the tubules, the dentinal fibrils, should be powerless and incapable of exerting any influence when their vitality is directly disturbed. Yet, after all the study that has been expended on this point, there have been developed no evidences of vital resistance on the part of the dentine itself, other than hyperæsthesia, capable of withstanding adverse criticism.

The principal evidence of vitality of the dentine, however, is exhibited in changes that occur in the tissues of the pulp itself on account of irritation of the distal ends of the dentinal fibrils in the processes of caries and of the abrasions. These are fully considered in the article on Pathology of the Dental Pulp, and need not be referred to here, especially as they do not relate to caries further than that they are one of its remote consequences. The fact that these morbid effects are transferred to the pulp through a considerable portion of dentine, without visible change in the dentine itself, denotes its incapacity for the exhibition of morbific changes through vital activity or the agency of vital forces resident within itself.

A few observers seem to have abandoned both the chemical and the vital theory, and have sought to explain the results by other means. Bridgeman, in an essay on this subject,[1] attributes caries to peculiar electrical conditions in which the crown of the tooth becomes the positive electrode, and the tissues in which the tooth is invested the negative. When these conditions are intensified by abnormal qualities of the fluids of the mouth, the crown portion of the tooth yields up its lime salts, setting free the acids with which they were combined; and this leads to molecular disintegration of the substance of the dentine in the form of caries. This is certainly a very ingenious theory, but is at variance with so many facts that any effort to maintain it must be futile. It can be readily understood, however, that by placing different metals in the teeth as fillings the saliva may act as an excitant and a battery be produced. From these artificial conditions I have seen effects that seemed to be the product of electrical currents.

Another thought has been advanced to account for caries on the hypothesis of vital action. In this it is supposed that on account of a disturbance of vitality, such as might produce inflammation in other parts of the system, the nutrition—or, more properly, the vital action—

[1] *Transactions Odontological Soc.*, vol. iii. p. 369.

of the particular part is disturbed in such a manner that an additional molecule of acid is formed, giving rise to the acid superphosphate of lime or the withdrawal of a molecule of lime, which is replaced by basic water, thus changing the insoluble neutral phosphate into a soluble acid phosphate. This idea seems to have arisen from a suggestion by Mr. Coleman that the acidity of caries was probably due to the formation of the acid phosphate of lime.

Among the many theories that have appeared from time to time to account for caries by the introduction or development of particular acids in the mouth, there are several that deserve mention either because of the high estimation in which they have been held by large numbers of intelligent practitioners, or for their intrinsic importance, or for the ingenuity with which they have been presented. One of these, especially urged by Dr. George Watt, and which may be termed the mineral-acid theory, has in America exercised considerable influence. I should, however, say that, while Dr. Watt claims that these acids especially are the cause of decay, he does not exclude the action of the organic acids. According to this theory, the particular acids productive of the great mass of caries are nitric, sulphuric, and chlorohydric. These give rise to three distinct varieties of decay, differing the one from the other in accordance with what is supposed to be the peculiar action of each of the acids in question. Nitric acid is said to produce white decay; sulphuric, black decay; and the chlorohydric, the intermediate colors. It is held that any of these acids may be formed in the mouth or may be introduced into that cavity, but for the production of caries they must be formed at the exact spot at which they act upon the tooth by some form of decomposition which takes place in substances that may find lodgment about the teeth. This, then, is in strict accord with the theory of Robertson, and amounts to an effort to explain the mode of procedure by which the acid is produced and to define the particular acids.

With regard to nitric acid, Dr. Watt says:[1]

"It is a singular fact that though oxygen and nitrogen manifest but little affinity for each other, yet they unite in various proportions, forming at least five well-known distinct compounds. It appears, however, from a variety of circumstances, that their tendency is to unite in the proportions which form nitric acid. The protoxyd is readily decomposed, and yields nitrogen, oxygen, and *nitrous acid*. The binoxide, if brought in contact with the atmosphere, takes from it two equivalents of oxygen, and also becomes *nitrous acid*, or NO_4 (the old chemical formulæ are used here). Hyponitrous acid, NO_3, on admixture with water is converted into nitric acid and binoxide of nitrogen; thus, $3NO_3 = NO_5 + 2NO_2$, in which case the latter will be converted into *nitric acid*. It follows from this that if oxygen and nitrogen unite at all in the mouth, let the proportions be, at the first, what they will, nitric acid must be the ultimate result, as air and moisture, the only agents necessary in the transformation, are here always present. . . . .

"Nitrogen is emphatically a conservative element, and manifests but little tendency to unite with anything, and especially with oxygen. It is

[1] *Chemical Essays*, p. 62.

probable, therefore, that these two elements unite indirectly. It should be borne in mind that organic nitrogenous bodies contain hydrogen and oxygen as well as nitrogen. Consequently, by their decomposition, these elements are liberated. The mutual affinities of the hydrogen and nitrogen take precedence, and the result is the formation of ammonia, NH_3. But ammonia exposed to the action of oxygen is always decomposed, an oxide of nitrogen being formed, and of course *nitric acid* is the result.

"With this view of the case, and from the fact that many persons permit the buccal mucus as well as particles of nitrogenous food to remain around, upon, and between the teeth till decomposition is effected, it is not surprising that the white variety of dental caries is so frequently found."

The formation of other acids in the mouth is followed out by a similar mode of procedure. For instance, this author says:

"Albumen is a constituent of mucus, and is contained in many articles of food. Sulphur, if not a constituent of, is always united with, albumen. Its ordinary presence in the mouth is therefore easily explained. Sulphur and oxygen unite directly under various circumstances, as in the combustion of sulphur, but it is probable that the union here is effected by indirect means. Hydrosulphuric acid, or sulphuretted hydrogen, is one of the results of putrefactive decomposition of albuminous substances. The breaths of our patients often bear ample testimony to its presence in the mouth. Now, the oxygen of the atmosphere rapidly decomposes this acid by taking its hydrogen to form water. The sulphur is therefore set free, and, being in the nascent state, its affinities are increased in energy, and it also unites with oxygen, forming the sulphurous acid, SO_2, which in the presence of the water of the saliva is rapidly converted into sulphuric acid, or SO_3."

This acid is regarded as acting on the constituents of the tooth but very feebly, so that the texture of the dentine is not entirely broken up, but by its tendency to the removal of the elements necessary to the formation of water, for which it has a very powerful affinity, the tooth-substance is carbonized, giving rise to very black, slowly progressive decays.

In respect to the formation of chlorohydric acid the following quotation will be sufficient:

"Though in its normal state the saliva is alkaline, yet in a great variety of abnormal conditions it contains one or more free acids, and the chlorohydric is one of those most frequently present. It often originates, no doubt, in the decomposition of the soluble chlorides contained in the saliva and mucus. When the chlorine of these is liberated, it takes hydrogen from the water of the saliva, and this acid is the result of the union."

This acid, in the degree of concentration in which it would be likely to be produced in the mouth, is not regarded as capable of dissolving the animal portions of the tooth. It is therefore supposed to remove the lime salts, giving rise to those soft, pulpy forms of caries in which there is a large mass that still retains its histological forms.

In his essays on this subject this author has endeavored to keep before his readers the idea that the acid must be formed at the very spot where its effects are manifested in the production of the phenomena of caries, for he has taken pains to state in connection with the consideration of

each of these acids that it may be taken into the mouth with the food or in the form of medicine, and that, while if used in this fashion carelessly it might injure the teeth, it could not thus produce the phenomena of caries, evidently for the reason that its action would not be spent on the particular parts of the teeth, to the exclusion of other parts.

The views entertained of the formation of these acids in the mouth seem not to rest on any basis of experimental study of which we have record, but rather upon a supposed likeness of the varieties of caries to the observed action of these particular acids. Later developments show that the results are dependent upon other agents.

The views just given have been much more prominent in America than in Europe. It seems that in the Old World the tendency has been to regard the organic acids as those more likely to be concerned in the production of caries. Their action has been investigated in this country as well, but the most elaborate treatise on this phase of the subject has been written by Dr. Magitot of Paris.

After a very elaborate study of the etiology of dental caries Dr. Magitot says:[1]

"The preceding considerations tend to establish that dental caries results from a purely chemical alteration of the enamel and ivory of the teeth, either by the products of acid fermentation developed in the saliva or by active agents introduced directly into the mouth. Now, if this theory be correct, we should be able to obtain the same effects by subjecting sound human teeth out of the body and deprived of life to the direct action of the same agents which produce this affection in the economy. This is in fact possible, and we shall relate and develop a series of experiments by which, sometimes in the mouth and under the ordinary conditions of development of natural caries, sometimes in liquids artificially prepared, we have produced changes identical with that of this malady.

"Thus will be demonstrated, as it seems, without doubt, the true nature of dental caries, which it will be impossible to regard henceforward as an affection of internal and organic origin or a vital lesion of nutrition, as has been generally believed up to this time."

Some of the experiments related by Dr. Magitot consist in a systematic observation of human teeth prepared and mounted on natural roots as pivot teeth. After some years of wear in mouths in which caries was actively progressive in the remaining natural teeth, the substituted teeth were affected with caries in the same manner as the natural organs. The cavities were of the same form, in the same positions in which caries is seen to attack the natural organs, and the whole appearance of the cavities produced showed the affection to be precisely similar. There was the same kind of progressive softening of the dentine, and the contents of the cavities had the same acid reaction that is always found to exist in progressive caries of natural teeth.

These experiments are related at length, and are considered as settling beyond all doubt the fact that caries is caused by an agent acting from without, and is independent of the vitality of the tooth attacked. Dr. Magitot, however, says: "A fundamental distinction must be observed.

[1] *Treatise on Dental Caries, Experimental and Therapeutical Investigations*, by Dr. E. Magitot, translated by Thomas Chandler, D. M. D., p. 121.

It consists in the absence of all phenomena of reaction on the part of the tooth and the absent dental pulp, whilst in pathological caries the injured organ reacts and struggles against the invasion of the disease." This resistance is regarded as sufficient to render the progress of the disease slower, and even, in some favorable cases, to arrest it altogether.

Another series of experiments was undertaken to determine the effect on the teeth out of the mouth of solutions of different substances. Some of these were fermentable, others not.

Several experiments were made with solutions of sugar. Solutions were made with one part of sugar to three parts of water, and in this perfectly sound teeth were placed under two conditions: 1st. They were simply laid in the liquid without any kind of protection; 2d. The teeth were completely protected with a coating of wax except at a single point on the enamel. The vessel was then set away loosely corked and allowed to remain two years, in which time the solutions were, of course, allowed to undergo the process of fermentation. At the end of the two years the fluid was found markedly acid, of a deep reddish color, and covered with a deep mould. The teeth not protected by the coating of wax were completely decalcified. The teeth protected with wax at all but one point were also decalcified, but at the point of exposure there was a localized cavity having all the characteristics of caries. In another experiment identical with this, except that a little animal matter was added to hasten the process of fermentation, the result was almost exactly similar. In the third experiment a few drops of creasote were added, to prevent fermentation. This seems to have failed. The fermentation proceeded with results similar to those just described. In the fourth experiment glucose was added and a few drops of creasote, to prevent fermentation, and the teeth were placed in solution as before. In this instance fermentation was successfully prevented. The solution at the end of two years remained clear. There was no mould and none of the teeth showed any alteration whatever. In the fifth experiment teeth arranged in the same way were placed in a cold saturated solution of sugar of milk. No fermentation took place, and there was no effect produced on the teeth. In the sixth experiment a one-to-three solution of cane-sugar in distilled water was brought to the boiling-point and hermetically sealed while hot. A group of sound teeth had been weighed with great care and placed in the flask before heating the solution. At the end of two years no fermentation had taken place. The teeth appeared unchanged. They were dried and again weighed, and it was found that they had undergone no loss whatever. A seventh experiment with glucose under identical conditions with the last showed similar results.

The experiments with sugar seem to show conclusively that as sugar it has no hurtful influence on the teeth, but when fermentation takes place the teeth are profoundly affected. In each of the cases the fermentation was of the acid character, not vinous, and the acid first produced was generally acetic or lactic, which latter acid usually passes into the butyric fermentation, and finally is liable to change into other forms as the different fermentative processes succeed each other. In this series of experiments, therefore, the teeth were in turn subjected to various acids

without any knowledge as to their strength or the duration of the exposure to any particular one; but the results show conclusively what we may expect from the fermentation of sugar in contact with the teeth.

In another series of experiments the white of an egg was mixed with water, the conditions being otherwise the same as in the experiments with sugar. At the end of two years the results were very similar. In the solutions that underwent the process of fermentation the teeth were decalcified, but in those in which fermentation did not take place the teeth remained perfect.

Experiments with the organic acids produced the following results; in each case the teeth remained in the solution two years:

Lactic acid, 1 to 1000, but slight effect.
Lactic acid, 1 to 100, teeth decalcified.
Butyric acid, 1 to 1000, teeth partially decalcified.
Butyric acid, 1 to 100, teeth completely decalcified.
Citric acid, 1 to 1000, teeth partially decalcified.
Citric acid, 1 to 100, teeth wholly decalcified.
Malic acid, 1 to 1000, enamel chalky, dentine partially decalcified.
Malic acid, 1 to 100, teeth decalcified.
Cider, teeth decalcified.
Acetic acid, 1 to 1000, teeth not affected.
Acetic acid, 1 to 100, enamel not affected, dentine decalcified, and the roots of the teeth shrivelled.

This gives a fairly good idea of the power possessed by the organic acids to decalcify the teeth. It must be remembered, however, that in the solution of 1 to 100 the decalcification, though complete in two years, progresses very slowly, so that a momentary exposure of a tooth to even a much stronger solution would be productive of no appreciable injury.

Dr. Magitot has experimented also with many other substances whose action seems to me to have little or no relation to the etiology of caries. The views entertained by him, however, doubtless led him to attach to them an importance greater than I can give them. He says:[1]

"It is perfectly established that dental caries results from the direct alteration of the organ by means of substances which originate in the saliva or are accidentally introduced—an alteration usually preceded and favored by certain congenital or acquired predispositions of structure or anatomical conformation. . . . .

"Caries, regarded from this point of view, consists, then, precisely in a simple solution of the calcareous salts of the dental tissues by an acid element developed or brought in contact with them. Such is the rigorously logical conclusion which seems to us to result from all the considerations and experiments just stated."

It would seem that this author places substances *introduced into the oral cavity* upon the same plane as those developed in contact with the teeth. This being the case, he has experimented with the acids and substances contained in food or condiments. It is also curious to note that while he has been careful as to the fermentation of the fluids with

[1] Pp. 158-164.

which he has experimented—and in a large number of them fermentation has produced the acid which has decalcified the teeth experimented upon, which fact he particularly notes—yet he nowhere puts prominently forward the thought that these agents are formed in contact with the identical points at which caries is manifested. It is true that fermentation taking place within the mouth is many times alluded to, and the agency of micro-organisms in the process is also admitted; still, but slight importance is attached to them.

Continuing, Magitot says:[1]

"Other secondary phenomena are sometimes produced concurrently about the altered parts, and have by various observers been held to a certain degree responsible. It is thus that putrid decompositions, which have especially for their source débris of animal or vegetable substances of alimentation, have been invoked; in like manner the cryptogams and vibrios, whose formation we have regarded as an epiphenomenon of the malady, have been considered as agents of the alteration by Facinus, thus taking precedence of the theories of Pasteur."

It seems to have been Dr. Magitot's thought that the agents that produce caries are either developed in the fluids of the mouth, and evolved with them as they are secreted, or else are introduced from without, rather than formed in isolated points of fermentation. In his search for these agencies all the varying conditions of the fluids of the mouth in health and disease have been questioned. That in such agencies are to be found some of the predisposing causes of the malady there seems no reasonable doubt; but certainly, after all the fruitless search of the last half century, it is time to turn our attention elsewhere. I would here reiterate the proposition that if the cause of caries of the teeth is to be found in the disintegration of their structure by an acid or by acids, we must find that these agents are produced or applied at the very spot where the caries has its beginnings or is making its advances. Otherwise we must fail. Caries of the teeth is, as a malady, strictly localized, and is not the product of any agent distributed generally in the oral fluids.

There are many other authors, such as Weld, Salter, Coleman, Taft, and others, who have written well on this subject, and from whom we might quote; but in doing so only slight shades of difference in the views presented would be obtained, without in any wise affecting the trend of thought already given; it is, therefore, unnecessary to our present purpose.

Agency of Micro-organisms in Caries.

In the previous pages considerations have been presented which lead to the conclusion that caries of the teeth is a result of the corrosive action of acids developed in contact with them. Certain observations of the utmost importance in the further explanation of these processes are now to be noticed. They relate to the agency of those micro-organisms concerned in the various fermentative processes by which acids are produced.

[1] P. 164.

From time to time during the discussion of the relations of micro-organisms to the process of fermentation there have appeared suggestions that decay of the teeth might be a result of the action of microbes. But the first extended study of fungi in connection with this process was undertaken by Leber and Rottenstein, who published an account of their observations in 1867.[1] At the time their studies were made plans for the separation and individual study of those micro-organisms which appear in connection with the carious process had not been systematized. Hence these observers seem to have confounded all other micro-organisms with *Leptothrix buccalis*. By treating decayed dentine with iodine and acids a violet color of the granular masses filling the widened tubules was obtained, and the conclusion that these were composed, in part at least, of micro-organisms was announced—an observation since confirmed by the use of the improved methods of staining introduced by Dr. Koch. So complete has this demonstration been that in any case of erosive softening of tooth-structure within which micro-organisms cannot be demonstrated by well-known processes we are justified in saying that such a softening is not true caries, or is not of the nature of caries as it is found in the human mouth. Leber and Rottenstein do not regard the fungus as capable of penetrating the normal enamel or dentine, but suppose that, a beginning being made by an acid, it enters, and by its growth assists in the destructive process.

The following extracts define the views of these authors upon this point (pp. 68–97):

"From what has been said, it results that two principal phenomena manifest themselves in the formation of dental caries—viz. the action of acids, and the rapid development of a parasitic plant, the *Leptothrix buccalis*." . . . . "It seems that the fungi are not able to penetrate an enamel of normal consistency. The dentine itself, in its normal condition of density, offers great difficulties to their entrance, and we are not yet sure that the leptothrix could triumph over this resistance." . . . . "We cannot decide at present if the leptothrix is able to penetrate sound dentine when from any circumstance it happens to be denuded." . . . . "But if the enamel or dentine become less resistant at any point through the action of acids, or if at the surface of the dentine a loss of substance has occurred, then the elements of the fungus can pass into the interior of the dental tissues, and produce by their distension, especially of the dentine, effects of softening and destruction much more rapid than the action of acids alone is able to accomplish." . . . . "The participation of the fungus is constant in the production of caries which has reached this stage. As soon as a loss of substance can be shown there is found the presence of fungus, so that the question whether or no acids alone could produce ravages more considerable is without importance."

The *modus operandi* by which *Leptothrix buccalis* (or other micro-organisms) may produce softening of the dentine is left without explanation. It may here be mentioned that in the very beginning of this line of investigation a mistaken idea was entertained, which has been perpetuated in nearly all subsequent writings upon the subject—that if micro-organisms are instrumental in the production of decay they must

[1] An English translation appeared in 1868.

first enter the structure of the tooth. This error seems dependent upon a failure (which is very apparent) fully to comprehend the theory of fermentation with the production of an acid, which acid, being formed in contact with a particular part of the tooth, acts chemically upon its substance and decomposes it. It should be remembered that if microbes act at all in this process it is through their agency in setting up fermentative changes, during the progress of which substances are chemically altered in such a way as to create an acid or other chemical agent capable of acting on the constituents of the tooth and decomposing them. Therefore contact with the tooth, provided this contact be sufficiently prolonged, is all that is required. The chemical substance provided goes before and prepares the way for the entrance of fermentative agents. This fact being kept in mind, much of the confusion of ideas apparent in the earlier discussions of this question will be prevented.

The work of Leber and Rottenstein made a profound impression on the dental profession, notwithstanding the fact that most of their propositions fell from lack of evidence. The subject has since then been taken up by others, improved methods have been devised, and our knowledge has been greatly increased. In this work Messrs. Milles and Underwood of London have taken an important part. Their results were communicated at the meeting of the World's Medical Congress held in London in 1881. These gentlemen had the use of the improved staining methods introduced by Dr. Koch, and fully verified the findings of Leber and Rottenstein as to the presence of micro-organisms in the tubules of carious dentine. After an extended series of flask experiments, they announce the conclusion that the decalcification of the teeth in decay is accomplished by an acid secreted by the organisms, and that there are other phenomena present, such as the widening of the tubules and the discoloration of the decayed mass, which are not to be explained by the action of acids. The widening of the tubules is regarded as being the direct work of the micro-organisms, which consume the dentinal fibrils and the decalcified walls of the tubules (they use the term *channels*), and in this way finally break down the entire mass.

After passing over the *vital theory* of caries as being already completely disproved, Milles and Underwood say:

"With regard to the purely chemical theory, we cannot accept it as wholly satisfactory, for the following reasons:

"1. Because the destruction of dentine effected by the action of acids alone under aseptic conditions does not resemble caries either in color or in consistency, it being colorless and gelatinous, the process uniformly attacking all parts of the surface.

"2. Because sections of dentine so destroyed show uniform destruction of the matrix, but not enlargement of the channels occupied by the fibrils; whereas the true caries first attacks the soft tissues—*i. e.* the fibrils—and encroaches from that *point d'appui* upon the surrounding calcified structure, thereby producing the characteristic enlargement of the channels, until two channels break into one, the intervening matrix being wholly destroyed.

"3. That, although artificial caries has been produced exactly resembling true caries, we have failed to discover any record of experiments in which this has been the case when septic influences were excluded. Two experi-

ments have indeed been recorded in which the teeth were protected from septic agencies, in one by the addition of creasote, in the other by hermetic sealing of the flask (see Magitot's experiments), and in neither of these did caries occur. We assume, therefore, that two factors have always been in operation: (1) the action of acids, and (2) the action of germs. Further, our own flasks show that malic and butyric acid, with saliva in a meat infusion, have not, under aseptic conditions, produced caries.

"It may be asked, If a tooth can be decalcified by acids out of the mouth, and these acids are constantly in action in the mouth, then if they produce caries why can they not produce simple decalcification? To this it may be replied that acids alone do not destroy a living tissue—that the stomach is not digested by its own acids until it has been removed from the body.

"4. Lastly, we would urge that when caries occurs in the mouth it is always under circumstances more favorable to the action of germs than to that of acids. There is always, first of all, a minute pit or haven where germs can rest undisturbed and attack the tissue. We cannot, upon the purely acid hypothesis, explain why the same acids that originally caused the decay, gaining access through some minute imperfection of the armor of enamel, do not in the same mouth or under the same conditions attack the wounded enamel at the edges of a filling. The germs cannot rest there: they are constantly washed away if the surface is fairly smooth; but the acids literally bathe the part (during the intervals between the acts of mastication, when the alkaline parotid and submaxillary saliva neutralizes their action).

"This theory—which, for the sake of distinction, may be called 'septic'—is rather an amplification of the chemical theory than a contradiction of it. Most probably the work of decalcification is entirely performed by the action of acids, but these acids are, we think, secreted by the germs themselves, and the organic fibrils upon which the organisms feed, and in which they multiply, are the scene of the manufacture of their characteristic acids, which, in turn, decalcify the matrix and discolor the whole mass.

"From our observations on cementum to which caries has extended we conclude that the process is very similar: the bioplasmic contents of the lacunæ and canaliculi afford board and lodging for the organisms, which multiply, and, when sufficiently numerous, decalcify the surrounding bone, so that each lacuna loses its outline and extends in all directions."

In regard to the order of the occurrence of the phenomena of caries, and the relation of micro-organisms thereto, the conclusions of these observers were an advance upon anything before developed, and, considering the fact that they had not been able to make out the life-history of the fungus, its physiological processes, by any manner of demonstration, it seems quite remarkable that they should have approached so nearly to accuracy of judgment. They did not make the necessary separation of the organisms found, nor cultivations for the study of their individual characters and the molecular changes or remolecularizations of matter they induce when in contact with different substances.

This, thanks to Dr. Miller, has been done in case of some of the micro-organisms of the mouth, and it only requires a continuance of the work to make us familiar with them all. It must be remembered, however, that this requires a vast amount of labor of the most painstaking character as well as a thorough training in this kind of work. I have had enough experience in it myself to form some judgment in

the matter, and it seems to me impossible for one burdened with the cares of a full, or even a light, practice successfully to carry out any considerable series of these observations with that care and accuracy which the subject demands. The chances for contaminations and mistakes in various directions are so great as to require one's whole thought for their successful avoidance. For these reasons I shall not, in what I have to say on this particular subject, put forward my own observations where I can avail myself of those of persons whom I know to have been better situated and better prepared for the work, and whose skill is known and recognized. I would say, however, that it is by no means certain that one who has busied himself principally with original research of this character is best calculated to construct theories from the facts derived from even his own experiments.

This work is as yet in its infancy, and, though enough has been accomplished to furnish an ample basis of fact for the formation of well-grounded theories not only as to the agency of micro-organisms, but also as to the modes of their action, the development of many additional facts may be expected in the near future. It seems unnecessary to follow all who have written on this point. Nearly all who have attempted to investigate in this field have added something to our knowledge of it. Even in those cases in which no facts of enduring value have been added difficulties have been illustrated for the benefit of those who followed. But, after all, the most important part of the work has been done by those in no wise connected with the dental profession, and it is to them we must go for a knowledge of the agency of micro-organisms in the decompositions in general, and the work in our particular field must be guided and directed by the information thus gained.

Ever since the discovery of the yeast-plant by Schwann, and the establishment of the fact of its necessary participation in the act of alcoholic fermentation, it has been assumed by a considerable portion of the best students of natural phenomena that this was the type of all fermentations and decompositions. Indeed, it was soon shown by Schwann and his colaborers that sterilized solutions would not undergo decomposition, fermentation, or putrefaction when hermetically sealed, nor even after the admission of air purified by heat. This, however, was not considered conclusive. It was claimed that the disposition to decomposition is communicated by the contact of substances in a state of *molecular motion*, by which their elements are being rearranged in new forms, and that heat will stop this molecular movement and destroy the tendency until it is again communicated by the contact of this kind of influence.[1] This, it was asserted, might exist in the gaseous form and be freely communicated by means of the air. In 1854, however, Schroeder sterilized fermentable solutions and soups, to which he admitted air after having filtered it through sterilized cotton, with the idea that if organic germs caused decomposition these would be caught in the meshes of the filter. This experiment was eminently successful. Solutions did not decompose, though the air was admitted without heat or other change than removal of the particles floating therein. These particles were supposed to be—in part, at least—organic germs which

[1] See Liebig's *Organic Chemistry in its Application to Physiology and Agriculture.*

would undergo development when brought in contact with a favorable soil.

After this came the brilliant experiments of Pasteur and his colaborers, in which it was conclusively proven that none of the fermentations or putrefactions could progress without the presence of organic germs, and that each one of these is dependent on the presence of a special form of organism peculiar to it, and to none other. Following close on these discoveries came their application in surgery by Lister, who by the use of appropriate means for arresting the ingress of micro-organisms succeeded in preventing decomposition in wounds. These results, most of which have been accomplished within my own lifetime and memory, have had the effect of almost completely banishing the old molecular-motion theory of Liebig and substituting the germ theory in its stead.

The brilliant results of this series of observations are of the greatest importance in the explanation of the phenomena under consideration. For this reason the close study of these fermentative processes is of the utmost importance to those who would gain the most accurate understanding of caries of the teeth.

As briefly representing the results of these investigations we may formulate the following propositions:

The act of fermentation comprises the physiological processes of life —namely,

1st. The formation of a solvent (which is usually an unorganized ferment, peptonizing agent, or diastase) for the performance of the act of digestion, or the preparation of food-material for absorption and assimilation.

2d. Assimilation or nutrition, or the act of tissue-building.

3d. The formation of waste products, the act of denutrition, or the shedding out of material that has once been formed into protoplasm or used in connection with the process of tissue-building.

4th. The capability of reproduction in a definite line of forms.

The performance of these acts is *the condition* of the physical existence of life, and they must be performed by every form of life, no matter how high or how low in the scale.

As illustrating the physiological processes of fermentation, it is well to study the higher plants (not disregarding the physiological processes of the higher animals), for the reason that in them certain processes can be better made out than in the microscopic organisms. For this purpose I have made diligent study of some particular plants that seemed to give better facilities than others. Among these studies the sprouting of the grain of corn presents especial facilities for observation in microscopic section. It, as most others, is composed of three natural divisions—the germ, the perigerm, and the starch envelope. The germ is the embryo plant; the perigerm (the scutellum of botanists) is the organ of digestion destined to serve the needs of the germ during its embryonic development; the starch envelope is a store of food to serve the young plant until such time as it shall have developed the organs with which it will be enabled to gather its own food.

Under the influence of warmth and moisture the germ is quickened

into activity, and at the same time the perigerm elaborates a substance which is known as a soluble or unorganized ferment, the office of which is the digestion of the store of starch with which it is surrounded. This soluble ferment, diastase, or digestive fluid, comes in contact with the starch-granules and converts this substance into glucose and levulose. This is exactly similar, physiologically, to the formation of the peptones by the gastric juice of the animal, and is the digestion which fits the food, the starch, for the needs of the developing germ of the corn. When this remolecularization of the starch is thus accomplished, it is taken up by a set of ducts that convey it to the germ. This set of ducts ramify plentifully through the mass of the perigerm and form a plexus immediately beneath its epithelium, a layer of columnar cells separating the perigerm from the starch envelope. By the careful use of sugar tests it is possible to follow this sugar along these ducts to the germ, and, after the growth of the germ has advanced somewhat, into the ducts of the growing plant. But here it is lost; another kind of remolecularization has taken place, by which it is converted into the tissues of the growing plant. This change is nutrition. As these processes go forward, and are followed by the preparation of sections at the expiration of each twelve hours after the planting of the grain, it will be seen that the starch-grains that lie nearest the perigerm have disappeared, and that the meshes in which they lie are empty, and afterward those that lie next, and so they continue to disappear as the germ grows, until its rootlet has struck down into the soil and the leaflet is spread to the air. The organs for the gathering of the food for the plant have found the elements from which that food is to be obtained, and the store of starch, not yet quite exhausted, is no longer needed.

But this is not all. If the grains of corn are planted in a soil the constituents of which have been chemically examined, it will be found that during the process of germination this soil has received acetic acid. This is in accord with the laws of life as we find them everywhere expressed wherever they have been sufficiently examined, for in conjunction with all growth we find the formation of waste products. In this case the waste products are acetic acid, which is left in the soil, and carbon dioxide, that is given off to the air. This, as we shall see presently, is the type of the process of fermentation.

Suppose we have planted the seed in two inches of damp sand placed upon a piece of polished marble. Growth takes place, and the roots strike down through the loose sand and soon come in contact with the solid stone. They are unable to penetrate this, and, instead, they spread out upon its surface. After this growth has continued for a time, if the plants and sand be carefully removed from the polished stone, it will be found that wherever a rootlet has come in contact with it, it has left its trace in the form of a removal of the polish; and a close examination of this shows that a portion of the solid rock has been dissolved and removed, leaving the imprint of every rootlet (Sachs). The roots have been doing the same toward the stone that the perigerm did toward the store of starch. They have been preparing the food for the nutrition of the growing plant, and the hardness, the apparent insolubility, of the stone has not been a sufficient barrier against them. They have

furnished the means of dissolving it (Sachs supposes this solvent to be carbon dioxide), and have appropriated such of its elements as were demanded by the needs of the plant. This is an illustration of the universal law that all living things, both plant and animal, must digest and prepare food-material for assimilation. In the physiological sense it is not essentially different from the digestion which takes place in all the higher animals, including man. In the higher animals this is a very complex process performed by an elaborate physical mechanism. In the walls of the stomach a special tissue is developed, the office of which is to prepare the unorganized ferment, pepsin, which, with the aid of other substances elaborated by similarly specialized organs, performs the office of digestion for the whole group of cellular forms that constitute the animal.

In the seed there is still a division of labor. Here we find, indeed, in the perigerm an organ set apart for the accomplishment of the act of digestion as in the higher animals, but its mechanism is so different and so simplified that nothing but the closest study of its functions will remind the student of the analogy that exists between it and the stomach of the animal. In the plant there is no specialized group of cells for this office, but the performance of the act is distributed among the rootlets. Now, when we follow this process down through the lowly organisms, we find a continuous simplification of the mechanism for the performance of this function until all trace of a specialized organ is lost.

Shall we conclude from this that the function is lost? Is it not more probable that as we descend to those very lowly organisms we will find all of these functions combined in the single cell? If, now, we turn our attention to the plant known as the torula, which is the active agent in alcoholic fermentation, and study its physiology, we find the following facts:

"When pure vinous yeast is washed with distilled water, a peculiar substance is found dissolved in the water. This is yielded continually during the life of the plant. Examinations have proven this substance to be an unorganized ferment having a peculiar effect upon sugar. This has been examined by Berthelot, Becamp, and others. It has been precipitated and obtained in the form of a powder somewhat similar to pepsin, and when redissolved has been found to retain its original power over cane-sugar. This action is to split up the sugar into two substances, called glucose and levulose. . . . .

"This reaction always takes place as the primary step in alcoholic fermentation, and is the primary digestion which permits the appropriation of the food-material by the yeast-plant. This is entirely analogous to the digestion of food in the stomach of an animal, by which such food is received in the blood, to be conveyed to the tissues for their nutrition, and is the same as the digestion of starch in the seed; but it is accomplished in the surrounding media instead of a receptacle provided for the purpose.

"This is one instance of a type of digestion which I believe to be universal in case of all unicellular animals and plants. The formation of a stomach is a provision for the conservation of force, but it in no way changes the *modus operandi* of the digestive function." [1]

[1] *Formation of Poisons by Micro-organisms*, p. 84, Black.

Here, as in all other forms of life, we are unable to follow by any form of experimentation known to us the further changes that take place. In the seed we have followed the digested material into the ducts of the growing germ, and they are lost in what we suppose to be the changes of nutrition. In the animal we may follow the digested material into the blood, and again it is lost in the changes of the nutritive process. But in both of these we find the material returned again in the form of waste products. Now, in the yeast-plant we have also followed the changes consequent upon the digestive process. We may also watch the growth of the plant by the aid of the microscope, and see the young buds spring forth, and follow their development into full-grown cells. We have no reason for the supposition that this growth is different in the main points of its physiology from the other forms of life that we see around us. Then the further changes in the digested material must be those of the nutrition of the plant through which its growth is maintained, and in harmony with all other forms of life the material must be returned in the form of waste products. This we find in the form of alcohol and carbon dioxide. This, then, is fermentation, and forms the recognized type of all of the fermentations known to us. In all that have yet been sufficiently made out, in which the life-processes have been successfully followed, the essential phenomena have been found to agree substantially with those here detailed. Among the animal forms the principal waste products are urea and carbon dioxide. Among the vegetable forms the waste products are the alkaloids, the organic acids, and carbon dioxide. In the torula, which is the agent of alcoholic fermentation, the waste products are alcohol and carbon dioxide. In acetic fermentation the waste products are acetic acid and carbon dioxide. This proves to be the law of fermentation and putrefaction so far as they have yet been accurately followed.[1]

It will be seen that these propositions cover the essential factors of all life-processes, and link together the proposed three kingdoms (the microbe, the vegetable, the animal) in one chain of functional activities that are common to all and necessary to all. That fermentation is the result of the life-processes of certain forms of micro-organisms may now be accepted as a truism, and will not be argued.

There are certain chemical processes which in their results closely imitate the fermentations. These are still called fermentation, but they are essentially different in their mode. A number of substances which are formed naturally by true processes of fermentation can be formed artificially by chemical processes.

What is called fermentation by an unorganized ferment is but the first step in a true fermentation. In digestion this is seen in the conversion of starch into sugar by the ptyalin of the saliva, in the conversion of flesh into peptone by pepsin, in the conversion of cane-sugar into glucose and levulose by the unorganized ferment of the torula or vinous yeast-plant. All of these are agents formed in the life-processes of living organisms, and the fact that they may be separated from that organism, precipitated, and dried, and will perform their function afterward on

[1] I have developed these laws more at length in the little work *Formation of Poisons by Micro-organisms.*

being dissolved in water, only shows their wonderful power. They are only the agents of digestion separated from the organisms by which they were formed. The boiling temperature renders them inert.

The essential physiological processes of the life of agents of fermentation must harmonize with those which characterize life in general, for while, in the study of biology, we find the most endless variety of form, there is presented only one plan of relation to the material world. The physical instruments for the performance of these acts may vary indefinitely without vitiating the act itself. Thus a description of a process of fermentation of any particular character involves the physiological processes of the organism which is the agent of that fermentative change. This is very much more important than the morphology of that particular form of life. As the agent of fermentative changes, we are principally interested in its behavior toward the material world in respect to its physiological acts; or, in other words, we should inquire into the nature of its digestive agent and its waste products. What is its food, and in what chemical form is it delivered back after having served the purposes of the organism? These are its essential characteristics. As a micro-organism, its *form* may be confounded with others even by the skilled observer.

It is this feature of the experimentation and observations of Dr. Miller of Berlin that gives them their peculiar value. In the studies of this subject in its relations to caries of the teeth antecedent to his, many had perhaps seen the same micro-organisms, which act as the agents of that fermentation by which the acids are formed, through which the dissolution of the substance of the tooth in caries is effected; but no one had made sufficient study of their physiology to know anything of their remolecularizations of matter, and they therefore failed to learn their essential characteristics. While these previous studies were very important in that they served to show the difficulties with which the observer had to contend, and were essential to the formation of appropriate plans of experiment, they are now of little use in the further elucidation of the process of caries.[1]

Dr. Miller began his observations with a series of experiments with saliva, with a view to ascertaining whether, organic germs being excluded, it contains anything capable of setting in motion such a process of change as would produce an acid at isolated spots where it or food might be detained about the teeth. In this search the ordinary phenomena of the conversion of starch by ptyalin was observed, but with this conversion the process terminated. Sugar was formed, but no acid of any kind. This agrees perfectly with all that was known of the fermentative powers of this fluid; and from many sources we have learned that the further decomposition of food-particles lodging about the teeth must be in accord with the decompositions in general—that is to say, it must be

[1] The experiments of Dr. Miller of Berlin, Germany, to which I shall have frequent occasion to allude in what follows, were published in the *Independent Practitioner* of February, March, and May, 1884, and May and June, 1885; and I deem them so important that, with the consent of Dr. Miller, and through the courtesy of Dr. Barrett, editor of the above-named journal, they are reproduced as an appendix to this paper.

accomplished by the life-processes of an *organic ferment*. In the decomposition of these particles as they from time to time are presented in the mouth, a considerable variety of fungi are to be found. The separation of each of these the one from the other, and the study of their physiological processes separately by individual cultivations, would be a great task, and was not at first undertaken. In the previous studies of this subject it had been sufficiently determined that the micro-organisms appearing in the deeper parts of the mass of progressive caries were much more constant in their characters and apparently presented fewer varieties. This being the case, it seemed best to study the organisms found there. With this in view, culture-mediums[1] were infected by fragments of softened dentine taken from the deeper portions of the carious mass, with precautions to prevent the ingress of any germs from other sources. These were kept in an incubating apparatus at the temperature of the blood. The usual controls (culture-mediums prepared, but not infected) were placed with them. Fermentation took place promptly in the infected tubes. This occurred with sufficient uniformity to demonstrate conclusively that the ferment was derived from the carious dentine. The fermentation was constantly accompanied by acidification of the culture-medium, as shown by the use of litmus-paper. Other mediums were then infected by transferring to them a minute portion from one of those that had undergone the fermentative process. These new cultures promptly underwent the same process. This was continued for a sufficient number of generations to show conclusively that there was present an organic ferment capable of the continuous propagation of its kind—a point of great importance in this investigation. This much being determined, the question of the capability of the acid generated to decompose the elements of the tooth without other concentration than that attained in the culture was tried. For this purpose fragments of fresh and sound dentine were introduced into the cultures. These were promptly softened by the solution of the lime salts.

Thus was found a ferment within the carious dentine showing itself capable of continuous propagation in a certain line; hence, a living ferment. It was also demonstrated that this living ferment is capable of forming an acid of sufficient concentration to decalcify dentine. In connection with these cultures there constantly appeared a micro-organism in appearance the same as that so constantly present within the carious dentine. As this remains the same in all of the cultures, it is perfectly evident that it is the organic ferment which by its life-processes produces the results stated.

By methods which seem to have been carried out with due care, Dr. Miller has found, isolated, and tested the unorganized ferment (soluble ferment) or digestive fluid of this organism. This he found to have an effect upon cane-sugar identical with that of the unorganized ferment of the yeast-plant—*i. e.* it converts cane-sugar into levulose and glucose (dextrose). This action is similar to that of most of the organisms subsisting upon the sugars.

The acid produced has also been subjected to analysis by the same

[1] See appendix to this paper.

experimenter, and found to be lactic acid, the waste product of the organism.[1]

Thus the four essentials in the physiology of this organism have been made out—viz. a digestive body, assimilation as shown by growth, a definite waste product (lactic acid), and the capacity for reproduction in a definite line of forms. These findings sufficiently demonstrate the existence of a living ferment; and as this ferment was in all instances obtained directly from the deeper parts of carious dentine, and the acid produced is proven to be sufficiently active, without further concentration, to decompose the elements of a tooth, the evidence seems sufficient to connect it with this process as the cause.

There are, however, some other points in the physiology of this organism, some of which have been determined; very important in relation to the process of decay. In the depths of a carious mass the access of the oxygen of the air is, to say the least, very precarious, and it becomes important to know whether the organism is capable of development when excluded from free oxygen. It would seem, from a review of Dr. Miller's experiments, that it is practically anaërobic, as its development is not hindered by any exclusion from the air that he was able to devise. It is also certain that the presence of oxygen is not especially detrimental to its growth or its acid-generating power, as it produced sufficient acid to decalcify dentine when enclosed in a tube corked with cotton. Therefore the organism is capable of development and the production of its characteristic acid *on the surface of a tooth* upon which it may find a lodgment, or in the innermost depths to which it may penetrate the dentine. In its relation to caries this is a very important consideration; for if there is no other hindrance to its development and the performance of the functions detailed, caries would be practically incurable without the complete removal and exclusion of the organism from the carious cavity. As it might proliferate anew and renew the fermentative process, the leaving of a single germ on any part of the walls of a cavity would effectually destroy the usefulness of an otherwise most perfect stopping. After making many examinations of decayed dentine and the organisms found in it, I cannot conceive that in all of the carious cavities successfully treated by the stopping process a perfect removal can have been effected; some explanation of their failure to proliferate becomes necessary.

It is possible that this explanation will be found in a failure of the food-supply of the organism. It is well known that micro-organisms are often confined to certain qualities of food, as is the case with other

[1] In the earlier controversies it was pointed out by Justus Liebig that if alcohol was formed as an effect of the life and growth of the yeast-plant, as claimed by Schwann, it must be regarded as the waste product of that organism. In the discussions of recent years this point has not had the prominence given it that it deserves. Indeed, most writers have left it without explanation. At the same time, they have recognized certain facts going to show that this is the true explanation of the phenomena. One of the most prominent of these is that this product, when it exceeds a certain amount, is always poisonous to the organism which produces it, and thus checks its development. This effect is in all respects similar to that of urea upon the animal in case of failure of excretion, and in harmony with well-known physiological laws. Dr. Miller in his experiments has found also that when a certain amount of lactic acid has been formed the growth of the organism is retarded.

organized beings, and Dr. Miller's findings seem to demonstrate with sufficient clearness that the different forms of sugar constitute the natural food of the plant, those not directly fermentable being promptly converted by the unorganized ferment of the organism. It seems also that the organism is capable of growing in beef-extracts without the presence of sugar, but with such a complete change in its physiological operations that *no acid is produced.* This singular phenomenon is vouched for by Dr. Miller. In my own experiments on this point the fungus did not seem to grow well, but there was generally, after some days, a slight acidification, though nothing comparable to that in the sugar cultures. The great difficulty I experienced in the prevention of contaminations leads me to place more confidence in Dr. Miller's experiments than in my own, yet after what I have seen I cannot regard the organism as being *at home* in a pure beef-extract. *Then, if by the operation of filling it is enclosed in such a manner that sugar cannot be obtained, its power in the production of caries is at an end as soon as the sugar enclosed with it is consumed.*

So far as the growth of the organism in the mouth is concerned, the question of its power to digest starch is of but little consequence, for the reason that this substance is always converted into a fermentable sugar by the ptyalin of the saliva. Therefore, if any of the forms of sugar or starch are present in solution, they will be readily absorbed to almost any depth by carious dentine. Thus the organism is supplied with the proper food for the production of lactic acid, and can act in the production of caries. There are, perhaps, very few mouths in which this form of food is not supplied in sufficient amount for its needs, and it is well demonstrated by experiment that in case of temporary deficiency there will be no destruction of the organism, for it may subsist—for a time, at least—without this aliment.

This series of facts developed by direct experiment seems sufficient to demonstrate the correctness of the suppositions of Robertson and Regnard. They fill the gap left by them—viz. the demonstration of the process of fermentation and the production of the acid by which the constituents of the teeth are decomposed. This demonstration, however, does more than explain the development of the acid and the solution of the lime salts of the tooth. Caries presents phenomena other than these, and which all previous theories failed to account for—notably the widening of the tubules and the constant appearance of micro-organisms within them; for in the solution of teeth by acids this characteristic widening of the tubuli is not present. In natural caries the tubuli are constantly found packed full of micro-organisms, and in the series of experiments alluded to it has been demonstrated that these organisms are capable of liquefying several varieties of semisolid culture-mediums, and my own experiments show that some liquefaction of gelatin occurs in the presence of a very small amount of sugar. In addition to this, it is fairly well shown that the organism is capable of living on pure beef-extracts. To do this it must digest them. With these facts in view, the widening of the tubules is easily accounted for. A portion of the glue-giving basis-substance, after having been robbed of its lime salts, is dissolved. It is probable that this is done by the unorganized fer-

ment of the organism, and that the results of this digestion are appropriated. Indeed, the known facts detailed render this the most obvious explanation of the phenomenon. It accounts not only for the widening of the tubules, but for the final complete breaking down of the structure of the dentine with the formation of a cavity. It is not necessary, however, to refer the final disintegration of tooth-structure to the action of this organism alone; for after a considerable degree of softening has occurred it is probable that other organisms, so plentiful in the mouth, may assist in the process.

Another point in the physiological processes of living beings deserves notice here. It is an established law that the waste products of an organism become poisonous to that organism when they have collected in a certain quantity. This is true of urea in the animal, it is true of alcohol in the vinous fermentation, and Dr. Miller found it to be true of the organism causing caries. When lactic acid has accumulated in certain amount (this amount being not yet definitely determined), the further development of the organisms is interfered with. Their power to go on producing lactic acid in the depths of the dentine is accounted for by the formation from the lime salts of the tooth of the lactate of lime, which does not interfere with the further development, and, in fact, is equivalent to a removal of the waste product. Long before the existence of a special organism in lactic fermentation was known, it had been found that by adding chalk or other form of lime the fermentation could be continued and much more lactic acid produced. Following up these facts, Dr. Miller has analyzed carious dentine and found it to contain calcium lactate.

With these facts before us, the localization of caries is no longer an enigma. It is clear that with the motions of mastication and of the lips and tongue these organisms will not be allowed to grow on any parts of the teeth that are exposed to friction. Hence caries never occurs at such points. But they may grow in the form of little colonies in any places where they are secluded from direct washings by the saliva, and in which they are protected from displacement. Such protected points are found between adjacent teeth, in pits, fissures, or any irregularities of form that will give them lodgment. *These points give the opportunity for fungi.* Direct experiment shows that they will produce acid abundantly within twenty-four hours after their implantation. If in any such place this acid is developed in contact with the tooth, and the development is allowed to progress without interruption, the effect of the acid will be to decompose the enamel, and finally to penetrate it and form a place of lodgment in which the fungus can continue its development without being subject to frequent displacements. Many have said that this fungus is incapable of attacking enamel. That is evidently true. The fungus has no power of attacking anything or growing into anything, except it be a thing that offers spaces filled with soft tissue, or openings into which it may grow as the vine grows through the spaces in a lattice-work. It is not the organism that makes the attack, but the products of the organism, the lactic acid. When the dentinal tubules are once exposed, they form a protection to those filaments of the fungus which strike into them in the process of

growth, and development occurs in that direction. Hence the continuous progress of caries when it has once fairly begun in the dentine. Then the growth will continue in any direction in which space is offered for the development of filaments. In this way the tubules become packed full of the organisms, and the surrounding dentine is always decalcified in advance of the growth of the fungus by the lactic acid produced. That this is the true explanation of the etiology of dental caries there is no longer a reasonable doubt. There is nothing presented in the phenomena of the affection of which this does not afford a rational explanation. That there are difficulties still surrounding some phases of the occurrence or non-occurrence of the affection in special cases and under special conditions there is no question. These will be discussed on another page.

I take the following extract, written by the American editor, from Coleman's *Dental Surgery and Pathology:*

"A theory has been advanced that these parasites, which may be found in mouths where the teeth are perfectly sound and without any unfilled cavities of decay, have lodged in the carious places simply as locations where they are partially protected from dislodgment by the breath, drink, or food, as fissured rocks will support vegetable or animal life in the crevices, while the smooth surfaces, exposed to the winds and rains, are bare of vegetation."

So far as plant-life is concerned this is about correct. The rootlets of plants can no more obtain a hold upon the rocks in such positions than the fungus of caries can grow on the exposed parts of a tooth. But where a crevice furnishes a place for the lodgment of a seed, and moisture retains a little dust, plants are found to grow, and their rootlets emit a solvent that causes the solid stones to yield them nourishment. In this way the hard rocks are caused to crumble. I have already explained how it is that the rootlets of the growing plant leave their imprint on polished stone. It is well known that old tombstones that have been allowed to become moss-grown first lose their polish, then their surface is softened and crumbles away. The lichens leave their imprint upon the rocks by dissolving and appropriating a part of their substance. So it is with plant-life wherever found. The relation of life to the material world is such that many of its forms will wrest their food from even the solid stones by aid of the juices formed for this purpose. The fungus of caries destroys the teeth in a similar manner.

Phenomena of Caries.

The phenomena presented by caries have been well described by Tomes and others who have followed him. In this study there has not been much disagreement as to what has been seen. There have, however, been sharp disagreements as to the interpretation of the phenomena observed. The more important of these points of difference have now been for the most part harmonized, and the controversy need not here be revived. For these reasons I do not deem it desirable that the progressive development of the views now entertained be followed

out. It will be sufficient to describe these changes as we now understand them, with but occasional references to the views of those who have previously written upon the subject.

Caries is not known to begin on a smooth, clean surface of a tooth. It may, as already stated, begin in any position in which lodgments occur, whether the surface be even or not, but it is seen much oftener to occur upon uneven surfaces, or those that lie in contact with an adjoining tooth or in such relation to it as to protect a portion of the surface from friction, and thus favor the lodgment of particles of food. Fissures that occur in the enamel are also often affected with caries. In case caries begins in a fissure of the enamel of a tooth after it has fully risen above the gum (in the eruption of the tooth), the first obvious sign is the dark color of the fissure. This change of color may be very decided or very slight. The amount of change of color in the fissure itself gives no indication of the amount of caries. Indeed, we may often find these fissures discolored when there is no caries whatever. Usually, however, trial with an instrument will show an exposure of the dentine, with softening immediately beneath the fissure. Probably, in a large proportion of these cases, the enamel in the deeper parts of the fissure was never perfect. Often there may be reasonable doubt as to whether the imperfections seen are the result of the agent productive of caries or of faulty development. I will therefore describe the effects seen in caries of the enamel in connection with the appearances presented by the affection in other positions.

When the enamel of a fissure has been penetrated, a softening of the dentine occurs immediately beneath. If the tooth is very nearly normal in its structure, this softening is in the form of a cone with its apex toward the pulp of the tooth and its base against the enamel immediately surrounding the fissure. If the fissure is of some considerable length, it may modify this form slightly. It is readily seen from the form of the cavity that there is a tendency to follow the dentinal tubes, for the greatest penetration is almost uniformly along the length of those tubes terminating immediately beneath the fissure. There is also seen a marked disposition to extension laterally. When I analyze my observations closely in regard to this lateral extension, I find it to be very much confined to the immediate region of the junction of the dentine and the enamel. If now the structure of the dentine at this point is closely studied, it is found to be a region in which there are a great number of anastomosing loops connecting the dentinal tubes, and as new tubes become involved penetration takes place in the direction of their length. These facts show that there is a strong tendency to penetration in the direction of the natural openings in the dentinal structure—a fact that has been remarked by most of those who have studied the subject, especially by Tomes, Leber, and Rottenstein. The penetration, however, does not in all cases seem to be confined to these directions, for carious cavities are found of the most various shapes; and the instances in which penetration has been transverse to the direction of the tubules are not few. These differences have been especially noted by the older authors, and have given rise to the terms "penetrating caries," "spreading caries," etc. These deviations from the direction

of the tubules are often, if not always, due to faulty formation of the dentine. This is most distinctly demonstrable in the case of what is called *spreading* caries. It is seen oftener in the first molars than any other teeth, and in the carious points having their beginnings in the fissures of the grinding surface. In these cases, if the carious process has not already progressed so far as to have destroyed much of the crown, it will at once be seen that the development of the first-formed portion of the crown was distinctly faulty. If the decay has proceeded so far as to destroy the evidence of this in the particular tooth, it may generally be demonstrated by the examination of those portions of the other teeth which were in process of formation at the same time. Thus, when the first molars are affected, the surface at or near the cutting edges of the central incisors should be scrutinized. In these cases the decay often spreads over the crown of the tooth superficially, destroying the entire grinding surface without penetrating to a considerable depth. Not unfrequently this is so very marked that the caries is seen to extend under the enamel over the margins of the grinding surface in such a way that when the enamel breaks away the remaining part of the crown is nearly flat. At this point the decay may cease, as the parts are smoothed down by the friction of mastication.

If in a case of this kind not too much affected by the destructive process sections are prepared for microscopic examination, it will be found that in the dentine there are numerous imperfections in the form of interglobular spaces, or there may be very imperfect depositions of lime salts, presenting various forms, but especially are they often seen in the form of a granular layer, more or less thick, just beneath the enamel. Every case of caries I have examined presenting marked deviations from the direction of penetration which I first described has been explainable on the basis of faulty formation. Therefore the proposition seems to be maintained that *caries penetrates dentine mostly in the direction of its natural openings*. The fact that in many cases the openings are abnormal and due to faults of development does not affect this statement.

FIG. 402.

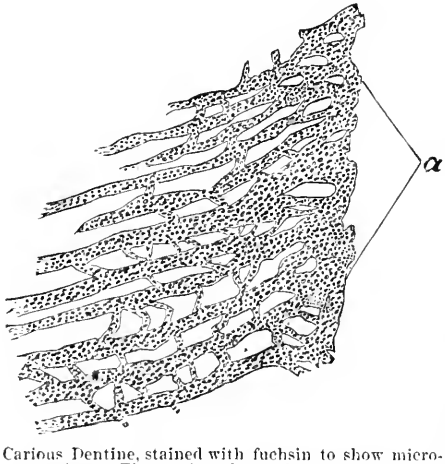

Carious Dentine, stained with fuchsin to show micro-organisms. The section shows the condition of the tubules as filled with micro-organisms along the junction of the dentine with the enamel at *a*. The tubules are very much enlarged. ($\frac{1}{5}$ immersion objective.)

The penetration transversely to the dentinal tubules of the crown portion of the tooth in normally-formed dentine is usually very slight indeed, and that which does occur is probably due to penetration through the very fine connecting tubuli which pass from the one to the other. The reasons for this become very obvious when considered in connection

with the cause of caries as detailed in the former pages of this paper. The fungi which effect the dissolution of the elements of the tooth by the formation of their special products grow into the natural openings, and are confined to them until such time as the structure falls to pieces. This falling to pieces does not occur suddenly, but there is ordinarily a more or less considerable thickness of affected dentine covering that which is yet normal. In this, in which the histological elements still retain their forms nearly perfect, the natural openings are found to be crowded with the fungus up to within a short distance from the normal tissue. There is, I believe, always a zone of partially softened dentine, free from the fungus, lying next to that which remains normal. In all the lateral branches large enough to admit them, the fungus granules will be found in single file, while very many tubuli are seen to be too small to permit their entrance. Thus a reason for this peculiarity in the direction of penetration is furnished.

If, beginning at other points on the surface of the tooth, the direction in which caries penetrates is examined, we find the same general rule observed; and if the structure of the tissue involved is known, the direction that the softening will take may be readily foreseen. The deviations from the normal direction of the natural openings of the tissue will be in consequence of some one of the forms of abnormal development; and an acquaintance with these will be, in the main, a sufficient guide in determining the direction probably followed by the carious process in those instances of deviation from the usual course which are occasionally met with. All who have made extensive studies of faulty development have noted the frequency of a granular zone just beneath the enamel, especially in the sides of the crown toward the neck of the tooth. In other cases there is a distinct enlargement of the anastomosing loops of the tubules at the juncture of the dentine and enamel. Again, rings of interglobular spaces more or less perfectly encircling the crown occur quite often. Many of these are, however, broken up into irregular clumps or isolated patches. It will readily be seen that these conditions will give the direction of penetration great variations and result in cavities of irregular forms. Some will spread widely just beneath the enamel and produce a broad shallow cavity; possibly this spreading may be in a particular direction, which, if the point of beginning is on the side of the crown, is likely to be in a direction leading around the tooth.

The penetration of the structure in the line of the tubules leads to the exposure of the pulp, usually before great spreading has occurred. Extended examinations show that in any considerable number of cases in teeth of the best development exposure of the pulp will occur with the least destruction of tissue; that is to say, that the more perfect the development, the more completely the penetration is confined to the direction of the tubules.

The effects of the softening of dentine by caries are different from those observed in softening obtained by simple solution in an acid. If a section of dentine is subjected to the action of a mineral acid, the decalcification of its whole substance occurs; but there is a marked disposition to the isolation of the individual tubes by the more rapid solu-

tion of the intertubular substance. In this way, by careful work, the tubules may be isolated without any apparent enlargement of their internal calibre. The appearances are distinctly different in caries. It is true that there is seen some disposition to the isolation of the tubules, but at the same time the internal calibre is distinctly and markedly enlarged; and this enlargement of the internal diameter is often, if not most generally, such as to destroy the walls of the tubes before the dissolution of the intertubular substance, thus merging two into one, three into one, etc., until the histological structure is lost. In many instances this enlargement is seen to be quite regular, but in the greater number of cases I have examined there has been a disposition to irregular swellings or a more or less nodulated appearance of the individual tubes. Among the different tubules there are also very great differences noted. Some are very much enlarged, while others are but slightly changed. In all of these a proper staining with an aniline dye will show that all available space within the swollen tubules is occupied by micro-organisms. This condition of enlargement does not occur until the tubules are occupied by this fungus. As has been before remarked, the softening precedes the growth of the fungus, but the enlargement of the tubules does not.

Very early in the progress of the softening the tubules present a very peculiar appearance, in that the intertubular substance becomes more clearly defined, and in such a way as to outline the tubular walls. This appearance has been described by Tomes as similar to a multitude of tobacco-pipe stems in cross-section. The effect will not be produced by the solution of dentine in an acid, but is peculiar to caries as it occurs naturally in the human mouth. In stainings made with chloride of gold of sections of fresh dentine softened to a certain degree with acids this appearance may be greatly exaggerated by the staining of the walls of the tubules a bright red, while the intertubular substance remains clear. It may also be shown in other ways that the intertubular substance is different in some degree from the walls of the tubules; but no satisfactory explanation of this peculiar appearance in caries has yet come to my notice.

The penetration of enamel is distinctly different from the penetration of dentine. This substance has not the natural openings that are characteristic of the dentine, and therefore does not present the same opportunities for growth of the fungus within its structure. It has been held by most of those who have written on this subject that the fungus is incapable of attacking enamel. If by the term "attack" is meant an invasion or growth of the fungus into the substance of the enamel, this view is correct. No signs of the fungus are to be found in the enamel until after it has become so far disorganized that its crystals are loosened and begin to fall apart. Except that of localization, and in some instances discoloration, the softening of the enamel in the first stages of caries presents no other phenomena than those produced on that substance by acid action out of the mouth. In case this effect is rapid, the enamel is seen to lose its transparency, and soon its crystals or prisms show a disposition to fall apart in such a way as to give the impression

that they have been separated the one from the other.[1] This disintegrated material is easily removed from the surface in the form of a fine dust, and upon microscopic examination is found to be composed of short lengths of the enamel-prisms or rods. It seems that the acid has the effect of dissolving the connecting substance which unites these prisms or rods into a compact mass, and that the rods themselves are dissolved more slowly. Thus the enamel first becomes porous, and finally some of the rods fall away, leaving minute openings through its substance by way of which the fungi of caries are admitted to the dentine beneath. On the proximal surfaces of the teeth, near the point of contact, a portion thus softened may frequently be found; this may be brushed away and the surface again polished, and show no opening exposing the dentine. Other such cases may on careful investigation show one or several openings of minute size through which the dentine is exposed. After such exposure the enamel is undermined by the more rapid softening of the dentine, which extends laterally under it. In this condition the enamel is more or less *disintegrated from its internal surface.* This disintegration presents precisely the same characteristics as that occurring on the outer surface.[2] In this way the enamel is gradually destroyed through its entire thickness, or more often, by the more rapid disintegration of the dentine beneath, is weakened and left unsupported, and breaks away, leaving the opening into the cavity jagged and irregular. In many instances of very rapid decay, however, especially if the enamel be very thick and strong, the carious process will extend to a considerable distance under it laterally before breakage occurs; and in this case the opening may be so small that the cavity might escape detection but for a slight discoloration which is seen through the enamel.

Discoloration in caries presents a wide range of variation. When it occurs in the fissures, as in the grinding or buccal surfaces of the molars, it is generally accompanied from its commencement by a dark color of the enamel along the walls of the fissure. The carious dentine beneath may be very dark; it may also be white, slightly yellowish, or of any shade between this and a jet black. In caries commencing in the proximal surfaces of the teeth, if the progress in the enamel be very slow or if the process of softening has been only slight and then has ceased, the surface of the enamel becomes very dark to a point as deep as the injury to its structure extends. In many cases, however, particularly those in which the progress is rapid, the surface of the enamel affected loses its transparency, but remains white, or it may be even whiter than normal. The rule, both in caries of enamel and in that of dentine, is that the more rapid the progress of the disease the lighter the resultant color. But even

[1] As representing the histological elements of the enamel, the words prisms, crystals, and rods have been used in a like sense by writers.

[2] J. Tomes has described the solution of the enamel-rods as occurring first in the central part of the rod. This appearance is often given in artificially-prepared specimens in which a section has been momentarily exposed to the action of an acid. But in all of my experiments in which sections have been exposed to the action of dilute acids until the enamel-rods have fallen apart, it has seemed clear that the connecting substances were primarily dissolved, thus separating the rods. I have uniformly found this true of carious softening.

where the mass of the carious contents of a cavity are light colored there is often some discoloration about its margins. When the opening into the cavity is hidden on the proximate sides of the teeth or under cover of a deep fissure, the location of many carious areas is shown by their color appearing through the enamel.

The discoloration of the carious parts does not seem to depend in any degree on the carious process. It appears to be determined by the settling of coloring matters into the partly-decomposed tissue. These seem to be derived chiefly from the dark sulphurets formed in the mouth by the action of sulphuretted hydrogen upon such metallic elements as may be present. This discoloration is easily and perfectly imitated out of the mouth upon teeth that have been acted upon to any considerable extent by acids. To accomplish this, place them in water holding a small quantity of sulphuretted hydrogen in solution, fill the vessel full, and place in the dark to prevent decomposition of the solution; and the tissues of the teeth, to a point as deep as that affected by the acid, will gradually assume a dark color. This fact, taken together with the other fact—that all rapidly-progressive cases of caries are in color white or nearly so, especially in their inner parts—leads to the supposition that the discoloration is in no wise dependent on the agent that produces caries, but is borrowed from without. It should be mentioned also that when caries has ceased or become *stationary* all of the injured tissue usually assumes a dark color within a short time. The color of caries, therefore, affords some index to the rate of progress. The lighter colors pertain to the more rapidly progressive cases, and the very dark colors, those that are dark through the substance of the dentine, to cases that are stationary. The fungus is dead.

Predisposing Causes of Caries.

The study of the predisposing causes of caries presents a wide range for observation and speculation. Certain conditions manifestly predispose the teeth to caries, and the manner of their effect is easy of explanation. Other conditions *seem* to predispose to caries, while the manner in which they act to that end is, with our present knowledge, not demonstrable. Many conditions heretofore regarded as active causes of caries must now be viewed as predisposing causes only, or as having no relation to the affection.

Faulty formation of the teeth is probably one of the most effective predisposing causes of caries. Yet in a more strict sense it cannot be regarded otherwise than as a condition giving *opportunity* for the disease. These faulty formations may be divided into two varieties of deviation from the normal—those relating to form, and those relating to structure, the latter of which, so far as they relate to the dentine, have been considered in connection with the phenomena of caries. It seems clear that an acid which will dissolve the lime salts of the teeth will do so whether the formation be good or indifferent; for this faulty formation has relation not to the molecular or chemical composition of these salts, but to the physical structure of the part. Density makes a great difference in the rapidity of the solution, on the same principle

that an acid capable of dissolving or decomposing very soft and porous chalk will also decompose chalk of the most solid form. The latter will, however be decomposed much more slowly than the former, for the reason that the acid can act only on the surface, while if the acid permeates the structure it will act much more rapidly. This is the principle upon which the more rapid decay of the teeth of faulty structure must be explained. We may add to this the fact that in many cases of faulty formation there is not so much of the lime salts to be dissolved as in the denser structures.

On this principle it is clear that if in any case the structure of the enamel is imperfect it will be more susceptible to injury by the agents productive of caries than if it were perfect, and will be penetrated where, under otherwise similar conditions, a perfect enamel would not; at least, the time required to effect the penetration would be very different in the two cases. The cause that acts on the one, however, will act on the other only in less degree.

Imperfections of the enamel of the teeth are liable to occur in any position. It has generally been claimed that they are especially liable to occur on the proximal surfaces. My own examinations do not bear out this idea. It is true that in the majority of cases the enamel is somewhat thinner on these surfaces, but its structure seems to be just as good as elsewhere, and its power to resist the corrosive action of acids is the same, except that its thinness allows it to be penetrated more quickly.

The faults in enamel which chiefly predispose to decay of the teeth are those which occur in the form of pits and fissures. These combine faults of structure with faults of form. They occur in the grinding surfaces, and less frequently in the buccal surfaces of the molars, in the grinding surfaces of the bicuspids, and in the palatine surfaces of the incisors. Teeth of the best form and structure otherwise seem to be most liable to this class of faults; especially those that are large and the cusps of which are very prominent. In most of these cases it seems that the growth of the enamel organ has not quite kept pace with the growth of the dentine, or that there has been a want of correspondence between the two in such a way that the last of the ameloblasts to be calcified are pulled slightly apart, a fissure resulting as a consequence.[1]

[1] I have carefully followed the formation of this class of faults in microscopic sections of growing human teeth during their entire period of development, and noted especially the relations of the formation of the dentine and enamel from the beginning to the end of the calcification of the crown. There seems to be an impression that the entire crown of the tooth is formed before the calcification begins. This is an error. The formation and calcification are in progress at the same moment, but as soon as a part is calcified it ceases to change its form. This calcification begins on the summit of the cusps, and at this time all of the form of the tooth that is unchangeable is represented in those points. The remaining parts of the tooth are not yet formed. Take, for example, a bicuspid. The first hard tissue is the points of the cusps, and these lie very close together, but do not touch. As growth proceeds they move farther apart continuously until the form of the grinding surface of the tooth is completed. Now, if there has been a strong growth of dentine, and the enamel is built thick and high on the cusps, the breadth of the enamel-membrane is not sufficient to dip down perfectly into the centre of the depression, and its cells are separated at the central point in such a way as to leave a gap which is finally represented by a fissure. The principle of the formation of the fissure is the same in all positions, and applies to the formation of pits

This is occasionally so complete that a portion of the dentine is left uncovered or with but a slight thickness of very imperfect enamel. This is not always enamel in the true sense, in that it is devoid of enamel-rods. It is probably composed of the same matter as the connecting substance between the enamel-rods, which, as we have found, is easier of solution than the substance of the rods themselves. This ease of solution, however, is not the principal condition predisposing to caries. The predisposition is found principally in the *form*—a pit or groove, giving opportunity for caries by serving as a point for the retention of particles of food, etc., until the process of fermentation has created an acid which will act on the tissue. When it is once implanted in them, these pits protect the fungus from dislodgment, thus favoring its development, and little by little the enamel is dissolved out and admission to the dentine gained.

The manner of contact of the proximal surfaces has much significance in predisposing the teeth to decay. Those in which there is the greatest amount of surface not self-cleansing are, other things being equal, most liable to caries. Hence, teeth so formed that the proximal surfaces are at all points very nearly in contact, yet without actually touching, are rendered more liable to caries, provided the festoon of the gum does not fill the space. When I analyze the conditions under which caries is most liable to occur, I am convinced that this is of great importance, and that caries generally does not occur while this space is filled by the gum to the point of contact of the adjacent teeth. Two reasons may be given for this: First, the festoon of the gum fills the space and tends to prevent lodgments from occurring; second, the secretion given out by the healthy gum, especially that coming from the gingival space, is antiseptic to a sufficient degree to prevent fermentation of very slight amounts of matter in immediate contact with it. Therefore, so long as the gum remains healthy, decay does not begin in immediate contact with its border. The breaking down of this septum of the gum by the repeated forcing of food between the teeth or from other causes becomes a predisposing cause of decay. I may add also that, without becoming distinctly unhealthy, the gum sometimes recedes slightly from between the teeth, and in this way predisposes the teeth to caries by giving opportunity for its beginnings, in that a receptacle is formed for the lodgment of particles which undergo fermentation in contact with the teeth. Malpositions of the teeth, when of such character as to favor such lodgments, also predispose to the beginning of caries; and in these cases it is often shown that what is supposed to be the strongest enamel will be penetrated if placed in such position that lodgments occur against it.

Hereditary influences are very powerful predisposing causes of decay of the teeth. This has been recognized by all who have examined the subject. Indeed, this influence is too manifest to be overlooked by any one who has given the subject close attention. It seems to me, however, that it has in the past been by many much overrated, though it must

as well. It seems evident that the ameloblasts will allow of some spreading without division one from the other, but this tolerance is limited, and in the later stages of calcification the power of proliferation is reduced to the lowest point.

be acknowledged as an important factor. Two separate factors enter into the law of heredity in its relation to caries: one of these is capable of demonstration; the other must for the present be regarded as an hypothesis. *The first is all told in the transmission of form.* That peculiarities of form are transmissible from parent to child is of course generally held to be a truism, and requires only simple mention. As has been seen in the previous pages, deviations from the best forms of teeth are powerful in predisposing to caries. This element of heredity, great as it is, is probably not the greatest. This does not furnish a reason why one person may go through a long life without caries, while much the greater number of his neighbors suffer from its effects. There is undoubtedly something in the constitution of the fluids of the mouth of different persons rendering them favorable or unfavorable to the propagation of fermentation. Differences in the constitution of the saliva of different individuals are sufficiently manifest. Some persons have saliva which is exceedingly viscid or emits a peculiar odor, and one or the other of these peculiarities is likely to be present in other members of the family. This is also true of other fluids, as the perspiration. It is also true that the lower animals are subject to diseases having their basis in the growth of micro-organisms to which men are not liable, and *vice versâ*. Men are but slightly susceptible to anthrax, which makes such havoc among sheep and cattle in some parts of Europe, while the lower animals are not subject to measles, whooping cough, etc. Again, adults are usually insusceptible to many diseases which prevail among children. In the present state of our knowledge we can account for these differences only on the supposition that there are variations in the constitution of the cellular elements or fluids which render them in the one case unfavorable, and in the other favorable, to the action of the cause of disease. It is only on this supposition that a rational explanation can at present be founded. There has been great endeavor to explain the tendency to caries upon the basis of changes in the nutrition and structure of the teeth themselves. Certainly, there has been sufficient study of this point to demonstrate that the predisposition is not explainable on this basis. We must assume that in some cases the cause of caries is not present in the mouth, or, if present, that it is too feeble to produce active results. There is not a sufficient difference in the structure of the teeth themselves to account for the manifest differences seen in practice. Indeed, the strongest and best-formed teeth often fall a prey to caries and are rapidly destroyed, while in other cases teeth not nearly so good either in form or structure are unaffected. When we examine the cause of caries and the conditions of its activity, we are forced to the supposition that the basis of these differences is in the environment of that cause, affecting its activity, not in the power of the teeth to resist.

This holds a close relation to heredity as manifested in other diseases. Of all diseases that are to-day regarded as hereditary, there is probably not more than one (syphilis) directly transmissible from parent to child. In all others the element of heredity must be in the constitution of the cellular elements or the peculiar character of the fluids that in some way renders the subject susceptible to the particular form of disease. If the

special disease has as its basis a change in the physiological qualities or activities of the cellular elements, as in the cancers, there is something in the physiological constitution of the individual rendering the cellular elements peculiarly liable to this form of excitement. If the particular disease has a fermentation as its basis, the fluids of the individual must furnish a favorable soil for the growth of the fungus of that fermentation. Again, persons acquire a temporary susceptibility to certain diseases, not from a condition of ill-health that is in any way manifest, but apparently through some minor changes, as yet impossible of analysis, in the action of the vital forces of the organism or constitution of the fluids. If we can trust the combined observations of the profession, changes that are of the same order certainly occur in the predisposition to caries. Why is it that pregnant women become temporarily more susceptible to caries? Certainly not from any change in the structure of the teeth themselves, rendering their lime salts more easy of solution by an acid. Of all the tissues of the body, the teeth are least prone to structural changes consequent upon variations in nutrition, and therefore are least liable to temporary susceptibility to disease on that account.

The saliva is certainly in a large degree antiseptic in its qualities, and opposes the process of fermentation, notwithstanding the fact that fermentation, in some of its forms, is continually in progress in the mouth. It is practically impossible to protect wounds of the mouth from micro-organisms, yet these wounds are less liable to sepsis than any others in the organism that are exposed to external influences.

It is possible that what have been noted as the antiseptic qualities of the saliva as seen in its relation to wounds in the mouth may be due to the continued irrigation of the surfaces by the flow of fresh saliva, which washes away septic organisms or their products. This in a large degree explains the occurrence of decay in protected points only, and furnishes a reason for the rare occurrence of caries in the lower incisors.

When all of the facts known to us are considered, the most plausible supposition is that there are differences in the saliva that in some cases render it an unfavorable soil for the propagation of the peculiar fermentation found to be the cause of caries. In other cases it becomes a very favorable soil for the growth of this peculiar fungus, and caries is correspondingly active. When we look around us and gather together the facts at our command in regard to the susceptibilities of those forms of life which we know, and see how they affect each other in ways that seem inscrutable, these suppositions, while losing none of their mystery, are seen to be in harmony with those forced upon us in other fields of observation.

Morbid Conditions of the Fluids of the Mouth.

By most authors who in the past have examined the subject morbid conditions of the saliva and of the mucus of the mouth have been considered as among the active causes of caries. In view of the explanation given in the previous pages, this becomes impossible. If the causes of caries have been correctly detailed, the influences favorable to

caries exerted by the morbid conditions of the saliva must be subordinate or secondary, in that they furnish a better soil for the promotion of fermentation or assist in decomposition by virtue of the acid they may contain. The first of these influences has been considered under the head of Heredity. That the fluids of the mouth often contain acids in a very dilute form, but sufficient in amount to be readily detected by litmus-paper, is well known to all who have given attention to the subject. This acid, whatever its origin, is distributed generally in the fluids. There is no localization demonstrable by our present modes of research, except it be that the mucus exuded from the gum in a state of irritation is more markedly acid than the other fluids. This latter point, as it affects only special cases, will be examined later.

Some years ago very extended examinations of the fluids of the mouth were made with reference to acidity and its possible connection with caries. I made personal tests in several thousand cases. These gave rather complex results, but in the main seemed to demonstrate that the two conditions were in no wise connected as cause and effect. So decided was this that, while I went into the series of observations with a conviction that Tomes, Magitot, and others were right in attributing caries to this cause, I retired with the belief that, whatever be the cause of caries, it has little or no connection with acid saliva. In many the tendency to caries was not in any degree related to the degree of acidity of the fluids of the mouth. In an article which I wrote in 1880, after this series of experiments, these sentences occur: "Decay of the teeth is certainly a specific disease, running a specific course, and evidently arising from a specific cause, but this cause is not as yet certainly known." . . . . "While there is no decay without the presence of an acid, there is not necessarily decay because of the presence of an acid." . . . . "While an acid is not only always present, but is probably a necessity to the inception and progress of decay, there may be an agent acting in conjunction with the acid that is not yet known or recognized."

Now, after the demonstration of the cause of caries by Dr. Miller, which represents the *unknown* in these sentences, we are able to analyze the probable effects of morbid conditions of the fluids of the mouth more closely than before, especially after studying the microscopic phenomena in the light thrown upon them by the demonstration of the cause. It is now perfectly clear that acids alone, while they may decalcify the teeth, cannot produce the phenomena of caries. Dr. Mayr has well said: "The decay under consideration is so specific that the mere action of acids is not sufficient to produce it."[1] The occurrence of micro-organisms in, and the widening of the calibre of, the tubules is a prominent manifestation without which the presence of caries, no matter what the amount of softening, may confidently be denied. This has now been confirmed by so many observers that it has become a truism; and after the studies of the physiology of this fungus cited in the previous pages we have no need to go to the fluids of the mouth to find the acid. It is developed *in situ*. Acids that are commingled with the fluids of the mouth, whether developed therein or introduced from with-

[1] *Independent Practitioner*, 1884, p. 195.

out, cannot produce caries. There is no reason why an acid commingled with the fluids of the mouth should exert a localized action on the teeth. Their action would be general, and greatest on the exposed surfaces. It is not impossible that some such effect is produced—indeed, I have seen evidence that such is the case—but this does not seem to have any relation to the localized action which represents the inception of caries.

Acid mucus occurs under circumstances that seem in certain cases to connect it with the inception of caries. These are those forms of the disease which occur near the margin of the gum in connection with points of irritation. In irritations of the gum-tissue there often arises a markedly acid condition of the mucus exuded at that spot. This has been especially noted by Tomes and Magitot, and is regarded by them as a direct cause of decay of the teeth. I cannot, in the light of recent developments, regard it as a cause of caries proper, but it may be productive of a softening of the tissue at that point or an actual solution of the lime salts, which will *give the opportunity for the implantation of the agents productive of fermentation and caries.* Certainly, observation seems to connect local irritations of the gingivæ with a certain proportion of that form of caries beginning about the necks of the teeth; and it is sufficiently demonstrated that under these circumstances the mucus is markedly acid. It should be noted, however, that in these cases the irritation is not of such a character as to be productive of pus. All observation shows that pus, wherever it occurs, is directly preventive of caries. If under any circumstances pus is continuously discharged into a cavity of decay, the decay ceases. This furnishes a reason why roots of teeth protruded through the gum, and thus exposed, so seldom decay. There is generally an irritation of tissue in their neighborhood sufficient to keep them more or less bathed in pus. This is also noted in case of roots which have lost their crowns, and the gum of which is in such a condition as to keep its broken end bathed in pus; also in some cases in which chronic alveolar abscess discharges into a cavity through the pulp-canal. This affords a condition of environment that is markedly opposed to caries; and, though pus is distinctly different from saliva, it is still an evidence of the possibility—we may say the probability—that changes in the constitution of the saliva may occur that will render it unfavorable to the propagation of caries.

There is another form of acid mucus that seems to be distinctly different from that produced by irritation of the gums, in that no irritation is apparent and the condition is more or less permanent. In some cases it seems to be hereditary. It may, however, be acquired. In this condition the mucus seems much indisposed to mix with the other fluids of the mouth. It is more viscid than normal, and may be drawn out in long threads by touching the finger to the gums and withdrawing it. I have seen cases in which these threads could be extended to the arm's length before they would break. This character of the mucus has been noted by a considerable number of writers, and seems to have been regarded as an active cause of caries. It certainly appears to furnish a condition favorable to the propagation of the disease, for in most of the

cases that have come under my observation caries has existed, and has been severe and usually difficult of successful treatment.

Absorptive processes stand in such close relation, clinically, to the production of acid mucus from points of irritation, and the results, when slight, are so similar, that it is difficult to discriminate between them. I have reference here to absorptions just beneath the margin of the gum or at the point of union of the soft tissue with the tooth, consequent upon some slight irritation. This is a factor in the predisposing causes of caries that has not until recently had recognition.[1] This absorption is in all respects similar to that which occurs at the roots of teeth which have been transplanted, and, like that, is dependent on a slight irritation of tissue, through which irritation it is caused to temporarily take on a new function—that of the production of a substance which dissolves the hard structures with which it is in contact, making room for the growth of its own granulations.

The phenomena of absorption may be studied in a variety of positions and circumstances. Wherever observed, we find very much the same conditions in the tissue involved. This is true whether it be in the removal of the root of a temporary tooth, removal of bone in change of form (physiological), removal of the roots of replanted teeth, burrowing into pieces of ivory that have been thrust into the flesh for the purpose of experiment (Krause, Koelliker, Tomes), removal of sponge in the sponge-graft, or the absorption of the surgeon's animal-membrane ligatures (pathological). In all cases granulation-cells or leucocytes are brought in contact with the substance to be removed, under the influence of which it gradually disappears. (In the physiological absorption of bone the osteoblasts have been regarded as performing this function.) Just what the cellular action is in these cases is not at the present time positively demonstrable. But that the substance which effects the solution is of the nature of an unorganized ferment seems almost certain. Krause suggests that it contains lactic acid. At any rate, the granulations invade the tissue gradually, and room is made for them by its disappearance. In this way the part is burrowed out, whether it be bone, tooth-substance, catgut, or sponge, and the granulations fill the space. In all cases of pathological absorption it is fairly demonstrable that the action is in response to an irritation or excitement of a mild character of the cells of the part in which leucocytes are formed or called and proceed to the building of granulations. If in any case the irritation is of such intensity that pus is formed, the process of absorption fails. As the part of the tooth acted upon rises above the soft tissues, this in time becomes dark colored; and if it be on a smooth, self-cleaning surface not too deep, no decay results. If, however, the process of absorption has produced excavations sufficiently deep to afford lodgments and thus give the opportunity for fermentation, the result is the formation of a cavity by true caries. Then these absorptions are not a direct cause of decay, nor are they caries in themselves; but they give *the opportunity* for the implantation of true caries, and are therefore a predisposing cause.

Prof. W. H. Eames of St. Louis has described certain effects upon

[1] *Formation of Poisons by Micro-organisms*, 1884, Black.

the crowns of teeth as the product of absorption brought about by the absorbent organ, so called, which removes the root of the temporary tooth or effects the liberation of the permanent tooth in the process of its eruption through the gums.[1]

Cervical absorptions (absorptions at the necks of the teeth) are generally very small affairs which before caries results are liable to be overlooked; indeed, heretofore they have been altogether unnoticed. They occur about the necks of the teeth after the age of maturity or late in life. As the irritation proceeds there is often a tendency to the shortening of the gingival margin, in such a way as to expose more of the neck of the tooth. In this manner the injury becomes exposed, and caries is implanted. In many cases the irritation causes a thickening and eversion of the gum in the form of a little pocket; caries is induced, and proceeds to the formation of a cavity. This is oftenest seen on the buccal surfaces.

I have said that cervical absorptions are generally slight. This, however, is not always the case. I have in my possession several specimens in which they are very large, having destroyed a large part of the crown of the tooth. In one of these, a lower molar, the pulp-cavity was laid open. The granulation-tissue which filled the space was still in the cavity formed, and came away with it when it was extracted, giving me the opportunity for a close inspection. This, however, shows no differences from the absorptions in general. In another lower molar the larger part of the crown was destroyed, and the posterior root separated from it by granulations that seemed to have grown in from the gum at the posterior border. Cavities formed in this way differ from those formed by caries, in that there is very little softened tissue; and this does not present the phenomena of caries, but those of absorptions of the roots of the permanent teeth.

Clinically, it is almost impracticable to divide these effects when slight from those supposed to be produced by acid mucus. There is a similar irritation of the gum, and the general appearances are very closely allied as to the effects upon the tooth-structure. They occur at very nearly the same points on the surfaces of the teeth, so that after the occurrence of caries the one cannot with certainty be told from the other. The results of acid mucus, however, are always distinctly below (toward the crown) the margin of the gum, while cervical absorption is always at a point in contact with the gum and covered by it.

Diseases of various sorts have been regarded as predisposing to caries of the teeth, and many observations tend to confirm this supposition. In some of the continued fevers there is an acid condition of the scanty saliva continuing for days and weeks together; and it is not uncommon to find a number of carious cavities making their appearance a short time after convalescence, as has already been explained. The distribution of the acid saliva is general, and its effects should be seen, if at all, on the teeth generally, not localized. A more probable explanation of these phenomena is to be found in the fact that through neglect for so long a period to remove lodgments fermentation in the interstices about the teeth has been allowed to go on unobstructed. This applies

[1] *Transactions of the Illinois State Dental Society*, 1884.

to all forms of disease that interfere with the usual motions of the mouth or with the usual care of the teeth. There is no sufficient evidence that diseased conditions give rise to changes in the teeth themselves that render them more susceptible to caries.

There is, however, sufficient proof that a predisposition to caries is often acquired in cases where it did not exist in early life or is not transmitted as a hereditary predisposition. As explained in connection with the subject of heredity, the supposition that some change in the constitution of the saliva renders it a more favorable soil for the propagation of fermentation is the only hypothesis which, with our present knowledge, seems tenable. This explanation applies to variations in the constitution of the fluids brought about by temporary deviations from health, as well as more lasting changes.

Clinical History of Caries.

Under this caption it is intended to study caries of the teeth as it appears clinically, laying aside the consideration of its etiology and microscopic features except as incidental references.

Caries has pretty definitely fixed habits as to its points of beginning, and one of its most notable characteristics is that it never attacks a tooth on a surface that is smooth and is constantly kept worn and clean by the attrition of mastication or the friction of the tongue, lips, or cheeks. All such points are absolutely exempt from attack.

The points on the surface of the teeth at which caries has its beginnings may conveniently be divided into four classes, according to the character of the surface:

Class 1st. Pits and grooves in the enamel;

Class 2d. Proximal surfaces;

Class 3d. Smooth surfaces which from any cause are habitually unclean;

Class 4th. Necks of the teeth, at or near the junction of the cementum and enamel.

These classes of caries have different characters peculiar to these positions, and which are of considerable importance in a clinical sense.

The first class is, in a large majority of patients presenting themselves for dental operations, the earliest to make its appearance. It occurs in the pits and grooves in the enamel wherever found—in the molars, in the corrugations of the grinding surface, and in the groove or pit which is often present in the buccal surface; in the bicuspids, in the groove in the grinding surface or pits that often occur at either end of this groove; in the upper incisors, in a pit or groove often present in the lingual surface; in any pits, grooves, or imperfections resulting from faulty formations or arrest of development in any position in the surface of any of the teeth.

The occurrence of this class of decays is dependent principally on the opportunity given for fermentation at these points by the *depth* of the pits and grooves in the several teeth. This is modified by the individual predisposition to caries. In the child this latter may be inferred after having learned the condition of the teeth of the parents. If caries

begins early in these positions, it may or may not be marked by a dark color of the pit or groove. If, however, a beginning is delayed for from five to ten years after the eruption of the tooth, a dark color is usually present. The enamel in this position is very thick and heavy, and the pit or groove often penetrates it more or less completely; so that caries apparently does not begin on the outside, but in the depths, of the pit, from which it spreads under the strong enamel to a considerable extent, and often penetrates the dentine deeply before giving any sign, especially in children where the dark color is not present as a warning. This is often shown by an ashy-gray color seen through the enamel. In older patients this color is more generally dark.

This type of caries often appears very soon after the eruption of the tooth; the first to appear in the permanent teeth are usually in the first molars. These cavities occur in about 25 per cent. of first molars, or an average of one to every patient who applies for dental operations.

(My charts, which are presented on pp. 782–785, are constructed from my records of fillings, and teeth extracted are not taken into account. This in some degree vitiates the result. First molars are extracted in larger proportions than other teeth; therefore the numbers given in the text are probably too low.)

In the main, there is a considerable degree of correspondence as to time in the beginnings of caries in the pits of the several teeth, provided these pits are about equal in depth and form; so that in the retention of foreign matter they will be about equal. For instance, if decay occurs in the first molar at eight years, or two years after its eruption, decay may be expected in the pits of the second molar about fourteen, the corresponding period in the age of the tooth or time after its eruption. It will be seen that if the conditions are the same the same time will be required to produce a cavity, and observation shows that in the majority of cases this is true clinically. The second molars, however, show only about 15 per cent. of decays in the pits, or only a little more than half as many as the first molars. This is probably due to the fact that the pits are generally not so deep. This is also true of the bicuspids and incisors; and in these teeth (the pits are very often absent) the decays are much fewer in number. The time of their occurrence may generally be reckoned by the rule given above; but it will be noted that in those teeth in which decay is more rare the age at which it occurs is somewhat greater. This, however, is probably not true of the pits of the incisors. These occur only in a small proportion of cases; but if very pronounced, they decay at about the same time as, or a little later than, those in the first molars. The wisdom teeth often decay much sooner after their eruption than the other teeth. This is explained by the fact that there is often a long period of irritation of the tissues by which they are surrounded during their eruption, and that they are injured by absorptive processes or by acid mucus. If they escape this—that is, if they come through the gum readily—they decay relatively later than any other teeth. The reasons for this will appear subsequently.

The second class, or proximal decays, in cases in which the predisposition is marked, are as a general rule a year or two later in their appear-

ance than the first class, and also follow pretty closely the order of the eruption of the teeth. But if in the individual case the predisposition to caries is but slight, they will usually be several years later in their appearance. In this class there is often an exception in the mesial surfaces of the first molars, which frequently very soon after their eruption are infected from a close contact with a carious surface on the second milk molar. The importance of this class of carious cavities is evident from the fact that they outnumber all others combined in the ratio of about 3.38 to 1. (This is the result given in Charts Nos. 1 and 2. In these it is probable that the number of cavities indicated in the proximal surfaces of the bicuspids is too large, on account of the number of adults who require *refilling* of these cavities. Refillings in cavities previously filled by myself have been carefully eliminated, but cavities previously filled by others have not been designated in my records.)

Occurring on smooth surfaces of the teeth, where the enamel is generally fairly good and free from pits, they are somewhat slower in their beginnings than those of the first class, probably because the penetration of this enamel is more difficult. But the position offers the best advantages for lodgments and fermentation, and the conditions for this are more constantly present than in any of the other positions in which caries has its beginnings. In some examinations of the skulls of the older Indian races made a few years ago I found that they presented a very much larger proportion, comparatively, of this class of caries than our own people. Where the predisposition to caries is less, this class will be found in greater relative proportion, and the cavities will appear later in life. The ratio in which they occur on the individual surfaces of the several teeth is displayed in the charts.

The beginnings of this class of cavities are very much hidden. The special point at which a great majority of them occur is just above (toward the root of the tooth) the point of contact of the teeth, where the cavity cannot be seen. If observed closely at the right time, a very minute opening, or it may be several openings not far apart, will be found, the enamel about these being softened through the greater part of its thickness, and generally injured for a space on either side. Therefore, in preparing small proximal cavities for filling, very wide cutting is required to remove all of this injured enamel. Very often—generally, I may say, unless revealed by a delicate exploring instrument—the first discoverable trace of these cavities is a discoloration which shows through the enamel of the crown. In young persons this has usually an ashy opacity, but in older persons it is likely to be dark. When this appears, caries has made considerable progress in the dentine. It is not very unusual for the pulp to become exposed before the patient is aware of the existence of a cavity, the evidence of which, in molars and bicuspids, is often first made known to the patient by the sudden breaking down of the undermined enamel of the crown, toothache frequently following, from compression of the exposed pulp. Of the four classes of caries this is by far the most destructive.

The third class comprises but comparatively few cases. These are, for the most part, seen on the labial surface of the incisors and buccal surfaces of the bicuspids and molars. (This and the fourth class are

FIG. 403.

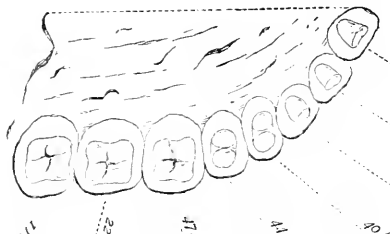

CHART No. I.
UPPER JAW.

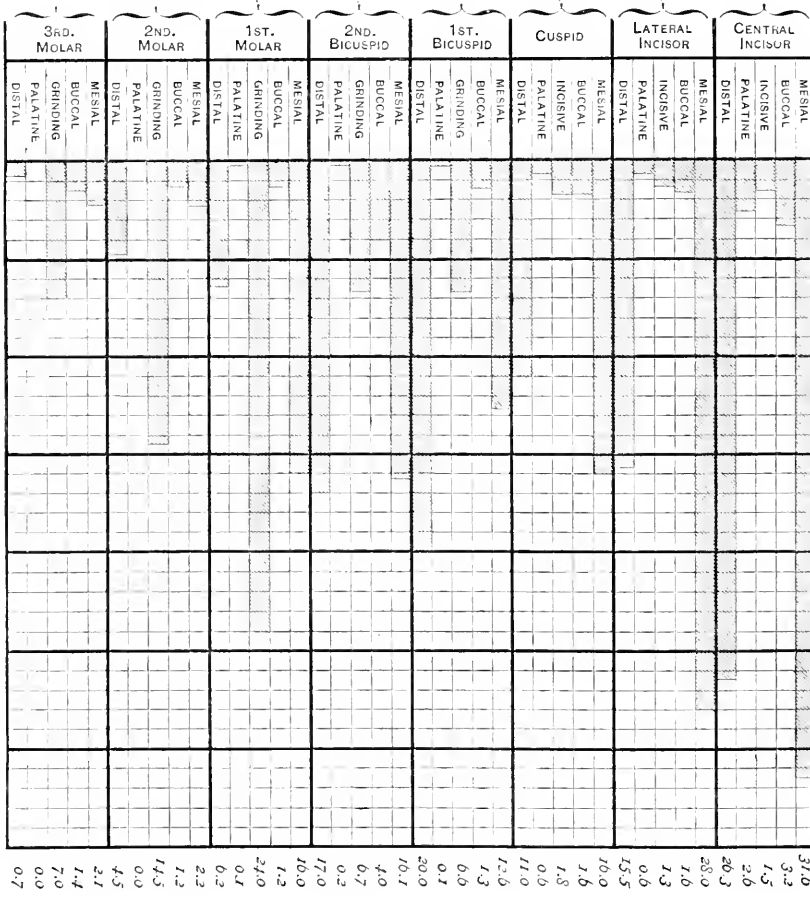

DESCRIPTION OF CHARTS.

These charts represent the number of carious cavities observed in *one hundred persons*, and the position of these cavities on the individual surfaces of the teeth. There are five columns of squares devoted to each tooth of one side of the mouth, representing the five surfaces as shown on the left hand. The number of cavities in the surface represented is shown by the number of squares darkened, so that the effect of the diagram as a whole gives a striking picture of the frequency of decay in the individual surfaces of the several teeth. On the right the percentage or the number per hundred persons, is given in figures calculated to the first decimal point. On the left the percentage of cavities in the individual teeth for all surfaces is given in the same way. The cavities occurring on

FIG. 404.

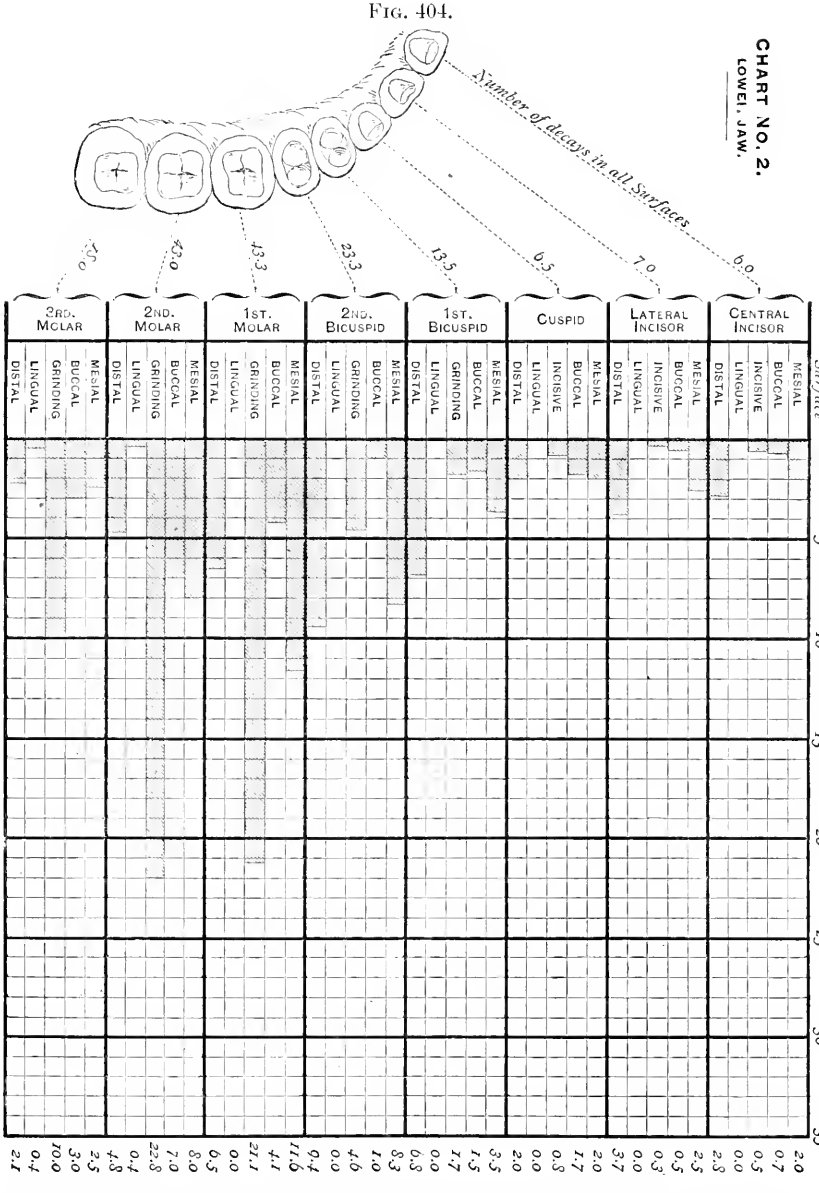

one side of the mouth only are represented. And only one decay in an individual surface is counted; that is, if two or more pits are found decayed in the grinding surface of a molar, but one is counted; and the same rule is followed with all of the other surfaces.

Charts No. 1 and 2 (upper and lower jaw) are made up from my records of fillings for 628 persons of all ages, and therefore represent what is seen in practice rather than the actual number that may occur.

Charts No. 3 and 4 (upper and lower jaw) are made from 100 of my own patients between the ages of ten and twenty-five years, for whom I have filled all cavities and know the condition at present. They represent the actual number of cases in which the individual surfaces have decayed in these 100 persons.

FIG. 405.

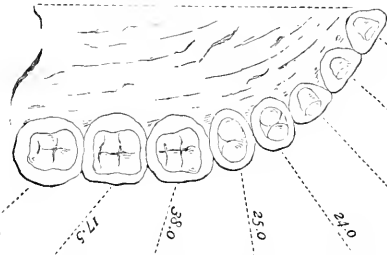

CHART NO. 3.
UPPER JAW.

Surface	Central Incisor	Lateral Incisor	Cuspid	1st Bicuspid	2nd. Bicuspid	1st. Molar	2nd. Molar	3rd. Molar
Mesial	33.0	7.5	.0	14.0	8.5	24.5	10.5	4.5
Buccal	3.5	.0	6.5	.0	.5	.0	.5	.0
Incisive	.5	.0	.0	.0	.0	.0	.0	.0
Grinding					7.0			
Palatine	5.0	3.0	3.5	3.5	.5	1.5	1.5	.0
Distal	17.5	9.0	.0	.0	9.0	6.0	1.5	1.5
Mesial	38.5	7.5	.0	8.5	9.0	6.0	5.0	.0
Buccal	2.5	.0	3.5	.0	.5	.0	.5	.0
Incisive	.5	.0	.0	.0	.0	.0	.0	.0
Grinding					7.0			
Palatine	3.0	3.0	3.5	3.5	.5	1.5	1.5	.0
Distal	9.0	9.0	.0	.0	9.0	6.0	1.5	1.5
Mesial								
Buccal								
Grinding								
Palatine								
Distal								

FIG. 406.

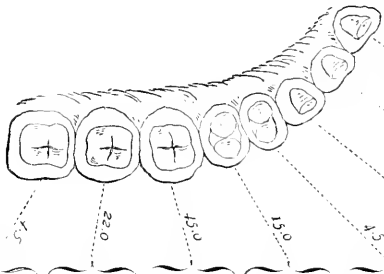

CHART NO. 4.
LOWER JAW.

Surface	Central Incisor				Lateral Incisor				Cuspid				1st. Bicuspid				2nd. Bicuspid				1st. Molar				2nd. Molar				3rd. Molar			
	Mesial	Buccal	Incisive	Lingual	Distal	Mesial	Buccal	Incisive	Lingual	Distal	Mesial	Buccal	Incisive	Lingual	Distal	Mesial	Buccal	Grinding	Lingual	Distal	Mesial	Buccal	Grinding	Lingual	Distal	Mesial	Buccal	Grinding	Lingual	Distal	Mesial	Buccal	Grinding	Lingual	Distal
5																																		
10																																		
15																																		
20																																		
25																																		
30																																		
35																																		
	3.0	.0	.0	.0	1.0	1.5	.0	.0	.0	3.5	.5	2.0	.0	.0	.5	1.5	1.0	1.0	.0	1.0	4.0	.5	5.0	.0	5.5	8.0	6.0	27.5	.0	3.5	2.5	2.0	15.0	.0	2.5	.5	1.0	3.0	.0	.0

not distinguished on the charts, being mixed with others that appear on the same surfaces.) In the incisors their beginning is usually marked by the dark color of the enamel near the gum. This face of the tooth is habitually gummed over with half-dried mucus and débris, thus giving *opportunity* for fermentation and caries. Inquiry will generally disclose the fact that the person habitually sleeps with the mouth open, this often being traceable to some obstruction in the nasal passages. These cavities occur chiefly in persons under eighteen years of age, and not unfrequently before the twelfth year. In the bicuspids and molars this form of decay also occurs, and apparently from habitual uncleanliness, which, however, does not seem to be traceable to the same causes.

The fourth class is always accompanied by a diseased condition of the gums. They have their beginnings very close to the margin of the gum, or even beneath it, just at the junction of the enamel and cement. The gum, however, is usually everted or shrunken from the neck of the tooth before caries proper is demonstrable. The manner of the beginning of these cavities has been described in the consideration of acid mucus and absorptions in their relations to caries. They do not often occur in children, but are generally seen in middle life or old age. Indeed, this form of caries may almost be said to be the only type that attacks elderly persons. Occasionally it wrecks a denture after danger from the other classes of caries has long since passed.

The characteristics presented by caries of the teeth in individual cases are of great importance in the clinical sense. The rule is that if, after beginning in a tooth, the caries advances rapidly, it will do so in all other cases occurring in that individual. If it is seen to proceed slowly in the teeth first attacked, its progress will be slow in those that are attacked later. This may be denominated a characteristic observed in individual cases. It must be noted, however, that the number of beginnings of caries hold but little correspondence to the progress after a beginning has been made. In some cases decay commences early in a few teeth only, and they are very quickly destroyed; in other cases the individual teeth are attacked at intervals of considerable duration, and in each case are quickly destroyed. It is not uncommon in the examination of cases in which there have been no dental operations to find that several teeth have been destroyed by caries, while all the others have entirely escaped, or that in a very few others decay has begun and is running the same rapid course. In another series of individuals an opposite condition will be found. Several carious cavities may have formed, while very few of them have progressed so far as to do serious injury, continued observation showing that they are still making comparatively slow progress. In other cases very few cavities will be found, these few remaining almost stationary.

Thus it will be seen that caries in individual cases presents special characteristics in reference to the liability to the beginning of decay, and also as to the progress of that decay after the beginning has been made. As these characteristics are combined in each individual case, they may be formulated as follows:

First Characteristic: Many decays start and progress rapidly.

Second Characteristic: A few decays start and progress rapidly.
Third Characteristic: Many decays start and progress slowly.
Fourth Characteristic: A few decays start and progress slowly.

These characteristics seem to be dependent on two conditions and their opposites—namely, the activity of the cause of caries in the individual case, and the opportunity presented for attack by the condition of the surfaces of the individual teeth. If the cause of caries be active, if the condition of the fluids of the mouth be such as to favor it, caries that has gained a start will progress rapidly to the destruction of the tooth. After the causative agent is once implanted in the dentine, the circumstances giving or withholding *opportunity* no longer affect its progress. This progress may be modified by one of two influences or by both—namely, by the condition of the fluids penetrating the cavity, and by the condition of the tissue being destroyed. The latter modifying influence occurs only in individual cases in which the dentine is of faulty formation, which abnormality has been sufficiently described in connection with the phenomena of caries. The principal condition modifying the general rate of progress of caries is the state of the fluids entering the cavity. It will be seen, from the studies contained in the preceding pages, that the food-material upon which the fungus must depend for its acid-producing power, and without which caries cannot progress, is not found within the dentine, but must be absorbed from without. This circumstance is of much importance in this connection—not from the probability that this food-material is likely to be scarce in the buccal fluids, but as showing the dependence of the active agents in the production of caries upon the fluids external to the cavity.

The beginnings of caries are dependent largely on those predisposing causes that *give opportunity.* Without the presence and activity of the cause there can be no caries; and the degree of that activity will tend to modify the number of cavities, because a certain degree of action will be sufficient to make a breach under conditions in which a less degree of activity would fail. This is not the principal circumstance modifying the beginnings of caries; for if it were, we would not see those cases in which one or two teeth have been quickly destroyed, while the others have escaped altogether. The principal circumstances giving opportunity for the beginnings of caries are unfavorable forms of the teeth and habits of uncleanliness. This is illustrated by the tendency of carious cavities to occur in pairs on certain surfaces of similar teeth on opposite sides of the mouth, where the form is presumably the same. The predisposing conditions due to faults of form giving opportunity for the beginnings of caries have, however, been sufficiently discussed on a previous page, to which the reader is referred.

These characteristics are seen in every possible degree of intermixture and affect all classes of caries. I have seen some cases in which the teeth seemed to have been attacked in every possible position, and rapidly destroyed, very soon after emerging from the gum. In these cases the condition of the fluids of the mouth is certainly such as to favor that process of fermentation which is the basis of caries, and the forms of the teeth are of a kind to favor the beginnings at numerous points. It

is doubtful, however, if any formation or structure of the teeth, be they ever so perfect, could withstand the conditions present in such cases. The activity of the processes calculated to decompose them is so energetic that the strongest teeth would be destroyed in a short time. The worst cases I have seen were those of two Swedish girls, twin-sisters, eighteen years old, who came to me for advice a few years ago. In these most of the teeth, including the lower incisors, which are so generally exempt from caries, were already decayed to the gums, and those that still retained a portion of the crown were attacked at from one to four points. Fortunately, such cases are rare. With this as the worst representative of the beginnings and the destructiveness of caries, we might give cases illustrating all forms of gradation, down to a case in which an individual tooth shows a dark spot indicating that at some time in the past the products of fermentation had injured the enamel.[1]

Caries of the teeth is essentially a disease of youth (compare charts). This is especially the case with the first and second classes of caries, which comprise the great mass of cases. It is a notable fact that the predisposition to caries diminishes as age advances. It is usually strongest in childhood or youth, and the greater number of cavities have begun at the age of eighteen. Very nearly all of the first and second classes have begun before the age of twenty-five. Perhaps there is more than one reason for this. If we suppose that the disposition to caries remains the same, it is presumable that at the age of twenty-five years all points favorable to the beginnings of decay have been attacked. All except the wisdom teeth have for a dozen years or more been exposed to the agents productive of caries; and if beginnings have not been made within this time, it is presumable that they will not be made unless there is some change in the conditions. This is probably the principal condition of the cessation of the beginning of new

[1] Some years ago I proposed the terms *vis inita* (beginning power), from *vis*, power, force, and *ineo*, to begin; and *vis deleta* (destroying power), from *deleo*, to blot out, to destroy, to represent these characteristics. These terms may readily be used for the purpose of expressing the conditions in any given case, and for this purpose I associate with them numbers to show the *degree* of the special characteristic. The following gives the extremes of the possible combinations:

Vis inita 1, combined with vis deleta 1 to 100.

Vis deleta 1, combined with vis inita 1 to 100.

These may be used in the description of cases for the purpose of the more ready and accurate representation of the facts that may exist or of the conditions observed, without reference to the causes which may be supposed to underlie these effects. For instance, in describing the conditions found in case of the two Swedish girls spoken of in the text, I should say there was present vis inita 100 and vis deleta 100. This expresses my conception of caries of the worst characteristics or the most violent form in which it is manifested. In a case in which a medium number of decays made their appearance, and each of these was running a very rapid course to the destruction of the teeth attacked, I would represent it as vis inita 50, vis deleta 100. In another case, in which a medium number of beginnings of decay was apparent, and these presented rather a dark color and showed other characteristics indicating that the progress was rather slow and yet decided, I would state it as vis inita 50, vis deleta 25. In this way all gradations of the characteristics of caries as manifested in the individual case may be readily presented without unnecessary circumlocution. The use of this plan is also of great advantage in teaching.

In this use the term *vis inita* represents the actual exercise of the opportunities presented for the beginnings of caries in the individual case, and *vis deleta* the activity of the progress after the beginnings are made. The terms themselves are purely arbitrary.

cavities. There is much reason, however, to believe that the environment of the causative agent becomes with advancing age less favorable to progress. The first of the permanent teeth to take their places in the arch are those most frequently affected by caries (see charts). Caries already begun advances less rapidly in older persons, and in some cases cavities cease to progress. The cases of general spontaneous cessation of progress in carious cavities are few, no matter what the age, yet a number of such cases have occurred under my observation. The disposition to caries is not steady, however, but presents fluctuations more or less marked. These are sometimes seen following an illness. In women it is often noted in pregnancy, especially in first and second pregnancies. Other conditions have from time to time been noted which seemed temporarily to dispose the individual to an exacerbation of the tendency to caries. Yet in the great majority of cases this disposition is gradually diminished with increasing age to such an extent that if the cavities are well treated but few decays will begin after the patient is thirty or thirty-five years old, and the beginning of these will generally be found to depend upon some change in the conditions giving opportunity.

This leads to the consideration of the infectious nature of caries, which is best shown by the results of treatment in cases which manifest a strong predisposition to the disease. Many times I have undertaken cases in which there seemed to be but little hope of success; yet I have found that if caries could be eradicated from the mouth, and its exclusion maintained for a time, the tendency to the disease rapidly diminished, and to such an extent as to make its control a matter of but little difficulty. Infection is always a strong element in the beginning of caries. I have had, in numbers of cases, opportunity to study this feature in the children of the same family, where some would be careless and others fairly careful in attendance for operations. Those who were careless, and in this way allowed the continuance of the conditions favoring infection—namely, a number of cavities continuing in progress and adding to the amount of the fungus growing in the mouth—have almost uniformly had much the larger number of cavities at the age of twenty or twenty-five. It is doubtful if this fungus grows well in the mouth where it is fully exposed to the saliva. Partial seclusion seems more favorable to it. Certainly it does not produce results unless it is fairly well secluded and sheltered from the fluids of the mouth. Possibly, as already explained, this may be due to the washing away of its products.

In a considerable number of cases there is a spontaneous cessation of caries in cavities that have made considerable progress. This is, in most instances, connected with some change in the form of the cavity, usually the breakage of one or more of its walls in such a manner as to give to all of its parts free access of the fluids of the mouth. This, if the individual is approaching middle life and the predisposition to caries has not been very considerable, will be sufficient to stop the progress of the decay. In case the predisposition to caries is strong, it is necessary that the whole surface decayed be exposed to the friction of mastication to bring about a cessation of the decay. In this case the

whole of the injured tissue will become intensely black. In a number of instances I have seen the spontaneous cessation of a considerable number of decays under conditions that showed plainly that the cause had ceased to act. The fungus was dead.

The fourth class of caries is occasionally seen to become very troublesome after the other classes have ceased altogether. It is the class of decay that is most likely to give trouble in old age. Its beginnings are determined almost entirely by irritations of the gingivæ, giving rise to absorptions about the necks of the teeth, which, becoming exposed through the recession of the gums, become the seat of caries. They are usually broad cavities that are shielded partially from the free entrance of the fluids of the mouth, either by débris or by adjoining teeth or by an overhanging gum. The teeth are attacked one or two at a time, probably at considerable intervals or very irregularly as to time. Occasionally the teeth in a certain part of the mouth may be attacked together. Caries of this character is sometimes very destructive—more for the reason that the position is such that the pulp of the tooth is exposed with but little destruction of tissue than on account of the decay. The beginnings are usually in the cementum near its junction with the enamel, and in the molars, especially, the pulp-canals are often in close proximity. Decays very much resembling these are often seen in younger persons who wear partial plates abutting against the remaining teeth.

APPENDIX.

FERMENTATION IN THE HUMAN MOUTH:

ITS RELATION TO CARIES OF THE TEETH.

THE INFLUENCE OF ANTISEPTICS, FILLING MATERIALS, ETC., UPON THE FUNGI OF DENTAL CARIES.

THE FUNGI OF DENTAL CARIES; THEIR PURE CULTIVATION AND EFFECT UPON LOWER ANIMALS.

BIOLOGICAL STUDIES ON THE FUNGI OF THE HUMAN MOUTH.

By Dr. W. D. MILLER, Berlin, Germany.[1]

During the last two years I have stated at different times and places, as the result of many experiments, that "the first stage of dental caries consists in a decalcification of the tissue of the teeth by acids which are for the greater part generated in the mouth by fermentation." The object of the investigations described in this and the following papers is to determine this ferment and the conditions essential to its action. I shall seek in what follows to present no views which are not the legitimate and necessary results of rigid and exact experiment, and I shall give in detail a description of each series of experiments, in order that every one may have an opportunity to judge of the accuracy of the work and the justice of the conclusions drawn from it.

It is, nevertheless, with some hesitancy that I venture to present before the dental profession the results of my last six months' labor, having learned by experience the almost endless number of agents which combine to vitiate such a series of experiments as that which I am about to offer, and the exceeding great care which is necessary in excluding or eliminating all irrelevant factors. If, therefore, I have been guilty of any oversight or failed to take all possible precautions to guard against error, I hope that some one will kindly show me where I have gone astray and put me in the right course again.

The larger apparatus necessary for these experiments are:

[1] Reprinted from the *Independent Practitioner*, February, March, and May, 1884, and May and June, 1885.

1. A large double-walled incubator, with gas-regulator for maintaining any desired constant temperature.

Fig. 407.

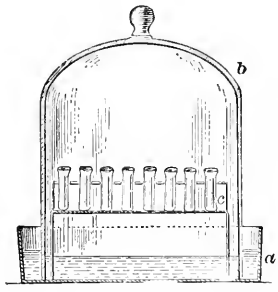

Damp Chamber: *a*, shallow glass vessel partially filled with water; *b*, glass globe lined with wet bibulous paper; *c*, metallic stand for culture-tubes.

2. A Koch sterilizer.

3. A damp chamber. (See Fig. 407.)

4. A drying-oven for sterilizing instruments, glass vessels, etc., at a temperature of 150° C.

5. A good microscope with either water or oil immersion.

It is not necessary to mention the smaller instruments, glass vessels, etc., etc., nor the apparatus necessary for making a chemical analysis of the products of the fermentation; these are sufficiently familiar to every one.

To avoid repetition, I will say here that *all* vessels and instruments used in the culture experiments were purified in the flame of a Bunsen burner when practicable, otherwise by exposing for fifteen minutes in the drying-oven to a temperature of 150° to 160° C. (302° to 320° F.), and that all substances used as culture substrata were sterilized four times by exposure, at intervals of twelve hours, for half an hour, to steam at 100° C., in a Koch sterilizer. Furthermore, all infections from carious dentine were made as follows: The cavity of a freshly-extracted carious tooth is cleared of food and carefully brushed over with a pledget of cotton dipped in carbolic acid (90 per cent.). The acid is then thoroughly absorbed by means of bibulous paper, and layer after layer of the soft dentine removed with a repeatedly purified instrument until the deeper parts are reached; then a portion of the clean soft dentine scarcely as large as a pin-head is removed and quickly brought into or upon the culture medium.

Infections from the mouth were made by scratching upon the surface of the mucous membrane of the cheek or the margin of the gum with the end of a clean platinum wire, and then dipping it into the culture medium. The materials used for culture were:

No. 1.	Sterilized saliva	50.0
	Sugar	1.0
	Starch	0.5
No. 2.	Sterilized milk.	
No. 3.	Decoction of malt	50.0
	Sugar	1.0

The malt decoction is made by boiling, with slight evaporation, 20.0 dry malt with 120.0 water for ten minutes, and filtering.

No. 4.	Sterilized saliva	50.0
	Water	50.0
	Starch	20.0
	Sugar	2.0

The starch is added to the cold solution of water and saliva and stirred until it becomes evenly divided throughout the solution; it is then poured into shallow glass vessels with glass covers and put into the sterilizer for complete sterilization; it there congeals and forms a solid mass, upon the surface of which the infections may be made. It possesses all the advantages of gelatin, with one great additional one, in that it does not liquify at blood-temperature.

No. 5.	Decoction of malt	100.0
	Sugar	2.0
	Starch	20.0

Prepared in the same way as No. 4.

No. 6.	Beef-extract	2.0
	Water	100.0
No. 7.	Water	100.0
	Beef-extract	2.0
	Sugar	2.0

No. 8. Fresh-baked potato cut into slices one-half inch thick with a clean knife.

Other substances were used, but need not be considered here. Additional sugar is not absolutely necessary where malt is used, though I have so far obtained better results by adding a small quantity. The kind of sugar is immaterial, provided it be fermentable; even cane-sugar, though not directly fermentable, is converted into a fermentable variety in the culture. Where small quantities of any culture material were used the cultures were kept in the damp chamber, to prevent their drying up or becoming too concentrated by evaporation. All cultures were made under a temperature of 36° to 38° C.

We will begin with the fundamental experiments.

Exp. 1. Fresh saliva is mixed with sugar or starch, 1–40, and kept at blood-temperature. It invariably becomes acid in four to five hours. But some one, no doubt, will say that this is a result of no consequence, because the experiment was not made within the oral cavity; for his personal benefit we give the following:

Exp. 2. A glass tube 2 cm. long and 3 mm. wide is filled with starch, sterilized, and fastened to a molar tooth in the mouth on going to bed; next morning the contents of the tube will have a strong acid reaction. A cavity in a tooth or a piece of linen which may be saturated with a solution of starch will answer the purpose as well as the glass tube. That the acid is the same in each case will be further established below.

Exp. 3. The mixture of saliva with starch or sugar is kept for a half hour in the sterilizer at 100° C., and then placed in the incubator; it does not become sour in four, nor in twenty-four, hours—in fact, not at all. We conclude that the ferment is rendered inactive by a temperature of 100° C.

Exp. 4. The starch is heated to 150° C. before mixing with the

saliva; the solution still becomes sour. Conclusion: The ferment exists, not in the starch, but in the saliva.

We have now to determine the question, Is it an organized ferment (fungi), or is it an unorganized ferment (ptyalin)?

This question is determined by the following experiments:

Exp. 5. From 6 to 8 grams of saliva are agitated in a test-tube with as much sulphuric ether as it will take up, starch added, and the whole put in the incubator. On examination after a few hours we will find sugar in the solution, but no acid; in other words, the acid-forming ferment has been rendered inactive, but the unorganized sugar-forming ferment not.

Exp. 6. Instead of ether, enough carbolic acid is added to make the solution one-half per cent. strong; the result is the same. These two experiments show that the ptyalin of the saliva (which was not injured by the presence of the ether or the carbolic acid, as proved by the fact that it retained its diastatic action) is not the cause of the acid reaction.

Exp. 7. According to Paschutin, ptyalin is devitalized by exposure twenty minutes to a temperature of 67° C. Organized ferments could not be killed by the same means. We accordingly subject a mixture of saliva and grape-sugar to the given temperature for twenty minutes. We thereby destroy the ptyalin; the mixture, nevertheless, becomes sour if allowed to stand in the incubator for twenty hours. This experiment confirms the result of experiments 5 and 6, and we begin to suspect that we have to deal with an organized ferment. This supposition is confirmed by the following experiment.

Exp. 8. Six to eight drops of a perfectly sterilized solution of sugar in saliva (1–40) in a miniature test-tube with cotton cork are infected from the mouth or with carious dentine, as described above; in twenty-four hours the solution will be acid. With a fraction of a drop of this solution a second tube is infected; it will likewise become acid. From this a third, etc., etc.; each becomes acid in turn, while the control tube (containing the same solution not infected) remains neutral.

The conclusion is plain that we have to do with a ferment which is capable of reproducing itself; in other words, an organized ferment. It therefore becomes evident that not only free in the mouth, but in the deeper parts of carious dentine, we have a fungus which is capable of producing an acid reaction in characteristic substrata.

Exp. 9. Each of thirty small tubes was furnished with eight drops of solution No. 1, and each of thirty other tubes with as many drops of solution No. 3, and all were sterilized. Twenty-four were then infected from the mouth, twenty-four with carious dentine, and twelve were left as controls. In twenty-four hours all forty-eight of the infected solutions were acid, while the twelve controls remained neutral.

Exp. 10. Make a solution of 40.0 of saliva and 1.0 of starch; put equal portions in two flasks, *a* and *b*, and cover the surface of the solution in *a* with a layer of pure oil, to prevent the free access of air; or,

Exp. 11. Place flask *a* in an air-tight bottle containing a fresh alkaline solution of pyrogallic acid (which abstracts the oxygen from the air); or,

Exp. 12. Exhaust flask *a* by means of the air-pump, so as to produce a tolerably complete vacuum. The quantity of acid produced in *a* will be, on an average, the same as that produced in *b*.

We conclude from experiments 8, 9, and 10 that the fungus in question is independent of the free access of air or oxygen for its development and characteristic action—a conclusion which would exclude the fungus of vinegar (*Mycoderma aceti*), and which is of the utmost practical importance, since it signifies that this fungus can develop and perform its work deep in the dentinal tubules or under fillings, provided the necessary materials are furnished it.

Exp. 13. Place a piece of carious dentine upon the surface of the culture material described in number 4, 5, or 6; in twelve hours the dentine will be surrounded by a white ring from 4 to 8 mm. in diameter; the material within this ring will be partially liquefied and have an acid reaction. The same result follows when the infection is made from the mouth.

Exp. 14. Produce 10.0 of saliva by chewing a sterilized quill toothpick, add 0.5 starch or sugar, and place in the incubator. Then give the oral cavity a most thorough cleansing with pure water, using toothpick, brush, and floss, the object being to free the mouth from microorganisms as completely as possible. Then produce again 10.0 saliva, add 0.5 starch or sugar, and put in the incubator; the amount of acid produced in a given time will in the latter case be often as low as one-fourth of that in the former. Conclusion: By thoroughly cleansing the mouth we no doubt remove the greater portion of the fungi; hence the small amount of acid produced. By using strong antiseptics or by repeatedly filtering the saliva we may reduce the amount of acid produced in twenty-four hours almost to 0. An experiment yet to be made is to take the saliva direct from the gland before it becomes infected with the organisms of the mouth; it should not then become sour when mixed with starch and allowed to stand at blood-temperature. In every case a careful microscopic examination of the cultures was made, revealing the constant presence of a fungus, chiefly in the form of diplococci, either single or in chains, less often in the form of bacteria, bacilli, or even threads. (See Fig. 408.) Sometimes all these forms are found on a single thread, thus proving what I have already demonstrated for *Leptothrix buccalis* and *Leptothrix gigantea* (Miller), the genetic connection of these different forms. The particular form in which the fungus occurs depends somewhat upon the culture medium, as well as upon the age of the culture. By using a glass tube as culture vessel we may demonstrate that, whether the culture is made in the mouth or out of it, under similar conditions the fungus is the same. The fungus

FIG. 408.

Some of the forms in which the fungus treated of in this article occurs.

is not capable of producing an acid reaction of all substances in which it may vegetate. A luxuriant growth may be obtained in beef-extract, but no acid is produced unless sugar is present. It is only from carbohydrates (especially sugar) that it appears to be able to produce acid in any considerable quantity or at all. This question, however, as well as the morphology, physiology, development, and life-conditions of the fungus, will receive subsequent consideration.

We have, then, a micro-organism which agrees morphologically with the *Bacterium acidi lactici*, and which, without the presence of oxygen, produces acid from sugar; so that we would probably not be far from right if we were to say that the organism in question is simply the fungus of lactic acid. We will, however, reserve our decision for another page, where the analysis of the product of the fermentation will be given, that being the one *sure* method for determining the species of any ferment bacterium.

In all cultures it is, of course, essential that the culture substratum be neutral when the inoculation is made; should it be acid, it must be neutralized. This is best accomplished by very carefully adding the carbonate of sodium. Without this precaution it would be somewhat difficult to determine whether acid had been produced by the action of the fungus or not.

In the light of these experiments, the thorough decalcification of the tooth-substance in caries is easily accounted for. The saliva is, no doubt, always, particularly in mouths of uncleanly persons, impregnated with sugar, either taken directly into the mouth or formed there by the action of the ptyalin of the saliva upon starch. The question of the presumable diastatic action, as well as of a presumable inverting power on the part of the organisms themselves, will be considered in the section on Physiology.

Wherever this stagnates between the teeth in fissures, etc., etc., especially during sleep, it *must* become acid. When a portion of the dentine has become decalcified, it, as is well known, takes up the liquids of the mouth, and the fungi with them, like a sponge, and the fungi, being independent of the free access of air, go on producing acid within the dentinal tubules. As each layer of dentine becomes softened in turn the micro-organisms *follow after*, continually producing new acid. Hereby the zone of softened, non-infected dentine is readily understood. The production of acid is entirely independent of the reaction of the saliva as it enters the mouth; hence the uselessness of "testing the saliva" for acid. That the liquid squeezed out of the tubules of *decaying* dentine has an acid reaction every dentist in America who has a piece of blue litmus-paper and is not color-blind can easily prove for himself.

The result of experiment 6 plainly shows one cause of the good effects which the profession has seen from the use of carbolic acid.

The fact that a pure culture was obtained in most cases by the first inoculation seems to indicate that the fungus exists in a state of tolerable purity in the deeper parts of the carious dentine. This question will, however, receive consideration later. The action of the fungus upon

substances which contain no carbohydrates will also be considered under Physiology.

In addition to these experiments, I add the following: A sound bicuspid tooth was sawed into sections, varying from $\frac{1}{3}$ to 1 mm. in thickness, and an equal number of these sections placed in each of two test-tubes. Into one of these test-tubes were then brought 5 c.c. of a perfectly neutralized 2-per-cent. aqueous solution of beef-extract; into the other the same solution, with the addition of 0.2 cane-sugar. Both tubes, with their contents, were then sterilized, and upon cooling infected from a pure culture of the fungus under consideration.

The solution in the second tube became acid in a few hours; not so, however, with that in the first tube, it being non-fermentable. At the end of one week the thinner sections in the second tube were so far softened that one of them, removed for examination, could be easily bent between the fingers. At the end of the second week all but the thicker sections were completely decalcified. One of these sections was now placed upon the freezing microtome and made into cuts, which were stained in fuchsin and mounted in Canada balsam. A microscopic examination showed that the fungi had penetrated many of the tubules to a considerable depth, the invaded tubules being at the same time slightly extended. At the close of the third week the invasion was found to have become much more extensive, the tubules much dilated, and in some places the walls were broken through, leading to the formation of oval spaces or caverns in the dentine. In short, we had a typical case of caries.

It is hardly necessary to state that the thinnest sections in the first tube, where the development of the fungus was not accompanied by an acid fermentation, did not show even the traces of softening, to say nothing of caries.

I had, then, produced caries by inoculating sound dentine from a pure culture of a fungus found in carious dentine in the presence of the same fermentable substances that occur in the mouth. It seems that a clearer solution of the problem can at present scarcely be expected. Of course the thought at once suggests itself to every one that this decay is quite independent of putrefaction; all evidence points to the conclusion that putrefaction at most does nothing more than dispose of the already devitalized and much riddled remains of tissue, and we are in danger of overrating its influence even at this stage.

Pieces of dentine in a solution kept constantly pure and sour by fermentation not only become softened and show the microscopic changes characteristic of carious dentine, but finally, after some months, disappear altogether, as has repeatedly been the case in my cultures. From this we must infer that the process commonly known as putrefaction is absolutely essential at no stage of caries; especially is this the case in caries of enamel.

It has been intimated that the active agent in this process is nearly related to, if not identical with, the fungus of sour milk, *Bacterium acidi lactici*. The analysis of the product of fermentation will show the truth or falsity of this supposition.

The method of carrying out such an analysis will now be given: 200

c.c. fresh saliva are mixed with 2.0 starch and allowed to stand forty-eight hours at blood-temperature; the mixture is then filtered and heated to 100° C., to stop the fermentation. This process is repeated until about a litre of the solution has accumulated. It is then placed in a retort and reduced to a volume of about 75 c.c. It will be very strongly acid. A few drops of this liquid are added to a thin solution of methyl-violet, and leave it unchanged; from this we conclude that we have to deal with an organic acid, as an inorganic acid would turn it first blue, and then green. Since the acid did not distill during the prolonged boiling, we may set it down as non-volatile; hence a non-volatile, organic acid. The distillate was very slightly acid; we will call it distillate No. 1, as we wish to refer to it again.

The solution was further reduced in volume to about 40 c.c. over the water-bath, and then transferred to a large glass vessel, briskly shaken with 1½ to 2 litres of sulphuric ether, and allowed to stand until the ether became perfectly transparent. This was then filtered into a large retort and distilled, proper precautions being observed to prevent accidents. When the volume had been reduced to about 50 c.c., the solution was filtered into a porcelain vessel and still further reduced over the water-bath. A portion of the solution tested in the short tube of a Mitscherlich double-shadow polaristrobometer gave as a mean of nine readings a rotation of the plane of polarization equal to 0.015°, or 0° 0.9′. In other words, the solution was optically inactive, the 0° 0.9′ being far within the range of the error of experiment, especially as the solution was not absolutely transparent.

An excess of freshly-prepared oxide of zinc was then added to the solution and the whole slowly and carefully boiled, water being added as it was found necessary, till the reaction became neutral, or nearly so, filtered into a large glass evaporating dish, and put away at the temperature of the room for the salt to crystallize. A drop of this solution placed upon a glass slide gave upon crystallization the forms seen in Fig. 409, which are at once recognized as crystals of lactate of zinc. In a few days a quantity of a whitish crystalline powder had formed. This was placed upon a filter, the mother-liquid squeezed out, washed in absolute alcohol, dissolved in hot water, recrystallized, and dried over sulphuric acid; it then weighed 0.343. After exposing to a temperature of 100° C., or a little more, till the weight became constant, it weighed 0.2816; it lost, accordingly, 17.9 per cent.[1] of water of crystallization, corresponding to 3 molecules of water. The salt was then dissolved in water, the zinc precipitated as carbonate and burned. The burned mass (zinc oxide) weighed 0.0970. We have, consequently,

FIG. 409.

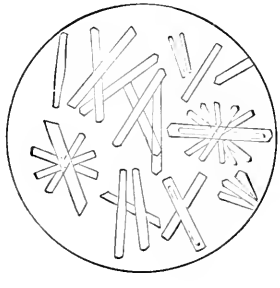

Substance analyzed (a zinc salt) = 0.343
Oxide of zinc = 0.097

[1] Theoretically, 18.2, or 0.3 per cent. more.

The zinc oxide is seen to be equivalent to 28.2 per cent. of the substance analyzed.

The formula for the inactive ethylidene lactate of zinc is

$$\left.\begin{matrix} C_3H_5O_3 \\ C_3H_5O_3 \end{matrix}\right\} Zn + 3H_2O = 243 + 54.$$

Dried at ordinary temperature, it contains 27.3 per cent. zinc oxide. The result obtained from the analysis differs, therefore, from that deduced from the formula by less than 1 per cent., and settles beyond doubt the fact that the substance analyzed was the lactate of zinc, or that the acid generated by the fermentation is lactic acid—or, more exactly, inactive ethylidene lactic acid, since, as shown above, the acid solution was optically inactive and the zinc salt contained 3 molecules of water of crystallization. The salt was furthermore soluble in 62 parts water at 14° C.

I repeated the analysis with the following solution:

Water, 1000 c.c.
Saliva, 300 c.c.
Bouillon, 200 c.c., made by boiling 125.0 beef ten minutes in 300 c.c. of water.
Sugar, 10.0.

This solution, being slightly acid, was neutralized with the carbonates of lime and sodium, sterilized, and infected from a pure culture of the fungus in question. It was treated throughout exactly in the manner above described, except that the zinc salt was converted into the sulphide instead of the carbonate, and burned with powdered sulphur in a stream of hydrogen. The result was as follows:

Substance analyzed	=	1.0540
Zinc sulphide	=	0.415
Zinc	=	26.38 per cent.

instead of 26.74 per cent., as deduced from the formula—a difference of only $\frac{1}{3}$ of 1 per cent.

In this case the substance was dried at 100° C. before weighing, and the formula becomes

$$\left.\begin{matrix} C_3H_5O_3 \\ C_3H_5O_3 \end{matrix}\right\} Zn = 243.$$

One more analysis was made, using—

Water,	1000 c.c.
Liquid beef extract,	20 c.c.
Sugar,	10.0

The result was the same, and need not be given, the two analyses above described being abundantly sufficient to show that the acid generated by the fungus in question is the common ferment, lactic acid.

Distillate No. 1, referred to above, owed its slight acidity, we now know—in part, at least—to lactic acid, since, when an aqueous solution

of lactic acid is boiled, a small fraction of the acid goes over with the water. To ascertain, however, whether any other acid, especially volatile, was present, the distillate was boiled with carbonate of lime, filtered, evaporated to dryness, a small amount of dilute sulphuric acid added, and heated in a retort over the water-bath. A few drops of an oily acid came over, which when taken upon the fingers smelled like butyric acid; the amount, however, was so small that no attempt could be made to analyze it.

I have been able with some degree of certainty to establish the presence of lactic acid in carious dentine by a method theoretically so simple that it seems strange it has never been made use of before, but which, however, in practice, is carried out only with great difficulty. My first and second attempts were only partially successful; the third succeeded sufficiently well to justify its description here.

In this experiment I made use of fifteen teeth, all containing considerable quantities of carious dentine, and all extracted on the day of use. The remains of food were first removed from the cavities, but none of the softened dentine; then all the softened dentine was taken out and placed in a porcelain vessel, cut or picked into fine pieces, placed in a test-tube with 1 c.c. of water and two drops of a 10-per-cent. solution of hydrochloric acid added. Any free lactic acid in the carious dentine would remain free, and any existing in combination with lime would be set free by the hydrochloric acid. It was then gently shaken with about 25 c.c. sulphuric ether, and the latter, holding the lactic acid in solution, was after some minutes poured off into a second test-tube; here it must be allowed to stand from twenty-four to forty-eight hours, till it becomes perfectly clear. It was then filtered into a porcelain dish, evaporated, a few drops of distilled water and a small quantity of *freshly-prepared* zinc oxide added, gently boiled (water being added as necessary) for ten minutes, the three or four drops of liquid remaining filtered on to a glass slide and allowed to crystallize. I obtained the forms seen in Fig. 410. Their close resemblance to the crystals of the lactate of zinc (Fig. 409) will be seen at once. There can, in fact, scarcely be a doubt that they are lactate-of-zinc crystals. The lactic acid concerned in their formation must, of course, have existed in the carious dentine.

Fig. 410.

I have noticed in the dental journals a tendency on the part of some writers on this subject to derive a large amount of satisfaction from the statement that, after all, what I have done to clear up the subject of dental caries was done and known long ago. One writer even states that he might almost have said two years ago something that I said but a few months since. Let me say, once for all, that I have too little spare time to devote any of it to the discussion of the question who *said* this or that first, or even who *might almost* have *said* something two years ago. There is perhaps no human disease about which more has been *said* than about caries of the teeth; and when the subject shall have received its final settlement, there will be hundreds who may say, "I told you so." Malassez and Vignal very justly say of Baumgarten, who claims

priority over Koch in the discovery of the tubercle bacillus, "*Il ne suffit pas de* trouver, *il faut* prouver;" and I do not hesitate to say, with reference to some of the discussions which for years have been carried on concerning the cause of dental caries, "*Il ne suffit pas de deviner, il faut trouver* et *prouver.*"

It is not enough to guess the cause, or guess at it: we must *find* the cause, and, having found it, *prove* that it is the cause sought for.

If we infect a beef-extract-sugar solution with carious dentine, as already described in this paper, using every possible precaution to obtain perfectly pure material and to prevent the access of germs from without, and keep the solution at 37° C., we may observe the following phenomena: In from eight to ten hours the solution will show a slight cloudiness, which at no time, however, amounts to complete opacity. Tested with sensitive litmus-paper, it will be seen that the acid reaction has already appeared. In fifteen to twenty hours the fermentation will generally have reached the most active state, and soon afterward a colorless, flocky precipitate will begin to form on the bottom of the vessel, accompanied by a corresponding clarifying of the solution and a diminution of the fermentative activity. After the lapse of forty-eight hours the sediment will have completely formed, and the solution will be almost as transparent as when the experiment began. The time required for the completion of this series of phenomena will, however, naturally depend somewhat upon the amount of dentine taken for the infection and the amount of the solution used.

Impurities in the culture manifest themselves in various ways—it may be by an excessive cloudiness of the liquid, or by the formation of a skin upon the surface of the solution, or the failure of the latter to become clear after the regular lapse of time, etc., etc.

Dentine is an excellent medium for separating the different fungi found in the mouth, the most of them not being able to exist in the deeper parts, partly on account of the acidity of the medium, partly on account of the lack of free oxygen. We may, therefore, with the proper amount of care, obtain material of such purity as to produce a pure culture in the first generation.

If we microscopically examine the sediment which has formed on the bottom of the vessel, we shall find it to consist of cocci and diplococci, either single or in chains—in either case, without motion. Under a low power they appear round and regular; with $\frac{1}{18}$ oil immersion they are seen to be round or oval, regular or irregular, involuted, etc., presenting the most various shapes and sizes. I have never been able to detect the existence of spores, and reproduction takes place only after the scheme presented in Fig. 411, Nos. 1, 2, 3, 4, 5, 6, 7. A coccus which may be round in the beginning by extension in one axis becomes oval or elongated; soon after, it shows a contraction in the middle, resulting in the production of a diplococcus or two cocci, each of which may produce two cocci in the same manner.

We find, consequently, in a chain taken from a growing culture, some of the cocci round, others oval; some of the diplococci but slightly contracted, while in others the contraction amounts almost to a complete division. (See Fig. 411, *d*, *e*, *f*.) Frequently the cells acquire a pro-

nounced bacterium form; so that if they did not occur in the same chain with the ordinary forms, one would be in doubt as to whether they belonged to the same species.

The growing cells in a chain sometimes turn upon their shorter axis, and then, growing out in the new direction, produce very peculiar fig-

Fig. 411.

ures (Fig. 411, *f*, *g*). In stagnant cultures the cells under high power are mostly very irregular, having in groups the appearance of the bones of the wrist. (See Fig. 411, *a*, *b*.)

Very characteristic are the involution forms produced both in stagnant cultures and in media which are not well adapted to the needs of the fungus. Here the forms and sizes are so various that it sometimes becomes exceedingly difficult, if not impossible, to tell if certain ones are normal or abnormal. (See Fig. 411, *h*, *i*, *j*, *k*.) In exceptional cases the threads surround themselves with a thick gelatinous sheath. (See Fig. 411, *c*.) The protoplasm of the involuted cells generally presents a granular appearance (Fig. 411, *h*,*k*).

Fig. 412.

If we make a large number of cultures at once, we will in about one case out of five to ten (and if the cultures are made in a decoction of malt much more frequently) meet with a second fungus, essentially different from the one just described. It occurs chiefly in form of bacilli, but also as leptothrix, bacteria, diplococci, and cocci singly, or, as is mostly the case, in long zig-zag threads (Fig. 412).

The discovery of this fungus, with its different forms of development, affords a very ready explanation of the fact that in a single dentinal tubule we sometimes find a transition from leptothrix to bacilli, from bacilli to bacteria, and from bacteria to cocci—an occurrence which I demon-

strated nearly two years ago before the American Dental Society of Europe, before the Gesellschaft fuer Heilkunde in Berlin, and to various private persons, including some of the most celebrated mycologists in Germany. Those who maintain, as was done in the British Dental Association, that such cases may not be found, are responsible for their own mistake.

*Macro*scopically, cultures of this fungus in beef-extract-sugar solution are not easily to be distinguished from cultures of that described above. The fungus collects as a sediment on the bottom of the vessel; it never forms a skin on the surface of the liquid, and produces but a moderate cloudiness of the same. In most decoctions, however, they present some peculiarities. Sometimes the fungus floats about in the solution in semi-transparent balls, or rises up from the bottom of the vessel like a miniature cloud of smoke, or collects in small patches on the sides of the vessel, while the solution itself remains almost perfectly clear. The cells are motionless and do not form spores.

In order to discriminate between these two fungi, I will designate for the present the one first described by the prefix *A* (alpha), and the one under consideration by the prefix *β* (beta). In all probability, the *β*-fungus also produces lactic acid from sugar. I say "in all probability," because, though I have always been able to detect lactic acid in cultures of this fungus, I could not say with absolute certainty that cocci and diplococci of the species *A* were not present.

FIG. 413.

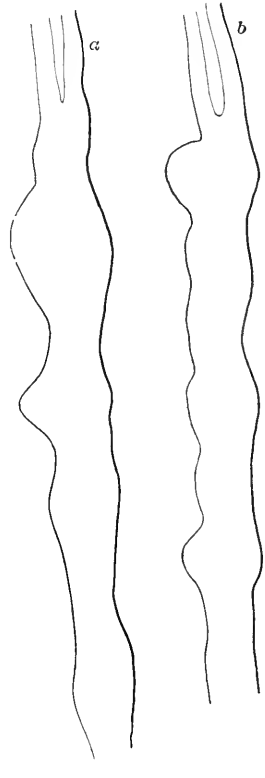

We have, then, in carious dentine two distinct fungi—one always, the other often, present; the former surely, the latter probably, producing lactic acid from sugar. If these fungi are the direct cause of dental caries, we should be able to produce caries by subjecting sound dentine to their action. This I have accomplished, as already described.

In Fig. 413, *a*, are seen in outline two tubules of dentine melted together by natural caries, and in Fig. 413, *b*, two tubules melted together by artificial caries.

In Fig. 414, *a*, are likewise two tubules from natural caries, and in Fig. 414, *b*, two from artificial caries. It is a fact of considerable interest that, though the fungi themselves are perfectly colorless, pieces of dentine subjected to their action become yellowish, light brown, or dark brown, etc., depending upon the medium in which the culture is made, while different pieces of dentine in the same culture do not by any means necessarily acquire the same color.

The carrying out of this experiment is attended with difficulties, and some may try it and fail; I have failed many times. The necessity of

repeatedly changing the solution very much increases the danger from impurities; especially must the saccharomycetes be guarded against. The acidity of the medium caused by the caries fungi renders it very favorable for their development; and when they have once found their way into a culture, it might as well be thrown away at once. Again, notwithstanding the presence of the pieces of dentine, the solution sometimes becomes sufficiently acid to impair, if not to destroy, the vitality of the fungus. In this case the dentine becomes softened, but only a slight invasion of the tubules takes place. Then, of course, in the very last stage of caries, other fungi, especially *Leptothrix buccalis*, are present in the decomposing dentine, and sometimes produce an appearance in its *superficial* layers which I have not attempted to reproduce artificially. It is not difficult by a simple microscopic examination of the fluids of the mouth, as well as of carious dentine, to find forms morphologically identical with those described above.

Fig. 414.



In Fig. 415 is seen in outline a portion of an epithelial scale from the

Fig. 415.

human mouth, highly magnified, with the fungi lying upon the surface. The forms seen in Fig. 416 were obtained from a glass tube filled with starch and kept in the mouth overnight, while Fig. 417 is from carious dentine. The *A* caries fungus agrees morphologically with the fungus of sour milk as delineated by Pasteur. Later experiments, however, render it probable that the souring of milk is produced by an altogether different fungus, a short, thick *bacterium*,

Fig. 416.

Fig. 417.

occurring in twos, seldom fours, which may also be found in the human mouth (though probably not deep in carious dentine), and will be considered at another time.

In the case of both fungi the *fermentation* goes on independently of the presence of free oxygen. I have already shown that where only a trace of oxygen is present in no way comparable with the amount of acid produced, the degree of acidity was as great as where there was free access of air. Whether, however, this *trace* of oxygen is essential to the life of these fungi—*i. e.* whether without it they would perish from asphyxia—is a question which we will not discuss here.

It has been generally supposed that the production of lactic acid by fermentation from sugar is accompanied by the evolution of carbonic acid; in fact, Fluegge says that no fermentation can go on without the production of carbonic acid. This statement will hardly be borne out by a study of the fermentation produced by the fungi of tooth caries.

A glass vessel of 500 c.c. capacity was filled with beef-extract-sugar solution infected with a pure culture of caries fungi and made air-tight with a rubber stopper carrying an efflux-tube for collecting the gas over mercury. After twenty-four hours, during which time 1.75 c.c. acid had been produced, one single gas-bubble was collected, which may have been due to a slight change of temperature, as well as to a veritable gas-evolution. The splitting appears, therefore, to be perfectly smooth, and to take place in accordance with the simple formula,

$$C_6H_{12}O_6 = 2C_3H_6O_3.$$

It presents a marked contrast to the stormy character of the butyric and alcoholic fermentations, in case of which the pressure of the gas evolved is often sufficient to burst the vessels containing the cultures.

There is perhaps at nearly all times a sufficient amount of sugar in the oral cavity to enable the fungi of caries to carry out their characteristic ferment action. It remains, nevertheless, an interesting question whether they have the power to form sugar out of starch—*i. e.* whether they have any diastatic action. About thirty cultures in an aqueous solution of beef-extract and starch and in a solution of starch in sterilized saliva gave, for the most part, negative results; in exceptional cases a slight diastatic action appeared to take place, which I am inclined to regard as the result of some impurity in the culture or an error in the experiment.

On the other hand, the fungi appear without doubt to possess the power to invert or to render non-fermentable sugars fermentable, since cane-sugar, which is not fermentable and does not reduce alkaline solutions of sulphate of copper, acquires both these properties when subjected to their action. That this result is caused by the action of a ferment produced by the organisms, and which may be separated from them, is, I think, demonstrated by the following experiment: By making a number of cultures at one time in vessels of 200 to 500 c.c. capacity and collecting the sediment which was deposited on the bottom of the vessels, I succeeded in bringing together a considerable quantity of the fungi; this was then treated with 90-per-cent. alcohol filtered and dried in a porcelain vessel, thoroughly rubbed with sand, digested with

water at 23° C., and again filtered; the filtrate (which must be clear and should contain the ferment in solution) was added to a solution of cane-sugar, which then showed in the long tube of a Mitscherlich polariscope a rotation equal to 5.19°. The solution was now allowed to stand four hours at a temperature of 38° C., after which time it produced a rotation of only 4.54°, indicating a decrease of about two-thirds of a degree. The solution also produced a slight reduction of an alkaline solution of sulphate of copper—*i. e.* a certain portion of the cane-sugar had been converted into invert sugar.

In the presence of the fungi the non-fermentable sugar, by the action of the invertine produced by the fungi, takes up one molecule of water and is converted into invert sugar, a mixture of levulose and dextrose, both of which are fermentable:

$$\underset{\text{Cane sugar.}}{C_{12}H_{22}O_{11}} + H_2O = \underset{\text{Levulose.}}{C_6H_{12}O_6} + \underset{\text{Dextrose.}}{C_6H_{12}O_6}.$$

We may say, therefore, that the micro-organisms require sugar to produce fermentation, but that it is immaterial which kind of sugar is furnished them. The fermentation is most active between the temperatures 35° and 40° C. Above 50° and below 15° C., little or no production of acid takes place.

In addition to these two species of fungi, others of minor importance are occasionally met with in the mouth, and will receive attention later on.

I would not have any one think that I look upon the above as a thorough consideration of the fungi of tooth caries; to me it appears very imperfect. Nevertheless, I have thought it well to present the matter before the profession in the hope that others might be induced to take it up and help to complete the work thus begun. I will now present the results of experiments relating to the action of various antiseptics, filling materials, etc. upon the fungi under consideration.

The Influence of Antiseptics, Filling Materials, etc. upon the Fungi of Dental Caries.

Having established upon an experimental and scientific basis the fact that caries of the teeth is to a certain extent the direct result of the action of ferment acid or acids[1] upon the tissue of the tooth, followed, particularly in the case of the dentine, by the action of the ferment organisms themselves upon the decalcified tissue, it becomes a matter of the first importance to determine, first, by what means we may counteract the action of the acids or prevent their production; second, by what means we may save the already decalcified dentine from complete destruction.

Evidently, there are three methods by which the desired end may be partially obtained:

1. By repeated, thorough, systematic cleansing of the oral cavity and the teeth we may so far reduce the amount of fermentable substances in the mouth and the number of ferment organisms as to materially dimin-

[1] The chief work in the production of caries is performed by lactic acid; other acids are only auxiliary factors.

ish the production of acid. This is so self-evident that it needs no further comment.

2. By the repeated application of alkaline substances we may to a certain extent neutralize the acids before they have acted upon the teeth to any considerable degree.

3. By a proper and intelligent use of antiseptics we may destroy the organisms themselves, or at least render them inactive. It is this method which is especially applicable in the second stage of dental caries—*i. e.* the stage which follows the decalcification—and to which we will here give exclusive attention. We must, however, constantly bear in mind that, by whatever method we proceed, a previous thorough cleansing of the teeth is absolutely indispensable. There is no known solution, alkaline or antiseptic, applicable in the human mouth which will penetrate between the teeth or to the bottom of fissures and cavities when these are filled with food in sufficient quantity to have any appreciable effect. Therefore before all antiseptics or alkaline washes come the toothbrush, toothpick, and floss silk.

In my experiments for determining the action of various antiseptics upon the fungi of tooth caries it appeared to me that by allowing the antiseptic to act upon the fungi in their natural medium, saliva, I could obtain results of more practical value than by experimenting upon them in artificial solutions and in pure cultures, neither of which ever occurs in the human mouth. Furthermore, since the fungi can attack the teeth only after a partial decalcification, we have, in the first place, to demand of an antiseptic not so much that it destroys the fungi as that it prevents the production of acid by them.[1] Consequently, if an acid reaction failed to appear in a solution of saliva and sugar to which a certain antiseptic had been added as soon as in a like solution to which no antiseptic had been added (control), it was taken as evidence of the activity and value of the antiseptic used. This method could, of course, be used only with substances having a neutral reaction. The solutions were also subjected to a microscopic examination, to render the evidence doubly sure.

In the following table I have indicated the percentage of each antiseptic experimented upon which must be present in a sweetened-saliva solution to prevent the appearance of an acid reaction in twenty-four hours, or, in case of alkaline or acid antiseptics, to prevent the development of the characteristic fungi in the same time.

For example, if to 100,000 parts of sweetened saliva we add one part of bichloride of mercury, the solution will not be found acid after the lapse of twenty-four hours even though the control become sour in four or five hours. If we add only one part to 500,000, the acid reaction will appear somewhat later than in the control.

This table is designed to show the comparative strength of the antiseptics most commonly used. The action of the antiseptics having an acid or alkaline reaction upon the fungi was determined by the use of the microscope alone:

[1] The production of acid may be taken as synonymous with the development of the fungi, though the failure of the acid reaction to appear after a certain length of time does not necessarily indicate that the fungi have been *devitalized.*

	Production of Acid (Development of Fungi). Prevented.	Retarded.
Bichloride of mercury	1–100,000	1–500,000
Nitrate of silver	1–50,000	1–100,000
Iodoform	1–5,000	1–10,000
Naphthaline	1–4,000 (?)	1–9,000
Iodine	1–6,000	1–15,000
Oil of mustard	1–2,000	1–5,000
Permanganate of potas.	1–1,000	1–2,000
Eucalyptus oil	1–600	
Carbolic acid	1–500	1–1,000
Hydrochloric acid	1–500	1–1,000
Phenylic acid	1–200	1–500
Liquid of Agate Cement	1–250	
Liquid of Excelsior Cement	1–225	
Lactic acid	1–125	1–250
Carbonate of sodium	1–100	1–200
Salicylic acid (Conc. alcohol sol.)	1–75	1–125
Alcohol	1–10	1–20

The experiments show that bichloride of mercury is about two hundred times as powerful as carbolic acid, and demonstrate very clearly the mistake of substituting weak solutions of this antiseptic (1–1000, as I have seen recommended) for concentrated carbolic acid. One one-thousandth is only one-fifth as powerful as pure carbolic acid, which in many cases may be used with impunity. It is consequently useless to attempt to introduce the sublimate solution for the purpose of sterilizing root-canals, cavities before filling, etc., unless we may use at least a $\frac{1}{2}$-per-cent., if not a 1-per-cent., solution. I see no reason, however, why this may not be done. In a few cases I have used a 1-per-cent. solution for treating root-canals, and do not hesitate, particularly with the rubber dam adjusted, to wipe out cavities before filling with a 2-per-cent. solution, and see no possible evil which could result from it. A well-known physiologist in Berlin has told me that he uses a 1-per-cent. solution in his own mouth for aphthæ, and with excellent results. We should not, however, overlook the fact that a 1-per-cent. sublimate solution is only one-fifth as powerful as pure iodoform.

As a mouth-wash I have frequently used a $\frac{1}{10}$-per-cent. (1–1000) solution myself, and have seen no bad results from it; I would not, however, recommend it to my patients in this strength. It has, besides, for me, an exceedingly disagreeable and lasting taste which it is difficult to disguise, and produces an immediate increased secretion of saliva and mucus which is very annoying. A $\frac{1}{50}$-per-cent. solution (1–5000) may eventually be brought into use; in this concentration it is four times as powerful as a 1-per-cent. solution of carbolic acid. The very high antiseptic power of nitrate of silver is particularly noteworthy. Why may it not be employed in place of the much more dangerous mercuric chloride?

The action of tobacco upon the fungi is worthy of notice. Five grammes of old Virginia plug were boiled fifteen minutes in 50 c.c. of water, the loss by evaporation being constantly replaced; the decoction was then filtered and a portion added to an equal volume of saliva with sugar. This produced a mixture scarcely stronger than that which many veteran chewers carry around in their mouths all day, and in it

the fungi led only a miserable existence. Much more remarkable, however, was the action of tobacco-smoke upon the fungi, the smoke from the first, third, or last quarter of a Colorado Claro cigar being found amply sufficient to sterilize 10 c.c. of a beef-extract-sugar solution previously richly infected with caries fungi.

The apparatus used for this experiment (see Fig. 418) explains itself. A current of water passing through the part B in the direction indicated by the double-headed arrow produces a current of air through the part A in the direction shown by the single-headed arrow which draws the smoke from a lighted cigar through the solution. The rate at which the cigar smokes may be regulated at will by the cock of the hydrant.

FIG. 418.

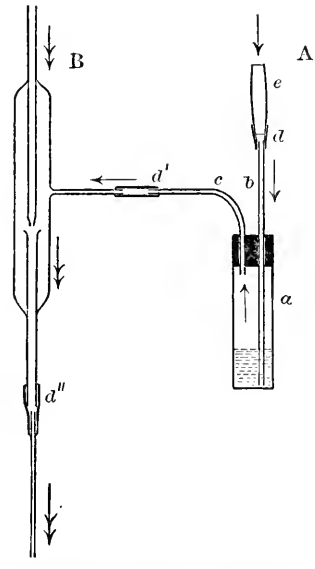

a, glass cylinder with infected solution; *b*, *c*, glass tubes; *d*, *d'*, *d''*, rubber tubing; *e*, cigar (Colorado Claro); B, water air-pump. A current of water passing through B in the direction indicated by the double-headed arrow produces a partial vacuum in the bulb, and consequently a current of air in the direction shown by the single-headed arrow, or through the cigar, which if lighted will smoke at a rate determined by the pressure under which the water is flowing.

In consideration of the strong antiseptic power of tobacco-smoke, we might be inclined to infer that tobacco-smokers should never suffer from caries of the teeth; it is evident, however, that there are very many points in the dental arch to which the smoke never penetrates.

In the preparation of cavities for inserting fillings it is naturally often next to impossible to remove all the carious dentine, and in all such cases it is especially desirable that the filling material itself should possess antiseptic properties, since we, in using such a material, not only destroy those organisms existing in the carious tissue, but the material, if it remains permanently antiseptic, retards the working of the ferment organisms from without and the appearance of secondary decay. We need, therefore, a material for filling which is not only antiseptic at the time of insertion, but which remains permanently so after being inserted. I have endeavored to determine the relative antiseptic power of different filling materials (cements, amalgams, etc.) not only at the moment of mixing, but after they were thoroughly dry, after they had lain some hours in sweetened saliva, and after they had been an indefinite time in the human mouth.

A large number of miniature test-tubes (homeopathic pill-tubes) were provided with cotton stoppers and sterilized. Into each was brought $\frac{1}{2}$ c.c. of beef-extract-sugar solution previously infected with carious fungi (pure culture). To the first tube was added a small drop of a 1-per-cent. sublimate solution, the second tube was left untouched, and into the third, fourth, fifth, etc. were brought the filling materials whose antiseptic virtues were to be tested; these were in the form of cylinders 2 mm. in diameter and 3 mm. long; if old fillings from the mouth were used, pieces were taken having approximately the same size.

These tubes now being placed in the incubator, their contents became cloudy one after the other. In those tubes which contained fillings of but slight antiseptic power the development of the fungi proceeded rapidly and the cloudiness soon appeared; if, on the other hand, the filling was strongly antiseptic, the development of the fungi was hindered and the cloudiness appeared later. The first tube to which the sublimate solution had been added of course remained clear, and by comparing the others with this it was easy to see just when the turbidity began to show itself; the second tube, containing no antiseptic and no filling, served as control, and the space that intervened after the control became turbid till any one of the other tubes became turbid was a measure of the antiseptic power of the material in that tube.

As the result of a great number of experiments, I have been able to get together the following table.

When the control tube becomes turbid in five hours, then—

A tube containing	an old oxyphosphate filling becomes turbid in	5	hours.
" "	an old oxychloride filling becomes turbid in	5	"
" "	a gold cylinder becomes turbid in	5	"
" "	a Hill's stopping cylinder becomes turbid in	5	"
" "	an amalgam cylinder (kept twelve hours in saliva) becomes turbid in	$5\frac{1}{7}$	"
" "	an agate cylinder (kept twelve hours in saliva) becomes turbid in	$5\frac{1}{4}$	"
" "	an old amalgam filling becomes turbid in	$5\frac{3}{10}$	"
" "	an amalgam cylinder (mixed dry) becomes turbid in	$5\frac{3}{8}$	"
" "	an amalgam cylinder (mixed wet) becomes turbid in	$5\frac{1}{2}$	"
" "	an oxyphosphate cylinder (twelve hours in saliva) becomes turbid in	$5\frac{1}{2}$	"
" "	an amalgam cylinder (twelve hours old) becomes turbid in	$5\frac{2}{3}$	"
" "	an old filling of tin and gold becomes turbid in	$5\frac{4}{5}$	"
" "	an oxyphosphate cylinder (twelve hours old) becomes turbid in	6	"
" "	an agate cylinder (twelve hours old) becomes turbid in	$6\frac{1}{4}$	"
" "	an iodoform cement cylinder (twelve hours in saliva) becomes turbid in	$6\frac{2}{5}$	"
" "	a pyrophosphate cylinder (mixed dry) becomes turbid in	$7\frac{1}{8}$	"
" "	a pyrophosphate cylinder (mixed wet) becomes turbid in	$7\frac{3}{8}$	"
" "	an oxychloride cylinder (twelve hours old) becomes turbid in	9	"
" "	a piece of dentine from a tooth impregnated by a copper amalgam filling becomes turbid in	11	"
" "	an iodoform cement cylinder (twelve hours old) becomes turbid in	12	"
" "	an iodoform cement cylinder (fresh) becomes turbid in	?	"
" "	a globule of mercury becomes turbid in	—	
" "	a cylinder of black oxide of mercury becomes turbid in	—	
" "	a cylinder of any copper amalgam becomes turbid in	—	
" "	any old copper amalgam filling becomes turbid in	—	
" "	a cylinder of oxychloride (fresh) becomes turbid in	—	

The (—) signifies that the solution remained permanently clear.

We see from these results that the only filling at present in use which exerts a continual antiferment[1] action upon the walls of the tooth and its immediate surroundings is the old copper amalgam; not only that, but the very substance of the tooth containing such a filling itself

[1] I use the terms antiferment and antiseptic interchangeably, though the former is perhaps preferable, since we are treating of ferment, and not septic organisms.

becomes antiseptic, a piece of bluish or bluish-green dentine from such a tooth very powerfully retarding the development of the fungi, and, indeed, in two cases completely destroying them. Secondary decay in such a case would be next to impossible where anything like cleanliness was observed.

This result is well supported by observations which I have had abundant opportunity to make for the last five years here where this material is so extensively used, and I do not hesitate to say that if our only object is to check the destruction of tissue by caries there is no material at present in use with which this object may be so surely accomplished as with a good copper amalgam. It is a material, however, which I have never used, though I am not aware of any bad effect produced by it beyond the discoloration of the tooth. Skogsberg's iodoform cement came into my hands too late to complete the experiments with it. It has undoubtedly strong antiseptic properties, which it does not completely lose even when exposed to the saliva, and might, no doubt, be used to great advantage as a foundation for permanent fillings. Old fillings of tin and gold possess slight antiseptic power, still less (almost zero) old amalgam fillings (not copper). The very inconsiderable power of amalgams to prevent the development of ferment fungi is a source of some surprise, since we have been accustomed to look upon them as very active in this respect. It is probably a mistake to attribute the hardening of dentine under amalgam fillings to the antiseptic action of the amalgam, since in the first place it possesses this power to but a slight degree, and in the second place the hardening may take place under fillings of gutta-percha equally well. If we dry the cavity but indifferently well and then choose a piece of gutta-percha which we think will about fit the cavity, warm it, and stuff it into the cavity, we, of course, can expect only bad results. If we proceed as follows, we will obtain excellent results, as I have seen time and again: Adjust the dam, excavate carefully, especially the margins, wash with a strong antiseptic, dry thoroughly with bibulous paper, and then with the hot-air syringe, till the surface of the dentine becomes whitish, paint with a thin solution of copal varnish, dry again with warm air, then put in the gutta-percha in small pieces, one after the other, being *sure* that each piece sticks to its place, especially along the margin, just as if you were making a filling of gold. A piece which has once moved in its place must not be allowed to remain, as a leak will be the result. Remove such a filling after two years, and the cavity will often be found in an excellent condition for a gold filling.

The oxychlorides, when first mixed, are powerfully antiseptic, but soon lose their energy when exposed to the action of saliva.

The oxyphosphates are very much inferior to the oxychlorides in antiseptic power, and should never be used in cavities where there is much soft dentine. This conclusion is borne out by my own experience in practice, and by that of others with whom I have conversed on the subject. Dr. Paetsch first called my attention to the disastrous results of such a practice, and his testimony was confirmed by that of Dr. F. P. Abbott and others.

It must not be expected that the results given in the above table are

absolutely free from error. The experiment is attended with more difficulties than are at first sight apparent; especially does the sterilization of the filling materials themselves involve much time and labor, and the results are not always constant; this was especially the case with iodoform cement. Amalgams and phosphates gave quite constant results. The tests with some of the materials were made over twenty-five times; with others, such as copper amalgams, where there was no doubt as to the result, only a few experiments were made.

Caries of the teeth, except in the later or last stage, is the result of a ferment process, and the organisms found in the deeper parts of decaying dentine, which I have isolated and obtained in pure culture, are ferment organisms. The decomposition of the pulp and contents of the root-canal, attended by bad-smelling products, is, on the other hand, a putrefactive process in which entirely different species of fungi are concerned. Whether or not the results which I have obtained for the fungi of caries would apply equally well to those putrefactive fungi is a question which can be settled only by experiment upon pure cultures of the same.

Although I have now, as I think will be granted, established upon a sure basis the fact that caries of the teeth may result directly from the action of acid-producing fungi in the presence of fermentable carbohydrates, the conclusion would hardly be justifiable that by keeping the mouth constantly and perfectly free from all fermentable substances, or by repeated application of antacids or antiseptics to all parts of the teeth, or by all these means together, we could ever banish dental caries from the oral cavity. A most powerful influence which we do not well understand is exerted by the nutritive processes in the teeth themselves.

I am assured by men who have grown old in the practice of dentistry that mouths which have long been under their observation, and which practically have been completely free from caries for years, at once, on account of some sudden change of health, show a general breaking down or crumbling of the teeth *en masse* in the space of a few weeks. It has also been my experience that patients who have been dismissed by their dentists in America with the assurance that, according to previous experience, their dentures would require no treatment for one or two years, have come to me a few weeks later with teeth looking as though they had not been under the hands of a dentist for years. Some say the ocean-voyage spoiled their teeth; others attribute it to a change in the climate, food, health, etc.

At any rate, we have here a cause which lies without the domain of both bacteria and acids (either ferment or otherwise). The lime salts of the teeth are supposed to form with the organic matter of the tooth a definite chemical compound, and it is probably due to this fact that simple salts of lime are so much more readily soluble in weak acids than pulverized tooth-bone, or that the tartar upon the teeth is so much more easily soluble than the teeth themselves; so that when any one rinses his mouth with vinegar, and afterward finds lime in the vinegar, we know that the lime in by far the greater part—if, indeed, we may not say altogether—came from the tartar. Now, though there is no positive evidence for the supposition, it is certainly not altogether improb-

able that, as a consequence of certain derangements in the nutritive functions of the teeth resulting from a change of health, etc., etc., a dissolution of the affinity between the lime salts and the organic matter may take place, thus setting free the easily soluble lime salts, which are then carried away in solution or washed out mechanically. This is a supposition only, which I bring forward because facts in this case are absolutely wanting. If it should, perchance, contain a trace of truth, then adult and pulpless teeth should be less subject to these *sudden* attacks of caries than young teeth with living pulps.

There still remains much hard work to be done before the subject of dental caries may be dismissed as having received a final solution *in all its different phases*. There are men enough in the profession, however, who are willing to work, and who do not shrink from the tasks yet to be performed.

The Fungi of Dental Caries: Their Pure Cultivation and Effect upon Lower Animals.

In the preceding pages will be found the description and illustrations of two species of micro-organisms obtained from carious dentine. These species I isolated by inoculating culture liquids with very small pieces of carious dentine taken from near the border of the normal tissue. If the fungus was not at once obtained in the pure state, a second culture tube was inoculated, after the method of fractional culture, with a minimum portion of the first, and so on. It soon, however, became apparent that the capture of these two species by no means ended the work; on the other hand, new forms continually presented themselves, and, in order to be able to determine definite characteristics for each species, resort was had to the culture on plates of gelatin prepared with beef extract, calf's broth, malt decoction, etc.

The beef-extract gelatin, for example, I prepare as follows: 200 c.c. water + 3.0 beef extract + 3.0 sugar are first neutralized, then slowly boiled for five minutes and filtered (filter and all other vessels, of course, sterilized). After cooling, 8.0 of the finest gelatin is added and gradually heated till the gelatin is dissolved; it is then cleared with the white of an egg, and all together kept at the boiling-point for about five minutes, stirring constantly to prevent burning; it is then passed through a filter surrounded by a bath of boiling water into glass tubes with cotton stoppers (both sterilized), and kept in a refrigerator. When to be used, it is melted in warm water and poured upon sterilized cold glass plates, which may be 0.15 m. long by 0.07 m. wide, and placed in the moist chamber. The layer of gelatin should be about 2 mm. thick.

Suppose, now, we have a culture containing different species of fungi and we wish to separate them. A thin platinum wire with one end melted into a glass rod is sterilized in the flame of a Bunsen burner, and on cooling dipped into the impure culture and lightly drawn across the surface of the gelatin; the fungi which adhered to the platinum wire are thereby scattered in a row upon the surface of the gelatin, and in a short time we will find that at certain points in the row one form of fungus has developed and at other points other forms. Now, if we

take upon the end of our platinum wire a small quantity of fungi from one of these points and draw it across the surface of a second plate, we will in parts of this line invariably obtain a pure culture of one of the species in the original impure culture, nearly every species being distinguished by some characteristic in the form which it takes in growing and in its action upon the gelatin. Having obtained a pure culture in this manner, test-tubes containing gelatin are inoculated with it. In these it may be kept in a pure state for weeks or months, while the plates are always short-lived.

The gelatin method of pure culture has one great disadvantage in the low melting-point of the gelatin: 24° to 25° C. is the highest temperature to which they can be exposed without danger of melting, and this, to fungi which are accustomed to a temperature of 37° C., is not always a matter of indifference. I have succeeded in isolating three species besides the ones previously described (see p. 802), and—only for the purpose of distinguishing them—I will designate them by the Greek letters γ, δ, and ε. These fungi are shown in Figs. 420, 421, and 425. In Fig. 419 I have reproduced the fungus described on page 802 as a caries fungus, for the sake of comparison. When the species α, γ, and δ are isolated, it is not difficult to tell one from the other; when, however, they are mixed together, it is next to impossible to determine which is which, and especially is this the case with α and γ. Their modes of development on gelatin are, however, so different that we possess therein a ready means of distinguishing between them. The α-fungus, *sparingly* inoculated into gelatin tubes, presents in a few days the appearance which I have attempted to represent in Fig. 422. It may be compared to a bunch of grapes which presents all gradations from the fully-developed berry to the little green one; the masses of fungi are globular or ovoid, exceedingly fine, and semi-transparent, presenting altogether a strikingly beautiful culture which it is impossible to even approximately represent by drawing. It furthermore forms a button upon the surface of the gelatin; the latter becomes softened, but not liquefied. On the plates it

Fig. 419.

Fig. 420.



Fig. 421.

Fig. 422.



Fig. 423.

Fig. 424.

presents soft, milky ridges or knots raised sometimes a millimeter above the surface of the gelatin and obtaining a width at the base of 3 to 6 mm. The γ-fungus differs from all other fungi that I have yet found in decaying dentine in that it completely liquefies the gelatin. The culture tubes present, therefore, a funnel-shaped area of liquefied gelatin, while the fungi themselves fall to the bottom of the funnel. (See Fig. 423.)

This fungus forms furrows in the plates; and if the plate is turned on its edge, the whole mass of fungus flows from one end of the furrow toward the other or slides quite off the plate.

The δ-fungus (Fig. 421) forms completely *opaque* masses which may have a slight yellowish tinge, provided the gelatin itself is yellowish. It has a small surface-growth and liquefies the gelatin only to a slight extent. In cultures on plates which are two or three days old, the row of fungus appears to lie in a trough or depression in the gelatin. It does not move, however, when the plate is turned on edge. (See Fig. 424.)

For the fungus of Fig. 425 I have not yet been able to establish definite peculiarities of growth. As far as my observations have at present extended, it differs from that of Fig. 421 in that it is almost entirely wanting in surface-growth and forms colorless masses even in colored media. It does not liquefy the gelatin. Viewed by transmitted light, it appears to have a bluish tinge and a slight opalescence. It grows, however, very slowly, and I have consequently as yet been unable to establish certain and definite characteristics for it. The fungus described on page 802 grows still more slowly at gelatin temperature, and I cannot at present give any microscopical features by which cultures on gelatin may be distinguished.

Fig. 425.



The most important feature connected with all these fungi, especially the coccus-forms, is that they possess a ferment activity—in other words, they are capable of producing acid out of sugar, or, in the human mouth, out of starch, by the aid of the diastatic action of the saliva. They may consequently all be looked upon as factors in the decay of the teeth. I would not venture to say that the α-fungus is more concerned in the process of caries than all the rest together; nevertheless, such is the constancy with which I have found it that if any one else should make the assertion I would have no reason for contradicting him. Cultivated in liquid substrata, none of them form films or skins upon the surface of the liquid, but powdery or fleecy precipitates upon the bottom and sides of the vessel. None, so far as I have observed, produce an evolution of carbonic acid in solutions containing sugar, nor do they appear to suffer when the access of oxygen is restricted.

A question of great importance not only for dentists, but for general physicians—and, in fact, for everybody—is that relating to the possible pathogenic nature of these fungi. We find in the works of Leyden and Jaffé, Haussman, Bollinger, James Israel, etc., sufficient ground for the statement that "these fungi, in all parts of the human body which they

reach, can play the same malignant rôle as upon the teeth." Gangrene of the lungs, abscesses of the mouth and throat, chronic pyæmia, etc., etc. have by various authors been ascribed to the action of the fungi of the human mouth. Raynaud, Lannelongue, and Pasteur produced what they called *maladie nouvelle* by inoculating rabbits with the saliva of a child bitten by a mad dog, and A. Fraenkel has in a number of cases produced sputum-septicæmia by inoculating rabbits with his own saliva.

We ask ourselves, then, the question, May not many of our obscure cases of infectious disease which now and then appear after extraction or other dental operations, and which are without further examination attributed to the unclean instruments or hands of the dentist, be the result of an infection produced by micro-organisms in the patient's own mouth? If a man's saliva contains organisms which when brought into the blood of a rabbit occasion death in twenty-four hours, would it be a matter of no consequence to produce so large a wound in his mouth as that caused by the extraction of a tooth? For the purpose, if possible, of throwing some light upon this question, I have undertaken a series of experiments for determining whether the organisms which are most commonly found in the human mouth possess the power of producing death (by septicæmia or otherwise) by inoculation. These experiments, as well as the others recorded in this article, I have, in fact, only begun. My absence from home, however, prevents my carrying them on during the summer months, and I have determined, therefore, to present the results which I have already obtained, few and imperfect as they are.

The inoculations have thus far been performed on three rabbits, one rat, and six white mice. They were made partly with a mixture of the two fungi α and γ, and partly with saliva which had been kept in sterilized calf's broth for fifteen hours at blood-temperature.

Each rabbit received 1 c.c. of the infected liquid, injected directly into the lung or abdominal cavity; the rat 0.2 c.c., and the mice 0.1 c.c.

Exp. 1. Small rabbit inoculated with 1 c.c. in the abdominal cavity: In the course of a few hours the rabbit appeared evidently ill, refused to eat, and remained quiet in the corner of the cage. In twenty-four hours diarrhœa appeared, with a slight elevation of temperature. These symptoms increased during the next day, till fifty hours after the time of inoculation it was found at the point of death. The examination showed the blood to be almost entirely free from organisms and no indication of septicæmia. Living fungi were found, however, in the abdominal cavity, and a large part of the right lobe of the liver was completely riddled with masses of fungi; also in the fæces were found enormous numbers, which morphologically were identical with those in the liver, their entrance into the alimentary canal from the liver being easily accomplished. I unfortunately neglected, however, to establish their identity by the proper cultures.

Exp. 2. Rabbit inoculated as in Exp. 1: The animal manifested a slight indisposition on the second day, from which it soon recovered.

Exp. 3. Rabbit inoculated in the right lung with saliva which had been kept in sterilized calf's broth for fifteen hours at 37° C.: No effect apparent.

Exp. 4. White rat, injection in abdominal cavity: The animal remained well.

Exps. 5–11. Seven white mice; five inoculated in abdominal cavity with α- and γ-fungi; two in the lungs with saliva in calf's broth: Of the former two died at about the fortieth hour under the same symptoms as in Exp. 1. Great numbers of fungi were found in the abdominal cavity, which by culture on gelatin proved to be the γ-fungus. A number of colonies were likewise found in the liver. Microtome sections of the liver of the rabbit stained in fuchsin show, when examined under the microscope with sufficient light to drown the tissue, a distribution of the fungi very similar to that often seen in the outermost layers of carious dentine. (See Fig. 426.) Of course no definite conclusion can be drawn from a few experiments. They are, however, sufficient to show that these fungi certainly do possess a pathogenic character, and when brought into other parts of the human body may be able, under predisposing conditions, to produce disastrous results. Especially the continual swallowing of these fungi in great numbers may by their ferment activity alone in the course of time produce very serious derangements of the stomach and alimentary canal, since the small percentage of hydrochloric acid in the stomach, even in the presence of the normal quantity of pepsin, is not sufficient to devitalize them. It was with a certain degree of satisfaction that I have failed thus far to find the coccus of sputum-septicæmia in my own saliva. It is, however, very desirable that experiments should be made with the saliva of many persons, for the purpose, if possible, of determining in what proportion of cases this fungus is present.

FIG. 426.

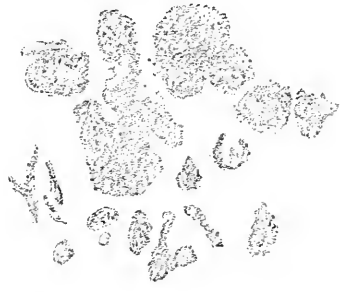

Messrs. Underwood and Milles have endeavored to repeat some of my earliest experiments in the production of artificial caries, but, under those very abnormal conditions against which I entered warning in the *Independent Practitioner*, failure was the necessary result. They performed, further, a very elaborate experiment, lasting six months, in which the baths became so putrid and offensive that "they quit the experiment with relief." They naturally produced no caries, thereby furnishing an admirable confirmation of the fact to which I have so often called attention—that it is impossible to produce even a trace of caries by putrefaction alone. They tried a third experiment, putting the fungi under such abnormal conditions that they could not produce acid, and of course failed again, once more confirming the fact that I have long since established—that we can have no caries without acid. With these experiments they risk the statement that artificial caries is probably an impossibility. The production of artificial caries is a *fait accompli*, and to deny its possibility is only to endanger the reputation of him who denies. They state further that they can find no softened dentine which does not contain micro-organisms. This, however, is con-

trary to the experience of a great many American microscopists, and, moreover, as I have elsewhere stated, I shall take with me to the next meeting of the American Dental Society of Europe several hundreds of specimens of carious dentine, and be ready to show the areas of softened, non-infected dentine on any one or on all of them.

Messrs. Underwood and Milles understand me, in the third place, as being of the opinion that all the micro-organisms connected with caries of the teeth are only different forms of one fungus. The readers of the *Independent Practitioner* know better. I have stated simply that *one* of the many fungi found in the human mouth in connection with caries of the teeth may produce different forms of development. This is the fungus which I have designated by the prefix β. It is scarcely necessary to add that I am always prepared to prove its existence microscopically, as well as on the authority of many of the best mycologists of Germany.

No one, I think, will deny that within the last few years I have done a large amount of work and contributed some evidence toward the solution of the problem of dental caries. The amount of material dealt with and the ground gone over have been so extensive that it has been absolutely impossible, with the greatest efforts, to remain as long by each step as would have been desirable. It may be, therefore, that at some points the subject has not been presented with sufficient clearness or decisiveness; it may be, too, that at some points the conclusions have been faulty, since I make no pretension to infallibility. Time will show whether this is the case. At present I know of no important change which I could make if I were to rewrite all my contributions of the last three years.

I desire to give, in closing, a very short *résumé* of the work which I have accomplished:

1. I convinced myself by the examination of some thousands of slides of carious dentine that micro-organisms were always present, and that they, without any doubt, were the cause of various anatomical changes which were found to take place in the structure of the dentine during caries. (Here, of course, the question of priority does not suggest itself: Leber and Rottenstein, as is well known, were the first to give definite expression to this fact.)

2. I proved, at the same time, that the invasion of the micro-organisms was not, in the majority of cases, simultaneous with the softening of the dentine, but that large areas of softened dentine could be found that contained no fungi. Of all those who examined my preparations in America, no one, whatever his theory, ever once denied this fact. I concluded from this that the softening of the dentine went in advance of the invasion of the organisms.

3. I determined by analyses of masses of carious dentine sufficiently large to give reliable results that the softening of the dentine is of the nature of a true decalcification; that the decalcification of the outer layers is almost complete and diminishes in degree as we advance toward the normal dentine; furthermore, that the same relations maintain in dentine softened in a mixture of saliva and bread or in weak organic acids; also, that in a mass of carious dentine the lime

salts had been removed to a much greater extent than the organic matter.

4. I maintained from the first that the softening of the dentine was produced by acids for the most part generated in the mouth by fermentation. I had, however, no direct proof of this.

5. I *proved* that fungi exist in great numbers in the human saliva and in carious dentine which have the power to produce acid under conditions which are constantly present in the human mouth. I determined this acid—for one of the fungi, at least—to be the ordinary ferment, lactic acid.

6. I produced caries artificially which under the microscope cannot be distinguished from natural caries by subjecting sound dentine to the action of these fungi in fermentable solutions.

7. I determined the influence of various antiseptics and filling materials upon the fungi of caries.

8. I isolated various forms of these fungi and determined, *in part*, the conditions most favorable to their development, their characteristic reaction upon gelatin, their physiological action, their effect when inoculated into the system of lower animals, and their possible connection with certain obscure diseases generally attributed to the carelessness of the dentist.

My continual search has been after facts, and such facts as I have obtained I have presented before the profession, never putting before them either theory or speculation, nor anything which was not the result of severe and continued labor; and in this spirit I propose to prosecute this work, as well as any other that I may undertake in the interest of the profession.

BERLIN, May 21, 1884.

NOTE.—Since writing the above I have succeeded in producing death by septicæmia of both mice and rabbits by injecting into the lung saliva from the mouth of a perfectly healthy person.

BIOLOGICAL STUDIES ON THE FUNGI OF THE HUMAN MOUTH.[1]

IN order to be able to determine upon the proper course to be taken in the attempt to remove or check the progress of any disease, it is necessary that our ideas of the cause and course of that affection be established upon the most certain, exact, and scientific data which we are capable of attaining. Unfortunately for the dental profession, the attempt to furnish a scientific solution of the problems of dental caries has until recently been confined to a very few, and even now a majority

[1] German mycologists use the term *Pilz* indiscriminately to designate either schizomycetes, blastomycetes, hyphomycetes or myxomycetes. When it is desirable to refer to any one of these groups in particular, they use the prefixes *Spalt, Spross, Schimmel* or *Faden*, and *Schleim*, giving *Spaltpilz, Sprosspilz, Schimmel-* or *Fadenpilz*, and *Schleimpilz*. Following their example, I have in previous papers used the term "fungus" for all of the four groups of mycetes mentioned above, and shall also use the term in this paper, in which only schizomycetes are treated of.

of the investigators in dental pathology are content to restrict their observations to the clinical aspect of the question—a course which could never produce a satisfactory solution—while others even openly advocate a speculative course and do not hesitate to ascribe to every new factor discovered in nature a *rôle* in the production of caries of the teeth. Consequently, we have had presented to us, in turn, worms, acids, inflammation, electricity, infusoria, bacteria, putrefaction, toxic agents, etc., etc., as causes or conditions of *caries dentinum*, some of these theories containing some truth and some a surprising amount of absurdity. In the last two or three years, however, a great advance has been made in the methods of study and a number of important points have been firmly established:

1. The observation of Leber and Rottenstein that micro-organisms are constantly present in decaying dentine has been confirmed (Weil, Milles, Underwood, Miller).

2. The softening of dentine in caries has been shown to be chemically identical with that produced by certain weak organic acids (Miller, Jeserich, Bennefeld).

3. It has been established that various organisms found in the human mouth produce the decalcifying acid by first converting non-fermentable sugars into fermentable varieties, and secondly by splitting fermentable sugars into lactic acid (Miller, Hueppe).

4. The same organisms have been found capable of dissolving decalcified dentine, while they have no apparent effect, even after two or three years, on sound dentine (Miller).

5. Caries of dentine chemically and morphologically identical with natural caries has been produced outside of the mouth (Miller).

6. It has been furthermore shown that certain of the organisms of the human mouth are capable of developing under exclusion of air, thus making it possible for them to propagate within the substance of the dentine (Miller, Hueppe).

I propose to describe in the following pages a series of experiments made for the purpose of obtaining more definite information respecting the number and morphology of the fungi of the human mouth, and their physiology, as far as is necessary to an understanding of the part which they may perform in the production of caries of the human teeth.

At the meeting of the American Dental Association at Saratoga a number of tubes containing pure cultures of fungi were passed around; with regard to these a reporter remarked that "they were evidently beyond the information of the majority." It is not very flattering to American dentistry if its representative association allows a question of so great importance to remain beyond its comprehension, nor is there any excuse for such a condition of things now, so widespread have the methods of pure culture become. I rather incline to the opinion that the reporter misinterpreted the apathy of the members of the society. I shall, at any rate, here describe in a few words the methods now universally employed in isolating any given fungus, and then more in detail give the means which I have used to ascertain the physiological characteristics of the different fungi when obtained in pure culture.

We will start with a solution densely impregnated with micro-organisms and a number of tubes of culture gelatin perfectly sterilized. The gelatin being melted, we add to the first tube one bead (on a loop of sterilized platinum wire) of the solution; this is called the *first dilution*. From this tube we add two or three beads to a second tube (*second dilution*), and from the second five or six beads to a third tube (*third dilution*). The gelatin is then poured upon horizontally placed sterilized cold glass plates. It congeals in a few seconds, and the three plates are placed in a pile (on glass benches) in a moist cell. The plates are examined after twenty-four to thirty-six hours under a magnification of 100 diameters. By this means the fungi are so separated that on the third plate there will generally not be more than two to ten (on the second there may be one hundred or two hundred, while on the first, of course, there are very many more). As each micro-organism develops, being fixed in the gelatin, we will have at that point a pure culture of that particular kind; at another point we obtain a colony of a second kind; and so on. In general, colonies of different fungi may be distinguished with the greatest ease by their microscopic appearance. With a sterilized platinum wire bent at right angles at the end we now pick up a number of the colonies of each kind under the microscope (100 diameters), and transfer them directly to tubes of culture gelatin, only one colony to each tube. We have then (except in case of a possible accidental air-infection) pure cultures. Some experience is necessary to enable one to pick up the colonies under the microscope. Beginners should not attempt it with plates where more than one colony is in the field at once.

The method described on page 813 may also sometimes be used to great advantage. For fungi which do not grow on gelatin, agar-agar or congealed blood-serum should be used. The former, 1 to $1\frac{1}{2}$ per cent., has a higher melting-point than gelatin, 10 per cent., and remains solid at the temperature of the human blood. When it is used for plate-cultures, it must be melted in hot water and the infection made at a temperature of 40° to 42° C. Below this temperature it becomes solid and cannot be poured; above it the germs would be liable to suffer. In other respects the agar-agar media are treated as the gelatin. Congealed blood-serum cannot, of course, be poured upon plates. It is prepared in test-tubes so inclined as to give the greatest possible surface, and a minimum quantity of the substance containing the fungus or fungi spread over the surface. Having obtained a pure culture of any fungus, the points to be determined regarding it are the following:

1. Its morphology (bacillus, spirillum, micrococcus).
2. Is it movable? Does it produce spores?
3. What are its growth-characteristics on various media, microscopically and to the naked eye?
4. What are its relations to oxygen?
5. Does it produce fermentation? If so, what fermentation, under what conditions, and with or without development of gas?
6. Does it cause putrefaction?
7. Does it have a diastatic, inverting, or peptonizing action?
8. Has it a pathogenic character?

9. Does it produce coloring-matter?

10. What is its susceptibility to the action of the various antiseptics?

The first and second of these questions are, of course, determined by the microscope alone; the third, by the microscope and the naked eye combined; the fourth, by the methods described on page 814, or by placing a thin strip of mica upon one half of the culture-plate before the gelatin solidifies. The mica then adapts itself closely to the surface of the gelatin, excluding the air; and if the fungus requires oxygen for its development, the colonies beneath the mica either will not develop at all or they will be very small compared with those on the other half of the plate, their growth ceasing as soon as the oxygen in the gelatin has been consumed (Koch). The fifth point is answered by infecting fermentable solutions with the fungus in question, placing it under various conditions of temperature, etc., and determining the products of fermentation (if any); the sixth, by analogous methods; the seventh question is determined by the action of the fungi upon starch, cane-sugar, and albumen (boiled white of egg); the eighth, by experiments on animals; the ninth, by the appearance or non-appearance of color in the vegetation itself or in the surrounding medium; the tenth, by experiments that will readily suggest themselves. Other points to be investigated will be mentioned farther on.

Boiled potato is a medium of great value in the determination of schizomycetes. No medium, however, requires greater care in preparation and after-treatment than this in order to obtain satisfactory results. Any sound potato *which does not become mealy or crack open on boiling* will do for the purpose. It is first thoroughly washed and brushed, and, all defective spots and deep eyes being removed, it is placed for one hour in a corrosive sublimate solution, 5 to 1000, then in the steam sterilizer for one-half to one hour. In the mean time, the moist cell is sterilized and the bottom lined with filter-paper wet with sublimate solution, 5 to 1000. The potatoes are while hot removed from the sterilizer with sterilized forceps, cut into halves with a cold sterilized knife, and placed directly upon the sublimate paper (the cut surface up) and the cell closed. Potato-sections prepared in this way should remain unchanged indefinitely. When the potato has become cool, the cover of the cell is carefully removed and the fungus which is to be cultivated is spread upon a space about as large as a dime in the centre of the section. Fungi which, morphologically as well as in their reaction upon gelatin, agar-agar, and blood-serum, show no appreciable differences, may sometimes be easily distinguished by aid of the potato culture. The potato can seldom be used to separate fungi—*i. e.* to prepare pure culture. It is chiefly used as a reagent in distinguishing between fungi already in pure culture. For example, all comma bacilli yet discovered grow on potato except the one found by Deneke in old cheese, which does not develop at all on potato, and is thereby at once distinguished as an entirely different fungus.

Eggs may often be used to great advantage. They are prepared as follows: The *fresh* egg is placed in sublimate, 5 to 1000, for ten minutes, then in the steam sterilizer for one hour. The cell for eggs is prepared as for potatoes, except that a sterilized glass plate resting on a

glass bench is placed in the bottom to support the egg-sections. As the eggs must be handled with the fingers, the hands must be thoroughly washed, then soaked in sublimate, 5 to 1000, and then washed again in *alcohol absolutus*, to remove the sublimate. The eggs are shelled while still hot and cut into two, three, or four sections. They are vaccinated in points upon the white; the yellow is not so well adapted to culture experiments, since it cannot be cut with a smooth surface.

I always keep on hand sections of potato and egg, also tubes of gelatin, agar-agar, and blood-serum; and when in my practice particularly good material or anything uncommon presents itself, a portion of it is at once transferred to these different culture media; so that it is pretty sure to develop in one of them, at least. For example, I have several times met with a fungus in the human mouth which produces a yellowish coloring-matter, and which absolutely refuses to grow on anything which I have tried except potato.

By use of the methods described I have isolated twenty-two different fungi from the secretions or deposits of the human mouth, and have endeavored to determine, as far as possible, their separate peculiarities of growth, physiological action, etc. It will, however, at once suggest itself to every one that a thorough study of twenty-two different fungi involves an enormous amount of labor and might constitute almost a life-task for one experimenter. The task is, moreover, rendered still more difficult by reason of the fact that many of these fungi show differences of action when cultivated in different media, rendering the number of experiments necessary to come to a definite conclusion doubly great. I shall, therefore, not attempt to present an exhaustive treatment of the subject, but rather an introduction, hoping, at the same time, to establish some points which may be of use in bringing about a clearer understanding of the factors involved in the production of dental caries.

Regarding the first point to be considered—the morphology of the fungi—it is not at all necessary to enter into a minute description of all the different forms here presented; the figures will give a sufficiently clear idea of their diversity and the appearance of their colonies under a low power. For the rest, suffice it to say that ten of them are micro- or diplococci, five are bacteria, and six bacilli. Some show more than one form of development. It would, however, lead us too far from our subject to discuss this fact here.

In liquid media three grow out into long leptothrix, forming bundles or meshes of intertwining uni- or multicellular threads, while one develops into spirilli; eight are motile, fourteen are non-motile, while three only have been seen to form spores. The others multiply by division alone.

With reference to the latter point, however, I have not made examinations sufficiently careful or extensive to be able to speak decidedly. Eight liquefy nutritive gelatin, one converts it into a paste, thirteen leave it unchanged. On agar-agar the differences of growth are not sufficiently pronounced to deserve particular mention. In gelatin the microscopic appearance of the colonies of a sufficient number of these fungi is

FIG. 427.

shown in the figures (*b*). It will be seen that the appearance of the colonies forms a much safer means of differentiation than the morphological characteristics of the fungi, it being very seldom that in growing two fungi present exactly the same appearance. An exception is, however, presented by 6 and 7, which to the naked eye and under the microscope grow on gelatin exactly alike; moreover, on potato, white of egg, blood-serum, agar-agar, and milk their effect is identical. One, however, produces a yellow coloring-matter, the other not; and thereby they are easily distinguished. The others may all be readily distinguished by their growth on potato.

In relation to oxygen they show great differences. Ten are strictly aërobian—*i. e.* they grow only where the air has free access; four are not strictly aërobian—*i. e.* they propagate also when the atmospheric air is excluded, though not so rapidly; eight grow equally well with or without access of air; sixteen produce an acid reaction in a solution of beef-extract, peptone, and sugar; four produce an alkaline reaction without the appearance of bad-smelling products and appear to leave the solution neutral. With regard to the six, however, the results were not satisfactory, sometimes the reaction being acid, at other times neutral or alkaline, depending somewhat upon the material used for the cultures.

Fig. 428.

Some which produce an acid reaction in fermentable solutions give rise to an alkaline reaction in non-fermentable solutions. The acid produced is probably in all, or in nearly all, these cases, lactic acid. This fact I established for No. 1 by chemical analysis, for No. 2 by forming the zinc salt and crystallizing, for No. 5 by the color test.[1] In the other cases the acid was not determined. Thirteen were repeatedly cultivated on potato. Of these, five grew rapidly, one in particular covering the whole surface of the section in forty-eight hours and completely liquefying it to a depth of 1 to 2 mm., the liquefied mass flowing off at the sides; the others develop very slowly and attain only a limited growth. I am not able to say whether any of them possesses a diastatic action. It is, however, highly probable. Fifteen were cultivated on boiled white of egg. Four grew very rapidly, No. 19 (see Fig. 439) in particular in from two to four days, converting the egg into a semi-transparent pasty mass which gradually disappeared. In the first two days large quantities of sulphuretted hydrogen are developed; later, ammonia. Seven grew slowly on the white of egg, and four scarcely at all. The nourishment of the fungi naturally takes place at the expense of the albumen of the egg, which is converted into a soluble variety by the peptonizing action of the fungus. In two cases the presence of peptone could be detected in the dissolved mass

Fig. 429.

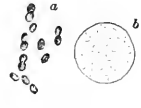

[1] Two drops carbolic acid, 1 drop chloride of iron, 20 c.cm. water, produce a violet color which becomes yellow on the addition of lactic acid, even in very dilute form. I am not prepared to say that this is an absolutely sure test for lactic acid. It is the test used by Prof. Ewald and others for detecting lactic acid in the stomach, and is considered by them to be decisive. Of course the culture material itself must not give this reaction. Beef-extract, for example, cannot be used, as it already contains lactic acid. A few other substances also give this reaction, but none, I believe, which are likely to be produced in these cultures.

after separation from the albumen by the biuret reaction, the organisms producing more peptone than they needed for their own consumption.

Fig. 430.

Some of them produce in fermentable solutions considerable quantities of gas. If a glass bulb with a fine stem drawn out to a point be filled with milk inoculated with No. 3 (see Fig. 428), otherwise sterile, and kept at blood-temperature, in twenty-four hours so much gas will be generated that on breaking off the point the whole contents of the bulb will be ejected with considerable force. The same effect may sometimes be produced, though not so markedly, when non-fermentable solutions are used. We may expect a similar action to take place when we seal up a dead pulp in a tooth, the gas itself not only escaping through the apical foramen, but, if its exit is hindered, ultimately forcing particles of the decomposing pulp through with it. The question suggests itself whether certain configurations seen in carious dentine may not owe their origin in part to the pressure of gas.

Fig. 431.

Four produce coloring-matter, Nos. 5 and 7 (Figs. 430 and 431) in gelatin cultures some days old, forming brick-yellow masses such as may be seen occasionally on the buccal surface of teeth which are not kept well cleaned.

On potato they appear bright yellow. Nos. 10 and 13 give the gelatin for a space 1 cm. in diameter around the colony a grass-green tinge. I doubt very much whether either of these organisms has anything to do with the production of green stain, all my attempts to isolate a chromogenic fungus directly from green stain having thus far failed. Cultures of some of these fungi were made on dentine and enamel. Sections of dentine, when decalcified, neutralized, and soaked in saliva and sugar, formed, when kept in a perfectly damp cell, a medium on which a considerable development took place, microtome sections of the dentine after two weeks showing a destruction of substance at the point of inoculation.

Fig. 432.

On sections of normal dentine the fungi in some cases appeared to maintain an existence until the organic matter exposed upon the surface of the section was consumed, after which the development ceased, while normal enamel, as might have been expected, formed about as good a culture substratum as glass or porcelain.

A description of the cultures in milk, blood-serum, etc. is not necessary for our present purpose; also, experiments on animals have been made in too limited a number to lead to accurate results. It is very plain, however, that a study of the pathogenic character of twenty-two fungi is out of the question. No. 19, which possesses peculiar interest on account of its similarity to the cholera-bacillus, was tested on mice, guinea-pigs, and rabbits. A small quantity from a pure culture injected into the abdominal cavity of mice almost invariably caused death in a few hours. Guinea-pigs and rabbits have

Fig. 433.

thus far shown themselves proof against it even when large quantities were injected into the duodenum (the *ductus choledochus* not being ligated). Experiments were made with a number of antiseptics in addition to those given on page 810. Arsenious acid, contrary to the repeated statements of one of our journals, possesses an antiseptic power at least half as great as that of carbolic acid, and about twenty-five times greater than absolute alcohol. Chlorate of potassium, on the other hand, possesses scarcely any available power whatever. Peroxide of hydrogen proved to be particularly active.

Fig. 434.

The following practical conclusions appear to follow from the experiments above recorded:

1. A great majority of the fungi found in the human mouth are capable of producing acid from cane- or grape-sugar, and it is probable that, *with very few exceptions*, all can when the proper conditions are presented to them. In nearly all cases which have been examined with special reference to this question the acid has appeared to be lactic. The acetic-acid fermentation, which cannot go on at temperatures above 35° C. (Fluegge), is out of the question in the human mouth, nor is there as yet any proof of the presence of more than minute traces of butyric acid.

2. In non-fermentable substances the reaction will be found either neutral or alkaline, in some cases considerable quantities of ammonia and sulphuretted hydrogen being produced. If, therefore, a decomposing pulp is sealed up in a tooth, its reaction cannot be acid, and caries cannot take place in either the pulp-chamber or the root-canals.

3. Of considerable interest is the fact that the same fungus may produce an acid reaction in one substratum and an alkaline in another. If, for example, No. 19 (Fig. 439) be cultivated in certain neutral non-fermentable substances, an alkaline reaction will appear; if then sugar be added, the reaction will in a few hours change to acid. In such a case we undoubtedly have two distinct processes going on—first, the nutrition of the organism, accompanied by the appearance of alkaline products; and secondly, its fermentative action, accompanied by acid products. Ordinarily, the latter so outweigh the former that the resultant reaction will be acid. This is, however, by no means necessarily the case. On the other hand, conditions may readily be produced under which the resultant reaction will be neutral or alkaline, especially in the human mouth, where so many different fungi and so various conditions are present. In such a case the result would be to put a temporary check upon the advance of the decalcifying process—in other words, upon the caries itself. In the case of particularly foul-mouthed persons the foulness itself may become a preventive of caries.

Fig. 435.

Fig. 436.

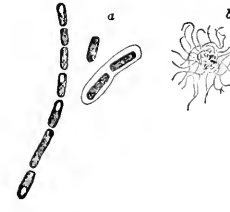

4. The possession of a peptonizing action by a large number of these fungi readily accounts for the solution of the decalcified dentine.[1]

5. Any one of these fungi which can produce acid by fermentation of carbohydrates or can dissolve the decalcified dentine may aid in the production of caries, while any one which combines both these properties—as many of them do—may alone bring about the phenomenon of dental caries. A solution of the dentine or enamel without previous decalcification cannot take place. The fact which I have so often affirmed, and which was denied by Milles and Underwood—that one continually meets with large tracts of softened, non-infected dentine—has been completely confirmed by Arkovy and Matrai. They say: "The invasion extends, however, only to a certain depth, and only isolated tubules show a deeper invasion, sometimes to twice the depth, and reach the border of the normal dentine," the whole territory between the isolated tubules being free from invasion.

Fig. 437.

6. The comparative or complete independence of many of these organisms of the free access of air renders their propagation within the dentine or under fillings where softened, non-sterilized dentine has been left an easy matter.

Fig. 438.

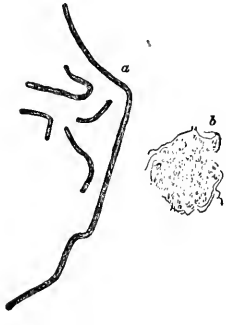

7. The fact that dentine and enamel form so exceedingly poor culture substrata for schizomycetes is an additional proof of the position that their attack upon the teeth is only secondary—*i. e.* they owe their rapid development to the secretions, deposits, etc. of the oral cavity; and not until the tissue of the tooth has undergone a certain change—first decalcification, second peptonization—can they adapt it to their nourishment. The decalcification is produced chiefly by acid resulting from the action of the organisms upon certain carbohydrates in the human mouth, while the peptonization is produced either by the direct action of the protoplasm of the organisms upon the decalcified dentine or by the action of a ferment which they produce.

Fig. 439.

A knowledge of the properties of the fungi of the human mouth, as

[1] Not a little confusion has been introduced by attempted artificial definitions of putrefaction and fermentation. The idea that every change in nitrogenous organic substances must be of the nature of putrefaction is particularly misleading. A ferment of the nature of pepsin which dissolves coagulated albumen is widely distributed among the fungi of fermentation as well as putrefaction, and the schizomycetes in general require nitrogenous substances in some shape for their nutrition. The dissolution of the organic portion of dentine is by no means dependent upon the presence of putrefactive organism, but may be accomplished equally well by fermentation. As previously stated, I never found a putrefactive organism in the deeper portions of carious dentine. Moreover, the acid reaction of carious dentine is highly unfavorable to the development of such organisms. I intend to repeat and extend my experiments on this point. The presence of putrefactive organisms, while it would accelerate the second stage of caries, could only retard the first.

given above, combined with a microscopic and chemical examination of carious tissue and comparative studies of caries of living and dead teeth, appear to me to furnish a fair solution of the phenomena of dental caries. That other agents than those of a parasitic nature are also often concerned there can be no doubt. To say nothing of predisposing causes, an acid reaction of the oral secretions, acid medicines, acid foods, etc. may give rise to caries at points which otherwise probably would have escaped.

PATHOLOGY OF THE DENTAL PULP.

By G. V. BLACK, M. D., D. D. S.

The dental pulp comprises the soft tissue that occupies the central cavity of the crown of the tooth and the canals in the roots to the apical foramen. It is thus divided into two portions—the coronal portion or bulb, which occupies the crown-cavity, and the canal portion, which occupies the roots or root-canals. Aside from this, the coronal portion has a projection of its tissue under each of the cusps of the tooth, as in the molars, which are called the *horns* of the pulp. These horns are often quite long and slender, especially in young teeth with long cusps. Generally, the form of the pulp corresponds pretty closely to that of the tooth, except that it is every way more slender.

The Tissue of the dental pulp is of the connective-tissue group, and supports an abundant supply of blood-vessels and nerves. Its mass is

Fig. 440.

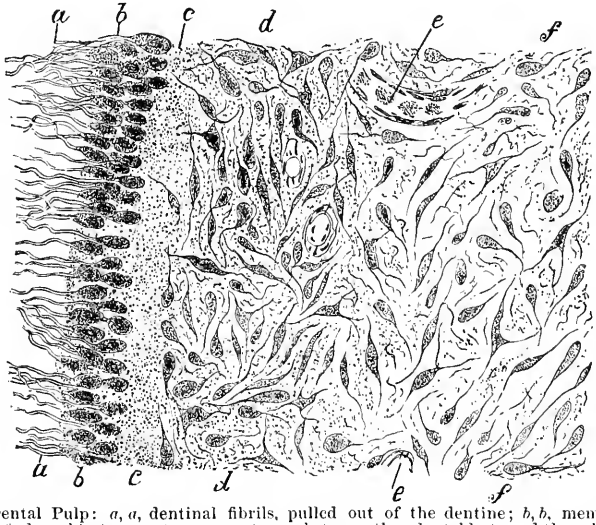

Margin of Dental Pulp: *a*, *a*, dentinal fibrils, pulled out of the dentine; *b*, *b*, membrana eboris or layer of odontoblasts; *c*, *c*, transparent zone between the odontoblasts and the cells of the pulp proper; *d*, *d*, layer of cells closely packed together; *e*, *e*, blood-vessels; *f*, *f*, cells less closely placed toward the central portions of the pulp (Wales' immersion $\frac{1}{10}$ in. objective).

made up of a semi-gelatinous matrix, which is quite thickly studded with cells, but these cells do not in themselves form a complete tissue, in that they are not placed in contact with each other. They are

imbedded in the gelatinous matrix, always a little apart from each other, even where most thickly set. The accompanying illustration (Fig. 440) gives a good idea of the pulp-tissue as seen with a high power in thin sections stained with hæmatoxylin. This is from the crown portion of the pulp, and in this the cells are set in no particular position relatively to each other, but seem to be placed as if by accident in every conceivable position. In the root portion this is different: the cells are there placed with their long axis parallel with the long axis of the canal; which arrangement gives the tissue quite a different appearance.

The Cells are generally spindle-shaped, with a delicate filament or process extending from either end. The form, however, varies considerably, especially in the coronal portion of the pulp. Some may be seen so delicate and slender that they seem but little else than a filament, while others are nearly round and much larger in their central part. Again, we meet with many cells, especially in the coronal portion, that have three and four filaments extending in as many directions. In the normal pulp these filaments are very slender and are lost in the gelatinous matrix. These, in all well-prepared sections, appear as minute threads in all parts of the tissue (as shown in the illustration).

The Distribution of the Cells varies considerably in different portions of the pulp. They are fewest in number in the central parts of the coronal portion. All around the periphery of the pulp, just a little inside the layer of odontoblasts, we find a zone that is much more thickly studded with cells (*d*). This is seen in all parts of the pulp periphery. Between this and the layer of odontoblasts there is a narrow zone that is usually almost or quite destitute of cells. In sections so prepared as to show them this is found to be occupied by a very fine plexus of nerves.

FIG. 441.

Odontoblasts clinging to a Fragment of Imperfectly-developed Dentine. The tissue was pulled away in mounting the section. The cells are drawn just as they lay distorted in the mounting, but a good idea is given of their true form (glycerin mounting, $\frac{1}{16}$th inch obj.).

The Odontoblasts form the periphery of the pulp, and lie in contact with the dentine (Fig. 440, *b*). As seen with hæmatoxylin staining, they seem to be flask-shaped cells with a process extending into the dentine, the fibrils of Tomes, or the dentinal fibrils. There is also a process extending from the pulpal end of the cell which does not take the stain and cannot be seen by this mode of preparation. In Fig. 441, I have shown these cells as they appear in plain unstained section, mounted in glycerin, with the one-sixteenth inch immersion objective. The cells are shown just as they happened to lie, without correcting any of the distortion caused by the mounting. In this section the odontoblasts seem to have been pulled off from the tisssue of the pulp in pressing down the cover-glass, and the fibrils are evidently somewhat stretched out of

the dentine; otherwise the drawing may be regarded as representing very closely the true form and relations of these cells to each other and to the dentine.

The Blood-vessels of the pulp are very numerous. In young teeth, the roots of which are not yet fully formed, there are usually a number of small arteries entering the pulp; but as the apical foramen becomes narrower these diminish in number, until finally there are not more than two or three, and in a very large number of cases only one. This divides and subdivides until the entire tissue of the pulp is filled with a network of capillaries, which is especially rich in the periphery of the organ immediately beneath the odontoblasts. Fig. 442 gives a good idea of this. The veins are usually a little larger than the arteries, and anastomose with each other very freely. The blood-vessels of the pulp are remarkable for the *thinness* of their walls—a fact that becomes very important in the study of its pathological conditions. The smaller veins are generally nothing more than the endothelial cells placed edge to edge or margin to margin. The arteries have a circular and a longitudinal layer of muscular fibres, but these are very thinly distributed.

FIG. 442.

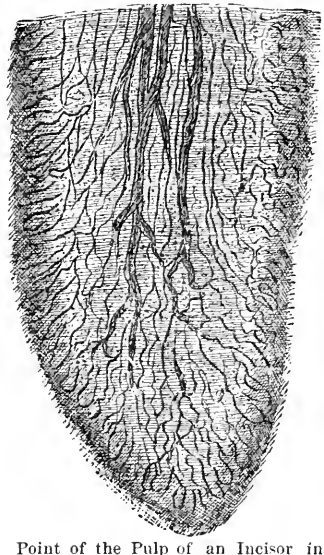

Point of the Pulp of an Incisor injected with Peale's blue to show the blood-vessels (× 25).

The Nerves of the Pulp enter the apical foramen usually in a single bundle, which breaks up but little in the canal portion of the pulp, but in the coronal subdivides in every direction to send filaments to the periphery. Immediately beneath the layer of odontoblasts there is a very delicate plexus of fine naked nerve-filaments. These are not well seen in sections stained with hæmatoxylin, but with chloride of gold or by treating with caustic potash, as recommended by Boll, they come into view.

This makes up, in brief, the sum of the pulp-tissue. The only element really peculiar to it is the odontoblast or dentine-forming cell. The tissue may be regarded as semi-fœtal in type; that is to say, it is a true connective tissue which seems not to have reached mature development. It is only occasionally in the root portion that we see the cells so placed in relation to each other as to form a tissue by their conjunction during the health of the organ. They seem to be simply imbedded in the gelatinous matrix, as is seen so markedly in the tissues of the fœtus. The gelatinous matrix contains no areolæ during the health of the organ, but, as we shall see, often becomes areolar in chronic hyperæmia and chronic inflammation of the pulp. The dental pulp seems to be destitute of lymphatics—a fact of considerable moment, as will be seen in the study of its pathology and symptomatology. With these points well in mind we are prepared to study the changes that occur in

the diseases of the pulp. But before proceeding to this it may be well to examine the *sensory functions* of the pulp, with the view of a better understanding of its symptomatology.

The Sensory Functions and Symptomatology of the Dental Pulp.

A proper understanding of the sensory functions of the dental pulp is so important to the correct interpretation of its symptomatology that it seems to me necessary to introduce here its consideration. It is generally and correctly considered that the physical function of the pulp is the formation of the dentine and the maintenance of its vitality. But aside from this the pulp has a special sensory function which is limited in the most remarkable manner, and which, so far as I am able at present to determine, has no parallel among the organs and tissues of the body. *This function consists in a peculiar resentment to thermal changes.*[1]

It requires both the pulp and peridental membrane to make up the sum of the sensory functions of the tooth. The sense of touch resides wholly in the peridental membrane, which receives the impression of even the slightest touch upon any part of the surface of the tooth. The pulp, on the other hand, has not the sense of touch. If it had, it is clear that it would not be able to exercise it in the normal condition of complete encasement within its dentinal chamber. It is completely shielded from contact with the outer world, and in this condition has no need for the sense of touch or the tactile sense. This is true also of the dentine. Indeed, the dentine derives its sensory function directly from the pulp through the fibrils of Tomes or dentinal fibrils, and, except that it is more limited, agrees in all respects with the pulp. The dental pulp responds very promptly to *injury*—not by means of a sense of touch, but by means of the sense of *pain*. There is a sharp distinction to be made between these two functions—a distinction having a special bearing upon the symptomatology of the organ. The tactile sense is a localizing sense. The sense of pain when standing alone is not a localizing sense. It may be said that the mind takes no cognizance of organs that have not the tactile sense. It does not follow that these organs fail to respond to injurious impressions through the sense of pain, though some organs, as the retina, have not even this property. Pain, however, is not accurately located by the mind without other aid than the mere sense of suffering. For instance, a patient can form no conception as to whether a painful sensation proceeds from the stomach, the transverse colon, or other organ in the neighborhood, for the simple reason that these organs are destitute of the tactile sense. Patients, indeed, learn to associate certain pains with certain affections—as much, perhaps, by the qualities of the pains as by any sense of localization. This quality of localization is purely a matter of education and not a matter of special endowment. On the other hand, an injury to the surface of the body involving the skin is accurately located by the associa-

[1] This is spoken of in the introduction to the article on Diseases of the Peridental Membrane; but on account of its intrinsic importance, and a desire to make each article complete in itself, it will be treated here as if not mentioned elsewhere.

tion of the sense of pain with the tactile sense; and the more pronounced and acute the tactile sense of the part, the more precisely will a minute injury be located. Hence we find in practice that pain from injuries to the surface is correctly located by the patient whether he has the opportunity of individual inspection of the parts or not. This, as I have indicated, is not the case with internal parts that have not the tactile sense; and it is in disease of these parts that we have what is known as *reflected pain*. Reflected pain is a pain located by the mind of the patient at a distance, more or less great, from the seat of injury or disease by which it is caused. This is probably divisible into two qualities or kinds of reflection. In the one variety the pain is simply wrongly located by the mind; in the other the pain is actually induced in another place through a perversion of nervous function. Our meagre knowledge of the *modus operandi* of the production of pain renders the very accurate following of this subject extremely difficult; but when we see muscular contractions occurring in different parts of the body, the effect of disturbance of nervous function by local disease, it is reasonable to suppose that pain also may be thus produced. Indeed, these muscular contractions may be the source of reflected pains which are accurately located through what is known as the sixth or muscular sense. Much of the pain in the muscles of the back occurring in women in connection with disorders of the uterus is of this character. Pleurodynia may occur as an expression of disturbed nervous function, the result probably of intense tonic contraction of a few fibres of some one of the intercostal muscles, or it may be of isolated fibres of several of them. Much of what we know as reflected pain is, however, generally of a different character from these latter examples, and its mode of production is different. A patient complains of a persistent pain in the knee, and the surgeon recognizes it as a symptom of disease of the hip-joint. The cause of the pain is in the hip-joint, but the diseased tissue, being destitute of the tactile sense—indeed, in this case of any nerves of sense—the pain is wrongly referred by the mind of the patient. A patient has pain in and retraction of a testicle, and the surgeon will probably be suspicious of stone in the urinary bladder, and look for the other symptoms with which the presence of a calculus is usually associated. Another complains of a pain in the region of the scapula (shoulder-tip pain), from which the physician diagnoses disease of the liver. In inflammation of the iris the principal seat of pain is in the brow. In this manner we might go on indefinitely enumerating examples of reflected pain, and in every instance it will be found that the diseased organ is one that has not the tactile sense. The instances given are among the best known, and most constantly associated with the organs named, that occur in symptomatology, and serve to illustrate the general principles of the subject. But in very many instances there is no well-defined point at which pain is felt in diseases of a given internal organ. Pain may be felt at various points, and may be shifting from one point to another; may be in close proximity to the diseased organ or remote from it; may be slight or severe. For instance, in case of stone in the urinary bladder, besides radiating pains and the symptoms that have their seat in the neck of the bladder and urethra, "spasmodic con-

tractions in the rectum, vagina, testes, neighborhood of the kidneys, perineum, or thighs, burning sensations in the soles of the feet, in the heels, or in the elbows, may be present, occurring mostly in paroxysms" (Ziemssen).

I have spoken of reflected pain as the product of muscular contractions through perversion of nerve-function. There is another mode of the production of pain closely akin to this, which occurs through disturbance of the vaso-motor nerves, producing contractions or dilatations of the muscular coats of the arteries, thereby causing variations in the blood-supply to local parts or organs. In the following pages I give experimental proof of the association of intense pain with hyperæmia; and it seems to be conceded that local deprivation of blood (anæmia) is also a cause of pain, and to which form of disturbance are referred many of the types of so-called neuralgia.

The true office of symptomatology is the accurate observation, recording, and grouping of these reflected pains, so that the combined results of investigators will be of use to the practitioner in the determination of the ailments of his patients. It is to the general principles of this subject, as established in the field of general practice, that we must go for the basis on which to found our study of the symptomatology of the dental pulp. In order that this shall be of most service to us, we should first understand as accurately as possible the actual sensory functions of the organ in health. I have explained above that the dental pulp has not the tactile sense. In this respect it is a true internal organ, and as such its symptomatology must be studied.

The dental pulp manifests a very decided sensibility to thermal changes; not that it readily determines degrees of temperature or distinguishes heat from cold; in fact, the pulp, unaided by the nerves of other parts, as the lips, gums, and peridental membrane, seems incapable of so discriminating.

Experiment.—Select a normal tooth; one standing alone is to be preferred; adjust the rubber dam; then pack cotton or other non-conducting material around the neck of the tooth. When this is done apply another piece of rubber dam to the tooth over the cotton. About one-half of the crown may be left exposed after the second piece of rubber dam has been applied. Both pieces of rubber should be sufficiently large to allow water to be used with a syringe without danger of coming in contact with the patient's face or clothing, and between them napkins and cotton should be so placed that a very perfect non-conductor shall be formed. Any tooth may be used by placing the first piece of dam over three teeth, one on either side. When all is satisfactorily arranged and the patient's eyes are shielded, throw alternately a jet of ice-water and a jet of hot water on the exposed crown of the tooth. It will be found that the patient feels a sharp twinge of pain from the contact of each jet, but does not experience the sensation of heat or cold at all.

The teaching of this curious little experiment is of great importance in the study of the symptomatology of the dental pulp; normally, this sense of pain upon sudden changes of temperature is the only *sensation conveyed to the sensorium from this organ.* That sense by which we

recognize heat and cold is contributed by the lips and gums, but the pulp itself resents thermal change by the sense of pain. This general fact we see exemplified almost every day: a person taking a drink of ice-water, if not accustomed to it—and generally if he is—experiences a twinge of pain in the teeth: *this resentment to heat and cold is the special sense of the dental pulp; under normal conditions it has none other whatever.*

In diseases of organs having a special function the expressions of disease are exaggerated during the exercise of that function, and the case is generally made worse for the time. In affections of the uterus this is seen during the performance of the function of menstruation, and so on with other organs. With many organs of the body the performance of their peculiar function is necessary to the continued existence of the individual, and cannot be suspended; but in all cases where rest can be had without endangering the patient it seems to be the plain duty of the physician to secure it. The oculist should shield from the light an inflamed retina or iris, accompanied with photophobia, in order that the diseased tissue may have rest from the performance of its peculiar function. On the same principle, a diseased dental pulp should be shielded rigorously from thermal change. Indeed, it may be stated that a very large proportion of the difficulty that arises in the pulps of teeth under treatment is due to inattention to this one point. The careless handling of the burr or sand-paper disc may, simply from over-heat, instantly precipitate a condition of disease from which, as we shall see farther on, the pulp of the tooth will never recover.

In the symptomatology of the pulp of a tooth there are certain points, based on its structure and sensory functions, that are peculiar to it, as distinguished from the diseases of the peridental membrane and neighboring tissues, and are constant for all of its diseases. This being the case, it may be well to consider these peculiarities separately. We have already seen that the pulp is, in its symptomatology, an internal organ, and as such fails to locate its ailments. This is so marked a peculiarity, and has come to the notice of the observant specialist so frequently, that it need only be mentioned to be understood. Yet the full force of this proposition seems not to be appreciated. It may be stated that no one can locate with reasonable certainty a single diseased pulp among the teeth by the sensation of pain alone. When it is properly located it is done by other means. By the sensation alone the patient is generally able with certainty to refer the pain to a given side of the face, but nothing more. The more definite location of the pain is left to the chance notion of the patient, or is determined by some accompanying circumstance, as the existence of a cavity: a sudden pain is felt, and the tongue finds a crumb crowded into the cavity in a certain tooth; this occurring repeatedly, the location of the ailment becomes in this manner definitely and correctly fixed in the mind. In some such way as this most of the cases that present themselves for treatment are correctly located by the patient. But in any case in which the patient is left without some such guide the pain is more likely to be located wrongly than rightly; and especially if there exist circumstances calculated to lead the patient astray, he is very sure to err.

Recently I was called on by a lady who had for some days been suffering severely with a pulpitis. I found that before calling on me she had been to three practitioners, but failed to obtain relief, owing to the fact that she had located the pain in one tooth, while each of the dentists whom she had consulted had located it in another. The patient was certain she was right, and her advisers were equally sure that their diagnosis was correct, and in the disagreement nothing could be done for her relief. Upon examination I found that she referred the pain to a second molar that had recently been filled, and that the cause of trouble was in the first bicuspid, as shown by the temperature test. The patient imperatively demanded the removal of the offending molar. After trying in vain to explain to her her mistake, and finding that in her disturbed mental state the sacrifice of a tooth was the only possible way out of the difficulty, I seized a pair of forceps and removed the offending *bicuspid* before she was aware that I had "fastened on the wrong tooth," as she expressed it. The relief from pain which followed had the effect to bring her to her senses and to the admission that she "must have been mistaken as to the tooth;" but this required some days.

Cases of such absolute insanity as this are not very common, but cases of pain wrongly located are of very frequent occurrence. Some months ago I had a patient who for several weeks had suffered with recurring pain in the superior bicuspids of the right side. She had forced cotton saturated with some harmless nostrum between them for the relief of the pain until they stood apart one-eighth of an inch. The teeth were perfectly sound, and responded normally to the temperature test. The cause of pain was found in an exposed and hyperæmic pulp in the second lower molar of the same side, which had a carious cavity under the margin of the gum that had escaped the observation of the patient.

The pain in these cases is not always referred to the teeth. One of the most constant localities of reference is in the ear of the same side. It may, however, be referred to the temple, the infraorbital foramen, the malar prominence, the angle of the lower jaw, the side of the neck, and other localities more remote.

The teeth in these cases are never sore to the touch. Pressure, or even the stroke of an instrument, calls out nothing abnormal, but a dash of cold water upon the offending member will usually excite a vigorous paroxysm of pain.

In acute diseases of the dental pulp its sensitiveness to thermal changes is augmented, usually, to a very marked degree. In most cases this is the first symptom that attracts the attention of the patient, and is often present for some time before other symptoms are noticed; and even after the suffering becomes severe the paroxysms may occur only after exposure to thermal change. As a rule, any pain in the region of the face or ear that is markedly increased by filling the mouth with cold or warm water has its origin in disease of the pulp of a tooth. The most notable exceptions to this rule are to be found in some of the rarer types of neuralgia of the branches of the fifth pair of nerves in the form of *painful tic*, and in the earlier stages of apical pericementitis

caused by the expansion in the pulp-cavity of gas arising from decomposition of pulp-tissue, in which case warm water causes an increase of pain by increasing the expansion. In the later stages of acute disease as the pulp approaches a moribund condition its sensibility is lessened, and is finally lost.

The DIFFERENTIAL DIAGNOSIS between diseases of the dental pulp and the different forms of pericementitis is usually easily made out, if it is remembered that the peridental membrane is the organ of the tactile sense for the tooth. If the peridental membrane is inflamed, the tooth is sensitive to the touch, and is not sensitive to reasonable thermal changes; while in acute and painful diseases of the pulp the tooth is not sensitive to the touch, but is very sensitive to changes of temperature. Reflected or radiating pains do not occur in diseases of the peridental membrane without the presence of a tooth that is sore to the touch. In case of reflected pain from disease of the pulp the tooth is not sore to the touch.

In *Degenerations* of the dental pulp its sensibility to thermal change is generally markedly diminished. In some cases I have noticed that painful sensations came on some minutes after excitation by thermal change, as though the pulp was incapable of the usual quick response. This may be true even though the pulp is in a condition to cause very severe pain, and under these conditions I have thought that there was a greater tendency to reflected pain. In such cases unusual difficulty is encountered in the differential symptomatology between neuralgia and reflected pain from the dental pulp. The greater tendency to reflected pain in these cases is probably on account of the comparative insensibility of the pulp to local disturbances.

Dental Neuralgia is a form of the affection which has its immediate exciting cause in some disease of the dental pulp. This should not be confounded with the reflected pains spoken of above. In many cases, however, a differential diagnosis is difficult to arrive at, on account of the close similarity of the symptoms. Dental neuralgia very rarely, if ever, occurs in other than persons who are of what may be called a neuralgic diathesis; that is to say, disease of the dental pulp alone is not a sufficient cause of neuralgia, but in persons who, by virtue of their nervous constitution, are subjects of neuralgic affections, or in persons who, on account of malaria, anæmia, or other form of nervous depression or exhaustion, have temporarily come into a neuralgic condition, the irritation of a diseased pulp may be the exciting cause determining an attack in the branches of the fifth pair of nerves, or even in more remote parts. In making this statement the reflected pains of which I have spoken above are excluded. They do not properly come under the denomination of neuralgic affections, though they seem to have been widely recognized as such by members of the profession. It is rather to the credit of the scientific following of the symptomatology of disease, that many of the painful maladies heretofore regarded as neuralgic have been assigned names in accord with their true character. Still, after the exclusion of these forms of reflected pain cases occur now and then that undoubtedly present the characteristics of neuralgia. It seems that irritation of terminal nerves will slowly bring about an unusual excitability of the region supplied by the nerve-trunk from which the branch

involved in the irritation proceeds, and often of others in close sympathetic relation therewith. This is especially noted in the hyperæsthetic condition of the first branch of the fifth pair during painful diseases of the eye, and equally so in the second and third in diseases of the pulps of the teeth. This hyperæsthesia of the second and third is to be explained by the fact that both contribute to the nerve-supply of the teeth, and are thus brought into close relations with each other. Therefore in neuralgic conditions of the general system a peripheral irritation may inaugurate a true neuralgia. But while this is true, it must be remembered that the fifth pair of nerves is a frequent seat of neuralgia from causes entirely occult or remote from the teeth; and these may even affect the teeth themselves prominently. It will be seen, therefore, that I cannot go into the details of this subject without treating of the general subject of neuralgia, which would be out of place in this article.

However, those forms of the affection that arise in anæmic individuals from the irritation caused by a diseased tooth-pulp have usually certain peculiarities that serve in some degree to distinguish them from those that arise from causes more occult. These I will try to point out as they have appeared to me in practice.

Neuralgias of the fifth pair of nerves arising from occult causes or from irritation which is probably central or in the course of the nerve-trunk, usually affects one or the other of its three principal branches. This may be the first, second, or third, but the second or third is more frequently the seat of the affection than the first. The pain may apparently be located in the trunk of the nerve or in its terminal branches, and therefore may appear prominently on the skin. It is somewhat rarely that it is found affecting two of the branches of the fifth at the same time. In the forms of neuralgia that have as their exciting cause a diseased dental pulp, the pain is first felt in the second or third branch of the fifth pair, but very soon affects both, the pain alternating between the two, or there may be painful points referable to both at the same moment. The pain does not appear in the terminal branches or in the skin. After some time the pain manifests a peculiar tendency to pass down the side of the neck, and finally into the chest or arm of the affected side; and there is pain in the ear in a very large number of cases; which is not the case in neuralgia from other causes. Paroxysms of pain are liable to be excited by trifling circumstances, as in other forms of neuralgic affections, but more particularly by changes of temperature affecting the teeth, or they come on during eating or after meals. In some cases the recumbent position has seemed to increase the pain. But the most reliable symptom of this form of neuralgia is the fact that the disturbance of a particular tooth is sufficient to induce a paroxysm; not the rapping of the tooth with an instrument or any form of violence applied to the surface of the tooth, but the touching of the pulp with an instrument or sudden changes of temperature.

I have usually found this form of disease to be connected with the degenerations of the pulp described hereafter. Sometimes several cases have occurred that seemed to indicate a particular pathological condition of the organ, attended with a tendency to neuralgia, but further investi-

gation has again dispelled this idea, and now it seems to me fairly well settled that it is the condition of the patient that determines this form of pain, rather than the particular form of disease of the dental pulp by which it is excited. It appears, however, that neuralgia rarely results from acute affections of the pulp.

Swelling (that is apparent) is uniformly absent in the diseases of the dental pulp. In diseases of the peridental membrane swelling occurs uniformly, either in slight degree or extensively. Especially is there apt to be some swelling and tenderness of the lymphatics of the angles of the neck. This does not occur in any of the diseases of the dental pulp. The only instances in which I have noted exceptions to this rule have been in inflammations of the pulp in children, in teeth of which the roots were not yet fully developed, and consequently were still wide open at the apex. But even in these cases it is of rare occurrence. This fact is to be explained by the consideration of the anatomy of the parts, together with the theory of œdema and the cause of the swelling of the lymphatics in inflammatory diseases. In regard to the latter, it seems that in inflammations the tissue-changes are imperfectly performed, resulting in the formation of abnormal waste products which are taken up by the lymphatics. These cause swelling and tenderness of the first lymphatic glands at which they arrive in their course toward the central parts of the body. This being the case, it is clear that different inflammations will differ as to the amount of swelling they will cause in these glands, those of a septic character usually causing the most, for the reason, perhaps, that the poisonous products of micro-organisms are added to that produced by the abnormal tissue-changes. Thus a common "canker sore" on the mucous membrane will often cause more trouble to the glands in the angles of the neck, than an alveolar abscess. The principal reason why we have no lymphatic swellings in connection with inflammations of the dental pulp is probably to be found in the fact that the pulp has no lymphatics; therefore the altered products of inflammation are not removed by that system of vessels.

The absence of œdema in inflammations of the dental pulp is evidently owing to the confinement of the organ in its dentinal chamber, together with the absence of areolæ in its tissue. These two causes combine primarily to prevent the escape of the serum of the blood from the vessels, and secondarily to prevent its infiltrating the surrounding tissues. It cannot pass through the dentine, and in the normal condition the apical foramen is too narrow to allow of much escape by that route, especially as inflammation is for the most part confined to the bulb of the pulp at some distance from the apical foramen. For these reasons, any effusions that occur in the pulp are necessarily removed by the veins, if removed at all, and therefore do not cause swelling of contiguous parts. Ordinarily, the effusions must be very slight, for the simple reason that there is no space for their accommodation. That *swelling of the pulp occurs*, however, must be plain to every one who has noticed its protrusion into a cavity of decay through an orifice exposing its tissue.

In widespread diffusive inflammation or hyperæmia of the pulp there may be some effusion into the apical space, causing the tooth to be

lifted slightly in its socket, and giving symptoms resembling apical pericementitis. I have noted symptoms of this kind a few times in intense hyperæmia induced primarily by thermal changes; but it seems most likely, when all of the facts are considered, that these symptoms, when occurring in teeth with living pulps, are the result of some slight traumatic injury to the peridental membrane, such as would occur from inadvertently catching a hard substance between the teeth in mastication. At any rate, in the preparation of sections of the pulp I have as yet been unable in any instance to connect this class of symptoms with either inflammation or hyperæmia of the organ; and I have made a number of selections with this special end in view, but in each instance have found the pulp healthy. These results are contrary to my previous convictions. The only class of cases in which I have been able to demonstrate the existence of inflammatory products at the apical foramen have been those in which the pulp was almost wholly disorganized.

Hyperæmia of the Dental Pulp.

Hyperæmia of the dental pulp is probably the most important of its pathological conditions, for the reason that it is among the most common that the dentist has to combat, and for the fact that it so often terminates in the destruction of the organ. By the term hyperæmia is meant the over-filling of the vessels of the pulp with blood. This subject seems to have been in the past very generally overlooked by writers on dental pathology, probably on account of the difficulties of examination and discovery of the exact conditions at the moment of extraction. Heretofore, this condition has been studied subjectively for the most part; that is, symptoms have been depended upon to reflect the condition of the organ, and while hyperæmia has had recognition, it has usually been regarded as an accompaniment of the inflammatory process. This is a grave mistake: there is probably no organ or tissue in the body in which hyperæmia unaccompanied by other morbid process is so common or so dangerous to the tissue involved. For these reasons, together with the intrinsic importance of the subject, I have followed its study as closely as the limited time of a busy practitioner would allow, and since determining to write this treatise have taken pains to make a practical reinvestigation of the whole subject, for the purpose of the correction of any possible error of previous studies.

Before proceeding farther it may be well to give in some detail the modes of study that I have found best calculated to give correct information on this subject; and it may as well be said now that these plans of research apply to the study of all of the morbid processes of the organ, but more especially to hyperæmia. For the purposes of microscopic section the dental pulp furnishes but a small amount of tissue, and it will be seen at once that it cannot be handled for the purpose of preparation as can tissues that may be had in larger amounts. The efforts that have been made at decalcifying the tooth and afterward hardening, and then making sections of the pulp *in situ*, have not given satisfactory results—partly on account of the action of the acid upon the

pulp-tissue, and partly on account of the distortion of the tissues by shrinkage. Then, too, the blood in the vessels at the time of extraction has generally been lost. The question of retaining and displaying in microscopic section the natural injection occurred to me a number of years ago; and after some experiment I found it possible to do this in such a manner as to display the difference between the healthy and the hyperæmic pulp in very striking contrast. The first object to be accomplished in this study is to *capture the condition*, or, in other words, to be able finally to place the pulp in section under the lens with the vessels containing the blood just as they did at the moment the tooth was removed from the alveolus, at least without their having lost the red blood-globules. This process I will give very briefly.

When a suitable case is presented, first examine the condition of the tooth itself as seen in the mouth. Then obtain its history, the symptoms it has presented from the first painful impressions until the present. If the pain has been paroxysmal, find if possible what has been the disturbing cause that has ushered in the paroxysms, the duration of the paroxysms, the occurrence of soreness on closing the mouth, and, in short, a full history of the case. *The condition of the tooth at the moment of extraction, especially as to pain, is a matter of prime importance in this study.*

Now extract the tooth and drop it at once into Müller's fluid. It should not be handled nor disturbed in any way. It should lie in this fluid for at least one week, at the expiration of which time it will be found that the blood in the vessels has become so hard that it will not be displaced if carefully handled, and that the red globules have preserved their form perfectly, and will do so during the subsequent handling. After the expiration of this period the tooth should be cracked in the vise, as recommended by Salter. This is done by wrapping it in muslin and placing it in the jaws of a powerful vise (this should be so strong that there will be no springing together of the jaws on cracking the tooth, as that would be liable to crush the pulp), and bringing them together steadily until the tooth cracks open. If it is skilfully placed, the line of fracture will generally follow the long axis. Then place the tooth in clear, freshly-filtered Müller's fluid and carefully remove the pulp from its bed. In some instances the layer of odontoblasts will remain adherent to the walls of the pulp-chamber, in others they will remain with the pulp, and often the dentinal fibrils will be pulled out of the dentine to a considerable length. The pulp is now to be placed in a thin solution of gum arabic to which some gum camphor has been added to prevent mould. The strength of this solution is very important; *it should in no case be strong enough to float the pulp.* This should be the test of its strength. If the fluid be of greater specific gravity than the pulp, its tissue will shrink, otherwise not. The gum-arabic solution should now be slowly evaporated in any convenient way, so that it is not done too rapidly, to the consistence of very thick jelly. This should require three or four days, and it will be found that the impregnation of the pulp-tissue with the gum will keep even pace with the thickening of the solution, and that the tissue will remain at the bottom of the vessel. When the solution has become as thick as is con-

sistent with handling, the pulp should be taken up with as much mucilage as will conveniently adhere to it, and placed, in such a position as may be desirable for cutting, on a bit of fine cork, which is then floated on alcohol with the side on which the pulp is placed down. In from twelve to thirty-six hours, according to the amount and consistence of the mucilage, the surface will become hard from the abstraction of the water by the alcohol. It should not be allowed to become too hard or the tissue will be injured. A little experience and judgment will enable one to control this. When the drying has reached the right point, the tissue, cork, and all should be invested in the microtome in the proper position for cutting, using paraffin or other suitable substance for imbedding, and allowed to stand for twelve or twenty-four hours. The moisture remaining in the mass will by this time have become evenly distributed, so that it will be of equal consistence throughout. It should now be just hard enough to cut smoothly when kept wet with alcohol. If all has been properly done, it will be found that very fine sections can be made. Every particle of the tissue can be cut, and if desirable the sections can be numbered and examined in their order, and every part of the tissue brought under the lens. The sections may be mounted directly in glycerin without dissolving out the mucilage, and every cell retained in position, or the mucilage may be dissolved out in tepid water, and afterward the section may be stained or prepared in any way desirable, just as can those obtained by any other process; and it will be found that the blood will remain in all but the largest vessels.

For the illustration of this subject I have chosen sections stained with hæmatoxylin, except in a few cases which will be noted. This is done, not for the reason that this staining is thought better than any other, but rather for the sake of uniformity of illustration. In the study of any such subject the various modes of preparation should be employed.

Hyperæmia may occur in any degree, from a slight distension of the vessels of the pulp to an expansion that seems enormous, and, considering the close encasement of the organ in its dentinal envelope, almost inexplicable. The distension of the vessels is usually seen in the greatest degree in the bulb or coronal portion of the pulp, and is apt to be very unevenly distributed; but it is not uncommon to find the vessels of the whole of the bulb of the pulp greatly expanded and overfilled with blood. Fig. 443 represents a field from the margin of a section of the pulp of a tooth extracted during a severe paroxysm of pain, the vessels containing the natural injection except at some points, as at *c*, *c*, *c*, *c*, from which the coagulum has fallen in the handling of the section. This was a case of extreme sensitiveness to thermal changes, in which severe paroxysms of pain, lasting for an hour or more, were occasionally occurring, seemingly excited by very trivial changes of temperature. This condition had continued for several weeks. The tooth was much decayed, but the pulp was not actually exposed, though but a thin covering of dentine remained. The examination reveals no signs of inflammatory changes whatever. This I find common in those cases in which a pulp has become abnormally sensitive to thermal changes without exposure or irritation from external sources other than changes of temperature. This forms an important feature of the pathology of the

dental pulp, for the reason that its causes are so constantly present and their action augmented in every case of filling with metal. It is liable to occur in the pulp of any tooth, however sound and otherwise healthy.

Sensitiveness to thermal changes in a certain degree is, as has been explained above, the normal sensory function of the pulp. In each instance of the exercise of this function there is an unusual amount of

FIG. 443.

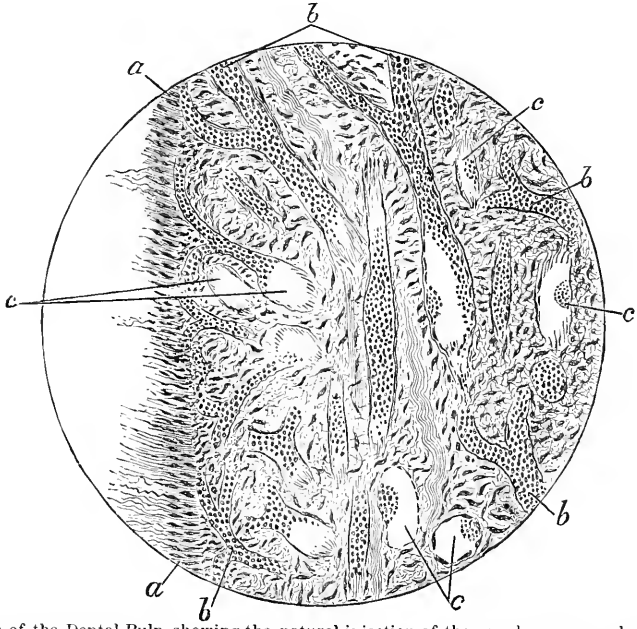

Hyperæmia of the Dental Pulp, showing the natural injection of the vessels: *a, a*, membrana eboris, or layer of odonoblasts; *b, b, b, b*, vessels distended with blood; *c, c, c, c*, points from which the blood has fallen in handling the section.

blood sent to the organ. This, when in a reasonable degree, is purely physiological—a temporary physiological hyperæmia which calls out a simple warning in the form of an unpleasant sensation, and immediately passes away. It is evident in this case that no injury results; but when this is repeated frequently with a degree of thermal change that is inordinate, the vessels finally fail to contract in a normal manner and remain overfilled with blood, and at the same time acquire an unusual degree of susceptibility to thermal influences, so that very slight changes produce great results. This is evidently in a large degree a nervous phenomenon. The tension of the blood-vessels, the degree of their contraction upon their contents, is under the control of the nerves of the vaso-motor system, and in the dental pulp these are prominently affected by thermal change in such a way that the vessels in some degree *let go their grasp on the blood* and expand passively before the pressure of the circulation. This condition becomes pathological when the part has become inordinately excitable by over-stimulation or the vessels fail to resume their normal tonicity after the momentary excitement has passed.

Irritation of the distal ends of the dentinal fibrils augments the susceptibility of the pulp to thermal changes, and in this way contributes to the development of the condition of hyperæmia. This is a matter of observation, or is based on the fact that very much the larger number of observed cases of hyperæmia are to be found in teeth in which the dentine is largely exposed by decay or some of the forms of abrasion. This can in part be explained by the fact that the covering of dentine is reduced in thickness, thereby contributing to the ease with which thermal changes may penetrate to the interior; but we are continually witnessing the rise of this condition in case of cavities that are so hidden away between the teeth that this cause cannot operate. In many of these cases there is actual exposure of the pulp with inflammation, but hyperæmia occurs repeatedly without exposure of the organ. It is evident, however, that this cause only renders the pulp more susceptible by increasing the excitability of its nerves. That this condition is by no means dependent on any lesion of the tooth for its origin is exemplified by its frequent occurrence in perfectly sound teeth.

The Pain in hyperæmia is sharp and lancinating, and paroxysmal in its character, especially in the earlier stages. It is usually referred to the teeth, though it very often happens that the patient is unable to refer it to a particular tooth or designates the wrong one. In case the pain has been slowly developed in a particular tooth without a cavity that has attracted the patient's attention, or in case there are many cavities in the teeth, it is very liable to be referred to any part of the distribution of the fifth pair of nerves, and may exhibit the peculiar changes of position so characteristic of some of the forms of facial neuralgia. The reference of the pain to the ear is very common. A close study of the symptoms will connect the beginning of the paroxysms with some form of thermal change. This sometimes requires more care in the inquiry than, from the nature of the case, would be expected. It often happens that a patient has insensibly learned so perfectly to shield the tooth from direct contact with cold water that he may drink ice-water with impunity even when a tooth is so sensitive to thermal change that a breath of cold air is sufficient to precipitate a severe paroxysm of pain, or the pain may come on shortly after drinking from the cooling of the contiguous parts. Patients have often told me that ice-water taken in the mouth did not cause pain, when on examination I have found that water twenty degrees lower in temperature than the blood thrown directly on the tooth would cause the most excruciating suffering. It is quite remarkable how perfectly some persons learn to shield their teeth from the effects of ice-water. Recently in conversation with a physician on this point he contended that thermal change did not affect his teeth any more than other tissues of his body; he could drink ice-water without any disagreeable sensation whatever, and had done so for years. I asked him to fill his mouth with ice-water and distend his cheeks with it; which he did at once. The result was a paroxysm of pain (described by him as "awful") which continued for some minutes. He had, as most people do who use ice-water, learned unconsciously to shield his teeth from contact with the water while in the act of drinking. This is the reason so many people come to us with hyperæmia of

the pulp and give a history in which pain from changes of temperature has no place. The painful tooth is actually shielded from contact with cold water unwittingly, but every breath of cold air affects it. This is markedly exemplified by the comfort afforded by completely covering in the affected tooth with a closely-fitting gutta-percha cap; which, I may add, is almost the sole treatment that I have employed in this condition for some years past. The point is simply to obtain *absolute rest* from thermal change until there is complete recovery of the normal tone of the vessels.

Tissue-change in hyperæmia unaccompanied by inflammation is confined to the walls of the vessels, and, so far as is yet determined, consists of a passive distension resulting from a semi-paralysis of the local action of the vaso-motor nerves of the part. This may be more or less complete, and the distension slight, or it may be very great. This distension may be recovered from very quickly, as is usually the case in the early stages of the affection, or as the case progresses recovery of the normal calibre of the vessels does not occur for days together, or possibly not at all. There is no change in the coats of the vessels that can be determined by microscopic investigation except the one of distension. This distension, as most commonly seen in well-prepared sections, is fairly represented in Fig. 444. This is from a case that had been subject to paroxysms of pain for some weeks, and was extracted during one of these. During the greater part of this time, however, it had remained free from pain. In some cases of a similar character—*i. e.* presenting similar symptoms, but extracted during the interval of quiet—nothing remarkable is presented; the veins in the bulb of the pulp may be abnormally large and contain more blood than usual, while the arteries will be almost or quite empty and the injection of the capillary system wanting. This difference is very striking when the sections of

FIG. 444.

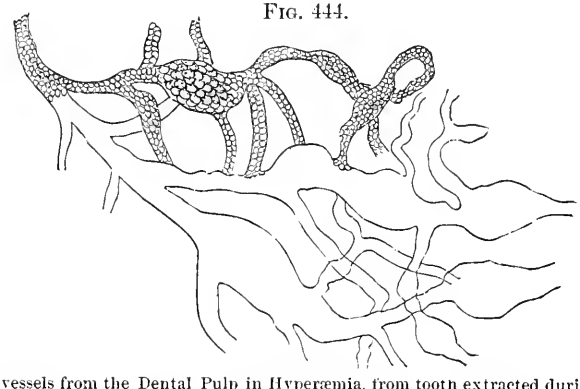

Dilated Blood-vessels from the Dental Pulp in Hyperæmia, from tooth extracted during a paroxysm of intense pain.

a number of pulps of known history are carefully compared, and shows the wonderful degree of recuperation from this condition of engorgement.

As the case progresses, the cause continuing to act at frequent intervals—*i. e.* in cases that present a history of frequent and very severe

pain, usually attributable to thermal changes—the blood-vessels lose their regular outline and become more or less varicose. In Fig. 444 I have represented quite a remarkable group of these varicosities as they appeared in the pulp of a tooth extracted during a paroxysm of pain. In my studies of this subject I have met with so large a number of cases presenting this varicose enlargement of the vessels that I must think it quite common. They occur in every possible form of contortion. Occasionally a vein will be seen presenting a peculiar nodulated appearance and seemingly crowded with blood-globules to the point of bursting, as shown in Fig. 445. In some instances single protuber-

FIG. 445.

A Small Vein from a Hyperæmic Pulp, greatly distended and nodulated.

ances will be seen upon the side of a vessel, as though it had been a weak point distended by force from within. Salter has noticed these aneurismal enlargements, but seems to have connected them with the sloughing or ulceration of the pulp; in which he is quite right, for I have also seen them in the position named by him. It seems to me quite curious that he had not also noticed this condition of the vessels separate from ulceration. In Fig. 446, I have copied his illustration.

FIG. 446.

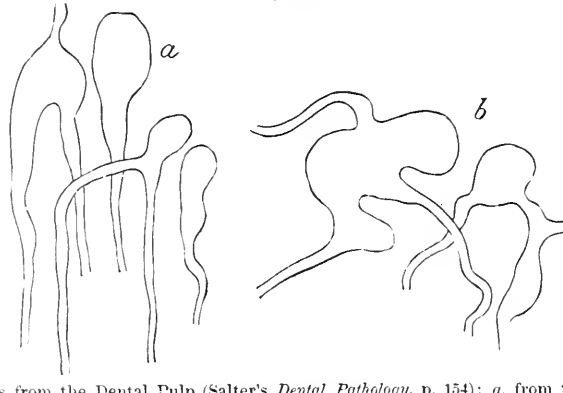

Dilated Vessels from the Dental Pulp (Salter's *Dental Pathology*, p. 154): *a*, from the root portion; *b*, from the coronal portion.

This is also an enlargement of paralyzed vessels, and certainly belongs to the condition of hyperæmia as associated with the inflammatory process, which will be presently considered.

This enlargement of the vessels is only the beginning of the story of hyperæmia. When the enlargement becomes excessive, and in some instances in which it does not seem so very great, another phenomenon presents itself. This is the migration of the red blood-corpuscles from the vessels, as in infarction, described in the article of this work on General Pathology, to which the reader is referred for the general principles involved in the subject. In the dental pulp, however, this is not by any means always a complete infarction, but the escape of blood-globules

here and there through the pulp-tissue, where the distension of vessels seems to be the greatest. This is often interspersed with what seem to be slight extravasations of blood. In Fig. 447 is presented an illustration of this taken from the pulp of a tooth which I extracted during a most intense paroxysm of pain that had been continuous for several hours: nearly the whole of the tissue of the bulb of the pulp contained red blood-corpuscles scattered through its substance. A large proportion of the veins were enormously enlarged, as shown at *a*, *a*, and splotches of red blood were seen at many points in the tissue, as shown at *b*, *b*, *b*. I have noted this condition in a considerable number of cases, and also have evidence in the remains of partly-absorbed clots in my sections that even this may be recovered from; at least, the condition of occasional extravasations. This lesion evidently leads, in many cases, to the complete infarction of the pulp, in which its tissue is entirely filled with red blood-globules, resulting in its destruction. It has not been my fortune to prepare sections of a pulp in a state of complete infarction, but I have no doubt that many of the sudden deaths of the pulp *en masse* occur in this way.

FIG. 447.

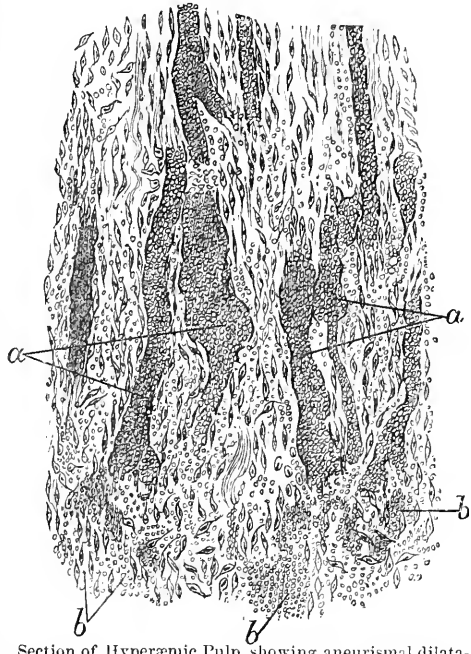

Section of Hyperæmic Pulp, showing aneurismal dilatations of the vessels, extravasations of blood, and red blood-discs escaped apparently by diapedesis: *a*, *a*, dilated vessels; *b*, *b*, *b*, extravasated blood. Besides this, red blood discs are plentifully distributed everywhere in the neighborhood of the veins. The tooth was extracted during a paroxysm of pain.

Hyperæmia leads to diffuse inflammation of the pulp whenever any considerable amount of red blood has escaped into the tissues; it is doubtful if it will occur before this. My own observations have not decided the point, but the experiments of Cohnheim seem conclusive in showing that inflammation does not result from the most extreme hyperæmia that can be induced by the paralysis of the vaso-motor nerves. In his experiments there was probably no extravasation of red blood to act as a nidus of the inflammatory movement. My observations seem to show conclusively that in almost every extravasation a mild form of inflammatory action is set up, by which new elements are thrown out which act the part of absorbents in the removal of the extravasated blood, and that in this way a general diffusive inflammation of the pulp may be brought about as a result of hyperæmia. In this way also diffusive inflammation of the pulp very often occurs without the exposure of the organ to any external irritation whatever.

The causes of hyperæmia have probably been sufficiently indicated by what has been said above. It should be added, however, that heat operates as powerfully in its production as cold, and that the dentist, by the careless use of the burr in the engine, but especially by the heating of the sand-paper disk in the finishing of fillings, is constantly liable to precipitate a condition of hyperæmia from which recovery is very difficult or impossible. Inordinate heating in this way operates powerfully to dilate the vessels of the pulp; and from the observations I have made I am confident that extravasations occasionally occur from this cause, resulting finally in the death of a pulp which at the time of the filling of the tooth was in good condition. I have noted these untoward results in my own practice and in that of others.

Inflammation of the Dental Pulp.

There is probably no tissue in the body in which inflammation, with its characteristic tissue-changes, can be studied in prepared sections to better advantage than in the dental pulp. This is owing chiefly to the fact that its cells are, comparatively, sparsely distributed in its matrix, and for this reason are not so much in the way of the observation of the inflammatory elements; then, too, the normal cells have so nearly the same general form and character that changes in them are easily noted. I think I may say that I have studied the characteristics of this process as it occurs in the dental pulp with more pleasure than in any other tissue. But, however interesting this phase of the subject may be, I must refer the reader to the article on General Pathology, where he will find it discussed in detail; here I will consider the subject only as it relates to the dental pulp.

Inflammation of the dental pulp has been discussed in some degree by almost every writer who has taken up the subject of dental pathology. It is therefore well known to the profession. There are, however, some conditions surrounding the pulp of a tooth which render inflammation of this organ peculiar in some of its phases, and which I wish especially to notice. One of these is the peculiar relation of the pulp to thermal changes, and the consequent augmentation of the inflammatory movement by the frequent exacerbations of the hyperæmia accompanying it. Most inflammations are accompanied by hyperæmia, and I know of no difference between the hyperæmia occurring as an accompaniment of inflammation and that occurring from other causes. It must be plain to every one that in an organ so prone to hyperæmia as is the dental pulp, and in which the blood-vessels are so liable to injury from this cause, inflammation will be more likely to assume a serious form than under other conditions. To this is added the fact that it is encased in solid walls of dentine, and is thus prevented from obtaining relief, as do other organs of the body, by swelling. For these reasons the dental pulp is more liable to destruction of tissue from the inflammatory process than other structures.

The rise of inflammation of the pulp of the tooth as a result of hyperæmia has already been sufficiently discussed, and need not occupy our attention now.

The chief causes of inflammation of the pulp of the teeth are, either exposure of the organ by decay, some one of the forms of abrasion, mechanical violence in the form of accident, or the operations of the dentist in the preparation of cavities and the insertion of fillings. Simple exposure of the pulp to the fluids of the mouth is usually sufficient to set up an inflammatory action at the point exposed; at least in my cuttings of the pulp I have found no case of complete exposure of the organ in which, on microscopic examination, the usual signs of inflammatory action were not present at the point of exposure This inflammation is, in many cases, limited to a very small amount of tissue; often to a very small portion at the immediate point of exposure. Inflammations that are strictly localized are very common. Occasionally, however, widespread inflammations are found which involve large portions of the pulp-tissue, but this is an exception to the general rule. Even in cases where the pulp is destroyed by the inflammatory process, it is usually accomplished little by little by the process of suppuration or ulceration, the invasion of the tissue showing a decided tendency to follow the course of the veins as they take their way toward its central parts and thence into the root portion, in such a way that the pulp is hollowed out, leaving its periphery intact until its blood-supply is cut off by the destruction of the vessels supplying it. In many of my sections this manner of invasion is very marked. If a tooth is extracted during a paroxysm of pain, inflammation of the pulp is almost uniformly accompanied by the signs of hyperæmia, they being present in a marked degree in the immediate neighborhood of the seat of inflammation; but if the tooth is removed during a period of quiet, the hyperæmia is limited to the vessels within the inflamed area. This is so constant that I am forced to the conclusion that the condition of pain depends very largely on the hyperæmia.

Wedl, Tomes, Salter, and Harris all speak of the very frequent occurrence of inflammation of the pulp before exposure of the organ. Much as I regret to differ with these gentlemen, to whom we owe so much of our present knowledge of dental pathology, my examinations have forced me to a different opinion. That inflammations do occur without exposure of the organ is no doubt true, as I have already indicated; but certainly the great mass of the cases occur coincidently with the exposure or afterward. If the pulp be examined by breaking open the tooth directly after extraction, and the existence of abnormal redness of its tissues or fulness of its vessels be regarded as evidence of inflammation, and this judgment be not corrected by careful preparation of the tissue for examination with reasonably high powers of the microscope, the cases of hyperæmia that I have described would all be regarded as cases of inflammation. From the fact of the general absence of any consideration of the subject of hyperæmia in the works mentioned, I suspect that this is the true explanation of the difference of opinion.

The tissue-changes due to inflammation are very easily followed in the dental pulp, especially in fine sections stained with hæmatoxylin or fuchsin. Other modes of preparation may be better for the determination of difficult points in the morbid process, but for the simple determination of its presence I know of no method superior to this. In

Fig. 448 I give an illustration, with a high power, taken from the margin of a field of inflammation, showing the inflammatory elements distributed among the normal tissue-cells. *a*, *a* point out the normal cells of the part; these are all more or less swollen, especially their pro-

Fig. 448.

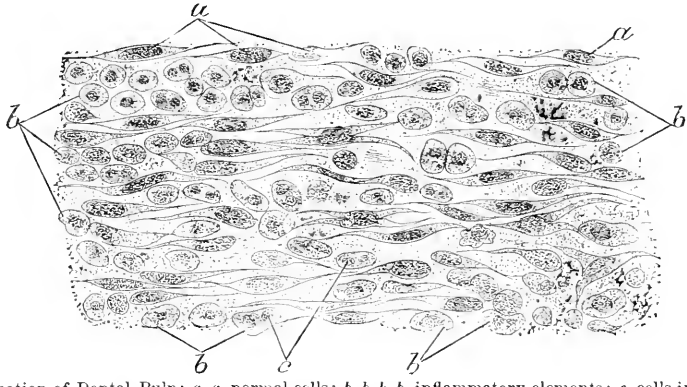

Inflammation of Dental Pulp: *a*, *a*, normal cells; *b*, *b*, *b*, *b*, inflammatory elements; *c*, cells in process of division ($\frac{1}{10}$ in.).

cesses. At *b*, *b*, *b*, *b* I have pointed out the inflammatory elements; these are leucocytes in the process of development and self-division, derived from the blood (white corpuscles) or from the rejuvenation of the original cells of the part. I have drawn the outline of each individual cell and its relation to its neighbors as perfectly as possible by aid of the camera lucida, and it will serve to show of what the inflammatory change consists, and how clearly it is seen by this mode of preparation.

As the inflammatory process proceeds, the normal cells of the part disappear and are replaced by the inflammatory elements, which are in fact young cells destined to develop and re-form the tissue, or degenerate and form pus, as they are more or less favorably placed. The mode of origin of these elements is discussed at length in the article on General Pathology. In some instances we may see in our sections, if not the actual diapedesis of the white globules from the veins, the results of this diapedesis in the most unmistakable manner. In Fig. 449 I give an illustration of this as it appears in a section of a pulp that seems to have been caught with the inflammatory process rapidly invading its substance. The illustration shows a group of distended veins at a point just before they enter the root portion of the pulp; and the tissue immediately around each of the veins is thickly studded

Fig. 449.

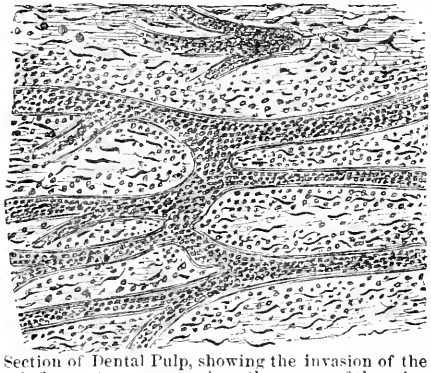

Section of Dental Pulp, showing the invasion of the inflammatory process along the course of the veins —the diapedesis of the white blood-corpuscles.

with leucocytes that have evidently escaped from the veins within a very short time before the extraction of the tooth. This part of the section resembles very much, except that the staining renders the cellular elements far more apparent, what is seen in the early stages of inflammation in the mesentery or web of the foot of the frog. In searching over sections of inflamed pulps I often see little islands of inflammation in the midst of apparently healthy tissue, as though a new nidus had been formed at a little distance from the point of irritation or exposure of the organ. It seems evident that these are occasionally the central points for the formation of those minute abscesses that are so often formed in the midst of the pulp-tissue. In Fig. 450 is given an illustration of one of these

FIG. 450.

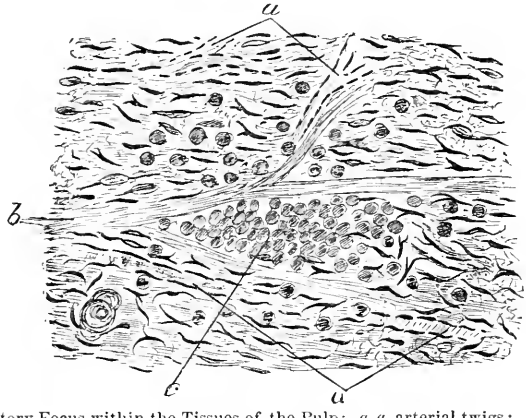

Minute Inflammatory Focus within the Tissues of the Pulp: *a*, *a*, arterial twigs; *b*, a nerve-bundle; *c*, collection of leucocytes.

—a very small one indeed, but one that cannot be mistaken. In this the inflammatory elements are very closely grouped together, with but few leucocytes scattered in the neighborhood. This is seen only occasionally in my sections. More frequently such islands of inflammation are seen in the diffusive inflammation that results from the condition of hyperæmia and slight extravasations of red blood. In these cases the tissue is apt to be stained with the coloring matter of the red blood-corpuscles that have been broken up in the process of absorption. I have made sections of a few pulps the tissues of which were thickly studded with these; and occasionally appearances indicate very certainly that extravasations have occurred at different times, some being advanced in the process of absorption, and others being comparatively fresh.

This breaking up of the red blood-corpuscles—or, rather the effect of it—has been noticed by several writers. When it occurs in large amount the coloring matter is absorbed into the dentinal fibrils, occasionally in such quantities as to give the dentine a red color, making it appear as though it were hyperæmic or as if the blood had really entered the dentine. This is most likely to be noticed about the junction of the enamel and cementum, where there is the least thickness covering the dentine from view. I think, however, that this redness of the dentine occurs oftenest after death of the pulp from infarction. In this case

there is a breaking up of the red blood-discs in the process of disintegration, and a large amount of coloring matter is set free in solution, and frequently will be found in the crystalline form in blood-clots. While in the state of solution this may enter the tubules in large amounts, and cause the discoloration of the entire dentine. In this case it is apt to be much blackened by the formation of the dark sulphurets, giving to the tooth a blue-black or even a black color, instead of a dark red.

I have seen but few cases in which there was a clear and unmistakable deposit of inflammatory lymph making space for itself within the pulp-chamber. One quite notable case occurred in the pulp of a second molar removed from a robust girl of fourteen years. This presented a history of a severe toothache, lasting for two days, two weeks previous to the time of extraction. The pulp was very slightly exposed from decay, and the deposit of lymph was in the neighborhood of this exposure, spreading over perhaps one-eighth of the surface of the pulp, and seemed to have been beneath the layer of odontoblasts. At least, it lay on the periphery of the pulp, and the odontoblasts were wanting; and it is fair to presume that they had adhered to the wall of the pulp-chamber when the pulp was removed from its bed—a thing that occurs in fully one-third of the cases in pulps that are fairly healthy. I cannot, therefore, assume that the odontoblasts had been destroyed, though they were certainly placed in a very unfavorable position. This pulp presented also evidences of previous extravasations of blood from hyperæmia. These deposits are occasionally seen within the tissues of the pulp in the form of islands, and usually seem remarkably free from cellular elements.

It seems to me that these facts show that the dental pulp has considerable power of recuperation from the inflammatory state. It is certain that moderate extravasations of blood are disposed of successfully, and that a considerable bulk, considering the size of the organ, of inflammatory lymph is tolerated without destroying it, and would undoubtedly be disposed of by the tissues if the case were placed under favorable conditions.

The symptoms of inflammation of the pulp cannot be very certainly differentiated from those of hyperæmia. It seems to me evident that in both cases the pain is for the most part dependent on the hyperæmia, and therefore very nearly the same line of symptoms are present. The pain in inflammation, however, is less paroxysmal or is more inclined to be continuous. The paroxysms continue for a longer time, and, instead of the pain ceasing, it is dull, heavy, and persists with more or less pertinacity. The pain, too, is much more liable to come on at night after retiring. It seems that in some instances the difference in the blood-pressure in the upright and the recumbent posture is sufficient to determine a state of pain by the greater expansion of the injured vessels in the inflamed tissue. It is probable that this may happen also when the vessels have been repeatedly injured by hyperæmic distension; but it is, I think, less liable to occur under such conditions. At all events, the differential diagnosis is in many cases very difficult to make out satisfactorily. I may say that in the cases that I have selected for making sections I have tried this very carefully for the purpose of

determining the differential symptomatology; but my success has not been such that I can speak very positively of any especial symptoms that are diagnostic. The general rule has been that I have found exposed pulps inflamed, whether there have been symptoms of any kind or not. (I do not mean here pulps covered by softened dentine that would be exposed in excavating, but pulps that are actually exposed to the fluids of the mouth.) I am satisfied that there are a great many cases in which exposed pulps become inflamed and go on to suppuration and the final destruction of the organ without presenting any symptoms whatever; indeed, it is by no means uncommon to find the pulp in a state of suppuration or ulceration in such cases. I am inclined to the opinion that inflammation without decided hyperæmia is not a painful affection. Certainly, it may destroy the pulp of the tooth without producing pain.

The causes of inflammation of the dental pulp seem to be, in most cases, external violence and the contact of the saliva. I have uniformly found the pulp inflamed if it had been so exposed that the saliva had had free access to it, whether it had presented any symptoms or not. It must be admitted, however, that the number of pulps obtained for examination, exposed but presenting no symptoms, have been comparatively limited. The part that micro-organisms play in the production of inflammation of the pulp is uncertain, but, all things considered, I have been inclined to the opinion that it is a very important one. Still, in my microscopic examinations I have not yet been able to find the tissues of the pulp invaded by them; possibly this may be the result of faulty manipulation, yet the same processes that I have used successfully in other situations have failed to reveal them here. They are plentiful, however, in the pus from suppurating pulps, and undoubtedly their waste products have much to do with the initiation of the inflammatory process.

Of the ability of the dental pulp, when placed in good hygienic conditions, to recover from inflammation, there can be no doubt whatever. The observed facts given in the previous pages fully warrant this statement, and it is also justified by clinical experience, judged in the light of microscopic investigation.

Suppuration of the Pulp

is of very frequent occurrence; indeed, it seems that the dental pulp is especially prone to suppuration when fully exposed to the fluids of the mouth. In the greater number of cases in which I have made careful examination superficial suppuration has been present; yet I have found a considerable number of cases in which the organ had evidently been widely exposed for a considerable time, and in which inflammation had made considerable progress, without any evidence of suppuration, and in which the layer of odontoblasts was still in position. Again, cases are found, and are by no means rare, in which suppuration has begun in the form of abscess within the substance of the pulp at a little distance from the exposed point. In the great majority of cases, however, the suppuration begins superficially, and the layer of odontoblasts at

the point of exposure is destroyed. In Fig. 451, *A*, I have represented in diagram a first molar with a proximal decay exposing the pulp. The darkened portion of the pulp at *b* shows the extent of the invasion of the pulp-tissue by the inflammatory process. In *B* is given an illustration of the tissue which I have taken from a central section, and which includes the most of the inflamed area. In this I have left the

FIG. 451.

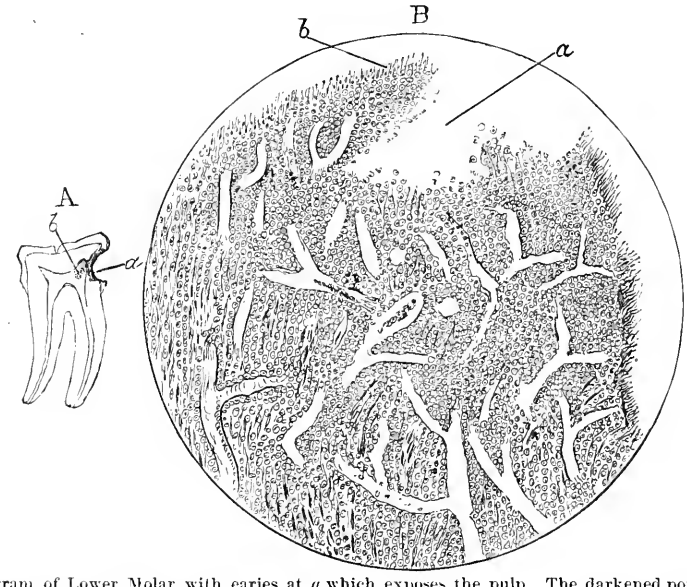

A, Diagram of Lower Molar, with caries at *a* which exposes the pulp. The darkened portion at *b* shows the extent of the inflammation. The rest of the organ was free from inflammatory change.
B, Illustration of the Inflamed Tissue, showing a part destroyed by suppuration at *a*. The odontoblasts are undermined at *b*. The blood-vessels which were filled with blood-clot in the section are left blank here, that they may be more apparent.

blood-vessels blank, that they may be more apparent, though in the section they are filled with clotted blood. It will be noted that in the greater part of the field the normal cells of the part have disappeared and given place to inflammatory elements, and that at the immediate point of exposure the odontoblasts are wanting, and the tissue has been invaded by the suppurative process forming a deep pocket in its substance. The undermining of the layer of odontoblasts at the point *b* is worthy of especial note (See Fig. 452 also.). This undermining of the odontoblasts occurs so often that I may say that it is the general rule in what may be called progressive suppuration of the pulp, which is the form that I have most generally found. Occasionally I have found suppuration—or more properly, perhaps, ulceration—following a very superficial inflammation, in which the tissue was apparently melting down into a sanious pus thickly inhabited by micro-organisms. In these instances there is a very superficial area of the tissue in which the blood seems to be clotted in the vessels, whether the tooth be extracted during a paroxysm of pain or not, and the melting down of the tissue is evidently on account of the deprivation of blood by this clotting pro-

cess, as has been suggested by Salter. It is probable that the micro-organisms, by the molecular changes which they produce in their life-processes, yield a material that determines this persistent clotting in the superficial capillaries, and in this way keep up the ulcerative process.

In most cases, however, as has been said, the invasion of the inflammation precedes the breaking down of the tissue in a much wider zone; and it is often seen to penetrate deeply into the substance of the pulp, following the direction of the veins. This tendency is well seen in Fig. 452, taken from a section of the pulp of a superior lateral incisor in which about one-fourth of the pulp at the coronal portion had been destroyed. This section also gives an excellent showing of the tendency to the undermining of the layer of odontoblasts. In this way the pulp is progressively destroyed from the point of exposure toward the apex of the root. In many cases this process is evidently in progress for many weeks together, during which time the suppuration alternates with efforts, always unsuccessful, at repair. In this way the pulp is destroyed, little by little, until only a small portion remains in the root-canal toward the apical portion. In other cases, however, the entire organ is destroyed at once by gangrene or infarction. That the pulp ever becomes cicatrized and capable of performing its functions after suppuration has been established I have no direct proof that is entirely satisfactory. In some clinical cases I have thought that this had been accomplished, but there is so much liability to error in these observations that this judgment must be taken with a considerable degree of allowance.

FIG. 452.

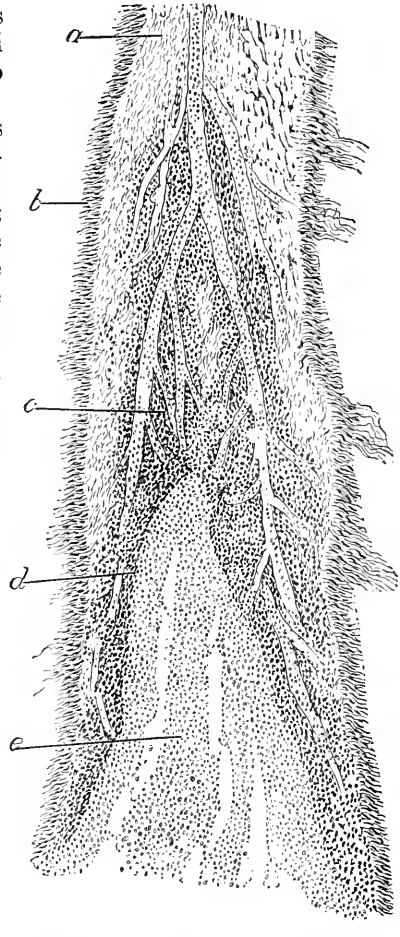

Progressive Suppuration of the Pulp of an Incisor: *a*, healthy tissue; *b*, odontoblast layer, or membrana eboris; *c*, inflamed tissue, in which the veins are seen to be dilated; *d*, line of demarcation of the suppurative process; *e*, pus.

A part of the crown portion of the pulp had been destroyed by suppuration, and in the remaining portion it will be noted how the pulp is hollowed out, the process pursuing the course of the veins and converging to the centre (× 100, reduced).

ABSCESS OF THE DENTAL PULP

is of frequent occurrence; and it seems to me probable that the suppurative process very often makes its beginnings in the form of a minute

abscess just within the layer of odontoblasts. These cells exhibit less disposition to change under the influence of inflammation than the other cells of the pulp, and I have often found them retaining their form and position when the tissue in immediate juxtaposition with them had been destroyed. Therefore, it seems probable that the first formations of pus would be retained behind them for a time in the form of a tiny abscess; at least, this is suggested by the facts observed.

Abscesses lying deeper in the tissue of the organ are seen to form by the aggregation of the inflammatory elements into a compact mass or little masses that lie near each other and run together in the process of increase. These cells, on account of the unfavorable conditions of their environment, degenerate into pus-cells, and the result is the formation of an abscess. Fig. 450 represents very fairly a beginning of the collection of inflammatory elements that might well serve as the nidus of an abscess if the conditions were unfavorable to their continued vitality. In Fig. 453 is given an illustration including about the half of a minute abscess that I discovered in the sections of the pulp of a central incisor about midway of its length. The coronal portion was suppurating, and the inflammation was rather more extended in its tissue than is common. I have seen abscess in the pulps of the molars much oftener than in the single-rooted teeth. Here it is not very uncommon to find several minute pockets of pus at a little distance from the point of exposure in cases in which the pulp has been exposed for a considerable period. When we note the swelling that usually accompanies the formation of an abscess in the soft parts, we can gain some idea of the destructive effect produced by the formation of an abscess in the tissue of the dental pulp, encased as it is in the dentine without the opportunity of obtaining the increased space necessary for the accommodation of the forming pus. This applies with the same force to the formation of pus on the surface of the organ when there is not a complete exposure that will allow of its escape, the formation of pus after a filling has been inserted, or under a capping. In any of these conditions, if the amount of pus formed is more than can find room, the compression and strangulation of the organ are inevitable; and I have every reason for believing that this form of strangulation and destruction of the pulp is not infrequent. This conclusion is based on the frequent finding of minute abscesses in the living pulp as prepared for microscopic exami-

FIG. 453.

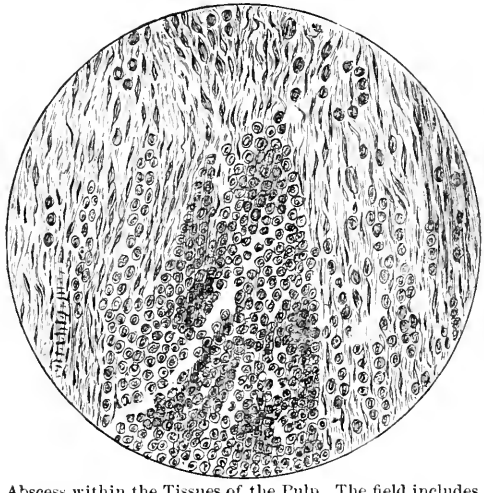

Abscess within the Tissues of the Pulp. The field includes about one-half of the little pocket of pus (× 250).

nation, the occasional discharge of minute quantities of pus from such abscesses by puncture, and also from the surface of the pulp after the removal of cappings, which I have noticed in practice, as well as the speedy relief from pain afforded by these operations.

The pain in abscess of the pulp is often very violent. It seems to arise differently from that occasioned by hyperæmia, in that the onset of the attack is not sudden and violent, but begins with a slight gnawing pain that persistently increases in severity, often until it becomes very intense. If relief is not obtained by the discharge of the pus in some direction, strangulation will sooner or later occur, the pain then ceasing. This, within from six to twenty-four hours, will probably be replaced by symptoms of apical pericementitis. Hyperæmia may of course be coincident with the formation of abscess and may mask its symptoms.

Small amounts of pus may be retained in the pulp-chamber indefinitely, and in this position may possibly undergo absorption. I have noted some instances in which it had undergone fatty degeneration, and seemed to be partially converted into an emulsion, as described by Salter. Under these circumstances gas is occasionally formed by a process of decomposition. Only a few days ago I was removing the pulp from a central incisor after it had lain in Müller's fluid for a week, and immediately on cracking the tooth I discovered in its tissue a cavity that contained a bubble of gas. Possibly this may have formed after placing it in the fluid, but the conditions for its formation must have been present before the extraction of the tooth, for they could not have arisen after it was placed in the fluid. Upon section of the pulp I found unmistakably that the gas-bubble was in an abscess-cavity. This is the only instance in which I have found evidence of the formation of gas within the living organ; and even in this I cannot say that the formation was not post-mortem. The generation of gas within the closed pulp-chamber, in which suppuration of the pulp is going on, undoubtedly takes place in some instances. In such cases warm liquids should increase the pain by expanding the gas, while cold would relieve it by the opposite effect.

Chronic Inflammaton of the Dental Pulp

may take any one of three forms. The more common forms are chronic inflammation with the continuous shedding of pus, which has been sufficiently described; chronic inflammation with the addition of new elements, or inflammatory hypertrophy; and chronic inflammation accompanied with degeneration of structure, or inflammatory degeneration.

No considerable hypertrophy of the pulp can occur while it is enclosed in a normal pulp-chamber, for the simple reason that there is no room for its expansion. In cases of exposure of the organ, however, a very considerable hypertrophy occasionally occurs, the new growth pushing out into the cavity of decay which has caused the exposure. This is seen as a fleshy mass in the carious cavity, and is often much greater in bulk than the pulp from which it has sprung. This growth does not all take place outside of the cavity, for there is often evidence in the arrangement of the tissue that shows us plainly that much of the

growth has taken place within the cavity, and has gradually been squeezed out through the opening. In other instances the growth seems to have occurred mostly at or without the orifice, exposing the pulp. In the greater number of the cases I have examined the growth seems to have been determined by the continual irritation of the tissue of the pulp by the sharp corners of the opening into the pulp-chamber. The growth itself is almost uniformly composed of granulation-tissue of rather a low type, which remains in a very primitive state. The accompanying illustration will give a good idea of this (Fig. 454).

FIG. 454.

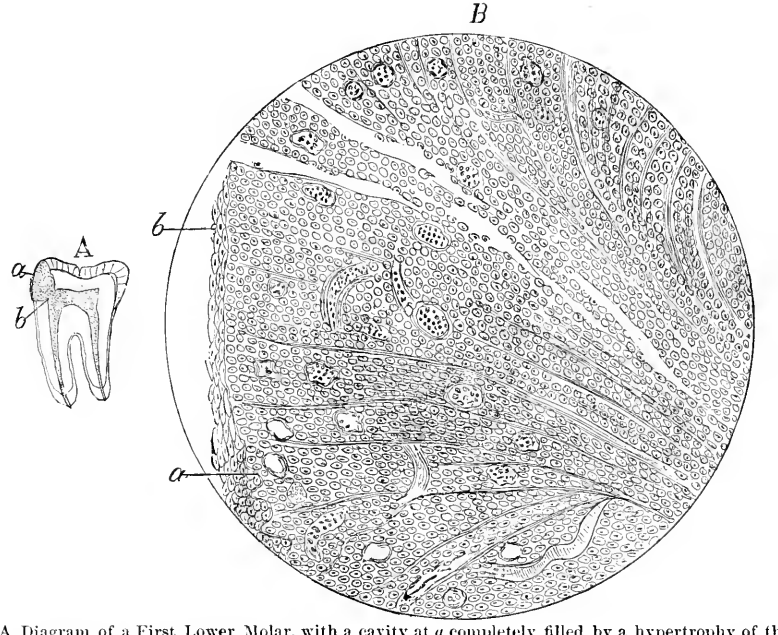

A, A Diagram of a First Lower Molar, with a cavity at *a* completely filled by a hypertrophy of the pulp, which has grown out through the orifice, exposing the pulp at *b*.
B, A Field illustrating the Tissue of the Growth, which is composed almost entirely of granulation-tissue of a very primitive type: *a*, a covering of epithelium presenting papillæ; *b*, epithelium apparently without papillæ.

Occasionally I have seen the tissue much more developed, approaching fibrous tissue in its structure. Many of these growths are covered on the exposed surface with the usual squamous epithelium of the mucous membrane of the mouth. This, evidently, has not developed from the tissues of the pulp, but is a transplantation from the epithelium of the adjacent gum, which has occurred after the fashion of skin-grafting. With the frequent abrasions that occur in the act of mastication I can readily understand how the epithelium could be transplanted, but I cannot understand how this form of epithelium could be developed from the tissues of the pulp. In a few instances such a growth has been known to become calcified. John Tomes[1] figures a case in which the pulp seems to have become somewhat hypertrophied after breakage of the crown of the tooth, and afterward to have become calcified. Heider

[1] *Dental Surgery*, p. 540.

and Wedl, in their eighth plate,[1] also give a figure of a similar case which occurred in an incisor tooth of the antelope. I have seen a very curious case of this kind occurring under a metallic capping. Some of the older members of the profession will remember that before the introduction of the cements there was a considerable effort to preserve the pulps of teeth by bridging over with thin plates of metal. Owing to a threatened alveolar abscess, it became necessary for me to remove a filling made by Dr. Isaiah Forbes of St. Louis, which the patient told me had had a capping of this kind in position for twelve years. The case was a lower wisdom tooth standing alone, with a very large amalgam filling occupying the anterior part of the crown. There was a little caries about its margin that enabled me to insert a point and pry the filling out *en masse*. This disclosed a large piece of gold plate which had been laid over an exposure of the pulp, leaving a considerable space between it and the bottom of the cavity. I was surprised to find this filled completely with what was evidently a calcification of the hypertrophied pulp, which had grown out and filled the space left under the capping. The mass was slightly movable, showing that it was not attached to the original dentine, but extended into the pulp-chamber in such a way that it was necessary to cut it to pieces to remove it. This form of calcification is evidently very rare.

Another result of inflammatory hypertrophy of the pulp—one that is very rarely seen, however—is the absorption of dentine from the inner walls of the pulp-chamber, causing its enlargement. I have never met with a case in which I had the opportunity of a systematic examination of this process, but in practice have seen several well-marked cases, and just now have under observation a first lower molar in which, on removal of the pulp, I found the whole of the floor of the pulp-chamber missing. Ten years ago, as my record shows, I capped a very ugly exposure in this tooth and made a large gold filling. For two or three years the pulp has been irritable, and I finally determined to remove it; and upon doing so found the pulp-chamber enormously enlarged, and that an opening to the peridental membrane between the roots had been formed. Another case was that of a central incisor in which the enlargement of the pulp-chamber was not so great, but was unmistakable.

Degeneration of the Structure of the Pulp

may occur from long-continued inflammation of a low grade. From my personal observations I should think that the tissue does not at any time become the seat of a high grade of inflammatory action; if so, the inflammatory elements must be removed by some process of degeneration and absorption. The original cells of the part also, for the most part, disappear or lose their nucleus, and become converted into very fine fibres. Areolæ develop in the matrix, and all the histological characters of the tissue are profoundly changed. Fig. 455 is given as an illustration of this, from a pulp thus affected in an extreme degree. These areolæ were evidently filled with fluid; hence a kind of œdema of the

[1] *Atlas of the Pathology of the Teeth.*

organ must have existed which in the enclosed pulp-chamber has probably gradually destroyed the cellular elements, and new elements thrown out in the inflammatory process have suffered the same fate. At any rate, those that are seen are all more or less shrivelled in appearance.

FIG. 455.

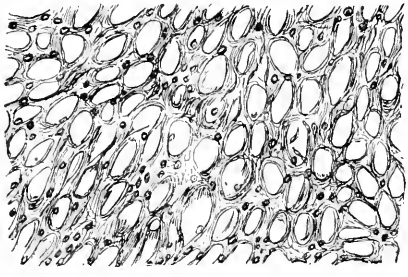

Chronic Inflammation of the Pulp, areolation, and degeneration.

This particular case was taken from the mouth of a young lady seventeen years old, and presented a history of rather severe pain at several different times during four or five months; it was "often uneasy." It had not given severe pain for two months before extraction. Cases are met with that present every possible grade of change, from the occasional appearance of areolæ to the complete areolation of large portions of the pulp, as shown in the illustration. But in the most extreme cases I have seen the areolation has not extended to the whole tissue. All grades will be found in the same pulp. The bulb suffers most, and often that part of the bulb nearest an exposure, while the rest of the organ seems to retain its tone more or less perfectly. How much hyperæmia may have to do in the production of this condition I cannot say. The evidence of œdema presented by the abnormal areolæ would indicate that the effusion was hyperæmic rather than inflammatory, but in all of these cases I have found the evidences of inflammatory action unmistakable.

My observations of this condition of the pulp lead me to the opinion that the sensibility of the organ is markedly diminished as this condition is developed. I have not, however, found a sufficient number of well-marked cases in the cuttings I have made to feel very certain of the symptomatology. From what I have seen I would suggest that this is probably the manner of the death of those pulps that we sometimes find dried up (mummified) in their chambers.

Deposits of Calcoglobulin

are found associated with inflammation in a considerable number of cases. I have not seen this deposit mentioned in any writings on this subject, yet it is so prominent that I fail to understand how it could have been overlooked. To my mind, this formation is associated with the formation of what are known as pulp-nodules. It possesses the same form of elements common to the pulp-nodule, including the forms of the calcospherite, but is soft enough to be readily cut with the knife in the preparation of sections, while the pulp-nodule is very hard. It has been present in a number of the pulps that I have cut, always in the inflamed portion, and usually near the point of exposure, often lying immediately beneath the layer of odontoblasts, but occasionally much deeper within the tissues of the pulp. It usually occurs in irregular masses, occasionally of considerable size; and scattered about

these there are generally a number of small globular forms, many of which have the onion-like layers of the calcospherite quite distinctly marked.

In Fig. 456 I give an illustration of one of these masses as it occurred in the pulp of a second molar from the mouth of a girl of fifteen years. About one-half of the coronal portion of the pulp was involved in inflammation, which, from the history of the case, must have been present for as much as two months, the tooth remaining quiet most of the time, but subject to paroxysms of pain lasting from a few moments to two or three hours. There were several such masses as the one represented in the pulp-tissue, all lying a little inside of the odontoblast layer and having globular forms in their mass or attached to their margins. In one part of the pulp there were a number of detached globules similar to those attached to the specimen shown. When mounted in glycerin, without staining, these masses are very transparent and show no color whatever. They stain an intense red with fuchsin, and are not bleached by immersion in alcohol for five or six hours. With hæmatoxylin they are stained blue or purple. Judging from the forms presented by these bodies, I suppose them to be calcoglobulin: I have not made the chemical examination that would be required to demonstrate this. They are entirely different from lymph-deposits, and do not show the reactions peculiar to amyloid deposits.

FIG. 456.

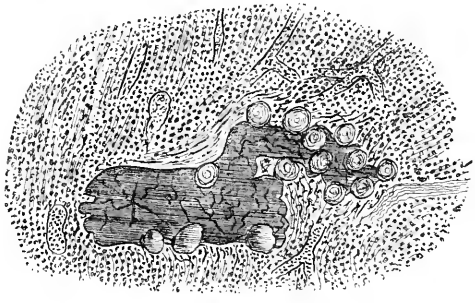

Deposit of Calcoglobulin within the Tissues of an Inflamed Pulp.

The idea that calcoglobulin is deposited in the pulps of teeth in the soft state has been arrived at with some difficulty, from the fact that it was known only as the basis of the pulp-nodule, the calcospherite, and perhaps of the dentine and bones, which remained after the solution of the lime salts with which it was originally combined. It thus forms the matrix of these bodies, and the assumption that this is calcoglobulin necessarily embraces the idea that the basis substance may be formed in the absence of sufficient lime salts for the complete calcification of the matrix. I know of no record of the accomplishment of this by artificial means, and certainly the subject needs further investigation.

The only situations of the natural—or, I might say, the pathological—formation of the calcospherite is in the dental pulp and in varicose veins. The formation of these bodies artificially seems to require the presence in solution of albumen, the salts of lime, and carbonic acid (carbon dioxide). When these materials are brought together in a tightly-stoppered bottle, calcospherites closely resembling those found in the dental pulp and in varicose veins are slowly deposited at the bottom. This subject has been very closely investigated by Rainie, Ord, Harting, and others, and the identity of the artificial forms with those found in the situations named seems well established. Now, the fact that these

bodies, called in this situation phlebolites or phleboliths, are found only in varicose veins where there is a condition of congestion or venous hyperæmia—in which cases, as is well known, there is a supersaturation of the blood with carbonic acid—seems to have an important bearing on the conditions of their formation wherever found. When there is venous congestion, as in the varicosities of the veins, the blood often becomes intensely venous, or, in other words, an unusual amount of carbonic acid has accumulated in it, and the blood may at the same time hold a sufficient quantity of the salts of lime. In this case we have the conditions found necessary for the formation of these bodies by the artificial process, and in the blood-vessels such locations are the only ones in which these bodies are found. This suggests the inference that in the dental pulp the formation of these bodies is dependent on a condition of congestion; which inference is strengthened by the finding of these soft forms only under the conditions of inflammation.

In this connection the question arises as to whether this soft form is the usual mode of origin of these bodies, they becoming more heavily impregnated with lime salts afterward. In favor of this idea is the statement made by most authors—and with which I concur—that in the growth of enamel and dentine there is a stratum constantly presented that has not acquired its full amount of lime salts, and is still comparatively soft. In the preparation of developing teeth I have often cut quite a little thickness of this without difficulty. Yet in all of my examinations I have never found a pulp-nodule in a soft shell or with a softer portion on the outside; and it seems to me that if the above were the true mode of their origin, I should have found this. This question has an important bearing on the subject of pathology as connected with the pulp-nodule. If these bodies are formed in the tissues of the pulp only under the conditions of venous congestion or inflammation, their presence has a signification that I had not attached to them. There can be no doubt but their presence in the pulps of teeth has some relation to irritation of the dentinal fibrils, for I have certainly found an increased number in the teeth of those who had suffered much from decay or abrasion, each of which exposes the fibrils to irritation.

The facts given above as to the mode of the formation of these bodies suggest the idea that calcoglobulin and the pulp-nodule originate in the veins of the pulp as a result of venous congestion or hyperæmia, and that the vessel is obliterated thereby; and it must be admitted that those conditions that are known to be favorable to the promotion of such congestions are the conditions under which we find the greatest number of pulp-nodules. I have, however, looked for evidences of their formation within the veins without success. Certainly, we find the congestions and the varicose veins, and most of these bodies have about them a condensation of tissue resembling in some degree a membrane; which fact has been noted by Wedl and a number of other writers. But I have not been able to make out in this any resemblance to the structure of the walls of the veins. Again, the forms of these bodies as seen in the dental pulp give no indication of their formation in the veins.

The Pulp-nodule may be found in any part of the pulp-tissue, but occurs mostly in the coronal portion or near the junction of this with the root portion. It is of irregular form, and in most specimens it is irregularly nodulated, as if made up of an aggregation of smaller nodules. In Fig. 457 is given a representation of one of these magnified (the true size being represented at *a*), which gives a good idea of the surface appearance of the mass. In respect to the nodulation there is the greatest variety, some specimens presenting a very smooth outline. These are usually the large ones, but even with these the nodulated surface is the rule. They are very hard, and are composed of the same material as the dentine, but have not the same structure. In Fig. 458 I have represented this as seen in section. The bodies made up of concentric rings are the calcospherites. These rarely make up any very considerable portion of the bulk of the nodule; indeed, I think they are as plentifully distributed in this section as in any that I have cut. The balance of the mass is made up of calcific material that shows no structure whatever, or may have some irregular lines or faults running through it without any definite arrangement. Usually, this is very clear and transparent, but a considerable number of specimens are irregularly clouded. These are not calcifications of the *tissue* of the pulp, but are formed in the *midst* of the tissue, making room for themselves by pushing the tissue aside, or, possibly, they may be formed in varicose veins, as suggested above. This distinction is important as dividing calcific degenerations of the pulp-tissue, in which the tissue itself is impregnated with lime salts, from the pulp-nodule. Both forms are found in the form of irregular bodies, and are not unfrequently associated in the same calcific deposit.

FIG. 457.

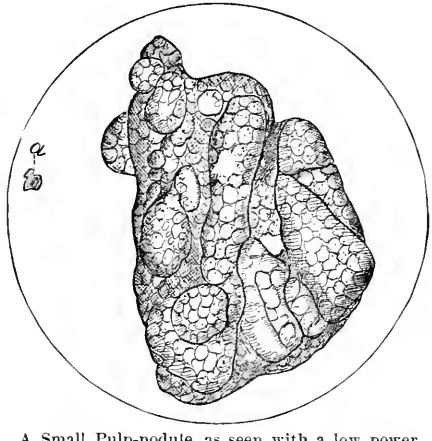

A Small Pulp-nodule, as seen with a low power, showing its nodulation: *a* represents the natural size (× 15).

FIG. 458.

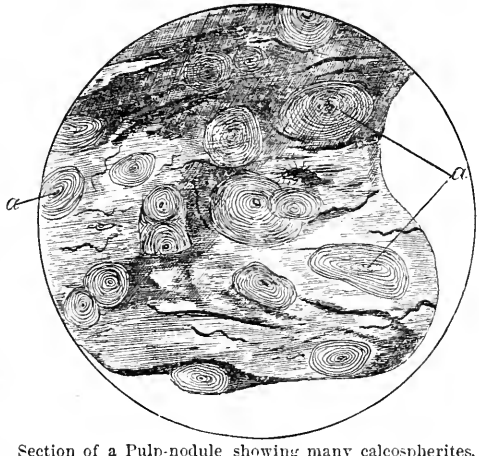

Section of a Pulp-nodule showing many calcospherites, as pointed out by *a*, *a*.

The nodules found in the root portion of the pulp are usually smoother

in their outline, and are much more likely to contain calcified tissues, than those found in the coronal portion. These are often associated with calcific degeneration of the pulp-tissue, which will be considered presently. In Fig. 459, I give an illustration of a group of these nodules.

FIG. 459.

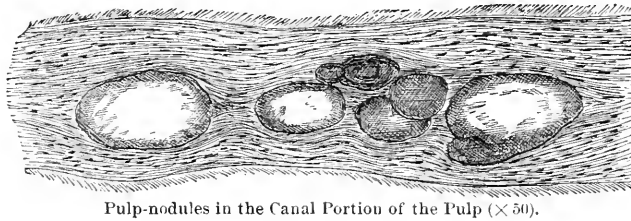

Pulp-nodules in the Canal Portion of the Pulp (×50).

There has been a disposition on the part of the profession to attach considerable importance to pulp-nodules in the pathological sense. After a very close investigation of the subject I cannot share this feeling. Whatever may be the circumstances attending their formation, they seem to do no injury after they are once formed; at least, that is the inference to which I am driven after a very large number of examinations of these bodies in teeth of known history. Carefully-conducted examinations show that they are more abundant in the teeth of the middle-aged and the old than in those of the young. They are also more plentiful in the teeth that have been worn by mastication or have suffered from any of the forms of abrasion than in others. In these cases the individual teeth that may have escaped the abrasion are about as liable to contain the nodules as the worn ones. I also find an increased number in teeth from mouths of persons that have suffered much from caries. Indeed, any circumstances that may expose the dentinal fibrils and subject them to irritation seem to contribute to the formation of pulp-nodules, not only in the teeth directly affected, but also in those that are not affected. Only a short time ago I selected four sound teeth, the enamel of which seemed very perfect (removed from the mouth of a woman twenty-five years old, the greater part of whose teeth had been destroyed by caries), and endeavored to make sections of them. Every part of the tissue was studded with these nodules to such an extent that I obtained but few sections good enough to display the condition of the tissue. These showed the tissue to be perfectly normal. In studying the pulps of teeth of known history I have been unable to find that those with pulp-nodules have given any peculiar symptoms or have given more pain than those without these bodies. It is, however, quite possible that these may occur of such size near the conjunction of the coronal and root portion of the pulp, or in the root portion, as to interfere with the circulation, and in this way contribute to the degeneration of the organ; or they may by their volume interfere with its functions.

HARD FORMATIONS WITHIN THE PULP-CHAMBER.

CLASSIFICATION.—A classification of the hard formations within the pulp-chamber seems desirable, yet it is doubtful if this can be done in a

perfectly satisfactory way at the present time; and, besides, it does not seem best to attempt to consider these entirely apart from the diseases of the soft parts, for the reason that the one seems in many cases to be directly dependent on the other. Some attempt at classification will, however, serve the purpose of simplifying description; I therefore give the following:

1st. *Secondary Dentine.*—A new growth of dentine more or less regular in formation, excited by abrasion, decay, or other injury, by which the dentinal fibrils are subjected to irritation at their distal ends.

2d. *Dentinal Tumor within the Pulp-chamber.*—An erratic growth of dentine into the pulp-chamber united to the wall by a pedicle. The structure is usually very irregular.

3d. *Nodular Calcifications among, but not of, the Tissues of the Pulp.*—These are the irregular nodulated masses so frequently seen either as very small stones or irregular masses. They contain many calcospherites. These were considered with the soft parts for the sake of convenience.

4th. *Interstitial Calcifications of the Tissues of the Pulp.*—This is the counterpart of calcifications elsewhere in the body, as in the arteries, etc.

5th. *Cylindrical Calcifications of the Pulp*, the tissues of which are probably in a state of fibrous degeneration. Usually seen in the pulp-canals.

6th. *Osteo-dentine.*—Erratic formations showing both the lacunæ of bone and dentinal tubes.

Calcospherites may be seen in connection with any of these. Many irregular formations are found that are scarcely assignable to any of these forms, and it is not unusual to find them intermixed with each other.

Secondary Dentine is the result of a new growth excited by some abnormal condition of, or injury to, the tooth. It is always deposited upon the walls of the pulp-chamber, and results in the reduction of its size. This must be distinguished from the normal growth of the dentine. In the young the pulp-chamber is comparatively very large, and diminishes in size for some time (which cannot be definitely stated) after the tooth has otherwise completed its growth or has attained the full form of its root and crown. This growth is continuous with the general structure of the dentine, without break or demarcation of any kind so long as it continues normal; but in case a new growth is excited by abnormal conditions there is generally a departure from the normal structure that distinguishes it sharply from the original dentine, and enables us to make out the original form of the pulp-chamber. This departure from the normal structure varies greatly in different cases. It is occasionally marked by a sharp curve or change in the direction of the tubules only, or there may be, and generally there is, a marked diminution of their numbers. Occasionally the sudden diminishing of the number of the tubules will be the only distinguishing mark, and in a very few instances I have seen what seemed to be a great reduction in the size of the chamber, that had occurred with such perfect regularity of structure as to leave no line of demarcation whatever; but this is rare. Generally there is a marked difference in the color of the new structure

as compared with the primary dentine, by which it is readily distinguished with the naked eye. This is seen in teeth that have been so worn by abrasion as to expose the new structure in the form of a yellowish spot which marks out the original form of the pulp-chamber.

The extent to which secondary dentine may be formed is a question of much importance. There seems to be a widespread opinion that the pulp-chamber may be obliterated by the formation of secondary dentine. This is an error. At least I know of no well-authenticated case of this kind. The secondary deposit seems to be limited within certain but not very definite bounds, which always stop short of the complete filling of the chamber. This deposit, as compared with the size of the pulp-cavity, is more extensive in the single-rooted teeth, as the incisors and cuspids, than in the molars. In the former it is not unusual to see considerable of the crown portion completely filled, so that the secondary formation will do good service in the protection of the pulp from exposure. In Fig. 460 is given an illustration of this as it is usually seen in the anterior teeth affected by abrasion. It will be noticed that the pulp-cavity is per-

FIG. 460.

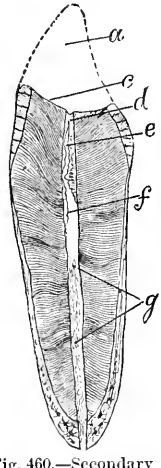

FIG. 461.

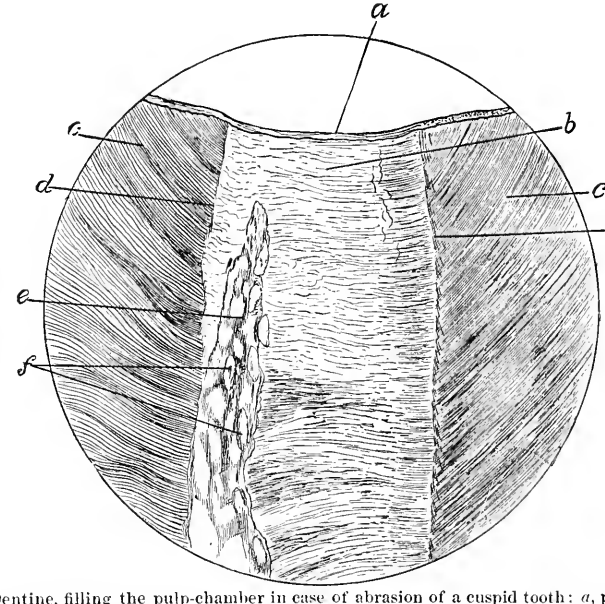

Fig. 460.—Secondary Dentine, filling the pulp-chamber in case of abrasion of a cuspid tooth: *a*, portion lost by abrasion; *c*, abraded surface; *d*, secondary dentine, filling a portion of the pulp-chamber, and acting as a protection to the pulp; *e*, slender point of the pulp; irregular deposits are seen on the walls of the pulp-chamber, as at *f*; *g*, cylindrical calcifications in the root portion of the pulp-chamber.

Fig. 461.—Secondary Dentine, from the same specimen as Fig. 460, magnified sufficiently to show the difference in primary and secondary tissue: *a*, abraded surface of crown; *b*, secondary dentine; *c*, primary dentine; *d*, junction of primary with secondary dentine; *e*, remains of pulp-tissue; *f*, small oval masses of calcific material.

fectly filled for only a very short distance in advance of the abrasion. This is more definitely shown in Fig. 461, from the same specimen, magnified sufficiently to show the structure as compared with the primary dentine. In this case it will be seen that the secondary formation

is fairly regular, but that the number of dentinal tubes is much diminished. This is quite the common form of secondary formations in the incisors and cuspids when they are slowly worn by attrition. This kind of formation is always limited, though some cases present much more of the secondary formation than others before the final degeneration and death of the pulp; which seems very certain to follow sooner or later, probably from exhaustion. In the root portion of this specimen (Fig. 460) there is an extensive deposit of cylindrical calcifications (to be described presently), which very surely mark the last performances of the organ.

In the pulps of the molar teeth affected by abrasion we find similar deposits of secondary dentine; but in this case there are certain peculiarities that deserve mention, especially as they are of importance in the clinical sense. In all of the double- or triple-rooted teeth there is a very distinct enlargement of the pulp in the coronal portion, from which the several root portions diverge into their canals. This forms the bulb of the pulp, which is absent in the single-rooted teeth. Now, in this case the formation of secondary dentine is confined almost exclusively to the bulb of the pulp, extending into the root portion very little, if at all, or, we may say, it is confined to the very orifice of these canals. Otherwise than this the deposit is very nearly uniform on all parts of the walls of the chamber, or if differences exist the deposit is least on the anterior and posterior walls and greatest on the floor and roof. In Fig. 462 I have accurately drawn the outline of a section of the crown of a superior molar abraded but slightly (though its associates were badly worn), for the purpose of illustrating the position of the secondary deposits as they are most generally seen in cases of extreme reduction of the size of the pulp. The lightly-shaded portion represents the original form and size of the chamber, and the dark shading that portion not filled by the secondary deposit. It will be noted in this case that the deposit is as great, or nearly so, rootwise from the remaining portion of the pulp, as that deposited next the crown; and in the one root which appears in the drawing the narrowing of the canal is confined to the portion originally within the pulp-chamber. So far as deposits of secondary dentine are concerned, this remains quite constant in all of my sections. In some cases the rootwise deposit is the greatest, but the difference is never very great. The narrowing of the root-canals within the original pulp-chamber is occasionally so extreme that it is difficult to get a broach through them; but the root-canal is usually about the normal size, provided always that there are no other hard formations except the secondary dentine. There are, however, occasional exceptions to this rule in which there is considerable

FIG. 462.

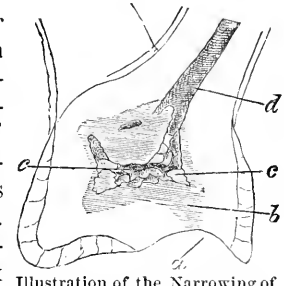

Illustration of the Narrowing of the Pulp-chamber in a Molar (superior) by the deposit of secondary dentine resulting from abrasion, showing the portions of the chamber in which the deposit usually occurs. The light-shaded portion (*b*) shows the original dimensions of the chamber, which in this instance seems to have been pretty large; *a*, a point of deep abrasion; *c*, *c*, remaining pulp-chamber, which is mostly filled with irregular masses; *d*, one of the root-canals. It will be observed that the narrowing of the root-canal is within the original pulp-chamber.

narrowing of the canals, but I have seen very few. In those cases in which the root-canal is obstructed I have generally found it to be with pulp-nodules, cylindrical calcifications, or general calcification of the tissues of the pulp. In Fig. 463, at *c*, *c*, there is a blocking of the

FIG. 463.

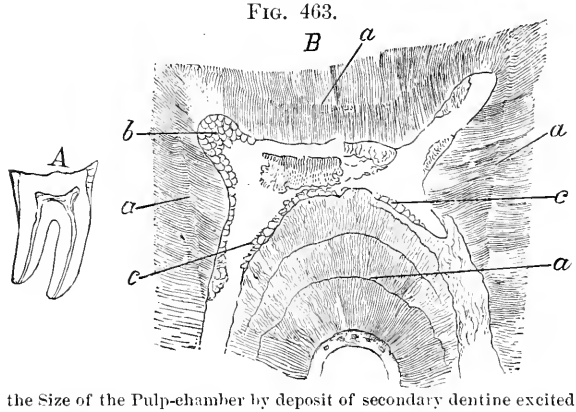

Reduction of the Size of the Pulp-chamber by deposit of secondary dentine excited by abrasion.

A, Diagram of a Lower Molar badly worn, showing narrowing of the pulp-chamber.

B, Illustration of the Tissue of the Secondary Deposit: *a*, *a*, *a*, *a*, outline of the original pulp-chamber, from which the secondary growth has begun; in the rootwise portion there appears a second line of beginning; *b*, globular dentine, in which a few dentinal tubes may be seen traversing the the globules; *c*, irregular crystalline deposits.

entrance to the root-canals by calcific deposits in the form of irregular crystalline masses. In this figure, at *A*, is represented a lower molar with the crown very much abraded by mastication, the pulp-cavity of which is very much reduced by the growth of secondary dentine. The lines *a*, *a*, *a*, *a* point out the original outlines of the pulp-chamber, and the new tissue formed is seen to be quite regular in its structure. The rootwise portion of the new formation shows two lines of the beginning of new growth, showing that there had been a cessation and rebeginning of the process. In passing I will call attention to the peculiar structure at *b*, in which a series of globules are seen to have a few dentinal tubes passing through them. Here the secondary growth has become markedly abnormal; and this abnormality is expressed in some form in almost every case in which the pulp has died from exhaustion following large deposits of secondary dentine.

It is found that these growths of secondary dentine caused by abrasion are not confined to the particular teeth worn, but if there is considerable wear of the teeth generally, those that may have escaped abrasion will have the growth of secondary dentine in very nearly the same degree as those that have actually suffered from the wear.

Growths of Secondary Dentine excited by Caries present some features that differ markedly from those excited by abrasion. As has been seen, deposits of secondary dentine excited by abrasions are very generally equally distributed on the inner walls of the pulp-chamber. In their structure and in the direction of their tubules they resemble very closely the normal dentine. In the study of secondary dentine the growth of which has been excited by the irritation of caries this is quite different in a large proportion of cases. The irritation is confined to a smaller

number of fibrils, and the new growth is very generally confined to a small part of the pulp-chamber immediately opposite the fibrils irritated —not generally, indeed, to the exact fibrils that are involved in the decay, but to that portion of the pulp-cavity. In Fig. 464 I give an

FIG. 464.

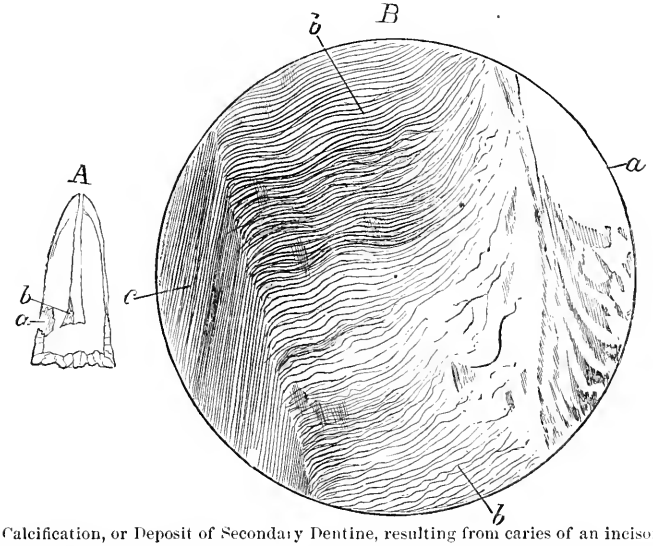

Calcification, or Deposit of Secondary Dentine, resulting from caries of an incisor.

A, Diagram of Section of Incisor, showing caries at *a*, and secondary dentine at *b*.
B, Illustration, magnified 200 diameters, to show the tissue of the secondary dentine: *a*, pulp-chamber; *b*, *b*, secondary dentine; *c*, primary dentine. It will be noticed that the dentinal tubes in the secondary dentine gradually disappear, giving place to a clear calcification.

illustration of this. At *A* is represented a section of a central incisor with a small dark decay in the proximal surface at *a*, and a growth of secondary dentine at *b*, which is confined to the side of the pulp-chamber toward the decayed point. At *B*, I give an illustration of the tissue of the new growth, in which it will be seen that there is a marked diversion of the tubules from the normal direction at the beginning of the new growth, and also that the tubules soon become irregular, and finally disappear, leaving the portion next to the pulp simply a clear calcification, showing that the pulp has degenerated and become incapable of the proper performance of its physiological functions—a sure precursor of its complete destruction. This tooth was from the mouth of a negro woman who came to me with an acute apical pericementitis. She was sure the tooth had not given her pain before the present attack. The pulp was not exposed, and no cause could be assigned for its death. I should say that in grinding the section I found that the pulp-chamber contained numerous calcific masses, which were lost, unfortunately, without their character having been ascertained. As there were many decayed teeth in the mouth, much of this may have been excited by sympathy. Yet the case illustrates very well the general nature of secondary dentine excited by decay. It is of medium type as to the regularity of structure, and the result is that which we may expect to follow in cases of consid-

erable secondary deposit—death of the pulp from degeneration of its structure.

In Fig. 465 is presented another case in which the exciting cause of the new growth was apparently about the same as that in Fig. 464. This case presented a history of hyperæmia from thermal changes. At *A* is given a diagram of the tooth considerably enlarged, showing the

FIG. 465.

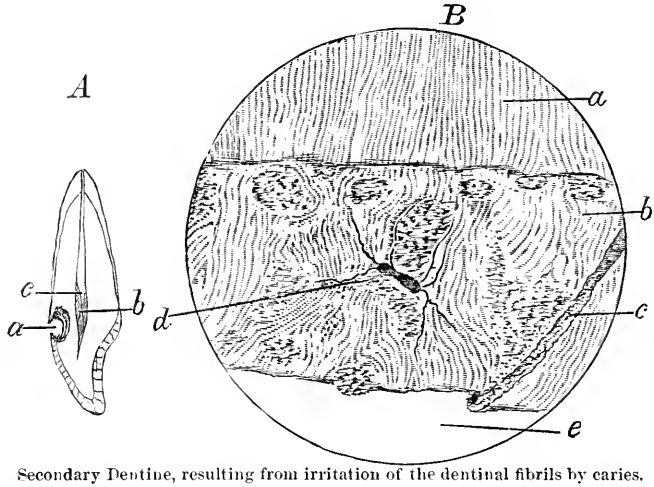

Secondary Dentine, resulting from irritation of the dentinal fibrils by caries.

A, Diagram of an Incisor having a decay in the labial surface, *a*, and a deposit of secondary dentine at *b*. The point from which the illustration *B* is taken is shown by *c*.

B, Illustration of the Tissue of the Secondary Deposit in *A*: *a*, primary dentine; *b*, secondary dentine; *c* seems to be a blood-vessel that has become calcified; *d*, an irregular fault having some resemblance to the lacunæ of bone: *e*, pulp-chamber. It will be noted that there are irregular deposits of granular matter in the substance of the secondary dentine, and that the tubules wind about them.

relative position of the decay and the growth of secondary dentine. *c* indicates the point from which the field *B* was taken. In this case the secondary formation was very irregular, and presented many fields of granular calcific material interspersed among the dentinal tubules. At *c* a blood-vessel seems to have been caught in the new growth, and has become calcified. At *d* there is a curious form resembling in some degree the lacunæ of bone, but I am inclined to the opinion that it is simply a fault. This case presents a curious specimen of irregular formation. If space permitted a great variety of these might be presented.

Fig. 466 is an illustration of a case in which the seondary formation has been excited by a very small decay on the labial surface of an incisor, and is confined almost entirely to the fibrils, the distal ends of which are irritated by the carious process. Such cases have been spoken of by a number of writers, but within my personal observation secondary dentine so strictly limited as this has been rare. It serves well to illustrate the fact recognized by most of those who have critically examined this subject, of the effect that is occasionally produced within the pulp-chamber by the irritation of the distal ends of the dentinal fibrils by the processes of caries. It must not be supposed, however, that such effects as those illustrated here or in other writings on this subject are uniformly

present in the pulp-chamber in cases of caries of the dentine. The facts are quite the reverse; and it is well that it is so, for, unless my observation is at fault, any very considerable deposits of secondary dentine mean exhaustion and degeneration of the pulp, followed finally by its complete destruction. In the search among decayed teeth for secondary dentine we may indeed find many examples and an indefinite variety of forms,

FIG. 466.

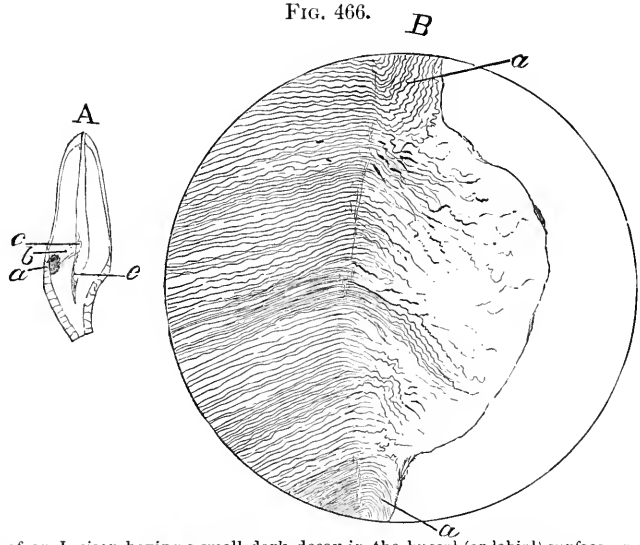

A, Section of an Incisor having a small dark decay in the buccal (or labial) surface: *a*, the tubules leading from this to the pulp-chamber are pointed out at *b*. At *c* a small deposit of irregular secondary dentine has occurred, which is seen magnified in *B*. The shading at *e* shows some secondary deposit along the wall of the pulp-chamber. The turning of the tubules away from the principal deposit, as shown at *a*, *a* in *B*, is very singular.

but the great majority of decayed teeth present no secondary formations. The circumstances that determine the formation of secondary dentine in the one case or fail to bring it about in another are by no means well known. My personal observations on this point seem to show that the greater number of these formations are found in connection with decays that have progressed very slowly, or, in other words, cases in which the dentinal fibrils have for a long time been continuously exposed to irritation. I have found them mostly in persons of middle age, though occasionally in those not yet past their teens. They are not, therefore, confined to any time of life, nor, so far as I am able to determine, to any peculiar condition of the teeth or the patient. I think they will be found oftener in cases in which the teeth have many cavities than in those in which the cavities are few. The teeth seem bound together by a bond of sympathy that is very marked, and any cause that produces a considerable effect upon one tooth has its effect upon all, often in a very great degree. This is seen most prominently, perhaps, in the secondary deposits excited by abrasions, in which all the pulps of the teeth suffer from the wear of a part of the number. But it is seen also in all of the diseases to which the teeth are subject. Decay that causes irritation with deposits of pulp-nodules in one tooth is certainly liable to

bring about similar results in the pulps of those otherwise unaffected. Inflammation of the pulp of a single tooth will induce hyperæsthesia of the pulps of the whole denture, etc. This is seen in other organs of the body as well. If one eye is seriously diseased, the other suffers from sympathy, and in certain pathological conditions oculists often extirpate one eye in order to save the other. The effect of one diseased tooth upon others is in every respect similar, though not so great in degree.

Dentinal Tumors within the Pulp-chamber are rare forms of the growth

FIG. 467.

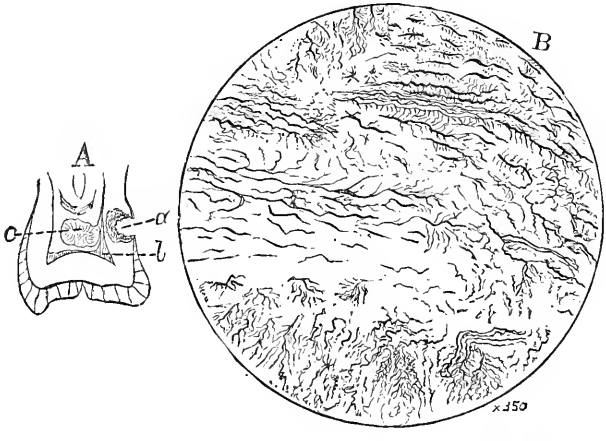

FIG. 468.

FIG. 469.

A, Section of an Upper Molar Tooth: *a*, a carious cavity; *b*, fairly regular secondary dentine; *c*, a dentinal tumor which has grown into the pulp-chamber, occupying the greater part of it. This was attached to the wall of the chamber by a rather narrow pedicle. The structure is extremely irregular, and varies much in its different parts. The section was saturated with balsam and ground thin and polished; afterward the balsam was dissolved out in turpentine, and it was then soaked in chloroform to remove the turpentine, and finally mounted dry.

B (Fig. 467) represents one field of view, and Figs. 468 and 469 two others. The tubules are quite remarkable for the large number of their branches and the irregularity of their direction.

of secondary dentine, in which a more or less considerable calcific mass is attached to the wall of the pulp-chamber by a pedicle. These growths are occasionally notable for the singular irregularity of their structure.

I have met with some very remarkable examples. One of these is represented in Figs. 467, 468, and 469. In Fig. 467, at *A*, is given a diagrammatic representation of a molar which had a small cavity in the anterior proximal surface. Opposite this there appears an ordinary growth of secondary dentine, pointed out by *b*; *c* is a large pediculated tumor arising from the growth of secondary dentine, and composed of the most extravagantly irregular dentine that has been my fortune to see. At *B* is given an illustration representing a field from this, and in Figs. 468 and 469 two more, which, taken together, illustrate the characteristics of the tissue very fairly. The illustrations will do more to convey a correct idea of the structure of this tumor than any verbal description that I am able to give. It is very transparent, except in some points where it is shaded by extremely fine tufts of tubules, as in some parts of each of the figures. These tufts form one of the prominent characteristics of the tissue, and appear here and there throughout its mass. These seem to unite in many places to form unusually large dentinal tubes, which, after pursuing a straight course for a short distance, are apt to be abruptly curved and lost, generally by passing out of the section, but sometimes seeming to end in blind extremities. There are also many very curious groupings of these tufts, as though odonto-

FIG. 470.

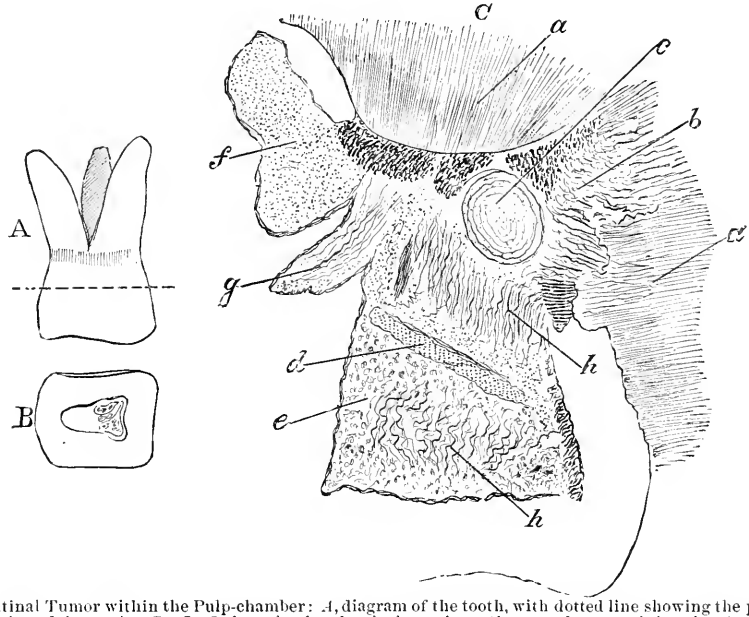

Dentinal Tumor within the Pulp-chamber: *A*, diagram of the tooth, with dotted line showing the position of the section *B*. In *B* the pulp-chamber is shown in section, nearly natural size, showing the tumor within. *C* is an illustration of the tissue of the tumor; *a*, *a*, the primary dentine; *b*, irregular tubules connecting the new growth with the primary dentine—most of these are very dark and irregular; *c*, a calcospherite included in the mass: *d*, apparently a blood-vessel calcified; *e*, calcified tissue; *f*, a finely granular mass; *g*, a spur of very transparent dentine. Dentinal tubules appear at *h*, *h*.

blasts, or at least dentinal fibrils, had originated at these localities. In some fields, of which Fig. 468 is an example, the tubules are very

sparsely distributed. In others they are quite thickly placed, or even crowded, as in Fig. 469. But the more general character is that of irregular grouping of the tubules with intervening clear spaces, as seen in *B*, Fig. 467. Now and then there are seeming faults filled in with very fine granular matter, one of which occurs in Fig. 468.

In Fig. 470 another case is illustrated, in which the new growth seems to consist partly of secondary dentine, which is intermixed with granular calcific material, calcified tissue, and calcospherite. These two specimens represent the extremes of tissue-formation occurring in these tumors. They are universally connected with the walls of the pulp-chamber by a pedicle, either narrow or broad, by which the dentinal tubes have passed into the tumor. It happens many times in the preparation of sections of these pathological growths that the pedicle is lost, giving the impression that the dentinal fibrils are developed within the tissues of the pulp. I cannot but regard this as an error. In every case in which I have had the proper opportunity for the examination of these masses presenting dentinal tubes they have sprung from the walls of the pulp-chamber, and some portion of the tubes are continuous with those of the primary dentine. And now I should regard the appearance of undoubted dentinal tubes in any mass within the pulp-chamber as a sufficient proof of that fact.

This form of tumor is confined exclusively to the pulp-chamber. I have never seen such a growth in the root portion. The causes which lead to the growth are evidently the same as those leading to formations of secondary dentine generally. What circumstances determine the erratic tumor-like form of the growth is entirely unknown. So far as the symptomatology is concerned, I know of no observations that throw any light whatever on the subject. The existence of the growth cannot be known until after the destruction of the organ, and its occurrence is so rare that we are not likely to obtain much light by having known the history of the chance cases discovered.

Calcifications of the Tissues of the Pulp are probably the most difficult of the problems presented in the consideration of the pathological formations within the pulp-chamber. Many specimens are presented which it is impossible to assign to any specific class, no matter how skilfully we may arrange our classification; yet in most of these cases we will find, if we have the proper opportunity of examination, that some part of the tissue is incorporated in the calcific mass, or so attached to it as to show that it is also undergoing the process of infiltration with lime salts. There are very few cases presented that show the form-elements of the tissue calcified in such a manner that it can be certainly identified; but after a large number of examinations with the object of determining this point, it is found that there are certain characteristic differences between these calcifications and the pulp-nodules that distinguish them with a considerable degree of certainty. They do not present the nodulated appearance of the pulp-nodules, but, on the other hand, have rather a regular outline with generally a smooth surface. When prominences are present, they are in the direction of the trend, as it may be called, of the tissue being calcified or the direction pursued by the blood-vessels of the part. The characteristics of the tissue,

if it may be so termed, will be discussed in connection with the illustrations.

Heretofore there seems to have been no effort to distinguish between these formations and the pulp-nodule. To my mind, the distinction is important in the pathological sense. The presence of a few pulp-nodules in a tooth is of very little significance so far as the future health of the pulp is concerned. We find no degeneration of the tissues of the pulp associated with them, unless, indeed, there are other causes of ill health of the organ. But tissue-calcification is uniformly associated with degeneration of the uncalcified tissues of the pulp. It is true that pulp-nodules may be seen in pulps that are rapidly undergoing the processes of degeneration, and may also be included within these calcifications. When once formed they do not disappear, and they will be connected with any diseased condition which may afterward overtake the organ. On the other hand, tissue-calcifications are never met with in healthy tissue.

In Fig. 471, I have illustrated a case of calcification which seems to include within it the form-elements of an inflamed pulp. At *A*, I have

FIG. 471.

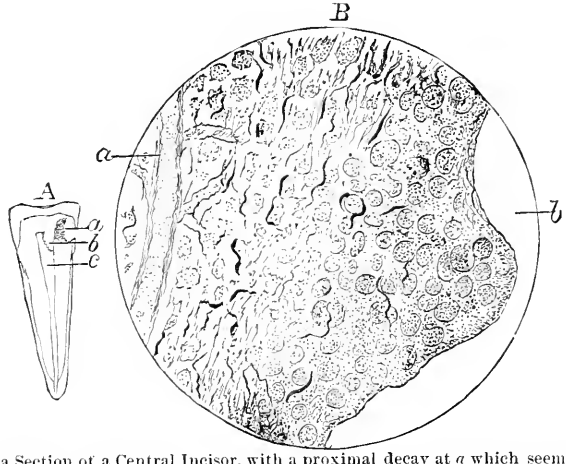

A, Diagram of a Section of a Central Incisor, with a proximal decay at *a* which seems to have penetrated the original pulp-chamber, but the opening is closed by a calcification at *b*. *c* marks the position of a detached mass of calcific material that was lost in mounting the section.
B, Illustration showing the Appearance of the Calcific Deposit. This seems to be a calcification of inflamed or cicatricial tissue. At *a* there is the appearance of a blood-vessel; *b*, pulp.

represented, diagrammatically, a central incisor with a proximal decay at *a* which opens the original pulp-cavity. This opening is closed by a calcific mass at *b*. At *c* there was a large elongated mass unattached to the walls of the pulp-chamber which was lost in mounting the section after it was ground At *B*, I give an illustration of a field of the mass *b* in *A*, in which the form-elements appear quite distinctly. At *a* there is the appearance of a blood-vessel with its branches. My supposition is that this calcification occurred after the exposure of the pulp by decay and inflammation of the pulp-tissue, and that for the time, no doubt, the pulp was protected. But in the formation of this protective

covering—or, we may say, primarily by the inflammation—processes of degeneration were inaugurated that resulted finally in the destruction of the organ.

Many calcifications of this order are found from time to time that are very large—as large, indeed, as the capacity of the pulp-chamber will allow. But the attachment of the mass to the walls of the pulp-chamber, as was the case in Fig. 471, is rather an exception to the rule. I have often seen these so perfectly fitting to the walls of the chamber in such cases that they appeared to be attached until I had ground a section. Fig. 472 is an illustration of a case of this character. At *A*, I

FIG. 472.

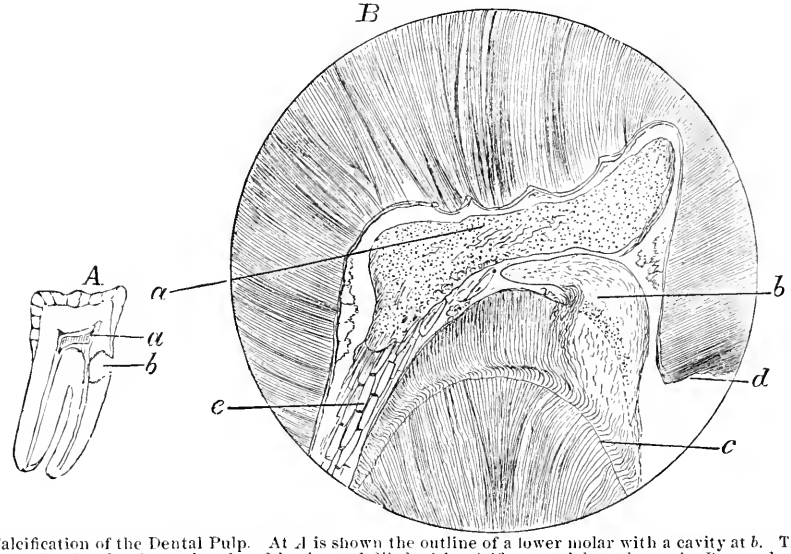

Calcification of the Dental Pulp. At *A* is shown the outline of a lower molar with a cavity at *b*. The pulp-chamber is much reduced in size and filled with calcific material, as shown in *B*. *a*, a large granular mass of calcific material, which is very transparent, but finely granular. A few very irregular lines are seen in the centre, which slightly resemble dentinal tubes; *b*, an erratic growth of irregularly formed and unusually transparent dentine; *c*, line of the growth of dentine from the floor of the pulp-chamber: the growth from other directions is so perfectly regular as to leave no markings; *d*, margin of the cavity of decay; *e*, a bundle of cylindrical forms of calcific material extending down into the root-canal. These extended to the apex of the root.

give an illustration showing a lower molar with a proximal decay at the junction of the enamel and cementum, exposing the pulp. In this case there has been a marked reduction in the size of the pulp-chamber by a secondary growth of dentine that is remarkable for its regularity, as will be seen by the inspection of the illustration of the tissue as shown in *B*. The line of the new growth is clearly marked in the rootwise portion at *c*, but in other directions there exists no demarcation whatever. At *b* there is a distinct dentinal tumor in the form of a spur having its base at *c*, where it springs from the rootwise portion of the original wall of the pulp-chamber, and its point turns in under the calcific deposit *a*. At *a* is a calcification that fills nearly the entire pulp-chamber. The mass is very clear and transparent, and presents a finely granular appearance, without any sign of structure except some irregular lines in its centre. With the low power with which the drawing was made these resemble

dentinal tubes, but with higher powers they are found to present characters which show them to be faults. At either extremity of the mass the degenerated tissue is apparent in the form of minute irregular threads which give these parts a clouded appearance. At the root-wise extremity it is connected with some cylindrical calcifications (*e*) which extend down into the root-canal.

These two illustrations may be regarded as exhibiting the extremes that appear in the study of this subject—the first showing most clearly the form-elements of the tissue calcified, and the last exhibiting the fewest traces. Generally, nothing can be clearly made out except some fine lines that seem to represent fibres that have persisted or the perverted forms of cells which seem to have escaped impregnation with lime salts. This may occur in groups, as I suppose, resulting in faults of irregular form, or single cells may remain, distorted perhaps beyond recognition. In some such way most of the tissue-calcifications possess a great diversity of markings of which nothing definite can be made by microscopic examination. In Fig. 473 is represented a field from a calcification

FIG. 473.

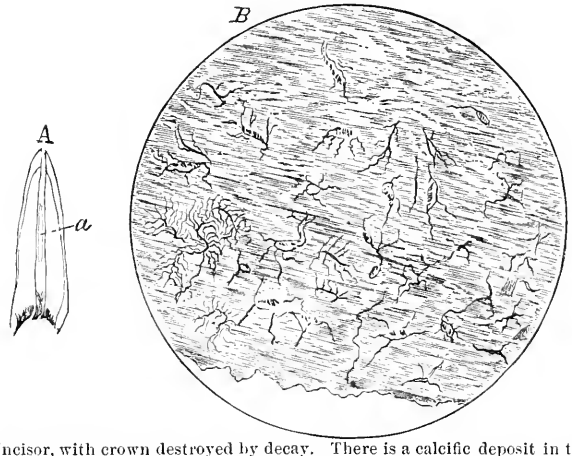

A, Outline of Incisor, with crown destroyed by decay. There is a calcific deposit in the root portion of the pulp-chamber $\frac{3}{8}$ inches long, pointed out by *a*.
B, Illustration showing the characters of the calcification. Some of the forms resemble somewhat the lacunæ of bone (× 350).

occurring detached from the dentinal walls in the root of a carious incisor. *A* is a diagram of the tooth, and the calcific mass was about half an inch in length, nearly filling the canal in the position pointed out by *a*. In *B* the peculiar markings are shown. The mass is very transparent, so that these forms are seen as clearly as if mounted alone. They have some resemblance to the lacunæ occurring in the cementum, and, while there might be a reasonable ground for difference of opinion, I suppose them to be faults formed by the persistence of tissue-cells that resisted calcification. A large portion of this mass presented no markings of any kind. Something of this class of fault occurs in almost every tissue-calcification, and the forms of them are as various as can be imagined.

The size and form of these masses vary indefinitely. They may be large enough to fill the pulp-chamber or they may be very minute. They are evidently formed very slowly, and may have their beginnings at several or many centres; and these separate pieces will coalesce as they enlarge in the same manner as is seen in the calcific plates that occasionally occur in the walls of the arteries. It would be interesting to know if there is any connection between this calcification in the dental pulp and in the arteries. I know of no observations in this direction.

Cylindrical Calcification is a peculiar form of interstitial calcification of the pulp occurring only in the root-canal, and is connected with the most marked degeneration of the tissues of the whole organ. At least I have not met with this form of calcification passing considerably into the coronal portion of the pulp in any case that I have examined. I present illustrations of this form in its varying degrees in Figs. 474,

FIG. 474.

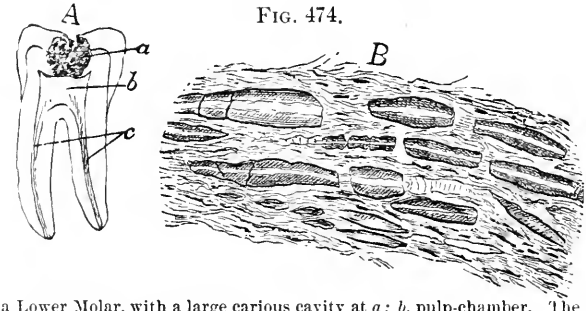

A, Outline of a Lower Molar, with a large carious cavity at *a*; *b*, pulp-chamber. The shaded portion, *c*, was occupied by cylindrical calcifications.
B, Illustration of the Cylindrical Calcifications (× 100).

475, 476. It occurs in patients of all ages, but perhaps is seen most frequently in middle-aged people who have suffered much from decay of the teeth or from abrasions. In the earlier stages of the process the calcific points are found within the tissues in very small cylinders or spindle-shaped masses too small to be seen with the naked eye. In this condition the pulp, when rolled in the fingers, will have a distinct gritty feeling, as if it contained particles of sand. It is difficult to make fine sections of such a pulp, for the reason that these hard grains will destroy the edge of the section knife. But when a section is had, it will be found that the cellular elements have mostly disappeared, or have lengthened out into slender spindle-cells to such an extent as to give the tissue a very distinct fibrous appearance; and lying parallel with these are found the little cylinders of calcific material, as seen in *B*, Fig. 474. At *A*, in the same figure, I give a diagram of the tooth, a lower molar with a large crown decay, from which the specimen was taken, in which the shaded portions of the pulp show the parts in which this form of calcification was found. This, I will say, agrees well with other cases that I have examined. In Fig. 475 the preparation was picked to pieces and spread out with needles, and it gives a better exhibition of the fibres seen in the tissue: it will be noticed in the fibres lying across the main trend of the tissue in the field how

the cylinders are attached to them by their ends. In picking these apart in the field of the microscope this is still more observable, and then it is found that each cylinder is firmly attached at either end to a little bundle of fibrous material; and it is hard to escape the conviction that these fibres are being infiltrated with lime salts. A pulp containing these calcifications will be distinctly stiffened, and may be bent about and will retain the curve given it like lead wire. Indeed, this is uniformly the condition of those pulps that seem stiff when removed by the broach.

FIG. 475.

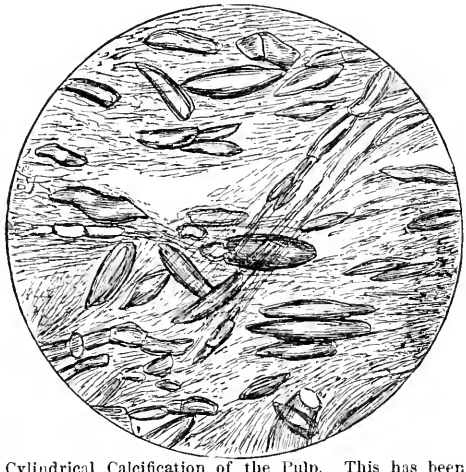

Cylindrical Calcification of the Pulp. This has been spread with needles, and the fibres that lay across the general trend show how the calcifications are attached at the end to the fibres. It will also be noticed that the tissue has lost its normal forms and degenerated into an irregular fibrous mass (× 100).

Fig. 476 represents an extreme degree of this form of calcification. Here is a more curious phenomenon still. The cylinders have grown and run together, but instead of coalescing end to end, forming rods, as might have been expected, they are irregularly jointed, and in the effort to pick these apart with needles it is found that these joints are held together quite firmly by fibres passing from the one to the other. In this condition the root portion of the pulp becomes very stiff; yet it may still be bent, and will retain its bent position like annealed wire. I do not think that this form of calcification ever runs together into a solid mass. It is evidently a distinct form, and dependent on a peculiar condition of the tissue of the pulp. I have seen

FIG. 476.

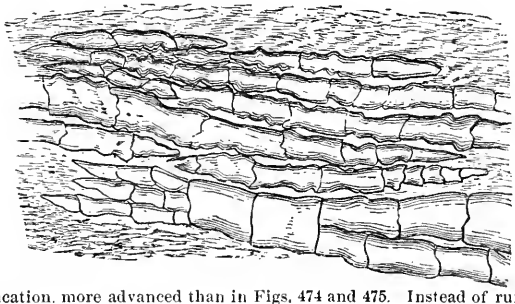

Cylindrical Calcification, more advanced than in Figs. 474 and 475. Instead of running together and forming a solid mass, they are irregularly jointed (× 100).

nothing in other parts of the body with which to compare it. We indeed find long, flattened calcifications in the arteries, but I have seen none with the distinctly jointed appearance shown in Fig. 476. What forces are in operation to produce these peculiar forms I am unable to say. I am

equally at a loss as to the symptomatology of this class of cases. I think there is no doubt that the death of the pulp follows closely in the wake of the calcification. Mr. Salter has also examined this form of calcification and described it in some detail. I agree with him in saying that "the whole of the tissues, cells, nuclei, connective tissue, blood-vessels, and multitudes of nerves, are swallowed up and obliterated in the calcific process." . . . . "The calcification is clearly not interstitial in the sense of being between the fibres," but the whole tissues are impregnated with the calcific material. They are not pushed aside, as in the formation of pulp-nodules, but are involved in the calcific process in the sense of being infiltrated, and thus converted into the hard substance and completely destroyed as tissue. But the calcific process is not the primary change, for before the calcification has begun the tissue is already profoundly changed, as has been indicated already, so that the cells have mostly disappeared.

This form of calcification does not as a rule stand alone, but is associated with other forms. Generally, there is more or less calcification of the tissues of the coronal portion of the pulp at the same time. This may be of any of the varieties, but with the exception of deposits of secondary dentine it is more commonly associated with interstitial calcifications in the form of smooth, round boulders, such as is shown in Fig. 472, or there may be several smaller stones of this variety.

Osteo-dentine is the rather inappropriate name that has been applied to osseous formations within the pulp-chamber. In the human teeth these formations are very rare, but in the teeth of animals they are seen quite often, especially in the very large animals. I have seen a number of these from the tusks of the elephant in which there seemed to be a mixture of dentinal tubes and bone-corpuscles. But to enter into a discussion of these peculiar formations in the animal kingdom generally would lead us too far for the purposes of this article. It has been my intention to adhere strictly to the human teeth both in description and illustration, notwithstanding the very great interest presented in the comparative study afforded in the diseases and accidents of the teeth of the animals.

The undoubted osseous formations met with in the pulp-chamber of the human teeth are very rare. In making this statement I exclude all hard formations in which bone-corpuscles are not present. This seems not to have been done by many who have written on this subject; but, on the other hand, some writers seem to have called almost all irregular formations *osteo-dentine*. The great bulk of these have not the slightest resemblance to bone.

The cases of osseous formation within the pulp-chamber that I have met with have all presented the general characters of cementum, and have been found in the root-canal attached to the dentinal wall or resting upon some irregular formation which separates them slightly from the dentine. This is different from the reflection of the cementum slightly into the pulp-chamber from the apical foramen, which occasionally occurs in such a way that I should not consider it in any sense pathological. It seems to me evident that bone will not form in these positions until after the atrophy of the layer of odontoblasts; at least, the specimens that I have

examined all indicate this. I present two illustrations of this in Figs. 477 and 478, both taken from incisor teeth that have been considerably abraded and the pulp-chamber partially filled by secondary deposits.

FIG. 477.

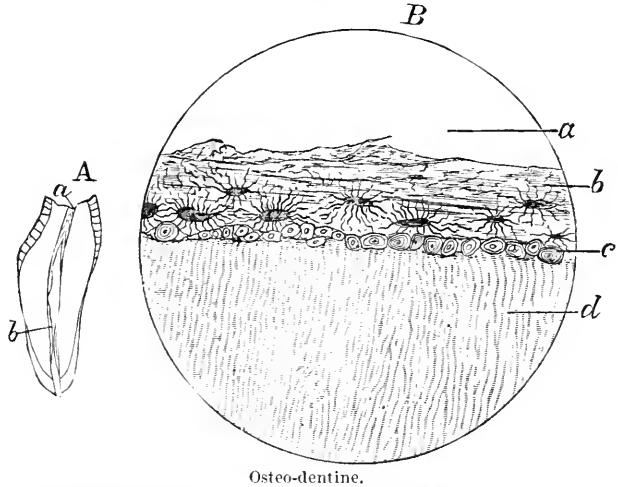

Osteo-dentine.

A, Outline of Abraded Incisor, with point of pulp-chamber (*a*) closed by secondary dentine; *b* points out a narrowing of the root-canal by a deposit of osteo-dentine.
B, Illustration of the Tissue of the Deposit: *a*, pulp-chamber; *b*, ossific material; *c*, layer of very small calcospherites; *d*, primary dentine (× 350).

FIG. 478.

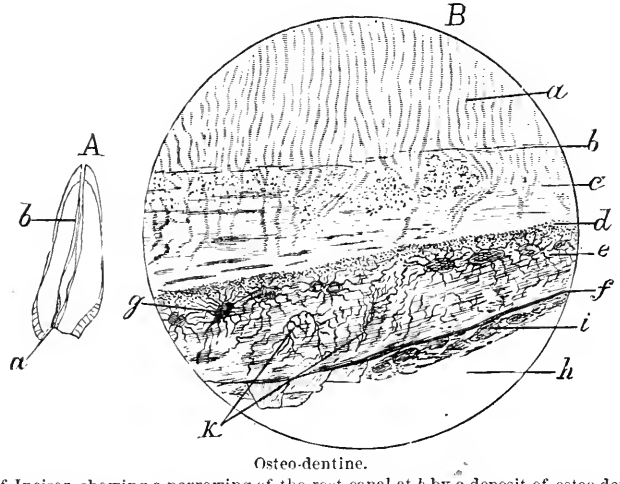

Osteo-dentine.

A, Outline of Incisor, showing a narrowing of the root-canal at *b* by a deposit of osteo-dentine.
B, Illustration of the Tissue: *a*, primary dentine; *b*, line of the beginning of a growth of secondary dentine; *c*, secondary dentine; *d*, layer of granular matter; *e*, osteo-dentine. This has the lacunæ at *a* and dentinal tubes at *k*. *f* seems to be the surface of the osseous deposit; *i*, irregular crystalline deposits; *h*, the pulp-chamber (× 350).

They are enough alike in every respect to have been taken from the same mouth, though, as a fact, they were not. In each I present a diagram of the tooth at *A*, with the position of the osseous deposit pointed

out by *b*. It will be noticed that in each case the pulp-chamber is very much narrowed at the point of the bony deposit, and is wider again toward the apex of the root. The only other position in which I have seen a similar deposit was in the palatine root of an upper molar, and in this the same narrowing occurred. In *B* of each of these figures the tissue is illustrated, and affords a better description than I can give in words. I will call attention to the fact that in Fig. 477 the bone is deposited upon a layer of small calcospherites, at which the dentinal tubes stop suddenly and completely. This growth seems to be in all respects a true cementum, presenting quite perceptibly the peculiar stratified appearance so generally seen in that structure. In Fig. 478 this is entirely different. There is a secondary dentine of very imperfect structure in which the dentinal tubes gradually disappear, and then the osseous formation is deposited upon a layer of granular matter. At *k* there seems to be a return of dentinal tubes. This particular section more nearly merits the name "osteo-dentine" than anything else that I have seen from the human mouth. It is possible that osteo-dentine may occur in other portions of the pulp of human teeth, or even in isolated nodules, as is undoubtedly the case in the teeth of animals, but as I have not met with them in all my cuttings, I think they must be very rare.

The Condition of the Layer of Odontoblasts in the varying states of the dental pulp is a point of the greatest interest, and I have delayed the consideration of it until this time, for the reason that I wished to present the other tissue-changes first, in order, as far as possible, to simplify description and prevent repetition. It will be seen that in all of the deposits of secondary dentine, except it be some of the more rare forms of dentinal tumor, the dentinal tubes, if not markedly diminished at the very beginning, soon begin to disappear; and if the case has met with no mishap in the way of exposure or hyperæmia of sufficient severity to cause death of the pulp, the dentinal tubes disappear entirely, giving place to clear calcification, deposits of granular matter, calcospherites, or other irregular structures. I believe this conclusion of the deposits of secondary dentine is universal if it is not brought to a stop by the premature death of the pulp. This means exhaustion of the organ to such an extent that it is no longer capable of physiological function; for, no matter by what cause it may be excited, we must regard the formation of true dentine in normal form as a physiological product of the organ, and whatever may be the differences of view in regard to the matter, all must regard the layer of odontoblasts as very nearly related to the formation of the dentine. The processes emanating directly from these cells are the occupants of the dentinal tubes—are the dentinal fibrils; and without these there is no dentine, for it is the presence of these that gives the structure the characteristics by which it is known to the histologist. Hence without the odontoblasts we cannot have the formation of dentine. There may be calcific material, but it will not have the form of dentine. This is exemplified in most of the illustrations that I have presented of the secondary formations within the pulp-chamber. These considerations, together with the ever-present fact that the characters of the secondary deposits

of dentine soon begin to show a failure as to the normal number of the tubes, has led me into the study of the condition of these cells in the varying conditions of the pulp as regards secondary deposits. I have, however, found this an exceedingly difficult study. In cases of calcification it is very difficult to get good sections without decalcifying the hard tissues, and in so doing the tissue is so deranged and otherwise injured as to be of little use. Again, in removing the pulp from its chamber the layer of odontoblasts so often remains clinging to the dentinal walls, either as a whole or in part, as to cause much vexation. With all of these troubles in the way it is not surprising that the study of this layer of cells in its diseases has made so little progress.

I have already alluded to the fact that this layer of cells seems to persist unchanged in acute inflammations of the pulp until it is undermined by the processes of suppuration. This, however, does not argue the greater vitality of these cells, but rather the reverse, for it shows that they are less susceptible to changes of form than the other cells of the organ. The facts already given speak plainly of the atrophy of the odontoblasts before the death of the pulp as a whole. Indeed, some of my observations seem to indicate that the pulp may remain alive for a considerable time after the atrophy of a large proportion of the odontoblasts. In many of my sections of pulps that had been long in a state of disease the peculiar structure of the margin of the pulp in which the odontoblasts lie has been present, but without the odontoblasts, or with one here and there only, or with patches from which they were missing, very much the same as we often see in secondary dentine where the tubes fail in patches or become fewer in number and finally disappear. Again, I have found in some sections that all signs of the normal periphery of the pulp were missing, and yet along the margin there was an occasional odontoblast which took the stain in a very unusual manner, as though profoundly changed in its chemical condition.

In Figs. 479 and 480 are given illustrations of these changes. These can be better appreciated by comparison with Fig. 440, in which the full number of odontoblasts that occupy the periphery of the pulp are present. This form of failure of these cells seems to accompany the degenerative changes of the tissues of the pulp that have been described, and, taken together with the evident persistence of these cells during the changes due to acute inflammations, show us plainly that it is in the chronic diseases that we must expect the atrophy of this layer. This agrees also with what is seen in secondary dentine. It seems that these cells are profoundly affected by irritation of the distal ends of the fibrils, for we often find them depositing secondary dentine in cases of abrasion, as has been indicated, and in connection with this performance the cells disappear. Not only this, but they disappear in many cases in which there has been no deposit of secondary dentine whatever. This has appeared prominently in two cases in which there had been long-continued inflammation, accompanied with hypertrophy of the pulp which was projected into the cavity of decay, as shown in Fig. 454. In neither of these cases were there any secondary deposits except a few pulp-nodules and a few masses of calcoglobulin; but over a consider-

able part of the coronal portion of the pulp there were patches from which the odontoblasts had disappeared from their matrix. The possibility that these had been pulled out of their matrix in the removal of the pulp from its chamber has been fully considered. This pulling out occurs in a considerable number of cases, so that I have become acquainted with its indications; and in the cases mentioned these indications are entirely wanting. Fig. 479 was taken from the coronal portion of the pulp of a tooth that had a considerable hypertrophic growth extending into a carious cavity, and from the history given by the patient it had evidently for five or six months been subject at intervals to severe attacks of inflammation; and, though there had been a large increase of its tissue, showing a tenacious vitality and a strong tendency toward reconstruction, the odontoblasts had disappeared from many parts of its surface, and in other parts there were but few left in the matrix of the membrana eboris, as is shown in the figure. In this pulp there was another abnormal condition of this membrane that deserves mention, though it is but an accidental disturbance: Along the dentinal wall, extending from the point of exposure through which the hypertrophic growth was extruded, the dentinal fibrils had been drawn considerably out of the dentine, and the layer of odontoblasts turned so that their long axis was almost parallel with the dentinal wall, with their pulpal ends inclined toward the opening: this was evi-

FIG. 479.

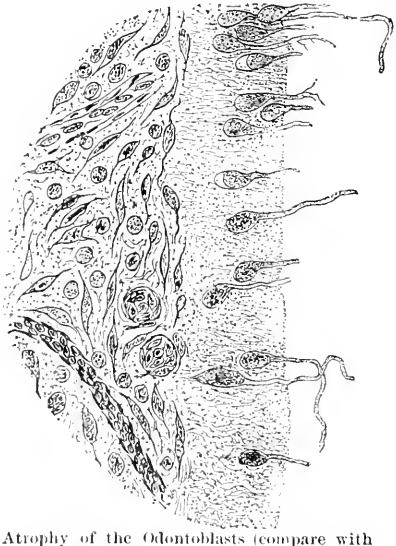

Atrophy of the Odontoblasts (compare with Fig. 440) ($\frac{1}{10}$th inch immersion).

FIG. 480.

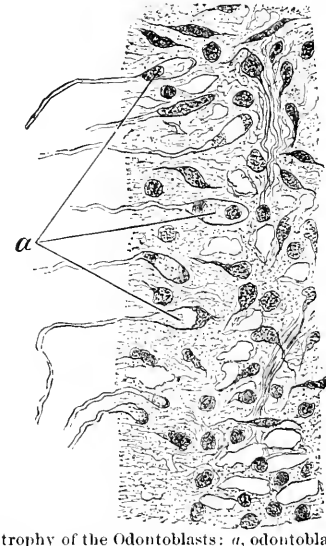

Atrophy of the Odontoblasts: *a*, odontoblasts that have taken the stain in an irregular manner. There is also a peculiar variation in their size. Some areolations appear in the tissue ($\frac{1}{10}$th inch immersion).

dently done by the swelling of the pulp and the protrusion of its mass through the opening.

Fig. 480 is an illustration of the condition of the membrana eboris in a pulp that had been somewhat reduced in size by the deposit of sec-

ondary dentine excited by abrasion. It had also suffered from hyperæmia and extravasations, as was shown by both the history and the appearance of old clots in its tissue, and finally was found to be in a state of chronic inflammation at the time of extraction. The odontoblasts had disappeared from a great portion of the periphery, and in many places all indication of the membrana eboris was lost. The illustration was taken from a point at which a few scattering odontoblasts remained. It will be seen that the usual demarcation of the membrana eboris is wanting, and the odontoblasts that remain are sticking in among the other cells and the inflammatory elements. They also present a singular variation in size, and the staining is different from the healthy cells. The general structure of the pulp was also much changed, areolations appearing in its matrix at a number of points.

In cases of much less degenerative change in the general structure of the pulp there are often observed changes of a more or less marked character in the odontoblasts; and my observations, taken as a whole, seem to indicate that these changes are quite common to the chronic affections of the organ, and especially so where there have been considerable secondary deposits of any kind except the pulp-nodules. It is probable that it accompanies them also if the pulp-nodules are very considerable in bulk.

The influence of the destruction of the membrana eboris with its odontoblasts in cases of exposure of the pulp is a question of great interest. It is to be regretted that there is no direct observation on this point that will assist us in arriving at conclusions. I have many times seen a hard formation that closed the breach, and for the time seemed to shield the pulp from external injury in cases which I had capped at a time when the pulp was fully exposed, and in such condition that I think there could be no doubt of the destruction of the odontoblast layer. But I have never had the opportunity of microscopic examination of such a case. A number of times I have drilled through these deposits to remove a dead pulp; and, so far as I was able to judge of the condition by such a mode of examination, it is not different from that found in death of the pulp following secondary deposits excited in other ways. A sufficient number of examinations of the secondary deposits in cases of exposure and known destruction of a portion of the surface of the pulp would settle the question as to whether these cells may be re-formed after they have once been destroyed. Until such observations have been carefully conducted in sufficient number, or until direct evidence of their re-formation has been had, the question must remain an open one. At the present time what evidence we possess on this point is certainly against such re-formation with the restoration of physiological function. In some cases of dentinal tumor—such, for instance, as that presented in Fig. 467—there seem to have been new dentinal tubes originated, and with these there must have been odontoblasts. The number of the tubes, and the peculiar tufts uniting to form tubes, seem to me to be evidence that odontoblasts have come into existence, but the tissue formed is in no sense physiological. Still, in these, in every instance, some portion of the dentinal tubes comes directly from the primary dentine.

General Considerations.

In the foregoing pages I have frequently alluded to the fact—which is apparent in a very large proportion of my microscopic preparations—that any of the secondary calcific formations within the pulp of the tooth result in exhaustion and the final death of the pulp. This fact is so prominent that it seems to me that it cannot well be overlooked, and yet in the capping of exposed pulps it seems to have been the thought of the profession that to be able to obtain a secondary deposit under such circumstances was to ensure the permanence of the health of the pulp. This was my own thought some years ago, but further clinical experience, combined with the closer microscopic study of the subject, has convinced me that this is a mistake. Secondary deposits may, and do, ensure temporary quiet, but so far from ensuring health are they that, as a matter of fact, they bring about the very state of matters that we most wish to avoid—the degeneration and final destruction of the pulp. In a large majority of cases, however, this result is brought about very slowly, and thus has escaped the notice of most observers. For if an exposed pulp is capped and the cavity filled, and the case seems to do well for a year or two, it is regarded as a success, and is lost sight of. When this returns some years later with a dead pulp, it is treated as one of the great mass of such cases that are constantly presenting themselves, and probably no note is made of the fact that it was capped at a certain time and was one of the many successful cases. And precisely the same thing is true of a large number of teeth in which very large fillings are made in cases in which there is no exposure of the pulp, as well as in many in which the fillings were not so very large. The fact seems to be that any condition of abnormal irritation is liable to produce these results whether it be from a capping, a large filling that increases the thermal changes by the greater conducting power of the metal of which the filling is composed, the exposure of the fibrils by abrasion, or other deleterious influence. And, taking my own records as a guide, I should be compelled to say that very large fillings without non-conductors in teeth with pulp not exposed are more destructive than well-made cappings with non-conducting material where pulps are fully exposed; provided that the capping material be at the same time non-irritating. It will be seen that in all of these cases the cause of difficulty lies in the fact of continuous irritation, and it makes but little difference from whence that irritation comes; it will in time do its work of destruction.

The time that pulps may live after the beginning of secondary deposits is a question of great importance. At present we are almost without exact observation on this point. Undoubtedly, the time varies widely in different cases, and may be said to extend from a year or two to half a lifetime or even more. A very large proportion of these pulps, however, are lost within ten years. Some of these cases will result in abscess, but very many pass on for years in a state of perfect tranquillity, giving no indication of the death of the organ. The only cases in which I have had the opportunity of making microscopic examination have been those of death of the pulp from causes other

than exposures capped by myself, and have not included cases in which I have had certain knowledge of the state of the pulp at the time of capping by others; but from the gross examination of clinical cases I have no doubt that, with the exception of the nature of the deposit, the general pathological changes are the same as those seen in very slow or stationary caries; that is, function becomes more and more irregular or abnormal until the pulp fails entirely.

Very many cases of capping pass on for years without any deposit whatever, and seem to remain in a perfectly healthy condition. This we must regard as the most desirable result that can be obtained. Enough of these cases have been noted to demonstrate the possibility of rendering the conditions so nearly normal that no disturbance of the functions of the organ occurs.

In relation to the symptomatology of the dental pulp more exact information is to be desired, especially as to the differential diagnosis of its different states. This will require that cases of known history be prepared in large number for microscopic examination and the results classified. The old plan of judging of the condition of the pulp by the symptoms presented is of but little scientific value until we shall have more direct knowledge of the conditions by which the symptoms are produced; and this can be gained only by the methods of study indicated.

DISEASES OF THE DENTAL PULP, AND THEIR TREATMENT.

By JAMES TRUMAN, D. D. S.

The diseases of the dental pulp, while not numerous, are an important part of the pathological conditions coming under the care of the dentist. It has been the aim of the writer to present the subject in the clearest manner possible, without undue overloading with quotations. As the minute anatomy of the dental pulp is fully treated elsewhere in this volume, no allusion has been made to it. Considerable space has been given to the consideration of thermal influence, as that important factor in pulp-irritation has measurably been neglected and its influence underrated in the production of pulpitis, etc.

The subjects treated are embraced under the following headings:

Thermal Influences.

Changes from Normal.
- 1st. Simple Exposure.
- 2d. Superficial Pulpitis.
- 3d. Deep-seated Pulpitis.
- 4th. Devitalization.
- 5th. Gangrene.
- 6th. (So-called) Dry Gangrene.

Nodular Deposits.

Polypus of the Pulp.

Thermal Influences.

The pathological condition of the pulp cannot be properly understood without devoting some consideration to the primary causes of inflammation in that organ, originating in external influences which bear more or less directly upon the diseases subsequently manifested.

The prolongations of the odontoblastic layer through the tubuli practically extend the pulp to the remotest ramifications of these passages, and, as they occupy the largest proportion of the dentine, it follows that the pulp cannot be considered simply as a central organ of the tooth-body, but must hold important relations to all parts of the tooth, and in return must receive all impressions made at the peripheral terminations; and in proportion to the extent of these will the effect be temporary or destructive. When it is understood, therefore, that in all exposed dentine surfaces we are dealing directly with the central organ

through its vital extensions, the importance of carefully considering the causes of irritation will be properly appreciated.

The pulp proper, while it undoubtedly receives impressions through the enamel, is never seriously affected by these unless disturbed by some sudden concussion or movement of the tooth or by deposits of calcific matter, but remains in the quiet performance of its function as one of the sources of nutrition to the entire structure. When, however, the dentine becomes exposed by the progress of caries, the contents of the tubes are kept in a continuous state of irritation. While the tube-contents have not as yet been demonstrated as consisting of a nerve-fibre or fibres, it is demonstrably true that sensation is carried from periphery to centre through this channel; and where sensation is, a certain amount of inflammation is always possible. While this is true in theory, it is practically demonstrated by the fact that the exposed tubes are a source of inflammation in the pulp, oftentimes through quite thick layers of dentine; and this is only possible under the supposition that the irritation of the surface layer has extended, by the general law governing inflammations, to the central tissue.

Pulpitis may, therefore, be said to have its origin in quite remote irritation; and this irritation may be produced by any of the many sources of disturbance present in the oral cavity, or it may originate from the action of the varying temperatures to which all teeth are exposed. The direct and most positive cause is in the progress of caries. The extent and rapidity of inflammation will depend on the density of the tooth affected. In soft-structured teeth with great deficiency of inorganic material the chemical action leaves exposed a greater proportion of organic matter, and necessarily opens up a larger surface of inner tubular tissue to the irritating action of the acid fluids, débris of decay, fungi, etc. The result is not only a more rapid destruction of the tooth, but, at the same time, a more speedy increase of the inflammation along the inner tubular contents. In very dense teeth the irritation is reduced to a minimum, and it is therefore rare to find the pulp affected. This is to be attributed to the contracted calibre of the tubes and the extremely slow progress of the disease. Between these two extremes there exist all grades of structure dependent on age and systemic conditions.

The causes already described rarely result in inflammation of the pulp prior to actual exposure, and may be regarded as simply placing the tube-contents in a condition suitable for the more positive action of atmospheric influence. This, from its continuous and more decided impression, becomes a serious factor in the preliminary irritations, with results more frequently injurious to the pulp than all the other causes combined. As before stated, the density of the tooth contributes a proportionate degree to its effect, and it therefore follows that the age must be considered in any treatment given teeth. Young or imperfectly-developed dentine, for reasons already enumerated, is more liable to these impressions, while old age is scarcely affected at all; hence the treatment adapted to the latter is clearly inadmissible in the former. Cold and heat, whether communicated through fluids or by draughts of air, have a similar effect, producing a violent shock and acute pain, which, if long continued, will result, as before stated, in pulp-irritation and

final devitalization. In moderately or very dense teeth this may produce but slight irritation, and, following the general law, may result in extra development of secondary dentine, an effectual barrier being thus interposed against further irritation. The operation of this law is beautifully illustrated in the formation of secondary dentine by occlusion in teeth worn down on the cutting edges and in the development of extra-cemental tissue in exostosis, and also in the calcification of the tubuli in caries in dense teeth. This is, however, only possible under favorable conditions—conditions rarely or never present in young teeth. Hence the filling of all such teeth with good conductors, without some intervening media to prevent the irritating influence, must be regarded as an objectionable practice. In exact ratio to the sensitiveness of the tissue will be the danger of thermal action, and this hyperæsthetic state will be in proportion to the conditions already described.

It is important to bear in mind the possible pathological contingencies in the treatment of so-called sensitive dentine. Over-stimulation from an irritant will have a very deleterious effect if too long continued or if applied over a too thin layer of dentine. The peculiar and quite different action of various obtundents must be carefully studied in their possible relations to the pulp, those being the best to use—if used at all—that confine their action to the superficial layer; and those of great penetrating power, of violent action, or that continue their devitalizing power through absorption should be used sparingly or be abandoned altogether. Among those of great penetrating power may be classed chloride of zinc, and of devitalizing power, arsenic.

The possible changes that may arise through thermal action necessitate care in the treatment of all teeth, no matter what may be the structure. While it does not come within the province of this paper to discuss the question, it will not be out of place to suggest that as a general rule no very sensitive teeth should be filled with as good a conductor as gold without a preparatory layer of gutta-percha, tin, or some equally reliable non-conducting material. Especially is this applicable to immature teeth or the teeth of children between the ages of twelve and fifteen. Indeed, so liable is the pulp to be affected during this period that it is very questionable whether gold should ever be used in that class of teeth.

The destructive action through conditions heretofore alluded to result eventually, if not checked by remedial agents, in direct irritation of the central organ. This opens up a long chain of tissue-disturbance that may end in the total destruction of the tooth, and possibly to more remote and serious lesions. These changes from the normal to abnormal may be classified as follows:

1st. Simple exposure.
2d. Superficial pulpitis.
3d. Deep-seated pulpitis.
4th. Devitalization.
5th. Gangrene.
6th. (So-called) Dry gangrene.

Simple Exposure.—The progress of the destructive forces eventually removes all intervening layers of dentine, and the pulp lies directly

exposed to their influence. While this organ, from its large supply of nerve-fibres, is very sensitive and easily disturbed by impingement of foreign matter, it very frequently bears this exposure without indications of pain; indeed, it not unfrequently happens that it passes through all the stages enumerated without any sign more than an occasional uncomfortable sensation. This is not, however, always the case. Fresh exposures always, when visible, present a rich red appearance, from the fact that the red blood-corpuscles have not been given time to take on the condition of stasis, or stagnation, in the progress of inflammation. The bright-red spot so familiar to all practitioners has, therefore, only a limited duration, and gives place to the secondary, or dark, stage peculiar to areas of inflammation, whether limited to minute or covering large surfaces. The red spot is therefore the indication of a pulp in a normal condition, or as near that as it is possible to have it and still require treatment. The exposure may not be visible to sight, as it may have occurred through the cracks always possible in dentine in defects of structure or by accident. It will, therefore, in such cases, be manifestly impossible to diagnose its condition or judge the length of time of exposure or the extent of the inflammation. The red presentation is the indication for a favorable judgment as to the propriety of the so-called process of capping. In proportion as the pulp has degenerated toward pulpitis will the possibility of success be decreased. This has been the experience of the writer, and is fully in accord with the general professional sentiment on this subject.

The difficulty in diagnosing a slight exposure is oftentimes very great, and, as it is of vital importance that this should be correctly done, the examination should be thorough. The simulation of exposure of the pulp by sensitive inner tubular fibres is always a source of difficulty. If it has been exposed to irritation for some days, the excavator may fail to find it; resort must be had then to some agent that will penetrate minute openings and act as a searcher. For this purpose nothing is superior to finely-carded cotton. The fibres of this insinuate themselves into minute orifices, and the opening must be very small indeed that will not be entered by them. The result is momentary pain, more or less acute, depending on the size of the aperture. While this simple test is not wholly to be relied on, it is the best at present at command, as it certainly is a very delicate one. Sensitive dentine is not affected by it, for the reason that the test is only available after excavation of all débris of decay; and this process cuts off all fibres level with the orifices of the tubes, into which, on account of their microscopical minuteness, the fibres of cotton cannot penetrate.

Superficial Pulpitis.—Inflammation of the pulp proceeds by the usual stages accompanying other inflammations—first, the irritation caused by the foreign matter; then the period of excitement or increased flow of blood, followed by the static period; then gradual loss of vitality in the part most affected; eventual death, followed by a putrescent condition. The first stage is that comprised under this heading, which may be described as superficial pulpitis from the fact that it frequently retains that character for a long time, and may therefore be properly considered as a distinct variety. When it assumes a chronic character, it is evi-

dently due to a large amount of vitality in the individual, giving a resisting power to the encroachment of disease. This peculiarity is often manifested in the power of resistance some pulps possess against the action of arsenic. Ordinarily, however, superficial pulpitis is of but short duration, and, following the general law, continues to the destruction of the whole organ. The possible error in diagnosis will be found in the difficulty of determining the extent of the lesion and whether it may not possibly have reached the condition of *deep-seated pulpitis*, the latter condition being generally accompanied by more or less periosteal disturbance, which will at times furnish a guide to judgment, though the violence of the inflammation will have to be the general diagnostic sign. If there is but little activity, if pain is not excessive and is not coupled with periostitis, the pulpitis may be regarded as superficial; but, on the other hand, if acute with the other accompaniments, it has reached a point where devitalization is certain to result, and any effort to abort the inflammatory state must result in failure. The usual attempt to quiet such pulps and then cap with some foreign material has but little to recommend it, and the final result is almost invariably *devitalization*.

The destruction of the life of the pulp is by no means dependent on exposure by caries. The organ holds its vitality by the slight connections with the main vessels and nerves through the oftentimes very contracted canal, the apical foramen of the tooth. It requires but a very slight disturbance at this point to cut off all sources of nutrition in this direction, and the pulp's life is sacrificed. This is much more easily accomplished than is generally supposed, judging by the very rough appliances, and the still rougher modes of using them, that have been adopted from time to time for the purpose of moving teeth. The separation of teeth by the wedge and hammer and powerful screws is but one sample of the wrong application of force upon a delicate tissue. The elasticity of the pericementum admits of a limited movement, and any force used beyond that must be cautiously applied, to prevent strangulation of the vessels of the pulp at the apex. The pulp may be devitalized and give no immediate sign, or it may result in sudden congestion or rapid discoloration. A sudden blow has the same effect, and, as this is peculiarly liable to occur to children, the largest percentage of loss from this cause occurs in the earlier years of life and very frequently fails of recognition until a later period, when discoloration gives the usual indication. Devitalization occurring under these circumstances is not necessarily a source of discomfort to the individual. The pulp-tissue is gradually decomposed or mummified, and the matter is gradually absorbed into the body of the tooth, and, in connection with the dead material already there, produces the dark appearance before alluded to. Such a tooth may remain comparatively comfortable for years. It requires the ingress of atmospheric germs to produce the products of decomposition which render the treatment the most troublesome and uncertain of any of the pathological conditions of which the dentist is called to take charge. This can be more properly considered under—

Gangrene.—This term is applied to the pulp in the last stages of

decomposition, for it is death preceded by inflammation. This may have been superinduced by the exposure of the organ, or, as previously described, by a too suddenly applied force. The destruction of the vitality leaves a mass of dead matter confined within narrow limits. This, even when exposed to the air, may remain quiescent for a long time, provided there is free egress for the products of decomposition. One of these—sulphuretted hydrogen—is formed rapidly. If by any means the aperture becomes closed, the excessive irritation from pressure that this produces rouses the pericementum into activity; the result is periostitis. This will give rise to symptoms more or less aggravated, depending largely on temporary or permanent systemic conditions. The state of the pulp at this pathological period is of far more importance than has generally been conceded. Unless great care is exercised, complications of a serious character are certain to result. The septic poison so infiltrates the surrounding tissue by long continuance that the treatment very often becomes exceedingly tedious, and in some cases ineffectual, especially in cachectic individuals. Atmospheric air as a factor in decomposition is in no case more clearly demonstrated than in pulps of this character. When confined in a sealed cavity, as in teeth without caries, they may remain, as previously stated, for years without any disturbance; but a free opening brings in a new element, and the destructive process immediately begins. In the exposed pulp this is always present; hence pulps of this character are loaded with germs. This is not the place to discuss the influence of bacteria on inflammatory conditions, but the observations of the writer point unerringly to the fact that their presence is quite necessary to the progress of such conditions, and their destruction is absolutely essential before any good result can be effected. Careful microscopic examinations in *pyorrhœa alveolaris* have demonstrated that very positively. Treatment of gangrene, therefore, must be based on this fact first, and, secondly, must be directed to an elimination of the gaseous products. This part of the subject will be more thoroughly treated hereafter.

Dry Gangrene.—This peculiar state of the pulp, subsequent to destruction of its vitality, is not easy of explanation, but there are cases which are undoubtedly produced by the development of secondary dentine, and a consequent stagnation in the circulation, as in *gangrena senilis.* This is often observed in teeth of old persons, but is more rarely seen where death of the pulp has taken place in a closed cavity. It has been termed the "mummified condition of the pulp." It is a frequent result of capping with oxychloride of zinc, and in such cases it is evidently due to its great penetrating property, dependent, probably, upon its affinity for the water and power of combining with the albumen of the tissues. It is for this reason, to a large degree, that oxychloride of zinc is the most valuable capping material, as it produces this very desirable state—a state in which the tooth is generally effectually preserved from the results described under the head of Gangrene.

TREATMENT.—The treatment of simple exposure, as well as the other more complicated pathological changes, has assumed increased importance with the development of dentistry; indeed, it may be said to base its progress and right to be deemed worthy to be called a profession

upon the intelligent conception of the management of this organ. The feeble and generally futile efforts to treat it made by the older dentists were necessarily failures, as they were of a purely empirical character and a continual violation of what are now well-understood principles. The old method of destruction by the actual cautery, while theoretically correct, was impossible of application with the then imperfect appliances, and the knowledge of the proper subsequent treatment was wholly wanting. There was little or no progress until after the introduction of arsenic as a devitalizer by Spooner, in 1836. It came into use very slowly, and Dr. Harris, the ablest of the pioneer dentists, for several years failed to perceive any advantage in its use, and he passed from his laborious and useful life before the pulp and its entire pathological relations were understood. It is very doubtful whether the half century that has been given to its study has clearly solved all the problems connected with it.

The two modes of treatment that have been adopted are—the one being conservative, and the other destructive—diametrically opposed, yet both lead directly to the same end, the preservation of the tooth. The former is effected by what is known now as capping, and the other by devitalization and removal.

Capping was very early adopted, in accordance with the theory that if the pulp could be protected from pressure it would maintain its vitality and perform its proper function for an indefinite period. This was based on erroneous conceptions of the character of the central organ, and also on defective knowledge of the powerful influence of other sources of irritation. It was not then clearly understood that the surface of the pulp from the period of first exposure is in a pathological condition, and that this must progress unless measures be taken to abort it, and that the mere interposing of some media, though nearly allied to dentine in character, would not avail to prevent this gangrenous destruction. The germ theory of disease was then unknown, and it is not, therefore, remarkable that the efforts at pulp-preservation usually ended in pulp-destruction. The earliest attempts were simply to protect the pulp from contact with the filling. The first cappings were made of gold and lead cut in circular form of a size sufficient to rest on the adjacent solid tissue. These were stamped to form a concave surface over the pulp. For this purpose gold was generally used, though lead, owing to its poorer conducting property, was regarded by many as preferable. Harris advocated the forming of the filling by so packing the gold that the caps would be formed out of the filling—a very difficult, and always an uncertain, operation. The results were not satisfactory. In subjects of great recuperative power the pulp would be preserved in spite of the defective process, but the number was so limited and the cases of failure were so numerous that the process was abandoned by all good operators. Attempts were made to modify the supposed injurious effect of the metals by the substitution of a material nearly allied to dentine, under the supposition that irritation would be thus reduced to a minimum; ivory, quill, and gutta-percha were therefore substituted, with but little better results. These were followed by asbestos, plaster of Paris, goldbeater's skin, collodion, court-plaster, tissue-paper saturated

with solution of Canada balsam, lactophosphate of lime, and finally oxychloride of zinc, oxyphosphate of zinc, and oxysulphate of zinc.

While these have been introduced nearly in the order named, there was an interregnum of years after the use of the metals before much reliance was placed on any form of capping, and the operation regarded as most satisfactory was the destruction and removal of the pulp and the filling of the canals. This, however, involved tedious operations, with a constant percentage of failures in inaccessible roots. So frequent were these that the active minds of the profession continued experimenting with various agents, but no good results were attained until the introduction of oxychloride of zinc as a filling material. It is uncertain who was the first to suggest this as a covering, but its use developed such surprising results that its almost universal adoption is one of the remarkable revolutions in the history of dentistry. This was owing partially to the general desire to make dental operations shorter if equally good results could be attained, and also to the general feeling that the destruction of the pulp cut off the principal, if not the only, source of nutrition to the dentine, practically rendering it a dead tooth with a partial vitality maintained through the cementum.

The theory of the action of the oxychloride was not well understood at this period, but the results were manifested in pulps retaining their full vitality for quite long periods of time and remaining perfectly comfortable. The number of years that have elapsed since its introduction for this purpose have given ample time to arrive at intelligent conclusions regarding it and other similar materials, and, while the writer does not propose to dogmatize, it would seem appropriate to the subject to give his views in connection with a description of the different modes of capping at present in use and a statement as to the direction in which failure or success may be looked for.

That capping can be made an invariable success must ever remain an impossibility. The delicate nature of the organ upon which we are called to operate—endowed, as it is, with sensory nerves inviting the inflammatory condition upon the slightest irritation—makes any treatment at once difficult and uncertain. Systemic peculiarities, the anæmic, the scrofulous, the syphilitic diatheses,—all operate against a satisfactory prognosis; and so common are these antagonistic forces that it is somewhat remarkable that there has been any degree of success.

The pulp from the moment of exposure being irritated by atmospheric germs, etc., it becomes necessary that the treatment attempted should first aim to overcome this condition. If the inflammation has not advanced too far, the action of some sedative combined with an antiseptic may be all that is requisite as a preliminary treatment. Oil of cloves, oil of cajeput, iodoform, or a 10-per-cent. solution of carbolic acid may be used at this period with markedly good results. It must be remembered, however, that capping over freshly-exposed pulps is alone under consideration.

The theory of the action of the oxychloride of zinc has been that its escharotic action is limited—that it preserves not only all the superficial tissue destroyed, but in case of devitalization of the balance of the pulp will preserve it also in the before-mentioned dry-gangrenous state; so

that even if death supervenes the disastrous results usually following the death of the pulp are averted. That this is true experience has amply demonstrated. Its porous character makes it a good absorbent, and its poor conducting quality is an additional element in its favor. In discussing the merits of an agent the requirements to be met must be taken into consideration; they are—1st. Close contact, to exclude air; 2d. Porosity; 3d. Non-conduction; 4th. Property of preserving tissue in case of death. With our present knowledge, these seem to be necessary; and an agent failing to meet all of these requirements will be a failure except under most favorable conditions—conditions of extraordinary vitality and resisting power. There is at present but one agent known that meets all these demands—the oxychloride of zinc. This is regarded by some as too powerfully escharotic, but this effect can be modified by an intermediate capping. Gutta-percha has no superiority over horn, quill, etc.; for, while it may be applied in solution and be perfectly adapted, it is still a foreign element without any of the peculiar therapeutic properties of some of the other substances. The same may be said of collodion, the resins, etc. The deep-penetrating property of oxychloride of zinc gives it decided therapeutical advantage over any other agent. This is very marked in the treatment by it of other pathological states, as in chronic pericementitis, alveolar abscess, etc. It is this penetrating power which ensures the pulp from decomposition in case of death, as the effect has been transmitted to the farthest extremity of the tissue. As oxyphosphate of zinc does not possess this quality, it is quite valueless in comparison with the first named, and will necessarily fail of good results. Hence, while each of the agents named has one or more of the required properties, success can be attained in the largest number of cases only by the use of that material possessing these in the fullest degree; and in the judgment of the writer, until some other material can be demonstrated as superior, reliance must still be placed on oxychloride of zinc. It must be said, however, that this opinion is widely at variance with some very good authorities.

Coleman[1] gives the preference to nitric-acid treatment. He says: "The softened dentine having been cleared away and the cavity otherwise prepared, the sensitiveness of the exposed pulp is lessened by a free application of carbolic acid; and then a small disc of card but little larger than the exposed surface, and well saturated with the strongest nitric acid, is laid gently upon it, and so retained for about half a minute. At times a sensation like toothache, but never severe, is felt for a few moments afterward. After removal of the nitric acid a cap of thick paper moistened with carbolic acid is placed over the pulp, and, if the tooth is to be filled with foil, over the paper cap one of metal, concave on the pulp-surface, to guard the pulp from all pressure. The filling is then completed." In amalgam fillings he recommends "to give a coating of oxychloride over the first paper cap, in place of the metal one." This is done to prevent change of temperature.

In considering the action of any agent in its effect on the pulp the possibility of the development of osteo-dentine must enter as a factor. If this were possible under all conditions, nothing more could be hoped

[1] *Dental Surgery and Pathology.*

for or desired; but that such is not the result, except in the fewest number of cases, must be clear to every observer, and the reasons for this must be apparent. If it occurs at all, it must be where the pulp is the nearest possible to a normal condition, the full normal state being very seldom met with. The vitality of the subject must be above the average, and—of equal importance—the agent used must have a limited power of stimulation. It is, therefore, if this position be correct, useless to expect new formations, except in limited degree, from the direct action of any of the usual agents. Oxychloride is too powerful an escharotic; oxyphosphate is preferable; and so on through the list. But little dependence can be placed upon this result, and until we have some gauge to determine the actual amount of excitation necessary to produce new tissue a favorable result may be regarded only in the light of an accident.

The introduction of oxychloride of zinc as a filling and capping material was naturally followed by investigation in other directions; efforts were made to avoid the direct injurious escharotic effect of this and other valuable agents. Dr. J. S. King in 1871 suggested covering the pulp, prior to the insertion of the oxychloride, with a paste made of carbolic acid and oxide of zinc. The anæsthetic and antiseptic properties of the former were supposed to meet the necessary requirements, while the latter furnished a convenient means of retaining it in a soft magma, and effectually excluding the air and giving a cushion on which to rest the denser filling, and thus avoid the effect of pressure. This theoretical view was sustained in practice. It was found that by placing a very small quantity directly over the pulp no pain followed the introduction of the oxychloride, and the results were apparently more satisfactory. Carbolic acid of full strength should not be used, a 20-per-cent. solution being quite strong enough. This mixture can be prepared at the time needed and gently pressed in position by a piece of spunk or bibulous paper, which at the same time absorbs any excess of fluid. Then cover this with the oxychloride, either as a cap or as a filling of the entire cavity.

Dr. J. E. Cravens in 1873 suggested the following practice as hastening the formation of secondary dentine. After careful drying of the cavity the pulp is covered with a paste prepared as follows: "Upon a warm slab of ground glass put a drop of Merck's lactic acid and twice that volume of magma or freshly-precipitated phosphate of lime; then rub until a complete solution is effected. This is lactophosphate of lime. To this solution add dry phosphate of lime until the paste is of proper consistence for application. Place the paste directly on the exposed pulp so as to occupy all the space and yet make no pressure upon it; then remove the moisture from the surface of the paste with spunk or some absorbent; then cover it with two or three pieces of bibulous paper cut to fit the cavity and moistened with sweet oil. Press this carefully upon the paste, especially upon the border; then cover this, and fill with oxychloride. No preparative treatment is required." This dressing should remain for from two to six weeks, and must not be disturbed during that time.

For the purpose of protecting the pulp a film of collodion has been

used, a drop being placed over the exposed portion and the ether allowed to evaporate before covering it with the capping. Dr. Francis of New York suggested the saturation of tissue or Japanese paper with Canada balsam and laying this gently over the pulp. This plan has been quite extensively adopted by some prominent operators, who regard it as superior to other modes. Various other processes have been suggested, all looking to the same end, each and all having the same percentage of success and failure. One of the most satisfactory in the writer's hands has been a modification of Dr. King's method, which he has used almost exclusively since it was first mentioned; and that is the addition of a small amount of iodoform to the paste of carbolic acid and oxide of zinc. The value of this agent as an antiseptic can hardly be overestimated, and as an obtunder of pain it is second only to chloroform. Its non-irritant quality renders it peculiarly adapted for this purpose. The two objectionable features are the odor and the tendency to nauseate; hence it must be used only in minute quantities for this purpose, as it is presumed that this will remain on the pulp for an indefinite period.

The practice in regard to subsequent treatment varies, and its discussion does not fall to the province of the writer. Suffice it to say that some make use of the material adopted—whether it be gutta-percha, oxychloride, oxyphosphate, or oxysulphate—simply as a cap, filling the balance of the cavity with the permanent material. The safest plan, however, is to prepare the capping of sufficient thickness to support a metal filling, if that is decided upon, doing this while the capping material is in a semiplastic condition; then fill temporarily with gutta-percha, to test results. At a future sitting the filling can be finished without risk of disturbing the capping first placed—a consideration of very great importance.

In closing this portion of the subject it may be said that no plan has as yet been proposed that gives a satisfactory solution of the problem under discussion; and, while it remains true that the pulp ought to be saved, no treatment has as yet been devised and no specific been introduced to accomplish this in all cases, and, as before stated, it would seem impossible that this can ever be done while conditions are as we find them. From the great discrepancy in reports from different sections, it is very evident that localities have much to do with success. This ought to be expected. Healthy locations, giving vigorous organizations, would result more favorably than the opposite, and the treatment that would give a large percentage of success in the one would result in almost total failure in the other.

The discussion of treatment has been wholly confined to freshly-exposed pulps or those but slightly affected by long exposure. Those in the first or secondary stages of pulpitis have not been mentioned, but will be more fully considered in the proper place. It may be stated as a rule that in proportion to the extent of the inflammation in the pulp will be the probability of failure.

Before entering into the treatment of inflamed pulps it will be consistent with the plan marked out to consider the subject of *entire devitalization and removal*. This mode of procedure antedated that of capping,

and was for many years the only mode of overcoming the difficulties arising from exposures; but the treatment—if it may be dignified by this title—was confined to the anterior teeth. This was necessarily so, as no appliances were then in use adapted to the posterior teeth. The plan then adopted was that before described—destroying the pulp by the actual cautery, or, by what was in more general use, hooked or barbed instruments, to tear it out by force. It is needless to say that either of these operations was so barbarous in its infliction of pain that it is scarcely presumable that many submitted to it. The removal at the present time may be performed with a minimum amount of pain by the use of local anæsthetics and the galvano-cautery, but at the period referred to neither of these agents was known. Up to the time when Spooner introduced arsenic as a means of devitalization the canals from which pulps had been removed were allowed to remain unfilled; the result was decomposition of the remaining organic matter, followed by pericementitis, alveolar abscess, etc. The reasons for this were not then understood, and the untoward results were ascribed to the operation, and not to the true cause—the leaving unclosed canals to become receptacles for effete matter with its train of evils. It was not until long after the introduction of arsenic that this imperfect mode of operating was in part remedied. The credit of this is due to Dr. Maynard of Washington, D. C., who perfected the process now known as filling the canals. Until this was demonstrated as an effectual remedy when perfectly performed, the filling of teeth was of very little service. Attention was immediately turned to improving the mode of introducing arsenic and of limiting its action. Since that period the experience derived has more clearly demonstrated its value, and it remains the only agent that will effect the destruction of the pulp with certainty and with comparatively little pain to the individual. To accomplish this, however, certain things are to be considered.

Arsenic acts by first exciting the sensory nerves and then paralyzing them, arousing inflammation violent in proportion to the amount used. This first stage of excitement passes off, and the arsenic is gradually absorbed. Death of the organ does not immediately follow; indeed, cases have been noticed where sensation returned after apparent death. As the irritation is violent at the earlier stages, and is, as before stated, in proportion to the quantity used, it follows that an overdose will produce an amount of excitation that will defeat the object of its use; or, in other words, the inflammation suddenly aroused will resist the absorption, probably through the action of the well-known law that pressure of fluids on one side of a membrane tends to prevent the passage of fluids or substances in solution upon the other side, and thus arsenic will fail to do more than increase the congestion. The same result is manifest in the use of large quantities in the stomach, the sudden inflammation frequently producing a similar effect on a larger scale. The recognition of this well-known fact renders the application of arsenic to inflamed pulps of doubtful value; indeed, it is very well understood that the irritated tissue will resist its action, and the application must be delayed until the inflammation has been reduced by treatment. It therefore follows that the destruction by arsenic will

be more satisfactorily performed, as in the case of capping, upon pulps the least irritated or nearly freshly exposed. The fact also having been demonstrated that quantity increases inflammation, and proportionately so to the amount used, it follows as a necessary sequence that it is better and safer to use minute quantities; and it has been further found by experience that this amount, when properly applied, may be reduced to the $\frac{1}{100}$ of a grain and be effectual to the extent of destruction desired. It has been further demonstrated that an amount sufficient to devitalize the entire pulp at one application is too large, as the destructive effect may be continued through the tissue in the apical foramen to the periosteum, and that the limitations of amount should be confined to the quantity that will carry destruction to the upper third of the tissue in the canal without comprising all of it. Keeping, then, this general statement in mind, its preparation and use may be described.

The preparation of arsenious acid for use in devitalizing the pulp was in the earlier days of its introduction regarded as of more importance than at present. Various agents were from time to time suggested either to reduce the pain or to limit the action of the arsenic to the part for which it was intended, or else to give bulk to the mass. For the first purpose morphia was recommended, and for the second charcoal and other materials. Why charcoal should have been used is not very clear, nor did it come into general use. Morphia, however, still retains its place with many, but the majority, probably, of operators use at present arsenic without any other combination than creasote or carbolic acid. One of the first to recommend morphia in connection with arsenious acid and creasote was Dr. J. D. White of Philadelphia. His formula was:

℞. Acidi arseniosi, gr. j;
Morphinæ sulphatis, gr. ij;
Creasoti, q. s. M.
S. To be made into a thick paste by several hours' trituration.

The proportional amounts of arsenic and morphia varied with different operators, and Dr. Foster Flagg suggested the use of acetate of morphia in place of the sulphate. His formula was:

℞. Acidi arseniosi, gr. j;
Morphinæ acetatis, gr. ij;
Acidi carbolici, gtt. iij. M.

Garretson makes it equal quantities of arsenious acid and acetate of morphia. Dr. J. D. White regarded thorough trituration as of great importance, to the end that the arsenic and morphia might be completely combined, but, the specific gravity of the former being greater than that of the latter, the arsenic would mainly sink to the bottom of the receptacle, thus introducing an element of uncertainty in its application; so that the preparation of small amounts and the spreading the mass over a considerable surface became a necessity if the operator would make the application with a reasonable degree of certainty of having received sufficient arsenic to accomplish the end desired. Owing to the

separation produced by the greater specific gravity of the arsenic even after the long trituration, the simple mixing of these ingredients in the glass or porcelain vessel in which it was to remain came to be the usual mode adopted; for this purpose the ordinary glass or porcelain tooth-powder boxes are all that is required. Very little creasote or carbolic acid should be used; for the thicker the paste is, the more convenient will be its application.

It is very questionable whether the addition of morphia is any improvement, as it has never been satisfactorily demonstrated that it diminishes the pain of the process. Adding bulky foreign substances is a decided detriment, as this prevents any approach to exactness of measurement—a matter which is of great importance.

The amount of pain following the application of arsenic is dependent on two conditions: first, the state of the pulp at the time; and secondly, the amount of pressure given to it by the covering used. Pulps will always give a painful response to pressure, but this will be aggravated in proportion to the inflammation already present in the tissue. In a highly-inflamed pulp the pain will be severe and continuous, and the arsenic, as already stated, will fail to act upon it. The patient will have hours of suffering with negative results. On the other hand, if there has been little or no irritation of this organ, the application causes pain which lasts for an hour and then ceases. The remarkable uniformity of this period leads to the conclusion that direct pressure must have something to do with the pain, but this does not entirely explain it. It would seem as though this amount of time was required to paralyze the nerves of sensation, while a longer period is necessary for the entire devitalizing process. This would appear to be the only reasonable explanation, as the pain is present when the utmost care has been taken to avoid pressure, and this will continue to the time specified. So certain is this that in non-irritated pulps the operator can safely promise his patient relief at the expiration of the hour. Continuation of pain over this period is a certain indication that the pulp was in an inflamed condition prior to the application. The patient should in all cases be instructed to return if the pain continues after the period named.

Exactness in administration is of great importance, for the rapidity of absorption of arsenic in non-inflamed tissue renders any excess of the agent a possible danger—a danger proportionate to the density of the tooth and the age of the patient. The destruction of the life of the entire pulp is not required, nor is it desirable. The upper third should, if possible, be kept in a nearly normal condition; its removal does not produce much pain and the parts in and around the foramen are left in a much better state. The danger of an excess of arsenic passing through to the pericementum is always imminent and should be carefully guarded against; the smallest quantity, therefore, of the paste should be taken: if applied directly to the pulp, a very minute amount will answer. It is difficult to give any clear idea of this in fractions of a grain, especially when paste is used, but an approximation may be arrived at by stating that an amount sufficient to lie on the point of a small hatchet-shaped excavator will be sufficient. From the $\frac{1}{25}$ to $\frac{1}{50}$, or even $\frac{1}{100}$,

of a grain of the powder may be used, depending on the position and character of the exposure. The most feasible mode of arriving at this is to divide a grain on a slab into the number of parts desired; this will familiarize the mind with the required amount.

It must be remembered that arsenic is rapidly absorbed by any organic matter with which it is brought in contact, so that foreign matter will prevent its action on the pulp-tissue just in proportion to the amount present; hence, the débris from decay should all be removed before making the arsenical application, and in the use of covering materials those of a nature to absorb should be discarded or their contact with the arsenic be prevented by an intermediate layer of metal.

The preparation of the cavity having been completed, the tooth should be carefully invested with the rubber dam, especial care being taken to have it bind closely at the gum-margin. Dry out the cavity, and then make the application direct to the pulp. Cover this with a lead cap, and then fill the balance of the cavity with gutta-percha. This part of the operation should be carefully performed, to avoid the possibility of the arsenic reaching the gum-tissue. Care must also be exercised that no arsenic adheres to the shank of the instrument, as this may accidentally lodge where it is not desirable to have it. For this reason wide-mouthed vessels as receptacles are the only ones fit to use, and the narrow-necked bottles so universally sold, containing arsenic and carbolic acid, should be condemned for this purpose.

Where the tooth is so badly broken that it is difficult to secure proper support for the retaining filling, recourse may be had, on proximal surfaces, to the adjoining tooth; where this fails, the filling should be ligatured in place. The difficulty of treating fractured teeth with arsenic has been very great, as these, in the case of anterior teeth, are frequently broken in such a manner that no supporting walls are left. An application of very minute amount should be made; cover this with a thin layer of gutta-percha and ligature it in position. This may destroy only a portion of the pulp, but still sufficient to enable the operator to secure a place for a second application, which generally is required. A very neat mode of accomplishing this is suggested by Dr. Kirk of Philadelphia: he uses the surgeon's rubber plaster where but a portion of the tooth is left, carrying it round the tooth. It will adhere satisfactorily for several days, or long enough to accomplish the object. The destructive character of arsenic is so well understood that any carelessness in its use in this operation amounts to malpractice, and should be condemned as such. When properly applied and carefully guarded, no agent is more thoroughly under control or more safely used; but in careless hands nothing can be more dangerous to the life of the tooth and surrounding tissues. Extensive sloughings have been produced by a lack of caution. While this is true, the very remarkable stories of the supposed bad results in its use have, generally, no foundation in fact.

The application should remain about twenty-four hours before examination. If the operation has been performed with judgment, the pulp will be partially destroyed—sufficiently so to be removed.

This operation, though apparently simple, is attended with consider-

able difficulty if attempted immediately after the devitalization by arsenic. In the single-rooted tooth the instrument is readily passed to the farthest extremity of the canal. The canals of the superior bicuspids and the molars, superior and inferior, are far more difficult of access. The extreme minuteness of the canals in the buccal roots of the superior first and second molars and the anterior root or roots of the inferior molars increases the difficulty. The operation is also rendered more uncertain by the bent form of the roots. Enlargement of the canal by drilling is possible to a portion of its extent, though great care is required to avoid passing the drill through the root. Cavities on the distal surfaces of molars require special treatment. Entrance to the canals through this surface is accomplished only by a sacrifice of a large portion of the tooth. Entrance to the pulp can be effected more satisfactorily by drilling through the buccal surface in the direction of the roots, or, what is preferable, to enter through the masticating surface, provided a cavity has previously existed on that surface: otherwise, the amount of labor required hardly justifies the operation.

The instrument generally used to remove the pulp is made from a watchmaker's broach, temper drawn and the steel barbed. This would be a very satisfactory instrument had it any lasting property, but the barbs naturally flatten or the steel breaks after one or two operations. The best instrument for this purpose is probably one made from steel wire, filed down to the proper size, then flattened at the extremity, bent in the form of a delicate hook, and tempered at this portion.

To remove the pulp the instrument must be passed carefully up the canal as far as possible and then rotated, in order to cut off the pulp-connections. When the barbed instrument is used, the danger of breaking is always present; and when this occurs, the fractured end is removed with difficulty. It may be accomplished by passing a second instrument, wrapped with cotton, up by the side of the first. The barbs become entangled in the cotton, and the broken piece is thus removed. A magnetized instrument has been recommended for this purpose, but the attractive force is, as a rule, insufficient to accomplish the removal. The operation will be found at all times difficult and tedious, and sometimes impossible. When this proves to be the case, the piece should be carefully located and the filling material carried directly to the most constricted portion of the canal and the balance carefully and very solidly filled. Where this has been well done, the writer has never known any unpleasant results to follow the leaving of the fragment of steel in the canal.

The pulp on removal will show the dividing-line between the part affected by the agent and that still in the normal state, provided that the amount of arsenic used has been small.

The proper time for filling the roots after the removal of the pulp has been a subject of much controversy. The safest plan is to place a mild antiseptic, as eucalyptus oil or oil of cloves or eugenol, in the canal and let it rest. The objection to immediate filling lies in the fact that there must be a collection of fluid and lymph in the canal from the apical foramen, and possibly from the canaliculi of the dentine, inviting putrefactive processes. It is necessary, therefore, to place the canal or canals

under proper treatment before inserting the filling. Those who advocate immediate filling contend that delay in closing the canal increases this collection of fluid, while the filling arrests it. Whatever force there may be in this reasoning, it is certainly the safest plan to wait for a restoration to normal conditions. Dr. Litch recommends, before filling, repeatedly to pass up each canal a probe heated to white heat, thus not only desiccating, but superficially carbonizing, the walls of the canals.

A second application of arsenic should not be made upon a pulp partially destroyed by this agent. If a portion of the pulp has been devitalized, except in the case of fractured teeth, it is better, and altogether more prudent, to let the pulp rest a day or two before attempting its removal. Some pulps are affected very slowly and require more than the usual twenty-four hours. In some cases repeated applications of arsenic fail to have any immediate effect, and in one case coming under the observation of the writer this was repeated several times, when, failing to get any results, the tooth was capped, and at the expiration of a year was examined, under the supposition that possibly a small amount of arsenic might have been absorbed and death followed; but the pulp still retained its full vitality, and was recapped.

The resisting power of the tissue of the pulp after devitalization by arsenic is very clearly demonstrated in the tenacity with which the organ resists the attempt to remove it. Even with the best-arranged barbed instruments this is by no means an easy matter, and frequently ends in its coming out in torn portions. This demonstrates—if demonstration be needed—that arsenic has no effect upon the tissue itself. The force of the retention is very easily understood when it is remembered that the pulp, with its microscopic connections, has intimate relations with almost the entire dentine, exclusive of its attachments through the foramen.

Arsenic, to a limited extent, is a preserver of tissue, but this does not prevent ultimate decomposition, which at the expiration of ten days will have progressed so far as to make the removal of the pulp or pulps a very easy matter; indeed, they may be drawn out by a pair of small surgical forceps. A delay, however, in removal to this period of change is wrong, as any approach to putrescence endangers the success of the subsequent treatment necessary to restore to healthy conditions.

That the pulp is very easily removed is true, but, from what has been already said, it will be understood that waiting for putrescence is a very reprehensible practice. The effect is precisely the same as in other forms of devitalization; indeed, pericementitis is seemingly more certain to follow than where death has occurred from causes enumerated. The best plan is to remove at once.

Treatment of Superficial Pulpitis.—Inflammation of the pulp may, as already stated, be limited in its area of action, not spreading to any extent beyond the crown portion; this slight irritation may or may not be accompanied by acute pain. The tooth, however, is never wholly comfortable. Attempts have constantly been made to save these pulps by capping, but it must be acknowledged with only a moderate degree of success. The reasons for this have already been fully stated, and it therefore only remains to give the general treatment.

If pain is an accompaniment, the inflammation must be reduced by mechanical and antiphlogistic measures. These consist in the removal of all decayed matter pressing upon and continuing the irritation of the pulp; local depletion of the congested vessels by bleeding and then thoroughly syringing with lukewarm water, to remove all particles of loose matter. The pulp may be temporarily capped by an agent or combination of agents. These should, first, destroy all bacterial germs; second, obtund pain; and, third, destroy septic emanations. To effect the first result, the agents that may be used are numerous. Of these, carbolic acid justly holds a high place; but this, while superior as a germ-destroyer, is a powerful escharotic, and in practice its use in full strength has been found not altogether satisfactory. Its valuable properties are, however, manifested when reduced to about 20-per-cent. solution. Carbolic acid is a local anæsthetic of considerable importance and can usually be depended upon to relieve the pain of pulpitis, but is more effective when combined with iodoform. The fact that this has the dual properties of an antiseptic and an anæsthetic of nearly equal value to chloroform renders it superior to all other agents for this purpose. As these two agents cover the three desired qualities, they are recommended as fulfilling the requirements of an excellent and very effective application. The medium to retain these in position may be the oxide of zinc; they should be combined at the moment of using and placed gently over the pulp. If it is found necessary to dismiss the patient for the time, a temporary filling of gutta-percha should be placed over this, care being taken not to press upon the temporary covering. To avoid the possible disturbance from the products of decomposition—always a possible factor of disturbance in these pathological states—it is safer to leave a passage through the temporary filling for the escape of an excess of gas. This is readily made by building the material round a canal-plugger and upon completion withdrawing it. Treatment of these teeth should never be attempted without this precautionary measure. Ordinarily, one or two applications will give satisfactory results; but if systemic conditions are unfavorable, the inflammation will not easily yield to palliative treatment, and resort must be had to the destruction of the pulp either by the arsenical application or by the removal of the portion of the pulp most diseased and the capping of the balance. This latter treatment is preferable in both cases, for, as already stated, arsenic does not act readily on inflamed surfaces, and a removal of a section before applying it is a matter of necessity. The plan of cutting out a portion of the pulp was probably first suggested by Dr. Allport of Chicago. It consists in the excision of a portion of the pulp at the orifice of exposure, drawing the edges of the incised part together and inducing their union, and in this manner closing the wound. From the "extreme delicacy of the operation," Dr. Allport regards it as "rarely a practical one." Witzel of Germany suggested in 1879 a modification of this. His plan was to treat with arsenious acid, and then after a limited time to cut out the crown portion and preserve the balance, or stump, of the pulp by capping. As the use of arsenic must necessarily sooner or later destroy the entire pulp, this mode cannot be recommended. Cases very frequently occur in chronic pulpitis where this operation of partial extirpation is

necessary; this is readily performed with a minimum amount of pain by the use of local anæsthetics. The pulp may be placed under the influence of chloroform, a drop or two being sufficient; or it may be benumbed by rhigolene, ether-spray, or cocaine; or an application may be made of iodoform paste—iodoform, carbolic acid, and oxide of zinc. If either the first or the last be used, time—from five to ten minutes—must be given for the action of the agents. Then with a sharp burr revolved rapidly by a dental engine the most highly-inflamed portion can quickly be removed. This accomplished, the pulp may be placed under a non-irritant antiseptic dressing, as oil of cajeput, and eventually be capped or destroyed by arsenic, as may be desired.

The treatment of *deep-seated pulpitis* is substantially the same as for that just described, except that any attempt at amputation must, from the nature of the case, be futile. The indications here are acute pain, generally complicated with slight persistent irritation, which will be manifested by pain upon striking the teeth. The aim must be to reduce the inflammation as much as possible by the means proposed in superficial pulpitis. Avoid any attempt at destruction by arsenic, as the effect of this would simply be to increase the irritation. It is better and safer to keep the pulp under the dressing until the acute inflammation destroys the vitality, and then remove before the period of putrescence. The point to be enforced is to avoid over-treatment. Removal of the pulp is the only effectual course to pursue, for anything less than this is almost sure to end in disappointment.

The management of *gangrenous* or *putrescent pulps* is probably one of the most difficult and unsatisfactory of any of the operations the dentist is called upon to perform. These may be classed under two forms—the one where death has occurred from extrinsic, and the other from intrinsic, influences. The liability of the anterior teeth in early life to receive blows makes the presentation of teeth having dead pulps, and yet being at the same time free from decay, not unusual. Again, regulating teeth frequently produces a similar result. Thermal action in young teeth too early filled with metal, exposures, etc. may produce devitalization. Blows or any sudden movement may result in strangulating the sources of nutrition at the apical foramen, or they may cut off the delicate connections entirely; but in the writer's judgment the effect is doubtless produced by strangulation. The reason for this conclusion is found in the fact that in regulating teeth where the movement is comparatively regular and without sudden jar the same result is sometimes apparent. The fact that this occurs at all should relegate to the obscurity of the past the practice of the rapid separation of teeth by the wedge, mallet, screws, and other barbaric instruments of the earlier professional life, for they certainly now have no place in the proper treatment of teeth.

From whatever cause death occurs, the fact must be remembered that the appearance of quiescence and comfort in the organ is wholly deceptive, and that it is ready to arouse to violent inflammation the connecting and surrounding tissues on apparently very slight disturbance. A dead pulp may remain for years—and, it may be, for life—very quiet if not exposed by caries, but may in a few hours produce violent pericementitis

if exposed to the action of the atmosphere. It is, therefore, oftentimes a question in the diagnosis of such a tooth whether the great risk warrants meddling with it at all. The prognosis must take in the possible results from systemic conditions. If these are unfavorable, it would be much better to allow the tooth to remain quiet rather than risk the more serious evil of acute pericementitis, alveolar abscess, and possibly, in a depraved habit of body, necrosis. All teeth with dead pulps are subject to this, but those sealed in a cavity are peculiarly liable to take on extreme manifestations. The preliminary treatment must first be, if devitalization has occurred in a tooth without pulp-exposure, to make an opening through the enamel and dentine into the pulp-chamber. This is best accomplished in the anterior teeth by the use of the engine, to penetrate the enamel at the basilar ridge. Then take up the hand-drill, care being taken to point the drill in the direction of the long axis of the root. The entrance of the drill in the pulp-chamber will be manifested by a sudden dropping into a cavity. This accomplished, drilling should cease and an application of an antiseptic be made—eucalyptus oil, permanganate of potash, or iodoform—and sealed up, care being taken to leave the before-described vent through the filling; the object of this care is to avoid any undue irritation and to prevent the development of germs. On the second visit the devitalized pulp may be removed. Whether the odor of decomposition be present or not, the treatment should always be based on the supposition that putrescence has commenced. Ordinarily, there is no difficulty in the removal of the decomposed pulp: a slight twist of the barbed broach will bring away all that may remain.

The odor of putrescence is ordinarily present. The product of this decomposition—principally sulphuretted hydrogen—is undoubtedly the prime factor in pericemental disturbance, and the importance of eliminating this cannot be overestimated. The amount of pressure from this rapidly-developing gas is very great, and until this is overcome filling of the roots must be regarded as a very dangerous operation. It is difficult, owing to the contracted space in the canal, to make any application that will reach all parts of the tooth and chemically change the gaseous products; hence a vent must be left, as described. The philosophy of the treatment must be based on the conditions present, the rapid development of bacteria, the generation of gas, and septic poison requiring an agent or agents that will meet these distinct conditions. While it is true that an ordinary antiseptic, such as carbolic acid, boracic acid, salicylic acid, etc., may destroy the bacteria present and prevent further decomposition, it is equally true that the conditions are not fully met; besides, the former in full strength is too irritating, and is not very effective in reduced form. It does not act chemically on the products of decomposition before mentioned, nor do any of the ordinary antiseptics. The subject was first clearly stated by Dr. Litch of Philadelphia,[1] and it is to his work that we are really indebted for the only intelligent answer to the query, What shall be done with putrescent pulps? After discussing the character of antiseptic agents, he says:

[1] *Cosmos*, February, 1882.

"A careful discrimination must be made between the powers, respectively, of such antiseptics as carbolic acid, creasote, oil of cloves, oil of thyme, oil of cajeput, etc., and such other antiseptics as chlorine, bromine, and iodine, which, in addition to their antizymotic power, are true chemical antagonists of those sulphuretted-hydrogen compounds of which putrefactive gases are constituted, such gases being immediately decomposed by them, their hydrogen element going either to the chlorine, bromine, or iodine, to form, respectively, hydrochloric, hydrobromic, or hydriodic acids, the sulphur being in each case precipitated.

"This can readily be demonstrated by acting upon a small portion of ferrous sulphide with dilute sulphuric acid and passing the sulphuretted-hydrogen gas which will result from the reaction through tincture of iodine. A milky precipitate of sulphur will at once appear, and at the same time the characteristic color of the iodine will disappear in consequence of the conversion of the iodine into hydriodic acid, a heavy, colorless gas which remains in solution in the water present in the alcohol of which the tincture is made. . . . .

"If the sulphuretted hydrogen is passed through the strongest possible solution of carbolic acid, no such precipitation of sulphur occurs; no change either in the appearance or chemical constitution of the carbolic acid is manifest. . . . . No matter how thoroughly the odor of putrefaction in a room or in a tooth may be masked or disguised by the characteristic odor of carbolic acid, creasote, oil of cloves, or, indeed, any antiseptic oil, the gases are none the less present, although their odor is neutralized; the disinfection is only apparent, not real. The further formation of putrefactive gases may be prevented, but the decomposition of those already formed must be accomplished by those chemical agents bromine, chlorine, or iodine."

It is questionable whether the position of Prof. Litch can be successfully refuted. Practice demonstrates fully the correctness of the theory, and since the adoption of this mode of treatment the writer has had more satisfaction and far less anxiety in the management of these cases than at any former period. The mode he adopts is to syringe out the canal thoroughly with warm water to which a small amount of listerine has been added. Then take about the twentieth part of a grain of iodoform[1] and moisten it with a 20-per-cent. solution of carbolic acid; carry this on a few fibres of cotton to the extremity of the canal and then seal up the crown with gutta-percha, leaving the vent through the filling. It may require repeated applications to remove the odor of putrefaction. The same effect has been said to be produced rapidly by the permanganate of potash, but it is questionable whether its low germ-destroying power makes it as valuable as some other agents. Dr. Miller[2] has very satisfactorily demonstrated the comparative value of various antiseptics, the bichloride of mercury standing at the head of the list as a germ-destroyer. While this is true of a very minute quantity of this agent, it may be equally true of a larger quantity of a weaker one. But in-

[1] The writer does not wish to be understood as asserting that iodoform stands in the same chemical relation to H_2S as iodine, but that in its clinical presentations it seems to be equally as effectual.

[2] *Dental Practitioner*, June, 1884.

crease in quantity is not always possible, as a very strong solution of permanganate of potash would probably result in discoloration of the tooth. Other antiseptics can, however, be used in large quantities without risk, and with results equally good as with the bichloride of mercury. In illustration of this, sulphate of quinia is one of the very best germicides in and around inflamed gums. The writer has had better results from this than from any other remedy. The theory of its action is that, in addition to its germ-destroying power, it inhibits the migratory movements of the white blood-corpuscle, and thus retards inflammatory processes.

The removal of all odor from the pulp-canals is supposed to be the guide to determine the time for filling them. It must be borne in mind that the pulp practically extends throughout the dentine, and that there must be a vast amount of microscopic tissue necessarily left in the canaliculi for future decomposition or discoloration; this is undoubtedly the cause of the change of color, more or less pronounced, in all these teeth. Care should be taken to have the antiseptic fluids pass well into the tubes, and to accomplish this by imbibition time must be given. A tooth should, therefore, be kept under an antiseptic for several weeks before filling.[1]

The next consideration is as to the filling material to use for this purpose. This is of far more importance than is generally conceded. The old plan was to fill always with metal, gold, or tin, and the results, while excellent, were not equal to those effected by other modes, for reasons now well understood. Wood, and even cotton saturated with carbolic acid, have been used. Gutta-percha, the oxyphosphates, and the oxychlorides have each found earnest advocates.

The necessity of having a thoroughly compact and solid filling would seem to require no argument, yet there are many who appear to think facility of removal a prime requisite. The writer's judgment, based on a long experience in filling canals, is that no canal can with safety be left loosely filled even with the best germicide present. That a gold filling will give better results, provided it is packed solidly, than a cotton, felt, or any other loose substance, has been demonstrated too often to be now successfully controverted. It is certainly settled that a canal must be impervious to fluids and the entrance of atmospheric air made impossible. If a material that combines solidity with antiseptic properties can be used, that should take precedence. Of the plastics, the oxychlorides alone meet this requirement; the peculiar property of these and their deep-penetrating power should bring them into more general use. The writer's attention was early called to this by the remarkable results attained by the use of oxychloride in the treatment of alveolar abscess, in which teeth have repeatedly been rendered comfortable, loose teeth tightened, the production of pus stopped, and the fistula closed by simply filling the canal with oxychloride of zinc. The constant repetition of these results led to the abandonment of gold or tin and the substitution of this material, and years of practice have

[1] Dr. Kirk (*Cosmos*) suggests the use of sodium carbonate in pulps of this character. He dries out the cavity and introduces a small particle of this agent, leaving it there a short time. It can be used in crystals or in solution.

served only to confirm this judgment. Chronic pericementitis, or even chronic alveolar abscess, is oftentimes best treated by simply filling the canals.

The mode of insertion is quite a simple one. A few fibres of cotton dipped in a thin batter of the oxychloride are passed into and packed solidly in the canal or canals. This becomes a solid mass in a short time, and if properly placed will be impenetrable to any of the fluids permeating the tooth. A method proposed by Dr. Hullihen of Wheeling, Va., in these cases was to leave the canal unfilled and make a vent at the free margin of the gum by drilling a hole through the root to the canal. This makes it a drainage-conduit, and, while the tooth may be comparatively comfortable, it is always malodorous and liable at any time to take on more complicated pathological conditions. This operation should be used only as a means of temporary relief. A mode of filling roots adopted by many good operators is to pass cedar saturated with carbolic acid into the canal; the swelling of the wood is supposed to perfectly fill the canal. Theoretically, this seems a very faulty operation. There is no certainty as to the length of time carbolic acid will retain its power, and wood is always a good absorbent. Reference need only be made to the condition of old wooden pivots and the adjacent tissue to furnish argument against the practice.

The *dry gangrene*—so called in contradistinction to the previously-described moist gangrene—is not of much pathological significance. The pulp is shrivelled and the canal is entirely free from the results of decomposition. The tooth retains its color. The reason for this state of the pulp is not very clear. It, however, according to the observation of the writer, occurs principally in very dense teeth, especially in the teeth of old age. This leads directly to the supposition that there has been a gradual filling up of the tubuli with secondary dentine, preventing the free circulation of fluids, if not stopping them entirely; this is evidently the case in senile dentine. While the possibility of this process is doubted by Wedl, who regards the translucency described by Tomes as dependent on the continuation of the "process of the dentine cells existing in the translucent portions of senile dentine, and that, as they still retain the property of imbibition, it may be assumed—with a certain degree of plausibility, at least—that these processes as well as other tissues in the decay of advanced age have lost more or less their distensibility, that their central vitreous substance has disappeared, and that, together with the investing walls of the dentinal tubules, they have become closed in such a manner that the entrance of atmospheric air is no longer possible." The writer's observations on senile teeth, and also on teeth lost at an early period of life through extreme density, are fully in accord with the conclusion of the elder Tomes. If these conclusions be accepted, the dryness observable in senile dentine, resulting in dry gangrene of the pulp, can be readily understood and the latter condition accounted for.

Teeth with mummified pulps (dry gangrene) require no attention on the part of the operator further than to remove the remains and fill. They never, so far as observed, are a source of irritation, and it is rare that they come into the hands of the dentist for treatment.

Nodular Dentine.

Under this name are classified the secondary deposits found in pulps. They may be purely physiological in character, and are not necessarily pathological. Indeed, it is difficult to draw the dividing-line between these two conditions, for the one may run into the other through the ordinary processes of development.

The formation of secondary tissue is dependent on so many and such diverse conditions that it is impossible to class it as belonging to any particular period or state. It may be found at all ages, in all teeth, and it has been observed even in deciduous teeth. There is one law, however, that seems universal in its application, and that is that the structure must average a superior grade. In other words, teeth of strong, dense character, yellowish color, are peculiarly liable not only to new formations, but to have this extra development assume the nodular or granulated form.

The relations sustained by the pulp to dentine and the part the former takes in the development of the latter are better understood to-day than at any former period, but no satisfactory explanation has been attempted throwing light on the peculiar form dentine assumes or showing why at a certain period in development it changes its character. It is, however, well known that the new formation differs from the normal, or regular dentine, in the irregularity of the tubuli, there being a distinctive line of demarcation between the new and the old. All that is really understood in regard to it is that up to an uncertain period normal tissue is developed, and after that the formation assumes the character of secondary, or osteo, dentine.

Before considering the character of these formations it may be well to examine into the probable causes that lead to their origin. They may be classified under two heads:

1st. Increase of density.

2d. Irritation.

The increase of density may occur at any age, and the familiar example of senile dentine, with its superabundance of secondary tissue, is a common presentation. Between these two extremes may be found all degrees of formation, ending frequently in loss of the teeth, they being thrown out as foreign bodies. Increase of density necessarily means an increased deposition of the inorganic material in the organized body. If it be accepted that the pulp is capable of forming dentine, either normal or abnormal in character, at all periods—and this is not disputed—it follows as a natural sequence that the cellular formative elements must possess unlimited power of development which is not confined to the peripheral cell-layer, but is equally distributed throughout the pulp; that every portion must be so endowed and be equally amenable to the universal law of formation. Secondary dentine is, therefore, not confined to the pulp proper in the form of minute grains or larger nodular calcifications, but is manifested in the translucent dentine of Tomes, which is but another state of the same development. Wedl does not regard this as proved, as by the use of "heated dilute hydrochloric acid" he was able to demonstrate that the "processes of the dentinal

cells" were brought into view. "In these experiments no essential differences could be discovered between the translucent and less diaphanous portions of the dentine."[1] These experiments would seem conclusive, especially those subsequently made to demonstrate the power of imbibition remaining in the fibrils or odontoblastic prolongations; but the means resorted to seem fatal to the conclusions. Secondary dentine is "not as dense as normal dentine and has less carbonate and more phosphate of lime" (Schlenker), and consequently would be less able to resist the action of powerful reagents. The result would necessarily be a reopening of the canals in the dried specimens, and because coloring-matter could be injected into the tubuli it does not necessarily follow that the fibrillæ, while retaining the form, also retained normal vital powers. The inference drawn by Wedl does not seem justified by the results. The importance of determining this must be apparent when it is considered that if the transparent zone is not recognized as a consolidation into secondary dentine it will be difficult to understand the law of its formation anywhere, and the nodular deposits must remain an enigma. Experiments with reagents are not always satisfactory, for the reasons stated, and the matter must be determined principally by inference, by analogy, and by results. The secondary formations in the tubuli occur in exceptionally dense teeth; the color simulates that of normal tissue, and its power to resist the encroachment of caries proves its comparative density. The well-known fact is that so-called eburnated dentine is but a form of arrested decay, and that in all very dense teeth caries progresses with extreme slowness—and in these the transparent zone is marked—indeed, is never seen in soft-structured teeth. In exceptional cases of extreme density there appears to be a total cessation of nutrition; the power of imbibition by natural processes is in a great measure lost and the connection with the pericementum broken up. This is remarkably illustrated in the loss of single and entire sets of otherwise perfectly-formed teeth, and that through no pathological changes, as in pyrorrhœa alveolaris. A patient of the writer, aged thirty-five, with a remarkably beautiful and dense set of teeth, gradually lost them all, until, edentulous, he was forced to resort to artificial substitutes. Microscopic examination of thin sections by high powers failed to show the slightest trace of tubular formation except in the inner third nearest the original pulp-canal. The whole tissue was diaphanous and apparently homogeneous. It was clearly a case of non-nutrition. Dr. Kirk[2] in a paper on the care of the children of the Institution of the Deaf and Dumb of Philadelphia illustrates the possibility of increasing the density as well as producing nodular deposits at a very early age. He says: "The majority of pupils are admitted between the ages of ten and twelve years. After a year's residence in the institution —during which time they are given excellent care in all that relates to their physical welfare—a marked improvement will be observed in the character of their teeth: they will be found exceedingly hard and dense, making the wear and tear on cutting instruments very great. . . . . But the most conclusive evidence which I have met with of the value of the

[1] Wedl, *Pathology of the Teeth.*
[2] "Relation of Food to Teeth," *Dental Office and Laboratory.*

diet-table, so far as the nutrition of their teeth is concerned, is the unusual number of cases of arrested caries and the formation of so-called secondary dentine. . . . . As showing still further the abundance of bone-forming material with which the blood is supplied, I have removed in two cases large pulp-nodules from the sixth-year molars of children not over eleven years of age."

Without extending the argument farther, it may be assumed that the facts warrant the opinion that the new formation in the tubuli is in direct ratio to the density.

The effect of *irritation* is well known to be a cause of new formations. The increased development of the cementum at the apex of roots—familiarly known as exostosis—is produced by a slight irritation, as the wearing of a plate over a root, the jar of clasps attached to a plate, the malocclusion of teeth, etc., etc. On the other hand, an excessive irritation produces absorption or destructive pathological conditions. Reasoning from this well-understood fact, it would be expected that the law of hypertrophy, as applied to bone, would give equal results with dentine, so nearly allied to it in character. The very familiar example of the wearing away of the anterior teeth furnishes us with an answer to this proposition. New formations proceed equally in proportion to wear, provided that wear is not too rapid. If the process is very slow, secondary dentine will develop gradually until the entire coronal pulp is obliterated and the tooth worn down to the gum-border. On the other hand, if too rapid, the pulp is quickly exposed. This is exactly a repetition of the before-mentioned result in slow caries. The progress of the disease produces an amount of irritation to develop new formation. In medium- or soft-structured teeth this is not possible; hence rapid destruction.

When we extend this familiar process of formation and destruction to the growth of new formations of the pulp, we are led at once to the conclusion that irritation is the principal—though possibly not the only—cause of secondary deposits. It is very probable that the process of mastication has very much to do with nutrition and increased inorganic deposits. It has long been observed that those teeth in constant use are more perfectly formed and resist caries better than those rarely brought under the forces of mastication. This can be accounted for only by the constant jar and slight irritation producing the before-mentioned result. It has yet to be demonstrated by actual observation whether these teeth are more liable to nodular calcifications than others, but theoretically this should be the case.

The effect of caries in producing new formations in direct line with the disease is beautifully shown in an illustration from Schlenker.[1] In this case the new formation is clearly the result of irritation carried through the tissue and proceeding in proportion to the caries. The same result is seen in Fig. 482, from the same author, in which the new formation extends over a still greater surface. By the wear from a clasp, a metal filling, especially gold, may produce a similar result by the constant, though slight, irritation through changes of temperature. A similar effect is usually expected from capping pulps; but this expec-

[1] *Untersuchungen über die Verknöcherung der Zahnnerven. Vierteljahrsschrift. f. Z.*

tation is rarely realized, as here the irritation is excessive and becomes a destructive force. In absolute inflammation of the pulp new forma-

Fig. 481.

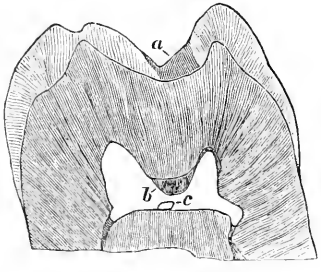

a, caries; *b*, adhering dentine formation; *c*, a free nodule with the connection dissolved.

Fig. 482.

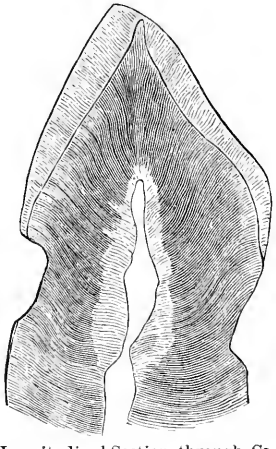

Longitudinal Section through Canine. Secondary dentine the result of a clasp (Schlenker).

tion is impossible. Schlenker says of inflammation of the periosteum followed by abscess that "if in such teeth secondary dentine is found it must not be accepted as positive that this is the result of inflammation of the pulp. If the pulp is inflamed, all new formations cease in hard tooth-structures."

Fig. 483.

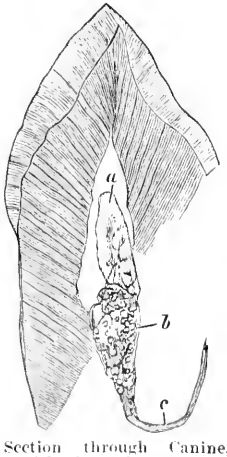

Section through Canine, with the Pulp; *a*, entire pulp; *b*, partial calcification; *c*, part of the pulp without nodules (Schlenker).

The same author divides the new formations into six distinctive sections: 1. Enameloid; 2. Enamel-dentoid; 3. Dentoid; 4. Dentine-osteoid; 5. Osteoid; 6. Calcoid. In regard to the former, the enamel nodule, he says: "At the yearly meeting of the Central Society of German Dentists held at Freiburg, 1875, I exhibited two free enamel nodules found in the pulp-tissue, since which time I have added three others free and two specimens of adhering enamel formations."

From the enamel-dentoid, or combination of enamel and dentine, he has two examples. In the dentine-osteoid the combination of cement and dentine takes place. The osteoid, as its name implies, consists wholly of cement, and the calcoid the calcification, in the connective tissue of the pulp, and felt as grains of sand.

The calcification of the tissue of the pulp into nodules is finely represented by an illustration from the same author. The symptoms of calcification are not sufficiently marked to render the diagnosis an easy one; indeed, the decision must rest largely on the character of the teeth and the exclusion of other sources for the neuralgic pains present. The usual

mode of diagnosing pericementitis fails here, for, as before stated, violent inflammation renders new formations an impossibility. The pain is in paroxysms, worse during the night and accompanied with a boring sensation.

Ordinarily, the new development is not a cause of neuralgia; indeed, it may be considered quite exceptional that this occurs, for in some one of its forms secondary tissue may be said to exist in every mature tooth. When, however, it assumes the granulated form, producing unequal pressure on the sensory nerves of the pulp, the result is pain—oftentimes of the most aggravated character. This may be confined to one tooth, but frequently will be repeated in one tooth after another until the entire denture is involved. Dr. Garretson mentions a case of this character where each tooth in turn was extracted, and all presented nodular calcification. Schlenker also gives a large number of cases.

The TREATMENT must be either to destroy the pulp or to extract the tooth; in most cases the former course will give relief. The suspected tooth must be carefully drilled through to the pulp and the usual application of arsenic made. If devitalization fails, nothing remains but to extract. Efforts have been made to reimplant these teeth, after removing all calcific deposits, and with some degree of success.

POLYPUS OF THE PULP.

In teeth much broken down by caries there is necessarily a constant irritation of the exposed pulp. This does not always result in a slow destruction of the organ, but eventuates in a hypertrophied condition that in time fills up the cavity of decay. In the experience of the writer these polypi are more frequently found in the inferior molar teeth where the crown has been hollowed out to a thin external wall. The increased development may be of small size or it may fill the entire cavity. Its character is readily determined by pressing it to one side, when it will be found to be a bulbous formation attached by a constricted neck to the coronal pulp. This will distinguish it from an epulis, which is attached to the alveolar walls. It is not ordinarily very sensitive. It has a dark-red color and is of a "spongy or fleshy consistence." "It contains an abundance of roundish and spindle-shaped cells, the bodies of the cells varying slightly in extent, which, together with a small amount of fibrous intercellular substance, comprise the principal portion of the tumor. The groups of cells are in long rows and have a radiated arrangement. The cells, which are provided with processes, unite here and there to form a network; rows of spindle-shaped cells also are met with; the blood-vessels pursue a tortuous course from the interior toward the periphery, are numerous, comparatively large; and invested with thick fibrous sheaths. The type presented by the capillary ramifications is different from that found in the pulp. Nerves or the remains of the parenchyma of the pulp are not to be seen. . . . . The parenchymatous connective tissue is the seat of the proliferation described as sarcoma of the pulp, in which the parenchyma gradually is destroyed, as is indicated by the absence of nerves and the altered character of the blood-vessels. As the sarcoma

is located upon the outside of the remains of the pulp, it serves in a measure to protect the latter" (Wedl).

The tumor may be purulent in character, though the amount of pus is limited. A number of such cases in the experience of the writer gave no evidence of pus-formation.

This proliferation of the pulp is principally confined to comparatively young teeth and teeth imperfectly calcified. They bleed readily at the slightest touch, but the ordinary result of inflammation of the pulp is not present. They do not end in pulp-devitalization, pericementitis, alveolar abscess, nor are they usually very uncomfortable. They seem to be, as Wedl expresses it, secondary formations, and furnish a protection to the central organ.

In cases of fracture where the pulp has been suddenly and violently irritated there may be an enlargement of the pulp of a somewhat different character. This will be extremely sensitive. In other respects it is similar to the ordinary polypus. "In microscopic structure this sprouting of the pulp differs little from the insensitive polypus, but its vitality implies a more abundant nerve-supply" (Salter).

TREATMENT.—The difficulty of giving any treatment to cases of fungous growth has long been understood. The polypus can readily be cut away, but it will return, and for the reason laid down; under the destruction of the pulp by arsenic it resists that agent, and hence success has not warranted prolonged effort in this direction. Coleman[1] gives a mode of treatment that in his hands has been satisfactory. He says: "We first dose the growth with carbolic acid, to deaden its sensitiveness, and then with a scythe-shaped lancet cut away as much as possible. After the bleeding has ceased we carry out the nitric-acid process." This was described at length in considering the subject of capping. It consists of applying the strongest nitric acid on a disk of cardboard to the pulp and retaining it there for about thirty seconds. It is then removed and the pulp capped.

Dr. B. G. Mærcklein recommends the continued use of iodine upon and around the fungous growth. He says: "After removing all foreign substances, dry the cavity as carefully and thoroughly as possible, and then apply the tincture of iodine with a pledget of absorbent cotton or bibulous paper until the entire growth has been covered with the iodine; after which, seal the cavity in the usual manner. This should be repeated every twenty-four hours until it has been entirely destroyed. If any portion of the pulp in the canals resists this treatment, it should after the expiration of ten days be devitalized by arsenic and the root or roots filled in the usual manner. For this purpose I prefer the oxychloride of zinc to any other material. If the fungous growth should fill the entire cavity, as is sometimes the case, it is necessary to modify the first part of the treatment. In such cases proceed as follows: Take small pledgets of bibulous paper or absorbent cotton saturated with tincture of iodine and place them between the fungoid and the walls of the cavity until as much pressure has been made as is consistent with the comfort of the patient, but in no case should it be carried to the extent of giving pain. This dressing is to be repeated daily until sufficient room has

[1] *Dental Surgery and Pathology.*

been obtained to proceed as in the first case. Some of the last class of fungoid growths are very persistent in resisting treatment, but I have never seen a case that did not yield where treatment was kept up for any length of time."

The writer's experience in various modes of treatment does not justify a hopeful prognosis in these cases, and the final result has been a resort to extraction as the only effectual remedy.

DISEASES OF THE PERIDENTAL MEMBRANE.

By G. V. BLACK, M.D., D.D.S.

The peridental membrane covers the root of the tooth and serves to unite it with its alveolus. In its structure it is very different from a periosteum, and its functions are different. The connection of the tooth with the wall of the alveolus is more that of an immovable joint, and yet a joint that permits a certain passive motion by which the tooth is cushioned, so to speak, against the hardships of severe blows and concussions that it is liable to receive in the performance of its peculiar functions of tearing and grinding food. This joint has, however, none of the elements of the joints that are movable by the muscles. There is no cartilage and none of the other elements of the movable joints intervening between the root of the tooth and the bony walls of its alveolus: the joint is effected by the interposition of fibrous tissue, with a sparse intermixture of cellular elements. In the formation of this joint the fibrous tissue is disposed in a definite form relative to the root of the tooth and the alveolar process. This is found to be, for the greater part of the root, in the form of a set of fibres running downward (toward the crown of the tooth) and outward (toward the alveolus), connecting with the alveolus.[1] These fibres serve to swing the tooth in such a way that, while it is permitted a very slight motion in its socket in any direction in response to a strain that may be brought against it, its position is regained at once when the strain is removed. This particular disposition of the fibres is found all over the body of the root of the tooth, but on the apex of the root and near the neck of the tooth the disposition of the fibres is different. At the apex the space between the end of the root and the alveolar wall is a little greater than elsewhere. *This I shall call the apical space* (Fig. 484). In this space the fibres radiate from the apex of the root to the alveolar wall in various directions without much regularity; yet it can generally be seen that there is a disposition to radiate *fanlike* from the apex of the root to the alveolus. Toward the rim of the alveolus the downward trend of the fibres is rapidly lost, and as the rim of the alveolus is passed this trend is reversed. In this way the fibres are gathered, as they pass from the

[1] In the descriptions given throughout this article I shall regard the tooth as a cone, with the crown as the base and the end of the root as the apex. Therefore, toward the crown, or base, is downward, and toward the apex of the root is upward, no matter whether the tooth be in the upper or lower jaw.

tooth, into rather a thick mass just over the rim of the alveolus, where they are continuous with, or merge into, the periosteum, which covers the outer surface of the alveolar process. This forms what has been termed the *dental ligament*. I will describe the gingivæ in connection with the diseases which have their beginnings in them.

The *blood-supply* of the pulp of the tooth and its peridental membrane is admitted to the apical space, usually, by a single arterial twig for each root. When within this space, it breaks up into a number of branches, and one of these enters the apical foramen, while the others pass down toward the crown of the tooth within the structure of the peridental membrane. These are generally found about midway between the root of the tooth and the alveolar wall, and in uninjected sections cut lengthwise will often give the impression that the membrane is composed of two layers, as we find it described in some of the older works. As these arteries proceed down the sides of the root they send out branches into the walls of the alveolus that anastomose freely with the arteries that supply the gums. And just at the rim of the alveolus there is a pretty rich plexus formed by union with the arteries of the periosteum and of the gum—the *gingival plexus*. This being the case, it is evident that the peridental membrane may receive its blood-supply from either of these two opposite sources. In alveolar abscess the blood-vessels of the apical space are often completely destroyed, but, as the anastomosis with the vessels of the gum over the alveolar rim and through the alveolar wall is so rich, the membrane does not suffer from lack of blood.

FIG. 484.

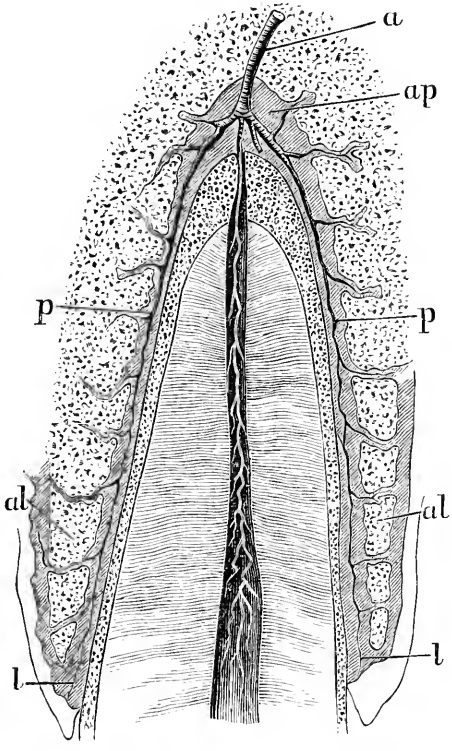

Root and Membrane of Tooth: *p, p*, peridental membrane; *ap*, apical space; *a*, artery; *al, al*, alveolar process; *l, l*, dental ligament.

The *nerve-supply* of the peridental membrane is also derived from two sources. These correspond perfectly with the sources of the blood-supply, and need no further description except to say that in this instance the principal supply seems to be from the direction of the gum and through the alveolar wall. This may not so plainly appear from anatomical examination, but experimental observation demonstrates that the

sensibility of the peridental membrane is not appreciably impaired by the destruction of the nerves in the apical space.

The peridental membrane is the *organ of touch of the tooth;* the enamel has no sense of touch. And the pulp is so encased within the hard structures of the tooth that it could not exercise the sense of touch if it possessed it; which, as a matter of fact, it does not. The pulp of a tooth conveys painful impressions only, and under normal conditions these impressions are aroused only by thermal changes. By means of the nerves of the peridental membrane, however, every touch upon the tooth is reported to the sensorium. These nerves are the proper nerves of touch for the tooth—as much so as are the nerves distributed to the finger-ends for the fingers. No other nerves of the tooth are so situated as to receive impressions made upon the tooth, and these must receive the impressions in a secondary way (which, by the way, is the case with all nerves of touch. In the fingers' ends these nerves are covered by the epithelium). When a tooth is touched, as by the tongue, by articles of food taken into the mouth, or by the finger, the peridental membrane receives the pressure, and through its nerves a sensation of touch is conveyed to the brain. Such a touch cannot affect the pulp of the tooth, because it cannot reach it; therefore the peridental membrane is the only organ of touch possessed by the tooth. This sense of touch is in normal conditions rather feeble, yet sufficiently pronounced to respond readily to very slight pressure on any tooth. That these nerves of touch are not distributed principally by way of the apical space I have satisfied myself by examination of the sensibility of this membrane after removing everything from the apical space. One of the most noteworthy observations I have made on this point was in the case of a young lady who had lost the pulp of the first bicuspid at a time when the apical foramen was still widely open, and through which another operator had inadvertently passed quite a large pellet of cotton. I found it necessary to cut through the alveolar wall in order to remove it, and I took particular care to remove everything in the apical space. The space was much enlarged by absorption, and was in a septic condition. In this case the pulp of the tooth was gone; the nerves entering the peridental membrane by way of the apical space were gone; and yet this tooth, at the earliest date at which the sense of touch could be differentiated from the sense of pain, was found to possess the sense of touch in a high degree. As progress toward recovery was made the sense of touch in this tooth became the same as in the others—or, in other words, it became normal. This and similar cases in which the same results were observed, establish the fact that the nerves of touch of the tooth are to be found in the peridental membrane, and that they are received—for the most part, at least—by way of the nerves distributed to the gum through the wall of the alveolus.

Therefore we find that the teeth are normally well supplied with nerves and blood from at least two different sources, and that, though one of these sources of supply may be cut off, they seem not to suffer materially on that account—at least, this is the case with the peridental membrane. Now, the cementum of the tooth is supplied with nutrient material from the peridental membrane. It follows that the loss of

some of the avenues by which this nutrient material may reach it will not materially impede its continued nutrition, and therefore will not materially lower its standard of health. This agrees substantially with what is seen in daily clinical experience. Teeth that have lost their pulps go on decade after decade continuing in the most perfect health. The sense of touch remains perfect; the connection of the tooth with the neighboring parts shows no signs of disturbance.

Diseases of the Peridental Membrane.

One of the first things that the student should recognize in the study of the pathology of the peridental membrane is the fact that it is subject to various forms of disease. Among these there are several distinct varieties of inflammation, which arise from distinct causes and require different treatment for their cure. No classification can at present be made that will be free from objections; yet a classification, even if not perfect, will assist in the comprehension of the details of the subject.

Classification.—1st. Traumatic pericementitis, or inflammation of the peridental membrane resulting from injuries.

2d. Absorption of the roots of the permanent teeth: (*a*) In diseased conditions of the peridental membrane; (*b*) After injuries and transplantations, replantations, etc.

3d. Pericementitis, or inflammation of the peridental membrane, having its seat in the *apical space* and following the death of the pulp of the tooth. This is the only inflammation of this membrane to which this term should be applied without the use of a descriptive adjective, and even here I think it is better to use the term *apical pericementitis.*

4th. Alveolar abscess. This abscess always has its seat in the apical space, and is a result of apical pericementitis following the death of the pulp of the tooth.

5th. Gingivitis, inflammation of the gingival border of the gum and lower border of the peridental membrane, occurring mostly from constitutional causes, including salivation from mercury, iodide of potassium, etc.

6th. Calcic inflammation of the gums and peridental membrane, a diseased condition dependent upon deposits of calculus, salivary or serumal, on the necks of the teeth.

7th. Phagedenic pericementitis, a specific, infectious inflammation having its beginnings in the gingivæ and accompanied with destruction of the peridental membranes and alveolar walls.

It will be noted that in this classification we have two distinct groups of pathological manifestations, the one having its beginnings in the apical space, and the other having its beginnings in the gingivæ.

Those *conditions resulting from injuries to the roots of the teeth*, and from replantations, transplantations, etc., will be treated in another article, to which the reader is referred. I will only treat of the pathology of absorption of the roots of the permanent teeth in those cases in which no previous injury has been observed.

On this point it may be stated as an axiom that *such absorption never*

occurs during the maintenance of the health of the peridental membrane. As to the conditions of this absorption we have very positive information; I cannot speak so certainly as to the nature of the causes which bring about these conditions. Absorption of the roots of the temporary teeth is in all respects a physiological process; the absorption of the roots of the permanent teeth cannot be so regarded; and yet an examination of the process in the two instances reveals the fact that they are identical in their nature, although the causes by which the process is set in action in the two instances are entirely different. Resorption of the roots of the temporary teeth is effected by certain cells known as *odontoclasts;* resorption of bone in the physiological processes of change of form is effected by cells known as *osteoclasts.* Each of these processes is physiological, and the cell or tissue that performs this function in each instance, is the same, the only difference being one of position. In each instance, as the calcific material is removed, the space is filled with newly-formed cells that crowd into the breach; so that newly-formed cells are always presented to the surface being absorbed. It is certain that these cells form a solvent that effects the solution of the calcific material, though it is not yet known precisely what this solvent is. It has been suggested by Rustizky and Krause that it contains lactic acid. This suggestion seems to have arisen from noting the behavior of these cells toward staining agents, and cannot be regarded as conclusive.

These cells not only effect the solution of the living bone, but they burrow into necrosed bone or pieces of ivory that are thrust into the tissues for the purpose of experiment (Billroth, DeMorgan, Tomes, Krause, Koelliker), and in this case the peculiar cells are to be found in the burrowings, the same as in the ordinary resorption of the bones or the roots of the temporary teeth. This shows us that the process of absorption is in no wise dependent upon the life of the tissue being absorbed. Further, other substances than bone may be absorbed. It has become quite customary among surgeons to use ligatures of animal membrane, such as catgut, silkworm-gut, etc., for deep sutures; these are left in, and are absorbed. In the microscopic study of this process it has been found that the leucocytes aggregate themselves about the ligature, and that in their presence its substance disappears in such a way as to form irregular pockets, the same as is seen in the absorption of bone. The cells crowd into the space gained, keeping it completely filled, until, finally, when the last particle of the ligature is removed, it is accurately represented by a solid cord of newly-formed living tissue. In case of the *sponge-graft* the sponge is removed in precisely the same manner, and is replaced by newly-formed tissue. In *modus operandi* these several processes are identical. In each instance an excitation of the tissue in the neighborhood of the substance to be absorbed is necessary, and it is also necessary that this excitation be not so great as to cause the formation of pus, as this, among other causes, will prevent the cells from performing their physiological function. In cases where a ligature has been used any considerable pus-formation in the immediate neighborhood is known to defeat the absorptive process. The presence of pus similarly arrests the absorption of other substances or tissues.

Now, by the application of the facts here presented we can know the conditions under which the roots of the permanent teeth are absorbed. There must in each instance be a mild form of irritation that will keep up local excitement of a particular kind. In the physiological processes this excitation is probably furnished by the nervous system. In the pathological processes of absorption the excitation is undoubtedly furnished by some local irritant which acts more or less continuously. What this irritant may be must be determined for each case independently. In many of the cases of absorption it will be found extremely difficult to determine the exact cause of the excitation, but in all cases that have come under my observation the tissues in the immediate neighborhood of the destructive process have been found hyperæmic and presenting the macroscopic appearance of granulation-tissue.

In many cases that present themselves to the practitioner it will be very difficult to assign a cause for this chronic irritation. One of the most frequent causes in my experience has been the protrusion of root-fillings beyond the apical foramen into the tissues of the apical space, where they keep up a very low degree of irritation. I have seen many cases in which this was the only cause that I was able to assign for the difficulty. These cases have nearly all been those in which I have myself filled the roots with gold. But since the filling of root-canals with gutta-percha has come in vogue I have met with a few cases in which the protrusion of that substance seemed to have acted as a cause. It is plain, however, that these materials will not invariably produce this result; for I have seen cases where the root-filling had extended into the tissues, and so remained for years without evil consequences.

Some of the cases that have come before me have seemed to arise from some cause entirely hidden. In one very remarkable case eight teeth of the upper jaw had lost their roots by absorption. Three of the eight had root-fillings that I had introduced fourteen years before; in the other five the pulps were alive. The process seemed to have been about the same in those with living pulps as in those in which the pulps were dead. The woman had become very intemperate and excessively fat. A number of cases have come to my notice in which this absorption has occurred on the roots of teeth otherwise healthy.[1]

The absorptive process in these cases is usually very irregular. It may attack the root at any point and remove its substance in the most irregular manner, or the root may be removed almost as are the roots of the temporary teeth. Irregularity of absorption is, however, the rule. This affection presents no symptoms by which it can be recognized before it becomes manifest by the loosening of the crown of the tooth. It is not amenable to treatment.

Apical Pericementitis, or Pericementitis following the Death of the Dental Pulp.—This, together with its resultant, alveolar abscess, is

[1] Since writing the above I have met with a case in which all of the posterior root and the floor of the pulp-chamber of a lower molar has disappeared by absorption. The tooth had a large contour-filling occupying the posterior half of the crown, which I placed there ten years ago, after capping the pulp. The pulp was alive, as I found by drilling into the pulp-chamber.

the most painful affection to which the teeth are liable. It consists of an inflammation of the peridental membrane, always beginning in the apical space, in the immediate neighborhood of the apical foramen. It never occurs during the life of the pulp of the tooth, or, if so, not until the pulp is irreparably inflamed. The tissue involved in the inflammatory process is encased between the walls of the alveolus and the root of the tooth in such a way as to hinder its expansion when engorged by the influx of blood. The tissue, although in normal conditions not unusually sensitive, is richly supplied with nerves, and in the inflammatory state soon becomes exquisitely painful. This inflammation is very prone to terminate in suppuration, with the formation of *alveolar abscess*. The affection may be ushered in immediately upon the death of the pulp of the tooth, or it may be indefinitely delayed. In some instances this inflammation may precede the death of the pulp, the inflammation of the latter seeming to be projected through the apical foramen. This, however, very rarely occurs, the rule being that the death of the pulp precedes the beginning of the inflammation in the apical space, usually some days, or until putrescence of the pulp has proceeded so far as to give rise to poisonous material, which escapes into the tissues by way of the apical foramen. In very many cases this is delayed for weeks or months, or may not occur even during a lifetime. The rule, however, is that it does occur sooner or later. It may be very positively stated that no tooth with an empty pulp-chamber is safe from apical pericementitis.

The SYMPTOMS of acute apical pericementitis vary much in different cases, but this variation is more as to the severity of the pain than as to the character of it. It is usually ushered in by a dull pain referred to the affected tooth. Usually this is at first somewhat relieved by pressure, but as the inflammation increases in severity pressure of the opposing teeth causes extreme pain; and, as the swelling of the tissues in the apical space causes a slight elevation of the tooth in its socket, thus bringing the whole force of the occlusion upon this tooth, this becomes the source of extreme suffering. Now the mucous membrane over the affected root begins to present signs of inflammation; it becomes a deeper red than the other parts of the mucous membrane, and the pressure of the finger causes pain. As the case progresses still farther the gum is liable to assume a purplish hue. The pain is continuous and becomes throbbing, each pulsation causing an exacerbation of the pain. Pus is usually formed in the apical space very quickly—within twenty-four hours—but sometimes is delayed for several days. With the formation of pus the case becomes one of acute alveolar abscess, which will be described presently.

The DIAGNOSIS of acute apical pericementitis usually presents very little difficulty. Pain caused by pressure on the affected tooth is a constant symptom that distinguishes it sharply from hyperæmia, or inflammation of the pulp of the tooth. In diseases of the dental pulp the affected organ does not become tender to the touch—at least, not until the inflammation has passed through the apical foramen, thus ushering in apical inflammation. In apical pericementitis the pain is always referred definitely to the particular tooth. In pulpitis the patient is often

uncertain as to the exact location of the pain; such an uncertainty on the part of the patient is in all cases sufficient to exclude acute apical pericementitis. Pain referred to different parts of the face, the ear, or other remote points, in the absence of a tooth sore to pressure, also excludes this disease as the cause, while it is characteristic of the affections of the pulp of the tooth. If the practitioner will keep well in mind the functions of the two organs, there cannot be much difficulty. The peridental membrane is the organ of touch of the tooth, and therefore definitely locates its ailments. The pulp of the tooth is not an organ of touch, and therefore does not definitely locate its ailments, but is especially prone to cause reflected pain, or pain referred to associate or distant parts. This is characteristic of the diseases of those organs that have no nerves of touch, as is seen in pain referred to the knee in hip-joint disease, pain referred to the region of the scapula in disease of the liver, pain referred to the brow in inflammation of the iris, etc. This peculiarity occurs so frequently in diseases of organs having no sense of touch as to make it a general law of symptomatology. Another point of prime importance is the fact that the dental pulp is especially sensitive to thermal changes, and that this sensibility is markedly increased in its diseases. The peridental membrane, on the other hand, has no special sensitiveness to thermal changes, and such sensitiveness is not developed to any considerable degree in its diseases. Therefore the existence of special sensitiveness to thermal changes in connection with a given case marks it at once as an affection of the pulp. There seems to be but one condition in which thermal change causes marked pain in acute or chronic apical pericementitis, and this is in cases when the pulp-chamber of the tooth is filled with gas in such a way as to cause pressure on the tissues of the apical space. In this case heat will give rise to an expansion of the gas, increasing the pressure and the pain, while the application of cold will relieve it. This, then, is diagnostic; for in affections of the pulp both heat and cold cause pain when suddenly applied.

Chronic apical pericementitis has all of the characters of the acute variety in a modified form. The patient usually complains of soreness of a particular tooth. This may be considerable, or it may be so slight as to occasion annoyance only. This condition may remain stationary for an indefinite time, or it may come and go, lasting a day, or two or three days, at a time. In some cases there will be marked congestion of the gum about the affected tooth; others will present no signs whatever to the eye. In most cases there will be some sensitiveness to pressure made with the finger over the root of the affected tooth; in these cases the tooth is not sensitive to thermal changes. The presence of such sensitiveness is sufficient for the exclusion of this affection from the diagnosis.

This form of disease is more likely to be confounded with phagedenic pericementitis than any other. They agree in many of their manifestations, but an examination of the peridental membrane as directed in treating of that affection cannot fail to render the diagnosis clear.

The CAUSE of apical pericementitis, acute or chronic, is always some irritating agent that finds its way into the tissues of the apical space by

way of the apical foramen. This agent is usually furnished by products of the decomposition of the pulp of the tooth. The tooth will in most instances be found with a cavity of sufficient depth to expose the pulp-chamber, the pulp being in a state of active decomposition, or, the pulp having been long dead, its chamber is found crowded with decomposing filth. The instances are not few, however, in which the affected tooth is found to be perfectly sound. In these cases the pulp has previously died from some of the diseases or accidents to which it is liable, and decomposition of the contents of the pulp-chamber has taken place. A large number of the cases seen in practice are those in which the pulp, after the insertion of a filling, has died from thermal changes or from pressure on the pulp. In those cases in which there is no external opening into the pulp-chamber it is not uncommon for the case to go on for a long time after the death of the pulp before painful symptoms manifest themselves—probably from the fact, so repeatedly noticed, that the pulp dries up, or becomes *mummified*, instead of undergoing decomposition. Sooner or later, however, serum will percolate into the chamber and decompose, furnishing the necessary poisonous material for lighting up inflammation in the apical space. According to recent observations in regard to the influence of micro-organisms—their necessity to the process of putrefaction—it is difficult to understand how decomposition can take place in the closed pulp-chamber, it having never been open; but, however this may be, the fact remains that such decompositions do occur. In very many instances this is postponed, as stated above, and during this time the peridental membrane retains its health.

Aside from this, there are many instances in which the pulp-chamber is filled with decomposing filth for indefinite periods and no inflammation results. It is probable that in these instances the apical foramen has become so closed with débris as effectually to prevent the passage of poisonous material.

In the TREATMENT of apical pericementitis the first thing that should receive attention is the pulp-chamber of the affected tooth. If there is a cavity opening into it, this should be enlarged, so as to gain free access to the root-canals; the decomposing pulp, or anything else that may be in the chamber or root-canals, should be removed in the most perfect manner possible, and the interior subjected to the most thorough cleansing. The best instruments for the purpose are the barbed broaches well known in the shops of dealers in dental instruments; these are usually put up in assorted sizes very suitable for this operation. Each broach should be examined before using, to see that none of the cuts for forming the barbs are so deep as to weaken the shaft at that point, rendering it liable to break. The use of the broach requires considerable practice to obtain the best results. It should usually be passed up beside the pulp with the barbs turned toward the wall of the chamber; and when the point has gone far enough, the barbs should be turned against the soft tissue and the broach withdrawn. Usually, the entire pulp will come out with it if the motion is skilfully executed; but sometimes the tissue will simply be torn up and the broach will come away without the pulp, especially when it is in a state of partial decomposition. Then

it will be necessary to twist the tissue around the broach. In doing this the greatest care should be exercised not to break the instrument and leave a part of its shaft in the root-canal. I have usually found it well to pass a fine broach carefully through the apical foramen, to make sure that it is open, so that if any pus has already formed it may be discharged through the root-canals. After this is done the interior of the pulp-chamber and root-canals should be bathed with some good disinfecting agent. In practice I have found that it matters little what this is, so that it is not an irritant and accomplishes the office for which it is intended—the thorough disinfection of the parts. For this purpose I have used carbolic acid more than any other agent, and I think this is most used by the profession. Other substances seem to act just as well, such as iodoform, sanitas, eucalyptus, iodine, salicylic acid, and a number of others. An objection to the use of carbolic acid has been raised by some operators on the ground that it is liable to close the apical foramen prematurely by the coagulation of albuminous material. Theoretically, the objection would seem to be well taken, but in practice I have not experienced any difficulty from this cause.

After disinfecting, the pulp-chamber should be loosely filled with cotton which has been dipped in some antiseptic lotion, and the cavity temporarily sealed. In a large majority of cases this treatment will be sufficient to terminate the difficulty. Within a few hours the pain will subside and the soreness disappear. In all cases the cavity should be sealed moisture-tight, and, if pus is forming, should be changed with sufficient frequency to prevent pressure from accumulation.

Cases are now and then met with in which this treatment is insufficient—that is, the pain persists. In such cases various means have been resorted to for the arrest of the inflammatory process. Counter-irritation is one of the simplest, and is often a very effective remedy. The form of counter-irritation that I most resort to is this: Cut a piece of soft blotting-paper the size desired and stick it on a small bit of rubber dam. Moisten the paper with chloroform, and place it over the root of the tooth in such a way that the rubber will protect the lips or cheeks from the action of the agent. This will, if the mucous membrane is dried before it is applied, make a blister within three or four minutes. I have thought it more effective, however, not to carry it to that extent, but to apply it until there is sharp burning, then remove, then reapply in the same way after an interval; and keep repeating this as long as seems necessary. Any means by which the chloroform can be applied to the parts and its evaporation prevented will be effective. I not unfrequently use it on a bit of punk, under my finger. Many plans for the application of counter-irritation in these cases have been devised from time to time, such as pepper-bags, plasters into the composition of which some one or more of the vesicants or irritants are incorporated. These, if well made, are effective and convenient.

Local blood-letting will often be effective, and is to be recommended in those cases in which local congestion is a prominent factor. This is best done by a cut encircling the tooth at its neck or by a cut in the mucous membrane immediately over the affected root. This, to be

most effective, should be carried to the bone. In persistent cases it is better to penetrate the bone and lacerate the tissues of the apical space. This is quickly done by means of a well-directed drill driven by the engine. It is needless to say that this is an instrument that should be used with great care.

A still better result is usually obtained by the use of carbolic acid for the painless penetration of the apical space. It is best done in this wise: The mucous membrane is first dried at the point at which it is desired to make the opening, and napkins are so placed as to keep it dry. Then a plugging-instrument with fairly sharp serrations and of convenient shape is selected. The point of this is dipped into a 95-per-cent. solution of carbolic acid, and a drop conveyed to the mucous membrane; this will at once produce a white eschar. Then a slight scratching motion with the serrated point is begun, with the view of removing the tissue that is whitened. This is continued until the carbolic acid is thick with the débris of the tissue torn up, then it is dried out and another drop added, as before, and the process continued. This is repeated as often as may be necessary, going deeper and deeper into the tissue in the desired direction until the bone is laid bare. Then a fresh drop of the acid is placed on the bone and the periosteum carefully raised over a sufficient space; then with a sharp chisel cut through to the peridental membrane. This will generally cause some pain and some bleeding, but after giving a little time for this to cease, and adding more of the acid, the apical space can usually be reached without difficulty. No blood should be drawn at any time during the operation except in penetrating the wall of the alveolus. In doing this no tissue is removed until it is anæsthetized by the carbolic acid. This is a little tedious, but it is almost painless, and the general effect is usually better than by other modes of penetrating the apical space. The carbolic acid has the effect of modifying the pain, and the opening left does not close so readily. I have frequent occasion to use this process with very sensitive patients, and have found it to be quite satisfactory.

These means of relief may with advantage be supplemented by constitutional treatment, especially in the more severe acute forms. Hot foot-baths at bedtime are usually found effective in combating the inflammation, if made use of before pus has formed. A brisk saline cathartic is still better, and it is well to follow it with quinine on the following day. This treatment is especially recommended in those obstinate chronic forms occasionally met with. In these it is well to repeat this several times within a few days.[1]

[1] Exclusive reliance upon local medication, so common in dental practice, is an evil which should be amended. At the request of Dr. Black the writer presents the following summary of a line of constitutional treatment which in a large percentage of cases has in his hands proved effective in preventing suppuration. It will be observed that it varies in detail, but not in principle, from that recommended in the text.

1st. After the evacuation of purulent matter or pent-up gases from the pulp-chamber, apply to the gums, over the implicated tooth, one or two good Swedish leeches. American leeches are unruly and difficult to manage in the mouth or upon any circumscribed surface. Each leech will draw about a fluidrachm of blood. After their removal the hemorrhage can be almost indefinitely prolonged by wiping away the clot as fast as it forms in the wound made by the leech and directing the patient to rinse the mouth with warm water as long as it may be desirable to continue the bleeding. In this way

Alveolar Abscess.—Alveolar abscess results from inflammation having its seat in the apical space proceeding to the formation of pus; therefore the location of alveolar abscess is always in its inception the apical space, no matter where it may afterward extend. If this be not the case, it is not alveolar abscess even though it be an abscess within the alveolus of a tooth. This term has been employed from time immemorial to designate this special form of abscess, and it should be strictly confined to this one form, so that all may know exactly what is meant. If an abscess occurs on the side of a root of a tooth as the result of injury, and be not the effect of the death of the pulp of the tooth, it is properly a traumatic alveolar abscess. If such an abscess occurs from any of the diseases that attack the sides of the root of the tooth and it is thought well to designate it as alveolar, the word should in all cases be accompanied by an adjective expressing the fact. This is necessary to accuracy.

Alveolar abscess, then, is in all cases a result of apical pericementitis. If the case is not seen until the formation of pus has begun, or if the means employed for subduing the inflammation have proved ineffectual, all the symptoms will show an aggravation. The gums over the affected tooth will become deeply congested, and perhaps actually

from a fluidounce to a fluidounce and a half of blood may readily be abstracted from each leech-bite, in addition to the amount originally drawn. When leeches are not obtainable, the method of scarification of the gum recommended in the text should be followed. Leeching not only possesses the great advantage of being an entirely painless method of abstracting blood, but secures a greater outflow than that obtainable from a simple incision. It should always be practised before any local medication is attempted, as the presence of any foreign substance upon the gum interferes with the biting of the leech, if it does not entirely prevent it.

2d. After the removal of the leeches give a full dose—from 6 to 10 grains—of quinine. This somewhat reduces the temperature and the force of the circulation, and possibly tends to retard the inflammatory process by arresting the migration of the leucocytes through the walls of the congested capillaries, although in the ordinary medicinal dose this may be considered doubtful.

3d. Following the quinine, give one drop of tincture of aconite-root every hour until bedtime. For safety, place the required number of drops (and no more) in a small bottle, carefully instructing the patient as to dosage. Ten or twelve drops are usually sufficient for the required number of hours, and this amount, even if taken at once by an adult, would not prove fatal. From such small doses no very marked effect upon the force or frequency of the circulation can be expected, but they will at least hold the inflammation in check and prevent an increased pulse-rate. Larger doses of aconite should not be given unless the patient can be kept constantly under observation and the effect of each dose noted—a precaution which the exigences of dental practice usually make impracticable. Under proper safeguards a reduction below the normal of from five to ten beats per minute in the pulse-rate is desirable and safely attainable.

4th. At bedtime give a full dose (10 grains) of Dover's powder. This is to be taken in conjunction with a liberal amount of hot lemonade, the feet to be previously well soaked in hot water, and the patient, when in bed, well covered, to promote sweating. This treatment is a most effective feature in general medication in this class of cases. The opium eases pain, quiets nervous irritation, lowers the circulation, and in conjunction with ipecacuanha promotes diaphoresis, thus diverting to the cutaneous surface perverted blood-currents, draining the congested vessels of their contents, and diminishing the force and frequency of the circulatory impact upon the inflamed area.

5th. *The following morning* give a brisk saline cathartic. If given during the previous day, its operation is likely to take the patient out of bed at night, and thus to interfere with the action of the Dover powder.

6th. Quinine, aconite, and opium to be continued (according to indications) until inflammation subsides, on the one hand, or the abscess has formed and discharged, on the other. (See Treatment of Alveolar Abscess.)—Ed.

inflamed. The pain becomes in many instances intolerable, and there may be a rigor followed by fever. In a number of instances I have seen fever of 103° and 104° F. in severe cases of acute alveolar abscess.

The first pus formed is pent up in the apical space by bony walls on all sides, and the pressure becomes very great; this results in rapid absorption of the surrounding bone. The rule in such cases is that the pus will burrow in the direction of the least resistance, and, as the bone about and enclosing the apical space is softer than the external lamina, it usually happens that notable destruction of bone occurs before the surface is reached, thus forming a considerable pus-cavity (Fig. 485). Even in this case, however, the tissues of the peridental membrane occupying the apical space are not, as a rule, destroyed. The fibres are swollen and greatly elongated, and the pus usually occupies spaces between them. This swollen tissue forms the mass so often seen attached to the end of the root of a tooth extracted while in this condition, or later, after the abscess has become chronic. The explanation of this seems to be that the fibres are loosened from the alveolus by absorption of the bone, but, the root of the tooth not being absorbed, the attachment of the fibres to the cementum is not broken up. This is the usual condition of the tissues in alveolar abscess, but in some cases it happens that this tissue is destroyed and the end of the root denuded of its membrane, which complicates the healing process. It seems from my own observation, however, that this occurs but rarely in the acute forms; in the chronic form it is more frequently met with.

Fig. 485.

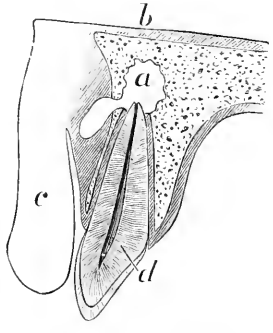

Acute Alveolar Abscess of Superior Incisor pointing on the Gum: *a*, abscess-cavity in the bone; *b*, floor of the nostril; *c*, lip; *d*, tooth.

During the time that the pus is burrowing in the bone the pain continues to be very severe and is of that throbbing character so peculiar to abscess-formation. The gums over the affected root become deeply congested and often much thickened by engorgement with blood, and the lymphatics about the angle of the jaw are liable to become very sore and swollen. There is not often during this time much swelling of the tissues of the face. Finally, the pus will find an exit from the bone. This usually occurs on the buccal side of the arch (the mouth is regarded as consisting of two cavities—the lingual cavity, inside the dental arch; the buccal cavity, outside the dental arch and inside the cheeks and lips), as shown in Figs. 485, 486, but may occur in any direction, the rule being that it will burrow in the direction of the least resistance. It is in obedience to this law that the large cavity is formed in the bone about the apical space. This portion of the bone is of a cancellated structure, and is much more rapidly absorbed than the denser portions near the surface; therefore there is usually a very considerable cavity formed in this portion of the bone in the first stage of the process, but after the penetration of the outer lamina of the bone the pus

finds its way into the soft tissues, where the resistance is less and the destruction of the bone ceases or progresses less rapidly. With the escape of the pus from its imprisonment within the bone comes a modification of all the symptoms. There is usually a marked abatement of the intense pain. This, however, is only an abatement, not a cessation: the pain continues in a less intense form. The features, which up to this time had shown but little of the effects of the malady except the expression of suffering, now become swollen, often with great rapidity. Frequently all the tissues of the side of the face affected become intensely œdematous and distorted, the eye closed, and the jaws so stiffened that the mouth can be but slightly opened. In this condition an examination will show a large tumor of the gum over the affected root. This may be in either the lingual or the buccal cavity, but in a great majority of cases it is found in the buccal. The tumor will be found fluctuating, and if left to itself will very generally open on the gum, just over the root of the tooth. This result should, however, be anticipated by opening with the bistoury, for it not very unfrequently happens that the tissues of the gum are raised from the bone and the pus finally gains an exit at the gingival margin; which complicates the process of recovery.

FIG. 486.

Acute Alveolar Abscess of the Lower Incisor pointing on the Gum: *a*, abscess-cavity in the bone; *c*, lip; *d*, tooth.

After the discharge of pus the inflammatory symptoms usually abate very rapidly. The pain generally subsides within a few hours, and the swelling within a day or two, though pus may continue to be discharged indefinitely. The amount of pus formed in these cases is often very considerable, the discharge being profuse and continuing for a number of days. The quantity, however, gradually lessens, and after four or five days it is usually reduced to a comparatively small amount. The abscess, if left to itself, usually assumes the chronic form, the pus continuing to be discharged, but in lessened volume. With the exception of the fistula and the slight discharge of pus, the parts now assume, so far as the eye can detect, their normal condition. This is the chronic form of alveolar abscess.

Acute alveolar abscess presents three forms in respect to the manner in which the pus leaves its bony enclosure. It may at once penetrate *into* the soft tissues, as described above (Figs. 485, 486); it may *separate the periosteum from the bone* and form a cavity for itself between the two, as shown in Fig. 487; or it may follow the peridental membrane down the side of the root and be discharged at the margin of the gum. The *second* is the form of abscess that is most likely to be attended with

necrosis of portions of bone, and for this reason should receive prompt attention for the purpose of preventing or limiting this very unfavorable result. This seems to occur mostly in those cases in which the inflammation has run very high, and in which there has been, or exists at the time of the escape of the pus from the bone, a very considerable inflammation of its substance and of its periosteum, by which the layer of osteoblasts have become so softened that they are readily separated from the bone beneath. In this condition of things the pus, in making its escape from the bone, instead of penetrating the overlying tissues, raises the periosteum in the same manner as in subperiosteal inflammations. In this way separation of the periosteum from the bone over a considerable surface occasionally occurs; and if the parts are suffered to remain in this condition for a considerable time, necrosis more or less extensive will result. If, on the other hand, the pus be promptly discharged, so that the periosteum may be again brought in contact with the parts from which it was separated, not much harm will follow; it will readily become reattached, and the parts will heal without difficulty. Separation of the periosteum is to be suspected when the tumor of the gum is broad and comparatively soft. After discharge of the pus by means of the bistoury an examination with a probe will reveal the fact that the bone is more or less extensively stripped of its periosteal covering. This form of abscess, when left to itself, is prone to discharge at the gingival margin after having separated the periosteum from the outer wall of the alveo-

Fig. 487.

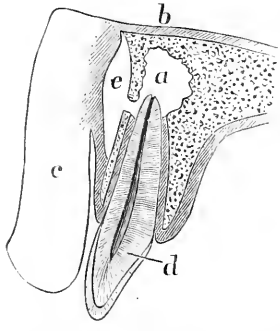

Acute Alveolar Abscess with Pocket of Pus between the Periosteum and the Bone: *a*, abscess-cavity in the bone; *b*, floor of the nostril; *c*, lip; *d*, tooth; *e*, pus-cavity beneath the periosteum.

Fig. 489.

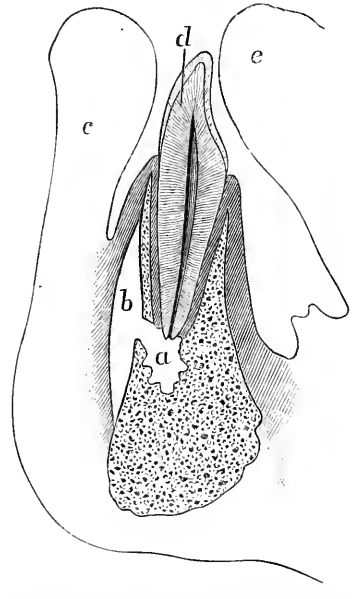

Acute Alveolar Abscess of a Lower Incisor with Pus-cavity between the Bone and the Periosteum: *a*, pus-cavity in the bone; *b*, pus between the periosteum and bone; *c*, lip; *d*, tooth; *e*, tongue.

Fig. 488.

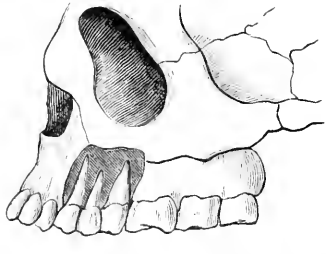

Necrosis of the Buccal Plate of the Alveolar Process from Alveolar Abscess.

lar process. In this condition the only blood-supply that this portion of the process can obtain is that which may come from the other side of the tooth through the anastomosis of the arterial branches in the peridental membrane, already in a more or less inflamed condition, or through the Haversian canals of the septum of the alveolar process between the teeth. This, it will at once be seen, will, in the inflamed condition of the parts, be a very precarious supply; and, as a result of this condition, necrosis of the alveolar plates overlying the root affected and those immediately adjacent is very liable to occur. Loss of these plates by necrosis occurring in this manner is shown in Fig. 488.

This form of abscess, occurring in the lower jaw (Fig. 489), is perhaps more likely to point on the face than any other of the acute forms, on account of the fact that gravitation carries the pus in that direction. This may drop gradually down and the pus be discharged under the chin, forming a chronic abscess such as is shown in Fig. 500; or if it be an anterior tooth, it may open in front, under the lip; or if it be a posterior tooth, on the lower border of the cheek. Less frequently this may happen from alveolar abscess in the upper jaw, the abscess pointing almost anywhere on the face, but more especially just under the prominence of the malar bone, in front of the attachment of the masseter muscle (Figs. 490 and 495).

The opening of an alveolar abscess on the face is always a grave misfortune because of the scar that is almost inevitable, and for this reason such a result should be guarded against with the utmost care. When it is apprehended, the pus should without delay be discharged into the mouth by use of the bistoury.

Occasionally this form of abscess is seen to raise the periosteum and soft tissues from the hard palate, the pus having discharged from its bony enclosure in that direction (Fig. 491). My observation leads me

FIG. 490.

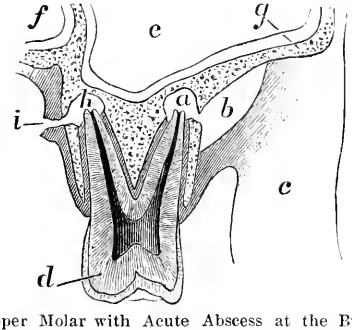

Upper Molar with Acute Abscess at the Buccal Roots and Chronic Abscess at the Palatine Root: *a*, cavity of acute abscess in the bone; *b*, pus-cavity between the bone and periosteum, extending out under the prominence of the malar process; *c*, tissues of cheek; *d*, tooth; *e*, maxillary sinus; *f*, nostril; *g*, malar process; *h*, cavity of chronic abscess discharging at *i*. (Compare with Figs. 495, 496, and 504.)

FIG. 491.

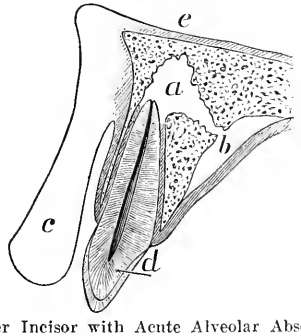

Upper Incisor with Acute Alveolar Abscess the Pus from which has raised the Periosteum from the Hard Palate: *a*, very large abscess-cavity in the bone; *b*, pus-cavity between the periosteum and bone; *c*, lip; *d*, tooth; *e*, floor of nostril.

to the conclusion that in this case there is not the same tendency to discharge at the gingival margin as in cases in which the tumor is situated

in the buccal cavity. When the abscess points in the hard palate, there is about the same liability to necrosis of the alveolar process, yet it usually seems to be limited more to the margins. Occasionally I have seen the periosteum stripped from the bone over the entire roof of the mouth, but retaining its attachment at the gingivæ and along the line of the posterior border of the hard palate, forming in this way a pus-cavity filling the entire palatine arch. In these cases, extensive as is the separation of the periosteum, necrosis of the bone but rarely occurs; indeed, I have never witnessed a perforation of the hard palate from this cause. This is probably due to the fact that the bones are thin and their blood-supply from the mucous membrane of the opposite surface is not interfered with. This accounts for the fact that in the palate necrosis of bone is usually limited to the immediate neighborhood of the teeth, where the blood-supply may be cut off by the tissue injury.

In these cases we recognize two causes of necrosis of bone. One is the intensity of the inflammatory process, which destroys by producing stasis over a considerable territory. This may cause necrosis in any locality whatever. The other occurs in such localities as may be deprived of their blood-supply by the injury of tissues in their immediate neighborhood upon which they are dependent. This is confined, for the most part, to the alveolar process, which receives its blood from two sources—through the vessels of the gum and periosteum of the outer surface of the process, and through the vessels that enter the apical space and supply the alveolar dental membrane. The latter vessels are cut off—temporarily, at least—by the formation of abscess in the apical space. Now, if the periosteum also is separated by the burrowing of pus beneath it, the death of this portion of bone seems inevitable, and clinical observation shows that this result does take place if this condition of things remains for a considerable time; yet it does not necessarily occur at once, and even here necrosis of the process may be prevented by prompt action in discharging the pus and keeping the parts in apposition.

The third form is that in which the pus, instead of penetrating the surface of the bone, finds its way along the side of the root, following the peridental membrane to the gingival margin, and is discharged at that point. This form is more rare than either of the others. When it occurs, it destroys a considerable part of the peridental membrane, and the alveolar process overlying this quickly disappears. This condition is readily recognized by passing a thin, flat, pointed instrument up by the side of the root and finding the peridental membrane wanting; whereas, if the pus has penetrated to the surface of the bone above and been discharged at this point, the peridental membrane, on raising the periosteum, will be found intact. The third form is perhaps more liable to be mistaken for phagedenic pericementitis than any other type of alveolar abscess.

Occasionally there occurs a case of alveolar abscess accompanied by extensive necrosis of the bones of the face. I have seen one extreme case in which all of the lower border of the right superior maxilla, including the whole floor of the antrum of Highmore, and all of the teeth from the central incisor to the wisdom tooth, were carried away. I did not

see the case until the necrosed parts were loosened, but, from the history given by the patient, there seemed to be no doubt that the trouble arose from acute alveolar abscess at the roots of the first molar. That tooth had for some time been decayed, and the patient had had severe tooth-ache several times; in one of these attacks the face began to swell, and it was in this inflammation that the necrosis occurred. The patient was a young man about twenty years old, and when I saw him was quite anæmic. He made a good recovery after the removal of the necrosed portions of bone. Another extensive case was that of a boy of nine years, in which all of the teeth from the cuspid to and including the twelve-year molar—which had not erupted—came away. This seemed to have arisen from alveolar abscess at the root of the first molar, which had been allowed to run its course without attention. Cases so extensive as these are, fortunately, very rare. In a few cases I have seen extensive necrosis of the alveolar processes that seemed to arise from abscesses occurring independently at the roots of various teeth, all of which had been neglected. In such cases the general health of the patients has usually suffered greatly, and they generally present an anæmic appearance.

Chronic alveolar abscess usually follows the acute form if the case is left to itself. The causes of this abscess are such that they are not self-limiting, as is the rule with a large proportion of the abscesses to which the human frame is liable. A common boil, or phlegmon, is cured spontaneously by the discharge of its contents; this is the general result in abscesses of the soft tissues. In subperiosteal abscess the discharge of the contents results in a spontaneous cure in those cases in which no necrosis of bone has occurred; but if there is necrosis, the presence of the dead bone may cause the abscess to assume the chronic form by its continuous irritation of the tissues with which it is in contact. In alveolar abscess we may, and generally do, have the case continuing in the chronic form without the presence of necrosed bone. In this case the irritant that is responsible for the continuance of the abscess is derived from the pulp-chamber of the affected tooth; that is, the same cause that brought about the acute form remains to keep up the chronic—namely, the discharge of septic matter from the pulp-chamber of the tooth into the apical space.

The presence of this abscess is known, except in that form called blind abscess, by a fistulous opening in the neighborhood. The position of this opening and the direction of the burrowing of the pus in chronic abscess furnish a great variety of forms, presently to be considered; just now the conditions peculiar to the apical space will engage our attention. When the pus is discharged from the acute abscess, the inflammation subsides and the parts, so far as the eye can detect, return to their normal condition, except that a fistulous opening remains. Even this may close, and, though rarely, the abscess may be cured spontaneously. The rule, however, is that the fistulous opening continues, and that pus may be found at the orifice at any time. The flow of pus is often profuse for the first few weeks, but, as a rule, it is gradually reduced until it is quite small in amount, and often the orifice heals over and opens again every few days; sometimes it closes permanently.

Then we have the condition of blind abscess (Fig. 492), in which there remains a mass of tissue in the enlarged apical space with which more or less pus is constantly intermingled. This condition of things may continue almost without change for any length of time, or the pus may be burrowing through the tissues without the patient's knowledge. A tooth in this condition is liable to periodic fits of soreness which will from time to time attract to it the attention of the patient. In such a case the symptoms differ but little from chronic pericementitis. The contents of the pulp-chamber are in a state of constant putrefaction, and the resulting products are as constantly being discharged into the apical tissues in a quantity sufficient to prevent healing. In this chronic form changes in the enlarged apical space take place very slowly, and usually are not very marked in their character. It seems evident from the comparisons I have made from time to time that the absorption of bone about the apical space is greater in the chronic than in the acute forms; therefore I conclude that in the majority of chronic alveolar abscesses the absorption of the bone is slowly progressing, though this is not necessarily true in all cases. I have seen some chronic abscesses of long standing in which the absorption of bone was very slight. In the majority of cases, judging from clinical experience gained in the treatment of these forms, the tissues of the apical space do not seem to be very much impaired in their vitality; for such abscesses heal with the greatest facility when the cause by which they are maintained—septic matter from the pulp-chamber—is removed. Still, there is a considerable number in which this is not the case. In some of these cases the difficulty seems to consist solely in the low state of the vitality of the tissues; so that time is required for them to recover tone. In others there is an actual destruction of the tissues of the apical space, this proceeding to such an extent that a portion of the apex of the root is denuded of its tissue. This is always a very grave condition as regards the prospect of recovery. Another complication also is liable to occur—*the deposit of serumal calculus* on that portion of the root which has lost its covering of tissue. This calculus is evidently derived from the exuded serum, and not unfrequently is deposited in the form of crystalline or crystal-like points; so that when the finger is passed over it one is strongly impressed with the similarity of the sensation to that produced by a burr. This calculus is an irritant, and is especially so when in this form, and of course it is impossible that the case can heal while it remains.

FIG. 492.

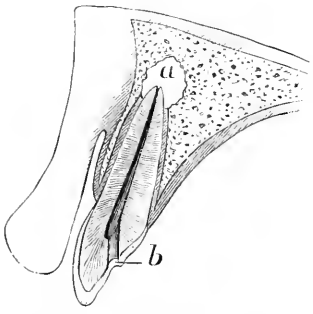

Blind Abscess at the Root of an Upper Incisor: *a*, abscess-cavity in bone; *b*, drill-hole exposing the pulp-chamber for treatment.

Cases are now and then met with that have taken on a septic condition and assumed a more aggravated type. In all of the cases before mentioned the pus is of the character known as laudable, but in the septic condition it becomes sanious, or very thin and watery. Now the

destruction of tissue becomes more apparent. Not only the bone, but the neighboring soft tissues, are found to be wasting away, and several openings for the discharge of sanious pus are likely to be formed; and the case, if left to itself, is likely to terminate in the spontaneous loss of the tooth. This condition has been described by Dr. Ingersol as *alveolar ulceration*. It seems to be caused by micro-organisms different from those usually found in the pus of ordinary alveolar abscess; but our knowledge of it is as yet too indefinite for positive statements to be made.

Chronic alveolar abscess may result directly from chronic apical pericementitis without acute inflammation having been present at any time; indeed, it may take place so quietly and with so little disturbance that the patient will not remember that the tooth has ever been sore or that anything has been wrong with it. The tooth affected is not necessarily decayed. Its pulp may have died from any of the diseases to which it is liable, and the tooth may present the appearance of the most perfect health. An abscess formed in this quiet way subsequently presents no symptoms different from those that follow the acute form.

The condition of the tooth in chronic abscess is not necessarily very characteristic. Of course the pulp is always dead, and in a certain proportion of the cases the tooth will be discolored by the absorption of the coloring-matter from the decomposing pulp, or after this by the formation of the dark sulphurets. This discoloration may exist in any degree, from the slightest perceptible tinge to a deep black. The rule is that there is some change of color by which the fact can be recognized that the tooth has lost its pulp. In many cases this is only a slight loss of translucency. Such a tooth is never sensitive to cold, and by this test the right tooth can usually be selected in case of doubt as to which of a number of teeth may have an abscess supplying the pus discharged from a fistulous opening in the neighborhood.

The burrowing of pus in the chronic forms of alveolar abscess forms a very important element in their history. This presents the widest variations, and is occasionally the source of much perplexity to the physician and the surgeon. The general rule is that the discharge is continued at the point at which the acute abscess at first opened—*i. e.* upon the gum over the affected root (Figs. 493, 494). This is, however, a general rule to which there are many exceptions. The point of discharge is frequently changed during the continuance of the chronic form; the fistulous opening heals over, and after a time the pus appears at another point, which may be at a distance from the original opening. This change may be, and generally is, made with so little disturbance that the patient is not cognizant that it is taking place until the new point of discharge is noticed. Exceptionally, considerable disturbance occurs; in fact, the abscess may again assume the acute form and force a new opening in a different direction or at a more remote point. The cases in which there is a certain soreness and stiffening of the tissues through which the abscess is burrowing are more common. This is especially the case if the parts be freely movable or if the pus is finding its way through muscular tissue, and yet it is singular how far pus may burrow among muscles without serious inconvenience. It often happens that the stiffening of the muscles is all that is complained of.

Among these burrowings of pus in this class of abscesses some general rules may be pointed out, and some particular forms that occur oftener than others may be mentioned. It is a general law of the burrowing of pus that it will go in the direction of the least resistance;

FIG. 493.

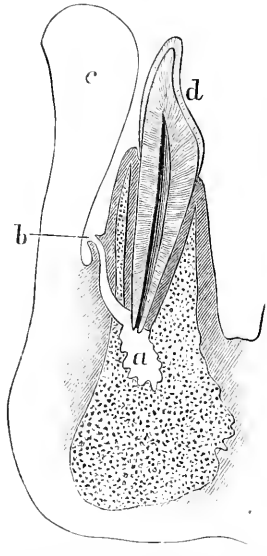

Chronic Alveolar Abscess at the Root of a Lower Incisor: *a*, abscess-cavity in the bone; *b*, fistula discharging on the gum; *c*, lip; *d*, tooth.

FIG. 494.

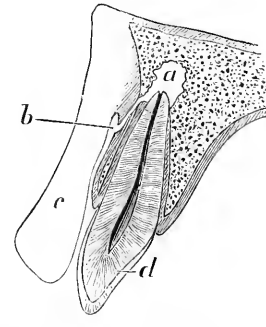

Chronic Alveolar Abscess at the Root of an Upper Incisor with Fistula discharging on the Gum: *a*, abscess-cavity in the bone; *b*, mouth of fistula; *c*, lip; *d*, tooth.

this law pertains more especially to the acute forms of abscess. In the chronic forms, in which the movement of the pus is very gradual, it is guided largely by *gravitation*, and therefore sinks to a lower point. Now, these two forces, acting together, will explain most of the movements of pus in the burrowings of chronic abscess. If, in the downward wanderings of the pus, it comes in contact with a more dense tissue, it will usually be deflected from its course toward that of less resistance; or if it be entangled in the fibres of such a tissue as the muscular and these run at an angle with the perpendicular, there will be seen a tendency to follow instead of to cross the fibres. Again, if the pus is burrowing in a softer tissue and in its course comes in contact with a muscle, it will usually be deflected and pass around the more dense tissue in the direction most favored by gravitation. In the same way, it will be turned from its course by dense fascia and burrow beneath it. This is the general law observed in studying the burrowings of pus in cases of chronic abscess, but it is by no means universal, for cases are occasionally presented in which it seems to be directly disobeyed. In the mass of cases, however, these will be found to be exceptional.

Now, by the application of these laws we will be assisted in tracing a discharge to its source, though in some exceptional cases it may mis-

lead. The rule is that we will find the point of discharge *below the source of the pus;* hence chronic abscesses of this class that burrow to a considerable distance are likely to discharge on the lower portion of the face or on the neck, and occasionally as low as the clavicle. Dr. E. D. Swain of Chicago has given me the details of a case coming under his care which illustrates this tendency. The pus from a chronic abscess at the root of a second superior molar became entangled in the fibres of the masseter muscle and followed them down through their length. At the lower border it emerged from this muscle beneath the border of the platysma myoides, and, having become entangled in the fibres of this, followed their direction downward and backward to the border of the trapezius, where it discharged on the skin. The masseter muscle was so disabled that the mouth could not be opened to the usual width, and the line of the sinus was readily traceable under the surface as it followed the platysma.

It is rather unusual for the pus from abscesses in the upper jaw to follow such a course. When such a discharge comes to the surface, the

FIG. 495.

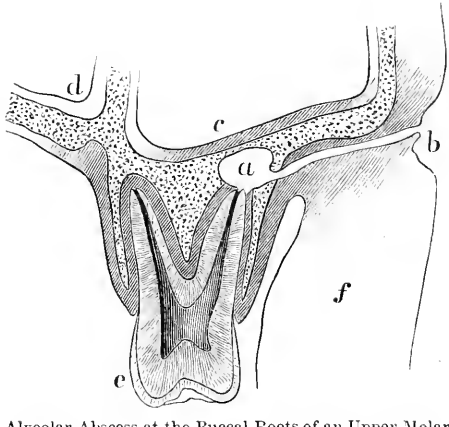

Alveolar Abscess at the Buccal Roots of an Upper Molar discharging on the Face: *a*, abscess-cavity in the bone; *b*, fistula opening on the face; *c*, maxillary sinus; *d*, nostril: *e*, tooth; *f*, tissues of cheek. (Compare with Figs. 490, 496, and 504.)

FIG. 496.

Scar caused by Alveolar Abscess discharging on the Face. (Compare with Figs. 495, 504, and 490.)

usual point is just beneath the prominence of the malar bone and in front of the anterior border of the masseter muscle (Fig. 495)—at least, of the abscesses of the upper jaw discharging on the face which have come under my observation more have presented at this point than at all others together. All those that I have seen in the act of pointing in this position have been of the acute form, but the history given me in some cases indicates that the chronic forms may occasionally point in this direction after the closure of the fistula opening on the gum over the affected root. The particular point of discharge seen in Fig. 496 forms a very characteristic scar, and on that account is of special inter-

est. My observation leads me to the conclusion that such fistulæ are usually the result of acute abscess of the form shown in Fig. 489, in which the periosteum is separated from the bone far out under the malar prominence. When the new tissue formed by the healing of the sinus has contracted, the skin is drawn inward under the malar prominence in such a way as materially to disfigure the face. The healing of the fistula forms a strong cord of new tissue, which in this instance has one of its ends attached to the skin and the other to the periosteum. This binds the skin down to the bone permanently unless it be relieved by an operation. (See p. 952.)

This class of abscess may discharge, also, anywhere in the region below the eye. As a general rule, the muscles are avoided, the pus burrowing around them when they happen to lie in the way. For this reason, perhaps, there is a tendency, when an abscess at the root of an anterior tooth discharges on the face, for the discharge to appear in the triangle between the levator labii superioris alæque nasi and the levator labii superioris. In two cases I have seen the discharge from an abscess of a central incisor appear close to the wing of the nose.

Occasionally we find an alveolar abscess discharging on mucous membranes other than those of the mouth; such cases are usually from abscesses situated in the upper jaw. I have three times seen abscesses at the root of the incisors discharging into the nasal cavity (Fig. 497). In these instances the pus passed through the bone, and in each instance the abscess-cavity was very large. I have also met with one instance in which the pus from an anterior tooth passed back beneath the mucous membrane and discharged at the junction of the hard and soft palate. Several cases of this kind have been reported in dental literature. Such cases are liable to cause the patient much trouble before a correct diagnosis is made unless he falls under the care of one who has given them some special study.

Fig. 497.

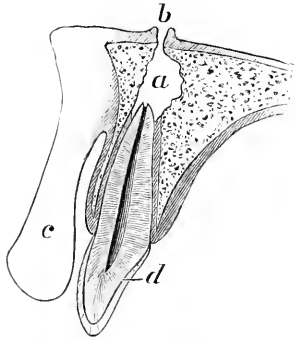

Alveolar Abscess at the Root of a Superior Incisor discharging into the Nose: *a*, large abscess-cavity in the bone; *b*, mouth of fistula on the floor of the nostril; *c*, lip; *d*, tooth.

The relation of the antrum of Highmore to the roots of the teeth (Fig. 498) is such that alveolar abscess is liable to discharge into that cavity. This sinus presents great variations in individual cases. In some there is a heavy lamina of bone between the roots of the teeth and the cavity, but occasionally a case is met with in which the roots of the teeth actually project into it, being covered, however, by a very thin lamina of bone in addition to the mucous membrane; in this case an abscess occurring at the end of the root will inevitably discharge into that cavity. This will sometimes produce serious complications, especially if the pus is not freely discharged by way of the nostril. The pus may also find its way into this cavity when there is considerable bone between it and the root of the tooth (Fig. 499).

By far the larger number of alveolar abscesses discharging on the face are situated in the lower jaw; this is undoubtedly for the reason that in this position the tendency is for the pus to be carried downward

FIG. 498.

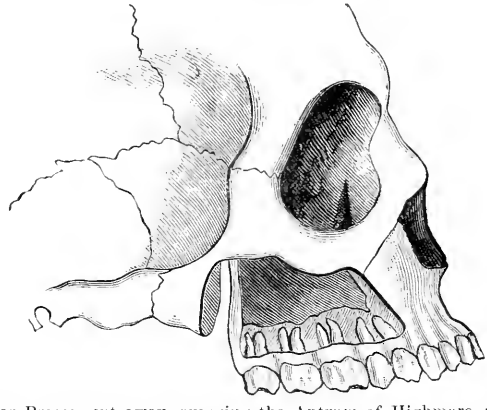

Skull with the Malar Process cut away, exposing the Antrum of Highmore, and with the Buccal Plate of the Alveolar Process removed, exposing the Roots of the Teeth, thus showing the relations of the Roots of the Teeth to the Antrum.

by gravitation. The greater number of these cases occur after the abscess has at one time opened on the gum, but finally has discharged so little pus that the fistula has closed. Then the pus that remains burrows little by little in the direction in which it is carried by gravitation, until it finally finds its way to the surface—usually, somewhere along the lower border of the inferior maxilla. As showing how insidious this creeping of pus may be, I recall a case in which I was treating an abscess at the root of a lower incisor for a patient in my own house; the case did not progress very favorably, but after a few weeks the discharge ceased and the fistula closed. Some time after this, when I was congratulating myself that the cure would be permanent, the patient one day called my attention to a "little pimple" under the chin. On examination, I found, to my astonishment, that the abscess, which I had thought well, had found a new outlet in that position, the pus having followed along the periosteum as shown in Fig. 500. This had occurred so quietly that the patient had discovered no unpleasant symptoms, though I had now and then inquired after his conditon. This is a form seen quite frequently, as compared with other abscesses opening on the face. These may, however, present anywhere on the face below the lip, though just under

FIG. 499.

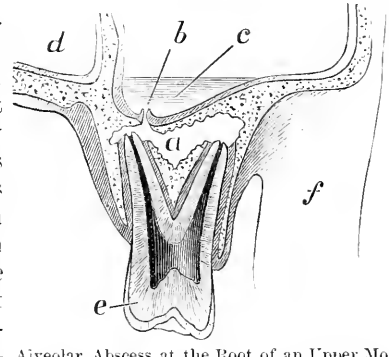

Alveolar Abscess at the Root of an Upper Molar discharging into the Antrum of Highmore: *a*, abscess-cavity in the bone; *b*, mouth of fistula on the floor of the antrum; *c*, pus in the antral cavity.

the chin seems to be a favorite point for them to open. Another form that opens at the same place I have illustrated in Fig. 501; in this the

Fig. 500.

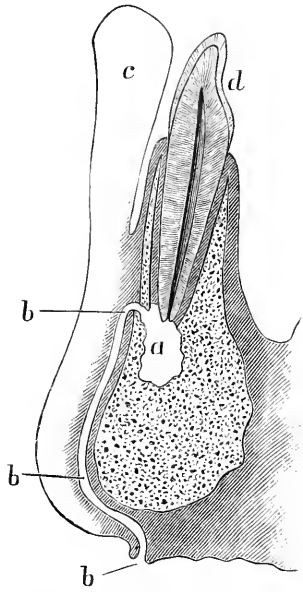

Chronic Alveolar Abscess at the Root of a Lower Incisor with Fistula discharging on the Face under the Chin: *a*, abscess-cavity in the bone; *b*, *b*, *b*, fistula following the periosteum down to the lower margin of the body of the bone and discharging on the skin.

Fig. 501.

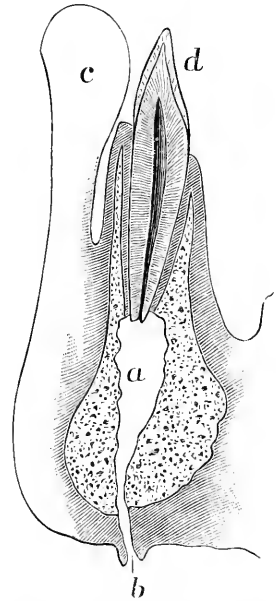

Chronic Alveolar Abscess of the Root of the Lower Incisor with Abscess-cavity passing through the Body of the Bone and discharging on the Skin beneath the Chin: *a*, very large abscess-cavity; *b*, mouth of the fistula.

pus has burrowed directly through the body of the bone. Such cases as this must, I think, usually occur from abscesses that were chronic from the first—*blind abscesses*, the pus from which has never penetrated the outer lamina of bone over the affected root. In such a case the pus may very readily make its way through the body of the bone, in obedience to gravitation.

Fig. 502.

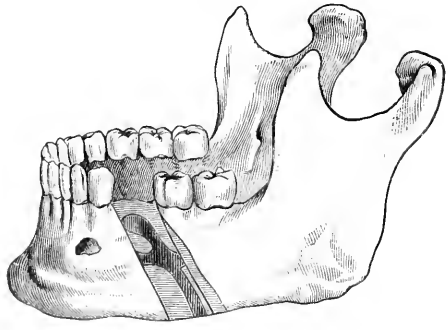

Fistula passing down through the Body of the Lower Maxilla. (See page 943.)

This class of cases is not necessarily confined to the anterior part of the lower jaw, but may occur at any point from angle to angle. Fig. 502 illustrates rather an unusual case that was presented to me some years ago. There was a fistulous opening just beneath the body of the lower maxilla, about the point where the facial artery crosses over the bone in ascending to the face; this,

the patient stated, had been discharging for more than eight years. Early in the history of the case he had had a tooth extracted, with the view of effecting a cure; but the operation failed of its purpose. Following up the sinus with a small probe, I found that it came from the body of the bone, and finally detected a loose substance. On carefully taking the direction and length of my probe, I found that this must be in the position formerly occupied by the roots of the tooth that had been extracted. Examination of the gums at the point revealed nothing unusual; the parts seemed healthy, but the space formerly occupied by the now missing molar seemed to be as wide as when it was removed. I dissected off the soft tissue, and found what seemed to be very solid bone; but with the first stroke with the chisel and mallet the chisel passed into a cavity. In this cavity I found a piece of necrosed bone that from its form seemed to be the septum that had been between the roots of the extracted molar; this bit of necrosed bone was the irritant that had kept up this discharge for so many years.

Alveolar abscesses opening on the skin are not confined to the face, but they may point still lower down, as on the side of the neck as far as the clavicle. I have myself seen quite a number that had opened at one-third and one-half the distance between the os hyoides and the clavicle. A route often taken in these cases is for the pus to follow the fibres of the platysma until the anterior border of the sterno-cleido-mastoid is reached, and there come to the surface. It is only occasionally that this point is passed, and then the pus may continue its burrowing as far as the clavicle. This is apt to carry it well out toward the shoulder.

The DIAGNOSIS of alveolar abscess, especially the acute form, does not often present much difficulty, for there is nearly always a very sore tooth to which the patient's attention has been strongly directed. The great dread of having a tooth extracted will, however, often cause a patient to keep that important fact from the physician. I have seen a number of patients who would say they had had no toothache, when a tooth was so sore that they dared not close the teeth together. This fact, however, hardly furnishes an excuse for treating a case of acute alveolar abscess as one of erysipelas—an error in diagnosis which more than once I have known made; the tumor of the gum is usually present and the general appearance of the swelling is quite characteristic after the case has reached a stage in which it could be mistaken for that disease. In some cases it might be confounded with subperiosteal inflammations, but these are more liable to be mistaken for alveolar abscess when they occur on the maxillary bones. Indeed, I have seen some cases in which it was very difficult to determine whether the beginning of the trouble was with the periosteum covering the bones or in the sockets of the teeth. The case from which Fig. 503 was made occurred under my own observation. I saw it early, and it was clearly a case of subperiosteal inflammation having its beginning just below the infraorbital foramen. Pus had evidently formed there, but the patient very positively refused to have anything done; and when I saw him again, a few days later, there was extensive necrosis that carried away four teeth with a considerable piece of the superior maxilla, laying open

the antrum of Highmore. The discharge of pus was at the free margin of the gum; and if I had not seen the case early, I should certainly have taken it to be one of alveolar abscess. Except as a matter of accuracy, this error would *then* have been of no importance; for it could have made no difference in the treatment.

Subperiosteal inflammation occurring under the temporal muscle, especially if it be in the temporal fossa, will usually discharge its pus into the mouth near the last molar tooth of the upper jaw, or it will appear on the face from under the zygomatic arch; and if the case be somewhat chronic, it may be mistaken for alveolar abscess. The temporal muscle is covered by a very dense fascia which prevents the pus from coming to the surface, and the fibres of the muscle will carry it in the direction indicated. In two cases I have met with there was very little pain complained of in the temporal region; both were fatal from the resulting necrosis of the skull.

FIG. 503.

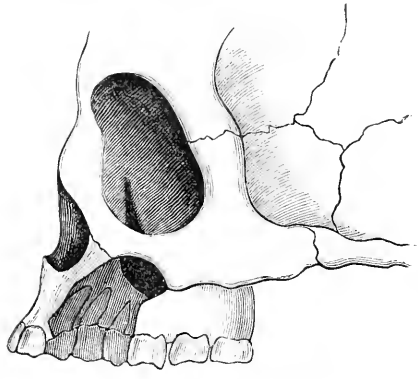

Loss of Bone and Teeth from Subperiosteal Inflammation.

In chronic abscess discharging at any distance from the teeth, as on the lower margin of the lower jaw or on the side of the neck, the chances that the pus may come from some small point of necrosis should always receive consideration. I have twice seen such cases, in which the discharge was in the same region in which we usually find it when, starting from alveolar abscess, the pus has burrowed into the tissues of the neck; in both of these cases the discharge was found to be caused by necrosis of the ramus of the lower jaw. In the search for the source of the discharge the condition of the teeth will often materially aid us. It must always be remembered that it is not necessary that a tooth be decayed or in any wise painful in order that it may be the subject of chronic abscess; but it must have lost its pulp, and therefore will not respond to the tests for vitality in that organ. Such a tooth, also, will very generally show a change of color—will be a shade or several shades darker than the teeth that are healthy. These points, in those cases in which the teeth are all seemingly good, will generally serve to indicate the affected tooth and aid materially in tracing the pus to its source. It must be remembered, also, that almost precisely the same symptoms may arise from *impacted teeth;* discharges from these very generally occur on the face if they lie deep in the bone. I have seen quite a number of these cases, in which the only way of distinguishing them from the more common form of alveolar abscess was the tracing of the sinus and finding in this way the impacted teeth.

The TREATMENT of alveolar abscess in the vast majority of cases presents but little difficulty. It consists in the simple cases in the removal of the irritant that has acted as the cause—*i. e.* septic matter from the

pulp-chamber of the affected tooth. If the case has occurred at the apex of a worthless crownless root, or if, from any cause, the tooth cannot be rendered useful if retained, the proper course is to extract at once, which ends the case. This is true though the abscess be of long standing and though the pus may have burrowed to a great distance. Even in those cases in which the pus is discharging on the side of the neck no other treatment is necessary, provided, always, that there are no spiculæ of necrosed bone to keep up the irritation. Except in rare cases, extraction is not necessary to a cure; and if the tooth is otherwise in a condition to be useful to the patient, extraction would be very improper treatment.

In *acute cases* it is generally best to evacuate the pus as early as possible and then allow the parts rest until the extreme soreness of the tooth has somewhat abated before undertaking further treatment. I have already detailed the treatment of apical pericementitis. Alveolar abscess is merely such a case gone on to the formation of pus; therefore the treatment must be varied to suit the different conditions that have arisen. If no tumor has as yet formed on the gum over the root of the affected tooth, and the condition as to soreness will allow of its being done, the pulp-chamber should at once be opened and the canals of the root cleared of their contents, in order to allow the pus to escape through the tooth. This course is generally better than to make an opening through the outer lamina of bone with instruments; for, as a rule, the pus will escape by way of the pulp-canal sufficiently well for all practical purposes. If the pus does not escape at once on opening the pulp-chamber and root-canals, a delicate instrument should be passed through the apical foramen, in order to remove any hindrance that may be lodged there. In a minority of cases the pus will not escape by this route, although the apical orifice may be open—for the reason, probably, that some part of the tissue of the apical space covers the foramen as a valve, preventing outflow. In case the pus escapes readily in this way, it should be allowed some time—from half an hour to two hours—to discharge, and then some disinfectant should be placed in the pulp-canal on a pledget of cotton and the cavity sealed so tightly as to exclude saliva. After this, if found necessary, the tooth may be opened from time to time for the discharge of pus that may accumulate; but in the majority of cases this will not be required. Such cases will usually heal at once or within a short time without other treatment. So general is this that it has become my habit to dismiss these cases for a week or ten days, advising the patients, however, to consult me immediately if they have a return of pain; and I find that it is only occasionally that anything further is required, the case being well at the next visit of the patient. If pain should recur, it is because more pus has collected, and all that is necessary is to open the tooth, discharge it, and again treat as before.

In case the pus cannot be discharged in this manner, an opening to the apical space should be made as directed in the treatment of apical pericementitis and the pus discharged in this way. It is best in this class of cases to place in the opening made in the gum a pledget of cotton, which should be moistened in a 95-per-cent. solution of car-

bolic acid. This will prevent the wound from closing and save the necessity for another operation should the abscess not heal at once.

In those cases in which *the external lamina of the bone* has already been penetrated by the burrowing of the pus and a tumor is present on the gum over the affected root, it is best to discharge it at once with the bistoury, and if the tooth is very sore—which is almost always the case—not to open the pulp-chamber until the soreness has somewhat abated. In this case it is especially necessary to place something in the opening in the gum to keep it patulous, for the fistula should not be allowed to close until the pulp-chamber has been opened and the root-canals cleared of offensive material. Usually, after two or three days the soreness will have so moderated that the pulp-chamber may be entered without very much pain. This should be done as early as practicable and the root-canals properly disinfected, after which the opening in the gum should be allowed to heal. This class of cases, when they occur in patients of reasonably good health, heal with great facility. It is not unusual for cases in which the intense swelling of the parts has caused the utmost distortion of the features, accompanied with the most intense pain and fever, to be to all appearance perfectly well in a week or ten days, while some of the milder forms are, so far as pain and soreness are concerned, well within a day or two.

Constitutional treatment in the graver forms of acute alveolar abscess should not be overlooked nor neglected. The nature of the affection is not such that it can be cured by the internal administration of remedies, and that is in no wise the object of medication, but rather to limit the intensity of the inflammatory action on the one hand and to promote the healing process on the other. It may also have for its object the mitigation of the pain. In very many of the cases that present themselves for treatment the inflammatory process will have reached its height—that is, it will begin to abate at once—on the discharge of the accumulation of pus; and in this case nothing can be done by the use of internal remedies to limit the extent of the inflammation. This has been an argument against the use of internal medication. But even in the cases stated internal medication may still save portions of bone from necrosis by the more ready reduction of the œdematous swelling and the quicker restoration of the normal circulation of the parts.

The *duration* of the inflammation is almost as important a factor in the production of necrosis as its intensity; therefore in all cases of considerable severity of the inflammatory process the local treatment should be supplemented with an active saline cathartic as an aid in the speedy reduction of the œdema and induration of the parts, with the view of the quicker restoration of the normal circulation to the alveolar borders and such other tissues as may be endangered. This treatment will also contribute much to the comfort of the patient by reducing the duration and intensity of the suffering. I do not insist that the cathartic should be saline, but it should be such as will produce large watery stools and be prompt in its action. If thought necessary, an opiate may also be given for the mitigation of the pain. In many cases the pain continues very severe for several hours after the discharge of the pus unless counteracted by this form of medication. After the cathartic has acted it

should usually be followed by a stimulant tonic; this should be prescribed on general principles, and will vary with the individual conditions of the patient. If his general health is fairly good, 10 or 15 grains of quinine in divided doses will suffice. If the patient be anæmic, one of the salts of iron should be added; and in cases in which, from the nature of the case, extensive necrosis is thought probable, the treatment should be especially vigorous.

All fomentations or poultices applied to the face should be strictly forbidden in acute alveolar abscess, for the reason that they invite an opening on the face; and if any softening in this direction is discoverable, the freest opening and drainage into the mouth should at once be established over the affected root, with the view of preventing such a result. In this matter special care is required in cases of the second form occurring in the lower jaw (Fig. 488).

If the treatment of the acute form fails of its object—the cure of the abscess—the case soon passes into the chronic form, which will now be considered.

The TREATMENT of chronic alveolar abscess presents, in some of its phases, characteristic differences from the treatment of the acute forms. There is generally no soreness or any considerable inflammation to contend with. The treatment is therefore more purely local and relates more especially to the removal of the cause perpetuating the discharge of pus—indeed, I may say wholly to this; for if the cause be removed, the tendency is to a spontaneous cure. Cases are sometimes presented to the practitioner in which the systemic conditions are so depraved and recuperative power is so low that an abscess will not heal without, in addition to local treatment, the use of remedies directed to the improvement of the general health.

With reference to local treatment, chronic alveolar abscess is best *divided into five forms, according to the conditions present in the apical space:*

1st. The simple form. In this the tissue of the apical space has not been so injured as to prevent a ready and spontaneous cure upon the removal of the fetid contents of the pulp-chamber.

2d. Cases in which injury to the tissue of the apical space has been so great as to prevent its taking on a healthy action readily, or in which it has been actually destroyed over a portion of the apical end of the root.

3d. Cases in which the tissue at the apical end of the root has been destroyed and serumal calculus has been deposited on the denuded portion.

4th. Septic abscess.

5th. Cases complicated with necrosis of bone.

The diagnosis of these different forms is not always easily made, for the reason that the apical space is not accessible for this purpose without either considerably enlarging existing openings or making a sufficient opening artificially; and if the abscess be of either the first or the second form—as may be expected in a great majority of cases—this is entirely unnecessary and may do harm. All that can be gained by an examination of the apical end of the root is to ascertain if serumal calculus

is deposited upon it or to learn whether or not the walls of the alveolus are necrosed. In case the apical opening is sufficiently large to do this readily without very material disturbance of the parts, it may be done at once; otherwise, the treatment should be begun with the idea that the case is of the simple form.

The treatment of the simple form of alveolar abscess consists merely in removing the débris from the pulp-chamber and root-canals of the affected tooth and thoroughly disinfecting them. For this purpose the pulp-chamber should be well opened with the drill and burr, no matter whether the tooth be much or little decayed or whether it be decayed at all, so that free access shall be obtained to the canals; and then these must be well cleaned with the broach. The enlargement of the *canals in the roots of teeth with any sort of drill* is not to be recommended; the chances are that it will do more harm than good. Indeed, in those cases in which it can be done safely it is not needed, and where it is needed it cannot be done safely. I have seen so much harm from this procedure that I feel that I cannot too strongly condemn it.

When the root-canals are well cleaned with the broach, they should be bathed with a good antiseptic and a pledget of cotton moistened with an antiseptic lotion placed in the root-canals and then the cavity in the tooth temporarily filled, but in such a way that the entrance of the fluids of the mouth will be thoroughly prevented. With this the patient should be discharged for a week or ten days, to give time for the spontaneous cure of the case. The rule is that at the next visit of the patient the abscess will be healed. As to the medicament used to disinfect the root-canals in these cases, I have found that it makes but little difference what is used, so that it accomplishes that one purpose well. Carbolic acid, eucalyptus, iodine, salicylic acid, creasote, iodoform, and various other antiseptics, seem to answer equally well. In some cases in which there is a large quantity of pus, and especially if it be rather offensive in character, it is well to wash out the whole tract of the abscess thoroughly at the first sitting. This is best done by means of *Farrar's syringe*, but any other syringe with a suitable nozzle may be used. This having been charged with the fluid, its nozzle is introduced as far into the canal as may be necessary, and, having all dry, is sealed in place with a piece of warmed gutta-percha and the contents of the syringe forced through the apical foramen and out at the fistulous opening. The fluids best suited to this purpose are sulphuric ether and peroxide of hydrogen. I have used sulphuric ether for many years, and have always been pleased with it; it cleans the parts well and seems to have a very valuable stimulating effect on the tissues. Since the introduction of the peroxide of hydrogen to the profession by Dr. A. W. Harlan of Chicago I have made considerable use of it for the purpose of thoroughly cleaning abscesses, and find it to take a place not filled by any other drug at our command. When introduced into an abscess-cavity, oxygen is liberated, producing an expansion of twelve times the volume of the liquid; thus a small amount of the drug will with its effervescence expel the contents of a large abscess. It is for this reason especially fitted for cleaning *blind abscesses*, into which a little of the drug may be forced through the

root-canal. After the washing is completed the pulp-canals should be filled with cotton saturated with a disinfectant, and the cavity temporarily filled as directed above.

In any of the forms of alveolar abscess cases will occur in which it will be impossible to open the apical foramen and gain access to the abscess by that route. This is always to be regretted, as the treatment succeeds best when directed through the canals; but in such cases the medicaments may with a fair degree of success be applied through the fistulous opening by injection with Farrar's or other suitable syringe. The nozzle of the syringe should, if practicable, be carried through the fistula directly to the apex of the root.

For some years I have quite largely used the following:

Take of Oil of cinnamon, 1 part;
Carbolic acid (crystals), 2 parts;
Oil of gaultheria, 3 parts. Mix.

This I use in those cases that require a stimulant disinfectant. The compound seems to possess properties quite different from carbolic acid. It may be used freely on the mucous membranes of most persons without the least danger of producing an eschar. Its antiseptic properties are sufficient for use in the pulp-chamber and root-canals. But its principal use is as a stimulant antiseptic to tissues that have lost their tone from long-continued inflammation; hence it is especially useful in the second form of chronic abscess. It may be injected into the apical space without danger of destroying tissue. It may be diluted with oil of lemon or oil of anise.

If after a week's time the fistulous opening should still be maintained, or in case of blind abscess pus should appear on opening the root, the treatment should be repeated. If the abscess does not heal in the course of another week or ten days, it may be regarded as belonging to the second class, or possibly to the third; and an examination may now be made, to ascertain whether or not there is a deposit of serumal calculus on the end of the root. Whether this should be done or not, however, will depend on conditions that must be decided in each case for itself. If there is no such deposit, the case will generally heal after time is given for the recuperation of the tissues of the apical space. A stimulating treatment is indicated. Caustics can do no good, but, on the contrary, may destroy what tissue remains. It is true that such cases will often get well after the use of caustics, but my experience is that they will require more time than if the caustics were not used. My observation is that *too much is done* for these cases by many operators. The main thing is to keep them clean and give them a chance to get well.

If the case does not heal within a reasonable time, the examination for deposits of serumal calculus should be made. An opening should be effected or the existing fistula should be sufficiently enlarged for an examination of the root; and if calculus be found, it should be thoroughly removed with suitable instruments. There is positively no chance for the case to heal as long as any of this deposit remains. It is better to cut away the end of the root than to leave the *least trace* of

the deposit. After the calculus has been removed in a satisfactory manner the case should again be left to itself to heal, simply keeping the parts clean. The prognosis in such cases is always doubtful; the greater number of them will recover, but some will be found in which, no matter what the treatment, there will be no reattachment of the tissue to the root. This, however, is rare. When we remember that Hunter *boiled teeth for replantation*, and yet obtained a union of the pericementum to the root of the tooth, we should expect such cases to reform the lost membrane and get well.

In the fourth class of abscesses, in which there is a discharge of a thin, watery, and offensive pus occasionally tinged with blood, connected with a more or less rapid, but marked, destruction of tissue, a more heroic treatment is required. In these cases there is a condition not ordinarily found in alveolar abscess. It is not kept up simply by the escape of septic matter from the pulp-chamber of the tooth, but is a true septic abscess, in which the poisonous material is being produced among the tissues themselves. For a remedial effect on this the strongest antiseptics are needed. The whole abscess should be injected with either a 95-per-cent. solution of carbolic acid, strong tincture of iodine, or ethereal solution of iodoform. The injection should be repeated perhaps twice within four days. The object in this treatment is to destroy this septic condition, and thus to convert the abscess into the simpler form; and as soon as that is accomplished the severe measures should be suspended and milder treatment substituted. This class of abscesses will give the most unsatisfactory results of any that are met with in practice. There is generally a comparatively great destruction of tissue, and a correspondingly long time is required for the healing process. In the mean time, the case will require constant care to keep the parts in good condition.

Abscesses that are complicated with *necrosis of the alveolar process* require special care in their treatment. If this lesion is discovered early in the case, the parts should be well cared for until by the natural process of the absorption the necrosed portions are loosened; they should then be carefully removed. I have learned by clinical experience that much of an alveolar process may be destroyed by necrosis from inflammation without necessarily destroying the hope of saving the tooth. Many of those cases that present a very bad appearance heal with surprising facility with a little care. In Fig. 488 I have represented a case in which the outer, or buccal, plates of the alveolar process were destroyed from an alveolar abscess, with more than half of the septum between two of the teeth; and yet those teeth are in very good condition to-day, eight years after the occurrence. The sketch was made at the time the necrosed portions of the bone were removed, and as nearly as possible represents the actual condition of the case. The treatment may be very briefly related. Before the pieces of necrosed bone, were loose enough to be removed the teeth were found to be so loose that it was thought best to wire them together and to their neighbors, to prevent motion. The parts were kept well cleaned by use of the syringe. As soon as it was practicable the necrosed portions were removed. Between two of the teeth the septum of necrosed bone passed

so far toward the lingual side that I had some trouble in removing it without disturbing the teeth, and in all the teeth the necrosed portion extended over the apices of the roots. The removal being accomplished, the soft tissues were laid in place over the roots, and maintained by a stitch passed around the central tooth of the series. Mild, stimulating antiseptic washes were used with the syringe daily until the discharge of pus ceased: this was in about a week, and the case was then gradually left to itself. A short time ago this patient allowed me to pass a small exploring-instrument in various directions through the tissues over the site of the former necrosis, and I found the alveolar process completely restored.

In most cases of necrosis of the alveolus where I have seen the patient daily I have succeeded in obtaining a restoration of the part, but it requires constant care. If the management of dressings, etc. is left to the patient, failure will generally result, for the reason that the parts become more or less septic, and instead of healthy granulations there is destruction of tissue. Where, however, the necrosis is less extensive, recovery is brought about with much more facility. In all these cases the condition of the pulp-chambers of such teeth as have lost their pulps should receive prompt attention, to prevent the discharge of poisonous matter by way of the apical foramen.

In those cases discharging on the face there is not necessarily any difference in the treatment of the abscess itself, but in the very beginning of the treatment the sinus should, if its situation is such as to make this possible, be cut off as near as practicable to the root of the tooth and the pus directed into the mouth. The sinus will then heal without further treatment, and the abscess is to be treated as usual. In some rare cases there may be a spicula of necrosed bone in the course of the sinus; this may have floated into it from the alveolus and lodged in a narrower part, or it may have come from a slight necrosis of bone that the pus has uncovered in its burrowings. Any such source of irritation as this will, until it is removed, prevent the healing of the sinus.

In the treatment of these cases many complications will arise that will tax the ingenuity of the operator. Some time ago I found, in a case of abscess at the root of a lower incisor, that the pus had burrowed down the anterior surface of the lower jaw to the point of the chin, though the fistulous opening was still maintained on the gum in the usual position. The abscess was of the second class, and did not heal readily. I found great difficulty in preventing the pus from dropping into the pocket, and, fearing that it would come through the skin, I, after unsuccessfully trying several expedients, finally passed a bistoury carefully down the length of the pocket and made a considerable cut as close to the bone as possible, laterally, on both sides of the sinus. I then put a compress on it for two days, so arranging it as not to hinder the escape of the pus on the gum. This produced enough adhesive inflammation in the parts to close the sinus at once. Afterward the abscess healed by the slow process usual in such cases. In all cases of this kind the ingenuity of the operator must be depended upon to overcome the difficulties that may present themselves. No set rules to accom-

plish this can be given for them, for the reason that all the conditions cannot be foreseen; and if rules were given, the intelligent dental surgeon would be likely to follow methods of his own devising in each case as presented.

The general rule is that the sinus will need no attention after the abscess has healed. It often makes a very ugly scar; but if this is under the chin, it will not be much exposed to view, and if on the neck may be covered by the clothing. If on the face, however, there will be disfigurement; each case must be studied with the view of lessening this as much as possible. The cord formed by the healing and contraction of the sinus is always somewhere attached to the bone, and it will often draw in the tissues in such a way as to be very unsightly. This is especially the case when the abscess has pointed just under the prominence of the malar bone in front of the attachment of the masseter muscle. In this case, if the finger is thrust into the mouth and a pull made outward against the scar, the round cord by which it is held down to the bone will be plainly felt. Now a tenotomy-knife may be passed in through the tissues of the cheek, and while a strong pull is being made on the cord it may be cut off where it is attached to the bone; this will allow the cheek to come out to its proper fulness at once. Then a pin may be passed through the central part of the scar and left lying against the face, to keep it in that position until the wound heals. This little procedure will greatly diminish the deformity, but will not entirely eradicate the scar (Fig. 504). In some such way most of the cases where the scar is badly drawn inward may be improved.

Fig. 504.

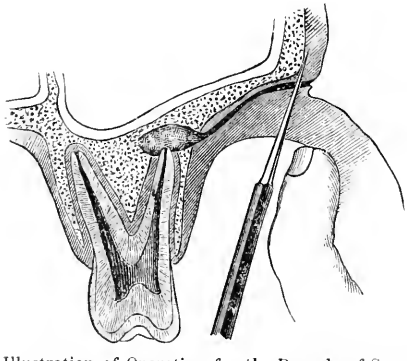

Illustration of Operation for the Remedy of Scar on the Face caused by Alveolar Abscess. (See p. 940. Compare with Figs. 490, 495, and 496.)

Finally, the case must be put in condition to prevent the recurrence of abscess. To do this, the contamination of the tissues of the apical space with poisonous material from the pulp-chamber of the affected tooth must be rendered impossible; this is effected by filling the root-canals and pulp-chamber with some enduring material. The requirements of a material for this purpose are threefold—first, that it shall be enduring, that it shall neither absorb moisture nor be subject to solution in any of the fluids of the body; second, that it shall be unirritating to tissues with which it may be brought in contact; third, that it shall be capable of such manipulation that the root-canals can be perfectly and solidly filled with it. Many materials have been proposed from time to time for this purpose, but of them all only two seem to me to possess these qualities in a sufficient degree to recommend them for the purpose; these are *gold* and *gutta-percha*. The gold meets the first two requirements most perfectly, while the gutta-percha—which was first recommended for this purpose by Dr. O. A. Glidden at

the meeting of the Illinois State Dental Society of 1873—is superior to it in the last. It seems well demonstrated that either of these materials can be so manipulated as to make a thoroughly solid root-filling, but in very delicate and tortuous canals the gutta-percha can be more easily forced to the apex than the gold. When the pulp-chamber and root-canals are solidly filled with either of these, the possibility of the formation of septic matter within them is at an end. The methods of manipulation by which the filling is accomplished belong rather to the operative department, and their consideration in detail here would occupy too much space.

The time at which a permanent root-filling should be made is an important consideration which must depend on the judgment of the operator in each individual case. Except in some peculiar cases, the healing of the abscess should be assured before the filling is undertaken: it is best that the abscess be actually well. When the operator is assured of this, the sooner the root is filled, the better. In those cases in which the apex of the root is cut away in order to remove from its distal side the last traces of a deposit of serumal calculus, it is probably best to fill the root at once, for the reason that the foramen may be cut to a point where it is rather large; if the root is at once filled, any material that is forced through into the apical space can readily be removed and the end of the root made smooth. Otherwise than in some such case as this the filling of the root before the abscess is well is not to be recommended. The principal reason for delay is the fact that the best means of treatment is through the open root-canals; therefore this avenue should not be closed until the operator is assured that it will no longer be needed.

Diseases of the Peridental Membrane having their Beginning at the Margin of the Gum.

This group of diseases has generally been passed over without very accurate description by authors who have written on the subject in past years. They have universally been grouped together under one name without differentiation. This name has varied with the different writers to such an extent that in looking over the literature of the subject we find almost as many names as authors. Spongy gums, inflammation of the gums, scurvy of the gums, false scurvy, diseased gums, gingivitis, pericementitis, suppurative inflammation of the gums, pyorrhœa alveolaris, odontolithus, etc., are among the terms most commonly used. The descriptions of this class of affections as given in works on dental subjects have generally been very short and imperfect, and even to-day I know of no book or writing that can be said to give a complete treatment of this branch of pathology. There have, however, appeared in the journals during recent years a number of very important papers treating of special phases of the subject which have had the effect of calling general attention to and of awakening interest in it. In this work Dr. J. M. Riggs of Hartford, Conn., has very justly the credit of having taken the initiative. Others had treated of the subject before Dr. Riggs, but this gentleman, by repeatedly calling attention to it in

society meetings, at the same time illustrating it by clinical operations, succeeded in awakening the general interest of the profession. Whatever we may now think of Dr. Riggs's explanation of the pathology of this class of lesions or of his method of treating them, he deserves the profound gratitude of the profession for what he has done. Unfortunately, Dr. Riggs has not left much in our literature on the subject, his communications having been oral, not written. And there is but little in the works of previous writers that will be available to me in the preparation of this portion of the paper; but of what I find I shall make free use, especially of what I have from time to time written myself. The classification I have given at the beginning of this paper may be imperfect and the growing knowledge of the profession may in time suggest improvement, but for the present it seems to be the best that presents itself, and I give it with the hope that it will be useful in the future study of this very important subject—a subject that has hitherto been neglected to an extent hardly creditable to the dental profession.

It has seemed to me that the time has come when the old names should be dropped and others introduced that are more in harmony with what is now known of the pathological conditions present in each case. This I acknowledge to be a difficult task, but it is absolutely necessary to accuracy. It cannot be expected that the profession at large will have definite ideas of these diseases until we have definite descriptions under definite names. In other words, so long as the nomenclature and writings on a given subject are vague and indefinite, so long will men's ideas of that subject be indefinite. The term *gingivitis* I limit to those inflammations of the gingivæ that occur from constitutional causes or the lighter forms of inflammation from soft deposits on the teeth. It may be argued—and justly—that all of the diseases of this class begin with an inflammation of the gingivæ; but when another factor has entered into the case, probably in its inception, it is proper that that factor should be expressed; hence the term *calcic* inflammation, expressive directly of the nature of the cause that perpetuates the disease. This is seen in two forms—serumal calculus and salivary calculus; but as these relate to the origin of the calculus that induces the inflammation rather than to the character of the inflammation itself, and as the two are very often blended together in the same case, it has hardly seemed to call for a separate name.

In the term *phagedenic pericementitis* I have again expressed the most prominent factor of the affection that is at the present time definitely determined—its destructive character. It is true that the calcic form is destructive, but not to the same extent. This disease is, in my opinion, caused by a specific form of micro-organism, but this has not been determined with sufficient accuracy to justify a name expressive of that conception. If in the future this should be determined with that definiteness demanded by science, a nomenclature should be adopted expressive of the fact.

The names heretofore in use have been applied to the entire group of diseases, and among them no distinctions have been made; the most of them are now no longer used. The term *pyorrhœa alveolaris* expresses

one fact common to all of these forms after they have made considerable progress, including alveolar abscess as well—*a flow of pus from the alveolus.* It must be seen by all that when we come to a classification of these affections this term loses all distinctiveness and cannot be of use. Possibly this name might be retained as expressive of the whole group of diseases in which there is a flow of pus from the alveolus, but this could not be of much value; especially is it objectionable after the use that has been made of it in the past. I therefore think it best to drop it altogether.

Gingivitis.—Before entering upon the study of gingivitis and that group of diseases having their beginnings at the gingival margin of the gums it may be well to call attention to the structure and functions of the parts. What are known as the *gingivæ,* or gingival margins of the gums, are those parts of the soft tissues that immediately surround the necks of the teeth and are in conjunction with them—the free margin of the gum (Fig. 505).

FIG. 505.

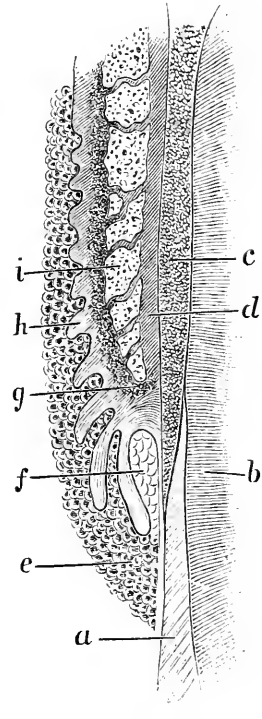

The Gingival Border: *a*, enamel of the tooth; *b*, dentine: *c*, cementum; *d*, peridental membrane; *e*, epithelial covering of the gingival border: *f*, gingival organ; *g*, dental ligament; *h*, subepithelial tissue; *i*, bony wall of the alveolus.

The exposed surface of the free margin of the gum is covered with a very dense squamous epithelium which fits it well to withstand the severe abrading contact with food necessary in the act of mastication. This rests upon a layer of softer epithelial cells, which cover a series of papillæ projected from the fibrous tissue beneath as a glove covers the fingers; the whole, when in the normal condition, rests on the rim of the alveolus and is drawn snugly around the neck of the tooth, forming a strong, resistant, yet flexible, cushion to the tissues which it protects. It is also strongly attached to the neck of the tooth and periosteum of the wall of the alveolus by radiating bundles of fibrous tissue that have become known as the *dental ligament.* In health this attachment to the tooth is from one-eighth to three-eighths of an inch from the extreme edge of the free margin, varying somewhat in different persons and about the different teeth of the same person and the different surfaces of the individual teeth. That part of the gingival margin that lies in against the neck of the tooth is of a different structure from its other parts. Here it is clothed with a very soft, round, or polygonal gland-like epithelium that suggests the formation of a gland, but fails to assume the glandular structure, though it seems to have been regarded as such by Serres. This—which I shall call the *gingival organ*—emits a profusion of small rounded cells which are always found in the saliva (Salter) and are usually called mucus-corpuscles. It is not probable that all of these

are derived from this source, but many of them certainly are, for they can be had for examination any time by passing a thin, flat-pointed instrument under a healthy free margin of gum and transferring that which adheres to a slide for microscopic examination. These often accumulate in considerable numbers under the free margin of the gum, and, mixed with micro-organisms, form the bulk of those soft cheesy masses that to the naked eye so nearly resemble pus that they are often mistaken for it. Indeed, Koelliker seems to have considered these corpuscles as a modified form of pus. They are, however, always found in this position, and therefore must be considered normal. Still, it is a question whether these little masses of cells or rings of cells that surround the necks of the teeth should be considered glands. If so, what is their function? At the present time this question cannot be answered satisfactorily, the subject not having been sufficiently studied. We have, however, some facts bearing on the question in the direction most important to the subject in hand. It is well known that certain glands have the power of the selection and exeretion of certain poisons, and in this way of eliminating them from the system, and that in the passage, if the substance be in large amount, hyperæmia, or even inflammation, may result. It is also known that mercury and iodide of potassium will produce inflammation of the free margins of the gums, and Salter has found that these cells are in greater abundance under these circumstances; also that the cells taken from the gingival border and submitted to chemical tests after the person has taken iodide of potassium are found to yield and are tinged with iodine. We have here, then, a sufficient proof that gingivitis may occur from constitutional causes, or, in other words, from poisons that circulate in the blood and have an elective affinity for this gingival organ. Certain medicinal agents are known to possess this property; what other substances there may be having similar affinities is as yet only a subject for conjecture. We can now speak positively of *mercurial* gingivitis and gingivitis from iodide of potassium. Each of these is a form of true constitutional gingivitis, usually termed salivation because the salivary glands are excited at the same time. Either of these forms of the disease may so extend that it might be termed a pericementitis, and that from mercury in some cases might take the name of any of the tissues of the mouth or face; but this is in all cases an extension of the inflammation from the gingivæ, which are uniformly the point of attack. It is not my intention to discuss these diseases further, as they are sufficiently treated in works on general medicine, and, thanks to a wiser use of remedies, they are now very rarely seen.

In the influences that produce scurvy we find another cause of constitutional gingivitis that is unmistakable, and the course of the affection, taken apart from the other manifestations of the disease, has much in common with the simpler forms.

Aside from these three well-known forms of gingivitis, a form occurs quite often—mostly in young persons—that is of much less note and requires only a passing notice. This is an inflammation usually confined to the gingivæ, but extending to most of the teeth. The margins of the gums become red and swollen and bleed from trifling causes.

There is often some eversion of the gum, and the pockets thus formed are filled with the peculiar mucus-corpuscles, pus-corpuscles, and the usual micro-organisms of the mouth. This inflammation seems not to assume a destructive character. There is little or no separation of the tissues from the necks of the teeth, and the difficulty is usually transient, lasting but a few weeks. In those cases, however, where there is a disposition to accumulations of calculus or other irritating substances, it may serve as the starting-point of a more permanent *local* irritation; it therefore requires the attention of the dentist. It will always be favorably modified by habits of cleanliness, and will soon pass away without other treatment; therefore the removal of the accumulations is usually all that is indicated. Of course the patient should be instructed in regard to the matter of keeping the parts well cared for. Some cases will be met with in which a brisk saline cathartic as an eliminant will be advisable, and this may be followed by the vegetable acids with advantage. For this purpose I have found nothing better than oranges or lemons; indeed, in all of this group of diseases these fruits seem to exert a very salutary effect.

There is but little doubt that simple gingivitis is often the starting-point of the more grave diseases of the peridental membranes presently to be described. The inflamed and swollen state of the gingivæ favors the lodgment of calculus by interfering with the natural tendency to cleanliness which results from the unrestrained use of the teeth in the mastication of food. This tendency is readily seen in most mouths when from any cause one portion of the mouth is not freely used, as in the case of a sensitive carious tooth. In such cases the effect of disuse is generally quickly seen in accumulations of débris, if not actual deposits of calculus, about the necks of the teeth in the region disused, with the consequent tendency to calcic inflammation. Now, in case of simple gingivitis, continuing for some weeks, the patient will become cautious about the use of the teeth and will avoid those things that hurt the gums, and therefore will not make that free use of the teeth best calculated to keep them freed from such accumulations in the natural way. In this manner Nature's plan for cleanliness is thwarted, and the condition is prone to pass into one of calcic inflammation.

Calcic[1] *Inflammation of the Peridental Membrane and Gums.*—I use the term *calcic inflammation* of the peridental membrane and gums to express that condition in which inflammation of these parts is caused and perpetuated by deposits of calculus on the necks of the teeth. As *deposits on the teeth* will be the subject of a special paper, I will not enter into a discussion of the causes that lead to them, further than these may depend on the local conditions. I recognize that a tendency to calcific deposits may be a constitutional vice which is probably hereditary in many cases, but may be acquired. This constitutional vice may be favored by conditions of the teeth themselves, by their form, by irregularities in their arrangement, by the condition of the gums, as in the swollen state found in simple gingivitis, by vicious personal habits,

[1] In the use of the term "calcic" denoting the cause of inflammation I follow an established usage, as seen in the terms traumatic inflammation, traumatic fever, septic fever, etc., all of which denote the cause, not the result, of the conditions named.

such as want of cleanliness, and by the use of soft foods which require but little use of the teeth, etc. Calcic inflammation is really one of the most grave of the diseases of the teeth—not that it is so very difficult of management when rightly understood, but from the great number of cases that occur and its insidious character, by which it so often destroys the denture before the patient is aware of the danger. Within my observation it is causing the loss of more teeth than is caries. The subject, therefore, merits the closest possible attention.

This variety of inflammation is dependent directly upon the accumulation of calculus upon the necks of the teeth, and presents two forms that may appear distinct from each other or may be blended together in the most intimate way. This relates to the source of the calculus and the position of the deposit. One form is derived from the serum that exudes from the tissues in a state of disease, and is uniformly deposited under the free margin of the gum; the other is derived from the saliva, and is deposited on the necks of the teeth close up against the free margin of the gum, but not beneath it. Any of the conditions that favor deposits favor thus far the development of the affection. Simple gingivitis will in this way contribute to its development. Indeed, one form of calculus seems to be dependent for its production upon previous conditions of disease; this is not properly salivary calculus, but the calcareous deposit from the serum. This I shall call *serumal calculus*. So far as I know, this form of calculus was first noticed by Dr. Brown of Georgia in an article in the *American Journal* (October, 1870). It was also described by Dr. Ingersol (*Ohio Journal*, August, 1881) somewhat at length under the title of "Sanguinary Calculus." I have not been able to determine that this form of calculus is characteristic of any one form of disease; it seems to be a result of any pathological state of the gingivæ causing them to weep a serous fluid. It is not, however, confined to the gingivæ, but may occur on any part of the root of the tooth, and not unfrequently is found on the apex of the root in old

FIG. 506.

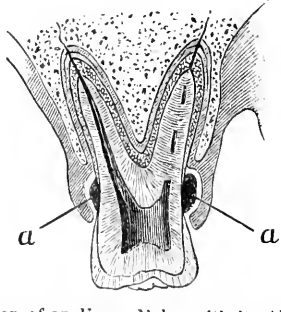

Section of an Upper Molar with its Alveolus, etc., showing Deposit of Serumal Calculus under the Gingival Borders: *a*, *a*, serumal calculus.

FIG. 507.

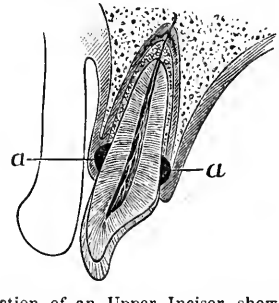

Section of an Upper Incisor showing at *a*, *a* a Deposit of Serumal Calculus within the Free Margin of the Gum.

cases of alveolar abscess. Yet it occurs much more frequently than elsewhere on the necks of the teeth immediately beneath the gingival border (Figs. 506, 507). There seems to be in the location and circum-

stances of the deposit of this calculus on the necks of the teeth a suggestion that this particular deposit may be from the secretion of the gingival organ; there is not enough known of the matter, however, at the present time to warrant any definite statements. It is possible that it may be formed without previous local disease, but my personal observations do not favor this idea.

As seen in this position, the deposit is generally in the form of a very hard brownish crust, but it is often deposited in little nodules adhering very firmly to the neck of the tooth, and usually extending to a large number, if not to all, of the teeth. It is in no wise limited, even in its beginnings or in its greatest accumulations, to the neighborhood of the ducts of the salivary glands, as is seen so prominently in the deposits of *salivary* calculus. My observation leads me to the conclusion that this deposit is determined by irritation of the gingivæ. This may be caused by neighboring deposits of the ordinary salivary calculus, by accumulation of micro-organisms or of food, or it may be from local irritation arising from constitutional causes. When a slight deposit has once taken place, it becomes an irritant which will in itself perpetuate the disease. It seems to possess peculiar irritating qualities, keeping the adjacent gum and lower border of the peridental membrane in a state of chronic inflammation resulting in the continued, though very slow, increase of the deposit. This deposit, when it is the sole apparent cause of trouble, may be many years in accumulation before it will be productive of serious conditions; finally, however, some ulceration of the lower border of the peridental membrane will occur, and it will be

FIG. 508.

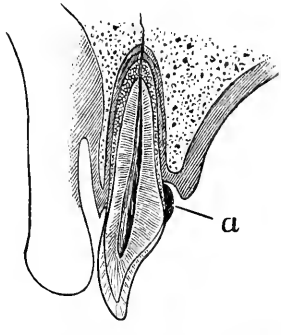

Section of an Upper Incisor showing at *a* a Deposit of Serumal Calculus and Destruction of the Lower Border of the Alveolar Wall and Peridental Membrane, with a slight Recession of the Gum, exposing the Calculus.

FIG. 509.

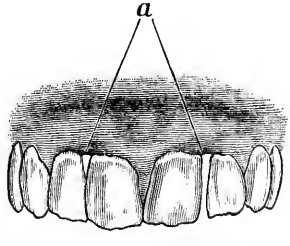

Absorption of the Septum of Bone and Recession of the Gum between the Central and Lateral Incisors caused by Deposits of Serumal Calculus under the Gingivæ.

very gradually destroyed, exposing the neck of the tooth. As fast as the membrane is detached from the root of the tooth the rim of the alveolar wall or socket of the tooth is absorbed, and the gum recedes with it, often exposing the brownish girdle of serumal calculus encircling the neck of the tooth (Fig. 508). Sometimes this condition of shrinkage is manifested by the subsidence of the septum of gum-tissue that drops down between the necks of the teeth, this forming a very

characteristic mark of the progress of the affection (Fig. 509). In these cases, as already explained, the lower border of the peridental membrane is destroyed and the septum of the alveolus absorbed, this allowing the gingival border to recede. It is not the gum that suffers, so much as the peridental membrane and alveolar wall. This condition is also frequently seen in connection with phagedenic pericementitis, but is not so characteristic, as in this disease there is less tendency to shrinkage of the gums. This does not occur in the same way from deposits of *salivary* calculus, on account of the greater tendency to active inflammation of the adjacent parts. More rarely, however, even with none but serumal deposits, the gum will be markedly inflamed, reddened, and spongy, and will bleed at the slightest touch. In either case pus will be found beneath the inflamed gum and usually be seen exuding on pressing the parts with the finger. If now the incrustations be removed, the peridental membrane will be found intact, though in an inflamed condition, just above the attachment of the crust, making a strong contrast to the conditions found in phagedenic pericementitis (presently to be described), in which the peridental membrane is destroyed and deep pockets are formed extending far beyond the calcareous deposits that may be present. (Compare Figs. 506, 507, and 508 with Figs. 518, 519, and 520.)

As these conditions continue the peridental membrane becomes more and more diseased; the formation of pus is more and more profuse; ordinary salivary calculus is now deposited on the root above the rim of brown serumal calculus, or this form may also extend along toward the apex of the root.

At this stage of the disease all the symptoms are likely to become aggravated and there is a continual flow of pus from the sockets of the

FIG. 510.

Section of a Lower Incisor with a large Deposit of Salivary Calculus impinging upon, and causing Inflammation of, the Gum.

FIG. 511.

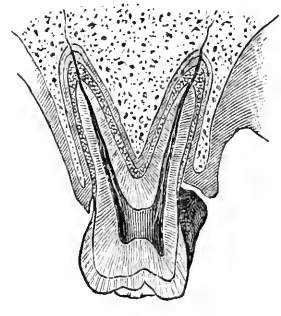

Section of an Upper Molar with Deposit of Calculus on its Buccal Surface causing Inflammation and Absorption of the Gum and Lower Border of the Peridental Membrane and Alveolar Wall.

diseased teeth, these gradually becoming loosened. In this condition that portion of the peridental membrane remaining about the end of the tooth becomes much thickened; so that, while the tooth shakes

about in every direction, it is still held in position with considerable tenacity. This condition of things is quite characteristic of the disease, and even at this late period serves to distinguish it from phagedenic pericementitis, in which the membrane around the end of the root is usually destroyed, while remaining still intact on some portions of the side. In this condition the teeth are irretrievably lost.

The conditions resulting from the deposit of *salivary calculus* are in all of their manifestations much the same as those just described. In this class of cases, however, the deposit is generally much more pronounced in the neighborhood of the openings of the ducts of the salivary glands—that is, on the lingual surfaces of the lower incisors (Fig. 510) and on the buccal surfaces of the upper molars (Fig. 511). It is not, however, confined to these localities. The beginnings of the deposits are almost always at these points, and as the deposit increases it spreads to either side, finally, in many cases, going the whole round of the dental arch. Thus the deposit, beginning on the lingual surface of the lower incisors, will gradually creep in between the teeth, and finally encircle them, and, passing from tooth to tooth, ultimately involve the entire set. This also may occur in the upper jaw, beginning with the molars of either side (Figs. 512, 513, and 514). Again, it is not uncommon to see mixtures of the two kinds of calculus, the salivary occupying the necks of the teeth near the ducts of the glands, and the ser-

FIG. 512.

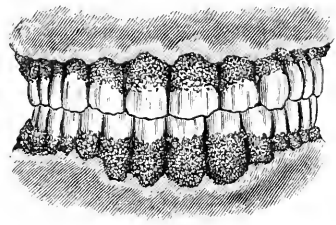

Heavy Deposits of Salivary Calculus causing general Calcic Inflammation.

FIG. 513.

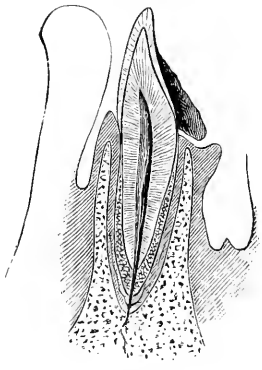

Sectional Illustration of a heavy Deposit of Salivary Calculus on a Lower Incisor, with partial Destruction of the Alveolus of the Tooth.

FIG. 514.

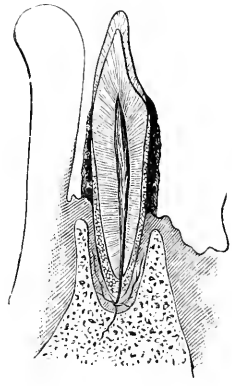

Sectional Illustration of Inferior Incisor with Deposit of Salivary Calculus less heavy than that shown in Fig. 512, but with greater Destruction of the Alveolus.

umal occupying those more remote. The salivary calculus is usually

of a light-yellow color, but is sometimes quite dark; it is much softer, is deposited in very much larger quantity than the serumal variety, and is much more rapid in its destructive effects. It seems to be more irritating to the surrounding tissues than the serumal. *No tissue retains its health if in contact with salivary calculus;* wherever it accumulates it carries destruction. Not only this, but it is very prone to follow up its destructive effects by fresh deposits in the space gained, and in this way is continually on the aggressive. Yet, if the deposit be cleared away from the teeth, the peridental membrane, just above, will be found intact; it may be inflamed and changed in texture, but it is not destroyed for any considerable distance in advance of the forming calculus. In this way the teeth are often loosened very rapidly. The lower incisors are usually the first to suffer and the first to be lost, after which the others, one after the other, are liable to suffer the same fate, until the entire denture is lost.

Instances are now and then met with of very large deposits of this calculus; I have often seen several molar teeth hidden from view by being covered completely in by them. The lower incisors sometimes bear a deposit greater in bulk than themselves. The destructive effects of this calculus do not seem to depend so much on the *amount* of the deposit as upon its *distribution*. For instance, the lingual surfaces of the lower incisors may carry a load of calculus equal to their own bulk and not suffer very much harm so long as their proximal and labial surfaces are free, while a much less amount of deposit, when extending entirely around the neck of the tooth, will cause a much greater destruction of the peridental membrane. It would appear, also, that when the deposit takes place very rapidly in a certain position there is less tendency to encroachment upon the tissues; the deposit in such cases seems to override the tissues instead of insinuating itself beneath them and around the root of the tooth.

In any case, it is not so much the deposit of calculus that is to be feared as the *continuance of that deposit in contact with the tissues;* for this it is that brings about the evil results. The gums and peridental membrane naturally heal kindly and quickly even after very considerable mutilation, and will do the same after an active inflammation has been developed by the presence of calculus; but when this continues for month after month and year after year, a time comes when they lose the power of recuperation: the tone of the tissue is lost and they become incapable of returning to health. This is seen in every degree. Some cases that look very badly will heal readily; others, only after much careful nursing has given them time and opportunity for recuperation. Still other cases refuse to heal so long as the teeth remain in their sockets—a clear indication that the tone of the peridental membrane has been irretrievably lost. I wish to emphasize this statement. It is not the tooth that is at fault, as many seem to suppose, but the peculiar tissue of the peridental membrane, the recuperative capacity of which has been worn out. John Hunter *boiled* teeth for replantation, and yet the tissues of the peridental membrane were found equal to the task of uniting with their roots. Teeth have been replanted successfully after having been knocked out and carried about in the pocket for hours

Can we imagine that the teeth in the mouth could be in a much worse condition? Certainly it is not the condition of the teeth themselves (provided, always, that they are properly cleaned), but the very low state of the vitality of the remaining portions of the peridental membrane, that renders the process of repair impossible.

TREATMENT.—The most important measure in the treatment of calcic inflammation of the peridental membrane and gums is the removal of the concretions from the teeth, and next the arousing in the mind of the patient an active determination to keep them clean in the future. These two measures are absolutely necessary to success; nothing can be accomplished unless they are scrupulously carried out. But with these two points attained success is assured in all cases during the early or middle of the course of the disease. It should always be kept in mind that this is purely a local affection dependent solely upon the irritation of accumulations of calculus, and that these accumulations form the only bar to a restoration of the health of the parts. Especially should these facts be impressed on the mind of the patient, and he should be made to understand that the result will depend largely upon his own efforts. The removal of these concretions in such a manner as to assure success is, however, one of the most difficult operations in dental surgery. Another very serious difficulty standing in the way of success is the very slack and inefficient notions that have been held in regard to it by the profession at large. When dentists learn to regard this operation as equal in importance to, and requiring as much thoroughness as, the filling of teeth, and when they apply themselves with the same diligence to acquiring the necessary dexterity in its performance, they will be rewarded with success; without this, success in the treatment of this disease cannot be attained. Either of the forms of calculus is an irritant, and this remains true no matter how small the quantity. The leaving of a small portion—be it ever so small—of calculus on the side of the root of a tooth is just as fatal to the result of this operation as is the leaving of a small portion of carious dentine on the margin of a cavity in which a filling is to be inserted. Absolute thoroughness is the requirement. (For more detailed description of the operative procedures in the removal of calculus the reader is referred to the article on Calcareous Deposits on the Teeth.)

The *instruments* for this operation should be formed with the greatest care and delicacy. They should for the most part be fashioned to work with a *pushing motion*—that is, they should work *from* the hand in the act of removing the concretions. Curved and hooked or hoe-shaped instruments formed to work *toward* the hand with a *pulling* motion may be of service in the removal of the bulk of the larger concretions of salivary calculus, but they are of inferior value in the removal of the last portions of the deposits or for serumal calculus that is deposited high up under the gum. For this purpose all the hooked instruments, no matter how delicately formed, should be discarded and slender points made to work with the *pushing* motion substituted. These should be made of the finest steel. The points should be from one-sixteenth to one-eighth of an inch in width, very thin—not thicker than ordinary writing-paper—and very gradually thicken up toward the shank, so as

to form a good spring. This part of the instrument should be of a fine spring temper to within three-sixteenths of an inch of the point, and the remainder should be hard. The point itself should be ground square, and kept sharp with the hone. These should be made in a sufficient number of forms, as regards curve of the spring part of the instrument, to enable the operator easily to reach any portion of the root of any tooth. Six or eight of these will be found sufficient for any operation that may present itself, and the instruments have the advantage of being easy of management if well formed. Those known as Dr. George H. Cushing's scalers seem to be the best yet in the market (Fig. 515). These instruments may be passed freely in between the most crowded teeth and reach every point where deposits adhere, and if judiciously used are capable of removing all incrustations with the least possible inconvenience to both patient and operator. They may be used with both the pushing and the lateral motion, but the pushing motion should be especially relied upon for the bulk of the work. At present no rules for this can be given that seem to me to be especially useful. The particular plans of manipulation will depend largely on the manipulative habits of the operator.

FIG. 515.

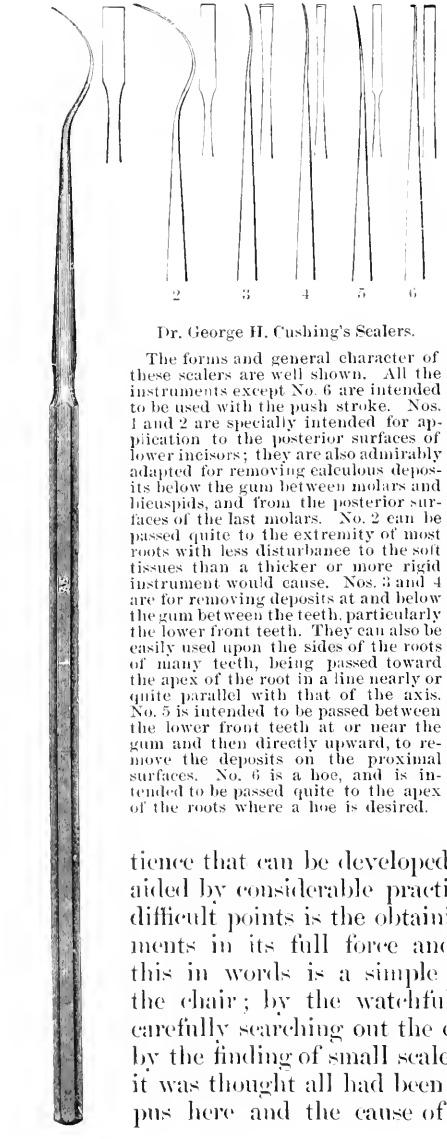

Dr. George H. Cushing's Scalers.

The forms and general character of these scalers are well shown. All the instruments except No. 6 are intended to be used with the push stroke. Nos. 1 and 2 are specially intended for application to the posterior surfaces of lower incisors; they are also admirably adapted for removing calculous deposits below the gum between molars and bicuspids, and from the posterior surfaces of the last molars. No. 2 can be passed quite to the extremity of most roots with less disturbance to the soft tissues than a thicker or more rigid instrument would cause. Nos. 3 and 4 are for removing deposits at and below the gum between the teeth, particularly the lower front teeth. They can also be easily used upon the sides of the roots of many teeth, being passed toward the apex of the root in a line nearly or quite parallel with that of the axis. No. 5 is intended to be passed between the lower front teeth at or near the gum and then directly upward, to remove the deposits on the proximal surfaces. No. 6 is a hoe, and is intended to be passed quite to the apex of the roots where a hoe is desired.

At first sight the operations seem very simple. The principal difficulty is in the finding and removal of the last particles of calculus. The bulk of the incrustations may be removed in a few moments by the merest tyro, but the removal of the last traces require a measure of skill and patience that can be developed only by the most determined effort aided by considerable practice. But, after all, one of the most difficult points is the obtaining of the conception of the requirements in its full force and completeness. The expression of this in words is a simple impossibility; it must be learned at the chair; by the watchful scrutiny of cases in practice; by carefully searching out the causes of failure in individual cases; by the finding of small scales that have prevented healing where it was thought all had been removed; by the finding of a little pus here and the cause of its continuance in a small particle

overlooked high up under the gum; by the finding of an inflamed point there, and the discovery of its cause in an unremoved scale. In a word, the proper conception of the absolute perfection required in this operation must be learned by a careful scrutiny of one's own failures, with the determination to correct them.

In many cases there will be found small incrustations of very slight thickness that lie so closely and smoothly to the root of the tooth that an instrument may slide over without removing, or even detecting them except by the most cultivated touch. These, when they occur in out-of-the-way places hidden by the gum, will tax the patience and skill of the most experienced operator, and it will require repeated efforts to find and remove them. The presence of all such points will after some days be manifested by a failure of the healing process, and they must be searched out before the case is discharged. Generally, such scales are dark-colored, and are readily seen if they can be so uncovered as to make visual search available. This may be much aided and extended by the plan proposed by Dr. Gilmer of Quincy, Ill., which consists in packing salicylized cotton[1] under the free margin of the gum and allowing it to remain for twenty-four hours, its expansion causing the gum to stand off from the tooth, so that small scales may be seen. This must be done with care and no more than the necessary pressure used, or the tissue of the gum will be injured. If judiciously done, the neck of the tooth may be exposed to view up to the attachment of the peridental membrane and without causing a slough. In positions where these plans of search cannot be made available the touch alone must be depended upon. The cutting away of the gum for the purpose of finding the last traces of calcareous deposits is in all cases to be deprecated; such deposits should be found and removed without this, for unless the gum tissue be in over-abundance any removal of it is detrimental to the future usefulness of the teeth and is entirely unnecessary to the curative process. Where there is hypertrophy of the gum, removal is judicious treatment and will expedite a cure. It is true that cases in which no hypertrophy exists are more easily managed by cutting away the gum as far as it is diseased than by the more conservative method of treatment, but in the calcic forms of inflammation there seems to me to be but little excuse for this procedure, as it is destructive of tissues that can be restored to health and usefulness, and which, when once destroyed, are not readily reproduced, the result being an undue and permanent exposure of the root of the tooth. The plan—so much practised of late—of removing the lower border of the peridental membrane and alveolar wall, but retaining the tissue of the gum, while not so destructive, *is entirely unnecessary* in the calcic forms of inflammation, unless the case be complicated with such a thickening of the alveolar border as will prevent the gum tissue from approximating closely to the root of the tooth. This is occasionally seen in old cases of serumal deposits. Then it is only necessary to break down the prominences of the wall of the alveolus in such a way that the tissue may assume the normal posi-

[1] Salicylized cotton is prepared by soaking common cotton in an ethereal solution of salicylic acid (40 grains to the ounce) and then drying it. This will irritate the gum much less than cotton alone—or, indeed, than any other substance that I have tried.

tion. Especial care should be had in all cases to preserve as much of the gum as possible, for upon that depends, for the most part, the renewal of the lost tissue. The rule is that the destruction of the gum is in any chronic case fatal to such restoration, the root of the tooth remaining denuded as far as the gum has been destroyed.

In all inflammations of the peridental membranes and gums originating in irritation from calculus, of whatever variety, or kept up by these causes, the tendency is to speedy recovery after their removal, provided, as has already been remarked, this is done before a certain stage of the destructive process has been reached. This stage of the affection is marked by a very distinct enlargement of what remains of the alveoli of the teeth—the rim of the alveolus having already been lost by absorption—and the *thickening of the peridental membrane*. In this case the teeth loosen in their sockets and the peridental membrane becomes profoundly changed in its character and qualities. But before this time there is little else to do than to keep the teeth clean after once removing all the crusts. There is usually seen an increased tendency to the growth of the fungi of the mouth about the necks of the teeth during the healing process, and this cause alone is very often sufficient materially to retard the cure. These should be carefully removed at least twice a day for a time, using for the purpose a soft brush and some disinfectant lotion; water strongly acidulated with lemon or orange, or even water alone, will answer. The *motion* of the brush should always be *lengthwise of the teeth* instead of across them, as is the manner of most persons in cleaning the teeth; this point is important, and the patient should be very carefully instructed in regard to it. The brush, used in this way, will clean the teeth better, and at the same time injure the inflamed gum less, than in any other way. In the greater number of cases this is all that is required to complete the cure. But the operator should keep every case under his care until it is quite well, for it will often happen that some points will need attention that have seemed to be doing well for a week or two, and examination will show additional calculus requiring removal.

In cases of long standing in which there has been considerable wasting of the alveolus and general enlargement of the sockets of the teeth, with thickening of the peridental membrane, still more care should be taken with the after-treatment. Much more time will be required for the return of the tissues of the peridental membrane and gum to the normal condition. Indeed, the normal condition of the parts will never be completely restored. The case will usually recover, if at all, with more or less of the root of the tooth denuded of peridental membrane and gum, which tooth will ever after be more liable to deposits of calculus; it will, therefore, require more vigilance on the part of the patient to keep it well after health is attained.

In many cases of calcic inflammation the tissues will be found in a state of active inflammation, turgid, and much thickened. In this condition I have found a from 20-to-30-per-cent. solution of chloride of zinc, applied carefully about the teeth, very effective in constringing the gum and removing from the tissue the condition of

extreme congestion. This is applied to the best advantage by what is known as Farrar's syringe (Fig. 516), by the use of which the remedy is placed in the exact position, and in the amount desired. This instrument, or some instrument that possesses its advantages, should be used for the application of any of the remedies for this disease, except, it may be, the milder washes with which the patient may be entrusted. Without such an appliance it is simply impossible to place the remedies in the position required. The only point at which the application of remedies is especially effective is *under the free margin of the gum*, and instruments must be used by which this can be accomplished. In these cases escharotics should not be used in the after-treatment, except within the first few days. Remedies of this class *reduce the vitality* of the tissues to which they are applied; indeed, unless they are used for the purpose of destroying something that serves to keep up the irritation, such as micro-organisms in the outer strata of partially dead tissue, or for the complete destruction of tissue so low in the scale of vitality as to make this advisable, they should not be applied at all. With this end in view, it is occasionally well to use carbolic acid full 95 per cent. in the beginning of the treatment. Magitot has advised the use of chromic acid; other cauterants also may be used. But after one or two applications any of these substances should be discarded in favor of those remedies that tend more to the stimulation of the tissues. For this purpose there is perhaps nothing better than the oil of cinnamon. The ordinary cinnamon water makes a very agreeable wash, but is not of sufficient strength to be very effective. Where there is great tissue-injury, I have found the following an excellent remedy:

FIG. 516.

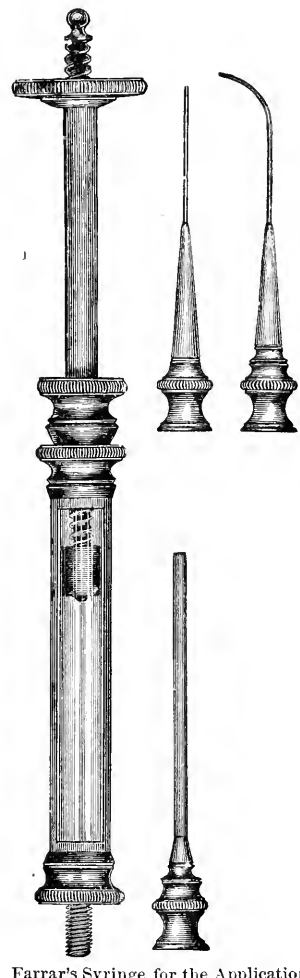

Farrar's Syringe for the Application of Remedies in Diseases of the Peridental Membrane.

Take of Oil of cinnamon, dr. iv.
Oil of gaultheria, dr. iv.
Carbolic acid (crystals), dr. i. Mix.

This may be freely used on the brush, or may be made into an emulsion in water at the time of using, and in that way used as a wash. This is at once a fairly good antiseptic and stimulant, and is a very efficient remedy. The principal indication is to keep the parts clean,

and to stimulate mildly those tissues that have been in a state of inflammation for so long as to have lost their tone, until they have recovered their vigor. Any plan of treatment that will effect this will answer all the requirements. Our materia medica contains a large number of appropriate remedies.

In those cases of long standing in which the alveolus is so much destroyed that the teeth have already become very loose not much can be done (Fig. 517); the rule is that the patient will do better with arti-

FIG. 517.

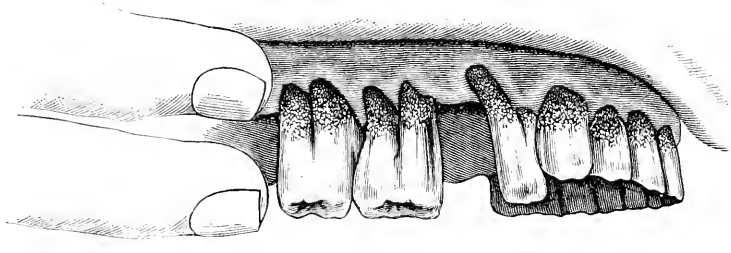

The Alveoli irreparably destroyed by Calcic Inflammation.

ficial teeth. If, however, it is only the four lower incisors that have become very loose—as often happens—and the remaining teeth can be readily cured, these incisors may be secured to the others by wiring or by slender clasps, thus keeping them moderately firm, and so fitting them to do fairly good service, often for a long time, if sufficient care is taken to keep them clean. They will often serve better than artificial teeth in this position.

The general law as regards PROGNOSIS is this: If the gum covers the root sufficiently to form an alveolus of sufficient depth to hold the tooth with the necessary firmness, it may be expected that care and time will restore the membrane to health and the bony parts will be sufficiently rebuilt to serve the purpose of holding the tooth in its position; but if the gum-tissue is gone as shown in Fig. 517, there is practically no hope for a restoration. Then the continual looseness of the teeth will in itself serve as an irritant to perpetuate the inflammation.

Phagedenic Pericementitis, or Destructive Inflammation of the Peridental Membrane.—Phagedenic pericementitis is a disease distinct from those previously described, yet it has many features in common with them. It may have its beginning in a gingivitis that in its inception cannot be distinguished from the simple form, or its character may be masked by deposits of either serumal or salivary calculus. On some accounts it would seem to merit the name of infectious pericementitis, but I do not regard the infectious character of the affection as sufficiently well established to warrant such an appellation, and for this reason must therefore regard the term "infectious alveolitis"—used by Dr. Adolph Witzel of Essen, Germany—as premature. Furthermore, it seems to me that the disease is essentially one of the peridental membrane rather than of the walls of the alveolus, as would be indicated by the use of Dr. Witzel's terminology. If the disease were of

the bony walls instead of the contents of the alveolus, I see no reason why the ailment should be cured simply by the removal of the teeth; certainly, if the disease were essentially of the bone, this result would not so invariably follow. But, on the other hand, it can be readily understood how, the disease being essentially of the peridental membrane, the removal—the destruction—of this would terminate the case. This agrees also with my observations as to the starting-point and the order of progress of this pathological condition.

The disease under consideration consists, then, in an inflammation of a peculiar character which results in the destruction of the peridental membrane. This destruction, also, is closely followed by the absorption of the walls of the alveolus; so that in the end both are destroyed. The disappearance of the two is so nearly synchronous that it is often difficult to say which has gone first; indeed, they seem to go together. In its least complicated form the disease is not accompanied with salivary calculus, or calculus of any kind. It seems to consist essentially in an inflammation—which may be acute or chronic—by which the peridental membrane is separated from the root of the tooth and destroyed fibre by fibre, cell by cell, very much as bone is destroyed molecule by molecule in the disease known as caries. In the progress of this destruction the membrane first becomes swollen; its individual fibres are very much enlarged and lengthened and intermixed with an abundance of inflammatory elements. The fibres seem first to separate from the root of the tooth and then to melt down, but still to retain their hold on the alveolar wall until completely destroyed. There is not necessarily any considerable inflammation of the gums; they are generally but slightly affected. In the chronic forms the disease is often limited very strictly to the peridental membranes. So far as I have had opportunity to observe its beginnings, it seems to take the form of a simple gingivitis, presenting a reddening of the gingival margins about the teeth attacked, this soon disappearing as the disease advances, or possibly becoming less apparent on account of the more general reddening of the neighboring gum tissue. At first there will be seen only an irritation of the gingivæ, but after this has persisted for some time close examination will show that the lower margin of the membrane is destroyed here and there in such a way that a thin, flat, but dull, blade will pass up along the side of the root farther than it should. A destruction of the tissue of the peridental membrane has begun, and already there is a slight pocket that contains a very little pus. This destructive process extends gradually toward the apex of the root—*i. e.* follows the length of the fibres of the membrane—and in most cases narrow, deep pockets are formed beside the root of the tooth (Figs. 518 and 519). This may occur only at one side of the root or at two or three points, which may be on the lingual or buccal sides of any of the teeth, or it may attack the proximal sides—indeed, any part of the membrane. As the destructive process extends lengthwise of the root it also more slowly widens, often quite irregularly, extending around the root; so that the tendency is to the destruction of the entire root-membrane. It is usually very irregular in its attacks; cases are seen in which the disease is for some time confined to one side of the root of a

single tooth or of two or three teeth. But the infectious character of the affection is shown by the tendency to attack the neighboring teeth, for in this way they are liable to fall one by one. This liability is not

FIG. 518.

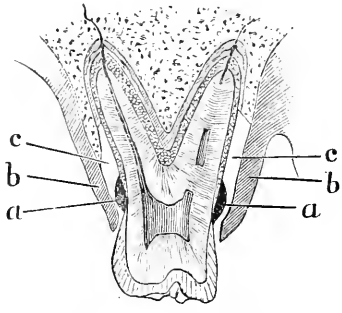

Section of an Upper Molar showing Destruction of its Membrane and Alveolar Wall by Phagedenic Pericementitis: *a*, deposit of serumal calculus; *b*, *b*, gum covering pus-cavity (*c*, *c*) formed by the destruction of the peridental membrane and alveolar wall. (Compare with Figs. 506 and 507.)

FIG. 519.

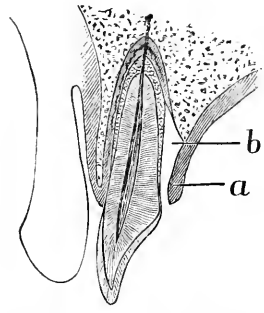

Section of Upper Incisor showing Destruction of its Peridental Membrane and Alveolus by Phagedenic Pericementitis: *a*, gum-tissues covering pus-cavity (*b*) formed by the destruction of the peridental membrane and alveolar wall.

confined to particular groups of teeth, as is the case with inflammation from salivary calculus attacking the lower incisors or upper molars, but seems to attack any of the teeth indifferently, no particular one being more liable to it than others. When the disease is confined to one side of the root, as the lingual sides of the upper incisors, the teeth are very liable to be gradually displaced, moving in a direction *from* the diseased surface; so that the teeth mentioned will slowly protrude forward. This is probably to be accounted for by the swelling of the membrane. In this manner the teeth may be gradually distorted as to their relative positions. This is frequently seen in the separation of particular teeth when the proximal sides of the roots are the points of attack.

More rarely the entire gingival margin of the peridental membrane is attacked at once and all destroyed together. I have seen this, however, in but few instances, the formation of pockets being the rule. These pockets deepen and widen, and finally encircle the root of the tooth, but much oftener pass up the length of the root to its apex before it has completely encircled it. When the disease is not complicated with deposits of calculus, it often happens that the entire apex of the root is stripped of its membrane, while the tooth is still held in place by the membrane of one side of the root, which has as yet been but little affected (Figs. 521, 522). Even in this condition the gums may have a fairly good appearance; they will show more red-

FIG. 520.

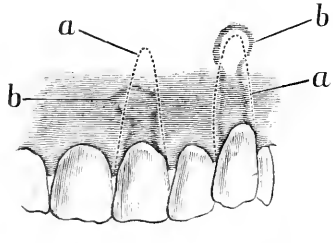

Illustration of a Case of Phagedenic Pericementitis: *a*, *a*, dotted lines representing the outlines of the roots of the teeth; *b*, *b*, irregular lines representing the extent of the destruction of the peridental membrane and walls of the alveolus. It will be noted that the gums appear nearly perfect. (Compare with Figs. 521 and 527.)

ness than normal and will occasionally be deeply injected, especially if the tooth has periods of soreness. Usually there is little or no recession of the gum, and casual observation might not detect the presence of the

Fig. 521.

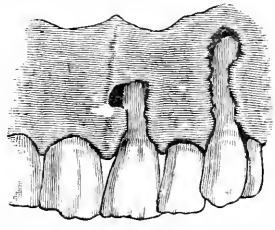

The same case shown in Fig. 519 denuded of the soft tissues to show more plainly the loss of the walls of the alveolus. This drawing was made after raising a semicircular flap of the soft tissues over each root for the purpose of thorough exploration. (See Fig. 527.)

Fig. 522.

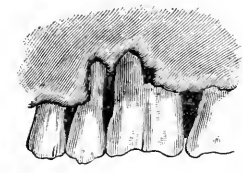

Loss of Bone and thickening of the Borders of the Lost Portion from Phagedenic Pericementitis. Shown denuded of the soft tissues.

disease. In respect to the outward appearance of disease, however, there may be observed the greatest variety.

The margins of the alveolar processes usually disappear as the destruction of the peridental membrane advances. Whether this precedes or follows the destruction of the membrane is often difficult to determine, but I have seen enough cases in which it was clearly demonstrable that the destruction of the peridental membrane preceded the wasting of the process to convince me that such wasting is simply a result of the loss of the membrane, as is the case when a tooth is extracted. There is, however, something more than this; for effects of disease of the process other than absorption are found. In a considerable number of cases, especially those of the more chronic forms of the disease, we may discover a definite thickening of the alveolar wall at or near its margin which is clearly the result of exostosis brought about by the irritation in the immediate neighborhood. In most if not all of these cases the peridental membrane will be found destroyed between this thickened rim and the root of the tooth. Furthermore, if the gum be slit up and turned back, giving time for the blood to be sufficiently cleared away to get a good view of the parts, it is readily determined that the portion of the alveolus lying next the tooth has been absorbed. We have, therefore, an absorption of the inner portion of the alveolar wall and at the same time a deposit of bone on the outer portion; so that finally the margin of the alveolar wall is decidedly thickened in such a way that the gum-tissue is held away from the root of the tooth. This usually occurs on the buccal or palatine wall; this, as it causes the gum to project, can be seen, and may be

Fig. 523.

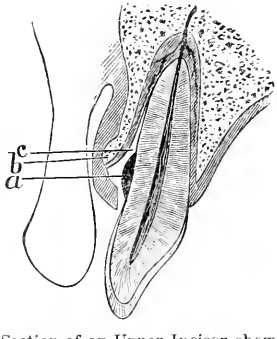

Section of an Upper Incisor showing Destruction of the Peridental Membrane and Eversion of the Alveolar Wall with thickening of its Border: *a*, serumal calculus; *b*, thickened border of the alveolar wall; *c*, pus-cavity.

readily felt with the finger. In these cases the absorption of the inner wall of the alveolus is readily determined by thrusting a delicate point through the tissues inside of this rim and exploring the widened alveolus (Fig. 523). Even in slowly-progressive cases this thickening of the rim of the alveolus is by no means constant, and then the rim of the alveolus is simply destroyed; in this case there is often a characteristic falling away of the gum if the destructive process has eaten away the whole septum between two teeth. The appearance is much the same as that often seen in calcic inflammation, already described. But many cases will be found where there is a deep pocket on the proximal side of the root of one tooth, while the membrane of its neighbor is uninjured; and in this case the gum will usually be supported in its position by a lamina of bone that will remain next to the sound membrane and may appear complete (Fig. 524). The thickening of the rim of the alveolus is usually very irregular and but rarely fully encircles the tooth. It may border the destructive process in any position, and may sometimes be seen bordering a deep pocket over which the whole thickness of the alveolus is destroyed (Figs. 521 and 524); in this way oddly-shaped prominences of the alveolus are occasionally seen. And, as the destructive process is going on beneath this thickening of the bone, there will often be found jagged prominences that will in themselves interfere with the healing process if they are not removed at the beginning of the treatment. This thickening of the alveolus is not seen in the cases that progress very rapidly. The destruction of bone in these cases seems to be a process of absorption rather than molecular necrosis, and is in part the result of the pressure caused by the swelling of the membrane in its inflamed state and partly from the condition of irritation of the membrane causing it to take on an absorptive action. I have seen but few cases in which actual necrosis of the alveolar border could be determined—so few that I must regard this condition as resulting from some accidental condition not necessarily pertaining to the disease.

Fig. 524.

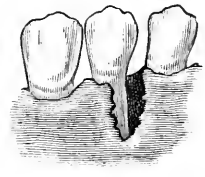

Loss of the Bony Wall of the Alveolus and thickening of the Borders of the Lost Portion from Phagedenic Pericementitis. It will be observed that only half of the septum between the two bicuspids is destroyed; the peridental membrane of only one of the teeth having been attacked, the bone immediately adjacent to the sound membrane is maintained. Also note the separation of the teeth. (Compare with Fig. 528.)

M. Magitot has spoken of absorption of the roots of the teeth in connection with this disease; I had not seen this until recently. Within the past year I have met with two marked cases, in which, so far as I am able to determine, the absorption was due to the irritation of the membrane. It seems evident from the nature of the affection that this would occur but rarely. The membrane is first separated from the root, and absorption of that part of the root could not take place afterward, for the reason that the pus would prevent the contact of the living tissue. I have expected trouble from the absorption of the roots after healing, but as yet have met with no cases. The absorption of the alveolar wall is easily understood, for the living tis-

sue usually remains in contact with it—at least, for a considerable time—and even when it is entirely denuded it contains within its bony structure the elements necessary to bring about its absorption. How much of the eversion of the wall of the alveolus may be due to the pressure caused by the swelling of the membrane is hard to determine. In some cases that I have recently studied very closely I cannot account for the eversion in any other way, impossible as this seems at first glance. All of these seemed to be acute cases. In one I made a very critical examination after slitting the gum and laying it off from the bone. I found the width of the space between the root of the tooth and the bone to be three-sixteenths of an inch. The shape of the space is shown in the drawing (Fig. 525). In this case there had been no complaint of trouble in this locality dating back more than two weeks, and I had carefully examined the mouth six weeks before without discovering anything of this nature. Two years before, I had treated this patient for phagedenic pericementitis affecting a number of the upper teeth, and ever since had kept watch of it to note the progress of the reformation of the alveolar walls lost at that time, some of which are as yet represented only by soft tissue. My own observation, together with the statements of the patient, would indicate that this eversion had occurred within the space of two or three weeks. There had been considerable pain for about a week; and when I first saw it, the gum was inflamed and swollen and pus was discharging freely from under the free margin. I cut out the everted portion of the bone, and after washing thoroughly with peroxide of hydrogen in which 1 grain of bichloride of mercury to the ounce was dissolved I stitched the gum back snugly about the neck of the tooth, and it healed almost as readily as an incised wound. This case seems quite novel; and if it had not occurred in a mouth that had previously been infected with phagedenic pericementitis, I might have passed it by for the time as an abscess occurring from some accidental cause. The other cases of similar character that I have seen have not run so rapid a course.

FIG. 525.

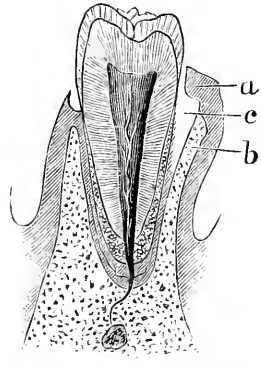

Acute Pericementitis with Eversion of the Alveolar Wall: *a*, swollen gum, which is raised above its normal position on the crown of the tooth; *b*, everted alveolar wall; *c*, pus-cavity, which also appears to contain fibres of the peridental membrane clinging to the wall of the alveolus.

The following case may be regarded as representative of the most acute form of this disease. About one year ago Miss D., a teacher, called on me for advice, saying that for three months she had had pain in the teeth of the right side of her mouth which came on every week or two, would last two or three days, and then subside. The pain was not very severe at any time, but radiated more or less to the *cheek*, malar process, and temple. At these times the teeth on the affected side were sore to the touch and she was not able to chew on that side of her mouth, and latterly some of the molars were sore almost continuously. An examination of the teeth revealed no decay. The eye detected a pro-

nounced hyperæmia of the gums about the molars of the affected side, especially of the upper jaw—not particularly of the margins of the gums, but extending over their entire buccal surface. The gums, however, fitted properly to the teeth without any sign of shrinkage. The teeth showed signs of good care; there was no calculus or other accumulation to be seen about them anywhere. The second upper molar had too much motion in its socket, but would not be called very loose. Taking a thin, flat scaling-instrument, I passed it up under the free margin of the gum of this tooth, and found the peridental membrane completely destroyed over the entire surface of the buccal roots. By passing a small needle-like exploring-instrument through the tissues in various directions I found that the entire buccal wall of the alveolus was gone, and also much of that part of the bone between the buccal and palatine roots. The third molar had a narrow, deep pocket at the posterior part of the buccal surface. About the first molar there were two pockets, which, taken together, almost encircled the tooth, but were not very deep. The first bicuspid had a deep, narrow pocket extending up two-thirds of the length of the root. On the buccal side, extending around to the proximal side of the anterior root of the lower first molar, there was a pocket extending almost the length of the root, with a corresponding loss of bone. There were a few other points of attack of less note in other parts of the mouth. By reference to my records I found that I had not examined the lady's mouth for fourteen months. I had made a large number of fillings for her in the years past, and had known her as a very careful patient. I feel very certain that there could have been no beginning of this disease prior to my last examination of the mouth, therefore all of this destruction had occurred since that time. The patient had noticed it only three months before. I extracted the upper second molar, and then found that the only part of the peridental membrane that was perfect was that of the palatine side of the palatine root; all of the membrane was destroyed but this. No salivary or serumal deposits whatever were found upon the tooth or its root. The remaining teeth were at once put under treatment, and by the use of antiseptic stimulants a cure was readily effected, with complete restoration of the membranes.

In another instance a lady came to me with one of her bicuspids in her hand. She said that on account of its apparent looseness she had called the attention of her dentist to it only a month before, and had been informed that no disease could be found. Two days before calling on me she had picked it out with the thumb and finger. An examination revealed the fact that there was very serious destruction going on about the roots of a number of the remaining teeth. Usually, the gums do not show much inflammation unless the case is complicated with deposits of calculus, and in this case there was so little appearance of any serious disease that a dentist of good repute had failed to discover it, though his attention had been directly called to it by the patient.

These I regard as the most typical cases of the acute form of the disease when not complicated with deposits of calculus. The rule is that the progress is slower and there is more appearance of disease to be seen in the neighboring parts than in the cases just cited. I have one case

now under observation that for five years I have been watching without using anything more than a little palliative treatment. When I first observed it, it was in its inception, and I have had the opportunity of frequent examination; and, fortunately, there has been only very little salivary calculus to complicate the case, and this is confined to the lower incisors. In this time eight teeth have been lost, and some others are in a very precarious condition. Soreness of the affected teeth comes on at irregular intervals, lasting a few days at a time and then passing away. This is common to the most of these cases, though I have seen a number that had made considerable progress without any complaint of pain at any time.

A class of cases occur on the lingual sides of the superior incisors that seem rather different from the usual types, and yet are evidently of the same nature. They are generally complicated with serumal deposits on the necks of the teeth, and I think occur oftenest in those persons that breathe mostly through the mouth. They have generally been rather persistent. Fig. 527 is a sectional illustration from one of these. The gum is usually thickened from the inflammation of its tissue and on account of the loss of the alveolar wall recedes, exposing more or less of the roots of the teeth. The teeth are often protruded to such an extent as to render them unsightly. They are usually very slow in their progress, and are apt to have serumal deposits extending high up toward the apex of the root.

FIG. 526.

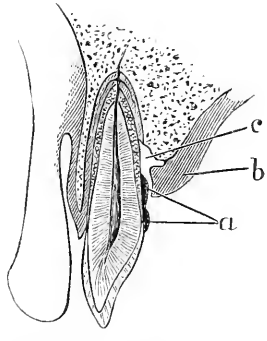

Phagedenic Pericementitis complicated with Serumal Calculus on the Lingual Surface of the Upper Incisors (sectional view): *a*, serumal calculus; *b*, inflamed and thickened gum that has fallen into the space made by the loss of bone, exposing a part of the serumal calculus; *c*, pus-cavity.

Thus far I have spoken mostly of that class of cases that have not been complicated with deposits of salivary or serumal calculus. This may be said to be the simplest form, but it is not the least destructive one, for I have seen the peridental membrane destroyed as rapidly without deposits of calculus as with them. Indeed, so far as the results are concerned, the presence of calculus seems to make but little difference. *The great majority of the cases are complicated with these deposits.* The rule is that we find nodules of serumal calculus under the margin of the gum even though the mouth has been well cared for; and if there has not been good care as to cleanliness, there will usually be deposits of salivary calculus also. When this occurs in considerable quantity, the appearance of disease becomes much more apparent because of the greater inflammation of the gum-tissue caused by the calculus. Here we have, in fact, the two diseases existing together—calcic inflammation from the deposits of calculus, and phagedenic inflammation farther up toward the apex of the root of the tooth. It is evidently this dual form so often presented by these affections that has so long delayed the recognition of the phagedenic variety as an independent disease. Every one who has had any considerable experience in the treatment of this class

of cases must have noticed the great differences they manifest in regard to healing after the removal of the calculus. This is not to be explained in all cases by imperfections in the performance of the operation. A certain minority of the cases will not heal, no matter how perfectly this is done; but the turgescence of the gum will diminish while the discharge of pus continues and the destructive process is still in unabated progress. This is the one fact that has so discouraged the profession with the treatment of these cases. It often has happened that the cases that promised the best results have proved the most rapidly destructive; it thus becomes a matter of the greatest importance that we be able to determine whether we have in a given case only an inflammation of the gums from deposits of calculus—calcic inflammation—or whether there is in addition a phagedenic inflammation of the peridental membrane. Our prognosis will be far more favorable if we determine that we have only a calcic inflammation to deal with. The absence of pockets extending up beside the roots of the teeth above the deposits of calculus (toward the apex of the root) is the surest indication of the absence of the phagedenic form of the disease. If this disease is not present, it will be found, when the last of the salivary calculus is removed, that the peridental membrane is intact just above—that is, it is attached to the root of the tooth. There are no points where the peridental membrane is destroyed much farther than the calculus has extended. The calculus may, however, have extended so far as to cause the loosening of the teeth, and thus bring about their loss. In this case there is usually far more wasting of the tissue of the gum than in phagedenic pericementitis, and there is usually, perhaps generally, a peculiar thickening of the tissue of the peridental membrane at the apex of the root—the tissue of the apical space—which holds the tooth quite firmly and yet allows it to shake about in the remains of the socket. This condition is quite uniformly *absent* in phagedenic pericementitis; so that the tooth *drops from its socket*, often almost without effort, though it has not seemed very loose—that is, did not shake about much in the remains of the socket. This difference is quite characteristic.

If the disease is phagedenic pericementitis, we will, on the other hand, when the calculus is cleared away, find that the peridental membrane is destroyed at particular points much farther than the calculus has extended on the root of the tooth, forming the pockets I have described, and the wall of the alveolus, instead of being destroyed as a whole, is destroyed somewhat in the form of fissures extending toward the apex of the root; or it is only over a portion of one of the surfaces of the root, leaving angular prominences of the bone that are often unduly thickened, as though the margin of the bone was everted. In the final loosening of the tooth it will usually be found that it is at last held by a portion of the membrane of one of its sides, the membrane over the apex of the root having been destroyed. These differences, as they are closely studied from day to day in the examination of the cases that present themselves for treatment, become quite characteristic and afford a pretty reliable ground of diagnosis. I have given these points at some length for the reason that they have been so generally overlooked by the profession.

It may here be said that cases occur in which the usual types are variously combined, and which cannot very certainly be assigned to either one or the other class. These will generally be old chronic cases of calcic inflammation which have been in progress for many years, and in which the gum tissues have been brought to so low a state of vitality that they no longer resist the encroachments of the ordinary micro-organisms of the mouth and are continually invaded by them. In these cases some wide pockets may be seen by the side of the roots of the teeth, but there is a more general wasting of the tissues and a more dilapidated appearance of the whole apparatus of mastication. In this class of cases it is common to see nearly all of the teeth loose—perhaps very loose—at one time, none, or very few, having been lost, all being held by the thickening of the tissues of the apical space. This state of things is characteristic of the last stages of general calcic inflammation of the peridental membrane and gums, and is seldom or never seen in the phagedenic variety.

Another point should not be overlooked. It sometimes happens that a case of alveolar abscess simulates the form of phagedenic pericementitis so closely as to cause a mistake in diagnosis. In this case an abscess occurs at the root of a tooth from the previous death of the pulp and consequent apical pericementitis, and the pus, instead of being discharged by any of the more usual routes, eats its way along the side of the root and is discharged at the margin of the gum. In this process the peridental membrane is destroyed over one side, or a portion of the side, of the root, forming a narrow pocket in some cases very much resembling the very deep pockets of phagedenic pericementitis. If in such cases it is remembered that when pockets of such magnitude are formed by the disease in question there are very sure to be other points of attack in the neighborhood, it will do much to clear up the diagnosis. The absence of these should always rouse a suspicion that the case may be one of alveolar abscess and lead the inquiry in that direction.

Of the ETIOLOGY of phagedenic pericementitis we have no very definite information. It seems most probable that the disease is caused and maintained by the presence of some peculiar fungus or form of micro-organism and that it is infectious. Some years ago I thought I had detected a form of fungus that stood in a causative relation to it, but further study has placed the matter in such doubt that I prefer to consider it as not proven. Others have also pointed out a seeming causative connection of certain forms of micro-organisms with the disease.

Dr. Arkoevy of Buda-Pesth says:[1] "There constantly occurs a certain fungus-formation which I find in close connection with the wasting of the alveoli and gingival margin, as well as the subsequent loosening of the teeth; it is quite different from leptothrix buccalis, although it is in developmental relation with it." Dr. Arkoevy seems to think that the fungus stands in causative relation to the disease. Dr. Joseph Islai, of the same place, has also studied this fungus, and expressed a similar conviction. Dr. Adolf Witzel of Essen, Germany, describes the disease as "infectious alveolitis" and considers it to be primarily of the alveolar borders. He says:[2] "We have, in fact, to deal neither with an ulceration

[1] International Medical Congress, London.

[2] *British Journal*, 1882.

of the gum nor with a primary inflammation of the periosteum, but with a molecular necrosis of the alveoli, or caries of the dental sockets, produced by *septic* irritation of the medulla of the bone." Again, Dr. Witzel says: "Should you ever chance to extract a tooth at the early stage of the disease, you will find the soft disorganization of the dental periosteum confined to the neck of the tooth. The remaining portions of it are velvet-like and loosened, and present a brilliant vascular injection increasing toward the root and associated with small nodules and lobular granulations. I have not yet examined these growths for nests of micrococci, but I have no doubt that they are to be found not only in the granulations, but also in the infected medullary tissue of the interalveolar partition. In the pus which may be obtained from the affected alveoli by pressing the gum we observe under the microscope a countless number of micrococci and bacteria, which doubtless find in the pockets of the gum tissue the most favorable condition for their continuous development."

I have with some care repeated the observations here alluded to and made many others of a like nature, and there can be no doubt as to the facts of the presence of micro-organisms in these situations. All these observations are very suggestive and show conclusively that these particular tissues are invaded by micro-organisms. My own observations, however, are not explicit in determining a single variety in these positions, and are therefore not sufficiently definite. There is such a profusion of micro-organisms constantly found in the mouth, especially in conditions of disease, that it is a work of the utmost difficulty to separate them and single out that particular form which produces the mischief and obtain experimental evidence of the fact that will bear the test of adverse criticism. Until this is done in a way to satisfy the critical demands of science it cannot be positively affirmed that this is a disease that owes its origin to the life and growth of micro-organisms. There are, however, other forms of evidence, which, while not so positive in their nature, may be of use in the absence of better testimony; these also point to micro-organisms as the cause of the disease. They may briefly be stated as follows: Those remedies that are known to destroy micro-organisms influence the disease most favorably; indeed, no other form of medication has been known to produce decidedly favorable results. The complete removal of the diseased tissue will often be sufficient to produce a cure. The presence of the disease in one part of the mouth is generally followed by its appearance in the neighborhood. It is observed that the disease will not flourish except in situations in which a fungus-growth would have some form of protection against the free flow of the buccal fluids such as the pockets formed by rather deep free margins of the gum will give; hence the cure of the disease by the removal of all free margins of the gums. Besides this, I have observations which, though they are not of such a nature that I can make a scientific use of them, fully convince me that the disease may be transplanted from person to person—that it is inoculable; hence it may be transplanted to the cleanest mouths, and the greatest care should be given to the instruments used in the treatment of these cases, to prevent its being conveyed to others. This point is

certainly true whether the disease is due to a fungus or not. The facts I have given show conclusively that it is purely a local disease, and not dependent upon any poison circulating in the blood of the patient or upon any systemic disorder. I have also become satisfied that it is in no wise hereditary, as is the disposition to the deposit of calculus; yet it seems likely that deposits of calculus do predispose the patient to this disease by placing the free margins of the gums in a more favorable condition for its propagation. Farther than this I do not think the deposits of calculus favor its development.

In making these statements I have not overlooked the fact that many who have written on this subject have regarded the disease as due to constitutional causes, and that in our journal literature we have reports of many cases in which such causes have been assigned. Among these may be found in turn nearly all those diatheses that are obnoxious. In these reports it is seldom that we find descriptions that will enable us to identify with certainty a specific form of disease of the peridental membrane; indeed, in most of the cases reported, the descriptions are so vague that we are unable to say whether the particular case was a gingivitis from constitutional causes, a simple calcic inflammation, or an inflammation of the phagedenic variety. For this reason the value of most of the reports that have been made is essentially limited.

That cases of inflamed gingivæ with extension to the peridental membrane occur from constitutional causes I have conclusively shown. Such disease may be produced at will by the use of mercury and other known substances, and we have every reason to conclude that such disease may be produced by agents that are entirely unknown to us circulating in the blood. Until we can differentiate these forms from the calcic and phagedenic varieties in the reports given us it is difficult, however, to estimate the true value of the observations.

The gouty and rheumatic diatheses have been regarded as contributing to inflammations of the peridental membrane; this opinion seems to be quite generally entertained by English practitioners whose opportunities for the observation of such cases, especially of the gouty diathesis, are very abundant. In my locality this disease is rare, but among the few families subject to it who have come under my observation disease of the peridental membrane has not appeared except in a few cases which were clearly calcic, and which promptly returned to a state of health without other treatment than the removal of the local cause. As to the rheumatic diathesis, my opportunities seem to have been sufficient; but an analysis of my cases of disease of the peridental membrane of all sorts fails to connect this diathesis with them as a cause.

The scrofulous diathesis seems to favor the development of any of this group of diseases. From my personal observations I should say that this influence is to be regarded purely as a predisposing cause—a condition in which the tissues of the individual have less power of resistance, and therefore more readily succumb. Anæmia and various other disorders or conditions serve much in the same way as predisposing causes.

The TREATMENT of phagedenic pericementitis calls for certain opera-

tions in common with the treatment of calcic inflammations. In all cases the first thing to be done is to discover and remove any and all deposits that may be on or about the necks of the teeth or their roots. In the phagedenic form of inflammation this presents greater difficulties than in the calcic form, for the reason that the deposits are often situated farther up on the roots and are more covered in by the soft tissues. It also happens more frequently that lying close against the sides of the roots of the teeth there will be found very thin scales, these being so smooth that their outlines are with the greatest difficulty detected by the touch; for this reason much care and patience is required for their complete removal. This operation, however, must be absolutely complete in order to effect a cure. This calculus, which is usually of the serumal variety, is an irritant, no matter how small the amount, and any parts left will serve to keep up the irritation.

As I have described the process and the instruments for the removal of the scales in treating of calcic inflammations, repetition is unnecessary. I would only urge the necessity for absolute perfection in this operation. With the removal of all deposits from the teeth the similarity in the treatment in the two diseases ends, for in calcic inflammation the tendency is to spontaneous cure when all calcic deposits are removed, but in the phagedenic forms there is no such tendency.

The further treatment is best considered under two heads—Surgical and Medicinal. In a large proportion of the cases the *surgical* treatment may end with the removal of the deposits from the necks of the teeth. This applies to all those cases in which there has as yet been but little destruction of the pericementum and alveolar walls and not much thickening or eversion of the alveolar margins, and will presently be considered.

In the graver cases surgical operations sometimes seem necessary—not but that we may effect a cure without them, but the cure will be accomplished much more readily with them. When there is rapid destruction of the tissue and a considerable portion of the alveolar wall has been destroyed and much of the peridental membrane detached from the root of the tooth, it is found better to cut away some parts of this with instruments. The pericementum is in a state of molecular disintegration and the alveolar wall is undergoing active absorption. Experience seems to demonstrate that the direct removal of a portion of these with instruments will expedite the cure. The means of doing this will vary greatly with the case. In cases in which the destructive process has not been very great and the diseased parts can be readily reached with an instrument passed up between the tooth and the gingival margin, a hoe-shaped excavator with a broad cutting edge or a chisel bent at an angle of twenty-five to fifty degrees may be introduced and the margin of the alveolar wall cut away as far as the judgment of the operator may dictate. This should usually be carried to such an extent that the bone may be felt to become firm and resistant to the cutting edge of the instrument. In this operation the greatest care should be taken not to wound or injure the gingival margin. This remark applies, however, only to that margin. The soft tissue farther up toward the apex of the root may be lacerated con-

siderably without evil result; but if the gingival margin be broken down or so injured as to cause a slough, this margin will be lost, and will defeat our efforts to obtain a reformation of the peridental membrane in its completeness. The stretching of the gingival margin by an instrument passed through for cutting away the process or the removal of the calculus is sometimes a serious evil. After the operation is completed the gingivæ should close around the neck of the tooth as well as, or better than, before it was begun. The closing of the gingival aperture in such a manner that irritating substances, and even the saliva, may—in the main, at least—be kept out will diminish the growth of micro-organisms to the minimum and expedite the cure. In cases still more grave, in which the cutting away of the diseased borders of the bone cannot, without injury, be well done through the gingival aperture, other modes of operating should take its place. The gums should be cut through directly over those portions of the alveolar wall to be removed or in such position that they will be readily reached with the instrument. This may be in the form of a puncture through which an instrument may be passed in several directions, or a flap of the soft tissue may be raised as represented in Figs. 527, 528, and the tissues

FIG. 527.

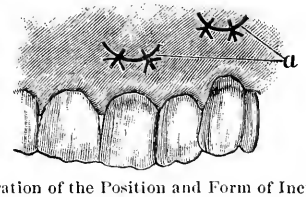

Illustration of the Position and Form of Incision through the Gum for exposing the Root of the Tooth and injured Alveolar Process: *a*, incisions. (Compare with Figs. 520 and 521.)

FIG. 528.

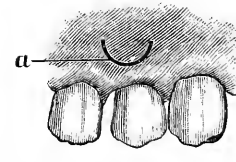

Incision for the Treatment of the Root and Alveolar Process in a Case of Phagedenic Pericementitis. (Compare with Fig. 524.)

beneath exposed to view. In this way the gingival margin may be saved from injury, and the denuded root of the tooth may be closely examined for any traces of calculus or other deposits and most thoroughly cleaned, while the trimming of the alveolar wall may be more perfectly done. After all is satisfactory and the wound properly washed as presently, described the flaps should be replaced and stitched down. In all cases the cutting of the alveolar walls should be done in such a way that the soft tissues will lie closely against the roots of the tooth. No spaces should be left intervening, for all such become pockets for the growth of micro-organisms and the formation of pus, which invariably retards the cure; therefore it is especially necessary that all jagged points of the bone be removed, all thick edges be trimmed down or broken away. All eversions of the alveolar wall should be cut off or their form so modified that no intervening space shall be left between them and the root of the tooth. In cases of eversion of the alveolar wall or thickening of its borders without considerable destruction of the peridental membrane, this may be cut away by a few well-directed blows of a chisel passed directly through the gum, and the bone so broken down that it will lie close in against the root of the

tooth. The pieces may be left in this position rather than mutilate the gingival margin in the effort to remove them. If they become necrosed, they will be thrown out within a few days, or will, if they retain their vitality, become united with, and assist in the rebuilding of, the alveolar wall. In those cases in which very deep pockets have formed extending lengthwise of the root of the tooth, with thickened borders of the alveolar wall on either side, I have found it best to raise a semicircular flap of the gum in order that I may reach both sides with the chisel and pare them down in such a way that the soft tissues may lie in smoothly against the root of the tooth. I regard the chisel as much better for this purpose than the burr. The burr driven by the engine produces unnecessary injury of the soft tissues in very many instances, and the trimming of the alveolar process is usually not so evenly and perfectly done as with the excavator or the chisel and the injured tissues are left in a much worse condition. Besides, there is more danger of injury to the gingival border. The object of this operation is twofold: first, the removal of tissues sunk so low in the scale of vitality as to be unable to recuperate, and with them the removal of the micro-organisms by which they are invaded; in this way the operation acts as a powerful antiseptic. A reasonable degree of mutilation of the subjacent tissues acts as a stimulant and invites the formation of granulations for the restoration of the lost parts; if, however, the mutilation of the tissues be carried too far, the injury will overbalance the good results. Second, the placing of the tissues in such position as to obliterate all interspaces, so that granulations may be the more effective in forming reattachments and repairing the injured parts.

It is important that all blood-clots be removed. This is true of all surgical wounds, and here it is doubly so, for the reason that the clot will so generally become septic. A bloot-clot, as such, is perhaps not an irritant, yet it is always a hindrance to the process of repair. It never becomes organized, as was held by the older pathologists, but is removed by a process of absorption. Granulations grow out into its mass, and the clot disappears as they advance; therefore, even when the clot does not decompose, considerable vital energy is expended in its removal and the granulations are diverted from the immediate work of connecting the different parts of the lesion. In this particular instance the clot is almost always decomposed by the micro-organisms present in the tissues or entering from without; therefore the parts should be washed with a peroxide-of-hydrogen solution of bichloride of mercury (1 grain to the ounce) in order to remove all blood-clots, and for the further purpose of rendering the parts as nearly aseptic as possible. Then, if a flap has been raised, it should be stitched in place. It is only in a few of the more acute cases that we may expect the parts to unite with the root of the tooth by first intention, but it is often desirable that the wound through the gum tissue should unite at once; this it will very generally do if the parts are placed well in apposition. If they are not so placed, the fluids of the mouth are liable to wash away the granulations and considerably delay the union. In order to prevent this, I am in the habit of first, after thoroughly drying the parts, covering the immediate wound with a bit of tissue-paper and then coating the whole

surface with a solution of gutta-percha in chloroform; this completely seals up the wound and prevents it from becoming septic, in addition to the protection to the granulations. This, if desired, may also be used to seal up the gingival margins after operations through the gingival aperture, by first drying the parts thoroughly and packing the gutta-percha around the necks of the teeth. In order to render it more secure in its position, a wire or thread may be used to first secure to the teeth a small piece of undissolved gutta-percha, to which the solution may be added. This means of sealing the gingival margins would be very valuable if the gutta-percha would cling to the gums with more tenacity, but it will generally hold for two days if well applied. Some effort in this direction has been made in the way of the construction of plates to fit over the parts, but such an apparatus is likely to do more harm by the collection of irritating agents under it than good by preventing friction. The requirement of such an appliance is that it shall hermetically seal the parts. After these operative procedures the further treatment is to be conducted as recommended for the simpler cases that are treated without other surgical interference than the thorough cleaning of the necks and roots of the affected teeth.

Many cases of this disease will be met with in which operative procedures further than the thorough cleaning of the necks and denuded portions of the roots of the teeth are entirely unnecessary. If there are no thickened or roughened margins to interfere with the contact of the parts, in many cases the medicinal treatment may be begun at once, even when considerable portions of the alveolar wall have been lost.

Some of the cases will present no calculus whatever to be removed, but even in these the roots should be well cleaned, for a close examination will show them to be coated with an apparent gummy material which clings quite closely and tenaciously to the root and should generally be loosened with an instrument. This is usually composed of micro-organisms and a kind of inspissated mucus or pus. The cavity or pocket should now be thoroughly washed with peroxide of hydrogen, for the removal of all débris. This and all subsequent washings may be done with peroxide of hydrogen in which a grain of the bichloride of mercury to the ounce has been dissolved. This combination has become quite a favorite in my hands for the beginning of the treatment, on account of its very fine antiseptic qualities. This washing should be done with the Farrar's syringe, or other instrument possessing its advantages.

In most cases we may go directly forward with antiseptic stimulant remedies presently to be described, but in some of the more acute forms the gums and soft tissues will occasionally be found much congested and turgid with blood. In such cases, after thoroughly cleaning the parts and washing with the peroxide of hydrogen and bichloride of mercury, it is well to begin the treatment with the application of a 30-per-cent. solution of chloride of zinc; this should be applied deep down in the pockets. After one or two applications of this remedy others of a different character should take its place, for its principal use is that of an astringent for the reduction of the calibre of the blood-vessels, which have become abnormally large. This remedy, however, possesses another

advantage in its antiseptic quality, which in this disease is very important. In phagedenic inflammation, whether acute or chronic, the inflamed tissue is usually very slow in the formation of granulations for the reattachment of the peridental membrane and restoration of the lost parts. The tissue seems to have lost tone; the character of the irritant or cause seems to be such that the tissues are lowered in their vitality, and for this reason they require a stimulating course of treatment in order to induce them to form granulations. For this purpose there is perhaps nothing yet discovered that acts better than the oil of cinnamon, but, as the destruction of the micro-organisms found growing in the tissues is an important desideratum, carbolic acid may be added, in the proportion of 1 part of carbolic acid in crystals to 2 parts of oil of cinnamon, or the mixture recommended for the treatment of alveolar abscesses may be used.[1] This should be applied within the pockets regularly once in four days.

The object of this treatment is twofold: first, the destruction of the micro-organisms or the removal of the septic character of the disease; second, the stimulation of the tissues, whose vitality is low. In pursuing this treatment it is especially important that the application be made with regularity. I have pursued this plan of treatment, closely studying the cases day after day by aid of the microscope, and have found that the next day after the application of the remedy no micro-organisms could be found in a mobile state, and all efforts in staining and searching in this way for micro-organisms among the tissues have failed, but on the fourth day they will usually be found. This plan of treatment is very much like the weeding of a foul garden: we may go over it to-day with a hoe and destroy all the growing weeds, but within a few days young weeds will be found springing up again, and it is necessary to repeat the operation. We may destroy the growing weeds with the hoe, but we cannot destroy the seeds that are in the ground; therefore the hoeing must be repeated time after time for success. The seeds that are in the ground must sprout and the sprouts be destroyed. Just so with our treatment in this disease: we can destroy the growing micro-organisms with our remedy, but we cannot destroy the spores that are in the tissues; therefore the treatment must be followed up week after week until the spores have been eradicated from the tissues. Then we may expect the healing process to go on undisturbed and the tissue to recover its normal tone. This is the theory of the treatment, and is found to succeed. I mention the particular remedies that are favorites in my hands, but it is not necessary that these special ones be used. Any other remedies that may answer a similar purpose—and of these our materia medica furnishes many—may be used instead.

If the operator understands the principles upon which the treatment should be conducted, he should have but little difficulty in the selection of suitable preparations. In addition to those which I have mentioned,

[1] 1-2-3 Mixture.

Take of Oil of cinnamon, 1 part.
Carbolic acid (crystals), 2 parts.
Oil of gaultheria, 3 " Mix.

Dr. A. W. Harlan of Chicago has been instrumental in the introduction of a number of agents that are very valuable. Among these I will mention the iodide of zinc in solutions of various strength as an astringent and stimulant, combinations of iodoform and eucalyptus, iodoform and eugenol, iodoform and oil of cinnamon, weak solutions of chloride of aluminum in water, 1 to 3 grains to the ounce, sanitas and eugenol, 3 parts of the former to 1 of the latter, as a germicide and tissue stimulant, resorcin in solution, from 8 to 24 grains to the ounce of water, as an antiseptic and tissue stimulant. All of these except the iodoform combinations are to be injected with Farrar's syringe into the pockets once in four days. The iodoform mixture may be packed into the pockets.

Dr. T. L. Gilmer of Quincy, Ill., has used phenol camphor[1] successfully in the treatment of this affection. He regards it as especially useful in obstinate chronic cases, and has found it succeed where other remedies seemed incapable of preventing the continuous discharge of pus. It is certainly a good parasiticide and its stimulant qualities seem very excellent. Its taste will be very objectionable to some persons. It is to be injected into the pockets in the same manner as the other remedies named.

The washing with the peroxide of hydrogen, either with or without the addition of the bichloride of mercury, should generally be repeated at each sitting, for the purpose of freeing the pockets from all débris before the application of the other remedies. Lately I have successfully treated some cases with this alone.

In the after-treatment of all cases the greatest care should be taken to prevent injury to the granulations in process of growth. Usually, after a decided disposition to heal is shown, the treatment should be limited to keeping the parts well cleaned. As a wash for the patient to use with the brush during the treatment the ordinary cinnamon-water of the United States Pharmacopœia is very excellent and agreeable. Most of my patients, however, have used the *1-2-3* mixture (page 984) diluted to about one-half with oil of anise or oil of lemon, or without dilution, by placing half a dozen drops on the brush once per day. This mixture seems to be in general use among physicians of my acquaintance for the treatment of catarrhal affections of the mucous membranes, especially the chronic forms, and its results are especially good. Any disinfectant stimulant wash will be beneficial, though not much reliance can be placed on anything of this kind, for the reason that it cannot be applied to the diseased parts (within the pockets) by the patient.

Just here a word in regard to the action of antiseptics may be important. A great majority of the antiseptics which are safe for use in connection with living tissues are depressant of the living forces and act directly to impair the functional activity of the living cells. For this

[1] Phenol camphor is prepared as follows:

Take of Carbolic acid, in crystals, } each ℥ss.
Gum camphor, }

Mix and heat on a sand-bath until both are melted; they combine to form an oily liquid.

reason the use of a strong disinfectant agent in this disease cannot be recommended, for, instead of building up, they tend to further depress the tissues already lowered in tone; therefore in their use it is especially necessary that some agent be combined with them to counteract this influence. Yet this can be only partially done, because any agent which will depress life in the form of micro-organisms will also depress life as it exists in the individual cell in the tissues; yet experimental study of the action of remedies shows us plainly that the different antiseptics depress the life-force of the animal cells and that of the micro-organisms in a different ratio. Hence there should be discrimination in their selection. Carbolic acid possesses this depressant power in a very marked degree. In the combination of carbolic acid with the oil of cinnamon and the oil of wintergreen the depressant effect of the carbolic acid is reduced to the least degree as to its action on the animal cells, while retaining its power over the vegetable cells. In this way we retain that quality of the carbolic acid desired, while we remove its undesirable properties. In eugenol we have also an antiseptic possessing a minimum depressing power over the animal cells; hence it is valuable in the treatment of this affection. In the bichloride of mercury we have an agent seemingly possessing very peculiar power over the life of micro-organisms—an agent which in solutions of *1 to 300* or *1 to 1000 parts* seems to destroy the life of these low organisms without especially influencing the animal cells with which it may come in contact. In studying the effect of these solutions I have been unable to discover that they produce any marked local depression; this would indicate that their depressing power is rather feeble. Carbolic acid used in the same way would cause marked local depression. This quality of carbolic acid renders it inapplicable, in its unmodified form, for use in this disease.

In regard to the reparation of the peridental membrane and the alveolar wall in this disease it may be said that repair rarely or never takes place after the manner of healing by first intention, but is always by granulation. Granulation may begin in the tissues overlying the parts of the root, but the reattachment creeps in from the margin of the injury where the peridental membrane is intact, or from the extremity of the pocket above, and slowly covers over the denuded portion of the root of the tooth. This is usually a slow process, but varies greatly in different cases. In explanation of this three theories may be entertained: *First*, in those cases in which the destruction of the membrane is traumatic or very recent it may be supposed that the cementum covering the root has not lost its vitality, and that its cells may grow, subdivide, and throw out processes beyond the surface of the cementum which may join with the granulations from the soft parts. In this way we can suppose the peridental membrane to be reformed, or rather reattached to the root of the tooth by first intention. As a fact, we see this occur in case of incision. Observation shows that this does not occur in the healing process following this disease. *Second*, we may suppose that, the cells of the cementum having lost their vitality, the granulations from the soft tissues grow into the old canaliculi or lacunæ of the cementum and reinhabit them, and in this way the reattachment is

formed with the root of the tooth. *Third*, we may suppose that the cells or granulations from the soft parts grow into the root of the tooth and remove a portion of the old tissue of the cementum by absorption and reform so much of it as may be necessary, and in this way reattachment occurs. However it may be, it is certain that the peridental membrane will attach itself to the root of a dead tooth, for otherwise Hunter would not have succeeded in any case in obtaining the attachment of the peridental membrane to the root after boiling the tooth, and yet this mode of preparing teeth for the purpose of replanting was recommended by him in 1778. In this case we must assume the reattachment of the peridental membrane to be that of the second or third of the supposititious forms above mentioned. In a large proportion of the chronic cases, at least, of this disease, the reattachment must be in the same way.

In the treatment of phagedenic pericementitis the complete reformation of the peridental membrane should be expected in all cases if the gingival margin has remained intact. Just so far as the margin of the gum may have receded from its normal position, just so far will we fail of regaining the reformation of the peridental membrane—that is to say, if a portion of the root of the tooth is uncovered, we cannot expect a reformation of its peridental membrane at that point.

The renewal or reformation of the alveolar wall is far more uncertain, yet in most cases this will also be reformed. I have examined my cases very carefully on this point, and have found that in most of them the alveolar wall has been slowly reproduced, yet in some in which the reformation of the peridental membrane has been complete the alveolar wall has not reformed during the two or three years the cases have been under observation.

These, so far as I have yet observed, are all cases in which there was much eversion of the alveolar wall, which was not cut away at the time of the treatment. These observations have determined me hereafter to cut away much more freely.

Sponge-grafting suggests itself as a means of renewing the gingivæ and lower border of the peridental membrane when lost from this disease. Soon after the introduction of this operation in general surgery, a few years ago, I made trials of it in the mouth with the view of testing its efficiency in the restoration of lost parts. For this purpose very fine sponge thoroughly freed of sand is prepared by macerating it in dilute hydrochloric acid, to remove any calcareous material it may contain. It should then be rendered aseptic by maceration in some one of the antiseptic solutions—preferably, one that will be the most nearly non-irritant to the granulations to which it may be applied. Thus prepared, the sponge is cut to a suitable size and applied to the granulating sore in such position, form, and quantity that it will represent the lost part, due allowance being made for after-shrinkage of the newly-formed tissue. The granulations will quickly grow into all of the meshes of the sponge and completely fill every space. The growth of the granulations seems to be stimulated and greatly accelerated by the presence of the sponge, while its meshes seem to act as a ladder on which they climb, so that the form of the sponge directs the form of the growth. The

sponge, when enclosed by the granulations, is absorbed; in other words, it is digested or dissolved in a material elaborated by the granulations in contact with it, and in this form taken into the circulation. It is thus removed completely, leaving newly-formed tissue in its place. This new tissue is, of course, scar or cicatricial tissue, and shrinks very much after the absorption of the sponge; it is therefore necessary that the sponge should be abundantly large when first applied.

Under favorable conditions the granulations grow into the sponge with such facility and so rapidly that it seems to offer a wonderful opportunity for the restoration of lost parts. The sponge can be trimmed to any form desired, so that the space left by the sloughing of the part or tissue destroyed by accident can be very perfectly refilled. In practice, however, some serious objections to its use have been developed, which, as they have come to be understood, have very much modified the opinion of surgeons as to its general usefulness. In the first place, in those cases in which the sponge-graft seems to have done well, the new tissue that has grown is often very poor in quality and liable to excessive shrinkage. The second, and worst, objection to its use is that the sponge-graft is especially liable to become septic. It seems to offer a remarkably favorable harbor for septic micro-organisms, and not unfrequently non-pathogenic forms will fill the sponge in such numbers as to do great mischief. When these pests have once gained a foothold in the sponge, it is next to impossible to dislodge them with any antiseptics that can be applied with safety to the granulations. All this is true in any case in which the sponge-graft can be applied, and has caused its abandonment by the careful surgeon in all but the most necessary, and at the same time most promising, cases. These are cases of loss of tissue on exposed parts where antiseptics can readily be applied, and where the wound is not subject to irrigation by any of the secretions but its own. Wounds of the hands or feet in which the parts, wound, sponge-graft, and all, can be frequently immersed in an antiseptic lotion or can be perfectly sealed by dressings impervious to micro-organisms, offer the most favorable conditions for the sponge-graft, while, on the other hand, the natural cavities of the body, in which these precautions are impossible, are the most unfavorable positions for this procedure.

In my efforts at sponge-grafting for the renewal of the peridental membrane and gingival margin I have proceeded in this wise: After determining by examination the size and form of the space, a suitable piece of prepared sponge is cut as near the required form as practicable and placed well up into the pocket, between the remaining portion of the gum and the root of the tooth. It should be of such form and size that when thus placed it will cover the exposed portion of the cementum and extend farther down on the crown of the tooth than the gum should do, so that it may be secured in position by a ligature passed about the tooth. The space for the reception of the graft can often be improved and its form more accurately determined by tenting with antiseptic cotton for a few hours before the application of the sponge. If the case progresses favorably, the granulations will within twenty-four hours have grown into the meshes of the sponge to such an

extent as to secure it in its position, and the ligature is no longer needed except to retain the sponge in immovable contact with the cementum of the root of the tooth, and thus favor the attachment of the tissue. In a few cases this has been accomplished, but even in these but little good has resulted, seemingly because of the poor quality of the new tissue, while a large proportion of the cases failed utterly on account of inflammation and suppuration, induced, apparently, by the foul condition of the sponge.

In the mouth antiseptic precautions are next to impossible on account of the flow of saliva and its constant contamination with micro-organisms. Indeed, in this position the sponge cannot be kept in good condition for a day by any precautions thus far known to us. I have thought to accomplish this by applying antiseptics very frequently, but have uniformly failed. In many instances the contamination is only with non-pathogenic organisms, and the constant ingrowth of the granulations will succeed in expelling the intruders even from a foul, stinking sponge, but in my own hands the contamination has so often been with septic organisms, as evinced by the occurrence of fever, that I must regard it as in some degree an unsafe, as well as a very uncertain, procedure. The more extended the grafts, the more care is required in their management, especially as the danger from sepsis is in some degree in proportion to the surface from which absorption may take place.

In one case—a woman of about fifty—a sponge-graft was applied for the purpose of filling in the upper jaw a gap about as large as the last joint of the finger, the opening having been caused by exfoliation of bone. For the first two days it seemed to do well, and the granulations were rapidly filling the sponge. On the third day the patient had some fever, and on the fourth day it was found necessary to her safety to remove the sponge and adjacent tissues with the knife. Septicæmia was very pronounced, but after the removal of the cause the effect readily passed away, and no great harm was done farther than a slight increase of the gap which it was intended to fill.

The application of the sponge-graft for the rebuilding of the peridental membrane and gum about one or two teeth cannot be regarded as especially dangerous to the patient, but the occurrence of fever in several cases under my observation shows plainly that it is not entirely devoid of danger, and that the extended application of these grafts in the mouth would not be justifiable even if the results were more uniformly successful than they have proved in my hands.

Before closing this paper I wish to say a word in regard to the habit of the profession in the management of this group of diseases. It seems as yet to be the universal custom to consider them as constituting one disease, and therefore there has been no division of treatment. The treatment which has been most strongly urged is in its surgical aspects similar to that which I have here recommended for the phagedenic variety, and it has been applied to all of the forms, the calcic as well as the phagedenic. This treatment, especially in the calcic forms of the disease, is entirely unnecessary, and even hurtful; for if the peridental membrane and the alveolar wall are largely cut away, the injury

is unnecessarily increased. Clinical experience demonstrates that in the calcic variety of the disease the tendency is toward a return to health, and that the mutilation of the parts is not only unnecessary to that end, but results in a much greater shrinkage of the gum-tissue and increased exposure of the root of the tooth, the great evil which we should labor to avoid; therefore I urge a close discrimination between these two forms of disease.

Amputation of the Roots of Teeth.

In practice a considerable number of cases occur in which a valuable tooth can be retained by the amputation and removal of one of its roots. These are cases in which one root of a molar has lost its socket from any cause, such as alveolar abscess neglected until the membrane is destroyed and the gum shrunken away, or from localized calcic inflammation, but perhaps oftenest from phagedenic pericementitis. In any of these cases, if the tooth be a first molar, or a second molar with the roots well separated and the other roots in a fairly good condition or capable of being rendered so by appropriate treatment, the root which has lost its socket may be cut away and the tooth will be fairly well supported on the root or roots that remain. The greater number of my amputations have been of the palatine root of the upper first molar, although I have frequently removed one or the other of the roots of the first molar of the lower jaw. The amputation of the palatine root of the first molar of the upper jaw is the easiest of performance, and leaves the tooth on its remaining roots in a better condition than any other tooth after a similar operation. The amputation is usually easily performed with the fissure-burr driven by the engine, or a common drill may be used to drill a row of holes through the root very close together, after which they may be connected by cutting out the interspaces with the fissure-burr. It is a work of but a few moments by either plan. The root should be cut as close to its bifurcation as possible; and if, after its removal, it is found not to be cut low enough, the remaining part should be burred away, so that no point shall be left. Finally, the whole surface should be made thoroughly smooth. Figs. 529 and 530 will give a good idea of this. The operation involves, of course, the filling of the pulp-canals of the healthy roots, as is usual in pulp-cases, and it is usually best to fill the root to be amputated solidly with gold before the operation of removal, as it is then more easily done. If from any cause this is inconvenient, with a fissure-burr a fissure may be cut which will include the pulp-canal as it emerges from the pulp-chamber,

Fig. 529.

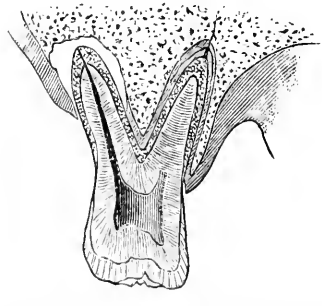

Chronic Case of Phagedenic Pericementitis in which the whole of the Palatine Root of an Upper Molar is denuded of its Membrane. (Compare with Fig. 530.)

and which may be filled at any convenient time after the removal of the root.

The amputation of one of the roots of the first molar of the lower jaw is perhaps called for oftenest from neglected alveolar abscess of the posterior root—at least, this has been the case in my practice. The operation is performed by the same means as that described for the removal of the palatine root of the upper molar. The operation, however, is rather more difficult, for the reason that it is not so easy of approach in the process of cutting, nor is the root so readily removed after it has been severed from the crown. Generally, the root should be cut as close to the bifurcation of the roots as possible and sloped down toward the proximal surface in such a manner that when the gum is well and shrunken as wide a space as practicable shall be left between the cut surface and the gum, so that it may the more easily be kept clean. (See Fig. 531.)

FIG. 530.

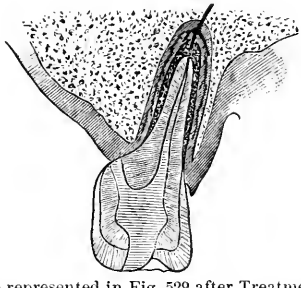

Case represented in Fig. 529 after Treatment by Amputation of the affected Root and filling of the Pulp-cavity and Canals. (Compare with Fig. 529.)

FIG. 531.

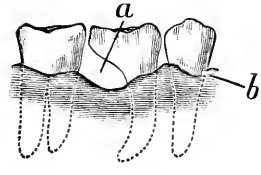

Amputation of the Posterior Root of the first Lower Molar (the roots of the teeth are shown by dotted lines): *a*, root removed; *b*, line of gum after shrinkage has occurred.

Usually this is most readily accomplished by passing a long fissure-burr through between the roots and cutting backward, or, if it is the anterior root that is being severed, forward. In most cases the lips can be held sufficiently out of the way to permit of this without difficulty. In some cases the incision will open into the pulp-chamber; but if this has been solidly filled before the operation, it will occasion no difficulty.

The removal of the root after it is severed from the crown is occasionally a little perplexing, yet in most cases in which this operation is advisable the alveolus of the root is so much destroyed that it comes away easily and may be pushed through to the lingual side with any appropriate instrument. Occasionally it will be found necessary to burr away some of the buccal side of the root to allow it to clear the crown as it is turned toward the inside of the mouth. These two positions are those in which the amputation of an entire root will oftenest be found available, but occasionally other teeth will be found on which the operation may be performed with advantage. These operations have uniformly been very satisfactory. A tooth that has long been a source of continuous annoyance is rendered comfortable and serviceable.

The amputation of the apex of the root of any of the teeth is occasionally required in case of long-neglected abscess. This is generally

made necessary by the collection of serumal calculus on the apex of the root or by the cementum of the apex becoming so infiltrated with the products of putrefactive processes that it becomes an irritant. In the first case it is generally best to remove the serumal calculus if this can be done without too much mutilation of the parts, but I have sometimes felt that to cut off the end of the root was the least objectionable of the two. In the second case the amputation of the apex of the root seems to be the only remedy. The operation is usually easy of performance with the fissure-burr. In any case in which this is justifiable there is usually no difficulty in reaching the root, for the bone covering it is generally destroyed by disease, so that only the soft tissues are in the way; but any margins of bone may readily be removed with the burr or chisel.

This operation has been recommended by various persons within the last two decades, but in my hands the percentage of cures of old chronic abscesses by this means has not been sufficiently great for me to recommend it with much confidence or to affirm that it will be found serviceable in any considerable number of cases; it should be used as a last resort only. The operation is usually not very painful and can be done in a few moments, and is worthy of a trial before giving up an otherwise valuable tooth.

ABRASION AND EROSION OF THE TEETH.

By G. V. BLACK, M. D., D. D. S.

Abrasion.

Abrasion of the teeth is a gradual loss of their substance from mechanical causes. It is seen almost entirely on the grinding surfaces of the molars and bicuspids, the cusps of the cuspids, and the cutting edges of the incisors. From the time that the teeth come through the gums they are subjected to wear through the exercise of their peculiar function in masticating food. Unlike other organs of the body, they are incapable of repairing losses which they may sustain by attrition, and portions of their substance removed in this way are permanently lost. If the epithelium of the sole of the foot is worn thin by attrition in walking over a sandy way, it is soon replaced by a growth of young cells from beneath and restored to its usual thickness. Except the teeth, this is true of any other portion of the body subject to attrition. Even the harder structures, such as the nails, are subject to a continuous growth through which the losses by wear are replaced. This growth always takes place at what may be termed the root of the organ —not upon the surface worn away—and the nail as a whole is pushed forward to supply the portions lost by the processes of attrition. In the case of certain animals—notably the rodents—we find the teeth constructed on this plan; that is to say, they are *continuously-growing organs* in which the loss sustained by attrition upon the *working end* is continually counterbalanced by normal additions at the *growing end*, and in this way the whole tooth is continuously moved forward to compensate for the loss.

This plan of compensating for loss by attrition is not present in the Herbivora, Carnivora, or Omnivora. In these the teeth have a definite period of formation and growth; and when this is completed, the size and form of the tooth are no longer subject to change through vital processes. Any loss by the process of attrition is, therefore, permanent.

A certain amount of wear is normal, and present in each individual as age increases. When the incisors first present themselves through the gums, they are distinctly tuberculated on their cutting edges. These tubercles usually disappear by the processes of abrasion at periods varying from the twelfth to the eighteenth year, and the cutting edge of the tooth assumes a straight or slightly-curved line, which it afterward maintains. At the same time facets produced by wear appear on the *sides of the cusps* of the molars and bicuspids. These facets are determined by the peculiarities of the antagonism of the particular denture

examined, and are, therefore, inconstant as to position. They always occur at such points as come in contact when the jaws are closed normally. In cases of fracture and disturbance of the relative positions of the two jaws the line of normal closure may as early as the fourteenth year be found in reasonably good casts of the teeth by noting these facets and bringing them together. In several instances at an earlier age I have succeeded in doing this by making use of the facets on the milk-teeth. In some cases the occlusion of the teeth is very imperfect, so that but few teeth touch when the jaws are closed, and in this case there will be correspondingly few facets.

The rapidity of wear seems to depend more on the manner of the antagonism than upon any other circumstance. Other conditions may modify it, such as the hardness of the teeth, which may hinder, or their softness, which may hasten, the process. The habitual use of rough, coarse food requiring much trituration will naturally produce more wear than the habitual use of very soft foods, etc. These are only modifying conditions, and not principal elements, in the predisposition to great waste by wear. I am persuaded that the chief causative agency consists in the rubbing of the teeth one upon another, as is plainly shown in the disposition to the formation of facets on the teeth of young persons. This wear is normal so long as these facets remain distinct and clear; when these are lost, it becomes abnormal.

Two elements seem to enter into abnormal wear, or abrasion. The principal of these is a fault in the antagonism of the teeth which permits sliding movements when the jaws are closed. In the perfectly normal antagonism of the human teeth sliding movements of the teeth of the one jaw upon those of the other without parting them slightly are impossible, for the reason that the cusps of the upper teeth fit into the sulci of the lower, and *vice versâ*, in such a way as to prevent it. In the normal use of the teeth this adaptation is made more perfect by the formation of the facets above alluded to, which are in this case always on the slopes of the cusps; for by this process the points which tend to hold the teeth asunder are worn down, allowing the cusps to become more firmly seated in the sulci opposite. In this way an antagonism naturally good becomes perfected. If, on the other hand, the antagonism is from the beginning very imperfect, so that the cusps of the teeth of the opposing jaws rest the one upon the other, the case is altogether different. This involves the formation of facets on the points of the cusps instead of on their sides, and in this way the cusps are shortened and a flat surface is established. If at first there are but few points preventing a sliding motion of the jaws, such points are usually early worn down by lateral or backward-and-forward motions, and all hindrance to these, and even to rotary motions, is removed. These movements are then liable to become habitual with the person and the teeth are worn flat, and in this condition ground down with abnormal rapidity. This is especially liable to occur if at the same time the incisors are in such a position that their cutting edges come the one upon the other. In this case all restraint upon lateral, and even rotary, movement is speedily removed; and such movements are often adopted by the individual, with the effect of rapidly wearing away the teeth.

In a considerable number of cases I have noted an habitual disposition to rub the teeth together—to gritting, as it is called, of the teeth—and this seemed to be connected with abnormal abrasion. It will readily be seen that a habit of this kind, once formed, may be maintained for years, and by the abnormal wear which it occasions may tend to remove the cusps of the teeth quite rapidly, and as these are removed the lateral and back-and-forward movements take a wider range, until the cusps disappear. Then the abrasion will proceed as if the antagonism had been faulty from the beginning. In this class of cases it is not unusual to see the upper incisors worn from their palatine surfaces until they become very thin, and finally only the enamel of the labial surface is left, this breaking away, leaving a jagged edge. As the jagged portions are gradually removed a wider range is given to the forward motions of the lower jaw, and the wear proceeds more rapidly than before. It thus appears that as the abrasion progresses it becomes more rapid, and it is not infrequent to find the teeth worn down to the gum within a very few years after they become distinctly flat, so as to permit of rotary movement upon a given plane.

In these cases, if a few teeth have been lost in one jaw, the teeth in the opposite jaw, having no antagonists, are not worn down; and if the loss has occurred early, they will be found to have retained their cusps, serving to show the original form of the denture. In addition to this, they will have risen in their sockets also; so that their crowns will project much beyond the plane of the other teeth. Occasionally irregularities formed in this way become very prominent.

When flat surfaces have been formed and wear has proceeded so far as to expose the dentine, this, being softer than the enamel, is hollowed out in the form of a cup by the trituration of food. These cup-shaped cavities are often of considerable depth, especially in case the enamel is very thick and strong. They are apt to be deepest when the teeth are about one-third or one-half worn, for the reason that on this part of the crown the enamel is thicker than it is farther toward the neck of the tooth. Where this cupping out is considerable, the enamel is liable to be broken away as the wear approaches those portions about the neck of the tooth, where it is thinner. In these cases it is very liable at such points to split away from the dentine up to its junction with the cementum. Then the dentine wears in such a way that food slides away from between the teeth during the process of trituration, a deep groove being abraded; or if the loss of enamel has extended over the greater part of one side, while it remains intact on the other, the tooth may be worn to a wedge-shape. By such mechanism as this teeth occasionally become very much worn and misshapen.

It is therefore characteristic of simple abrasion of the teeth that a flat surface is formed as the leading abnormality. This results from the rubbing away of the cusps by lateral and back-and-forward movements of the jaws, either from a habit acquired or from an original imperfection in the antagonism. As yet no way of checking this, when it has once made sufficient progress to be noticeable, has been put into practice. It seems probable that the judicious building of cusps at suitable points, so that they would interlock in such a way as to prevent the

sliding movements, would in a large measure prevent the disastrous results. While, in some cases that have been presented, I have thought of doing this, I have not had quite sufficient confidence to subject my patient to the amount of disagreeable manipulation required. Still, if it were proven to be effectual, it would be well worth doing. One great difficulty in the way of such an operation is the uncertainty of diagnosis.

Another procedure that might be utilized in many cases is the early correction of slight irregularities in such a way as to seat the cusps in the sulci of opposing teeth. This has the same objection as that mentioned above. Yet my own observations in the correction of irregularities show conclusively that if the diagnosis were made sufficiently early and the corrections effected it would save the teeth from untimely destruction. As I write I have before me the cast from the mouth of a boy thirteen years old, the cast being made for the purpose of correcting an apparently slight irregularity of the anterior teeth, in which the cusps of the first molars are so much flattened by the antagonism being on their points as to render them practically useless for the prevention of sliding movements. This early wear will illustrate the extreme difficulties of this subject.

It does not seem to have entered the minds of writers in the past that abrasion abnormal in degree is a thing calling for early diagnosis and operative procedures for the prevention of its ultimate results; therefore a sufficient mass of well-digested facts bearing on the subject have not been collected to enable even the well-informed operator to confidently recommend a tedious operation, of the utility of which his patient can have no conception, and concerning which the operator himself is in doubt. Yet if the cause of this abnormal wear is such as I have represented it to be, it is capable of correction by the early adjustment of irregularities, or by the timely and judicious building of cusps with gold or gold and platinum foil that will prevent free sliding movements and save the denture from untimely abrasion. Of course all dentists are acquainted with the capping, or building down, of abraded teeth, but I now allude to operations that will prevent abrasion in its inception and preserve the form of the teeth.

Abrasion also occurs in portions of the denture after the loss of a considerable number of the teeth, owing to the fact that all the force of the muscles closing the jaws and all the work of mastication have been thrown on a few teeth. In these instances, if much sliding motion is allowed, abrasion will be very rapid. This I have been in the habit of correcting, and the results have been such as to give me assurance that by the aid of the judicious registering and discussion of observations we should, in full dentures, be able to make timely diagnosis of danger in this direction and apply the remedy in time to prevent abnormal abrasion.

In abrasion of the teeth there are no changes in the adjacent dentine except it be a slight yellowing of the superficial portions of the exposed surface. Formerly it was supposed that consolidation of the dentinal fibrils occurred as an effort of vitality to erect a barrier to farther progress (J. Tomes). This view is no longer tenable. In those cases in

which the progress of wear has been exceedingly slow, as well as in the more rapid ones, the dentinal tubules are found to be open at the abraded surface. There is also a popular notion that the surface of the abraded dentine is harder than normal. This is an error. The assumption that the dentinal fibrils undergo calcification probably has had something to do with this opinion, but the principal circumstance leading to it is doubtless the difficulty experienced in penetrating abraded surfaces with instruments. This difficulty exists, and has been noted by many; but it is, however, not on account of a greater density of the dentine, but is the superior resistance of a polished surface over one that is not polished. Precisely the same differences are noted in the penetration of polished and unpolished surfaces of marble, or any other kind of stone.

Abraded dentine is often exquisitely sensitive, and certain changes are found to take place in the dental pulp as a consequence. These will be discussed after the consideration of erosion.

Erosion.

Erosion of the teeth is an affection characterized by a loss of substance of the organ occurring without apparent cause. It always has its beginning on the surface of the tooth over a limited space, and very gradually a pit or groove is formed which steadily widens and deepens, until in many cases a large part of the tooth is destroyed. This happens most frequently on the labial surface of the crown, and is often confined to the anterior teeth. It has been noted by a number who have written on kindred subjects, and much variety of opinion has been expressed in regard to it. In addition to the term erosion, it has been termed chemical abrasion, decay by denudation, etc., while others, as Salter, have regarded it as being essentially a result of friction applied by the tooth-brush or in some manner not very easy to comprehend.

As most usually seen on its first appearance, erosion consists of a slight cup- or dish-shaped excavation in the enamel of some one of the anterior teeth, generally situated from a half line to a line below the free margin of the gum. It is, however, not confined to this position, and may occur at any point on the crowns of any of the teeth; but perhaps four-fifths of the cases that have come under my observation have begun as far forward as the first bicuspid, and one-half or more have been on the labial surfaces of the incisors. Next to the incisors, the cuspids are much the more frequent points of attack. This applies to both the upper and the lower jaw. When this little excavation is discovered on one tooth, if it be closely watched it will be seen in the course of a few months—possibly a few weeks—that it is gradually broadening and deepening, and as this process goes on it will be noticed that little cups are appearing in a similar position in the teeth next adjacent. The erosion is rarely solitary, though such cases are known to occur. It very generally extends from tooth to tooth at either side of the one first attacked, but in nearly every case there is a preference that is quite noticeable for one or the other side. Although I have seen a number of cases that seemed to have begun on the central incisors and

in which the invasion of these continued to be about equal, I have never yet seen a case that maintained a symmetrical progress in respect to the the other teeth. The illustrations on another page will give a good idea of this. In many cases there is a marked tendency to the formation of a sharp angle with the surface of the enamel on the lower (toward the crown) margin of the erosion. This is particularly noticeable in Fig. 532. Occasionally this is seen to be next the gum (Fig. 534), but much more rarely, and in some instances both the upper and the lower margins are very square incuts. A few days ago I was consulted in regard to a case in which both of the superior central incisors were cut as if done with a No. 4 separating file, the cut extending considerably into the dentine. This case is remarkable as being the deepest cut, in proportion to its width, that I have ever seen. Generally the incuts are of considerable width; and if one margin is squarely cut in, or nearly so, the other slopes much more gradually to the surface, as will be seen in all the illustrations presented. More rarely cases may be seen in which the excavations are nearly circular, with the sides equally sloping. It will thus be observed that there is nothing definite as relates to form. I have seen a few cases in which there was a groove excavated lengthwise of the crown of the tooth, but these are very rare. Dr. Cushing of Chicago has related to me a curious case that came under his care, in which a groove was excavated in the labial surface of an incisor close to the proximal border, extending from near the gum to the cutting edge, from which point it passed backward across the cutting edge and then down, in the form of a groove in the palatine surface, nearly to the gum. Such a form as this is certainly remarkable. Another variety, of which two cases have come under my observation, is the wasting of the proximal surfaces of the teeth. In each of these round holes were formed, passing through between the teeth (each tooth being about equally eroded), as if filed out with a rat-tail file, the surfaces remaining hard and finely polished. When one of these first came under my observation, the crowns of the central incisors were almost severed from their roots, and similar openings were in process of formation between the other teeth on one side as far back as the space between the first and second bicuspids, while on the other it extended to the lateral incisor and cuspid only. This effect was confined to the upper jaw. In the other case the teeth of both jaws were similarly affected.

In all these cases the erosion makes the greatest progress in the teeth first attacked, and, in whatever stage of progress the case is seen, the extent of the loss of substance gradually diminishes as it recedes from this point in either direction. The difference in the extent of the loss of substance generally has a close relation to the time of beginning. Exceptions to this rule now and then occur, but it holds good in so large a majority of cases that after seeing the position and form of the erosion in two or three teeth we may prognosticate pretty certainly the form it will take in the adjacent teeth if the case progresses without interruption. This progress is well marked in illustrations 532 and 533. So far as my observation extends, the form and direction of the erosion are not materially changed—but rarely, at any rate—after it has once

begun. If the teeth are regular in the arch, the second tooth attacked will be eroded in almost precisely the same form as the first, and so on with third and fourth. But it is rare to see two teeth which are alike in the extent of erosion at the same date, except it be the central incisors. Those on which the process begins later will pass through the same forms and stages which the first has gone through before them.

Fig. 532 represents a cast made from an impression of a case in the practice of Dr. E. D. Swain of Chicago; its principal peculiarity is the

FIG. 532.

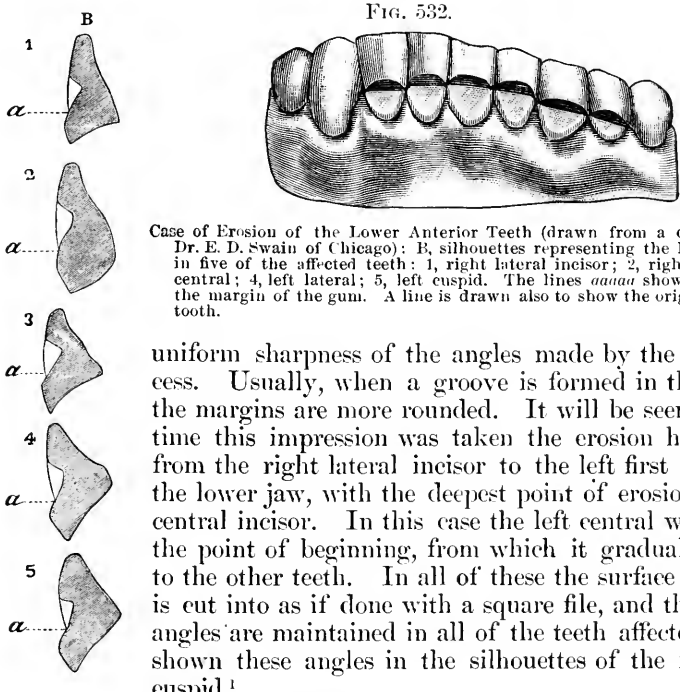

Case of Erosion of the Lower Anterior Teeth (drawn from a cast prepared by Dr. E. D. Swain of Chicago): B, silhouettes representing the loss of substance in five of the affected teeth: 1, right lateral incisor; 2, right central; 3, left central; 4, left lateral; 5, left cuspid. The lines *aaaaa* show the position of the margin of the gum. A line is drawn also to show the original form of the tooth.

uniform sharpness of the angles made by the erosive process. Usually, when a groove is formed in this position, the margins are more rounded. It will be seen that at the time this impression was taken the erosion had extended from the right lateral incisor to the left first bicuspid of the lower jaw, with the deepest point of erosion in the left central incisor. In this case the left central was doubtless the point of beginning, from which it gradually extended to the other teeth. In all of these the surface of the teeth is cut into as if done with a square file, and the particular angles are maintained in all of the teeth affected. I have shown these angles in the silhouettes of the incisors and cuspid.[1]

The surface of the exposed dentine was firm and hard and had a perfect polish everywhere, and there was no jutting of the enamel above the eroded dentine at any point. These tissues, differing so much in

[1] These silhouettes were made as follows: An impression was taken from the cast in modelling compound, care being taken to get it as sharp as possible. When this was thoroughly cold, it was oiled lightly and a cast made, also of modelling compound, by pressing the softened material quickly and firmly into the impression. When cold, they parted very readily. The cast was then cut away from before backward, perpendicularly, from its right-hand end until the right lateral incisor was reached. Then the cut surface was dressed down carefully on a piece of emery-paper laid flat until the centre of the tooth was reached, producing a perpendicular section from before backward of this tooth. The surface was then smoothly finished on fine emery-paper, and the back part of the cast was cut away to something near the shape of the tooth. (This cast was only of the labial surfaces; therefore the lingual surfaces as shown are only an approximation to correctness.) This was then inked on an ordinary rubber-stamp inking-pad and the silhouette of this tooth printed. The cast was then trimmed to the centre of the next tooth and its silhouette printed in the same way, and so on from tooth to tooth. These accurately represent the angles.

density, were finished as evenly and smoothly, the one with the other, as if done on the lapidary's wheel.

Fig. 533 was made from the cast of a case in my own practice, and represents the teeth as I first saw them. The patient was sufficiently intelligent to give what seemed to be a very reliable account of its prog-

FIG. 533.

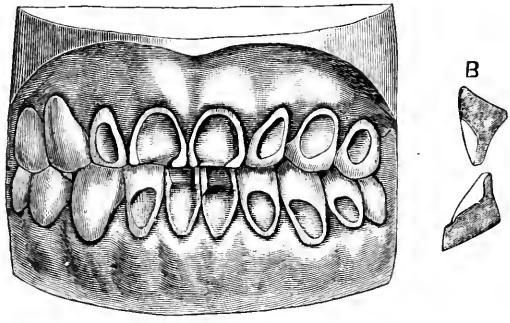

A Case of Erosion (drawn from the cast); B, silhouette from a perpendicular line through the left centrals, upper and lower, showing the loss of substance.

ress. A little more than three years before, she had noticed slight cups, which caused her some solicitude, appearing on the labial surfaces of the upper central incisors, near the gums. These were observed to widen very slowly, but seemingly very steadily, toward the cutting edge and laterally. About six months later the same condition was seen on the lower centrals, and the lesion seemed to progress more rapidly than the erosion of the upper teeth; so that at the end of the first year the loss of substance appeared to be about equal in depth. At about this time the erosive process was seen to be making its appearance on other teeth. Her dentist was then consulted, and she was told that the trouble resulted from the use of a stiff toothbrush which she employed. Very much against her will, she abandoned the brush for a year. During this time the erosion made more rapid progress than before, and the sensitiveness of the eroded surfaces, already quite considerable, increased greatly; so that, in addition to the marred appearance of the teeth, the hyperæsthesia became a source of great annoyance, occasional exacerbations occurring, during which exquisite suffering resulted whenever the eroded surfaces were touched. Finding that the abandonment of the use of the brush did not retard the erosion, she again resumed it; but, on account of the great sensitiveness of the eroded surfaces, she was ever after compelled to avoid them in cleaning her teeth. The erosion continued steadily, and at the end of the third year was as represented in the illustration. At this time intense hyperæsthesia of the pulps had occurred in the central incisors above and below. The sensitiveness was so extreme that the patient could not be induced to submit to any manipulation whatever. I therefore gave an anæsthetic and removed the pulps of the four centrals, which had the effect of rendering the patient fairly comfortable. Before cutting into the teeth the outline of the former pulp-chamber was distinctly seen in what seemed to be the

exposure of a secondary deposit, and in the removal of the pulps it was found that the chambers were abnormally small, on account of secondary deposits. After proper treatment of the root-canals the contour of the four incisors was restored with gold and platinum foil, and has stood perfectly to this date (two years). In the mean time, the erosion of the other teeth has been progressing, but much more slowly than formerly, and the sensitiveness has abated to such a degree that they are fairly comfortable. The indications now are that the process has come to a spontaneous standstill. I have in several instances observed this spontaneous cessation of erosion after it had made considerable progress, and in this case I do not think that the treatment of the central incisors had any influence in bringing about this result. The cessation did not occur at once, for very decided advance was made during the six months following the operation.

Fig. 534 was made from a cast of a case occurring under the observation of Dr. George H. Cushing of Chicago, and is here introduced because of its marked peculiarities. The case had not progressed very far when this cast was made, but I learn from Dr. Cushing that it is steadily advancing without any disposition to change in the form of the eroded surfaces. In this case the incut is sharply down from the surface of the enamel—slightly undercut, indeed—in a circular line following the free margin of the gum and about half a line from it, until the proximal borders of the tooth are reached, and then these borders are followed toward the cutting edge. The superficial portions of the tooth are smoothly removed in the included area, being deepest in that portion nearest the gum, and thinning out toward the cutting edge in such a way as to leave a perfectly flat surface. The surface thus eroded is perfectly hard and smooth in all its parts. This is the left lateral and central. In the tooth next adjacent on either side the erosion has begun in the same way, only that it has not extended over the crown of those teeth lying next those first attacked at the time the cast was taken. It will be observed that the right central is a little rotated in its socket—a circumstance that will have the effect of modifying the form of the erosion occurring in it. I have noted this in enough cases to be sure that it is the position of the tooth that produces the modification—a fact that is of importance in considering the etiology of the affection.

Fig. 534.

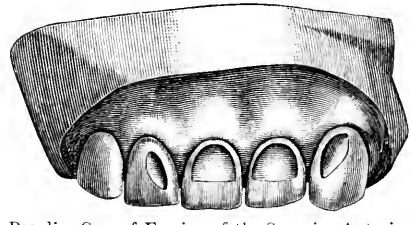

Peculiar Case of Erosion of the Superior Anterior Teeth (drawn from a cast prepared by Dr. Geo. H. Cushing of Chicago).

The forms shown in these illustrations serve to give an idea of the variations that occur in this process. Each case examined presents characteristics peculiar to it, and to no other. There are however, notwithstanding their sharp differences, certain similarities of form running through all the cases, which, after one has become accustomed to observing this affection, at the first glance mark them as cases of erosion. There are some cases in which the effect is seen over a large part

of the labial surfaces of the teeth without any sharp incuts at any point; others in which a simple groove well rounded at its bottom occurs across the crown of the teeth, near the gum, and at the margins of the enamel. I think it a fact that those cases which are thus indefinite as to their boundaries are not as rapidly destructive as those that show sharp outlines.

Erosion sometimes exists in association with mechanical abrasion. Where this occurs I think it is simply *intercurrent*, and not because the two processes have anything in common in their etiology. The only cases that I have seen in practice or in the literature of the subject seeming to offer a suggestion of interdependence of the one upon the other are those which affect the cutting ends of the incisors in some rare cases of mechanical abrasion. In a few cases that came under my observation several years ago all the crowns of the teeth, except the usual cupping out of the dentine, were worn flat and smooth, and the antagonism was perfect in the bicuspids and molars; but the incisors failed, in the worst case, to come together, by about three-sixteenths of an inch. It does not seem to me possible that this shortening of the incisors could have been the effect of simple abrasion. They cannot possibly be brought in contact, and they have become almost useless in the prehension of food; so that, as a matter of fact, they are scarcely used at all. Yet they continue to lose substance much faster than those teeth that bear the burden of mastication and the friction of the one upon the other. I have sought to find some explanation of this in the structure of the dentine, but without result; the structure of the teeth that were rapidly losing substance seemed as good as that of the others.[1] The effect is certainly that of erosion, and is identical with that process as seen on the labial surfaces of the teeth and occurring independently of mechanical abrasion. This has been noted by most writers since the time of Hunter.

Etiology.

The etiology of *mechanical abrasion* has been sufficiently explained in connection with its description.

The etiology of *erosion* is probably one of the most obscure subjects in pathology; with our present knowledge, it is practically unexplainable. This being the case, it seems incumbent upon every writer who treats of the subject to give any facts in his possession that may seem to have significance, in the hope that from the accumulation of data something tangible may be derived in the future. In the past various suggestions have been made, most of which seem untenable. The chemical theory, notwithstanding the many valid objections to it, is perhaps the one more generally held. Some, with J. Tomes and

[1] One of these cases was treated by restoring in gold the contour of the lost tissue, so as to perfect the antagonism. For this purpose pits were drilled, into which screws were driven, and, without otherwise cutting the surface, the gold built about these for retention. The surface was simply carefully washed with sulphuric ether, to cleanse it of any possible adherent animal matter. I had opportunity occasionally to see the case up to the time of the patient's death, ten years after the operation; the treatment was successful in every respect. This seems to argue that the cause was not in the tooth itself.

Salter, seem to regard it as the effect of the vigorous use of the tooth-brush, or some other form of friction—indeed, as a species of abrasion. It is, however, difficult to believe that simple friction of any kind can produce the effect seen in the cases I have illustrated, and many other forms occur equally difficult of explanation by that hypothesis. A causative agency has been sought for in the structure of the teeth themselves, but microscopical examination of the tissue undergoing erosion gives no results except to demonstrate that the fault does not lie in this direction, such teeth being generally found perfect in their organization and development. Again, faulty development has certain characteristics that are well known. If many teeth are faulty in a part of their structure, the faults are present in those parts of each of the teeth in process of development at the same time; therefore, if what I have called erosion were the washing out or brushing away of such portions of the tooth as were soft from faulty development, the erosion should follow the developmental lines, which it does not do in any case that I have seen.

The erodent, whatever it may be, acts from without. Neither the dentine nor the enamel immediately adjacent to the portions being removed, even up to the immediate surface, shows any changes whatever except it be a slight discoloration which is present in only a portion of the cases. There is, indeed, in most of the cases a very marked sensitiveness of the surface eroded, and finally of the pulp itself—which condition I shall discuss presently—but this does not seem to influence the hard tissues in any degree. Sensitive dentine is just as hard as dentine that is not sensitive.

As already stated, the more generally accepted theory is that erosion is in some way effected by acids, and, all things considered, this supposition is perhaps more tenable than any other that has been advanced; still, there are great difficulties in the way of its adoption. It is generally admitted that if it be an acid that acts as the agent the action must be different from anything now known to us. On this point I can throw some light, though I will fall far short of clearing up the mystery. Teeth may, by the action of acids, be eroded artificially so nearly like some of the forms seen in the human mouth that the difference cannot well be demonstrated. It is difficult to conceive, however, that the same conditions should occur in the mouth. But the experiment shows that it is not impossible that erosion may be the action of acids.

In 1870, while studying experimentally the condensation of gases on the metals (surface attraction) and the corrosion of metals with weak solutions of acids in the still condition as compared with the effects when the solutions were kept in motion, it occurred to me to try the effects on the teeth. From the results of my experiments on metals I supposed that the parts of a tooth exposed to a brisk current would not be softened in a given solution so rapidly as in the still condition. The apparatus I was using at the time was a train of wheels like those of a common clock, only heavier, run by a weight and made to revolve a glass paddle in a glass jar. This apparatus when in motion caused the liquid to spin around in the vessel continuously. It was capable of

regulation, so that it would give a current of any number of feet per minute up to one hundred or more. The jar was filled with a solution of hydrochloric acid of the strength of 1 part of acid to 400 parts of water, and the apparatus was arranged to run at about forty revolutions per minute.

Two bicuspids fresh from the mouth and perfect, with fairly long cusps (removed to obtain room for the correction of irregularity), were placed with their proximal surfaces together, to represent a natural position, and their roots were enveloped in gutta-percha, to represent the gum and alveolus, leaving the crowns exposed. These were fixed in the current in such a way that it would strike against their buccal surfaces not quite squarely, but at an angle that would cause the current that passed between the teeth to be deflected slightly from its course. The effect on these teeth was quite remarkable and entirely at variance with anything that I had expected. Metals corrode much less in a current than in the still condition in a given solution of acid, and the difference is quite marked on any surfaces that are well sheltered from the current, and I naturally expected that something similar would occur in case of the teeth. The result, however, was the removal of the cusps and the formation of a round opening between the two teeth. The effect on the cusps was noted on the second day, and the opening between the teeth on the third. On the fifth day the condition of the teeth was such as shown in the illustration (Fig. 535), in which *a* shows the condition of the tooth at the beginning as well as I could do it after witnessing the results, and *b* represents the condition on the fifth day of the experiment.[1]

Fig. 535.

Artificial Erosion. The original form of the tooth is represented at *a*. At *b* the same tooth is represented after having been subjected to a current of a solution of hydrochloric acid for five days. Strength of solution, 1 to 400.

The effect of the acid was to cut away the teeth at the points where the current broke around the sharper angles, especially over the points of the cusps. At the point where the solution ran between the teeth, that tooth against which the current bore while being deflected from its course was cut in the form of a deep groove, which corresponded in width with the space between the contact of the two teeth and the gutta-percha that represented the gum. The other tooth was grooved also, but not so deeply. At these points the eroded surface was left fairly hard and smooth, as in erosion as it occurs naturally in the mouth. The groove between the teeth reminded me strongly of a case I had seen some time before, in which round openings were cut between several teeth, while the effect on the grinding surface was more like abrasion.

These experiments were repeated a number of times with results that were somewhat variable. Three months' trial with a solution of 1 of acid to 1500 of water gave no appreciable result. Very strong solutions produced general softening.

These experiments show that an acid may possess an action under a

[1] These figures are made from the drawings that accompany my notes of the experiments made at the time. I have represented only the tooth most eroded.

change of circumstances very different from that seen when the action takes place in the ordinary still condition, and leads us to suspect that there may be circumstances modifying its erosive power which are not yet known or recognized. When we come to analyze the results of these experiments, this is all that can be said of it, so far as the explanation of erosion is concerned; for if an acid were present in the mouth in the strength of solution that is required to produce this peculiar effect out of the mouth, the teeth would be quickly destroyed. Were this not the case, it is difficult to conceive of a current being maintained in the mouth sufficient to effect the erosions met with in practice. Indeed, some of the forms of erosion are such that a current could not possibly be the cause—such forms, for instance, as are given in Fig. 534, where there is a perpendicular incut in a half circle, or in Fig. 535, where the teeth were eroded in the form of cups, or in many other cases that might be given.

The possibility that erosion might be effected by something like the absorptive processes occurred to me some years ago. Certainly a number of cases that have come under my observation have shown a peculiar congested condition of the lip that came against the portion of the labial surface being eroded, and it seemed probable that an acid secretion abnormal in character was being produced at this immediate point, which, together with the motions occasioned by the lip, might effect the solution of the substance of the tooth. In a few instances I have seen clearly the impression of the eroded surface in the lip, showing that it fitted into it very exactly. At the same time, litmus-paper applied to the lip showed that the secretions at that point were decidedly acid. This seems very near a demonstration of the cause, but I have met with cases in which no such agency could be proven—cases in which there is no tissue in habitual contact with the surface.

Dr. E. D. Swain of Chicago, who has taken much interest in this subject, has made a close study of the theory of electrolysis, especially of the ideas advanced by Mr. Bridgeman, whose experiments he has repeated and varied, using a large number of acids, different strengths of solution, etc., becoming finally convinced, however, that the explanation is not to be found in this direction.[1]

While pursuing these experiments Dr. S. has made some important discoveries in the diffusibility of acids, a table of which I have the privilege of giving. This table represents the percentage of each of the acids named (dissolved in distilled water) that can clearly be detected as giving an acid reaction with litmus-paper:

	Per cent.
Oxalic acid	1-260 of 1
Citric acid	1-160 of 1
Phosphoric acid	1-130 of 1
Acetic acid	1-65 of 1
Butyric acid	1-30 of 1
Tannic acid	1-30 of 1
Tartaric acid	1-260 of 1
Sulphuric acid	1-130 of 1
Nitric acid	1-130 of 1
Hydrochloric acid	1-140 of 1

[1] I am indebted to Dr. Swain for the privilege of the perusal of several unpublished manuscripts on this subject.

Dr. Swain's results agree with my own conviction as to the possible influence of electrolysis in the causation of this affection. Even if it were shown that the teeth could be eroded successfully by this method, the matter of the peculiar localization would present to its adoption as a theory (as it does to every other yet advanced) an obstacle that seems insurmountable.

The theory that it is caused by acid mucus is supported by several who have written on the subject, and our present knowledge affords no alternative but the acceptance of the general idea that it is the action of an acid under some peculiar modifying influences as yet unknown to us. While this is unsatisfactory in the extreme, there seems to be nothing better to offer. The influence of micro-organisms appears to be out of the question. These enemies are accustomed to seek foul places, and eroded surfaces are habitually clean surfaces. If by a change of conditions the surface eroded becomes habitually foul, caries takes the place of erosion. This occurrence is very rare, but is not unknown.

Sensitiveness of the Dentine.

The extreme sensitiveness of the eroded surfaces, not unfrequently occurring, has been alluded to. In a number of cases I have seen this so extreme that only the destruction of the pulp of the tooth afforded relief. Indeed, experience has taught me that this result is sooner or later likely to follow spontaneously, notwithstanding the large amount of secondary dentine usually found over the pulp in this disease. I have seen the death of the pulp occur when there was seemingly an abundance of dentine between it and the eroded surface for its protection. On the other hand, while I have seen the pulp-chamber cut through either after being closed with a secondary deposit or after the death of the pulp, I have never seen a case in which the living pulp became exposed.[1] There seems to be something in the cause of this affection peculiarly irritating to the dentinal fibrils, and the results of that irritation are shown by pathological changes in the pulp of the tooth. This naturally leads to an examination of the anatomical and physiological conditions that produce these peculiar results.

The dentine has no demonstrable nerves, and with our present facilities for microscopic examination it is reasonable to suppose that if they were present we would be able to demonstrate them. It seems to have been the thought of pathologists that in the production of the sensation which we call *pain* some nerve or nerve-ending has received the initial lesion which has produced this effect. It has long been recognized that in the strict adherence to this doctrine we would be unable to account for even the normal sensitiveness of dentine, much less the occurrence of hyperæsthesia. Yet the hyperæsthesia does occur, and in the most excruciating forms, and especially in the disease we are considering. It seems, therefore, fitting that we should study this condition in connection with this disease, especially as there is here absolutely no discover-

[1] Dr. E. D. Swain of Chicago gives a case in which the pulp was fully exposed from erosion.

able pathological change in the dentine itself which presents this hyperæsthesia, except a waste of its surface.

Fig. 536 is a sectional view of a central incisor with an erosion at *a* which exposes the dentinal fibrils. At *b* the layer of odontoblasts are shown—these line the pulp-chamber—and at *c* a nerve-branch the finer filaments of which are found ramifying in close conjunction with the odontoblasts. The processes from these odontoblasts form the dentinal fibrils which pass by way of the dentinal tubules to the periphery of the dentine. The odontoblast and its process, the dentinal fibril, constitute one cell; the protoplasm is united in one life; and whatever markedly affects the protoplasm of the fibril affects the protoplasm of the whole cell. For this reason any pathological changes that may be set in motion in consequence of irritation of the dentinal fibrils are found in the odontoblasts and the tissues in intimate association with them—in that portion of the pulp marked *e* in the figure. Along the course of the fibril itself no pathological changes whatever can be discovered, seemingly for the reason that the hard substance of the dentine—the basis-substance and the lime salts—is incapable of manifesting vital phenomena, is not living protoplasm. This portion of the dentine is essentially fixed material. It may be acted upon, but does not in itself act. It is passive.

FIG. 536.

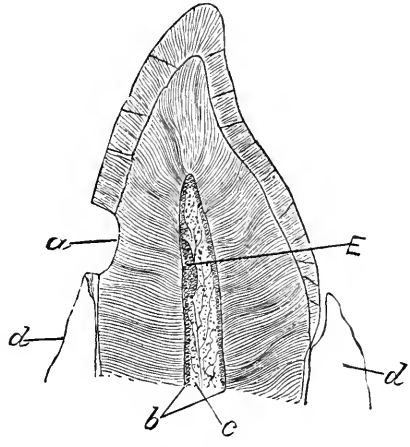

Section of the Crown of an Incisor: *a*, an erosion exposing the dentine; *b*, the layer of odontoblasts lining the pulp-chamber; *c*, a nerve-branch the delicate filaments of which are distributed about the layer of odontoblasts; *d*, *d*, gingival margin; E, point at which pathological changes first occur as the result of irritation of the dentinal fibrils at *a*.

The changes which occur in the tissues of the pulp in consequence of distal irritation of the dentinal fibrils are sufficiently discussed in the paper on Pathology of the Dental Pulp, and will not be repeated here except for the purpose of illustration. The effect of slight but continuous irritation of the ends of the fibrils is seen in the production of secondary deposits of dentine, which in those cases in which the area of irritation is small are not unfrequently confined to the area represented by the pulpal ends of the fibrils irritated. If the area of irritation is large, as in most cases of mechanical abrasion, the area of secondary deposits includes the whole internal surface of the pulp-chamber. If the intensity of the irritation of the fibrils be more considerable, the result will be irritation of the pulp, instead of secondary deposits, or possibly both, the secondary dentine proper giving place to irregular deposits. In case the irritation becomes excessive, well-marked hyperæmia of the pulp will occur, which occasionally results in the destruction of that organ before it is exposed to external influences other than through the medium of the fibrils.

Here we find that the pathological changes pass from the external to the internal structures by way of the protoplasmic lines, the dentinal fibrils. Having injured the process of a cell, the cell itself is injured.

Protoplasm is sensitive; this is exhibited in the amœba, the leucocyte, and the young connective-tissue cells generally. All of these respond to stimulants, both mechanical and chemical, and exhibit their sensitive properties by certain motions, by ceasing from the performance of motions, and by various forms of contraction. They exhibit sensitiveness to thermal changes. Cold tends to slow their motions, and if its degree is increased will stop them entirely. Heat renders their motions more active for a time; but if the increase of the temperature is continued, it causes them to take on a state of tetanic contraction and assume the spherical form. If the heat is discontinued, the movements will be resumed. Among the chemical irritants many affect them in a marked degree. Common salt in very small quantity (a drop of a 1-per-cent. solution added very slowly) first quickens their motions, and then causes sudden tetanic contractions, and in amœba the expulsion of any food they may contain at the moment (Brunton). The acids and alkalies affect them prominently. Hydrochloric acid causes the amœba to contract and form a ball with a sharp double contour. In it occur twitching motions which expel any food it may contain in its substance.

These are a few of the many well-known examples of the effects of reagents upon protoplasm by which its sensitiveness is shown. The leucocyte exhibits the same phenomena, with some variations, as do also the young connective-tissue cells. Leucocytes from different animals show some differences in their response to different stimulants.

These cells contain no nerves, and we cannot say that they exhibit pain; but when protoplasmic bodies—cells—come to be built into tissue and enter into physiological relations with nerves, may not this sensitiveness—which in the simple cell, when standing alone, is exhibited in motion, or tetanic contraction—be communicated to the sensorium and translated into the sensation which we know as pain? There seems to be no reasonable objection to this view, while there are some difficulties that are more readily explained by this than by the hypothesis that in the production of pain the initial lesion must be of some nerve or nerve-ending.

Fig. 537 represents diagramatically a group of odontoblasts with their processes, the dentinal fibrils, with a nerve-branch in close conjunction with the odontoblasts. In case of the irritation of the distal ends of the processes of these cells pain is produced, yet no nerve or nerve-ending is touched, there being no nerves in the dentine. Everywhere in the periphery of the pulp fine nerve-filaments may be demonstrated in close conjunction with the odontoblasts, and it seems evident that they communicate to the sensorium the impression made on the protoplasm of these cells through the injury to the fibrils. In this as in most other cases sensation follows the lines of pathological changes. According to present theories, hyperæmia is induced through the agency of the nervous system by a reflex action, and must be induced by the same manner of reflex action as pain itself.

Pathologists have generally regarded the nerve-endings as receiving the initial impression or injury in the production of pain on touch. It is a subject, however, that has always been very obscure—in fact, undemonstrable. Nerve-tissue is certainly itself sensitive, for pain may be produced by the injury of sensory nerves; but pain so induced is referred to the tissue to which the nerve is distributed, not to the nerve itself. Indeed, so far as consciousness goes, we would never know that we had nerves. In most positions in the body nerve-endings and the cellular elements are in such close relation that it is impossible to injure one

FIG. 537.

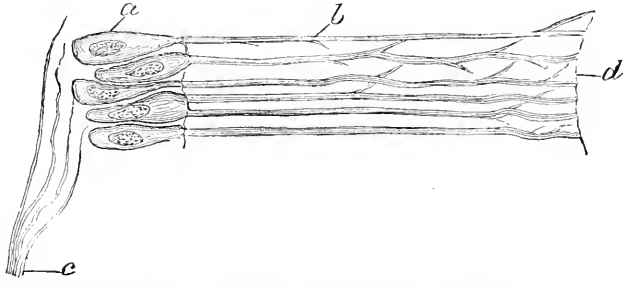

Group of Odontoblasts with their Processes (dentinal fibrils): *a*, odontoblasts; *b*, fibrils; *c*, nerve-supply. Irritation at the point *d* produces pain.

without injuring the other. The experimental isolation of a tissue-injury from injury to the nerves (these being intact) for the purpose of determining which receives the initial lesion causing pain does not seem to have been thought of or to have been possible to other positions than the one under discussion, and the general fact that without nerves there is no pain seems to have led physiologists to adopt the supposition that the nerves or their endings received the initial lesion giving the sensation of pain.

A close study of the literature of the subject of sensory nerve-endings and their relation to the various sensations will serve to demonstrate the obscurity of the subject and show how inaccurate is our knowledge of it. In practice the cases in which pain is developed—that is, demonstrably due to the direct wounding of nerves or nerve-endings—are very few indeed. In this statement I have not reference to pain or perturbations of functions that may result from disease of the nerve-centres; in this case we would deal with the nerve-cells (ganglion-cells) individually, and their processes. These are protoplasmic bodies in which specialized function is developed to such a wonderful degree that their injury produces exceedingly complex results.

The striped or voluntary muscles furnish an example of the propagation of impulse along protoplasmic bodies which is like that I have suggested in case of dentinal fibrils, except that it is an efferent instead of an afferent impulse. There is but one motor nerve-ending in conjunction with a single muscular fibre, no matter what its length (Krause, Koelliker); this is sufficient to communicate the impulse to contraction to the whole fibre, though it may be much longer than the dentinal fibril. Here it will be seen that the passage of an impulse along a

protoplasmic body *from* a nerve-ending seems demonstrated. In the explanation offered of the sensitiveness of dentine the impulse passes along a protoplasmic body *to* a nerve-ending. The conduction in the two instances is the same, but the impulse travels in the opposite direction.

By this consideration of the facts at hand it seems clear that this is the mode of transmission of sensation from the dentine. The dentine has no nerves, and, with the peculiar arrangement of the odontoblasts and their processes, nerves are not needed. The dentinal fibrils being processes of the odontoblasts, and these cells being in physiological relation to the sensory nerve-endings, the conditions for the translation of injury to protoplasm into the sensation of pain are complete.

These considerations also render sufficiently clear the reasons for hyperæsthesia of dentine and injury to the dental pulp by irritation of the dentinal fibrils.

COLLEGE OF

INDEX TO VOLUME I.

A.

Abdominal plates of embryo, 543
Abducent nerve, 282
Abrasion and erosion of teeth, 993
  of teeth, prevention of, 996
  secondary dentine resulting from, 867
Abscess, 701
  alveolar, 929
  blind, 936
  of dental pulp, 855-857
  septic, treatment of, 950
Absorption of bone, 47
  of ligatures, 922
  of roots in phagedenic pericementitis, 973
  of roots of teeth, 921
Absorptive processes in caries, 777
Accessory palatine canals, 91
  parotid gland, 208
Achatina, teeth of, 349
Acid causing caries, analysis of, 798, 799
  mucus in caries, 776
  produced by fungi of human mouth, 824-826
Action of muscles of mastication, 182
Acute apical pericementitis, diagnosis of, 924
    symptoms of, 924
Æluropus, teeth of, 464
African elephant, teeth of, 489
    tusks of, 489
Ailurodon, teeth of, 453
Air-cells, openings of, 137
Alligator, dentition of, 385
Alveolar abscess, 929
    chronic, 935
    constitutional treatment in, 946
    diagnosis of, 943
    discharge of, at gingival margin, 934
      on face, 933
    discharging into antrum, 941
      into nose, 940
      on neck, 943
    evacuation of pus in, 945
    opening pulp-chamber in, 948
    pointing in hard palate, 934
    treatment of, 944
  margin, thickening of, 971
  or superior maxillary artery, 234
  process, necrosis of, 951
    of inferior maxilla, 103
Alveolar process of superior maxilla, 86
      maxillary bone, 86
    removal of, 980
  septum, destruction of, 972
  wall, destruction of, 971
    development of, 107, 632
    eversion of, 971
Alveoli of inferior maxilla, 103
  of superior maxillary bone, 87
Alveolitis, infectious, 968
Alveolo-dental nerve, 290
    anterior superior, 291
    branches of, 291
Amalgam in caries, 811
Amblypoda, teeth of, 492
Amelification, 595
Ameloblasts, 641
  contact of capillaries with, 633
Amphicyon, teeth of, 452
Amœboid cells, 692
Amputation of dental pulp, 905
  of roots of teeth, 990
Amynodon, teeth of, 479
Anæmia, 687
Analysis of acid causing caries, 798, 799
Anatomy, Dental, 351
  Regional, 35
Anchitherium, teeth of, 481
Angular artery, 226
  vein, 249
Annelids, teeth of, 338
Anomodontia, teeth of, 384
Anterior auricular arteries, 229
    vein, 253
  cerebral artery, 242
  condyloid foramina, 53, 124, 128
  communicating artery, 242
  dental foramen, 101, 133
  ethmoid artery, 240
  ethmoidal foramina, 75, 134
  fossa of brain-case, 120
  jugular vein, 255
  lacerated foramen, 66, 122
  median fontanelle, 119
  nasal openings, 132
  occipital or transverse sinus, 261
  palatine canal, 86
    meatus, 86
  superior dental nerve, 291
  temporal artery, 230
Anthracotheridæ, genera of, 485
  molars of, 486

Anthroidial articulation of Gray, 112
Anthropoid apes, teeth of, 436
Antiseptic filling materials, influence of, on fungi of dental caries, 806
power of filling materials, 810
wash in calcic inflammation, 967
Antiseptics in alveolar abscess, 948
in phagedenic pericementitis, 984
power of, 808
uses of, on gangrenous pulps, 907
Antrum of Highmore, 89
Aortic obstruction, pulse in, 671
regurgitation, 671
Apical foramen, 355
pericementitis, 923
cause of, 925
chronic, 925
constitutional treatment of, 928
treatment of, 926
space, 918
painless penetration of, 928
Aponeurosis, occipito-frontalis, 167
supra-hyoid, 188
Aponeurotic fascia, 155
Apophyses of bones, 35
Appendages of skin, 147
Appendix to paper on dental caries (Miller), 791
Aqueduct of Fallopius, 59, 305
Aqueductus cochlea, 60
vestibuli, 59
Archælurus, teeth of, 459
Arctoidea, teeth of, 463
Areolar tissue, 154
Arion, jaw of, 349
Aristotle, lantern of, 339
Arrow-tooth (Toxoglossate) dentition, 346
Arsenious acid, action of, on dental pulp, 901
and morphia pastes, 900
method of application to dental pulp, 902
use of, on dental pulp, 899
Arteries, 215
alveolar or superior maxillary, 234
angular, 226
anterior cerebral, 242
communicating, 242
ethmoid, 240
temporal, 230
ascending cervical, 246
pharyngeal, 228
meningeal branches of, 229
auricular, 228
basilar, 243, 246
buccal, 234
central retinal, 239
cerebral, 241
ciliary, 239
circle of Willis, 242
crico-thyroid, 220
deep auricular, 232
temporal, 233
descending cervical, 227
palatine, 234
dorsalis lingual, 221
Arteries, external nasal, 241
facial or external maxillary, 222
frontal, 241
glandular, 224
incisive, 233
inferior coronary, 225
dental, 233
labial, 225
laryngeal, 247
palatine, 224
thyroid, 246
infraorbital, 234
internal carotid, 235
maxillary, or deep facial, 230
lachrymal, 238
lateral communicating, 243
nasal, 225
left common carotid, 216
lingual, 221
masseteric, 234
mental, 233
middle cerebral, 242
or great meningeal, 232
temporal, 229
muscular, of the orbit, 240
mylo-hyoid, 233
nasal or spheno-palatine, 235
occipital, 226
ophthalmic, 238
palpebral, 241
posterior auricular, 227
cerebral, 242
communicating, 243
ethmoid, 240
temporal, 230
pterygoid, 234
pterygo-palatine, 235
ramus cervicularis princeps, 227
ranine, 222
right common carotid, 216
small meningeal, 233
stylo-mastoid, 228
subclavian, 243
sublingual, 222
submental, 225
superficial temporal, 229
superior coronary, 225
laryngeal, 220
suprascapular, 247
thyroid axis, 246
tonsillar, 224
tracheal, 247
transversalis colli, 247
transverse facial, 229
tympanic, 232
vertebral, 245
Vidian, 235
Articular veins, 253
Articulating arteries, 229
Articulation, diarthroses, 112
temporo-maxillary, 112
Articulations, 111
of base of brain-case, 117
of occiput, 117
of skull at different periods, 118
synchondroses, 112

Artiodactyla, divisions of, 484
Atrophy of odontoblasts, 884
Attolens aurem muscle, 175
Attrahens aurem muscle, 175
Ascending cervical artery, 246
  nasal nerve, 291
  or orbital nerve, 301
  pharyngeal artery, 228
    meningeal branches of, 229
Auditory nerve, 310
Auricular artery, 228
Auriculo-temporal nerve, 294
Axis-cylinder, 266
Aye-aye, teeth of, 432
Azygos uvula muscle, 198

B.

Balistes vetulus, teeth of, 377
Baleen plates of cetacea, 413
Band of embryo, 618
Bartholin, duct of, 211
  gland of, 210
Base of brain-case, 124
Basement-membrane, 145
Basilar artery, 243, 246
    branches of, 246
  process of occipital bone, 51, 54.
Batrachia, teeth of, 379
Bats, classification of, 465
  dentition of, 465
  probable derivation of, 465
Bears, evolution of, 464
  teeth of, 463
Beginnings of caries, 779
Bela, teeth of, 346
Bell on caries, 732
Bichloride of mercury in phagedenic pericementitis, 986
Bicuspids, human, 442
Biological studies, cultures for, 822
    methods in, 821
    on fungi of human mouth, 819
Black on formation of poisons by microorganisms, 757
Blarina, teeth of, 426
Blastoderm, 142, 543
  development of, 554
Blind abscess, 936
Blood, absorption of, 686
  -clot, granulations in, 710
    how formed, 680
    organization of, 709
  -corpuscles, 531
    development of, 566
  physiology of, 533
  -pressure, increase of, 677
  -supply of peridental membrane, 919
  variations in, and in its distribution, 671
  -vessels, development of, 566, 706
    of dental pulp, 831
    of muscles, 164
    of skin, 145
    system of, 215
    thrombi in, 681
Bloodletting, local, 927
Bodies, stellate, 624
Body of inferior maxillary bone, 101
Bone-cells, 41, 575
  canaliculi of, 41
  formation, subperiosteal, 47, 585
Bones, 35
  apophyses of, 35
  arrangement of, 48
  articulations of, 118
  cancellated, 36
  chemical analysis of, 37
  cranial, 50
  dentigerous, of dog, 403
  development of, 45
  diaphyses of, 35
  epiphyses of, 35
  ethmoid, 76
  facial, 131
  frontal, 72
  Haversian canals of, 39
  hyoid, 108
  inferior maxillary, 100
    turbinated, 94
  inflammation of, 43
  intracartilaginous, 45
  lachrymal, 95
  lacunæ of, 41
  lamellæ of, 39
  malar, 97
  maxillary, inferior, 100
    superior, 81
  minute structure of, 38
  nasal, 96
  occipital, 52
  palate, 90
  parietal, 69
  perforating fibres of, 40
  periosteum of, 42
  softening of, 37
  sphenoid, 62
  spongy, 36
  subperiosteal, 47
  temporal, 55
  turbinated, inferior, 79
    superior, 79
  vomer, 80
  weight of, 37
  Wormian, 118
Bourrelet, 617
Brachio-cephalic veins, 248
Bradypus tridactylus, teeth of, 411
Brain-case, anterior fossa of, 120
  articulations of base of, 117
  floor of, 120
  middle fossa of, 122
  posterior fossa of, 123
  walls of, 120
Bridgeman on caries, 744
Broken striæ of Retzius, 656
Buccal and labial surfaces, caries in, 781
  artery, 234
  cavity, development of, 550
  glands, 206
  nerve, 293, 309
Buccinator muscle, 173
Bulbous cord, invagination of, 624

Bunodontia, teeth of, 484
Bunotheria, classification of, 416

C.

Calcic inflammation of the peridental membrane and gums, 957
prognosis in, 968
treatment of, 963
Calcification, 570
and decalcification of teeth, chart of, 647
cylindrical, 878
of bone, 46
of dental pulp, 914
of dentine, 644
of permanent teeth, Pierce on, 645
of pulp, symptoms of, 914
treatment of, 915
of teeth, 363
of tissues of dental pulp, 874
Tomes on, 573
Calcoglobulin, 575
deposits of, in inflamed pulp, 860
Calcospherules, 575
Calculus, removal of, 963
Camphor phenol, 985
Canal, anterior palatine, 86
Haversian, 39, 576
inferior dental, 104
infraorbital, 82, 134
lachrymal, 134, 136, 212
naso-palatine, 81
posterior palatine, 84, 91
Vidian, 65
Canaliculi of bone, 41, 576
Canals, accessory palatine, 130
dentinal, 594
Cancellated portion of bone, 36
Canine eminence, 84
fossa, 84, 133
Canines, definition of, 399
human, 441
Cape anteater, teeth of, 412
Capillaries, lymph, 326
Capping materials, 894
of exposed dental pulp, 886, 894
Capsular ligament, 114
Capsule of Tenon, 178
Capybara, teeth of, 469
Carbolic acid in capping, 897
in superficial pulpitis, 905
Carbonate of sodium as an antiseptic, 909
Cariacus, teeth of, 488
Caries, absorptive processes in, 777
acid mucus in, 776
action of tobacco on, 808
agency of micro-organisms in, 750
beginnings of, 779
characteristics of, 786
clinical history of, 779
commencement of, in enamel, 765
dental, 729
producing secondary formations, 913
discoloration in, 769
diseases causative of, 778
etiology of, 731
Caries, experiments on, 797
fungi causing, 801, 802
fungi of, 814, 815
growths in, 767
hereditary influences causing, 772
infectious nature of, 789
inflammatory, theory of, 734
in necks of teeth, 786
in pits and grooves of the enamel, 779
in proximal surfaces, 779
lactic acid in, 798
penetration of dentine in, 765
of enamel in, 768
phenomena of, 764
predisposing causes of, 770
pulp-exposure in, 767
Carious dentine, lactic acid in, 800
surfaces, classes of, 779
Carnivora, classification of, 448
teeth of, 448
Carotid artery, external, 218
internal, 235
canal, 59, 122, 127
sheath, 157, 216
superior triangle, 188
Cartilage, 138
-cells, 140
connective tissue, 35
elasticity of, 138
fibre, 140
fibro-elastic, 140
hyaline, 139
interarticulating disc of, 114
lacuna, 140
Meckel's, 105
nasal, 77
Cartilago dentalis, 617
Caruncula lachrymalis, 212
Cats, dental evolution of, 460
Cause of apical pericementitis, 925
of fever, 715
of shock, 719
Cavernous sinus, 259
Cavity of the mouth, 137
Cebidæ, teeth of, 435
Cell-movements in inflammation of dental pulp, 850
-proliferation, Ziegler on, 526
Cells, amœboid, 692
bone-, 41
cartilage-, 140
embryonal, of mucous membrane, 201
epithelial, 535
granulation-, 704
medullary or true marrow, 44
morphological appearance of, 531
multipolar giant-, 44
nucleated red blood-, 44
physiological consideration of, 524
stellate, 624
structure of, 523
wandering, 214, 692
Cementification, 590
Cementoblasts, 569, 591
Cement organ, 364
development of, 364

Cementum, 358
canaliculi of, 358
lacunæ of, 358
Central retinal artery, 239
Centrifugal nerves, 274
Centripetal nerves, 275
Ceratodus, dentition of, 375
Cerebral arteries, 241
fossa, 124
nasal slit, 80
Ceruminous glands, 152
Cervical fascia, 156
ganglion, 313
nerve, 309
Cervico-facial nerve, 309
Cervicularis princeps artery, 227
Cetacea, baleen of, 353
teeth of, 413
Change in the maxillary bones after birth, 107
Characteristics of caries, 786
Chart of calcification and decalcification of teeth, 647
Charts, 782–785
Cheiroptera, teeth of, 465
Chemical analysis of bone, 37
Chill in fever, 713
Chimæra plumbea, dentition of, 375
Chiromys, teeth of, 432
Chitin, 337, 342
Chloride of zinc in calcic inflammation, 966
Chlorosis, 689
Cholœpus didactylus, teeth of, 411
Chorda tympani nerve, 307
Chronic alveolar abscess, 935
discharging on face, 940
pus burrowing in, 937
apical pericementitis, 925
Ciliary arteries, 239
ganglion, 298
nerves, 299
long, 289
Cingulum of premolar of dog, 355
Circle of Willis, 242
Circular sinus, 260
Civets, teeth of, 457
Classes of carious surfaces, 779
Classification of bone, 48
of fishes, 365
of Mammalia, 393
Clinical history of caries, 779
Clinoid processes, anterior, 62
middle, 62, 63
posterior, 62
Cocci in caries, 801
Collateral circulation of carotid arteries, 218
Collodion in capping, 897
Coloring matter produced by fungi, 825
Color of bones, 37
of muscle, 160
Common carotid arteries, 215
artery, left, 216
line of, 216
Common carotid artery, right, 216
sheath of, 216
variations of, 218
temporal vein, 252
Compact portion of bone, 36
Comparative chronology of dental follicle, 651
Composition of enamel, 608
Compound tubular salivary glands, 204
mucous glands, 202
nerves, 277
Compressible pulse, 666
Compressor nasi muscle, 170
Condyle of bones, 49
Condyles of occipital bone, 52, 128
Condyloid fossa, 53
processes of inferior maxilla, 104
Congestion, local, 674
Connective tissue, 135
embryonic, 564
envelope, 630
fibrillar, 565
Constitutional treatment in alveolar abscess, 946
of apical pericementitis, 928
Contractile substance, 162
Conus, teeth of, 346
Cord for permanent teeth, development of, 634
of enamel organ, 620
Cornea, irritation of, 697, 698
Cornua of hyoid bone, 109
Coronal suture, 112
Coronary artery, inferior, 225
superior, 225
Coronoid process, 104
Corpuscles, lymph, 325
osseous, 41
Pacinian, 146
tactile, 142, 146
white, 325, 532
Cortical layer of enamel, 608
Corrugator supercilii muscle, 169
Counter-irritation, 927
Cranial bones, 50
nerves, 223
region supplied by, 277
Crest, infratemporal, 65
of nasal bones, 97
Cribriform plate, 79
Crico-thyroid artery, 220
Crista galli, 77
Crocodilia, teeth of, 385
Crustacea, masticatory apparatus of, 339
Crusta petrosa, 355
Cryptoproctidæ, classification of, 458
teeth of, 457
Culture materials, 792, 793
Cultures for biological studies, 822
gelatin, 814
Cup-shaped abrasions, 995
Cusps of teeth, facets on, 993
Cushing's scalers, 964
Cuticula dentis, 606
Cylindrical calcification, 878

D.

Death of dental pulp, 852
Decalcification of temporary teeth, Pierce on, 645
Deciduous dentition of man, 446
Decomposition of the dental pulp, 892
Deep auricular branch of internal maxillary artery, 232
  cervical fascia, 156
  facial or anterior internal maxillary vein, 251
    artery, 230
    vein, tributaries of, 251
  fascia, 155
    of face, 158
    of head, 158
  temporal artery, 233
Deep-seated pulpitis, treatment of, 906
Degeneration of structure of dental pulp, 859
Deinotherium, dentition of, 491
Delphinidæ, teeth of, 414
Dendrohyrax, teeth of, 475
Density of dentine, causes increasing, 912
Dental anatomy, 351
  caries, 729
    growths of secondary dentine excited by, 868
  erosion, hyperæsthesia in, 1006
  follicle, comparative chronology of, 651
  formula, 403
  groove, 616
  ligament, 919, 955
  nerves, middle superior set, 291
  neuralgia, 837
  operations, shock from, 725
  papilla, 641
  pulp, 592–636
    abscess of, 855–857
    blood-vessels of, 831
    calcification of, 914
      of tissues of, 874
    causes of inflammation in, 849
      producing devitalization of, 892
    cells of, 830
    chronic inflammation of, 857–859
    death of, 852
    decomposition of, 892
    degeneration of structure of, 859
    differential diagnosis between diseases of, 837
    dilated vessels of, 846
    diseases and treatment of, 888
    exposure of, 853
    function of, 832
    gangrene of, 892
    hyperæmia of, 840–843
    inflammation of, 848–853
    irritation of, 844, 889
    microscopic study of, 840–842
    nerves of, 831
    pathology of, 829
    removal of, 903, 926
    sensitiveness to thermal changes in, 848
Dental pulp, sensory functions and symptomatology of, 832
    simple exposure of, 890
    suppuration of, 853–855
    swelling of, 839
    symptoms of inflammation of, 852
    fissure of, 829
  ridge, 616
  sacculus, 361, 364
  tissues, 356
  tubes, 356
Dentary bone of fishes, development of, 378
Dentate sutures, 111
Dentinal canals, 594
  fibrils, 357
    secondary dentine resulting from irritation of, 870
  papilla, 568, 622
  processes, 357, 594
  sheath, 357
  tubules, softening of, 768
Dentine, 356
  analysis of, 356
  calcification of, 644
  deposit of, 592
  development of, 593
  discoloration of, 852
  granular layer of, 357
  increase of density of, 911
  nodular, 911
  organ, 361
    development of, 361
  secondary, 911
    resulting from irritation of dentinal fibrils, 870
  sensitiveness of, 1006
  structure of, 356
Dentinification, 591
Dentition of alligator, 385
Deposition of fat, 565
Deposit of dentine, 592
Deposits of calcoglobulin in inflamed pulp, 860
  secondary causes of, 913
Depressor alæ nasi muscle, 171
  anguli oris muscle, 173
  labii superioris muscle, 172
Dermal denticles, 353
    development of, 354
    structure of, 353
  spines, 354
Descendens noni nerve, 323
Descending cervical artery, 227
  or dental nerve, 291
  palatine artery, 234
    nerves, 301
Desiccation of enamel, 609
Desirabode on caries, 736
Desmatotherium, teeth of, 478
Development, embryonic, 542
  of alveolar wall, 632
  of blood-corpuscles, 566
  of blood-vessels, 566, 706
  of bone, 45
    intercartilaginous, 587

Development of bone, intramembranous, 48
subperiosteal, 47
of bones of the face, 110
of buccal cavity, 550
of cord for permanent teeth, 634
of dentine, 593
of dermal denticles, 354
of enamel, 643
of enamel organ, 562
of epiblast, 555
of ethmoid bone, 80
of fat, 565
of frontal bone, 76
of glands, 560
of hair, 558
of head, 109
of hyoid bone, 109
of inferior maxilla, 105
of interior turbinated bone, 95
of jaws, 110, 550
of lachrymal bone, 96
of malar bones, 100
of maxillæ, 551
of mesoblast, 555
of nails, 556
of nasal bone, 97
of occipital bone, 54
of parietal bone, 71
of palate, 551
of palate bone, 93
of pharyngeal teeth of fishes, 361
of sphenoid bone, 67
of superior maxillary bone, 88
of the teeth, 360, 609
of teeth of fishes, 378
of temporal bone, 61
of vomer, 81
Devitalization and removal of dental pulp, 898
of dental pulp, causes producing, 892
Devitalized pulps, removal of, 907
Diadectes, teeth of, 384
Diagnosis of alveolar abscess, 943
of exposed dental pulp, 891
Diapedesis of red blood-globules, 679
of white blood-globules, 692
Diaphyses of bones, 35
Diarthrosis, articulation, 112
Diclonius, teeth of, 387
Dicrotous pulse, 670
Didelphis Virginianus, teeth of, 495
Didymictis, teeth of, 430
Differential diagnosis between diseases of the dental pulp, 837
Digastric fossa, 60, 102
groove, 60, 127
muscle, 187
nerve, 308
Dilated vessels of dental pulp, 846
Dilophodon, teeth of, 478
Dimetrodon, teeth of, 383
Dinictis, teeth of, 460
Diodon, teeth of, 378
Diphyodont dentition, 396
Diploë, 120
Diploic veins, 261
Diprotodontia, teeth of, 496
Discoloration in caries, 769
of dentine following death of dental pulp, 852
Disease, definition of, 661
Diseases causative of caries, 778
of dental pulp and their treatment, 888
of peridental membrane, 918, 921
having their beginning at margin of gum, 953
Dissaeus, teeth of, 420
Distal end of bones, 49
Division of nerve-fibres, 268
Divisions of mammalian dentition, 396
Dicoglossata, 348
Dog, teeth of, 397
Dolphin, teeth of, 414
Dome or vertex of the skull, 120
Domestic cat, teeth of, 461
Dorsal plates of embryo, 543
Dorsalis lingual artery, 221
Dorsum sella, 62
Dry gangrene, 893, 910
Duct, lachrymal, 212
lachrymo-nasal, 213
of Bartholini, 211
of Steno, 208
of Wharton, 210
parotid, 208
submaxillary, 210
thoracic, 330
Ducts of Rivinus, 211
sublingual, 211

E.

Ear, muscles of the, 174
Echinidæ, food of, 341
Echinus (sea-urchin), dental system of, 340
oral apparatus of, 339
Ectocium, molars of, 480
Ectoconus, teeth of, 471
Edentata, teeth of, 408
Egg, ovarian, 540
Eggs, mammalian, 542
Eighth nerve, 310
Elasmobranchii, definition of, 365
teeth of, 370
Elasticity of cartilage, 138
Elephants, teeth of, 488
Eleventh nerve, 320
Embryo, dorsal, plates of, 543
neural, groove of, 543
plates of abdominal, 543
Embryology, 539
and histology, dental, 519
Embryonal cells of mucous membrane, 201
mucous membrane of the mouth, 611
Embryonic connective tissue, 564
development, 542
Embolism, 683
Eminence of parietal bone, 69
Emissary veins, 262
Emenentia articularis, 56
Empedocles molaris, teeth of, 383

Enamel, 359
analysis of, 359
cells, 362
composition of, 608
cortical layer of, 608
cuticle, 358
desiccation of, 609
development of, 643
fixed material in, 600
formed material in, 600
membrane, 606
nacreous layer of, 608
organ and papilla, connection between, 628
cord of, 620
inner tunic of, 626
development of, 361, 562
organic, layer of, 608
prisms, 359, 601
structure of, 359
variations in hardness of, 602
Endochondral bone, 45
Endomysium of muscles, 161
Endosteum of bone, 43
Envelope, connective tissue of, 630
Epiblast, 142, 543
development of, 555
products of, 556
Epicranial or occipito-frontal aponeurosis, 167
Epidermis, 143
Epiphyses of bones, 35
Epithelial cells, 535
Epithelium of mucous membrane, 199
of oral cavity, 199
reproduction of, 708
of the skin, 614
transplantation of, 708
Erosion and abrasion of teeth, 993
etiology, 1002
Erosions of teeth, position and form of, 997–1002
Esthonyx, teeth of, 425
Ethmoid bone, 76
process of turbinated bone, 94
Ethmoidal cells, posterior, 79
foramina, 75, 78, 134
notch, 75
spine, 62
wings, 77
Etiology of caries, 731
of erosion, 1002
of mechanical abrasion, 994
of phagedenic pericementitis, 977
Eustachian sulcus, 127
Evacuation of pus in alveolar abscess, 945
Evolution, theory of, 520
Examination of pulse, 663
Exciting cause of inflammation, 700
Exostosis, causes producing, 913
Experiments on caries, 797
with acids on teeth, 1003–1006
Exposed dental pulp, capping of, 886
diagnosis of, 891
Exposure of dental pulp, 853
treatment of, 893
Exposure of dental pulp, secondary deposit in, 886
External auditory meatus, 60, 127
angular process, 73
carotid artery, 218
branches of, 219
jugular vein, 255
and tributaries, 255
lateral ligament, 114
maxillary artery, 222
nasal artery, 241
oblique line of inferior maxilla, 101
occipital protuberance, 53
palatine nerve, 301
pterygoid muscle, 182
nerve, 293
plate, 67
rectus muscle, 176
surface of brain-case, 124
tendo-palpebrarum muscle, 169
Exudate, fibrinous, 694
Exudates in inflammation, 694

F.

Face, swelling of, in acute alveolar abscess, 931
Facets in cusps of teeth, 993
Facial artery, 222
branches of, 224
bones, 131
muscles, 166
nerve, 304
communicating branches, 305–307
origin of, 305
table of its branches, 305
notch of inferior maxilla, 103
or anterior region of skull, 131
or terminal nerves of superior maxillary, 291
region of skull, 131
vein, 224, 249
Farrar's syringe, 967
Fascia, 154
aponeurotic, 155
deep, 155
cervical, 156
of face, 156
of head, 156
of neck, 156
of orbit, 178
of Tenon, 178
omo-hyoid, 157
parotid, 209
prevertebral, 157
subcutaneous, 155
submaxillary, 157
superficial, 155
temporal, 179
Fasciculi of muscles, 161
Fat, deposition of, 565
development of, 565
-vesicles or adipose tissue, 44
Faulty antagonism of teeth producing wear, 994
formation of the teeth, 770

Fermentation a cause of caries, 738
in human mouth, experiments on, 793–795
its relation to caries of teeth, 791
in mouth, apparatus for experiments on, 792
Fever, 711
cause of, 715
chill in, 713
heat-production in, 714
results of, 717
surgical, 713
temperature in, 711
Fibres, muscular, 162
Fibrillar connective tissue, 565
Fibrils, dental, 357
Fibrinous exudate, 694
Fibro-cartilage, 140
-connective tissue, 35
-elastic cartilage, 140
Fifth nerve, 282
origin of, 284
pair of nerves, sympathetic ganglia of, 297
table showing distribution of, 287
Filling materials, antiseptic power of, 810
for pulp-canals, 909
pulp-canals, 899
time for, 903
used in capping, 898
Fishes, classification of, 365
teeth of, 364
Fissure, pterygo-maxillary, 130
glenoid, 56, 57, 127
sphenoid, 66
spheno-maxillary, 65, 99, 130, 134
Fistula discharging under the chin, 942
passing through lower maxilla, 942
Fixed material in enamel, 600
Flagg, Foster, formula for nerve-paste, 900
Flat bones, 36
Floor of nasal fossa, 135
of the mouth, 137
Fluids of the mouth, morbid conditions of, 774
Flying foxes, teeth of, 465
Fœtal septum, 551
Fomentations in alveolar abscess, 947
Fontanelle, anterior median, 119
posterior median, 119
Fontanelles, 119
lateral, 119
Foramen, anterior condyloid, 124
dental, 101, 133
lacerated, 66, 134
cæcum, 74
incisive, 86, 136
infraorbital, 84, 132
jugular or posterior lacerated, 52
lacerum medius, 122
posterius, 123
magnum, 54, 124
malar, 97, 134
mental, 101
middle lacerated, 58, 127
of Scarpa, 136
Foramen of Stetson, 86, 136
optic, 133
ovale, 65, 122, 126
parietal, 70
posterior dental, 103
lacerated, 127
pterygo-palatine, 130
rotundum, 65, 122
spheno-palatine, 92, 130, 136, 127
spinosum, 65, 122
stylo-mastoid, 60, 122
supraorbital, 73, 132
Vesali, 122
Foramina, anterior condyloid, 53
ethmoidal, 75, 78, 134
lacerated, 122, 134
infraorbital, 132
malar, 97, 134
mastoid, 124
naso-palatine, 86
of Scarpa, 86
optic, 62, 67
parietal, 117
posterior condyloid, 53, 124
ethmoidal, 75, 78, 134
Formation of bone, interstitial, 580
intramembranous, 48, 583
of ducts in grain, 707
of poisons by micro-organisms, Black on, 757
Formed materials in enamel, 600
Formula, dental, 403
Fossa, anterior, of the brain-case, 120
canine, 84, 133
cerebral, 124
condyloid, 53
digastric, of inferior maxilla, 102, 127
incisive, 101
lachrymal, 75, 133
middle, of the brain-case, 122
nasal, 134
parietal, 70
pituitary, 62
posterior, of brain-case, 123
pterygoid, 67, 104
scaphoid, 67
spheno-maxillary, 130
sublingual, 102
temporal, 128
trochlear, 75
zygomatic, 129
Fox squirrel, teeth of, 467
Frænum of lower lip, 173
of upper lip, 172
Frontal artery, 241
bone, 72
eminence, 74
nerve, 286
notch, 73
processes of malar bones, 98
sinuses, 73
vein, 250
Fronto-ethmoidal cells, 75
-malar suture, 117
-parietal suture, 117
-sphenoidal suture, 117

Function of peridental membrane, 920
Fungi causing caries, 801, 802
coloring matter produced by, 825
of caries, 814, 815
action of sugar, 805
evolution of carbonic acid by, 805
of dental caries, their pure cultivation and effect upon lower animals, 813
of human mouth, acid produced by, 824–826
biological studies on, 819
morphology of, 823
relation to oxygen, 824
peptonizing action of, 824
oxygen in relation to, 805
production of gas by, 825
Fungus growths in caries, 767

G.

Galeopithecus, teeth of, 428
Ganglion, cervical, 313
-cells of nerves, 264
ciliary, 298
Gasserian, 284
geniculate, 306
jugular, 313
inferior or petrous, 311
lenticular, 798
of Andersch, 311
of Ehrenritter, 311
of Meckel, 299, 301
ophthalmic, 598
optic, 302
otic, 302
semilunar, 284
spheno-palatine, 299, 301
submaxillary, 303
superficial jugular, 311
sympathetic, of fifth pair of nerves, 297
Gangrene, dry, 893, 910
of dental pulp, 892
Gangrenous pulps, causes of, 906
treatment of, 907
Gasserian ganglion, 284
Gastro-pneumonic system of mucous membranes, 199
Gelatin cultures, 814
General development of the head, 109
pathology, 661
Generation, spontaneous, 521
Genial tubercles, 102
Geniculate ganglion, 306
Genio-glossus muscle, 190
hyoid muscle, 190
Genito-urinary system of mucous membrane, 199
Geomalacus, jaw of, 349
Gila monster, teeth of, 386
Gingival organ, 955
Gingivitis, 955
Ginglymus, or hinge-joint of Allen, 112
Glands, lachrymal, 211
of Bartholin, 210
parotid, 207
sublingual, 210
Glands, submaxillary, 209
buccal, 206
ceruminous, 152
compound tubular mucus, 202
saliva, 204
development of, 560
labial, 206
lingual, 207
lymphatic, 328
Meibomian, 153
molar, 206
muco-salivary, 206
mucus, 198, 204
of mucous membrane, 198
palatine, 207
racemose, 203
sebaceous, 152, 560
secretory, of mucous membrane, 201
simple mucous, tubular, 202
sudoriferous, 151
sweat, 151
true salivary, 205
Glandular arteries, 224
Glandula socia parotidis, 208
Glasserian fissure, 56
Glenoid fissure, 56, 57, 127
fossa, 56, 127
Glosso-pharyngeal nerve, 310
communicating branches of, 312
lingual branches of, 312
muscular branches of, 312
pharyngeal branches of, 312
table of branches, 311
Glyptodon, teeth of, 410
Glyptostoma, jaw of, 349
Gold in caries, 811
Gouty inflammations of the peridental membrane, 979
Grain, formation of ducts in, 707
Granulation-cells, 704
Granulations in blood-clot, 710
Great superficial petrosal nerve, 306
wings of sphenoid bone, 64
Groove, dental, 616
digastric, 127
medullary, 548
mylo-hyoid, 102
Grooves for olfactory nerves, 77
Growth of bone, 47
Gum, structure of, 955
Gutta-percha for filling pulp-canals, 909

H.

Hair, 147
bulb of, 147
cuticle of, 148
development of, 558
fibrous or cortical portion of, 148
follicles of, 147–149
medulla of, 149
papilla of, 150
root of, 147
health of, 149
shaft of, 147
Halmaturus, teeth of, 496

Hamular process, 67
Hanover, stratum, intermedium of, 625
Hapale, teeth of, 435
Harmonic sutures, 111
Haversian canal, 576
canals of bone, 39
Heads of bones, 49
Health, definition of, 661
Heart lesions, pulse in, 670
Heat-production in fever, 714
Hedgehog, teeth of, 429
Heloderma suspectum, teeth of, 386
Hemorrhage, 685
Hemorrhagic infarction, 683
Hereditary influences causing caries, 772
Herpestes, teeth of, 456
Heterodont dentition, 396
Hiatus Fallopii, 58, 123
Highmore, antrum of, 89
Hippotherium, teeth of, 481
Hirudinæ (leeches), teeth of, 338
Histology, dental, 519
of teeth, 356
Hog, teeth of, 484
Homodont dentition, 396
Horse, canines of, 483
digits of, 482
incisors of, 482
molars of, 483
Human dentition, 437
Hunter on caries, 731
Hyæna, teeth of, 455
Hyænidæ, evolution of, 453
Hyænarctos, teeth of, 464
Hyænictis, teeth of, 456
Hyænodontidæ, teeth of, 420
Hyaline cartilage, 139
Hyo-branchial skeleton, 369
bones of, 369
Hyo-glossus muscle, 191
Hyoid artery, 220
bone, 108
development of, 109
Hyo-mandibular arch of codfish, 367
Hyperæmia, 676
local, 674
of dental pulp, 840, 843, 847, 848
pain in, 844
passive, 677
results of, 678
tissue, change in, 845
Hyperæsthesia in dental erosion, 1006
Hypoblast, 142, 543
Hyracoidea, ancestry of, 476
Hyracotherium, teeth of, 477
Hyrax, teeth of, 475
Hypoglossal nerve, 322
communicating branches of, 323
lingual branches of, 324
table of, 323

I.

Ictitherium, teeth of, 453
Iguanidæ, teeth of, 386
Iguanodon, teeth of, 387
Incisive artery, 233
crest, 86
foramen, 86, 136
fossa of inferior maxilla, 101
of superior maxilla, 84
Incisors, definition of, 398
human, 438
lower, human, 440
upper central, human, 440
lateral, human, 440
Indian elephant, molars of, 490
tusks of, 489
Infant layer of epithelium, 618
Infarction, hemorrhagic, 683
Infection by micro-organisms of the mouth, 816
Infectious alveolitis, 968
nature of caries, 789
Inferior constrictor muscle, 194
coronary artery, 225
curved lines of occipital bone, 53
dental artery, 233
canal, 104
foramen, 103
nerve, 296
branches of, 296, 297
communicating branch, 296
incisive, branches of, 297
lesser, 297
mental or labial branch, 297
labial artery, 225
laryngeal artery, 247
longitudinal sinus, 258
maxilla, at birth, 105
development of, 105
movement of, 105
maxillary bone, 100
nerve, 292
deep temporal branches of, 292
posterior temporal branch of, 293
meatus, 85, 136
oblique muscle, 177
ophthalmic vein, 261
or palatine artery, 224
or recurrent laryngeal nerve, 318
palatine vein, 251
palpebral veins, 251
pedicle of sphenoid bone, 67
petrosal sinus, 261
petrous ganglion, 311
rectus muscle, 176
thyroid artery, 246
veins, 248
turbinated bone, 94
crest, 92
Inflammation, 690
chronic, of dental pulp, 857–859
exciting cause of, 700
exudates in, 694
in dental pulp, causes of, 949
of bone, 43
of dental pulp, 848–853
cell, movements in, 850
lymph-deposits in, 852
recovery from, 853
symptoms of, 852

Inflammation of dental pulp, tissue-changes in, 849
of peridental membrane, cause of, 893
pain in, 693
subperiosteal, 944
swelling in, 693
temperature in, 693
tissue-changes in, 695
white blood-corpuscles in, 695
Influence of disease on bones, 49, 135
Infraorbital artery, 234
canal, 82, 134
foramen, 84
foramina, 132
nerve, 290
plexus, 292
ridge, 84
Infratonsillar or pharyngeal tonsils, 214
Infratemporal crest, 65, 129
Infratrochlear nerve, 289
Infundibulum of ethmoid bone, 79
of nasal chamber, 137
Inner tunic, 640
of enamel organ, 626
Innominate veins, 248
right and left, 248
Insectivora, teeth of, 417
Inter-articulating disc or fibro-cartilage, 114
-cartilaginous development of bone, 587
-globular spaces, 357, 595, 766
-maxillary bone, 88
-parietal bone, 54
suture, 116
Intermittent pulse, 670
Internal angular process, 73
auditory meatus, 59, 123
carotid artery, 235
frontal crest, 74
jugular vein and tributaries, 256
laryngeal nerve, 318
lateral ligament, 115
mammary artery, 247
maxillary artery, 230
deep temporal, branches of, 233
vein, 253
nasal nerves, 289
oblique ridge, 101
occipital crest, 53
protuberance, 53
pterygoid muscle, 181
nerve, 293
plate, 67, 68
rectus muscle, 176
tendo-palpebrarum muscle, 169
Interstitial formation of bone, 580
Intra-cartilaginous bone, 45
Intra-membranous bone, 48
formation of bone, 48, 583
Invagination of bulbous cord, 624
Invertebrates, teeth of, 337
Involuntary, smooth, or unstriated muscles, 164
Iodine, uses of, on gangrenous pulps, 908
Iodoform in capping, 898
in superficial pulpitis, 905
Irregularities of pulse, 669
of teeth caused by inflammation of the throat, 135
Irritation causing secondary dentine, 913
of cornea, 697, 698
of dental pulp, 844, 889
Ivory, nature of, 489

J.

Jaw, development of, 550, 629
Jelly of Wharton, 566
Jugular foramen, 52
ganglion, 313
notch, 52
process of occipital bone, 51

K.

Kangaroo, teeth of, 496
Koecker on caries, 733

L.

Labial and buccal surfaces, caries in, 781
glands, 206
or descending nerves, 292
Labyrinthodonts, teeth of, 381
Lachrymal artery, 238
bone, 95
canal, 134, 136, 212
crest, 95
duct, 212
fossa, 75, 133
gland, 211
groove, 84
nasal duct, 213
passage, 213
nerve, 288
process, 94
sac, 213
tubercle, 84
Lactic acid in caries, 798
in carious dentine, 800
Lacto-phosphate of lime in capping, 897
Lacuna-cartilage, 140
Lacunæ of bone, 41, 576
Lagomorpha, teeth of, 469
Lambdoid suture, 117
Lambdotherium, molars of, 480
Lamella of bone, 39
Lamina cribrosa, 59
of embryo, 618
Lantern of Aristotle, 339
Laryngeal artery, 220
Lateral communicating arteries, 243
fontanelles, 119
masses of ethmoid bone, 78
nasal artery, 225
processes of pulp, 358
region of the skull, 128
sinuses, 259
Layer, odontoblastic, 640
Leber and Rottenstein on caries, 751
Leeching in apical pericementitis, 928
Leeches (Hirudinæ), teeth of, 338

Left common carotid artery, 216
Lemurs, teeth of, 431
Lenticular ganglion, 298
Leptictis, teeth of, 424
Leptocardii, definition of, 365
Leptothrix buccalis, 751, 795
gigantea, 795
Lesser superficial petrosal nerve, 306
wings of sphenoid bone, 66
Leucocytes, 325, 692
Levator anguli oris muscle, 172
labii inferioris muscle, 173
superioris alæque nasi muscle, 171
proprius muscle, 171
palati muscle, 197
palpebral muscle, 176
Life, nature of, 519
Ligament, capsular, 114
dental, 919, 955
internal lateral, 115
stylo-hyoid, 189
-maxillary, 115
Ligaments of the temporo-maxillary articulation, 113
Ligatures, absorption of, 922
Limnæa, teeth of, 349
Line ridge or crest, 49
Lingual artery, 221
glands, 207
nerve, 295
branches of communication, 295
vein and tributaries, 254
Lingualis muscle, 191
Lister, method of, 755
Lizard, teeth of, 386
Local congestion, 674
hyperæmia, 674
Longitudinal sinus, 75
Lophiodontidæ, digital formula of, 477
teeth of, 477
Loxodon Africanus, dentition of, 489
Lutrictis, teeth of, 464
Lymph-capillaries, 326
Lymph, composition of, 325
-corpuscles, 325
deposits in inflammation of dental pulp, 852
-sinus, 329
-spaces, 326
of bone, 41
Lymphatic duct, 330
glands, 328
vessels, 325
of head and neck, 330
structure of, 327
valves of, 327
Lymphatics, deep, 330
of muscles, 164
of skin, 145
origin of, 326
superficial, 330
Lyrifera, definition of, 365

M.

Magitot on caries, 747
Magnum foramen, 124
Malar bones, 97
foramina, 97, 134
process, 85
Malpighi stratum, 144
Malpighian layer of the skin, 615
Mammalia, classification of, 393
origin of, 391
teeth of, 390
Mammalian dentition, divisions of, 396
eggs, 542
Marmosets, dentition of, 434
Marrow-fat, vesicles of, 44
of bone, 43
red, 43
red cells of, 45
yellow, 43
Marsipobranchii, definition of, 365
Marsupials, distinctions of, 493
teeth of, 493
Masseter muscle, 179
Masseteric artery, 234
nerve, 293
Mastication, action of muscles of, 182
muscles of, 178, 406
Mastodon, teeth of, 491
Mastoid artery, 227
foramen, 124
portion of temporal bone, 60
Materials for capping, 894
Matrix of osseous substance, 571
Maxillæ, development of, 551
Maxillary bone, inferior, 100
superior, 81
bones of codfish, 368
process of turbinated bone, 94
of malar bones, 99
sinus, 89
Meatus, anterior palatine, 86
external auditory, 60, 127
inferior, 85, 136
internal auditory, 59, 123
middle, 136
of superior maxillary bone, 85
superior, 136
of ethmoid bone, 79
of superior maxillary bone, 85
Mechanical abrasion, etiology of, 994
Meckel's cartilage, 57, 105
development of, 552
ossification of, 105, 554
ganglion, 299
Medullary groove, 548
or true marrow-cells, 44
plates, 548
sheath, 266
Megalonyx, teeth of, 411
Megalotidæ, teeth of, 453
Megatherium, teeth of, 410
Meibomian glands, 153
Membrana eboris, 358
destruction of, 885
Membrane, basement, 145
corium of mucous, 200
epithelium of mucous, 199
mucous, 198

Membrane of enamel, 606
of Nasmyth, 358
Meningeal arteries, 229
Meniscotherium, teeth of, 474
Menopomea, dentition of, 381
Mental artery, 233
foramen, 101, 133
process, 101
Mento-hyoid muscle, 189
Mesoblast, 142, 543
development of, 555
products of, 556
Mesonyx, teeth of, 418
Miacis, teeth of, 430
Micro-organisms in phagedenic pericementitis, 977
of the mouth, infection by, 816
Microscopic study of dental pulp, 840–842
Microscopical examination, preparation of bone for, 38
Midas, teeth of, 434
Middle cerebral artery, 242
clinoid process, 63
constrictor muscle, 193
deep temporal nerve, 293
fossæ of brain-case, 122
lacerated foramen, 58, 122, 127
meatus, 85, 136
or great meningeal artery, 232
superior dental nerve, 291
temporal artery, 229
vein, 253
turbinated bone, 79
Migrating lymph-corpuscles of tonsils, 214
Milk dentition, 498
Miller, experiments of, 759
on fermentation in the human mouth, its relation to caries of the teeth, 791
Mills and Underwood on caries, 752
Minute structure of bone, 38
Molar glands, 206
Molars, definition of, 401
human, 443
of elephant, shedding of, 490
wear of, 490
Molecular disturbances in shock, 722
Mollusca, dental apparatus of, 341, 349
Molluscan animals, functions of teeth, 350
radular apparatus, 342
Mollusks, chitinous armature of, 342
radular of, instructions for examining, 344, 345
Monkeys, teeth of, 434
Monodon, teeth of, 414
Monophyodont dentition, 396
Morbid conditions of fluids of the mouth, 774
Morphia and arsenious-acid pastes, 900
Morphological appearance of cells, 531
Morphology of fungi of the human mouth, 823
Motion, nerves of, 274
Motor nerves, peripheral end-organs of, 272
Mouth, cavity of, 137
Mouth, embryonal mucous membrane of, 201, 611
floor of, 137
roof of, 137
Movements of inferior maxilla, 115
Muco-periosteum, 200
salivary glands, 206
Mucous glands, 198, 204
membrane, 198
embryonal cells of, 201
epithelium of, 199
gastro-pneumonic system of, 199
genito-urinary system of, 199
glands of, 198
secretory glands of, 201
Multipolar giant-cells, 44
Mummified condition of the pulp, 893
pulps, 910
Muscles, action of orbital, 177
attolens aurem, 175
attrahens aurem, 175
azygos uvulæ, 198
blood-vessels of, 164
buccinator, 173
contractile substance of, 162
corrugator supercilii, 169
depressor anguli oris, 173
labii inferioris, 173
labii superioris, 172
endomysium of, 161
external pterygoid, 182
facial, 166
fasciculi of, 161
size of, 162
fibres of, 164
genio-glossus, 190
-hyoid, 190
Horner's, 169
hyo-glossus, 191
inferior oblique, 177
constrictor, 194
internal pterygoid, 181
involuntary, 164
levator anguli oris, 172
labii superioris alæque nasi, 171
proprius, 171
palati, 197
palpebræ, 176
lingualis, 191
lymphatics of, 164
of mastication, action of, 182
mento-hyoid (Macalister), 189
of ear, 174
of mastication, 406
oral group, 171
middle constrictor, 193
mylo-hyoid, 189
nasal set, 170
neck, 183
action of, 183, 185
nerves of, 164
number of, 166
occipito-frontalis, 166
of orbit, 175
of the pharynx, 192
omo-hyoid, 186

Muscles, oral, action of, 174
orbicularis oris, 171
palpebrarum, 168
orbital, action of, 177
palato-Eustachian, 197
-glossus, 196
-pharyngeus, 195
perimysium of, 161
pterygoideus proprius (Henle), 182
pyramidales nasi, 168
recti or straight of the orbit, 176
retrahens aurem, 175
risorius, 173
soft palate, 192
sterno-cleido-mastoideus, 184
-hyoid, 185
-thyroid, 186
stylo-glossus, 191
-hyoid, 189
-pharyngeus, 194
superior constrictor, 192
oblique, 177
supra-hyoid space, 187
temporal, 180
tensor palati, 197
tarsi, 169
thyro-hyoid, 186
trochlearis, 177
unstriped, 164
varieties, 165
voluntary, fibres of, 160
zygomaticus major, 172
minor, 172
Muscular arteries of the orbit, 240
fibres, 162
tissue, 159
Muskrat, teeth of, 467
Mustilidæ, teeth of, 464
Myeloplaxes of bone, 43
Mylo-hyoid artery, 233
groove, 102
muscle, 189
nerve, 296
ridge, 101
Myolemma, 162
Myrmecobius, dentition of, 493
Myrtiform fossa, 84

N.

Nacreous layer of enamel, 608
Nails, development of, 556
Narwhal, teeth of, 414
Nasal angle, 97
aperture, posterior, 136
arch, 132, 136
artery, lateral, 225
bones, 96
cartilage, 77
chamber, infundibulum of, 137
crest, 86
eminence, 73
fossa, 134
muscles, 170
nerve, branches of, 288
notch, 73
Nasal openings, anterior, 132, 136
or internal set of nerves, 292
or spheno-palatine artery, 235
process of superior maxillary bone, 85
septum, 135
abnormality of, 135
spine of frontal bone, 73
of superior maxilla, 86
of superior maxillary bone, 86
Nasmyth's membrane, office of, 608
origin of, 608
Naso- or oculo-nasal nerve, 288
-palatine canal, 81, 136
foramina, 86
nerve, 302
Neck, muscles of, 183
of bones, 49
veins of, 254
Necks of the teeth, caries in, 786
Necrosis of alveolar process, 951
of bone, cause of, in alveolar abscess, 934
Nervæ vasorum, 327
Nerve, axis-cylinder of, 266
-centres, 263
eighth, 310
eleventh, 320
endings in gland-cells, 271
fibres, 264, 268
fifth, 282
table showing distribution of, 287
medullary, sheath of, 266
ninth, 310
non-medullary or pale fibres, 268
posterior superior dental, 290
seventh, 304
sixth, 282
supply of the peridental membrane, 919
tenth, 313
trifacial, 282
trigeminus, 282
twelfth, 322
Nerves, abdominal or terminal, branches of pneumogastric, 320
abducens, 282
alveolar dental, 290
anterior palatine, 301
superior dental, 291
articular, 294
ascending or orbital, 301
auditory, 310
auriculo-temporal, 294
buccal, 293, 309
cardiac branches of the pneumogastric, 319
centrifugal, 274
centripetal, 275
cervical or intramaxillary, 309
cervico-facial, 309
chorda tympani, 301
communicating branches of the facial, 306
compound, 277
cranial, 273
descending or descendens noni, 323
palatine, 301
digastric, 308

Nerves, division of fibres, 268
end-plates of Kühne, 272
external pterygoid, 293
facial, 304
first pair of, 277
fourth pair of, 281
frontal, 286
ganglion-cells of, 264
glosso-pharyngeal, 310
hypoglossal, 322
incisor, 297
inferior dental, 296, 297
maxillary, 292
or recurrent laryngeal, 318
infraorbital, 290
intratrochlear, 289
internal laryngeal, 318
nasal, 289
pterygoid, 293
lachrymal, 288
left pneumogastric, 315
lesser inferior dental (Sapolini), 297
superficial petrosal, 306
lingual, 295
long ciliary, 289
masseteric, 293
mental or labial, 297
middle deep temporal, 292
superior dental, 291
motor oculi, 280
peripheral end-organs, 272
mylo-hyoid, 290
nasal or oculo-nasal, 288
naso-palatine, 302
neurilemma of, 267
nodes and internodes of Ranvier, 267
occipital, 308
œsophageal, 320
branch of the pneumogastric, 320
of external auditory meatus, 295
of motion, 274
of pulp, 655
of muscles, 164
of sensation, 275
of skin, 145
of special sense, 275
olfactory, 277
ophthalmic, 286
optic, 278
orbital or temporal malar, 290
parotid, 295
pathetic, 281
pharyngeal or pterygo-palatine, 302
pneumogastric, 313
accessory portion of, 313
cervical or inferior ganglion of, 313
communicating of, 312
jugular or superior ganglion, 313
lingual or terminal branches of, 312
posterior auricular, 308
superior dental, 290
temporal, 293
pulmonary branches of the pneumogastric, 319
recurrent branch, hypoglossus, 323
right pneumogastric, 315
Nerves, second pair of, 278
sensory peripheral end-organs, 271
spheno-ethmoidal, 289
palatine, 290
spheroidal end-bulbs of Krouse, 272
spinal accessory, 320
stylo-glossal, 308
-hyoid, 308
superior maxillary, 290
supramaxillary, 309
supraorbital, 286
supratrochlear, 286
table of the branches of the fifth, 287
of the hypoglossal, 323
of the spinal accessory, 320
temporal, 308
third pair of, 280
thyro-hyoid, 324
tonsillar, 312
branches of, 312
trochlear, 281
tympanic, branches of, 312
of Wrisberg, 305, 310
Nervous system, 263
nerve-endings in gland-cells, 271
peripheral end-organs of motor nerves, 272
of sensory nerves, 271
Neural groove of embryo, 543
Neuralgia, dental, 837
Neurilemma, or sheath of Schwann, 267
Ninth nerve, 310
Nitric-acid treatment in capping, 896
Nodes of Ranvier, 267
Nodular dentine, 911
deposits in pulp, 862
Nodules in pulp-tissue, 914
Non-medullary or pale nerve-fibres, 268
Notidanus, teeth of, 372
Notochord or chorda dorsalis, 109
Nucleated red blood-cells, 44
Number of muscles, 166

O.

Obtundents, use of, 890
Occipital artery, 226
branches of, 226
posterior meningeal, branches of, 227
bone, 51
basilar process, 51, 54
pharyngeal, spine of, 51
crest, 53
groove, 60
nerve, 308
vein, 254
Occipito-frontalis aponeurosis, 167
muscle, 166, 167
mastoid suture, 51
parietal suture, 117
Oculo-motor nerve, 280
Odontoblastic layer, 640
Odontoblasts, 357, 569, 592, 641
atrophy of, 884
of dental pulp, pathological condition of, 882

Odontoclasts, 922
Olfactory apertures, 136
nerves, 277
Olivary process, 62
Omo-hyoid fascia, 157
muscle, 186
Ornithorhynchus, horny teeth of, 352
Operation for diseased alveolar process, 980
for scar on the face, 952
Opercular bones of codfish, 368
Ophidia, classification of, 388
Ophthalmic artery, 238
muscular branches of, 240
ganglion, 298
nerve, 286
Optic chiasm or commissure, 278
foramen, 133
foramina, 62, 67, 133
groove of sphenoid bone, 62
nerve, 278
tract, 278
Oral armature, 353
cavity, epithelium of, 199
muscles, 171
actions of, 174
Orbicularis oris muscle, 171
palpebrarum muscle, 168
Orbit, fascia of the, 178
muscles of the, 175
veins of, 261
Orbital cavity, 132, 133
plates, 75
process of malar bones, 99
of palate bone, 93
Organic layer of enamel, 608
Organization of blood-clot, 709
Origin of osteoblasts, 589
Orthocynodon, teeth of, 479
Orycteropus capensis, teeth of, 412
Ossa triquetra, 118
Osseous corpuscles, 41
Os lingua, 108
planum, 79
Ossein, 571
Osseous substance of matrix, 571
Ossification, 574
classification of, 577
of bone, 46
Osteoblasts, 42, 45, 575
origin of, 589
Osteoclasts, 43, 44, 922
Osteo-dentine, 880
Osteo-porosis, 47
Os unguis, 95
Otic ganglion, 302
Ovale, foramen, 65, 122
Ovarian egg, 540
Ovum, segmentation of, 543
Oxychloride of zinc for filling pulp-canals, 909
use of, in capping, 895
Oxychlorides in caries, 811
Oxygen in relation to fungi, 805
relation of fungi to, 824
Oxyphosphates in caries, 811
of zinc for filling pulp-canals, 909

P.

Pacchionian fossæ, 71
Pacinian corpuscles, 146
Pain in hyperæmia of dental pulp, 844
in inflammation, 693
Painless penetration of apical space, 928
Palatal process, 86
Palate, development of, 88, 551
bone, 90
Palatine glands, 207
spine, 91
vein, inferior, 251
Palato-Eustachian muscle, 197
-glossus muscle, 196
-pharyngeus muscle, 195
-quadrate arch of codfish, 368
Palpebral arteries, 241
Panniculus carnosum, 183
Papilla and enamel organ, connection between, 628
dental, 641
dentinal, 568, 622
of skin, 144
Parietal bone, 69
eminence 69
foramen, 70
foramina, 70, 117
fossa, 70
Parieto-mastoid suture, 117
-sphenoid suture, 117
-squamous suture, 119
Parotid arteries, 229
duct, 208
fascia, 209
gland, 207
glandula socia, 208
space, 208
veins, 253
Par vagus nerve, 313
Passive hyperæmia, 677
Pasteur, experiments of, 755
Pathological condition of odontoblasts of dental pulp, 882
Pathology, general, 661
of the dental pulp, 829
Peccary, teeth of, 485
Penetration of enamel in caries, 768
Pepper bags, 927
Peptonizing action of fungi, 824
Perforating fibres, 40
Pericementitis, apical, 923
phagedenic, 954, 968
Pericementum, formation of, 631
Perichondrium, 141
Peridental membrane, blood-supply of, 919
diseases of, 918, 921
function of, 920
nerve-supply of, 919
structure of, 918
Perimysium of muscles, 161
Periosteum, 42
Peripheral end-organs of nerves, 271
of jaw, development of, 629
separation of, in alveolar abscess, 932
Periptychus, teeth of, 470

Peroxide of hydrogen in alveolar abscess, 948
Perpendicular plate of ethmoid bone, 77
Petro-basilar groove, 127
suture, 51
Petrous portion of temporal bone, 55, 57
Phacochœrus, teeth of, 485
Phagedenic pericementitis, 954, 968
complicated with serumal calculus, 975
treatment of, 979
Pharyngeal arteries, 228
or pterygo-palatine nerve, 302
spine of occipital bone, 51, 127
teeth of fishes, development of, 361
vein, 254
Pharynx, muscles of the, 192
Phlebitis, 252
Physiological consideration of cells, 524
Physiology of the blood, 533
Phenacodus, teeth of, 472
Phenol camphor, 985
Phenomena of caries, 764
Pierce on calcification and decalcification of teeth, 645
Pigment of skin, 146
Pine marten, teeth of, 464
Pinna, shell of, 596
Pisces, definition of, 365
Pituitary fossa, 62
Placoid scales, 354
Plagiaulax, teeth of, 494
Plates, medullary, 548
Plethora, 673
Pleurodont dentition, 381
Plexus, infraorbital, 292
Pliolophus, teeth of, 477
Pneumogastric nerve, 313
abdominal branches, 320
anastomotic branches, 316
auricular branch, 316
cardiac branches, 319
communicating branches, 313
inferior laryngeal branch, 318
left, 315
meningeal branch, 316
œsophageal branches, 319
pharyngeal branches, 316
pulmonary branches, 319
right, 315
superior laryngeal branch, 316
table of, 315
Porcupine, teeth of, 468
Polyprotodontia, teeth of, 494
Polypus of pulp, 915
structure of, 915
treatment of, 916
Port Jackson shark, teeth of, 372
Portio dura, 304
mollis, 310
Posterior auricular artery, 227
nerve, 308
vein, 253
basal tubercle, 355
cerebral artery, 242
clinoid foramen, 124
Posterior communicating arteries, 243
condyloid foramina, 53
dental foramen, 103
ethmoid artery, 240
ethmoidal cells, 79
foramina, 75, 134
facial vein, 253
fossa of brain-case, 123
lacerated foramen, 52, 123, 127
median fontanelle, 119
nasal aperture, 131
occipital sinus, 258
palatine canal, 84, 91
region of the skull, 128
superior dental nerve, 290
temporal artery, 230
nerve, 293
Poultices in alveolar abscess, 947
Predisposing causes of caries, 770
Prefrontal bone of catfishes, 368
of codfish, 368
Premaxillary, 88
bones of codfish, 368
Premolar of dog, 354
cingulum of, 355
crown of, 354
fangs of, 354
neck of, 354
parts of, 354
Premolars, definition of, 399
Prevention of abrasion of teeth, 996
Prevertebral arteries, 228
fascia, 157
Primates, teeth of, 434
Primitive dentition, characters of, 392
streak, 547
trace, 543
Priodon, teeth of, 410
Prisms, enamel, 601
Proœlurus, teeth of, 458
Proboscidea, teeth of, 488
Process, alveolar, of inferior maxilla, 103
of superior maxillary bone, 86
anterior clinoid, 62
condyloid, 104
coronoid, 104
ethmoid, 94
external angular, 73
frontal, 98
hamular, 67
internal angular, 73
jugular, of occipital bone, 51
lachrymal, 94
malar, 85
maxillary, 94
of malar bones, 99
mental, 101
middle clinoid, 63
nasal, of superior maxillary bone, 85
of bones, 49
olivary, 62
orbital, 93
of malar bones, 99
palatal, 86, 91
posterior clinoid, 62
pyramidal, 92

Process, sphenoidal, 93
spinous, 49
styloid, 60
uncinate, 78
vaginal, 67
zygomatic, 99
Processes, condyloid, 128
dentinal, 594
pterygoid, 67
Products of the epiblast and mesoblast, 556
Prognosis in calcic inflammation, 968
Prosimiæ, teeth of, 431
Protopterus, teeth of, 377
Proximal end of bones, 49
surfaces, caries in, 779
manner of contact of, 772
Pseudælurus, teeth of, 458
Ptenoglossate teeth, 347
Pterygoid artery, 234
bones of codfish, 368
fossa, 67, 104
notch, 67
processes, 67
spinosus muscle, 182
Pterygoideus proprius muscle, 182
Pterygo-maxillary fissure, 130
-palatine artery, 235
foramen, 130
Pulmonary veins, 247
Pulmonates, jaws of, 349
teeth of, 349
Pulp calcification, symptoms of, 914
treatment of, 915
-canals, method of filling, 910
-chamber, dentinal tumors within, 872
hard formations within, 864
dental, 592, 636
exposure in caries, 767
irritation in dental erosion, 1007
mummified condition of, 893
nerves of, 655
-nodules, 862
polypus of, 915
-tissue, nodules in, 914
Pulpitis, origin of, 889
superficial, 891
Pulps, mummified, 910
Pulse, compressible, 666
dicrotous, 670
different characters of, 668
examination of, 653
frequency of, 664
how produced, 662
in aortic obstruction, 671
in lesions of the heart, 670
intermittent, 670
irregularities of, 669
qualities of, 665
Pus, burrowing of, 930
of chronic alveolar abscess, 937
through lower maxilla, 942
formation of, in apical space, 930
Putrefactive gases, generation of, 907
Putrescent pulp, causes of, 906
treatment of, 907
Pyramidal process, 92
Pyramidales nasi muscle, 168
Pyorrhœa alveolaris, 954

Q.

Quadratus menti, 173
Quinia as a germicide, 909

R.

Rabbit, deciduous teeth of, 469
teeth of, 469
Racemose glands, 203
Rachiglossate teeth, 346
Rachiodon, teeth of, 388
Radular apparatus, molluscan, 342
of mollusks, instructions for examining, 344
Rami of inferior maxilla, 103
Ramus cervicularis princeps, 227
Ranvier, nodes of, 267
Ranine artery, 222
Rat, teeth of, 466
Ratfish, teeth of, 375
Rattlesnake, fangs of, 389
Rays, teeth of, 373
Red blood-globules, diapedesis of, 679
cells of marrow, 45
marrow, 43
Region supplied by cranial nerves, 277
Regional Anatomy, 35
Regnard on caries, 735
Regurgitation, aortic, 671
Removal of calculus, 963
of dental pulp, 926
Reproduction of epithelium, 708
of tissue, 702
Reptilia, teeth of, 382
Resorption of the roots of temporary teeth, 922
of tissue, Ziegler on, 529
of tissues, 530
Results of fever, 717
Rete Malpighii, 617
Reticular layer of skin, 145
Reticulum stellate, 626, 640, 641
Retrahens aurem muscle, 175
Retzius, broken striæ of, 656
Rheumatic diathesis, 979
Rhinoceros, dental evolution of, 478
teeth of, 478
Rhiphidoglossate teeth, 347
Ridge, dental, 616
infraorbital, 84
Riggs's disease, 954
Right common carotid artery, 216
Risorus muscle, 173
Rivinus, duct of, 211
Robertson on caries, 735
Rodentia, teeth of, 466
Roof of mouth, 137
of nasal fossa, 135
Root-fillings after alveolar abscess, 952
obtrusion of, into apical space, 923
Roots of teeth, absorption of, 921

Roots of temporary teeth, resorption of, 922
Rostrum of sphenoid bone, 64
Round foramen, 65, 122

S.

Sacculus, dental, 361
Sagittal suture, 116
Salicylized cotton, 965
Salivary calculus, 960, 961
glands, compound tubular, 204
increased supply to, 672
muco-, 206
true, 205
Sanguinary calculus, 958
Sarcolemma, 162
Scalers, Cushing's, 964
Scaphoid fossa, 67, 126
Scar on the face, operation for, 952
Scarpa, foramina of, 86, 136
Schlenker on new formations, 914
Schroeder, experiments of, 754
Scrofulous diathesis, 979
Sea-urchin (Echinus), dental system of, 340
oral apparatus of, 339
Seal, teeth of, 449
Sealing gingival margins, 983
Sebaceous glands, 152, 560
Secondary dentine, 865–872, 911
causes producing, 912
formation of, 890
deposit in exposure of dental pulp, 886
deposits in dental erosion, 1007
formations resulting from metallic fillings, 913
resulting from wear of clasps, 913
Secretory glands of mucous membrane, 201
Sectorials, characters of, 402
Segmentation of ovum, 543
Sella turcica, 62, 68
Selenodontia, teeth of, 486
Semilunar ganglion, 284
Semnopithecidæ, teeth of, 436
Sensation, nerves of, 275
Sensitive dentine, treatment of, 890
Sensitiveness of the dentine, 1006
to thermal changes in dental pulp, 843
Sensory functions of dental pulp, 832
nerves, peripheral end-organs of, 271
tract in teeth, 1009
Septic abscess, treatment of, 950
Septum, fetal, 551
nasal, 135
Serrated sutures, 111
Serumal calculus, 958
Seventh nerve, 304
Sharks, teeth of, 370
Sharpey's fibre, 40, 47
Sheath of common carotid artery, 216
of Schwann, or neurolemma, 267
Shock, cause of, 719
from dental operations, 725–728
liability to, 724
molecular disturbances in, 722
symptoms of, 723
Shoulder-girdle of codfish, 365
Sigmoid groove, 61
of sphenoid bone, 63
notch, 104
Simiidæ, teeth of, 436
Simple exposure of dental pulp, 890
mucous tubular glands, 202
Sinus, anterior, occipital or transverse, 261
cavernous, 259
circular, 260
inferior longitudinal, 258
petrosal, 261
longitudinal, 75
lymph, 329
maxillary, 89
posterior occipital, 258
superior longitudinal, 258
sphenoidal, 63
spheno-palatal, 259
straight, 258
superior petrosal, 260
Sinuses, frontal, 73
lateral, 259
of brain-case, 123, 257, 259
venous, of the cranium, 257
Siphonaria, teeth of, 349
Sirenia, palatal plates of, 352
Sixth nerve, 282
Skin, 141
appendages of, 147
blood-vessels of, 145
derm, corium, or cutis vera of, 144
epidermis of, 143
epithelium of, 614
lymphatics of, 145
nerves of, 145
reticular layer of, 145
papilla of, 144
pigment of, 146
stratum corneum of, 144
granulosum of, 144
lucidum of, 144
Malpighii of, 144
tactile corpuscles of, 142, 146
true, 144
Skull, 50
and its articulations at different periods, 118
as a whole, 109
facial or anterior region of, 131
general development of, 109
lateral region of, 128
posterior region of, 128
Sloth, three-toed, teeth of, 411
Small meningeal artery, 233
Smilodon, teeth of, 463
Snakes, poison-glands of, 389
teeth of, 388
Sodium carbonate as an antiseptic, 909
Soft palate, muscles of the, 192
Softening of bone, 37
Space, apical, 918
Spaces, interglobular, 595, 766
Special sense, nerves of, 275
Species, transmutation of, 520
Sperm whale, teeth of, 414

Spheno-ethmoidal nerves, 289
-malar suture, 117
-maxillary fissure, 65, 99, 130, 134
fossa, 130
-palatal sinus, 259
-palatine foramen, 130, 136
ganglion, 299
nerve, 290
notch, 92
Sphenoid bone, 62
ethmoidal spine, 62
bone, optic groove of, 62
spinous process, 65
Sphenoidal fissures, 66
process of palate bone, 93
sinuses, 63
turbinated bones, 64
Sphygmographic tracings, 667, 668
Spinal accessory nerve, 320
table of, 320
Spinosum, foramen, 122
Spinous process of sphenoid bone, 65, 127
Sponge-grafting, 987
Spongy portion of bone, 35
Spontaneous generation, 521
Squamo-tympanic suture, 56
Squamous portion of temporal bone, 56
sutures, 111
Stellate bodies, 624
cells, 624
reticulum, 626, 640, 641
Stapedius or tympanic nerve, 307
Stellwagen on caries, 764
Steno's duct, 208
Sterno-cleido-mastoid muscle, 184
-hyoid muscle, 185
-mastoid artery, 220
-thyroid muscle, 186
Stetson, foramen of, 86, 136
Stoppings used in capping, 898
Straight sinus, 258
Stratum corneum, 144
granulosum, 144
intermedium, 362, 642
of Hanover, 625
lucidum, 144
Malpighii, 144
Stricker on inflammation, 699
Structure of cells, 523
of dermal denticles, 353
of enamel, 359
of gum, 955
of occipital bone, 54
of parietal bone, 71
of peridental membrane, 918
Styloid process of temporal bone, 60, 127
Stylo-glossus muscle, 191
nerve, 308
-hyoid ligament, 189
muscle, 189
nerve, 308
-mastoid artery, 228
foramen, 60, 127
-maxillary ligament, 115
-pharyngeus muscle, 194
Stypolophus, teeth of, 422
Subclavian arteries, 243
Sublingual artery, 222
fossa, 102
gland, 210
Submaxillary duct, 210
fascia, 157
fossa, 102
ganglion, 304
gland, 209
triangle, 188
Submental artery, 225
vein, 251
Subperiosteal bone formation, 47, 585
inflammation, 944
Succinea, teeth of, 349
Sudoriferous glands, 151
Sulphuretted hydrogen, generation of, in pulp, 907
in pulp-chamber, 893
Superciliary ridges, 73
Superficial fascia, 155
jugular ganglion, 311
or cranial arteries, 227
pulpitis, 891
treatment of, 904
temporal artery, 229
branches of, 229
muscular branches of, 229
vein, 252
Superior carotid triangle, 188
constrictor muscle, 192
coronary artery, 225
curved lines of occipital bone, 53
hyoid artery, 221
labial veins, 251
laryngeal artery, 220
longitudinal groove, 120
sinus, 258
maxillary bone, 81
bone, alveoli of, 87
nerve, 290
malar, branch of, 290
orbital or temporo-malar branch of, 290
spheno-palatine branch of, 290
temporal branch of, 290
meatus of nasal chamber, 79, 85, 136
oblique muscle, 177
ophthalmic vein, 261
pedicle of sphenoid bone, 67
petrosal sinus, 260
rectus muscle, 176
thyroid artery, 219
turbinated bone, 79
crest, 92
vena cava, 248
Suppuration of dental pulp, 853–855
Suprahyoid aponeurosis, 188
space, muscles of, 187
Supramastoid ridge, 56
Supramaxillary nerve, 309
Supraorbital arches, 73
artery, 240
nerve, 286
notch or foramen, 73
vein, 251

Suprascapular artery, 247
Supratrochlear nerve, 286
Surgical anatomy of the basilar process, 55
fever, 713
Sutura, 111–115
Suture, coronal, 117
fronto-malar, 117
-parietal, 117
-sphenoidal, 117
inter-parietal, 116
lambdoid, 117
occipito-mastoid, 51
-parietal, 117
parieto-mastoid, 117
-sphenoid, 117
-squamous, 117
petro-basilar, 51
sagittal, 116
spheno-malar, 117
squamo-tympanic, 56
temporo-parietal, 56
Sutures dentata, 111
harmonic, 111
of cranial vault, 116
of face, 117
of skull, 111, 115
serrata, 111
squamosa, 111
Sweat-glands, 151
Swelling in inflammation, 693
of dental pulp, 839
Sympathetic ganglia of fifth pair of nerves, 297
Symphysis menti, 132
Symptomatology of dental pulp, 832
Symptoms of shock, 723
Synchondrosis articulation, 112
Synostosis, 118
Synovial sac, 114
Systemic veins, 247

T.

Table of the branches of the facial nerve, 305
of the glosso-pharyngeal nerve, 311
of the pneumogastric nerve, 315
of the cranial sympathetic ganglia, 297
showing distribution of fifth nerve, 287
Tactile corpuscles, 142, 146
Tæniodonta, teeth of, 434
Tænioglossate teeth, 347
Tapiridæ, teeth of, 478
Tarsius spectrum, teeth of, 431
Tatusia hybridus, teeth of, 409
Taxeopoda, teeth of, 470
Tebennophorus, jaw of, 349
Teeth, calcification of, 363
development of, 360, 609
ecderonic, origin of, 352
enderonic, origin of, 353
epiblastic, derivation of, 353
faulty formation of, 770
general definition of, 352
histology of, 356
Teeth, hypoblastic derivation of, 353
occlusion of, in man, 445
origin of, in invertebrata, 352
of, in vertebrata, 352
Temnocyon, teeth of, 453
Temperature in fever, 711
in inflammation, 693
Temporo-facial nerve, 308
-maxillary articulation, 112
interarticulating disc of, 114
ligaments of, 113
synovial sac of, 114
vein, 252
Temporal bone, 55
fascia, 179
fossa, 128
muscle, 180
Tendo-oculi muscle, 169
Tendons, 158
Tenon, capsule of, 178
fascia of, 178
Tensor-palati muscle, 197
-tarsi muscle, 169
Tenth nerve, 313
Terms used in describing bones, 49
Thermal changes, sensibility of dental pulp to, 832–834
influences affecting the dental pulp, 888
Thoracic duct, 330
Three-toed sloth, teeth of, 411
Thrombosis, 679
Thrombus, formation of, 681
Thylocoleo, teeth of, 497
Thyro-hyoid muscle, 186
nerve, 324
Thyroid artery, superior, 219
axis, 246
Tillodonta, teeth of, 433
Tin in caries, 811
Tissue, areolar, 154
cartilage, 35
changes in hyperæmia, 845
in inflammation, 695
of dental pulp, 849
connective, 35
fibre, connective, 35
granulations, 704
muscular, 159
reproduction of, 702
resorption of, 530
Tobacco, action of, on caries, 808
smoke, action of, on caries fungi, 809
Tomes on calcification, 573
on caries, 741
processes, 642
Tonsillar artery, 224
nerves, 312
space, 213
Tonsils, 213
infra- or pharyngeal, 214
Toothbrush, mode of using, 966
Tooth-cartilage, 356
-germ, 361
-pulp, 357, 592, 636
arteries of, 358
lateral processes of, 358

Torcular Herophili, 124, 258
Toxodontia, teeth of, 476
Toxoglossa, teeth of, 343
Toxoglossate (arrow-toothed) dentition, 346
Trabeculæ cranii, 109
Tracheal artery, 247
Tracings, sphygmographic, 667, 668
Transplantation of epithelium, 708
Transverse artery, 220
  facial artery, 229
    vein, 253
Transversalis colli artery, 247
Treatment of alveolar abscess, 944
  of apical pericementitis, 926
  of calcic inflammation, 963
  of chronic alveolar abscess, 947
  of phagedenic pericementitis, 979
Triangle, submaxillary, 188
  supra-carotid, 188
Trifacial nerve, 282
Trigeminus nerve, 282
Triisodon, teeth of, 424
Tritonium (trumpet conch), jaw of, 334
Trochlear nerve, 281
  fossa or tubercles, 75
Trochlearis muscle, 177
True salivary glands, 205
  skin, 144
Trumpet conch (Tritonium), jaw of, 343
Tubercle of temporal bone, 56
  posterior basal, 355
Tubercle or tuberosity, 49
Tubercles, genial, 102
Tuberosity of superior maxillary bone, 85
Tubes, dental, 356
Tumors, dentinal, within pulp-chamber, 872
Tunic, inner, 640
Turbinated bone, inferior, 79
    middle, 79
    superior, 79
  crest, inferior, 92
    superior, 92
Twelfth nerve, 322
Tympanic artery, 232
  nerve, 311
  portion of temporal bone, 60

U.

Ulceration, 702
Uncinate process, 78
Unguiculate series, teeth of, 416
Ungulata, teeth of, 476
Ungulate series, classification of, 470
    teeth of, 469

V.

Vaginal process of sphenoid bone, 67
    of temporal bone, 60
Vampires, teeth of, 465
Variations in hardness of enamel, 602
  of common carotid artery, 218
Variety of muscles, 165
Vasa afferentia, 328
Vasa efferentia, 328
  vasorum, 327
Vaso-motor nerves, influence on the circulation, 673
Veins, 247
  angular, 249
  anterior jugular, 255
  common temporal, 252
  deep facial, 251
  diploic, 261
  emissary, 262
  external jugular, 255
  facial or anterior facial, 249
  frontal, 250
  inferior ophthalmic, 261
    palpebral, 251
    thyroid, 248
  innominate or brachio-cephalic, 248
  internal jugular, 256
    maxillary, 253
  left innominate, 248
  lingual, 254
  middle temporal, 253
  occipital, 254
  of head and neck, 281
  of neck, 254
  of orbit, 261
  pharyngeal, 254
  posterior auricular, 253
    facial, 253
  pulmonary, 247
  right innominate, 248
  submaxillary, 251
  submental, 251
  superficial temporal, 252
  superior labial, 251
    ophthalmic, 261
    or descending vena cava, 248
  supraorbital, 251
  systemic, 247
  temporo-maxillary, 252
  transverse facial, 253
Vena cava superior, 248
Venous sinuses of cranium, 257
Vents for putrefied pulp-canals, 910
Vertebral artery, 245
Vertebrata, teeth of, 351
Vertical crest of nasal bones, 97
  plate of palate bone, 92
Vesali, foramen of, 122
Vessels, lymphatic, 325
Vidian artery, 235
  canal, 65, 123
Virginia deer, teeth of, 488
  opossum, teeth of, 495
Voluntary muscles, 160
Vomer, 80
  development of, 81

W.

Walls of the brain-case, 120
Walrus, teeth of, 451
Wandering cells, 692
Wart-hog, teeth of, 485
Watt on caries, 745

Weasels, teeth of, 464
Wedl on polypus of the pulp, 916
Weight of bone, 37
Westcot, experiments of, 743
Wharton, jelly of, 566
Wharton's duct, 210
White blood-corpuscles in inflammation, 695
globules, diapedesis of, 692
corpuscles, 532
White, J. D., formula for nerve-paste, 900
Willis, circle of, 242
Wormian bones, 118
Wrisberg, nerve of, 310

Y.

Yellow marrow, 43

Z.

Zeuglodon, teeth of, 415
Ziegler on cell-proliferation, 526
on resorption of tissue, 529
Zona pellucida, 547
Zonites, jaw of, 349
Zygomatic fossa, 129
process of malar bone, 99
of temporal bone, 56
Zygomaticus major muscle, 172
minor muscle, 172

END OF VOLUME I.



UNIVERSITY OF CALIFORNIA LIBRARY
Los Angeles
This book is DUE on the last date stamped below.
Biomed. Lib. JAN 4 1972
Form L9—10m-5,'67(H2161s8)4939

3 1158 821